site www.jaypeebrothers.com, for detailed information on medicine books, visit our website www.jaypeebrothers.com



OSCE for Emergency Medicine Practical Exam

Including Short Cases & Multiple Choice Questions

Devendra Richhariya

Forewords
TV Ramakrishnan
Nadeem Qureshi

JAYPEE

Contents

SECTION I OSCE in Emergency Medicine

1. **Arterial Blood Gas Analysis OSCE 3**
   Khusrav Bajan, Sharath TR, Mahesh Vyankatrao Salunke
2. **Point-of-Care Ultrasound (POCUS) in Emergency OSCE 22**
   Sandeep Gore, Atur Mahant
3. **HAZMAT PPE Infection Prevention Waste OSCE 39**
   TV Ramakrishnan, Mona Lisa Janarthanan
4. **Drugs and Instruments 52**
   Mona Lisa Janarthanan, TV Ramakrishnan
5. **Resuscitation OSCE 62**
   Venugopalan PP
6. **Cardiovascular Emergencies OSCE 79**
   Maitha Almazrouei, Omar Ghazanfar
7. **Respiratory Emergencies OSCE 89**
   Bhawana Sharma
8. **Gastrointestinal Emergencies OSCE 100**
   AN Venkatesh
9. **Renal and Genitourinary Emergencies OSCE 107**
   Devendra Richhariya
10. **Neurological Emergencies OSCE 111**
    Gouri Ranade, Sakthi Muthalraju
11. **Endocrine Emergencies OSCE 124**
    Shweta Ashok
12. **Eye, ENT, and Oral Dental Emergencies OSCE 139**
    Nilanka Mudithakumara
13. **Dermatology Emergencies OSCE 148**
    Tejas D Patel, Nishi Trivedi
14. **Obstetrics and Gynecology Emergencies OSCE 168**
    Patibandla Sree Sowjanya

15. **Pediatric Emergencies OSCE: Part I 175**
Nadeem Qureshi

16. **Pediatric Emergencies OSCE: Part II 187**
Amritesh Ranjan, Preeti Dwivedi, Manish Agrawal

17. **Geriatric Emergencies OSCE 199**
M Sai Surendar

18. **Infectious Diseases Emergencies OSCE 208**
M Rajadurai, J Joshua Vijay

19. **Toxicology Emergencies OSCE 233**
S Senthilkumaran

20. **Trauma: Part I OSCE 246**
Sanjay Shah

21. **Pediatric Trauma: Part II OSCE 267**
Awaneesh Katiyar

22. **Environmental Emergencies OSCE 274**
Olita Shilpakar

SECTION 2 MCQs in Emergency Medicine

23. **Basic Concepts of Emergency Medicine MCQs 292**
Devendra Richhariya

24. **Recent Concepts in Emergency Medicine MCQs 302**
Devendra Richhariya

25. **Special Situations in Emergency Medicine MCQs 307**
Devendra Richhariya

26. **Prehospital and Disaster MCQs 318**
Devendra Richhariya

27. **Resuscitation MCQs 324**
Devendra Richhariya

28. **Intensive Care Management MCQs 330**
Devendra Richhariya

29. **Cardiovascular Emergencies MCQs 351**
Devendra Richhariya

30. **Respiratory Emergencies MCQs 376**
Devendra Richhariya

31. Gastrointestinal Emergencies MCQs 386
Devendra Richhariya

32. Genitourinary Emergencies MCQs 396
Devendra Richhariya

33. Neurological Emergencies MCQs 406
Devendra Richhariya

34. Endocrinal Emergencies MCQs 409
Devendra Richhariya

35. Eye, ENT, Oral, and Dental Emergencies MCQs 412
Devendra Richhariya

36. Hematology and Oncology MCQs 417
Devendra Richhariya

37. Dermatology Rheumatology Psychiatry MCQs 430
Devendra Richhariya

38. Obstetrics and Gynecology Emergencies MCQs 433
Devendra Richhariya

39. Pediatric Emergencies MCQs 442
Devendra Richhariya

40. Geriatric Emergencies MCQs 455
Devendra Richhariya

41. Infectious Diseases MCQs 461
Devendra Richhariya

42. Toxicology MCQs 471
Devendra Richhariya

43. Trauma MCQs 484
Devendra Richhariya

44. Environmental Emergencies MCQs 504
Devendra Richhariya

Index 519

6 CHAPTER

Cardiovascular Emergencies OSCE

Maitha Almazrouei, Omar Ghazanfar

QUESTIONS

Q1. **A 38-year-old male patient presents to the emergency department (ED) complaining of fever, chest pain, and shortness of breath with known history of IV drug abuse. Physical examination reveals a painful lesion as shown in image below.**

a. Name the clinical sign shown in the image.
b. Name two other clinical manifestations seen in this disease.
c. Mention two microorganisms which can be seen in this disease.

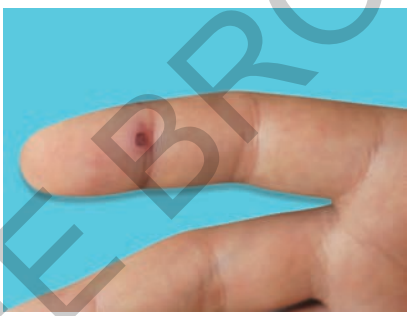

Q2. **A 25-year-old male presents to ED complaining of sharp left-sided chest pain and shortness of breath since last 1 day, the pain is worse on deep breathing. Past surgical history includes, recent left femur frature, post ORIF 3 weeks ago, chest X-ray shown below.**

a. Name the finding seen in the chest X-ray.
b. Mention three risk factors seen in this disease process.
c. Mention three abnormal physical findings seen in this disease.

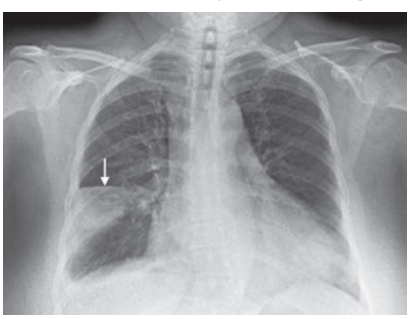

JAYPEE BROTHERS

Q3. **A 61-year-old male with history of hypertension and smoking presented to the ED with sudden onset of severe chest pain radiating to the back. Chest X-ray is shown in image below.**

a. Describe the finding in (1) and (2) shown in the chest X-ray.
b. Mention two risk factors from this condition.
c. Outline the treatment option of this disease process.

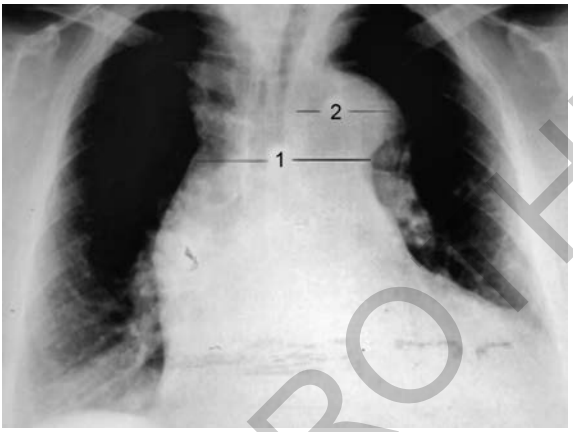

Q4. **Mention the three indications for the procedure shown in this image.**



Q5. **A 32-year-old male patient was brought to the ED after sustaining a gunshot wound in the midchest region. Bedside US image is shown in image below.**

a. Name the view and describe the finding seen in this US image.
b. Outline the treatment done in the ED.
c. Mention the three elements of a triad that can be seen in this pathology.

JAYPEE BROTHERS

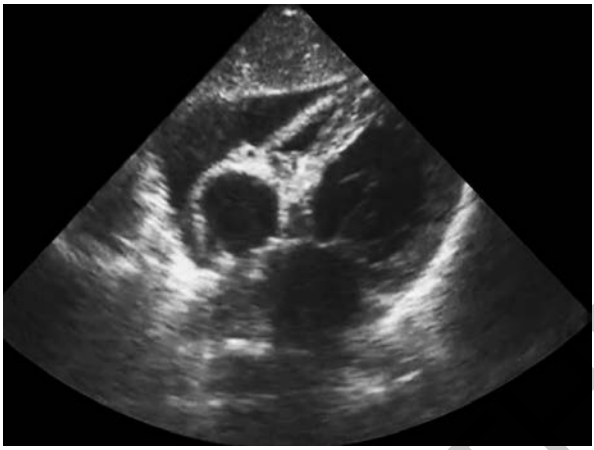

Q6. **A 65-year-old with a past medical history of hypertension and 30 pack-year smoking history is brought to the ED with a chief complaint of lower back pain.**

Vital signs are blood pressure (BP): 81/45 mm Hg, heart rate (HR): 112 beats/min, respiratory rate (RR): 22 breaths/min, O_2: 94% on room air (RA).

a. Describe the finding seen in the US.
b. Mention three risk factors of this condition.
c. Outline two treatment elements for this patient.

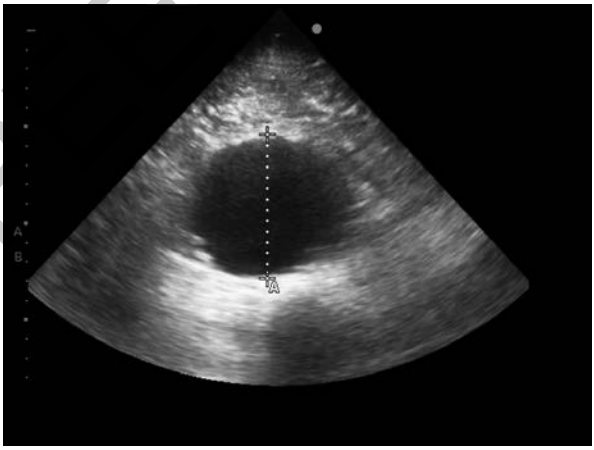

Q7. **A 55-year-old male presents to ED with history of chest pain, diaphoresis, shortness of breath, and orthopnea for 4 hours. Monitor was attached which shows vital signs: HR: 60 beats/min, RR: 22 breaths/min, BP: 97/60 mm Hg, O_2: 92% on RA. The ECG is shown in image below.**

JAYPEE BROTHERS

a. Describe the finding seen in the ECG.
b. Mention one laboratory test you would send in the ED.
c. Outline the definitive therapy.

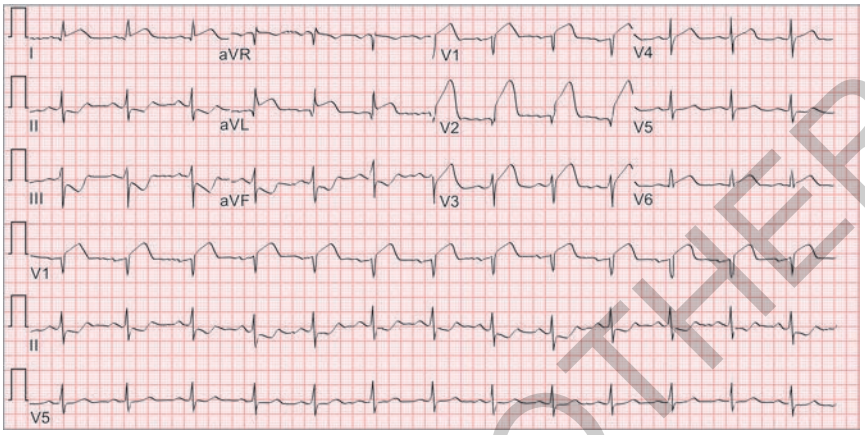

Q8. **A 1-week-old infant is brought to ED by his parents with complaint of central cyanosis. Oxygen saturation by pulse oximetry is 84% on maximal oxygen therapy, and chest X-ray is performed:**

a. Describe the finding seen in the chest X-ray.
b. Outline the drug treatment for this condition.



Q9. **A 55-year-old male presents to ED with long-standing hypertension and renal failure with complaints of generalized body and weakness fatigue. ECG is performed:**

JAYPEE BROTHERS

a. Describe two findings seen in this ECG.
b. Outline the cause of his condition.
c. Mention three treatment options for this patient.



Q10. **An 83-year-old man with previous coronary artery bypass grafting (CABG) and multiple percutaneous coronary interventions (PCIs) now presenting with breathlessness on exertion, three-pillow orthopnea, and bilateral lower limb edema. Interpret chest X-ray:**

a. Describe the finding marked by the arrows in the chest X-ray.
b. Describe two other radiological findings.
c. Mention three treatment options for this patient.



Q11. **A 1-month-old infant is brought to ED by his parents with complaints of fast breathing and irritable difficulty feeding.**

His vital signs are RR: 56 breaths/min, BP: 90/60 mm Hg, and HR: 200 beats/min. His skin is pink and capillary refill is about 2 seconds. The ECG is shown below.

a. What is the diagnosis of this condition?
b. Mention two treatment options for this patient.

JAYPEE BROTHERS

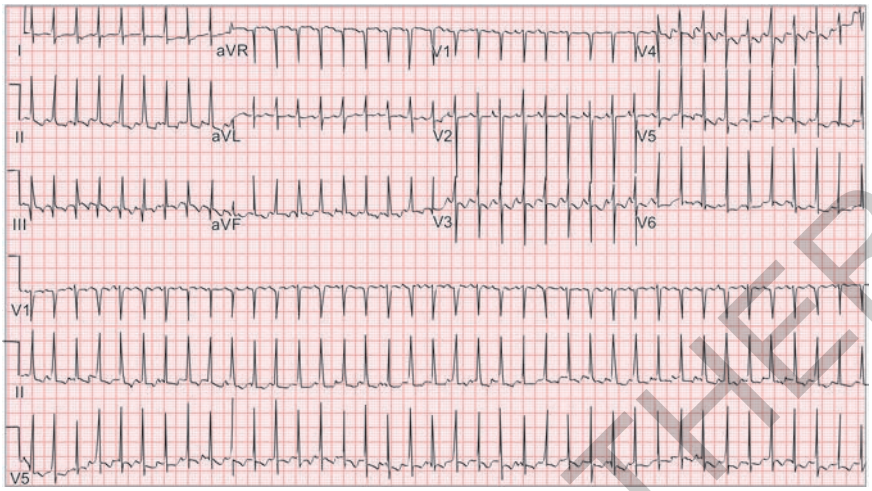

Q12. A 22-year-old male patient presents to the ED with complaints of palpitations 1 hour ago. The ECG is shown below.

a. Describe the finding seen in this ECG.
b. What is the management of this patient?

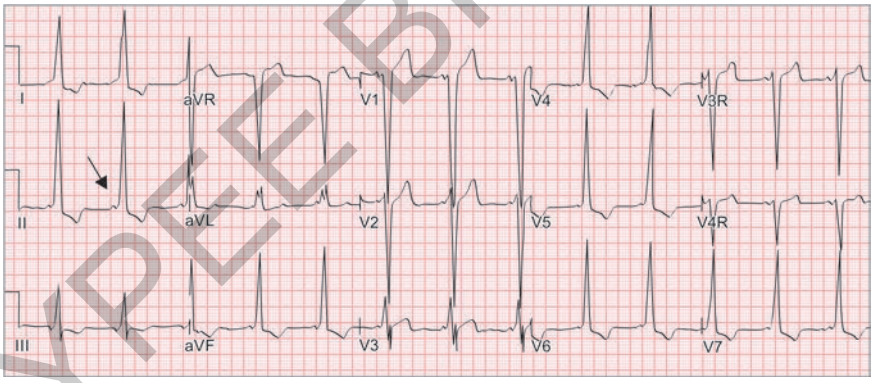

Q13. A 64-year-old female presents with lightheadedness in ED. No chest pain or shortness of breath.

Vital signs are HR: 170 beats/min, RR: 22 breaths/min, BP: 144/75 mm Hg, and O_2: 96% on RA.

a. Based on the case and ECG findings, what is the diagnosis of this condition?
b. Outline the treatment of this condition.

JAYPEE BROTHERS

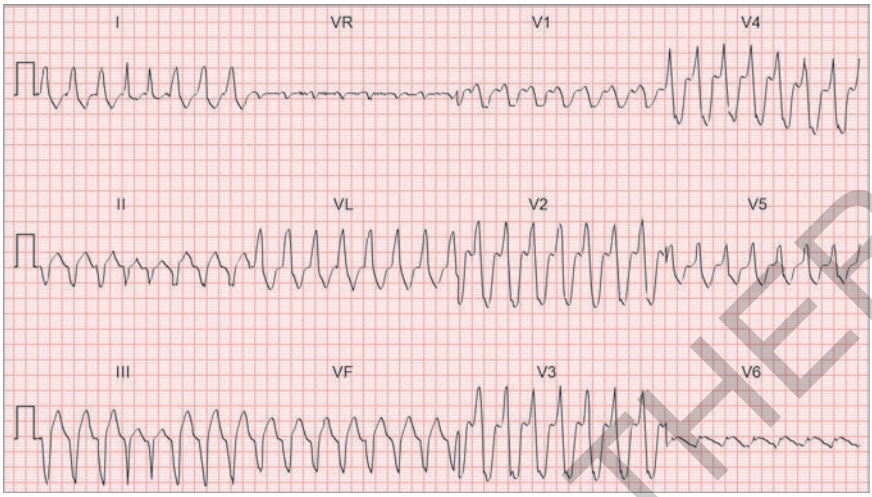

Q14. A 55-year-old male with past medical history of hypertension and type 2 diabetes presents to the ED with complaint of chest pain. The ECG is shown below.

a. Describe the ECG finding seen.
b. What is the anatomical distribution of this pathology?
c. Name the diagnosis.

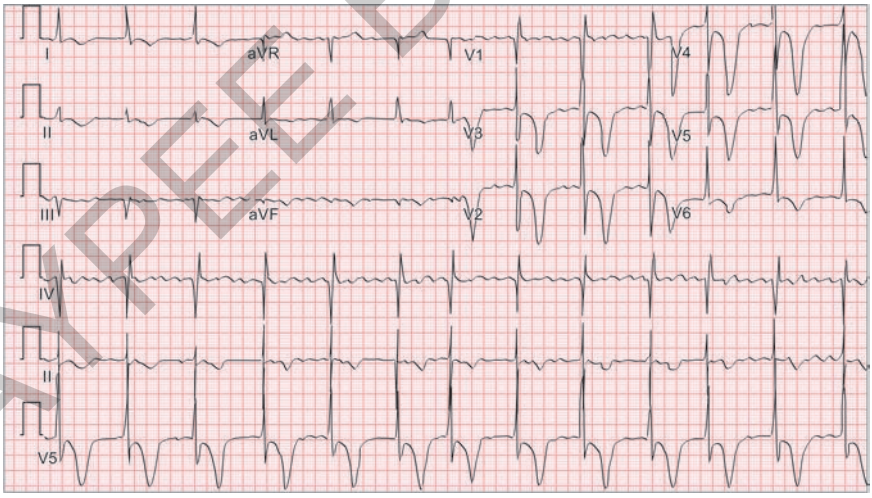

Q15. A 55-year-old male smoker presents to the ED with right-sided pleuritic chest pain, shortness of breath, and left leg pain without trauma.

JAYPEE BROTHERS

Vital signs are RR: 24 bmp, P: 115 bmp, BP: 88/40 mm Hg, and SaO_2: 94% on 4 L by nasal cannula (NC).

A computed tomography (CT) lung scan is performed and reveals the image as shown below:

a. What is the name of a risk stratification tool that would help you in the diagnosis?
b. Mention two treatment options that can help in this disease process.



ANSWERS

Ans. 1

a. Osler's nodes
b. Other clinical manifestations are Janeway lesions, splinter hemorrhage, and Roth spots.
c. Two microorganisms for this this disease are *Staphylococcus aureus* and *Streptococcus viridans*.

Ans. 2

a. A Hampton's hump is seen in the right peripheral lower lung field. Hampton's hump represents focal intraparenchymal hemorrhage due to infarction of lung parenchyma. A peripheral, homogenous, wedge-shaped, and pleural-based opacity with the apex pointing to the hilum.
b. *Risk factors:* Active cancer, trauma/surgery within past 4 weeks, recent travel, deep vein thrombosis (DVT), prior pulmonary embolism (PE), and pregnancy.
c. *Physical signs:* Tachycardia, tachypnea, hypoxia, and unilateral leg swelling.

JAYPEE BROTHERS

Ans. 3

a. (1) Widened mediastinum and (2) Prominent aortic knob
b. First connective tissue disease (Marfan and Ehlers–Danlos) and second patients older than 50 years with hypertension, bicuspid aortic valve, and pregnancy.
c. *Stanford type A dissection* involves the ascending and descending aorta and requires surgical repair. Aggressive blood pressure control and pulse control are needed to prevent on going dissection as surgical repair is planned.

Ans. 4

1. *Some indications:* Penetrating chest trauma with cardiac arrest and massive chest tube drainage
2. *Cardiac arrest following penetrating chest trauma:* Systolic blood pressure below 50 mm Hg after fluid resuscitation. Patient showing clinical signs of cardiac tamponade.
3. *Blunt trauma:* Cardiac arrest in the ED following blunt trauma of chest

Ans. 5

a. This subxiphoid view of the heart reveals a large pericardial fluid collection and compression of the right ventricle (RV) suggesting tamponade physiology.
b. Emergent pericardiocentesis
c. *Beck's triad:* Hypotension, muffled heart sounds, and jugular venous distension (JVD)

Ans. 6

a. An infrarenal abdominal aortic aneurysm (AAA), >5 cm around 7.47 cm in diameter.
b. Smoking, hypertension, male gender, family history, and dyslipidemia (DLP)
c. Resuscitate, transfuse blood products, and admit to operation room (OR) for surgical repair

Ans. 7

a. ST-segment elevation in the anterior lateral leads (V2-V6) acute ST myocardial infarction (STEMI)
b. High-sensitivity troponin
c. Immediate percutaneous transluminal coronary angioplasty

Ans. 8

a. X-ray chest showing enlarged, boot-shaped heart, consistent with tetralogy of Fallot.
b. *Treatment:* Prostaglandin E1; Stepwise approach should be adopted to manage tetralogy of Fallot; Oxygen, fluid resuscitation, morphine, and

JAYPEE BROTHERS

α-agonist therapy. Neonates may be benefited by prostaglandin E1. The major adverse effects of prostaglandin E1 are apnea and hypotension.

Ans. 9

a. This patient's ECG showing peaked T waves, a widened QRS interval.
b. Hyperkalemia
c. Calcium gluconate, insulin and dextrose, albuterol, Kayexalate, and dialysis

Ans. 10

a. Kerley B lines
b. Cardiomegaly, dilated pulmonary blood vessels, and mild right pleural effusion
c. Supplemental oxygen, noninvasive ventilation, diuretics, digoxin, angiotensin-converting enzyme (ACE) inhibitors, and β-blockers

Ans. 11

a. Supraventricular tachycardia (SVT)
b. Carotid sinus massage for 30 seconds Valsalva maneuver. If fails to convert, use adenosine

Ans. 12

a. δ delta wave; Shortened PR interval, and a delayed QRS upstroke
b. *Admission and pacemaker placement:* Procainamide is the treatment of choice in stable antidromic or irregular tachycardias in Wolff–Parkinson–White (WPW) patients, while amiodarone is considered a second-line agent. Unstable patients require cardioversion.

Ans. 13

a. The ECG shows a wide-complex, regular tachycardia, which is ventricular tachycardia (VT).
b. Amiodarone, procainamide, or lidocaine may be used to treat stable VT. Although cardioversion may be necessary for patients with hemodynamic instability.

Ans. 14

a. The ECG showing deeply inverted T waves in the anterior leads
b. Anatomical distribution of this pathology corresponds to left anterior descending (LAD) artery distribution. When, these inverted T waves associated with unstable angina indicate stenosis of the proximal LAD.
c. Diagnosis—Wellens syndrome

Ans. 15

a. Wells criteria
b. Tissue plasminogen activator (tPA) and surgical or catheter-based embolectomy

JAYPEE BROTHERS

for detailed information on medicine books, visit our website www.jaypeebrothers.com, for detailed information on me

OSCE for Emergency Medicine Practical Exam

Salient Features

OSCE for Emergency Medicine Practical Exam Including Short Cases & Multiple Choice Questions is a concise book for emergency medicine students. The textbook covers all the short and OSCE questions system-wise as per the emergency medicine curriculum examination pattern. This book will help exam-going emergency physicians in enhancing their clinical skills so that they can perform under pressure. This book will provide quality education to our upcoming emergency physicians to strengthen the clinical skills.

- The book consists of two sections. *Section 1*—OSCE in Emergency Medicine and *Section 2*—MCQs in Emergency Medicine
- System-wise short and OSCE questions including POCUS, trauma, toxicology, geriatric, and pediatrics are given
- Chapters consist of short and OSCE questions including infection, prevention, and HAZMAT disaster
- The book is recommended for students pursuing postgraduate degree, diploma, fellowship, or master's in emergency medicine.



Devendra Richhariya MBBS MD MBA (Hospital Administration) is a Senior Emergency Physician since the last 20 years. He is an Educator and a Mentor for national and international postgraduate emergency medicine students for fellowship program. He is also Author and Co-author of various textbooks, handbooks, and articles in national and international journals. He is the Chief Editor of *Textbook of Emergency Medicine including Intensive Care & Trauma, Solved Papers of Emergency Medicine for Postgraduate Students and Textbook for Emergency Medical Technicians* published by M/s Jaypee Brothers Medical Publishers (P) Ltd, New Delhi, India.

Printed in India

Available at all medical bookstores or buy online at www.jaypeebrothers.com

JAYPEE BROTHERS
Medical Publishers (P) Ltd.
EMCA House, 23/23-B, Ansari Road,
Daryaganj, New Delhi - 110 002, INDIA
www.jaypeebrothers.com

Join us on facebook.com/JaypeeMedicalPublishers

Shelving Recommendation
MEDICINE

ISBN 978-93-5696-622-2