rothers.com, for detailed information on dermatology books, visit our website www.jaypeebrothers.com, for detailed information on dermatology book

Under the Aegis of IADVL Academy

IADVL
Bedside Companion for Dermatology Residents



Editor
Biju Vasudevan







Associate Editor
Bhabani Singh

Assistant Editor
Shrikant Kumawat

Foreword
S Radhakrishnan

JAYPEE

Contents

1. **Bedside Tests in Dermatology: Introduction** 1
   Biju Vasudevan, Pankaj Das, Sreechithra Menon
2. **Light Microscopy in Dermatology** 6
   Kavita Bala Anand, Silky Priya
3. **Potassium Hydroxide Mount** 13
   Biju Vasudevan, Nitin Kumar Sharma
4. **Slit-skin Smear and Ziehl–Neelsen Stain** 26
   S Radhakrishnan, Binu Kunwar, Anand Mannu
5. **Tissue Smear and Giemsa Stain in Dermatology** 36
   Santhosh Battula, Senkadhir Vendhan, Nitin Kumar Sharma, Smriti Sharma
6. **Tzanck Smear** 44
   Vinay Gera, Senkadhir Vendhan, Nidhi Sharma, Sreechithra Menon
7. **Gram Stain** 54
   Vinay Gera, Abhinav Kumar Verma, Biju Vasudevan
8. **Bedside Tests in Sexually Transmitted Diseases** 63
   Nishu Bala, Senkadhir Vendhan, Sushmita Mishra
9. **Dark-field Microscopy** 76
   AW Kashif, Aneez Ali, Lalita Kumari
10. **Bedside Urine Tests** 84
    Vijayshankar Palaniappan, Ankan Gupta, Sunmeet Sandhu, Sreechithra Menon
11. **Wood's Lamp** 90
    Bhabani Singh, Sonal Jain, Prince Malla
12. **Diascopy** 101
    Pankaj Das, Silky Priya
13. **Intradermal Tests** 107
    Sampoorna Choudhary, Shekhar Neema, Dilip Paudel
14. **Patch Test and Other Allergen Tests** 118
    Abirami C, Chakravarti R Srinivas, Jamyang Choden

15. Calculation of Minimal Erythema Dose **126**
Durga Madhab Tripathy, Senkadhir Vendhan, Jamyang Choden

16. Pathergy Test **135**
Rahul Thombre, Smriti Sharma, Pankaj Das

17. Bedside Tests in Psoriasis **147**
K Lekshmipriya, Sushmita Mishra

18. Bedside Tests in Autoimmune Bullous Disorders **158**
Sidharth Bhat, K Lekshmipriya, Binu Kunwar

19. Urticaria and Related Disorders **166**
Karthi Kishore, Siva Chaitanya Senapathi, Sreechithra Menon

20. Bedside Tests for Peripheral Vascular Disease **178**
Bhabani Singh, Siddhartha Dash, Abhinav Kumar Verma

21. Demonstration of Ectoparasites **187**
Senkadhir Vendhan, Karthi Kishore, Prince Malla

22. Bedside Laboratory Tests in Hair Diseases **197**
Shrikant Kumavat, Siddharth Mani , Lalita Kumari

23. Bedside Tests to Detect Sweat Disorders **207**
Prachi Verma, Smriti Sharma, K Lekshmipriya

Index ***215***

CHAPTER 3

Potassium Hydroxide Mount

Biju Vasudevan, Nitin Kumar Sharma

INTRODUCTION

Potassium hydroxide (KOH) examination for fungal infections is a simple and cost-effective procedure and has a high sensitivity when performed by an experienced individual. It can be performed at a clinic on an outpatient basis, and the results are available within 1 hour. In experienced hands, a KOH mount is one of the most useful procedures in medical mycology, as it provides a rapid and accurate diagnosis in clinical settings where the diagnosis is in doubt. It has been adjudged more reliable than culture for the demonstration of dermatophytes. It is also helpful in the selection of appropriate culture media for the isolation of etiological fungal agents. In dermatology, a KOH mount of a skin scraping is a common procedure performed to demonstrate the evidence of fungal infection in skin, hairs, nails, and mucosa.

PRINCIPLE

Potassium hydroxide, a potent alkali, has the ability to soften, digest, and clarify tissues such as skin, hair, nails, or sputum when combined with specimens. This action targets the surrounding tissues, including keratin present in the skin, facilitating visibility of fungal hyphae and conidia (spores) under a microscope. Aqueous KOH effectively softens and digests protein debris, dissolving the cement substance-binding keratinized cells. As a result, fungal elements within clinical specimens become distinctly visible and easily observable.[1]

Procedure to make 100 mL of KOH 10% w/v solution:

- Weigh 10 g of KOH pellets
- Transfer the chemical to a screw-cap bottle
- Add 50 mL of distilled water and mix until the chemical is completely dissolved. Then, add the remaining distilled water to achieve a final volume of 100 mL.
- Label the bottle and mark it as corrosive. Store it at room temperature. The reagent remains stable for up to 2 years.

Caution: Potassium hydroxide is a highly corrosive deliquescent chemical. Handle it with great care and ensure the stock bottle of the chemical is tightly stoppered after use.

In a solution of KOH (10%), glycerol (10%) is added to prevent drying, as it is hygroscopic in nature and permits observations of the slide for up to 48 hours. The concentration of KOH may be increased depending upon the nature of the clinical material, as solid specimens require more than a 10% concentration, possibly up to 40%. Dimethyl sulfoxide (DMSO), a colorless organosulfur compound, can also be added to a KOH (20%) solution, which acts as a useful cleansing agent for fungi (KOH—20 g, DMSO—40 mL, and distilled water—60 mL). The wet mount

JAYPEE BROTHERS

with DMSO can be examined immediately without waiting for dissolution.

PREREQUISITE/MATERIAL REQUIRED

- *Equipment*: Microscope
- *Reagents and laboratory wares*:
  - Glass petri dishes
  - Clean and grease-free glass slides
  - Cover slips
  - Straight or bent wire
  - Needle
  - Bunsen burner
  - 10–20% KOH combined with a contrast dye of choice (KOH with DMSO optional)
- *Specimens*: It may vary according to the site of infection.

PROCEDURE OF POTASSIUM HYDROXIDE MOUNT

The standard method involves the following steps:[2,3]

1. The procedure should be explained to the patient in a language he or she understands, and written informed consent should be obtained beforehand.
2. The area is cleansed with water or spirit to eliminate dirt or any topical applications.
3. Utilize the blunt edge of a scalpel (No. 15 blade) to gather the specimen onto a clean glass slide and collect the scraping from the active margin in adequate quantity.
4. Alternatively, the specimen can be gathered on presterilized black chart paper, black card, or cellophane tape for transportation purposes.
5. The quantity and quality of the material examined significantly impact the availability of optimal results.
6. Once the scrapings are on the glass slide, add 1–2 drops of 10–20% KOH for hair and skin samples and 20–40% KOH for nail samples. Gently cover with a glass slip, lightly pressing and using a side-to-side technique to flatten the scale layer and mobilize excess solution to the edge. Any surplus solution can be gently blotted away using a paper towel, lens paper, or tissue.
7. Before microscopic visualization, the slide should be heated with a methanol burner to hasten keratinocyte digestion. However, caution is essential to avoid overheating the specimen, which can induce KOH crystallization and lead to artifacts. Sampling from hair and nails might necessitate prolonged heating to digest the denser keratinous material. In cases of thicker skin or hair lesions, leaving them for an hour enables adequate digestion of debris and intercellular substances. For nail specimens, a longer digestion time of up to 24 hours may be necessary.
8. To identify fungal elements, examine the slide under 10× magnification and study fungal morphology under 40× magnification. Partially close the condenser to lower the light intensity, providing better contrast. An excessively intense light source might diminish contrast, leading to potential oversight of unstained fungal elements.

PRECAUTIONS

- Ensure the KOH drop is not so large that it causes the cover slip to float.
- If kept outside a moist chamber, KOH dries, forming crystals that restrict the visibility of the fungus.
- After clearing, apply gentle pressure on the cover slip's top using a fold of filter paper or the handle of a teasing needle. This ensures even spreading of the material onto the slide.
- Fungal spores or hyphae may contaminate the laboratory's KOH solution, potentially yielding false-positive results. Therefore, a daily negative control should be established.

JAYPEE BROTHERS

- Wash off any applied medication or cloth fibers with distilled water before collecting the sample.
- Excessive scales collected may heap up dissolved keratin, potentially interfering with the results. To prevent this, avoid mounting scales excessively when placing them on the glass slide.
- Avoid excessive heating of the slide to prevent KOH crystal formation.
- Inadequate sample collection or previous treatment with antifungals might result in false-negative outcomes. If clinical suspicion remains high, consider repeating the test.[3,4]

APPLICATIONS (TABLE 1)[5]

In dermatology, the KOH mount is primarily used to diagnose superficial fungal infections. Many other cutaneous disorders that resemble fungal infections in clinical morphology, such as psoriasis, various forms of eczema, and pityriasis rosea, can be quickly ruled out by a positive KOH test. This negates the need for a biopsy in many cases. The KOH mount is also valuable in ruling out fungal infections in conditions, such as erythema annulare centrifugum, lichen planus, cutaneous T-cell lymphoma, and parapsoriasis, which might otherwise be mistaken for superficial fungal infections.

TABLE 1: Potassium hydroxide (KOH) mount application with finding under light microscopy.

Suspected conditions	Specimen	Diagnostic characteristics
Dermatophytes	Skin scrapings, nails	Long branching septate hyphae, arthroconida or spherical yeast cells, depending on the etiologic agents involved
Tinea capitis infection	Hair	May show either endothrix pattern in which spores are seen in the hair shaft or ectothrix pattern where spores arealso seen on the external surface of the hair shaft
Tinea versicolor	Skin scrapping	Clusters of short hyphae and spores; referred to as "spaghetti and meatballs" or "banana and grapes"
Tinea nigra	Skin scrapping	Brown branching septate hyphae and budding cells of *Hortaea werneckii*
Bacterial vaginosis	Vaginal fluid	Few KOH drops to vaginal discharge give fishy odor. On light microscopy, "clue cells" will be seen
Blue neck syndrome	Skin scrapings	Nematode larvae can be seen
Mycotic keratitis	Debrided epithelium from corneal ulcers appearing as whitish flakes	Examined for molds (*Aspergillus*, *Fusarium*, or *Nocardia* species)
Mucormycosis	Exudates from infected lesions or tissue	Aseptate hyphae
Chromoblastomycosis	Scrapings from crusted lesions	Muriform cells (aggregation of dark brown cells that resemble stones in a wall) or round and brown sclerotic bodies of 4–10 µm diameter with fission planes. They resemble copper pennies
Candidiasis	Curdy white discharge from infection site	Pseudohyphae (nonseptate hyphae) and round to oval yeast bodies
Aspergillus infection	Sputum	Septate hyphae with V-shaped branching
Blastomyces dermatitidis infection	Pus, sputum, or skin specimens	Yeast cells (large budding yeast cells with distinct broad base) of *B. dermatitidis*. *B. dermatitidis* is a dimorphic fungus with yeast cells in tissue

JAYPEE BROTHERS

Various indications and methods of collecting specimens are briefly explained herewith:[6]

- *Dermatophyte infection*: Dermatophytes are ascomycetes with septate hyphae that cause mostly superficial diseases in humans and other mammals. There are three genera of dermatophytes, (1) *Trichophyton*, (2) *Microsporum*, and (3) *Epidermophyton*. Although the species were historically divided into these genera by morphology and physical attributes, recent analysis by ribosomal ribonucleic acid (rRNA) sequencing indicates that the dermatophytes as a whole are a cohesive group with no clear distinction between the three genera. The diseases that result from a dermatophyte infection are known as tineas. The location of the disease on the body further defines the disease, so that tinea pedis is a dermatophyte infection of the feet, tinea cruris of the genitals, tinea corporis of the torso, and tinea capitis of the head. There are at least 40 species of dermatophytes that infect humans, and many of these fungi can cause disease in more than one body location. The most prevalent cause of tinea pedis is *Trichophyton rubrum*, and the most prevalent causes of tinea capitis are *Trichophyton tonsurans* and *Microsporum canis*. *Tinea nigra* is an uncommon dermatomycosis typically presenting on palmoplantar surfaces of the body and rarely occurs on interdigital surfaces. *Hortaea werneckii*, the underlying fungus, develops a melanin-like substance in the stratum corneum, resulting in the development of asymptomatic brown macules and patches with irregular borders. These pigmented lesions are concerning for melanocytic nevi or melanoma.[7]
    - *Dermatophyte skin infection:* Lesions suspected to harbor underlying fungal pathology are identified. The advancing border, known for its heightened fungal activity, serves as the optimal site, yielding superior results. In the majority of tinea plaques, an advancing rim characterized by erythematous papules and vesicles presents the ideal locations for scrapings. For enhanced accuracy, it is advisable to collect samples from multiple sites. Skin scrapings can be collected using the edge of a clean glass slide or the blunt end of a surgical blade **(Fig. 1)**. Collecting an adequate sample is crucial to obtain a higher yield of fungal elements. Insufficient sampling may lead to false-negative results. KOH examination reveals refractile and branching fungal hyphae of dermatophytes **(Figs. 2 and 3)**. In cases of tinea nigra, KOH examination of scrapings shows colonies of brown, septating, and branching hyphae with spores.
    - *Dermatophytic infection of hairs*: Various samples, including plucked hair, epilated hair, hair stubs, and matted hair crusts, hold significant value for examination. Ensure to incorporate skin scrapings from the surrounding infected scalp when preparing your hair mount. When dealing with lusterless hair close to the surface, use sterile epilation forceps



FIG. 1: Fungal sample collection technique.

JAYPEE BROTHERS

to pluck it along with its root. Woods lamp can be used to identify infected hair strands, manifesting yellow-green fluorescence for *Microsporum* species and bluish-green for *Trichophyton schoenleinii*. To aid in clearing, keep the hair shaft length under 5 mm. In the case of tinea capitis, gather scale scrapings from the base of broken hair and the affected scalp. Dermatophyte infection of hair reveals spores on a KOH mount, either within the hair shaft (endothrix) or outside it (ectothrix). Ectothrix spores appear grouped and attached outside the hair cortex. Conversely, in endothrix, these spores are not only densely packed inside the hair cortex but might also extend outside the cortex, potentially associated with hair shaft dystrophy **(Figs. 4 to 6)**. *T. tonsurans* commonly causes tinea capitis in children, recognized as "black dot ringworm" due to short and dark broken hairs resembling black dots. Ensure to sample and examine these hairs for endothrix spores.



FIG. 2: Clinical image of tinea corporis.

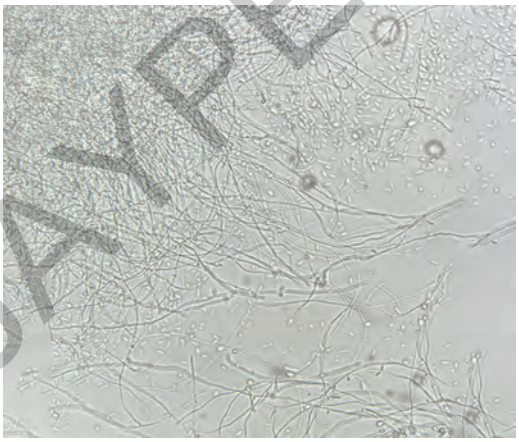

FIG. 3: Potassium hydroxide (KOH) mount showing refractile and branching fungal hyphae of dermatophytes (40×).

- *Dermatophytic infection of nails*: Fungal infection of the nail unit can impact any part of the nail structure be it the nail plate, nail matrix, or nail bed. Its presentation involves various discolorations, such as white or yellow-brown, violaceous, green, or black patches on the nail. Clinical signs also encompass subungual hyperkeratosis, separation of the nail from the nail bed (onycholysis), and thickening of the nail plate (onychauxis). The condition of onychomycosis can be categorized into five distinct clinical subtypes based on the pattern of invasion: (1) distal lateral subungual onychomycosis, (2) white superficial onychomycosis, (3) proximal subungual onychomycosis, (4) endonyx onychomycosis, and (5) total dystrophic onychomycosis. Nail clippings, avulsed nails, subungual debris, and the under surface of nail plates are suitable samples for diagnosing onychomycosis. For better visualization, nail clippings should not exceed 2–3 mm in thickness. Preferably, collect clippings from proximal areas targeting white or yellow, crumbly regions, as these areas commonly

JAYPEE BROTHERS



FIG. 4: Clinical image of tinea capitis in siblings.

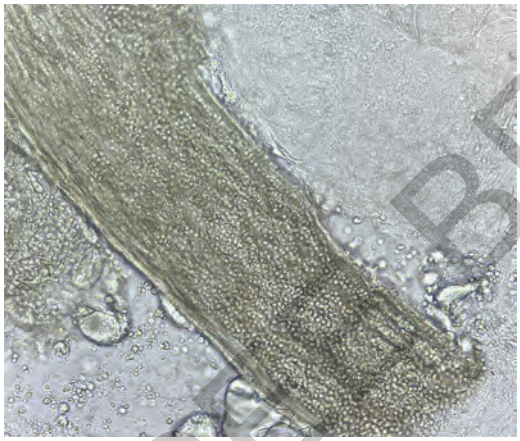

FIG. 5: Potassium hydroxide (KOH) mount of hair with ectothrix (40×).



FIG. 6: Clinical image of tinea capitis.

indicate active infection. If no distinct affected area is visible, sampling from the distal subungual debris is suitable, aiming to obtain material from the most proximal involved area. If suspecting paronychia, a *Candida* skin infection impacting the periungual skin, collect pus from beneath the nail fold for microscopic examination. This can be achieved by compression or incision using a number 11 scalpel blade on the inflamed tissue. The collected sample should be immersed in 40% KOH on a clean grease-free glass slide for 2 hours or more (up to 48 hours) until softening or digestion of the specimen occur (gentle heat should be applied to facilitate keratin clearance). Examination under low- and high-power objectives reveals the presence of hyphae or pseudohyphae **(Figs. 7 and 8)**.

- *Pityriasis versicolor*: Tinea versicolor, also known as pityriasis versicolor, is

JAYPEE BROTHERS



FIG. 7: Clinical image of onychomycosis both thumbs.



FIG. 8: Potassium hydroxide (KOH) mount of nail showing branching fungal hyphae (40×).

cause by dimorphic lipophilic and lipid-dependent yeasts of the genus *Malassezia* (formerly known as *Pityrosporum*) species, notably *Malassezia globosa* (*M.globosa*)and*Malasseziafurfur*.Patients with tinea versicolor typically present with asymptomatic hypopigmented (thought to result from damage to melanocytes and inhibition of tyrosinase by azelaic acid) or hyperpigmented (may result from a hyperemic inflammatory response elicited by *Malassezia* species), finely scaled, oval or round macules/



FIG. 9: Clinical image of pityriasis versicolor (anterior of trunk).

patches on the trunk and upper arms. Patients can have pruritus, particularly when the condition is more extensive. The term "versicolor" refers to the variable colors of the skin lesions that may occur in this disorder. Clinical manifestations of tinea versicolor are myriad, and the differential diagnoses are broad. Scaly hypopigmented or hyperpigmented lesions are identified and scratching the lesion can accentuate the scales (known as Besnier's sign). Collecting scrapings from the scaly edges often yields good results. When subjected to a KOH examination, scrapings from these lesions exhibit a distinctive appearance, described as "banana and grapes" or "spaghetti and meatballs" appearance which corresponds to the hyphae and spores, respectively **(Figs. 9 to 12)**.[8]

- *Candidiasis*: Candidiasis, an opportunistic infection caused by *Candida*, a eukaryotic fungus found in various forms, such as yeasts, molds, or dimorphic fungi. Diverse species of *Candida* exist, such as *Candida albicans*, *Candida glabrata*, *Candida krusei*, *Candida parapsilosis*, *Candida pseudotropicalis*, *Candida stellatoidea*,

JAYPEE BROTHERS



FIG. 10: Clinical image of pityriasis versicolor (posterior of trunk).

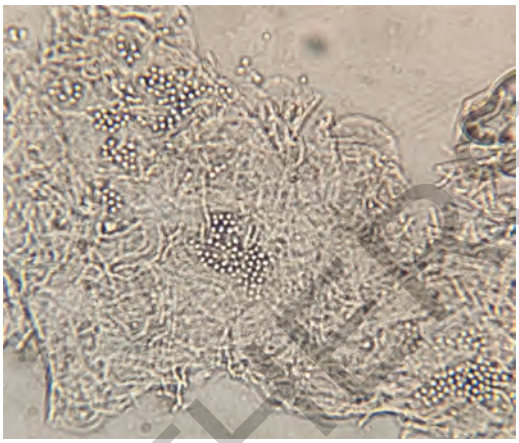

FIG. 12: Potassium hydroxide (KOH) mount of skin scrapping showing "spaghetti and meatballs" appearance which corresponds to the hyphae and spores (40×).



FIG. 11: Potassium hydroxide (KOH) mount of skin scrapping showing "spaghetti and meatballs" appearance which corresponds to the hyphae and spores (40×) (in another patient).

and *Candida tropicalis*. This infection commonly manifests as a secondary ailment in immunocompromised individuals, affecting oral cavity, vagina, penis, or other body parts. Oral candidiasis, often referred to as thrush, typically exhibits as white patches on the tongue and throat, accompanied by soreness and difficulty swallowing. It may manifest in various forms, such as pseudomembranous, erythematous, or chronic hyperplastic candidiasis. Vaginal candidiasis presents with symptoms, such as genital itching, burning sensations, and curdy white "cottage cheese" like discharge from the vagina. Yeast infections affecting the penis are less common and may show up as an itchy rash. Samples are collected based on the site of infection. For instance, curdy white discharge may be gathered from the oral cavity, vagina or glans penis, satellite pustules of cutaneous lesions, diaper area, web spaces, and nail clippings can be obtained. KOH mount will demonstrate budding yeasts, hyphae, pseudohyphae (nonseptate hyphae), and round to oval yeast bodies **(Figs. 13 and 14)**.[9]

- *Demonstration of fungi from cutaneous lesions of deep fungal infections*: Deep fungal skin infections are chronic diseases, caused by various groups of fungi. The clinical spectrum of these infections can be classified into (1) subcutaneous mycoses and (2) systemic mycoses. *Subcutaneous mycoses* occur when fungi like sporotrichosis, mycetoma,

JAYPEE BROTHERS



FIG. 13: Clinical image of oral candidiasis.



FIG. 15: Clinical image of pheohyphomycosis.



FIG. 14: Potassium hydroxide (KOH) mount of scrapping showing budding yeasts, hyphae, pseudohyphae (nonseptate hyphae), and round to oval yeast bodies (40×).



FIG. 16: Potassium hydroxide (KOH) mount of skin scrapping showing branching fungal hyphae of pheohyphomycosis (40×).

chromomycosis, and lobomycosis traumatically introduced into the skin and subcutaneous tissue. Systemic mycoses are caused by "true" fungal pathogens and opportunistic fungi. The "true" fungal pathogens are agents of histoplasmosis, blastomycosis, coccidioidomycosis, and paracoccidioidomycosis. The opportunistic deep mycoses comprise a spectrum of diseases including zygomycosis, cryptococcosis, aspergillosis, pheohyphomycosis **(Figs. 15 and 16)**, and hyalohyphomycosis.

- *Cutaneous cryptococcosis*: Placing a drop of serum or exudate from a lesion onto a slide with a few drops of 10% KOH and India ink reveals the capsulated forms of *Cryptococcus* **(Figs. 17 and 18)**.
- *Chromoblastomycosis*: Examining a KOH mount of skin scrapings from lesion surfaces displays sclerotic or muriform fungal cells **(Figs. 19 and 20)**.
- *Blastomycosis*: Observing a KOH mount of pus, skin scrapings, or sputum showcases round and

JAYPEE BROTHERS



FIG. 17: Clinical image of cutaneous *Cryptococcus* infection.



FIG. 19: Clinical image of chromoblastomycosis.



FIG. 18: Potassium hydroxide (KOH) mount of skin scrapping and India ink showing the capsulated forms of *Cryptococcus*.



FIG. 20: Potassium hydroxide (KOH) mount of skin scraping showing the copper penny body of chromoblastomycosis.

refractile spherical cells featuring broad-based buds.

- *Mycetoma*: It is a chronic subcutaneous granulomatous inflammatory disease caused by several true fungi and bacteria, and hence, it is classified as eumycetoma and actinomycetoma, respectively. The disease is characterized by numerous deformations and disabilities, high morbidity, and in its late stage it is potentially fatal. The triad of a painless subcutaneous mass, multiple sinuses, and discharge that contains grains of different colors, sizes, and consistency is characteristic of mycetoma. The grains can be directly examined under light microscope using 10% KOH, which can help in ruling out actinomycotes as causative agents by additional characteristic features identification **(Fig. 21)**.

JAYPEE BROTHERS



FIG. 21: Clinical image of mycetoma.

- *Bacterial vaginosis*: Bacterial vaginosis frequently occurs in sexually active women of childbearing age and is a common cause of vaginitis. To diagnose it, the vaginal fluid collected after removing the speculum should undergo pH testing. Few drops of 10% KOH should to be added to the discharge on a glass slide, and then sniffed to detect a fishy odor and wet mounts examined under light microscopy will demonstrate clue cells' of *Gardnerella*.
- *Mycotic keratitis*: A strong clinical suspicion, meticulous corneal scraping (deep scrapping) using a No. 15 blade on a Bard–Parker handle, and a comprehensive microscopic analysis of direct smears result in a high sensitivity of the 10% KOH smear. Samples of debrided epithelium from corneal ulcers, manifesting as whitish flakes, are directly mounted in 10% KOH for examination to detect molds (such as *Aspergillus* and *Fusarium*), yeasts, or *Nocardia* species.
- *Blue neck syndrome*: This condition is prevalent in Northern Kerala. The affected skin displays a dry, dull, and matte surface with a characteristic bluish-black hue, showcasing distinctive pigmentation of skin surface and clearly visible nonpigmented grooves in the skin folds. When skin scrapings from the neck are examined under a microscope using KOH mounts, nematode larvae are visible.

ADVANTAGES

- Economical, swift, and easy-to-perform test
- Minimally invasive procedure
- Requires minimal infrastructure
- KOH is a reliable outpatient procedure that yields quick results. Although fungal culture is a good confirmatory test for identifying fungus, it is more expensive and takes a minimum of 3 weeks to obtain results.
- KOH can serve as a primary screening tool for detecting fungal elements in hair, skin, nails, and sputum samples.[4]

LIMITATIONS

- Sensitivity of test depends on the operator's expertise
- Pus and sputum may contain artifacts that superficially resemble hyphal and budding forms of fungi. These artifacts may be produced by cotton or wool fibers, starch grains (in pleuritis), or cholesterol crystals.
- It only provides an idea about the presence of hyphal elements but cannot distinguish different fungi.
- Preparations cannot be kept for too long, although drying can be prevented by keeping the slides in a moist chamber.
- Wrong interpretations may lead to false-positive or false-negative results.[3]

CHICAGO SKY BLUE AND CALCOFLUOR-WHITE STAINS

Potassium hydroxide mount is the standard bedside laboratory technique for confirming

JAYPEE BROTHERS

dermatophytosis while culture is used to identify the species. However, KOH mount results in a lot of false negative results while culture takes a long period of about 4–6 weeks to yield results but identifies the species. Calcofluor-white staining observed under a fluorescent microscope has been found to detect dermatophytes with good efficacy in a few studies previously. Chicago sky blue stain is a new contrast stain for detecting dermatophytes rapidly and at a low cost. Chicago sky blue stain is a contrast stain that can help to distinguish between hyphae and epithelial cells and is used together with KOH as a clearing agent. When stained, fungal filaments appear distinct blue against a pale or purple background.

Calcofluor-white stain is a nonspecific fluorochrome that binds with cellulose and chitin contained in the cell walls of cellulose-containing organisms and facilitates the visualization of pathogenic elements.

This diagnostic test has showed significantly higher sensitivity, specificity, positive predictive value, negative predictive value, and accuracy, with very low rates of false-positive and false-negative results **(Figs. 22 and 23)**.[10]

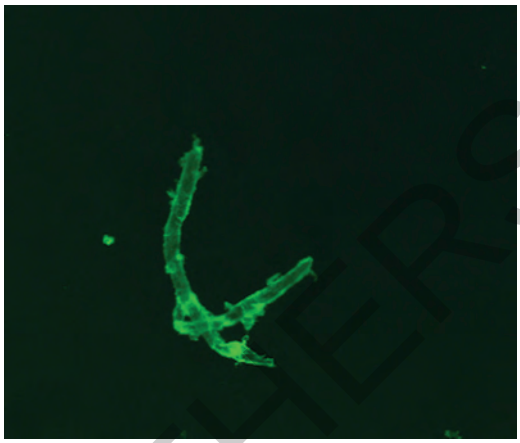

FIG. 22: Calcofluor-white staining observed under a fluorescent microscope demonstrating fungal elements.



FIG. 23: Calcofluor-white staining observed under a fluorescent microscope demonstrating fungal elements.

CONCLUSION

In conclusion, the KOH mount procedure stands as a fundamental and cost-effective tool in dermatology for diagnosing fungal infections in skin, hair, nails, and mucosa. Its simplicity, rapid results, and minimal invasiveness make it invaluable in clinical settings where timely and accurate diagnoses are crucial. While the KOH mount offers high sensitivity, it does come with certain limitations, such as dependency on operator expertise and the potential for false-positive or false-negative results. However, advancements in complementary staining techniques like Chicago sky blue and Calcofluor-white stains are promising additions, enhancing accuracy and reducing diagnostic errors. The versatility of the KOH mount extends beyond fungal infections, aiding in distinguishing various cutaneous disorders and guiding appropriate treatment paths. Despite its limitations, when performed meticulously and in conjunction with other diagnostic tools, the KOH mount remains an indispensable initial screening method, providing critical insights for dermatological diagnosis.

JAYPEE BROTHERS

Key Messages

- KOH mount is an easy-to-perform, simple, and cost-effective procedure and has a high sensitivity for clinical diagnosis in dermatology.
- It majorly helps in diagnosis of fungal infection in skin, hairs, and nails.
- However, it has certain limitations like false-positive results in various cases.

REFERENCES

1. Zaias N, Taplin D. Improved preparation for the diagnosis of mycologic diseases. Arch Dermatol. 1966;93:608-9.
2. Manjyot G, Saloni B. Mount the Menace!—Potassium Hydroxide in Superficial Fungal Infections. Indian J Paediatr Dermatol. 2020;21(4):343-6.
3. Brodell RT, Helms SE, Cosulich MT, Jackson JD, Abramovits W, Bhatia AC, et al. Tips and Tricks in Procedural Dermatology: Efficient and Effective Approaches to Achieving Optimal Diagnostic and Therapeutic Results. New Delhi: Jaypee Brothers Medical Publishers; 2019.
4. Chander J. A Textbook of Medical Mycology. New Delhi: Mehta Publishers; 2002.
5. Kurade SM, Amladi SA, Miskeen AK. Skin scraping and a potassium hydroxide mount. Indian J Dermatol Venereol Leprol. 2006;72:238-41.
6. Tille PM. Bailey & Scott's Diagnostic Microbiology. St. Louis, Missouri: Elsevier; 2022.
7. White TC, Findley K, Dawson TL Jr, Scheynius A, Boekhout T, Cuomo CA, et al. Fungi on the skin: dermatophytes and Malassezia. Cold Spring Harb Perspect Med. 2014;4(8):a019802.
8. Leung AK, Barankin B, Lam JM, Leong KF, Hon KL. Tinea versicolor: an updated review. Drugs Context. 2022;11:2022-9-2.
9. R AN, Rafiq NB. Candidiasis. 2023. In: StatPearls [Internet]. Treasure Island (FL): StatPearls Publishing; 2024.
10. Afshar P, Larijani LV, Rouhanizadeh H. A comparison of conventional rapid methods in diagnosis of superficial and cutaneous mycoses based on KOH, Chicago sky blue 6B and calcofluor white stains. Iran J Microbiol. 2018;10:433-40.

JAYPEE BROTHERS

or detailed information on dermatology books, visit our website www.jaypeebrothers.com, for detailed information on dermatology books, visit our we

IADVL Bedside Companion for Dermatology Residents

Salient Features

- This book contains bedside tests and investigations which would be handy for residents, practicing dermatologists, and faculty in institutions.
- The relevance, procedural steps, and findings of the tests in various situations are highlighted in the text using appropriate images, key messages, tables, and text.
- Bedside tests like KOH mount, slit-skin smear, Tzanck smear, and tissue smear are invaluable tools described in detail along with the stains used, namely Ziehl–Neelsen, Gram, and Giemsa stains.
- Bedside tests would help us to make an early probable diagnosis, while bedside investigations would help us reach an early confirmatory diagnosis many times.
- These processes are simple, easy to replicate, and do not require expensive equipment or techniques.
- The results are available at bedside when the patient has just presented to the OPD. This reduces precious time wasted in diagnosis, thus leading to early management and disease control. It leads to maximum satisfaction in a patient with minimal wastage of time, expenses, and discomfort.
- It is satisfying to the dermatology resident/dermatologist for having made a bedside diagnosis by following the simple procedures highlighted in the book.
- It will help postgraduate residents and examiners in their pursuit of exams.



Biju Vasudevan did his MBBS and MD in Dermatology and Venereology from the Armed Forces Medical College, Pune, Maharashtra, India. He has done his fellowship in Dermatosurgery from Bangalore Medical College, Karnataka. He has more than 160 publications, 40 chapters, and has edited 7 books. He is an avid quiz master having conducted about 30 quizzes. He is the current Chief Editor of the Medical Journal Armed Forces India, has been Deputy Editor of the Indian Journal of Dermatology, Venereology and Leprology, and Joint Secretary of IADVL among several appointments. He has been awarded the LN Sinha Award, The Young Dermatosurgeon Award, and the Systopic Oration at Dermacon 2022. His areas of interest include dermatosurgery, dermatopathology, connective tissue disorders, and psoriasis.

Printed in India

Available at all medical bookstores or buy online at www.jaypeebrothers.com

JAYPEE BROTHERS
Medical Publishers (P) Ltd.
EMCA House, 23/23-B, Ansari Road,
Daryaganj, New Delhi - 110 002, INDIA
www.jaypeebrothers.com

Join us on facebook.com/JaypeeMedicalPublishers

Shelving Recommendation
DERMATOLOGY

ISBN 978-93-5696-682-6