.com, for detailed information on cardiology books, visit our website www.jaypeebrothers.com, for detailed information on cardiology books

CSI–NIC Manual of Interventional Cardiology

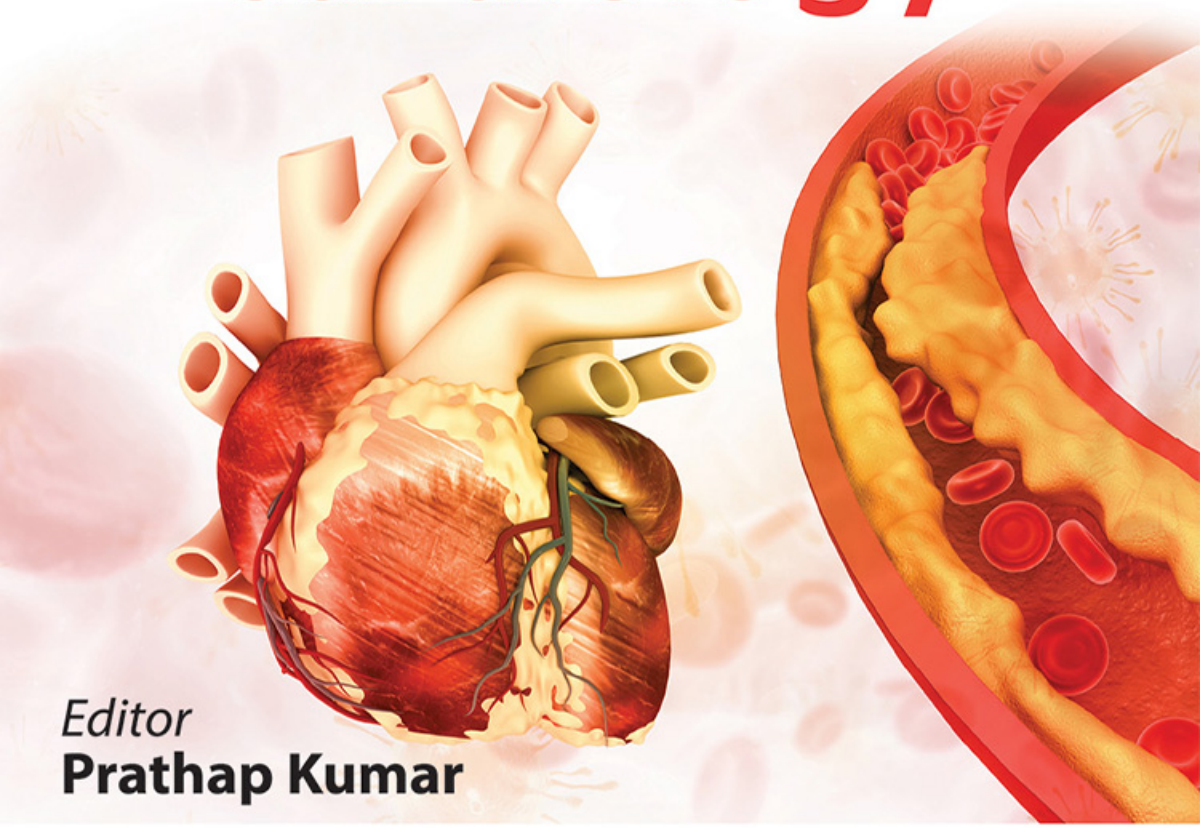

Editor
Prathap Kumar

Co-Editors
Manu Rajendran
Blessvin Jino

Forewords
Gerald S Werner
Imad Sheiban
Ramesh Daggubati

JAYPEE

Contents

1. **Catheter Selection and Angiographic Views for Anomalous Coronary Arteries: A Practical Guide 1**
   Aditya Kapoor

2. **Femoral Artery Approach: Access Techniques, Challenges, and Complications 7**
   Debabrata Roy

3. **Radial Access, Challenges, and Complications 16**
   Yashasvi Chugh, Sunita Chugh, Sanjay Kumar Chugh

4. **Techniques to Enhance the Guide Catheter Support During Coronary Interventions 22**
   Mrinal Kanti Das

5. **Guide Catheter Extensions: Utility, Deployment Techniques, and Troubleshooting 29**
   Mathew Iype, Praveen Velappan, Lais Muhammed

6. **Dual Lumen Microcatheters for Complex Percutaneous Coronary Intervention 34**
   PK Asokan

7. **Intravascular Ultrasound in Interventional Practice 41**
   Sajan Narayanan

8. **Optical Coherence Tomography in Interventional Practice 60**
   S Selvamani

9. **Image-based Optimization of Stent Implantation 81**
   Rajesh Vijayvergiya

10. **Coronary Physiology in Contemporary Percutaneous Coronary Intervention: Practical Approach 97**
    Anil Dhall, Ayush Malhotra

11. **Balloon Uncrossable Lesions: Technical Approach 140**
    AV Ganesh Kumar

12. **Ectatic Coronaries with Heavy Thrombus Burden in Primary Percutaneous Coronary Intervention: Approach 146**
    Ajith R Bhagawat

13. **Approach to Percutaneous Coronary Intervention in Calcified Lesions 154**
Sarita Rao, Roshan Rao, Abhishek Rathore, Achukatla Kumar

14. **Rotational and Orbital Atherectomy: Basics and Technique 164**
Sridhar Kasturi

15. **Rotational Atherectomy: Complications Prevention and Management 191**
Deepak Davidson

16. **Excimer Laser Coronary Atherectomy in Contemporary Percutaneous Coronary Intervention: Technical Tips and Tricks 200**
Radhapriya Yalamanchi, Refai Showkathali

17. **Treatment Strategy for Left Main Coronary Artery and Non-left Main Coronary Artery Bifurcation 213**
Madhu Sreedharan

18. **Side Branch Crossing and Recrossing in Bifurcation: Troubleshooting Techniques 226**
Dibya Kumar Baruah

19. **Side Branch Preservation 235**
Dilip Kumar

20. **Double Kiss Culotte Stent Technique for Coronary Angioplasty 244**
C Raghu

21. **Double Kiss Crush Technique: Step-by-Step Approach with Troubleshooting 250**
K Sivaprasad

22. **Kissing Balloon Inflation: How to Perform Optimally 260**
Stalin Roy J

23. **Proximal Optimization Technique 267**
Keshava Ramaiah

24. **Contemporary Management of Isolated Ostial Side Branch Disease (Medina 0,0,1) 273**
Arun Mohanty

25. **Left Main Coronary Intervention 283**
Prasant Kr Sahoo, Pankaj Manoria

26. Chronic Total Occlusion Percutaneous Coronary Intervention Toolbox 310
Roopali Khanna

27. Chronic Total Occlusion Wiring: A State-of-the-Art Guide 322
Surya Prakash

28. Antegrade Chronic Total Occlusion Crossing Techniques 334
Blessvin Jino

29. Retrograde Chronic Total Occlusion Crossing: Techniques 344
Byju Cheriya Kacheri

30. Wire Externalization Techniques in Retrograde CTO PCI..... 348
Manu Rajendran

31. Management of In-Stent Restenosis 361
A Sreenivas Kumar

32. Drug-coated Balloon in Clinical Practice..... 376
Rishi Sethi

33. Complex High-risk Indicated Percutaneous Coronary Intervention Clinical Approach..... 386
Manoj Sivaraman

34. Aorto-ostial Stenting: Tips and Tricks 395
Siva Kumar

35. Zero-contrast Percutaneous Coronary Intervention: Step-by-Step Approach 405
Prathap Kumar, Blessvin Jino, Manu Rajendran

36. Interventional Management of Coronary Aneurysms..... 412
Arun Gopi

37. Biovascular Scaffold: Current Status 418
Mahesh Nalin Kumar

38. How to Treat Coronary Perforations: Large Vessels, Distal Vessels, and Collaterals? 428
Sharath Reddy Annam

39. Stent and Wire Loss during Percutaneous Intervention..... 442
Ajay J Swamy

40. Entrapped Balloon and Balloon Fracture during PCI Management..... 449
Placid Sebastian

41. Transseptal Puncture and Balloon Mitral Valvotomy: Technical Tips and Tricks 457
Harikrishnan S

42. Alternative Sites of Large-bore Access and Devices and Techniques for Large-bore Access Closure 486
Ashraf SM

43. Transcatheter Aortic Valve Replacement: A Step by Step Approach 493
Ravinder Singh Rao

44. Transcatheter Aortic Valve Replacement: Complications and Management 501
Bagirath Raghuraman, Sabarish Sankaran

45. Transcatheter Mitral Valve Replacement: Step-by-Step Approach 513
Haresh Mehta

46. Transcatheter Edge-to-Edge Repair: Current Devices and Techniques 522
Praveen Chandra

47. Endovascular Aortic Aneurysm Repair: Basics and Techniques 532
NN Khanna, Saurabh Bhardwaj, Kritika Arora

48. Superficial Femoral Artery Interventions: Practical-based Approach 560
J Ezhilan

49. Management of Infrageniculate (Infrapopliteal) Peripheral Arterial Disease 569
Ashish Kumar Mandalay

50. Carotid Stenting: Step-by-Step Approach 589
Atul Mathur

51. Techniques of Pericardiocentesis 600
Ramesh Natarajan

Index 607

CHAPTER 2

Femoral Artery Approach: Access Techniques, Challenges, and Complications

Debabrata Roy

INTRODUCTION

The femoral artery access approach, initially described by Ivar Seldinger, has historically been the primary method of vascular access for coronary catheterization procedures. While several randomized trials have demonstrated the superiority of radial access over femoral access in terms of bleeding and vascular complications,[1-6] transradial access has now become the predominant route for coronary angiography and percutaneous coronary interventions. However, transfemoral access remains essential for selected complex percutaneous coronary interventions, mechanical circulatory support, and structural heart procedures requiring large bore access. The integration of adjunctive technology and techniques such as ultrasound guidance and micropuncture combined with fluoroscopy and palpation can improve outcomes associated with femoral vascular access.

INDICATIONS

- Access site for coronary angiography and intervention, particularly for procedures requiring larger sheath sizes
- Access site for percutaneous structural heart procedures (e.g., balloon valvuloplasty, percutaneous valves)
- Access site for peripheral vascular angiography
- Access for intra-aortic balloon pump/TandemHeart/extracorporeal membrane oxygenation (ECMO)/Impella device placement for hemodynamic support.
- Port for arterial access for invasive hemodynamic monitoring (radial access preferred)
- Patients with prior difficult radial access.

PRECAUTIONS AND PROPER PATIENT SELECTION

Vascular access site complications are common during coronary angiography and intervention and can be prevented by adhering to good access techniques, starting with appropriate patient selection based on a thorough history and physical examination.

JAYPEE BROTHERS

- *Thorough history:* Assessing factors such as peripheral artery disease (PAD), prior interventions for PAD, recent femoral access, presence of active groin infection, prior groin surgeries or radiation therapy, iliac or aortoiliac aneurysms, difficulties during prior femoral access, and risk factors for complications.
- *Physical examination:* Inspecting the groin for signs of infection or swelling, palpating for femoral and distal arterial pulses, and auscultating for bruits.
- *Basic laboratory values:* Including hemoglobin, platelet count, coagulation panel, electrolyte panel, and creatinine.

TECHNIQUES

The most secure location for puncturing is the common femoral artery (CFA) due to its substantial size and the ability to compress it over the femoral head. Originating from the external iliac artery, the CFA traverses beneath the inguinal ligament and divides distally into the superficial (SFA) and profunda (PFA) femoral arteries (*see* **Fig. 1**).[7] The optimal puncture site lies in the segment of the CFA situated above the bifurcation of the SFA and PFA and below the inferior epigastric branch, ensuring compressibility against the femoral head.

- *Access using anatomical landmarks* **(Table 1)**
- *Fluoroscopic guided access* **(Table 2)**
- *Ultrasound-guided approach* **(Table 3)**
- *Utilizing a micropuncture needle* **(Table 4)**
  - In fully anticoagulated patients, obtaining femoral access with a smaller gauge needle (micropuncture needle—21-gauge) is preferable to minimize access site complications.

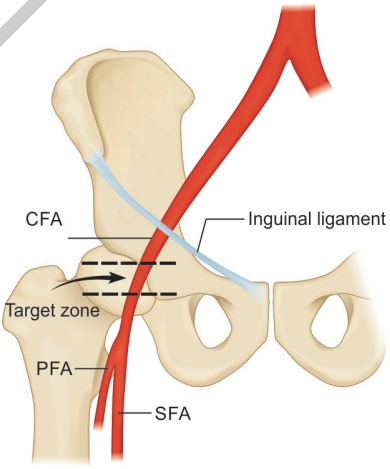

Fig. 1: Anatomical landmarks for femoral access.[8] (CFA: common femoral artery; PFA: profunda femoral artery; SFA: superficial femoral artery)

JAYPEE BROTHERS

TABLE 1: Access using anatomical landmarks.

Steps	*Advantages*	*Disadvantages*
• Identify the anterior superior iliac spine laterally and the symphysis pubis as a landmark for the inguinal ligament • Obtain access 2–3 centimeters below the midpoint between these landmarks • Needle to be aimed toward the area of strongest pulse. Angle of needle with skin should be 30–45°	Based on traditional teaching and most familiar method	• Inguinal crease is an unreliable marker for location of inguinal ligament • Difficult to appreciate the location of the inguinal ligament with palpation, especially in obese patients • Anatomical variations—high bifurcation, calcification, and plaque and obesity diminish the accuracy of this technique[9] • Low access increases the risk for bleeding and hematoma due to lack of a compressible site, and pseudoaneurysm[10,11] • High access (above the inguinal ligament) increases the risk of a retroperitoneal bleed and adverse outcomes[12]

TABLE 2: Fluoroscopic guided access.

Steps	*Advantages*	*Disadvantages*
Tip of the hemostat to be placed at the inferior border of the femoral head under fluoroscopic guidance: • Enter the skin with a needle at this site **(Figs. 2A and B)** • The CFA overlying the middle third of the femoral head should be aimed for puncture	Rapid access especially in cases with weak pulse • The presence and extent of vessel calcification can be noted	• Mismatch between skin entry site and location of inferior border of femoral head may occur after infiltration of skin with local anesthetic • Cannot account for a high CFA bifurcation (superior to the inferior border of the femoral head but inferior to the midpoint of the femoral head) or a very high bifurcation (superior to the midpoint of the femoral head)[13]

(CFA: common femoral artery)

- The micropuncture kit typically comprises a 21-gauge stainless steel needle, a 0.018-inch guidewire with a soft flexible tapered tip, and a 4 Fr × 10 cm micropuncture sheath with a dilator.

JAYPEE BROTHERS

TABLE 3: Ultrasound-guided approach.

Steps	*Advantages*	*Disadvantages*
• Position the vascular ultrasound (US) probe (5–10 Hz) above the palpated pulsation in the groin • Ensure the US probe is perpendicular to the course of the femoral artery, observing a clear and complete circle on the screen • Scan the artery by moving the US probe caudally along the skin to follow the course of the femoral artery and identify the bifurcation of the common femoral artery • Note that the vein is compressible, while the artery is typically pulsatile and not collapsible • Identify an anterior wall segment of the artery that is free of atherosclerotic disease or calcification • Locate the marker on the probe that corresponds to the marker on the ultrasound machine screen	• Enables the operator to identify and avoid plaque, calcification, and a pulsatile femoral vein • Prevents back-wall and side-wall punctures	• Operator training and experience are necessary • There is a risk of high puncture if the US probe slides cranially or if the needle trajectory is shallow and close to the US probe • There may be underestimation of the needle tip depth • Bony landmarks are challenging to visualize in ultrasound
• Align both as this is used to direct the needle as it traverses the skin and subcutaneous tissue. The common femoral vein is medial to the artery • Adjust the needle skin puncture site according to the depth of the femoral artery by puncturing away from the probe at a distance similar to the artery's depth • Continuously visualize the needle tip as it traverses the subcutaneous tissue. Ensure the ultrasound probe and beam remain stable while adjusting the needle direction in the subcutaneous tissue. Aim to puncture the anterior arterial wall of the segment and monitor the tip entering the artery • Exercise extreme caution to avoid moving the probe or left hand • Once access is achieved, maintain the probe in place until a wire is introduced through the needle and into the vessel		

JAYPEE BROTHERS

TABLE 4: Utilizing a micropuncture needle.

Steps	*Advantages*	*Disadvantages*
• Advance the micropuncture needle in a manner similar to that of a standard gauge needle • Once the artery is cannulated, ensure adequate blood flow. Insert and advance the 0.018-inch guidewire, preferably under fluoroscopic guidance • Remove the micropuncture needle over the guidewire and exchange it for the 4-Fr micropuncture sheath and dilator • Note brisk pulsatile arterial flow at this stage • Utilize a 0.035-inch J-tip guidewire through the micropuncture sheath and exchange the sheath for a regular 5–8-Fr femoral artery sheath	• Facilitates femoral angiography before inserting a larger caliber catheter, confirming the safety of the puncture site • Abandoning puncture sites with micropuncture access enables easier hemostasis afterward due to the smaller puncture size	• The guidewire's highly flexible tip reduces the tactile feedback during advancement compared to traditional spring-tip guidewires • Smaller caliber guidewires may inadvertently enter small branches, coupled with reduced tactile feedback, potentially leading to aggressive advancement into a small branch, causing perforation, a large hematoma, and other access site complications. This risk can be mitigated by closely monitoring the micropuncture guidewire advancement under fluoroscopy

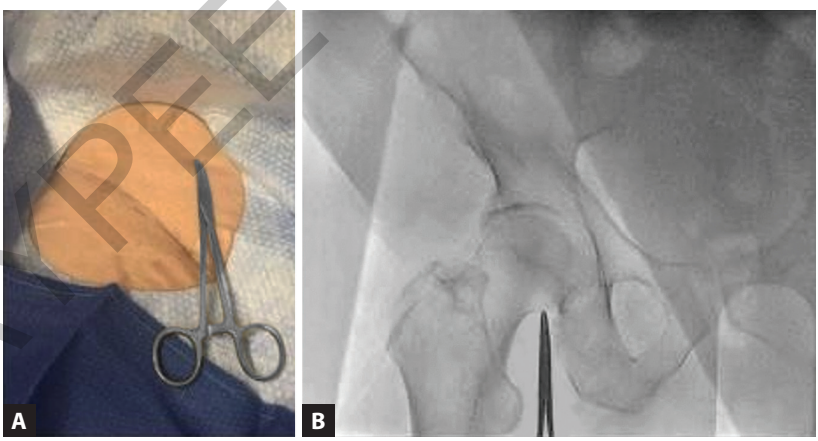

Figs. 2A and B: Correct location of skin entry based on the location of the inferior border of the femoral head.[13]

CHALLENGES

Navigating tortuous and diseased iliac arteries:

- Common in the elderly

JAYPEE BROTHERS

- After gaining access, it is crucial to assess the extent of the access wire within the femoral/iliac vessel.
- If the J-wire encounters resistance due to tortuosity or stenotic disease in the iliac arteries, consider placing a micropuncture sheath and then exchanging the J-wire for a soft angled glidewire. Avoid inserting the glidewire directly through the introducer needle to prevent stripping off its hydrophilic coat into the vessel.
- Once the wire reaches the aorta, switch to a long (25–45 cm) femoral sheath inserted over the wire under fluoroscopic visualization to bypass possible resistance points hindering catheter manipulation.
- If encountering resistance, reassess for the possibility of being subintimal or in a dissection plane, particularly in the presence of significant plaque. In cases of a tortuous aorta, a 45–90-cm sheath may be necessary, preferably placed over a stiff 0.035″ guidewire.

Access through femoral graft:

- Utilize ultrasound guidance to identify the anastomosis site and the optimal puncture site.
- Employ a micropuncture needle.
- Exercise caution when directing the wire into the graft and aorta (fluoroscopy guidance aids).
- Minimize manipulation within the graft.
- Serial dilation may be required.
- Use a long femoral sheath.

Patient on oral anticoagulants (OAC):

- Patients on OAC and fully anticoagulated [international normalized ratio (INR) >1.6] have similar 30-day major adverse event rates compared to those not anticoagulated.[14]
- To mitigate complications, employ micropuncture.
- Avoid heparin use if INR >2.5.
- Prefer radial access.

Anomalous femoral artery:

- Typically, the groin vein lies medial to the artery. However, in rare cases, the artery can be superficial to the vein at the base of the femoral triangle in the groin.[15]
- In such situations, prefer an ultrasound-guided approach to prevent AV fistula or retroperitoneal hematoma.

COMPLICATIONS[7,16-19]

Table 5 describes the complications and their management of a femoral arterial puncture.

JAYPEE BROTHERS

TABLE 5: Complications of a femoral arterial puncture and their management.

Complication	*Incidence*	*Risk factors*	*Management*
Hematoma	<3%	Low femoral puncture, multiple punctures, puncturing through an overlying vein, large sheath size, ineffective manual compression, female gender, anticoagulant and antifibrinolytic therapy and hypertension	• Small hematoma—manual compression • Large hematoma—rapid internal balloon tamponade, covered stent, or surgical correction
Pseudoaneurysm	1–3%	Low puncture	• <2 cm—no intervention • >2 cm and narrow neck—USG-guided compression or thrombin injection • >2 cm and wide neck—surgical closure
Dissection	1%	Occurs during withdrawal of shaped catheters, or large devices	• Retrograde dissection—conservative • Antegrade dissection—if flow limiting—femoral artery stenting
Arteriovenous (AV) fistula	<1%	Same as hematoma	Prolonged bandage, coil embolization, surgery
Retroperitoneal hemorrhage	<3%	High puncture, use of glycoprotein IIb–IIIa inhibitors, posterior wall puncture	• Intravenous fluid/blood transfusion • Reversal of anticoagulation • Angiography with selective embolization of active bleeding • Covered stent placement • Open surgical repair
Acute limb ischemia	<1%	Inadequate anticoagulation, delayed sheath removal	• Rutherford class I and IIa—endovascular techniques (percutaneous catheter-directed thrombolysis, thromboaspiration with or without thrombolytic therapy, mechanical thrombectomy) • Rutherford class IIb—open revascularization

JAYPEE BROTHERS

CONCLUSION

A combined strategy of fluoroscopic assessment of bony landmarks and ultrasound-guided arterial puncture in a segment without significant atherosclerotic burden can help target the ideal common femoral puncture site while ensuring safe transfemoral access. Micropuncture access followed by femoral angiography by hand injection enhances spatial orientation of the access site, contributing to improved outcomes.

REFERENCES

1. Bernat I, Horak D, Stasek J, Mates M, Pesek J, Ostadal P, et al. ST-segment elevation myocardial infarction treated by radial or femoral approach in a multicenter randomized clinical trial: the STEMI-RADIAL trial. J Am Coll Cardiol. 2014;63:964-72.
2. Chiarito M, Cao D, Nicolas J, Roumeliotis A, Power D, Chandiramani R, et al. Radial versus femoral access for coronary interventions: An updated systematic review and meta-analysis of randomized trials. Catheter Cardiovasc Interv. 2021;97:1387-96.
3. Jhand A, Atti V, Gwon Y, Dhawan R, Turagam MK, Mamas MA, et al. Meta-Analysis of Transradial vs Transfemoral Access for Percutaneous Coronary Intervention in Patients with ST Elevation Myocardial Infarction. Am J Cardiol. 2021;141:23-30.
4. Jolly SS, Yusuf S, Cairns J, Niemelä K, Xavier D, Widimsky P, et al. Radial versus femoral access for coronary angiography and intervention in patients with acute coronary syndromes (RIVAL): a randomised, parallel group, multicentre trial. Lancet. 2011;377:1409-20.
5. Mehta SR, Jolly SS, Cairns J, Niemela K, Rao SV, Cheema AN, et al. Effects of Radial Versus Femoral Artery Access in Patients with Acute Coronary Syndromes with or without ST-Segment Elevation. J Am Coll Cardiol. 2012;60:2490-9.
6. Romagnoli E, Biondi-Zoccai G, Sciahbasi A, Politi L, Rigattieri S, Pendenza G, et al. Radial versus femoral randomized investigation in ST-segment elevation acute coronary syndrome: the RIFLE-STEACS (Radial Versus Femoral Randomized Investigation in ST-Elevation Acute Coronary Syndrome) study. J Am Coll Cardiol. 2012;60:2481-9.
7. Bangalore S, Bhatt DL. Femoral Arterial Access and Closure. Circulation. 2011;124:e147-56.
8. Bhatty S, Cooke R, Shetty R, Jovin IS. Femoral vascular access-site complications in the cardiac catheterization laboratory: Diagnosis and management. Interv Cardiol. 2011;3(4):503-14.
9. Garrett PD, Eckart RE, Bauch TD, Thompson CM, Stajduhar KC. Fluoroscopic localization of the femoral head as a landmark for common femoral artery cannulation. Catheter Cardiovasc Interv. 2005;65:205-7.
10. Altin R, Flicker S, Naidech H. Pseudoaneurysm and arteriovenous fistula after femoral artery catheterization: Association with low femoral punctures. Am J Roentgenol. 1989;152:629-31.
11. Rapoport S, Sniderman KW, Morse SS, Proto MH, Ross GR. Pseudoaneurysm: A complication of faulty technique in femoral arterial puncture. Radiology. 1985;154:529-30.

JAYPEE BROTHERS

12. Kwok CS, Kontopantelis E, Kinnaird T, Potts J, Rashid M, Shoaib A, et al. Retroperitoneal Hemorrhage after Percutaneous Coronary Intervention: Incidence, Determinants, and Outcomes as Recorded by the British Cardiovascular Intervention Society. Circ Cardiovasc Interv. 2018;11:e005866.
13. Pitta S, Bagai J, Swaminathan RV, Latif F. (2020). Safe femoral access: Using all the tools in the toolbox. [online] Available from https://scai.org/safe-femoral-access-using-all-tools-toolbox. [Last accessed August, 2024].
14. Shammas NW, Shammas GA, Jones-Miller S, Gumpert MR, Gumpert MJ, Harb C, et al. Predictors of common femoral artery access site complications in patients on oral anticoagulants and undergoing a coronary procedure. Ther Clin Risk Manag. 2017;13:401-6.
15. Sahin B, Uzun A, Emirzeoglu M, Kosif R, Bilgic S. A deep femoral artery passing in front of the femoral vein. Folia Morphol (Warsz). 2003;62:143-6.
16. Işık M, Tanyeli Ö, Dereli Y, Taban VB, Altınbaş Ö, Görmüş N. Gradual treatment of arteriovenous fistula in femoral vessels as a complication of coronary angiography. Rev Bras Cir Cardiovasc. 2018;33(6):631.
17. Martin K, Ma AD, Key NS. Molecular basis of hemostatic and thrombotic diseases. In: Molecular Pathology. Amsterdam: Elsevier; 2018. pp. 277-97.
18. Olinic DM, Stanek A, Tătaru DA, Homorodean C, Olinic M. Acute limb ischemia: An update on diagnosis and management. J Clin Med. 2019;8(8):1215.
19. Stinis CT. Avoiding and managing femoral access site complications. Promedicacme.com. Available from https://promedicacme.com/wp-content/uploads/2017/11/Stinis-Curtiss-Femoral-Access-Complications.pdf. [Last accessed August, 2024].

JAYPEE BROTHERS

for detailed information on cardiology books, visit our website www.jaypeebrothers.com, for detailed information on cardiology books, visit

CSI–NIC Manual of Interventional Cardiology

Salient Features

- Provides the most updated knowledge on the selected topics in interventional cardiology
- Basics of arterial punctures, catheter selection, intracoronary imaging, and physiology
- Step-by-step approach on the techniques of complex coronary procedures
- Dedicated topics on latest technologies like excimer laser coronary atherectomy (ELCA), orbital atherectomy, etc
- Special topics on nightmares in interventions like coronary perforation, balloon fracture, stent loss, etc
- Update on structural heart interventions like transcatheter aortic valve replacement (TAVR), transcatheter mitral valve replacement (TMVR), transcatheter edge-to-edge repair (TEER), etc., and aortic interventions.



Prathap Kumar MD DM FIC is the Chief Interventional Cardiologist, Department of Cardiology, Meditrina Hospital, Kollam, Kerala, India. He has more than 23 years of experience in interventional cardiology. With his vast experience and expertise in the field, he has contributed immensely to the growth of interventional cardiology, earning distinctive recognition and respect in the country. After graduating with a bachelor's degree in medicine in 1988 from Government Medical College, Thiruvananthapuram, Kerala, he received an MD (Internal Medicine) degree in 1992 from BJ Medical College, Ahmedabad, Gujarat. A protagonist of the belief that heart matters most, he went on to obtain DM (Cardiology) in 1997 and a Fellowship in Interventional Cardiology from the University of Turin, Italy, in 2002. He is a pioneer in chronic total occlusion percutaneous coronary intervention (CTO PCI), both antegrade and retrograde approaches, in India. Apart from CTO PCI, he has a special interest in image-guided zero-contrast PCI in patients with renal diseases. He has performed live cases in many national and international conferences. He was instrumental in establishing the cardiology department in Benziger Hospital, an interventional cardiology center in Pariyaram Medical College, and in PRS Hospital, Thiruvananthapuram. He was also the Director of cathlab services in Manipal Heart Foundation, Bengaluru, Karnataka. He is currently the Chairman and Managing Director of the Meditrina group of hospitals, which has multiple centers across India, performing thousands of procedures at an affordable cost. His mission is to give premium health care at an affordable cost.

Printed in India

Available at all medical bookstores or buy online at www.ejaypee.com

JAYPEE BROTHERS
Medical Publishers (P) Ltd.
EMCA House, 23/23-B, Ansari Road,
Daryaganj, New Delhi - 110 002, INDIA
www.jaypeebrothers.com

Join us on facebook.com/JaypeeMedicalPublishers
Follow us on instagram.com/JaypeeMedicalPublishers

Shelving Recommendation
CARDIOLOGY

ISBN 978-93-5696-733-5