d information on pediatric books, visit our website www.jaypeebrothers.com, for detailed information on pediatric books, visit our website www.jaypeebrothers.com

Clinical Evaluation of Newborns, Infants and Children



Editor-in-Chief
S Sushamabai

Associate Editors
Lalitha Kailas
Darly Saramma Mammen
Suresh S Vadakedom

Foreword
Mohanan Kunnumal

3rd Edition

JAYPEE

Contents

SECTION 1 History and General Examination

1. **The Doctor** 3
   S Sushamabai
2. **The Family Interview** 5
   S Sushamabai
3. **Communication with Patients and Parents** 7
   VK Parvathy
4. **Communication as a Student** 16
   Darly Saramma Mammen
5. **Introduction to Medical Research** 21
   Manu Raj, M Geethadevi
6. **History Taking** 29
   S Sushamabai
7. **General Physical Examination** 49
   S Sushamabai
8. **Assessment of a Sick Child** 84
   Sheeja Sugunan, S Sushamabai
9. **Evaluation of the Unconscious Child** 94
   S Sushamabai, Sheeja Sugunan
10. **An Approach to Skin Lesions** 101
    Lalitha Kailas, Kalyani Pillai
11. **Assessment of Growth and Nutrition** 116
    S Sushamabai, VH Sankar
12. **Assessment of Development** 136
    S Sushamabai, Suresh S Vadakedom

SECTION 2 Examination of the Newborn

13. **Before You Proceed** 153
    L Rajam, S Radhika
14. **Initial Examination of the Newborn** 156
    L Rajam, S Radhika

15. Examination of the Baby in the Postnatal Ward 158
L Rajam, S Radhika

16. Daily Examination of the Newborn 186
L Rajam, S Radhika

SECTION 3 Basic System Examination

17. Cardiovascular System 193
S Letha, M Zulfikar Ahamed

18. The Electrocardiogram 210
M Veerendra Kumar, M Zulfikar Ahamed

19. Respiratory System 222
MD Fiji, VT Ajith Kumar

20. Gastrointestinal System and Abdomen 237
P Savida, Darly Saramma Mammen, R Bhanuvikraman Pillai

21. Nervous System 263
KS Vijayakumar, KP Vinayan

22. Neurological and Neuromuscular Investigations in Children 307
Vaishakh Anand, KP Vinayan

23. Confirmation of Death 323
Davidson Devasia, KP Vinayan

24. Endocrine System 333
M Vijayakumar, Lalitha Kailas

25. Musculoskeletal System 355
S Letha, Suresh S Vadakedom, Suma Balan

26. Pediatric Imaging: The Basics 371
L Jayasree, R Vishnu

Appendix-1 391

Appendix-2 407

Index 413

7

CHAPTER

General Physical Examination

S Sushamabai

Chapter Outline

- Introduction
- Getting the Cooperation
- Preparations for Patient Assessment
- Schema of General Examination
- Clinical Case Scenarios

INTRODUCTION

Please read Ch. 1, 2, 3, 4, and 6 before you proceed; For detailed evaluation of bones and joints read Ch. 25.

Physical examination of the patient should begin with general assessment to detect serious functional impairment of organs and systems requiring immediate care (Ref. Ch. 8) which should proceed parallel to the history. Patients requiring urgent life support should be spotted out rapidly by simple clinical signs and stabilized at the "Golden hour".

Compared to adults, physical examination of children needs more patience and tactfulness, and fast completion; lengthy examinations irritate children and their parents. As the values of vital parameters for different ages vary, the doctor should have the expertise to interpret the observed values quickly.

The outpatient room should provide maximum comfort to the child patient and the family as detailed in Ch. 2; strange instruments should be kept out of sight as the child may get frightened. The doctor should be mentally well prepared for the urgent management of difficult and sick patients 'encountered' at any time; at the same time to deal with the arrogant accompanying persons without any provocation. Experienced supporting staff and well-equipped emergency care services in functioning status should be available around the clock nearby.

Undressing the child each time should be partial only and should be done with the help of the caretaker always, to maintain cooperation, prevent hypothermia, and to avoid unnecessary allegations. For a crying baby, sufficient time should be provided to get the baby consoled. The nursing staff in the outpatient department (OPD) and emergency room (ER) should be enough experienced to provide gentle and expert care to sick and irritated babies. While examining adolescent girls a chaperone should be always present.

A systematic approach should be practiced as far as possible, but prioritize the system and techniques depending on the circumstances. Uncomfortable procedures such as examination of the throat, tympanic membranes, hips, and rectum should be reserved for the last, but the schema of presentation should be according to set pattern **(Box 7.1)**. Findings to be elicited at the end of the examination should be noted down using a different color ink to be completed later.

JAYPEE BROTHERS

BOX 7.1: Schema of general exam.

- Appearance
- Vital signs
- Danger signs
- Head-to-foot examination

GETTING THE COOPERATION

Small babies (<3 m of age) may be placed on the caregiver's lap or the examination table for physical examination. Infants and toddlers (6 m to 3 yr) prefer to remain on the caregiver's lap and older children (>3 yr) would like to be offered a seat. Occasionally one may come across highly irritable and noncooperative children of age group from the newborn period even up to adolescence (due to illness or fright). Breastfeeding is an effective way to pacify young infants. For the age group from 6 m to 2 yr, distraction by colorful toys is possible. In the age group 2–4 yr, colored picture books of animals, birds, fruits, vegetables, vehicles, etc., attract children and make them much more comfortable cooperative **(Fig. 7.1)**.

Older children like to hear compliments (e.g., your nail polish/hairdo is so fine, who made it for you?) which will build up friendship rapidly (Ref. Ch. 2). Alternatively, a screaming and struggling child at the sight of the doctor/nurse reveals intact vision and stranger recognition and thus gives a rough assessment of the nervous system and developmental status. Sedation of a struggling child may be needed occasionally to examine the cardiovascular system or abdominal mass evaluation.



Fig. 7.1: Getting the cooperation of the youngster.

PREPARATIONS FOR PATIENT ASSESSMENT

- *The doctor* should be receptive with a welcoming smile and vigilant, searching eyes, sharp ears, and warm sensitive fingers (Ref. **Fig. 1.1**). Observe all aseptic precautions-wearing mask and sterile gown and practicing proper hand hygiene by soap and water washing or by applying hand sanitizer.
- *The tools* should include an updated pediatric stethoscope (Ref. Ch. 17), moderately bright torch light, fingertip pulse oximeter, nonstretchable tape, wooden tongue depressor, thermometers, sphygmomanometer with adequately sized cuffs (Ref. Ch. 17), pediatric knee hammer, hand lens (to assess skin lesions), and otoscope. Minimum materials for developmental screening should be at hand (a red bangle tied with a red string, a squeaky doll, few red pellets, and a small picture book of animals, birds, fruits, flowers, and vehicles). Additional tools for each system examination are specified in the concerned chapters.
- *Child and mother-friendly environment*: Warm, clean, well-aerated assessment room with white curtains and few attractive and informatory wall pictures.
- *An emergency room* near the OPD with adequate life-saving medicines and equipment, experienced, well-behaved, and adequately trained staff (doctor, nurse, and paramedical staff).

JAYPEE BROTHERS

SCHEMA OF GENERAL EXAMINATION

Box 7.1 discusses how to proceed with examining the child brought to the OPD or ER.

Appearance

Is the child cheerful, alert, and cooperative, dull or inert, irritable or sick looking?

A sick child may remain with eyes closed and respond poorly to the mother's calling or may have open eyes with a *vacant aloof* look **(Fig. 7.2)**. Danger signs such as drowsiness, refusal to feed/poor breast sucking/fluid drinking, noisy breathing (stridor, wheezing, rattling, and grunting), tracheal tug (inward pulling of trachea at the suprasternal notch seen during inspiration in severe respiratory distress), apnea, cyanosis, convulsions, jaundice, severe pallor, severe malnutrition, overt bleeding, hypothermia (perceived by cold skin on holding the limb or feeling the skin warmth of the patient with the dorsum of fingers by the doctor), and severe congenital anomalies indicate serious illness. A child with any of these features should be labeled as sick.

Certain clinical parameters can be applied to assess the severity of acute illness in children. Yale Observation Scale 7 (YOS 7) with six parameters **(Table 7.1)** is found to be a valid one in many studies for the presence of bacteremia or serious disease in febrile children of age group >1–59 m.



Fig. 7.2: Sick child with a vacant look.

The best possible score is 6 × 1 = 6; the worst score is 6 × 5 = 30. The probability of serious bacterial infection is 2.75% if the score is <10; 26% with a score of 11–15; and 92.3% with a score >16.

Vital Signs

Vital signs to be evaluated are pulse rate (PR), blood pressure (BP), respiratory rate (RR), body temperature, capillary refill time (CFT), hydration status, and oxygen saturation.

Pulse

Count the radial pulse for 15 sec and multiply with 4 to get the rate and rhythm; if it is irregular or poor in volume, count for 1 complete minute. The right radial pulse is the one commonly evaluated.

Counting the Radial Pulse

The patient has to extend and half pronate the forearm at the elbow and partially flex the wrist. This position can be easily procured in infants and children by offering a "shake hand". With the index and middle fingers of the other hand, approaching from the radial side of the forearm, gently press against the distal end of the radius to get the arterial pulse **(Fig. 7.3)**. Radial pulse is difficult to obtain in newborns, obese, and edematous infants and in patients with shock; if so, rapidly search for brachial (over the cubital fossa), carotid (at the carotid triangle), or femoral pulsations (press midway between the anterior superior iliac spine and the symphysis pubis below the inguinal ligament). Occasionally one's own pulse may be confused with the patient's pulse;

JAYPEE BROTHERS

TABLE 7.1: Yale Observation Scale 7 (YOS 7).

Observation item	***Normal (score = 1)***	***Moderate Impairment (score = 3)***	***Severe impairment (score = 5)***
Quality of cry	Strong with normal tone *Or* Content and not crying	Whimpering *Or* Sobbing	Weak/moaning/high pitched
Reaction to parent stimulation	Cries briefly then stops *Or* Content and not crying	Cries off and on	Continual cry Or Hardly responds
State variation	If awake → Stays awake *Or* If asleep and stimulated → wakes up quickly	Eyes close briefly, awakes with prolonged stimulation	Falls to sleep *Or* Does not wake up
Color	Pink	Pale extremities *Or* Acrocyanosis	Pale *Or* Cyanotic *Or* Mottled *Or* Ashen
Hydration	Skin normal, eyes normal, and mucous membranes moist	Skin, eyes-normal, and mouth slightly dry	Skin doughy/tented and dry mucous membranes and/or sunken eyes
Response (talk and smile) to social overtures	Smiles *Or* Alerts (≤2 m)	Brief smile *Or* Alerts briefly (≤2 m)	No smile, face anxious/dull/ expressionless OR No alerting (≤2 m)



Fig. 7.3: Counting the radial pulse.

if so try to compare it with the examiner's own temporalis artery pulsations with the other hand. *Dorsalis pedis and posterior tibial* are the other peripheral pulsations to be assessed at the first visit itself; all these three should be palpated on both sides.

Assess the rate, rhythm (regularity), and force of pulsations and compare for each vessel on both sides. **Table 7.2** reveals the normal values of pulse, BP, and RRs in children in different age groups. Rapid or slow rate, irregular or feeble, or bounding pulse, all may indicate disease situations. *Physiological increase and decrease* in pulse rate during inspiration is sinus tachycardia

JAYPEE BROTHERS

TABLE 7.2: Normal values of PR, RR, and BP in children.

Parameter	*Preterm baby*	*Newborn*	*Infant*	*Child*	*Adolescent*
Pulse/min	120–160	100–150	90–120	70–110	60–95
RR/min	40–60	40–60	30–40	20–30	14–18
BP (mm Hg)	As per gestational age in Ch. 15	60/40	90/60	*90 + (2 × age in yr) #70 + (2 × age in yr)	

*90 + (2 × age in yr)—systolic BP 50th percentile
#70 + (2 × age in yr)—systolic BP fifth percentile
(BP: blood pressure; PR: pulse rate; RR: respiratory rate)

and on expiration is sinus bradycardia respectively; both are normal phenomena. Benign extrasystoles are nonpathological irregularities in rhythm. *A feeble pulse* may herald shock, aortic stenosis, cardiomyopathy, or vasculitis. *Unequal radial pulses* indicate preductal coarctation. *Radiofemoral delay* is seen in postductal coarctation beyond the subclavian vessel. For more details on pulse and BP see Ch. 17.

For 95th percentile BP values refer Ch. 17.

Blood Pressure

Record the BP (Ref. Ch. 17 for details) when the child is quiet or sleeping. Values <5th and >95th percentiles indicate hypo and hypertension, respectively.

Respiratory Rate

- *Observe the RR* whether fast or slow, regular or irregular, depth of respiration, abnormalities in breathing pattern, work of breathing, and added sounds perceived by naked ears.
- *Count the RR* by inspection in children since palpation or auscultation may interfere with the RR due to the tactile stimulus. Observe the inspiratory rising of the chest for one complete minute (since the rate can be irregular) while the patient is quiet and resting. Tachypnea or fast breathing is increased RR for the age as revealed in **Table 7.3** and is the best clinical indicator of respiratory distress and hypoxia in children.

TABLE 7.3: Agewise RR for tachypnea in children.

Age	*RR/min*
<60 days	≥60
≥60 days to 1 yr	≥50
≥1–5 yr	≥40
≥5 yr	≥30

The most common cause of tachypnea is lower respiratory infection. Hyperreactive airway disease, upper airway obstruction, congenital anomalies of the respiratory system, pleural effusion/empyema, pneumothorax, foreign body impaction of the airway, congenital heart disease, cardiac failure, cardiomyopathy, pericardial effusion, renal failure, renal tubular acidosis, diabetic ketoacidosis, inborn errors of metabolism (IEM), and drug intoxication (salicylism) are the other causes (Ref. Ch. 19).

Temperature

A change in body temperature (temp) to higher or lower levels is detrimental to body functions and indicates illnesses. In children up to 10 yr of age, body temp should be recorded from the axilla or groin for safety reasons. In older cooperative children and

JAYPEE BROTHERS

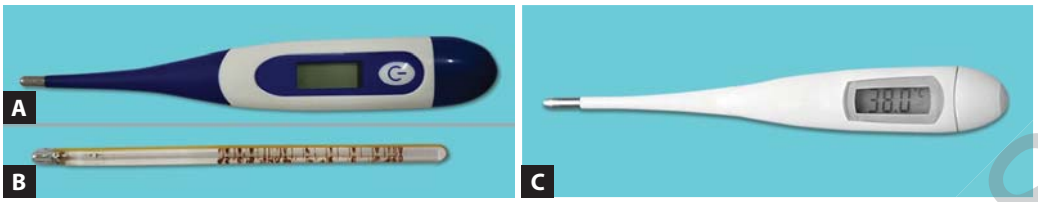

Figs. 7.4A to C: Different types of thermometers for body temperature recording. (A) Digital oral thermometer (blue); (B) Mercury rectal thermometer (yellow); (C) Digital rectal thermometer.

adults, oral recording is feasible. Hypothermia should be assessed by rectal recording. Electronic and mercury glass thermometers (oral and rectal) are equally reliable. The latter are not used at present in most places, because of the environmental poisoning hazard and danger to the patient if it breaks within the mouth or rectum. **Figures 7.4A to C** show the different types of thermometers. Rectal thermometers have shorter and more round tips compared to the oral types.

How to take body temperature?

Antiseptic (70% isopropyl alcohol) cleaning is a must before and after the use of the thermometer. Soap and water cleaning is needed for the rectal thermometer. Child should not have taken oral ice or warm water at least 30 minutes before oral temperature recording. For axillary recording, apply the thermometer tip correctly to the apex of the axilla without clothes in between; approximate the arm (which is flexed at the elbow) tightly and keep it till the beep of the electronic thermometer is heard indicating the time of reading. In the mouth, place the tip of the thermometer under the tongue, firmly close the lips, and ask the child to breathe through the nose. On hearing the beep the reading should be documented. In newborns suspecting hypothermia, sick children, and those with coma or severe protein-calorie malnutrition (PEM), rectal temperature recording is a must.

- *Rectal temperature recording:* Place the infant in lateral decubitus posture (or prone) over the parent's lap or over a table, hold the child's lower back firmly with one hand, and introduce slowly the lubricated tip of the rectal thermometer 0.5–1 inch through the anal opening. Stop the attempt if any resistance is felt. Keep the thermometer steady between the second and third fingers, cupping against the baby's bottom till the beep is heard. The oral temperature is 0.5°C higher than the axillary and the rectal temperature is 0.5°C higher than the oral. Hence, when the body temperature is reported, whether the recording is axillary, oral, or rectal should be specified (or report the temperature after adding appropriate correction).
- *Infrared thermometers* **(Fig. 7.5)** measure body temperature using infrared technology (equally reliable as electronic thermometers). Recording is easy and quick. They are costlier and accuracy may be affected by direct sunlight, lower surrounding temperature, sweaty forehead, and lack of contact with the forehead.
- *Interpretation of body temperature:* According to the American College of Emergency Physicians, fever is defined as rectal temperature >100.4°F. The three types of classical fevers are: Continuous,

JAYPEE BROTHERS

remittent, and intermittent. In continuous fever, daily fluctuations are <1°C and the temperature never reaches normal. In remittent fever, daily fluctuations are >2°C without the temperature touching the baseline (e.g., typhoid fever and tuberculosis). *Hectic or septic fever* **(Fig. 7.6A)** is a type of remittent fever having >3°C fluctuation (seen in abscess, deep-seated infections, pyelonephritis, and malignancy). In *intermittent* fever fluctuations exceed 1°C which lasts for a few hours of a day, *quotidian* fever is such fluctuations occurring daily, *tertian* fever is fluctuations occurring on alternate days (typical of *Plasmodium vivax* infection); in *quartan* fever, the fluctuations occur on every third day (typical of *Plasmodium malariae* malaria). With the widespread use of antipyretics, antibiotics, and chemotherapeutics these typical patterns of fever are uncommon now. In *relapsing fevers*, the spikes are separated by few normal days in between. In biphasic fever (camelback fever) two distinct phases of fever **(Fig. 7.6B)** occur over one or more weeks for a single illness. Leptospirosis, dengue illness, yellow fever, rat bite fever, tick fever, and paralytic polio reveal such biphasic fever. Fever with relative bradycardia (<10 beats/°F reductions) occurs in typhoid, brucellosis, leptospirosis, dengue fever, viral hepatitis, and myocarditis. **Table 7.4** reveals the interpretation of body temperature.



Fig. 7.5: Infrared thermometer.

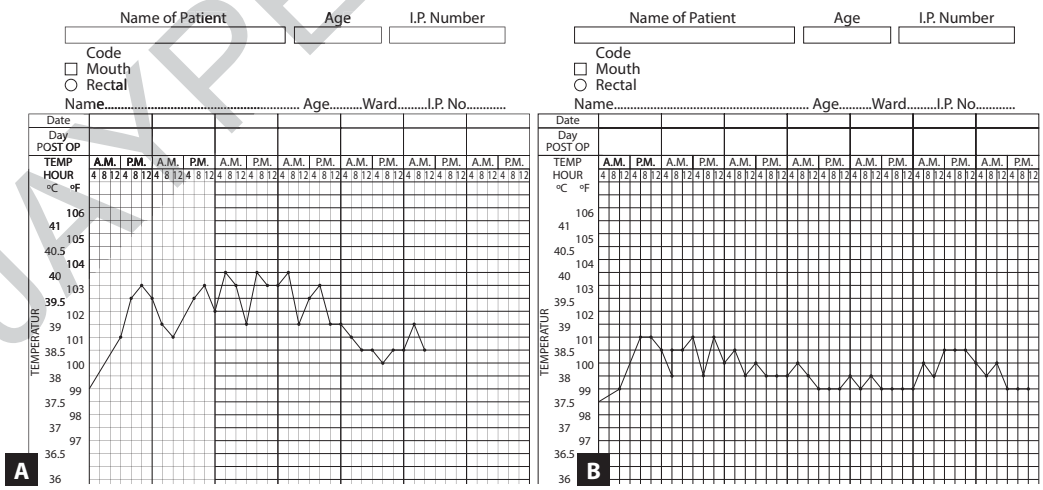

Figs. 7.6A and B: (A) Hectic fever in Acute osteomyelitis and (B) Biphasic fever in dengue illness.

JAYPEE BROTHERS

Capillary Refill Time (CFT)

Capillary refill time is a bedside test to detect the peripheral perfusion of tissues. To assess CFT lift the limb 15° above the precordial level and press the pulp of the finger (sole of foot in newborns) for 5 sec (count in mind 1,001; 1,002; 1,003; 1,004; and 1,005) so as to blanch the area and release. The time for blanch to disappear or CFT is normally ≤2 sec; ≥3 sec is prolongation (Ref. **Fig. 8.2B**); ≥5 sec is inadequate systemic perfusion as in hypovolemic and cardiogenic shock. This sign may not occur in the early stage of septic shock due to capillary dilatation. Exposure to cold environments can prolong CFT in normal persons. Other sites for CFT evaluation are precordium and ear lobules (in newborns).

Hydration Status

Assess the hydration status in all sick children by asking about the fluid intake (breastfeeding in small babies) "Is the baby drinking eagerly?" and the volume and frequency of urine voiding. Symptoms of dehydration are excessive thirst, voracious drinking, and tiredness/irritability. Lethargy, sunken eyes **(Fig. 7.7)**, absent tears, dryness of tongue and buccal mucosa, loss of skin recoil, and hypotension are the signs. **Table 7.5** reveals the grading of dehydration in children.

Skin recoil is the reverting of the skin after pinching, an important sign of dehydration. Pinch a fold of skin with fat over the abdomen midway between the umbilicus and flanks. Hold it for ten seconds (count 1,001, 1,002 and 1,003) and release. In normal hydration, skin recoils immediately without leaving wrinkles.



Fig. 7.7: Sunken eyes and scaphoid abdomen in severe dehydration.

TABLE 7.4: Interpretation of body temperature.

Body temperature	***Celsius (°C)***	***Fahrenheit (°F)***
Normal	36.6–37.2	98–99
Subnormal	<36.6 (cold stress in neonates)	<98
Hypothermia	<36	<95
Febrile	>38	>100.4
Hyperpyrexia	>41	>106

TABLE 7.5: Assessment of dehydration in children.

Clinical signs	***No dehydration***	***Some dehydration***	***Severe dehydration***
Sensorium	Alert	Irritable	Altered sensorium, coma
Eyes	Normal	Sunken	Very sunken
Oral mucosa and tongue	Moist	Dry*	Dry* and parched
Skin pinch	Immediate recoil	Recoils in 2 sec	Recoils after 2 sec
Thirst	Normal drinking	Drinks eagerly	Unable to drink
Urine output	Normal	Decreased	Much decreased/absent

*Oral mucosa can be moist after fluid intake or vomiting. Can appear dry in mouth breathers.

JAYPEE BROTHERS

In some dehydration recoiling occurs by two seconds. In severe dehydration, wrinkling persists >2 sec. In severely wasted children skin pinch will not recoil in normal hydration. The dryness of buccal mucosa is a reliable sign to assess dehydration in them. *To assess oral mucosal dryness*, introduce the index finger between the inner cheek and upper jaw posteriorly. Severe dehydration can lead to hypotension, anuria, renal failure, and coma.

The most common cause of dehydration in children is diarrhea. Repeated vomiting, excessive gastric aspiration, diabetic ketoacidosis, IEM, diuretic therapy, salicylism, diabetes insipidus, renal tubular acidosis (RTA), and starvation are other causes. Dehydration and anasarca may coexist in nephrotic syndrome, chronic liver failure, chronic congestive heart failure, and edematous malnutrition. In young babies presenting with unaccountable dehydration exclude congenital adrenal hyperplasia and RTA.

Oxygen Saturation

Low oxygen saturation is fatal unless corrected at the earliest. Hypoxemia can be screened by a pulse oximeter [a handy, easy to operate, reliable, cheap device, safe to home care patient also since it needs only minimal training **(Fig. 7.8)**]. The device measures the percentage saturation of hemoglobin (Hb) bound with oxygen in the blood. It is operated by applying the probe of the oximeter over a capillary-rich area of the body, ideally the pulp of the index or middle finger. Toes or ear lobules are advisable for newborns. The hand should not be cold or wet, be clean and warm, and nail polish removed. An appropriate-size probe is attached to the finger. As infrared light is passed through the fingertip, the oxygen saturation value appears along with the pulse rate. The value is noted as the reading becomes stable. Normal oxygen saturation is >95%. <90% in <5 yr children is hypoxemia and require oxygen therapy. The drawbacks are that accuracy is less in severe desaturation (<70%), hemoglobinopathies, hypotension, and carbon monoxide (CO) poisoning.



Fig. 7.8: Pulse oximeter recording.

Assessment of Danger Signs

Pallor, icterus, cyanosis, clubbing, lymphadenopathy, edema (acronym *PICCLE* signs), bleeding tendency, skin changes, subcutaneous emphysema, and bone tenderness are the danger signs.

- *Pallor* is the pale appearance of skin and mucous membranes usually due to anemia [caused by reduced number of red blood cells (RBCs)] or due to shock (subsequent to decreased perfusion). As per the WHO, anemia is Hb <11g/dL in children <4 yrs, <11.5 g/dL in 5–7 yrs, and <12 g in 8–14 yrs of age. Examine for pallor over the conjunctiva, mucosa, tongue, palms, skin, and nails. Pallor without anemia is seen in vasovagal episodes and septic shock. In severe pallor, palmar creases reveal faded appearance. Tachycardia and edema indicate the complication of congestive

JAYPEE BROTHERS

heart failure due to severe anemia. If there is koilonychia or spoon-shaped nails, it indicates iron deficiency. The presence of petechiae indicates platelet deficiency in number or qualitative defect and bone marrow aplasia or infiltration. Hyperpigmentation of the knuckles is pathognomonic of megaloblastic anemia seen in vegans (strict vegetarians); whereas, in congenital aplastic anemia, it is circumoral in distribution.

- *Icterus (jaundice)* is yellowish discoloration of the body due to the increase in serum bilirubin (>5 mg/dL in newborns and >2 mg/dL in older children). It is best detected in daylight by looking at the sclera **(Fig. 7.9)** and less on the undersurface of the tongue, palms, and skin (Ref. Ch. 15 for newborn jaundice). Yellowish discoloration of the body can occur in carotenemia also in which clinical manifestations and the investigations will be noncontributory. **Table 7.6** reveals the salient differentiating points between direct and indirect hyperbilirubinemias.
- *Cyanosis* is bluish color of skin and mucosa **(Fig. 7.10)** due to increased amount of reduced Hb (>5 g/dL) in superficial blood vessels. It can be *central* when both mucosa and skin are blue or **peripheral** if extremities only are blue with cold peripheries or *differential* if only upper or lower limbs are blue (Ref. Ch. 17). The causes of cyanosis are discussed in **Box 7.2**. Oxygen saturation may reach <85% in cyanosis. Hence, in severe anemia with Hb <5 g/dL, cyanosis may not be obvious clinically.
- *Digital clubbing* is selective enlargement of the distal segment of fingers or toes induced by chronic hypoxia (should be for at least 6 w) leading to increased capillary permeability



Fig. 7.9: Yellow sclera in jaundice.

TABLE 7.6: Differentiating points in two types of jaundice.

Signs	*Conjugated hyperbilirubinemia*	*Unconjugated hyper bilirubinemia*
Color of sclera	Orange yellow	Lemon yellow
Urine color	Dark yellow	Lemon yellow
Stool color	Clay color	Normal color
Body scratches	Very obvious	Absent
Liver changes	Obvious	Nil
Splenomegaly	±	Present
Urine bile salts	Present	Absent
Urine urobilinogen	+++	Absent
Bleeding tendency	Usual	Absent

JAYPEE BROTHERS



Fig. 7.10: Cyanosis, stage 3 clubbing.

TABLE 7.7: Clinical grading of clubbing.

Grade	*Clinical signs*
I	Increased fluctuation at the nail bed
II	Obliteration of the angle at the nail bed
III	Loss of longitudinal ridges of the nail, increased convexity of the nail from above downwards and from side to side "Parrot beak appearance" **(Fig. 7.10)**
IV	The terminal segment becomes bulbous like the end of a drumstick. Pain and swelling of wrist and hands

BOX 7.2: Causes of cyanosis in children.

Central cyanosis:

- Respiratory:
  - Congenital anomalies of the airways and lung
  - Foreign body impaction of airways
  - Progressive pneumonias
  - Tension pneumothorax
  - Pleural effusion
  - Suppurative lung diseases
  - Cystic fibrosis
  - Alveolar hypoventilation syndromes
  - Bronchopulmonary dysplasia
- Cardiovascular

Cyanotic congenital heart diseases (TOF, TGA with VSD, TAPVR, and pulmonary AV fistula)

- *Hemoglobin abnormalities:*
  - Methemoglobinemia
  - Sulfhemoglobinemia
  - Caboxyhemoglobinemia
- *Peripheral cyanosis:*
  - Exposure to cold
  - Shock
  - Vascular thromboembolism (arterial, venous)
  - Raynaud phenomenon

(AV: arteriovenous; TAPVR: total anomalous pulmonary venous return; TGA: transposition of the great arteries; TOF: tetralogy of Fallot; VSD: ventricular septal defect)



Fig. 7.11: Eliciting Schamroth sign.

and connective tissue hypertrophy by platelet-derived growth factor. Four grades of clubbing are described clinically **(Table 7.7)**. Clinical detection of advanced clubbing (grade III and IV) is easy. Grade II clubbing is best detected by:

i. *Schamroth sign* is the obliteration of the diamond-shaped space at the base of the nail bed when the dorsal surfaces of the terminal phalanges of similar fingers are placed in opposition **(Fig. 7.11)**.
ii. *Obliteration of Lovibond's angle:* The angulation between the nail plate and the skin below the nail is

JAYPEE BROTHERS

normally <180°. Hold the finger in profile, horizontally at the level of the eyes to see the angle. In clubbing as the tissues at the base of the nail become thickened, this angle is lost.

iii. *Phalangeal depth ratio:* Normally the distal phalangeal depth (DPD) is smaller than the interphalangeal depth (IPD). In clubbing DPD exceeds IPD because of the basal tissue proliferation of the fingertip; look at the profile of the finger held at eye level or measure the depth by calipers. The DPD/IPD ratio will be >1 (normally it is <1). **Box 7.3** shows the causes of clubbing in children.

In *koilonychia*, seen in iron deficiency anemia, nails become soft, thin, brittle, and spoon-shaped. This sign is uncommon in children.

- *Lymphadenopathy* or enlargement of lymph nodes is common in children due to repeated bacterial and viral infections producing lymphoid proliferation.
  - *Approach:* Enlarged lymph nodes present as swellings which may be the primary complaint or they may be incidentally detected while examining the child. The first step is to exclude the nonlymphoid masses simulating lymph nodes. In the neck, there are thyroid masses (goiter, thyroglossal cyst, and thyroid abscess), branchial cleft cyst/or infected sinus, neurofibroma, cystic hygroma, cervical rib, and sternomastoid tumor. Assess clinically and by relevant investigations. **Figure 7.12** reveals rapidly enlarging cystic hygroma with tracheal compression in an infant. Cervical, axillary, epitrochlear, inguinal, and popliteal lymph nodes can be examined clinically.

BOX 7.3: Causes of clubbing in children.

- Hereditary
- Idiopathic
- *Cardiac:*
  - Cyanotic congenital heart disease
  - Bacterial endocarditis
  - Chronic congestive heart failure
- *Respiratory:*
  - Lung abscess
  - Bronchiectasis
  - Chronic pneumonia
  - Empyema
  - Cystic fibrosis
  - Malignant neoplasms
  - Pleural mesothelioma
  - Tuberculosis (rare)
- *Gastrointestinal:*
  - Celiac disease
  - Chronic dysentery
  - Crohn's disease
  - Polyposis of intestine
  - Ulcerative colitis
- *Hepatic:*
  - Biliary cirrhosis
  - Chronic active hepatitis
- *Others:*
  - Hodgkin disease
  - Thyrotoxicosis
  - Congenital methemoglobinemia



Fig. 7.12: Cystic hygroma of the neck.

JAYPEE BROTHERS

- *Cervical lymph nodes:* The examiner may stand or sit facing the child; change the position as needed according to the lymph node groups and cooperation of the child. *Observe* the lymph nodes for redness, surrounding edema, ulceration, granuloma, or discharge. *Palpate* the nodes (on the left side with the right hand and vice versa) gently with the pulp of the index and middle fingers. Assess the size, location, consistency, tenderness, whether isolated or matted, presence of fluctuation, mobility/fixation to the skin or to other tissues. Palpate in order the preauricular, retro auricular, tonsillar, submandibular, submental, posterior cervical, anterior cervical, deep cervical, pretracheal, and lastly the supraclavicular groups. Examine the drainage area of the cervical lymph nodes (head and neck) for pediculosis, infections, ulcers, or swelling. **Figure 7.13** shows tuberculous lymph nodes on the posterior triangle of the neck.
- *Axillary lymph nodes:* With your left hand lift the patient's left arm to get it relaxed; palpate deeply with your right hand for the apical, medial, anterior, posterior, and lateral groups of lymph nodes; palpate the right axillary glands with your left hand in the same way. Posterior axillary lymph nodes are better palpated on standing behind the patient. Examine the drainage areas, i.e., upper limbs, breasts, chest, and upper abdomen for ulcers, infected wounds, lumps, and scratch marks.
- *Epitrochlear lymph nodes* are characteristic of infectious mononucleosis (IMN) and cat scratch disease (CSD). Gently hold the patient's forearm across the chest (left hand of the child with the left hand of the examiner and vice versa) and palpate with the fingers of the other hand above the epitrochlear region. Examine for scratch marks/ulcers on the forearm.
- *Inguinal lymph nodes* have superficial and deep groups; the former are visible, have vertical and horizontal groups, and are easy to see and palpate (examiner sitting and facing the child; child seated on the mother's lap/chair or standing). The vertical group is close to the long saphenous vein and drains the leg; the horizontal group is just above the inguinal ligament and drains the lower abdominal skin, anal canal, buttocks, lower vagina, and external genitalia excluding the testes.
- *Popliteal lymph nodes* are difficult to approach and need deep palpation. *Inspect the drainage area of each group of lymph nodes* for infection/scratch marks (characteristic of CSD), wounds, or insect bites to detect the etiology. Enlargement of cervical and axillary lymph nodes >1 cm and



Fig. 7.13: Tuberculous lymphadenopathy neck.

JAYPEE BROTHERS

for detailed information on pediatric books, visit our website www.jaypeebrothers.com, for detailed information on pediatric books, visit our website www.jaypeebro

Clinical Evaluation of Newborns, Infants and Children

Salient Features

- Provides a very good perspective in clinical assessment of newborns, infants, and children
- The contributors are eminent faculties with sufficient teaching experience from the most prestigious medical colleges of Kerala providing simplified student-friendly clinical approach
- Latest growth charts (WHO and other accepted ones) and tables are provided
- The initial four chapters deal with the various aspects of communication for medical students which will enable them to interact with patients and their parents, and face examinations and interviews confidently
- All chapters are well-elaborated with self-explanatory clinical photographs, systematic discussion and descriptive tables and clinical case scenarios
- Compact and handy with attractive, uniquely informative cover with different clinical scenarios

S Sushamabai MD (Pediatrics) DCH FIMSA FIAP is former Professor and Head, Department of Pediatrics, Government Medical College, Kottayam, Kerala, India, and also former Professor and Head, Department of Pediatrics, Pushpagiri Medical College, Pushpagiri Institute of Medical Sciences and Research Centre, Thiruvalla, Kerala. She is a renowned faculty in pediatrics with 47 years of teaching experience. She had her MBBS, DCH and MD (Peds) from the prestigious Government Medical College of Thiruvananthapuram in flying colors and had served in the Government Medical Colleges of Thiruvananthapuram, Kottayam and Kozhikode in different cadres. She was an internal and external examiner in MBBS, DCH, and MD (Pediatrics) examinations in all universities in Kerala and several universities in South India and is an astute clinician and an elegant academician. She is an elegant speaker at national and international forums. She has more than 125 scientific papers published in national and international journals. The main topics of interest for her studies are snake envenomation in children, childhood developmental delay and deviant development, childhood pneumonias, type 1 diabetes mellitus, and infectious diseases. Several chapters to many books have been contributed by her. Books written (1) *Clinical Evaluation of Newborns, Infants and Children* by M/s Jaypee Brothers Medical Publishers (P) Ltd, New Delhi, India (approved by the Kerala University of Health Sciences) for undergraduate and postgraduate study in pediatrics; (2) *Handbook of Pediatric and Neonatal Emergencies* (Jaypee Brothers). Her social commitments are many such as health education through mass media, school health programs, and caring for the disabled children through institutions and at community level. She is an active member of various organizations in the medical fraternity and a strong woman with exemplary leadership skills. She is Lifetime Member of the Indian Academy of Pediatrics (IAP), Indian Medical Association (IMA), IMA-Academy of Medical Specialities (IMA-AMS), and all subspecialties in pediatrics. She was Kerala State IAP President 2003 and Kerala State NNF (National Neonatology Forum) President 2005. She was Member of the Faculty of Medicine, Mahatma Gandhi (MG) University, Kerala, and Member of the MBBS Curriculum Committee of Kerala University of Health Sciences (KUHS).

Awards received:
(i) FIMSA 2000 Millennium Medal of Honor for the overall contributions in Pediatrics at the National Level; (ii) Dr PA Alexander Oration Award for the Best Doctor, IMA-AMS, Kerala; (iii) Best State President of IAP, Kerala, 2003; (iv) FIAP 2004; (v) Strong woman leader, IAP, Kottayam, Kerala, on International Women's Day 2021.

Printed in India

Available at all medical bookstores or buy online at www.ejaypee.com

JAYPEE BROTHERS
Medical Publishers (P) Ltd.
EMCA House, 23/23-B, Ansari Road,
Daryaganj, New Delhi - 110 002, INDIA
www.jaypeebrothers.com

Join us on facebook.com/JaypeeMedicalPublishers
Follow us on instagram.com/JaypeeMedicalPublishers

Shelving Recommendation
PEDIATRICS

ISBN 978-93-5696-736-6