nation on orthopedics books, visit our website www.jaypeebrothers.com, for detailed information on orthopedics books, visit our website www.jaypeebrothers.com



ORTHOPEDIC EXAM REVIEW

A Comprehensive Manual for Postgraduates

For MS, DNB & Diploma Students

Ashraf Shaikh

2nd Edition

JAYPEE

Contents

1. BASIC AND APPLIED SCIENCES 1

Calcium Metabolism *1*
Rickets *2*
Osteomalacia *4*
Osteoporosis *5*
Bisphosphonates (BP) *9*
Denosumab *10*
Parathyroid Hormone and Disorders *11*
Brown Tumor *12*
Scurvy *12*
Skeletal Fluorosis *14*
Development of Skeleton – Principles and Application *15*
Collagen *18*
Bone Healing *18*
Cartilage *20*
Cartilage Injuries and Defects *21*
Autologous Chondrocyte Implantation (ACI) *23*
Synovial Fluid Analysis *24*
Gait *27*
Blood Components *30*
Hazards of Blood Transfusion *32*
Autologous Transfusion *33*
DVT And Pulmonary Embolism *34*
Thromboprophylaxis/New Anticoagulants/ LMWH *35*
Fat Embolism *36*
Tourniquet *37*
Compartment Syndrome *38*
Stress and Strain *41*

2. PEDIATRIC ORTHOPEDICS 44

Proximal Femoral Focal Deficiency (PFFD) *44*
Perthes Disease *47*
DDH *50*
Slipped Capital Femoral Epiphysis *56*
Coxa Vara *59*
Angular Deformities of LL in Children *60*
Congenital Pseudoarthrosis of Tibia (CPT) *64*
Tibia Vara *65*
CTEV *67*
Congenital Vertical Talus (CVT) *69*
Calcaneovalgus Foot *70*
Torticollis *71*
Congenital Radio-ulnar Synostosis *72*
Polydactyly *73*
Congenital Trigger Thumb *74*
Limping Child *74*
Spina Bifida *74*
Trash Lesions (The Radiographic Appearance Seemed Harmless) *75*

3. HIP 77

Hip Biomechanics *77*
Approaches to Hip Joint *79*
Osteonecrosis (HIP)/AVN/Chandler's Disease *81*
Femoroacetabular Impingement *84*
Hip Arthroscopy *87*
Hip Resurfacing Arthroplasty (HRA) *89*
Femoral Neck Fracture Nonunion *90*
Evolution of THR *92*
Bearing Surfaces in Total Hip Arthroplasty *92*
Tribology *93*
Complications of THR and Periprosthetic Hip Fractures *94*
Osteoarthritis Hip *99*
Safe Surgical Dislocation of Hip/Ganz Surgical Dislocation of Hip *100*

4. KNEE 103

Knee Arthroscopy *103*
Anterior Cruciate Ligament Tear *105*
Posterior Cruciate Ligament Injuries *109*
Posterolateral Corner (PLC) Injury *110*
Meniscus *112*
Discoid Meniscus *115*
Meniscal Cysts *116*
Synovial Plicae/Plica Syndrome *116*
Recurrent Dislocation of Patella *117*
Osteochondritis Dissecans *120*
Osteoarthritis of Knee *121*
High Tibial Osteotomy *123*
Unicompartmental Knee Replacement *125*
Total Knee Replacement 126

5. SPINE 130

Anatomy of Vertebral Column *130*
Spinal Approaches *134*
Intervertebral Disc: Anatomy, Physiology and Prolapse *137*
Cervical Spondylosis *138*
Spondylolysis and Spondylolisthesis *142*
Lumbar Canal Stenosis *144*
Cauda Equina Syndrome *145*
Scoliosis *146*
Pedicle Screw *150*
Lateral Mass Fixation for Cervical Spine *151*
Vertebroplasty and Kyphoplasty *152*
Video-assisted Thoracic Surgery *154*
Minimally Invasive Spine Surgery *155*
Dural Tear *156*
Somatosensory–Evoked Potentials *157*
Nerve Root Blocks/Epidural Steroids *158*
Spinal Fusion Methods *159*
Role of Physiotherapy in Low Back Pain *160*
Failed Back Syndrome *161*

6. SHOULDER 163

Shoulder Instability/Recurrent Shoulder Dislocation *163*
Frozen Shoulder *168*
Rotator Cuff Disease *169*
Long Head of Biceps Brachii Rupture *171*
Reverse Shoulder Arthroplasty *172*

7. FOOT AND ANKLE 175

Arches of The Foot *175*
Blood Supply of Talus *176*
Tarsal Tunnel Syndrome *177*
Tarsal Coalition *178*
Flat Foot *180*
Hallux Valgus (Bunion) *181*
Retrocalcaneal Bursitis/Haglund *183*
Post-polio Residual Paralysis *184*
Claw Toes *185*
Triple Arthrodesis *187*

8. ORTHOPEDIC DISEASES 189

Osteogenesis Imperfecta *189*
Cerebral Palsy (Static Encephalopathy) *190*
Cleidocranial Dysostosis *195*
Achondroplasia *196*
Sprengel Deformity *197*
Klippel-Feil Syndrome *198*
Duchenne Muscular Dystrophy *198*
Gout *200*
Hemophilia *202*
Paget's Disease (Osteitis Deformans) *204*
Osgood-Schlatter Disease *206*
Carpal Tunnel Syndrome *206*
Tennis Elbow/Lateral Epicondylitis *208*
Dupuytren's Contracture *209*
Madelung Deformity *210*
Dequervain's Tenosynovitis *211*
Wrist Arthrodesis *213*
Kienbock's Disease *214*
Thoracic Outlet Syndrome *215*
Cervical Rib *216*

Rheumatoid Arthritis *217*
Rheumatoid Hand *221*
Pigmented Villonodular Synovitis (PVNS) *222*

9. BONE TUMORS 225

Introduction to Bone Tumors—Classification, Benign vs Malignant *225*
Bone Biopsy *227*
Aneurysmal Bone Cyst *227*
Giant Cell Tumor *229*
Osteoid Osteoma *231*
Chondroblastoma *232*
Chondrosarcoma *233*
Osteosarcoma *235*
Fibrous Dysplasia *236*
Ewing's Sarcoma *238*
Osteochondroma *239*
Amputation vs Limb Salvage/Principles of Surgery in Bone Tumors *241*
Multiple Myeloma *243*
Metastatic Bone Disease and Differentials *245*
Synovioma/Synovial Cell Sarcoma *247*
Muscle Biopsy *248*

10. BONE AND JOINT INFECTION 249

Osteomyelitis–Acute and Chronic *249*
Types of Sequestrum *253*
Septic Arthritis *253*
Tuberculosis of Hip *256*
TB Spine *258*
Psoas Abscess *263*
Mycetoma/Madura Foot *264*

11. TRAUMA 266

Monteggia Fracture–Dislocation *266*
Pelvis Fractures *268*
Acetabular Fractures *271*
Hip Dislocation *274*
Spinal Cord Injuries *276*
Hangman's Fracture *284*
Odontoid Fracture *285*
Canadian C-Spine Rule *286*
Morel Lavallee Lesion *286*
Scaphoid Non-union *288*
Terrible Triad of Elbow *290*
TFCC Injury *291*
Bennet and Rolando Fractures *292*
Carpal Instability *293*
Lunate Dislocation (Perilunate Dissociation) *294*
Flexor Tendon Injuries – Hand *295*
Game Keeper's Thumb *298*
Paediatric Fractures – Principles and Management *299*
Lateral Condyle of Humerus Fracture – Paediatrics *301*
Supracondylar Fracture Humerus – Paediatrics *302*
Paediatric Diaphyseal Forearm Fractures *304*
Pediatric Neck of Femur Fractures *305*
Complications of Colles' Fracture *307*
Ankle Sprain *308*
Ankle Injuries *309*
Lisfranc Injury *311*
Talus Neck Fractures *313*
Calcaneal Fractures *314*
Jones Fracture/5th Metatarsal Base *317*
Tendoachilles Tendon Rupture *318*
Chest Injuries *319*
Polytrauma *323*
Gas Gangrene *325*
Dynamization of Fractures *326*
Stress Fracture *326*

12. ORTHOPEDIC RADIOLOGY 329

Image Intensifier *329*
MRI *330*
CT Scan *333*
Nuclear Medicine Scans *333*
Ultrasound (US) *334*

13. OTHER TOPICS 337

Bone Cement *337*
Bone Bank *339*
Amputation *340*
Peripheral Nerve Injuries and Nerve Conduction Studies *343*
Brachial Plexus *346*
Obstetric Paralysis *349*
Median Nerve *350*
Ulnar Nerve *352*
Radial Nerve *353*
Nonunion (NU) *354*
Lld/Limb Lengthening/Ilizarov *358*
Masquelet Technique *364*
Volkmann Ischemic Contracture *365*
Chronic Regional Pain Syndrome (CRPS) *367*
Heterotopic Ossification *368*
Neurogenic Bladder *370*
Obturator Neurectomy *371*
Prosthesis *372*
Myoelectric Prosthesis *373*
Jaipur Foot *374*
Spinal Orthoses *374*
PTB Cast *374*
Traction in Orthopedics *375*
Gallow's/Bryant's Traction *376*
Thomas Traction Splint *377*
Skull Traction *377*
Bone Plates *378*
Tension Band Principles *380*
Locking Plate *381*
External Fixator *382*
Implant Removal *383*
Preoperative Preparation of Patient *384*
Rehabilitation of a Paraplegic Patient *385*

14. RECENT ADVANCES 387

Bone Substitutes *387*
Orthobiologics and BMP *389*
BMP (Bone Morphogenic Protein) *389*
Laminar Air Flow *390*
Reamer Irrigator Aspirator *391*
Fibrin Gel *392*
Lasers *393*
Gene Therapy *394*
Short Wave Diathermy *395*
Interferential Therapy *396*
Negative Pressure Wound Therapy (NPWT) *397*
Radiofrequency Ablation *397*
Ozone Therapy *398*
Vascularized Fibula Graft *399*
Intramedullary Nailing–Recent Advances *400*
Recent Advances in THR *402*
Viscosupplementation *402*
Stem Cells *404*
Bioabsorbable Implants *405*
Tranexamic Acid in Orthopedics *406*
Day Care Surgery *407*
Navigation and Robotics *408*
Isokinetic Exercises *409*
Tens Therapy (Transcutaneous Electrical Nerve Stimulation) *410*
OT Lights *411*
Evidence-based Medicine *413*

Index 415

SECTION

3

Hip

HIP BIOMECHANICS

I. BIOMECHANICS

1. Biomechanics is the study of forces (internal and external) acting on a living body.
2. Hip acts as a class I lever **(Fig. 1)**.

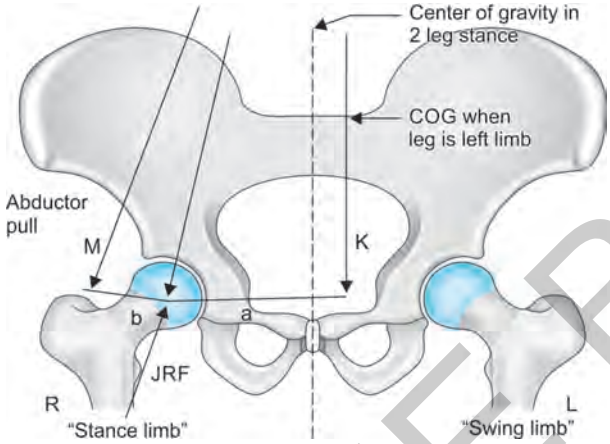

3. When both legs are on the floor → each hip carries 1/3rd body weight equally.
   (weight of the trunk and upper limb = $\frac{4/6}{2}$ = 1/3rd).
4. They do not have to carry contralateral limb weight.
5. The center of gravity is centered between both hips.
6. Moment (torque) = Product of force and the distance from which it acts.
7. Joint reduction force (JRF) → Force generated within a joint in response to the forces acting on a joint.

JRF = Abductor muscle force (M) + Body weight (K)
When the (L) lower limb lifted
↓
Its weight is added to the body weight (4/6 + 1/6 = 5/6)
↓
Also, the center of gravity is shifted to the (left)
The pelvis would tilt toward the (left) due to the BW
↓
- The abductors exert a counterbalancing force to maintain equilibrium
- Body weight (K) x moment arm (a) = Abductor force (M) x moment arm (b)
- [N] lever arm → a = 2.5b to 3b
- Therefore, the abductor pull must be three times that of BW

↓
Longer the abductor lever arm
↓
Less abduction force required to maintain balance
↓
Less pressure force on femoral head

II. APPLICATIONS

1. In Trendelenburg gait → Patient tilts toward the affected hip
   ↓
   Shifting the center of gravity toward it → ↓ BW lever arm
   ↓
   Less abductor pull needed → ↓ force on FH
2. Use of cane in C/L limb **(Fig. 2)**

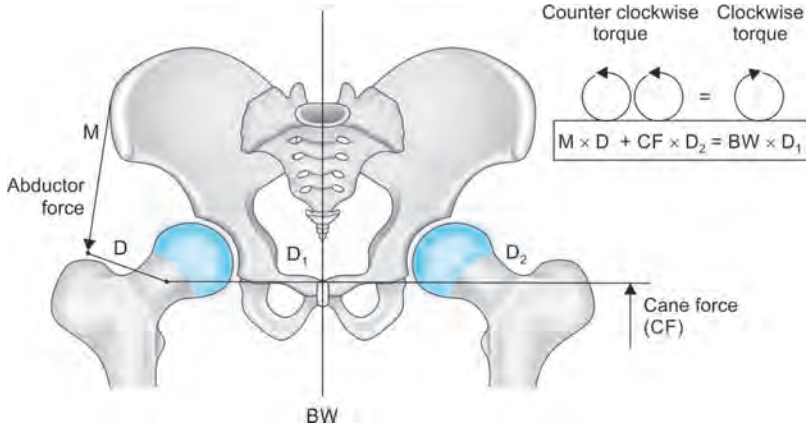

JAYPEE BROTHERS

Long lever arm of cane → substantially reduced JRF
↓
Only 15% BW applied through cane → Reduces JRF by 50%
↓
Coxa valga → decreased abductor lever arm
↓
Abductor muscle force↑↑
↓
∴↑Joint reaction force
↓
Coxa vara ↑Abductor lever arm
↓
↓Abductor muscle force
↓
↓Joint reaction force
However, as abductor length is decreased
↓
Muscles have to use more energy to contract → Fatigue easily

Other biomechanical aspects (Elaborate on these headings in the exam).

1. Mechanical aspects of LL
2. Anatomical axis of femur
3. Femoral anteversion
4. Femoral neck – shaft angle
5. Center of gravity → In front of S_2

III. APPLICATIONS IN THR

Principle: To reduce joint reaction force
↓
[N] ratio of length of lever arms of body weight and abductor muscle is 2.5 : 1
↓
In arthritis of the hip → Abductor lever arm is reduced due to destruction of the FH
↓
Further ↑ force on the joint
↓
Correction of the ratio is achieved by
↓
Centralization of femoral head by deepening acetabulum
↓
Reduces body weight lever arm
↓
Increased neck length
↓
Lengthens abductor lever arm
∴ Both ↓JRF → ↓Wear of implants
↓
JRF minimal → Hip center in anatomical position

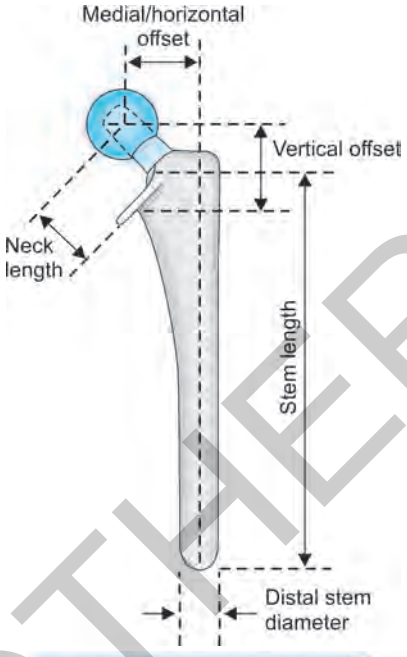

If medial offset is ↓ (inadequate)
↓
Shorter abductor lever arm
↓
Limp | Raised JRF | ↑Bony impingement
↓
Dislocation, wear
↓
If medial offset is excessive
↓
↑Stress on stem and cement
↓
Loosening and periprosthetic fracture

1. Neck length is very important as it affects both vertical and horizontal offset **(Fig. 3)**.
2. Principle of medialization has given way to → preserving subchondral bone.

↓

3. Deeper acetabulum only as much necessary → to obtain bony coverage.
4. THRs are done without GT osteotomy → Abductor lever arm altered only relative to the offset of head and stem.
5. ROM → influenced by prosthesis design **(Fig. 4)**.

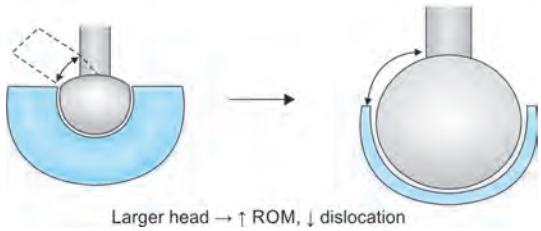
Larger head → ↑ ROM, ↓ dislocation

JAYPEE BROTHERS

6. **Component orientation**
   1. *Acetabular position*: (Lewinnek safe zone)
      1. Anteversion: 15–20°
      2. Abduction: 45–50°
   2. *Femoral stem position*:
      Anteversion → 15°
      ↑ → Anterior dislocation
      ↓ → Posterior dislocation.
   3. Further reading: Spinopelvic alignment and its effect on acetabular shell positioning. (Recent hot topic)

APPROACHES TO HIP JOINT

I. CLASSIFICATION

A. Based on Direction

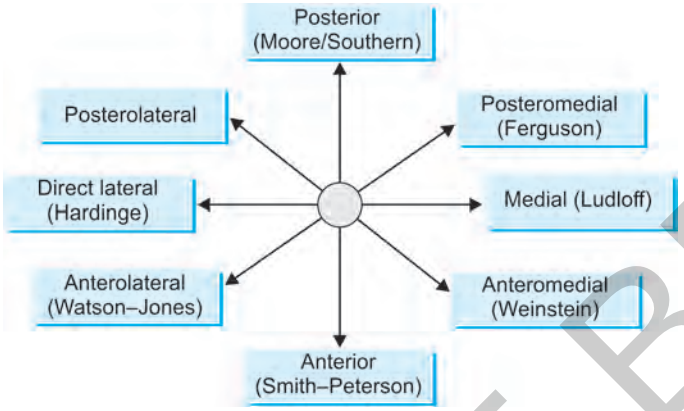

B. Based on Incision and Invasiveness

1. Standard incision (e.g., posterior)
2. Mini incision (MIS)

C. Based on Type of Surgery

1. Open
2. Arthroscopic

a. Anterior approaches:

Indications:

i. Arthrotomy (Infections)
ii. Synovial biopsies
iii. Pelvic osteotomies
iv. Excision of tumors, myositis ossificans
v. Anterior column fractures of acetabulum
vi. Open reduction of developmental dysplasia of the hip (DDH) when dislocated femoral head lies anterior superior to the true acetabulum.
vii. Intra-articular fusions.
viii. Arthroplasty → Total / Hemi

1. **Smith–Peterson: Iliofemoral (Fig. 5)**

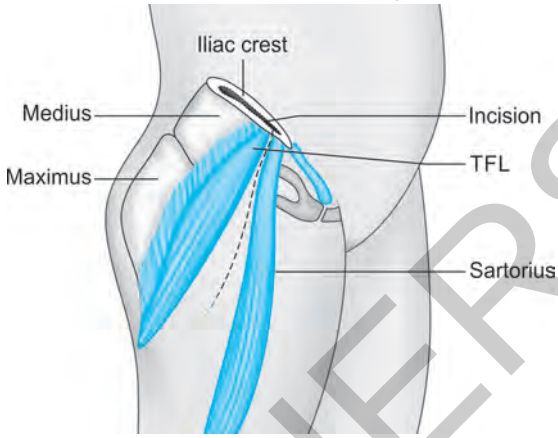

i. *Position:* Supine with sandbag under the pelvis on the operating side.
ii. *Incision:* Longitudinal incision between anterior iliac crest toward upper thigh curving over the anterior superior iliac spine.
iii. *Soft-tissue dissection:*
   1. Superficial: Sartorius and TFL
   2. Deep: Rectus femoris and gluteus medius
iv. *Internervous plane:* Femoral nerve (sartorius) and superior gluteal nerve (TFL)
v. *Arthrotomy:* Adduct and externally rotate
   ↓
   Excision capsule longitudinally or F – shaped
vi. *Dislocation:* By ER
vii. *Closure:* In layers, capsule rarely closed. Fascial planes closed and skin.
viii. Advantages:
   1. Preservation of vascularity.
   2. Limits chances of dislocation
      ↓
   3. Limits muscle cutting and separation.
   4. No abductor disruption→No postoperative limping.
ix. *Disadvantages:* Limited access → technically demanding to place components in arthroplasty.
x. *Specific complications:*
   1. Lateral cutaneous femoral nerve

2. **Somerville–Transverse bikini incision**
3. **Anterolateral: Watson–Jones (Fig. 6)**

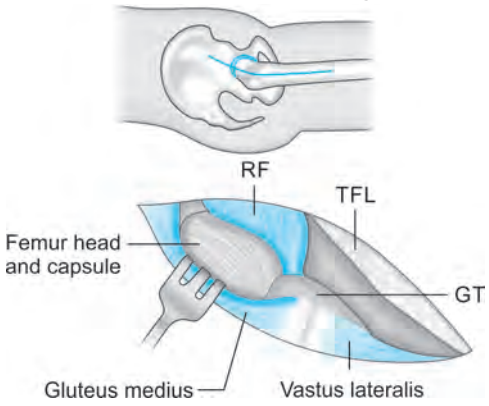

JAYPEE BROTHERS

i. *Position:* Supine or lateral.
ii. *Incision:* 10–15 cm longitudinal incision centered over tip of greater trochanter.
↓
Incision crosses the posterior third of the GT before running down the shaft.
iii. *Soft-tissue dissection:* Plane between tensor fascia lata and gluteus medius ↓
No internervous planes →–Both muscles supplied by SGN.
iv. *Extending:* Incising the fascia lata anteriorly or posteriorly.
↓
Extending down the lateral aspect of thigh → splitting the vastus lateralis to gain access to the lateral aspect of femur.
Trochanteric osteotomy may be needed.
v. *Arthrotomy:* Capsule is divided longitudinally over the anterior superior femoral neck.
vi. *Dislocation:* ER, traction and adduction.
vii. *Closure*:
1. Wound closed in layers starting with the capsule.
2. If a trochanteric osteotomy was done, it has to be reattached.
viii. *Advantages*:
1. Better stability.
2. ↓ Chances of dislocation → posterior
3. ↓ Sciatic nerve damage.
ix. *Disadvantages:*
1. Injury to SGN → Weakness of abductors
2. Damage to LCFA
x. *Modifications*:
1. Mueller's anterolateral minimally invasive approach
2. Ganz-trochanteric flip osteotomy

b. Lateral:
1. McFarland and Osborne
2. Hardinge
3. McLaughin and Hay
4. Harris

1. **Hardinge**

Transgluteal approach:
i. *Position:* Lateral or supine position.
ii. *Incision:* Posteriorly directed lazy J incision central over the GT, and in line with the femur shaft.
iii. *Soft-tissue dissection:* Gluteal fascia and ITB divided → Plane between tensor fascia and gluteus maximus identified.
↓
Gluteus medius tendon and muscle fibers and vastus lateralis split
→ ∴ No true internervous plane.
↓
G. medius split → Not >5 cm from tip of GT → to prevent injury to SGN **(Fig. 7)**.
iv. *Dislocation:* ER and abduction.
v. *Closure:* G. medius tendon repaired → non-absorbable suture. ITB required.
vi. *Advantages*:
Avoids need for trochanteric osteotomy → Early mobilization
↓ Sciatic nerve ⊗ compared to posterior approaches
vii. Complications:

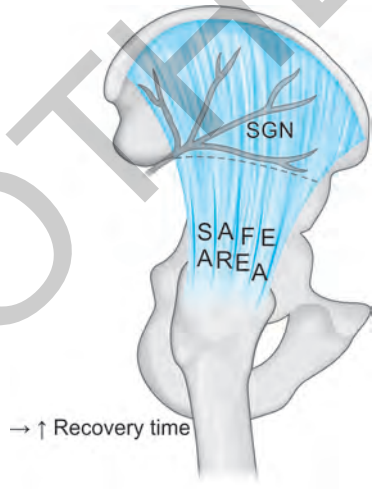

viii. Damage to G. medius → ↑ Recovery time.
ix. Heterotopic ossification.

c. Posterior:
1. Gibson–Posterolateral
2. Moore (Southern)
3. Osborne

Modified Gibsons:
1. *Position:* Lateral
2. *Incision:* Begin 6–8 cm anterior to posterior superior iliac spine (PSIS), just distal to iliac crest.
↓
Extend it distally to the anterior border of G. max.
↓
Distally along the line of the femur
3. *Soft-tissue dissection:*
i. ITB incised in line of its fibers.
ii. Extend incision along anterior border of G. maximus.
↓
iii. Separate posterior border of G. medius and piriformis.
↓
iv. Divide G. medius and minimus at their insertions → but leave enough for reattachment.

JAYPEE BROTHERS

4. *Dislocation:* Flex and IR hip.
5. *Advantage:*
   i. Excellent exposure to acetabulum and femoral neck.
   ii. Easy insertion of THR prosthesis.
6. *Disadvantage:* ↑ Posterior dislocation
   ↑ Sciatic nerve injury.

Posterior–Moore (Fig. 8):

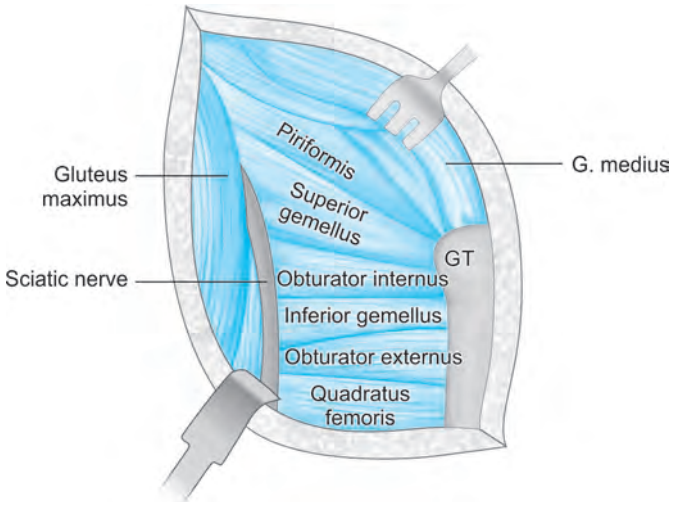

1. *Incision:* 10 cm distal to PSIS
   ↓
   Extending distally and laterally with the fibers of G. max.
   ↓
   To the posterior margin of GT.
   ↓
   Continued 10–15 cm distally parallel to the femoral shaft.
2. *Soft-tissue dissection*: Separate the fibers of G. max through blunt dissection → Not >7 cm → prevent IGN ⊗
   ↓
   G. medius retracted anteriorly
   ↓
   Short external rotators identified and cut > stay sutures.
   ↓
   Retracted posteriorly and prevent sciatic nerve injury.
3. *Arthrotomy:* T-shaped incision
4. *Dislocation, advantages, disadvantages:* Same as modified Gibsons.

II. MEDIAL APPROACH

1. *Indications:*
   i. Mainly in children → Protects blood supply and soft tissue.
   ii. Open reduction of DDH
   iii. Psoas release
   iv. Obturator neurectomy
   v. Adductor release
2. *Disadvantages:*
   i. Close to perineum
   ii. Limited exposure.
   iii. Deep incision → vascular injury
3. *Position:* Supine with flexion, Abduction, and external rotation, sole of foot lies along medial side of opposite knee.
4. *Incision:* Longitudinal incision on medial side of thigh → 3 cm below pubic tubercle.
5. *Ludloff:* Between pectineus and adductor longus and brevis.
6. *Weinstein:* Pectineus and neurovascular bundle.
7. *Ferguson:* (Superficially) A. Longus and Gracilis, (Deep) A. Brevis and Magnus **(Fig. 9)**.

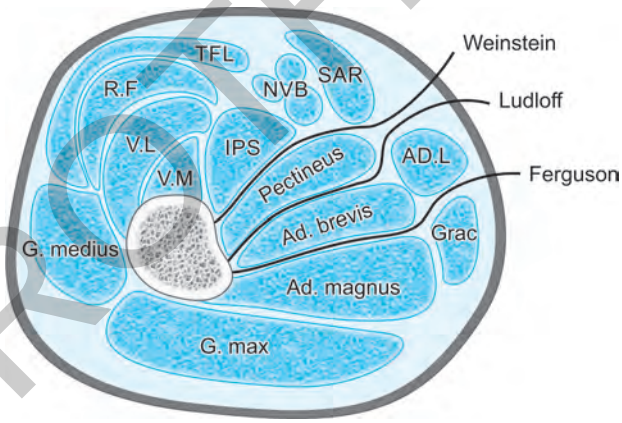

OSTEONECROSIS (HIP)/AVN/ CHANDLER'S DISEASE

Progressive destruction and alteration of bony architecture because of compromised vascularity.

I. ETIOLOGY AND CLASSIFICATION

ON → 1°: Idiopathic
ON → 2°: Underlying cause present

ON → Post-traumatic → Fracture of femur head, acetabulum, neck or hip dislocation
ON → Nontraumatic

1. Idiopathic
2. Drug induced
   1. Steroids (>20 mg/d for 3 months)
   2. Chemotherapy
   3. Smoking (>20 pack years)
   4. Alcohol (400 mL/week)
   5. Antiretroviral therapy
3. Irradiation
4. Hematological → Sickle cell, Thalassemia
5. Infection and autoimmune → HIV → SLE, RA → Septic arthritis

JAYPEE BROTHERS

6. Endocrine:
   1. Cushing's syndrome
   2. Hyperparathyroidism
   3. Pregnancy
7. Dysbarism–Caisson's disease
8. Metabolic → Gaucher's disease
   CRF
   Hepatic failure
   Hyperlipidemia

II. PATHOPHYSIOLOGY

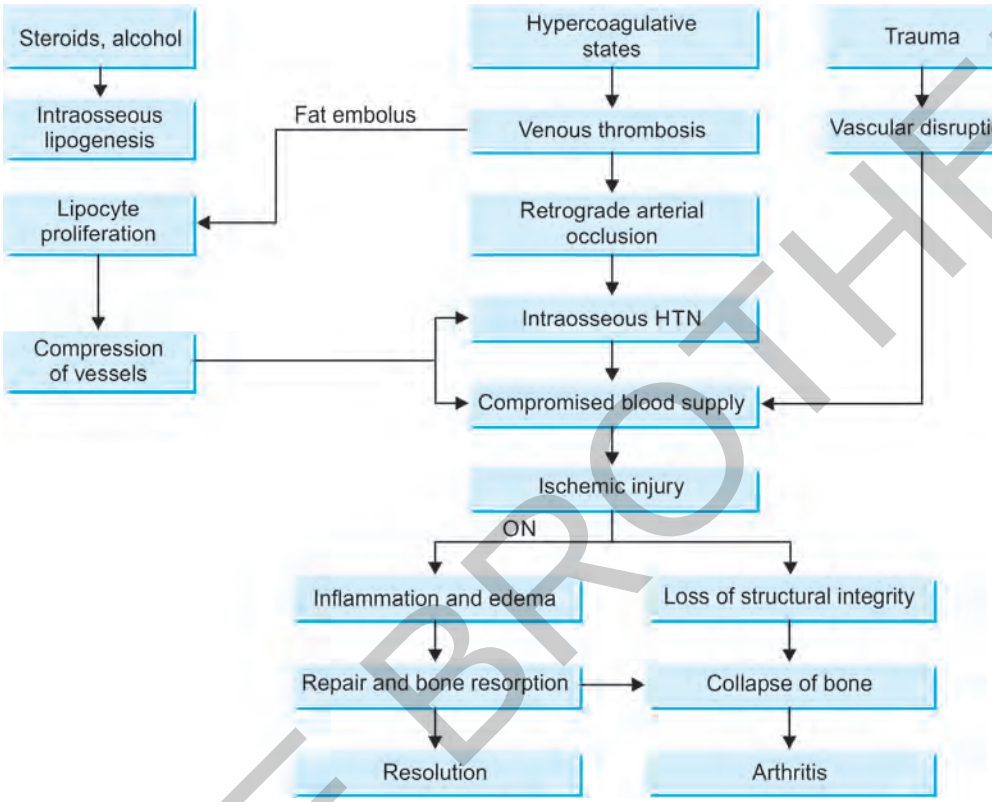

"Starlings resistor" → Femoral head **(Fig. 10)**

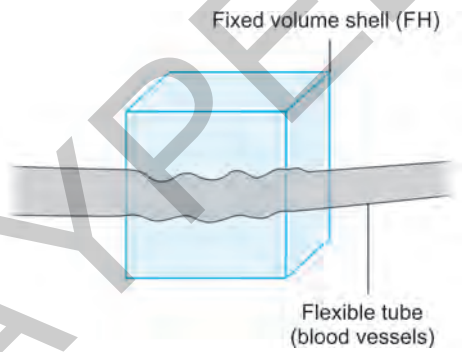

Fig. 10: "Starlings resistor" → Femoral head.
Pressure within the shell determines the flow within the tube.

III. CLINICAL PRESENTATION

1. Males > Females
2. *Age:* 35–50 years
3. *B/L:* 50%, steroid: 80%
4. *Pain:*
   i. Most common presenting symptom
   ii. Groin
   iii. Insidious onset
   iv. Progressive
5. *Limp:*
   i. Antalgic gait
   ii. Trendelenburg gait
6. *Restricted ROM:* Earliest IR
   ↓
   Knee to axilla sign
7. Thomas test → Flexion deformity
8. Sectoral sign – Differential rotation
9. Limb length discrepancy

IV. RADIOLOGICAL INVESTIGATIONS

1. *Classification:*

Modified Ficat and Arlet
Steinberg – University of Pennsylvania
ARCO: Association of Research Circulation Osseous

JAYPEE BROTHERS

2. Modified Ficat and Arlet **(Fig. 11)**

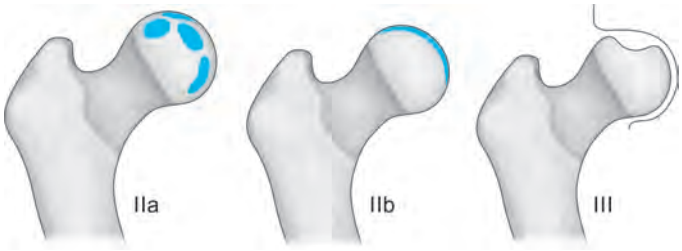

0: Normal/Silent hip
I: Cold spot on FH → Bone scan
II: Density changes in FH
IIA: Sclerosis, subchondral cysts
IIB: Crescent sign
III: Collapse of FH, JL—normal
IV: Joint space narrowing, acetabular changes (arthritis)

3. *MRI*:
   1. Highest sensitivity (99%) and specificity (99%)
   2. Double density sign
4. Bone scan → Doughnut sign
5. Modified Kerboul's angle → Midcoronal and midaxial sections
   Collapse risk **(Fig. 12)**
   >240° = High
   190–240° = Moderate
   <190° = Low

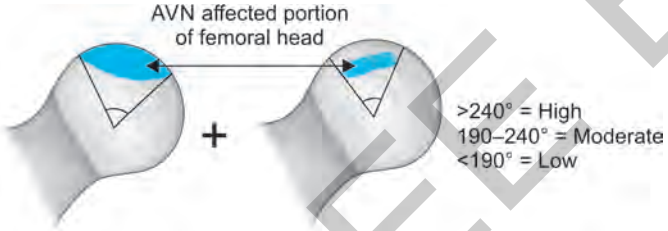

V. MANAGEMENT

A. Conservative

1. *Bisphosphonates:*
   i. Indicated in Ficat 0–II → Precollapse
   ii. Alendronate 70 mg/week × 3 years (Oral)
   iii. Zoledronic acid IV yearly 5 mg + alendronate 70 mg/week × years
2. *Other drugs (questionable efficacy):*
   i. Lipid lowering agents → Statins
   ii. Teriparatide
   iii. LMW heparin – Coagulopathy pts
3. *Adjuvant modalities:*
   i. Pulsed electromagnetic field (PEMF)
   ii. Extracorporeal shockwaves
   iii. Hyperbaric O_2 therapy

B. Operative

Hip preserving	*Hip sacrificing*
Aimed to relieve pain and prevent progression:	
1. Core decompression	1. Hip arthroplasty
2. Vascularized and nonvascularized bone grafting	2. Arthrodesis
3. Revascularization procedures	3. Excisional arthroplasty
4. Proximal femur osteotomies	4. Hip resurfacing
5. Osteochondral reconstruction	

a. **Hip preserving:**
   1. **Core decompression (Fig. 13):**
      Described by Ficat and Arlet in 1960s
      ↓
      Incidentally when they were trying to find cause of pain in ON
      i. *Indications*:
         1. Stage I and II → Relieves pain significantly.
         2. Age < 50 years
      ii. *Contraindications:* After FH collapse
      iii. *Technique*:
         1. *Traditional:* Drill an 8–10 mm hole through subchondral necrosis.
         2. *Alternative:* Multiple 3.2 mm channels drilled in different direction.
      iv. *Mechanism*:
      Decompression of starling's resistor → Compartment syndrome resolved
      ↓
      A. Relieves intraosseous pressure → relieves pain
      B. Stimulates healing response via angiogenesis
      v. *Additional modifications*:
         a. Fibula grafting:
            1. Most commonly used in India
            2. Mechanical support → prevents collapse
            ↓
            3. Predominantly cortical → Slow resorption
            4. Less regenerative tissue required to fill the defect
            5. → Nonvascularized
            6. → Vascularized
               i. Better channel for revascularization and regeneration.
               ii. Technically, demanding

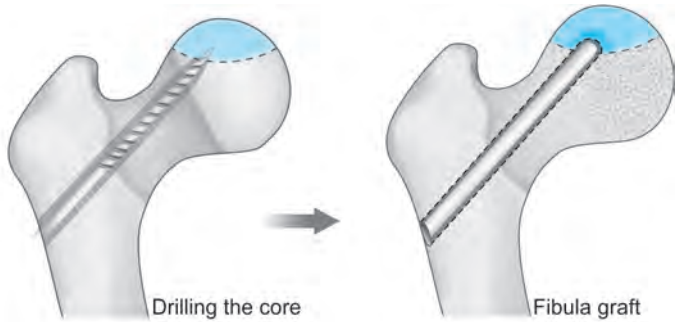

Fig. 13: Core decompression and fibula grafting.

JAYPEE BROTHERS

b. Bone marrow aspirate:
1. Technique:
i. Aspirated from iliac crest.
ii. Pooled aspirate → 150 mL
↓
iii. Filtered to removed fat and clotted blood
↓
iv. Concentration done at 400 g for 5 minutes
↓
v. Leukocytes removed → Aspirate = 30 mL
vi. Concentrate injected through core decompression hole under pressure.
2. Rationale:
Core decompression alone fails due to
↓
Insufficient creeping substitution from small number of progenitor cells in the necrotic and surrounding bone
↓
Bone marrow → Hematopoietic component
↓
Stromal component → Osteoprogenitor cells

vi. *Postoperative management:* Protected weight bearing for 6 weeks

vii. *Pearls*:
1. Avoid window below LT → Pathological fracture
2. Avoid entry in anterior half of femur
↓
Lesion anterolateral
3. Avoid FH perforation

viii. *Prognosis*:
a. Poor:
1. More 15% area of acetabular surface
2. Combined necrotic angle >240°
b. Good → Young patient

2. **Curettage and bone grafting techniques:**
i. Merle d'Aubigne light bulb: Through cortex of FH – Neck junction **(Fig. 14A)**
ii. Trapdoor (Mont): Through articular surface **(Fig. 14B)**.

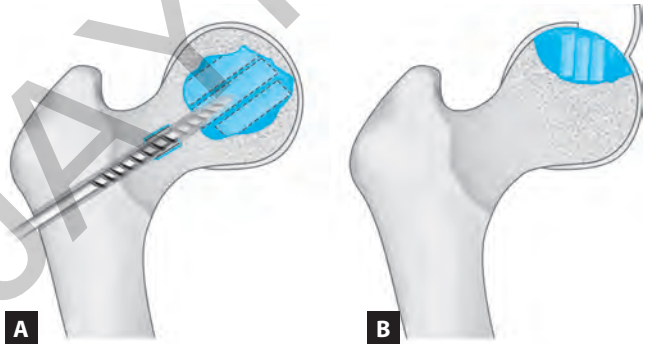

Figs. 14A and B: (A) Merle d'Aubigne light bulb; (B) Trapdoor (Mont).

iii. Local pedicle vascular bone graft
a. Meyer's quadratus femoris
b. TFL
c. Gluteus medius
d. Sartorius

3. **Osteotomies:**
i. Damaged painful region → out of weight bearing axis → relieves pain.
ii. Gives damaged region time to heal
iii. Indications and prerequisites:
1. Young (<50 years)
2. Stages 2–3 (ARCO)
3. Small Kerboul necrotic angle (<200)
4. <30% FH involvement
5. Minimal acetabular involvement
6. No ongoing RF (steroids, alcohol)
iv.

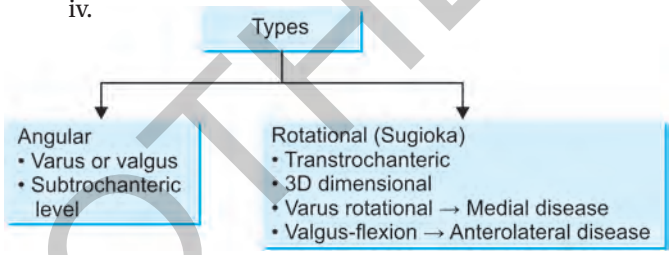

b. **Hip-sacrificing:**
1. **Total hip arthroplasty:**
i. Current gold standard for advanced disease
↓
ii. Most reliable → Pain relief, immediate return of function
iii. Pain relief, immediate return of function
iv. Young patients:
a. Uncemented > Cemented
b. COC > Metal–on poly
↓
c. High rate of linear wear and osteolysis.
v. Indications:
a. Advanced arthritis
b. Age >50
c. Kerboul >240
d. All failed previous surgery
2. Arthrodesis: Stable hip → at cost of ROM. Manual laborer.
3. Hip resurfacing: Advanced DJD → Small focus, C/I in ongoing etiology (steroid use).

FEMOROACETABULAR IMPINGEMENT

I. INTRODUCTION

1. Early abnormal contact between the bony prominences of the acetabulum and femur
↓
2. Mechanically limits the physiological movements of hip
↓
3. Producing pain at terminal hip ROM

JAYPEE BROTHERS

II. CLASSIFICATION

1. Cam
2. Pincer
3. Combined

A. Cam (Fig. 15)

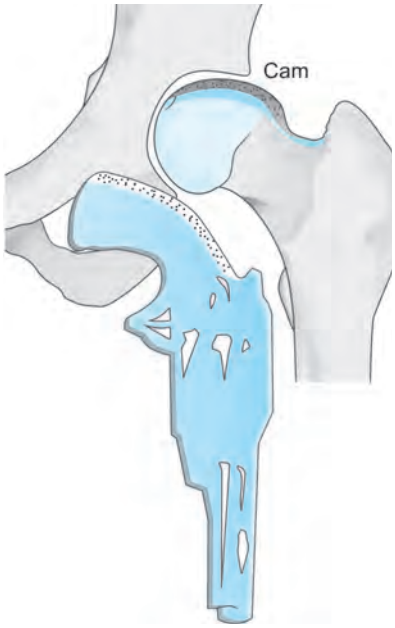

Fig. 15: Cam lesion: Pistol grip deformity.

1. Femoral cause → due to aspherical portion of the femoral head-neck junction.
2. Two morphological features of femoral head in cam.
   i. "Pistol grip" deformity – ↓ Femoral head-neck offset on the superior/anterolateral region.
   ii. "Bump" or exuberant bone in the anterosuperior region of the femoral neck. ↓
   Classic anterior impingement.
3. Sphericity mismatch
   ↓
   Shearing at chondrolabral junction.
   ↓
   Cartilage delamination and labral separation.

B. Pincer (Fig. 16)

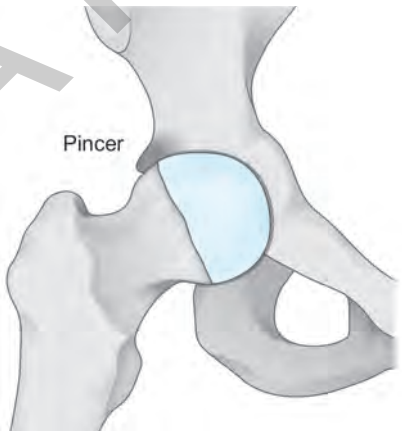

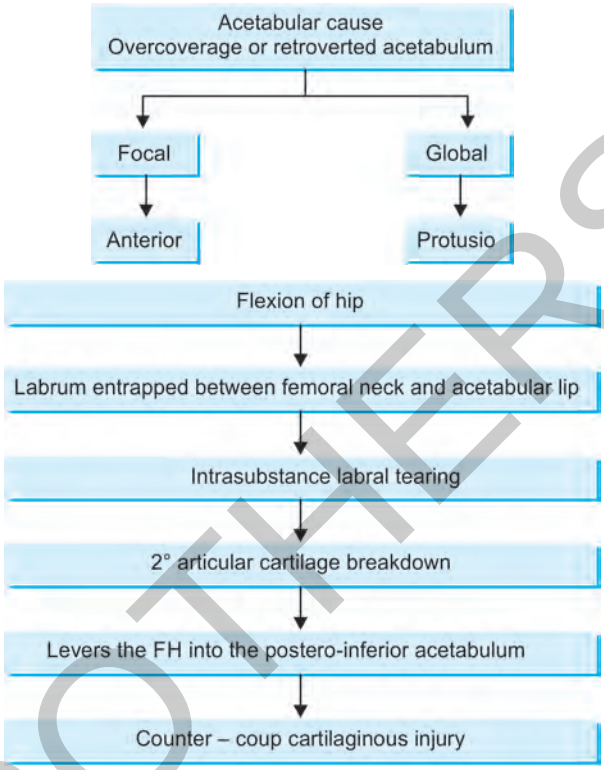

III. CLINICAL FEATURES

1. M: F → Cam → 14:1
   Pincer → 1:3
2. Age → Cam → Early middle age (21–51 years)
   Pincer → Late middle age (40–57 years)
3. Pain → i. Activity related
   ii. Groin (deep) or anterior thigh
   iii. Increases on hip flexion and IR
4. Mechanical symptoms → Clicking/Popping
5. ROM hip flexion
   ↓ Adduction
   IR
6. Pincer → Sudden stop in ROM
   Cam → Gentle stop
7. FADIR test +ve
8. Drehmann's sign +ve → Passive ER of hip while performing hip flexion. (Gearstick sign)

IV. INVESTIGATIONS

A. X-ray

1. True AP (hip in 15° IR)
2. Modified Dunn view
3. False profile view.

B. Cam

1. *Pistol grip deformity:* Asphericity and abnormal contour of femoral head and neck
2. Break in the reverse Shenton's line
3. α angle >50° = Cam **(Fig. 17)**

JAYPEE BROTHERS

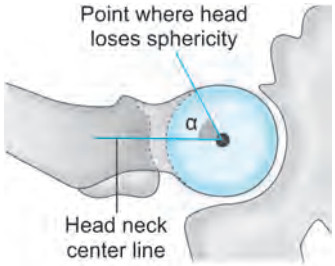

4. Anterior offset:
   i. Anterior offset = Anterior femoral head radius – Anterior femoral neck radius
   ii. Normal >10 mm, Cam: < 8 mm
5. Head-neck offset ratio $= \frac{\text{Anterior offset}}{\text{FH diameter}}$ (Cam: <0.17)

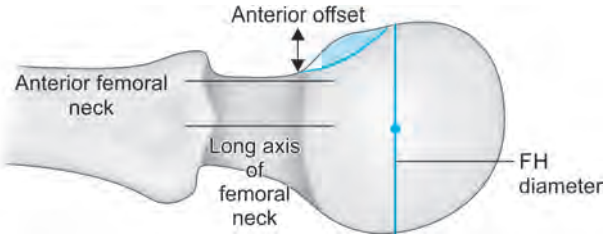

6. Horizontal growth plate
7. Femoral retroversion
8. Cam + Pincer = Kissing lesions

C. Pincer

1. Coxa profunda, protrusio acetabuli
2. Crossover sign/Figure of 8 sign: Acetabular retroversion, anterior overcoverage
3. Posterior wall sign:
   i. Normal → Very close to FH center
   ii. Retroversion → Medial to FH center
4. Lateral center-Edge angle of Wiberg **(Fig. 19)**
   Normal = 25–39°
   ≥40° = Pincer

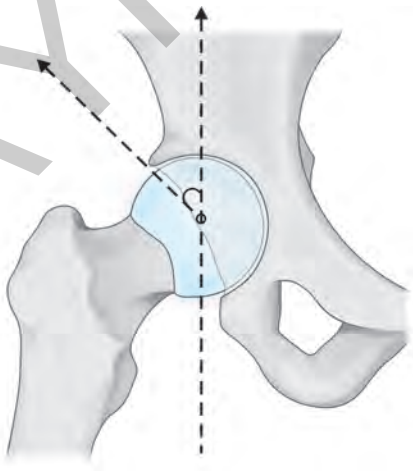

Fig. 19: Lateral center-edge angle of Wiberg > 40° in pincer FAI.

5. Tonnis roof angle → <0° Pincer **(Fig. 20)**

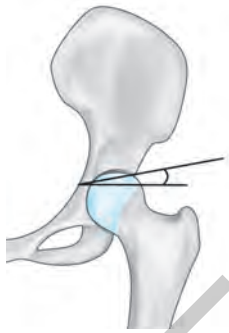

Fig. 20: Angle between a line along the superior acetabulum and the horizontal (normal hip shown in the figure).

6. Extrusion index → Normally 25% head is not covered by the acetabulum.
   In Pincer: <15° is not covered.
7. *Acetabular index:* Normal = 33–38°, <15° = pincer
   (Inter- teardrop line to lateral acetabular roof)
   MRI → Articular cartilage, labral tear.

V. MANAGEMENT

A. Conservative

1. *Modality*:
   i. Activity modification
   ii. PT
   iii. NSAIDs
2. *Indications*:
   i. Minimal symptoms
   ii. No mechanical symptoms
3. Structural abnormality does not improve with conservative management, hence many patients → Surgery.

B. Operative

1. *Benefits*:
   i. Pain relief due to removal of structural abnormality
   ii. Early recognition and management prevents OA
2. *Goals of surgery*:
   i. Precise deformity correction: Intra- and extra-articular
   ii. Treatment of soft tissue abnormality (labrum, articular cartilage, etc.) **(Fig. 21)**

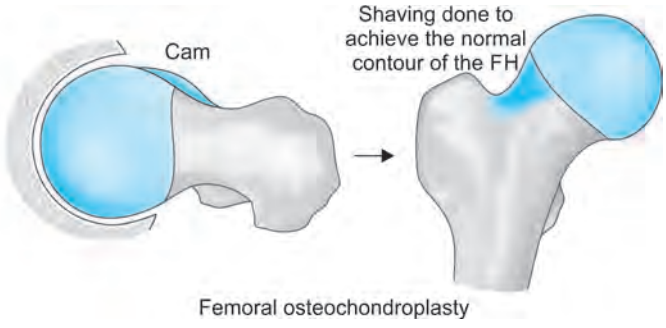

Fig. 21: Shaving off of the cam lesion.

JAYPEE BROTHERS

3.

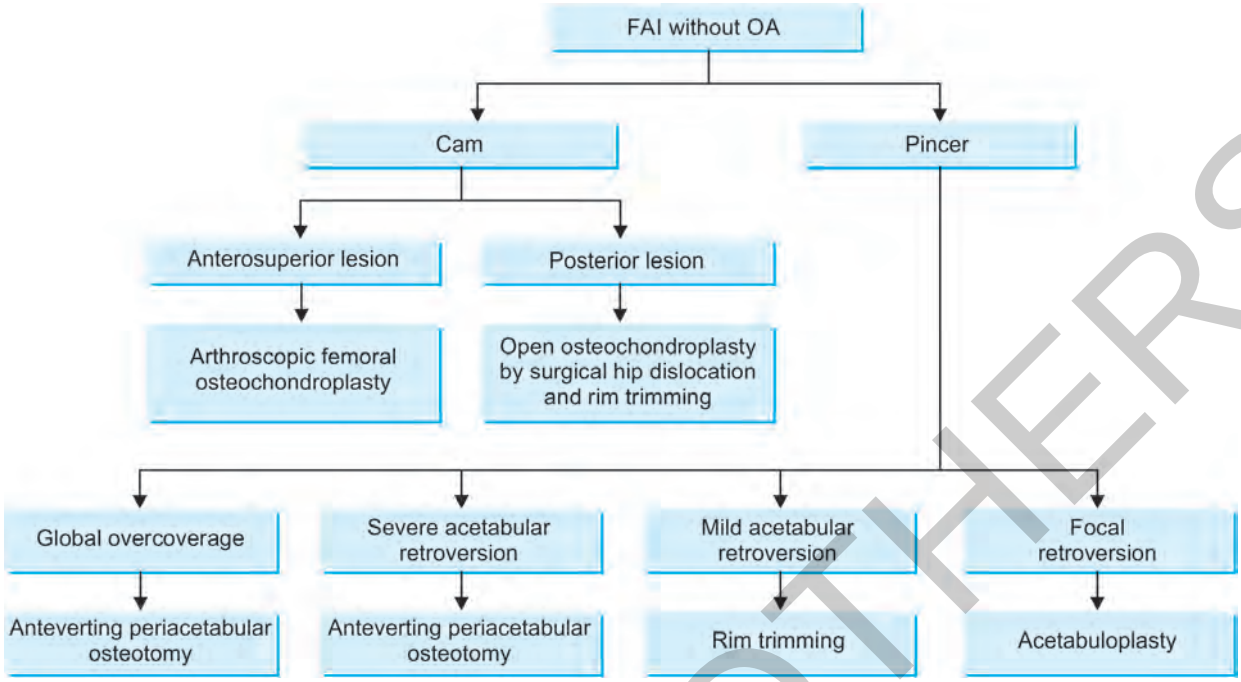

4. Osteochondroplasty **(Figs. 21 and 22)**:

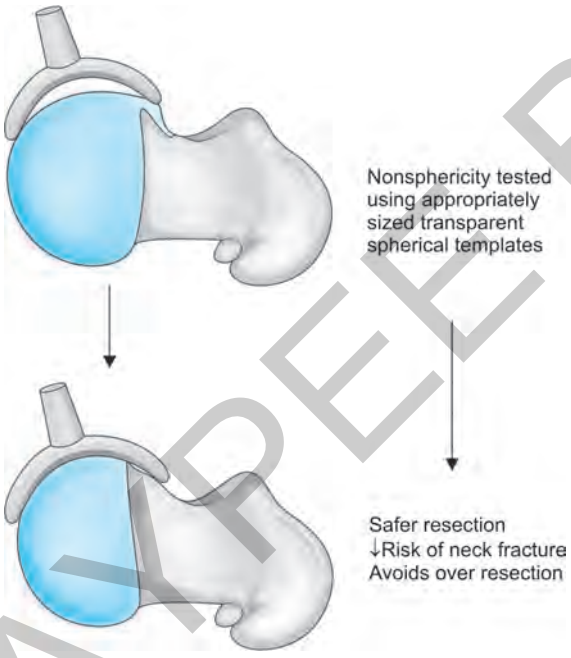

   i. Nonsphericity tested using appropriately sized transparent spherical templates
      ↓
      a. Safer resection
      b. ↓ Risk of neck fracture
      c. Avoids over resection
   ii. Presence of cyst near the peripheral border of the nonspherical segment is sometimes noted, which indicates point of maximum impingement.
   iii. Perfusion confirmed by bleeding from raw cancellous bony surface following neck debridement.
   iv. Bone wax applied to debrided surface prior to relocation
   v. Postoperative → NWB Gait training → 6 weeks
      a. Avoid flexion >70° and abduction to allow healing of osteotomy site.
      b. Radiological healing >6 weeks → Weight bearing.

5. FAI with OA → Arthroplasty.

VI. COMPLICATIONS

1. Femoral neck fracture
2. Heterotopic ossification
3. Residual deformity following arthroscopic treatment.

HIP ARTHROSCOPY

I. INTRODUCTION

1. Hip arthroscopy is a minimally invasive surgical procedure that uses an arthroscope to diagnose and treat hip disorders.
2. It provides excellent visualization of the articular surface of the joint, peritrochanteric and extra-articular region around the hip.
3. It is technically demanding because of the sphericity of the femoral head and the dense capsule and musculature that surround the joint.
4. In arthroscopic anatomy, hip is divided into central, peripheral and peritrochanteric regions.
5. Image intensifier is required.

JAYPEE BROTHERS

II. INDICATIONS

Intra-articular	*Periarticular*
1. Femoroacetabular impingement (FAI; cam and pincer type) 2. Labral pathology 3. Chondral lesions 4. Ligamentum teres injuries 5. Loose bodies 6. Synovial chondromatosis 7. Septic arthritis 8. Synovial-based diseases 9. Adhesive capsulitis 10. Capsular laxity and instability 11. Isolated femoral head fractures	1. Greater trochanteric pain syndrome 2. Snapping hip syndromes 3. Proximal hamstring repair 4. Sciatic nerve entrapment 5. FAI [ischiofemoral and anterior inferior iliac spine (AIIS) subspine type] 6. Gluteal tears 7. Iliopsoas tendon pathologies 8. Piriformis release

III. CONTRAINDICATIONS

Absolute	*Relative*
1. Advanced osteoarthritis 2. Severe proximal femoral deformity (Legg–Calvé–Perthes disease, slipped capital femoral epiphysis) 3. Ankylosis 4. Dysplasia with femoral head migration 5. Severe acetabular retroversion 6. Joint contracture 7. Protrusio acetabuli	1. Moderate osteoarthritis 2. Mild dysplasia 3. Obesity

IV. COMPARTMENTS

1. Central compartment → Requires traction for access.
   Consists of,
   i. Acetabular fossa and femoral head articular surfaces
   ii. Acetabular rim and labrum
   iii. Ligamentum teres
   iv. AIIS and capsule
2. Peripheral compartment
   i. After completion of the central compartment procedure, the leg is removed from traction and the hip is flexed to 45°.
   ↓
   ii. Relaxation of the capsule
   ↓
   iii. Better access to the peripheral compartment.
   iv. Consists of,
      a. Femur head-neck junction
      b. Iliopsoas tendon
      c. Medial synovial fold
3. Peritrochanteric and extra-articular compartment → No traction needed
   i. Iliotibial band and bursa
   ii. Hip abductor tendons
   iii. Piriformis muscle
   iv. Sciatic nerve
   v. Hamstring origin at ischial tuberosity

V. SETUP

1. Instrumentation
   i. 70° arthroscope
   ii. Long cannula and guides
   iii. Flexible instruments
2. Fluoroscopy is needed for hip arthroscopy.
3. Positioning
   i. Supine →
      a. Utilizes fracture table
      b. Patient position becomes easy
      c. Surgeon familiarity
   ii. Lateral →
      a. Easier in obese patients
      b. Requires distractor devices
4. 10–12 mm distraction needed to cannula placement.
5. Traction time must be < 2 hours to ↓ neuropraxia chances.

VI. PORTALS

Portal	*Function*	*Site*	*Risk*
Anterolateral	1. Primary viewing portal 2. Instrumentation → anterolateral	1. 1 cm superior and anterior to the anterior border of GT 2. Made first under fluoroscopy	Superior gluteal nerve
Anterior	Central compartment access and instrumentation	1. Intersection of a line drawn from tip of GT and line drawn inferiorly from ASIS 2. Second portal to be made	1. Lateral femoral cutaneous nerve 2. Ascending branches of lateral femoral circumflex artery 3. Femoral neurovascular bundle
Distal anterolateral	Access to peripheral compartment near femoral neck	1. Starting point 3–4 cm distal to the anterolateral portal 2. Traction is removed and the hip is placed in either neutral flexion and extension or in 45° of flexion to relax the anterior capsule	Ascending branch of lateral femoral circumflex artery

JAYPEE BROTHERS

detailed information on orthopedics books, visit our website www.jaypeebrothers.com, for detailed information on orthopedics books, visit our website www.jay

ORTHOPEDIC EXAM REVIEW

A Comprehensive Manual for Postgraduates

Salient Features

- Designed for MS, DNB, and Diploma students, though undergraduates and practicing orthopedic surgeons can also benefit from the concise nature of the manual.
- Comprises over 300 frequently asked questions in postgraduate examinations and covers more than 90% of the syllabus.
- Features numerous flowcharts, tables, and diagrams (all hand-drawn) and thus easily reproducible in the examinations.
- Content is tailored to meet the examiner's expectations in answer sheets.
- Answer length is appropriate to the significance and type of topic.
- Saves significant time spent on note preparation.



Ashraf Shaikh MBBS MS DNB MNAMS MRCS(England) is a distinguished Assistant Professor at the Department of Orthopedics, Seth GS Medical College and King Edward Memorial (KEM) Hospital, Mumbai, Maharashtra, India, which is home to the largest orthopedic department in the country. He completed his residency from the same esteemed institute in 2021 and received the prestigious Pandurangi Award for the Best Outgoing Orthopedic Resident. He also won the Torrent Young Scholar Award, a nationwide exam with more than 365 participating orthopedic residents. In 2022, he completed his Diplomate of National Board Examination (DNB) and became a member of the National Academy of Medical Sciences. He is also a member of the Royal College of Surgeons of England. Dr Shaikh is a certified Advanced Trauma Life Support (ATLS) Instructor by the American College of Surgeons (ACS). In 2023, he was honored with the "BOS Rising Star" award by the Bombay Orthopaedic Society. He has published and presented many papers at national and international conferences. Besides his love for orthopedics, Dr Shaikh is passionate about world cuisines and food blogging, football, and equity investments.

Printed in India

Available at all medical bookstores or buy online at www.jaypeebrothers.com

JAYPEE

JAYPEE BROTHERS
Medical Publishers (P) Ltd.
EMCA House, 23/23-B, Ansari Road,
Daryaganj, New Delhi - 110 002, INDIA
www.jaypeebrothers.com

Join us on facebook.com/JaypeeMedicalPublishers

Shelving Recommendation
ORTHOPEDICS

ISBN 978-93-5696-854-7

9 789356 968547