rothers.com, for detailed information on dermatology books, visit our website www.jaypeebrothers.com, for detailed information on dermatology books

diginerve®
A Jaypee Initiative
• Video Lectures • Dr. Wise AI Chatbot
• Question Bank • Notes
Download App

Bestselling Book by Subject Specialists

Includes New INI-CET Pattern Questions

Review of DERMATOLOGY

840 Full color photographs
220 hand-drawn illustrations

Based on Latest Standard Textbooks Fitzpatrick 8/e, Rook's 9/e, Bolognia 3/e, Habif 5/e, Andrews 11/e, McKee 4/e, King Holmes 4/e, Lever 10/e, IAL 2/e

HIGHLIGHTS

- The first, most detailed, complete color dermatology book dedicated to PGMEE
- Images in full color integrated along with the chapter text
- Covers all MCQs till November 2024, covering all exams
- High-yield charts, Aid to remember, Mnemonics, Simplified hand-drawn conceptual diagrams in every chapter
- Quick revision segment at the end of the chapter for last minute revision

Saurabh Jindal







7th Edition

Explained Referenced Answers
All Recent Questions (2024–1997)
INI-CET (2024–2020)
NEET Pattern (2024–2020)

JAYPEE

Contents

Recent Questions and Answers with Explanation ..... *xv*

1. Anatomy and Physiology of Skin*** 1
2. Skin Lesions, Morphology, Histopathology and Investigations*** 16
3. Hansen's Disease***** 40
4. Tuberculosis and Other Bacterial Infections**** 72
5. Fungal Infections***** 89
6. Viral Infections***** 116
7. Protozoal, Arthropods and Parasitic Infections*** 142
8. Sexually Transmitted Diseases*** 156
9. Blistering (Vesiculobullous) Diseases***** 187
10. Papulosquamous Disorders***** 218
11. Disorders of Adnexae/Appendages***** 248
12. Dermatitis**** 265
13. Disorders of Pigmentation**** 285
14. Connective Tissue Disorders, Drug Eruptions*** 308
15. Disorders of Hair and Nail*** 330
16. Skin Tumors, Vascular Lesions, Skin and Endocrinal Disorders*** 349
17. Important Short Topics*** 359

Index *377*

*****	Most Important
****	Very Important
***	Important

CHAPTER 2

Diagnostic Work-up Before Intrauterine Insemination

INTRODUCTION

Work-up of both the partners is required but should be restricted to the tests that contribute to the prediction of effectiveness of intrauterine insemination (IUI).

HISTORY TAKING

Try to get detailed history about any medicines that patient is taking or surgery done for both the partners. History of chewing tobacco, smoking, alcohol, or hard drugs is important, as it may contribute to infertility. Lifestyle details must also be asked for. It often happens that work timings or burden of one/both the partners may be the cause of infertility.

This history is very important, including the history of previous infertility treatment taken, also including IUIs done. This will decide how many IUIs can be further done. If no gonadotropin IUI cycles are done or the cycles are not monitored by color Doppler for assessment of follicular quality and endometrial receptivity, I will not consider these IUIs adequate.

LOCAL AND GENERAL EXAMINATION

For female partner, routine per abdominal, per vaginal, and per speculum examination of the patient is required to find out any evident abnormalities in abdomen that may be associated with or may be causative of infertility. Though prevaginal examination can be avoided, if the transvaginal ultrasound is done by the gynecologist himself. Local examination of the male partner consists of per abdominal examination and examination of the scrotum, if required, in standing position and with Valsalva to assess for varicocele.

General examination of both the partners includes assessment of vital parameters such as heart rate, blood pressure, respiratory rate, etc. Patient's height and weight are also noted along with calculated body mass index (BMI).

A BMI between 25–29.9 kg/m^2 or >30 kg/m^2 does not appear to have a negative effect on live birth rate after IUI. Obesity may be associated with higher risk of biochemical pregnancy after IUI.[1]

DETAILED ULTRASOUND SCAN

It is done to assess uterus, ovaries, and tubes for any pathologies and their impact on fertility potential of the patient. This scan ideally should be done between day 6 and 7 till day 18 of a normal length cycle. The endometrium is multi-layered during this period and, therefore, Müllerian duct abnormalities and endometrial pathologies can be diagnosed more confidently **(Figs. 1A and B)**. One may also look for fibroids **(Fig. 2A)**, adenomyosis, or other uterine pathologies and also for ovarian and adnexal lesions such as endometriomas or hydrosalpinges **(Figs. 2B and C)**. But this may be considered a pilot scan and may be done when patient presents for the first time.

JAYPEE BROTHERS

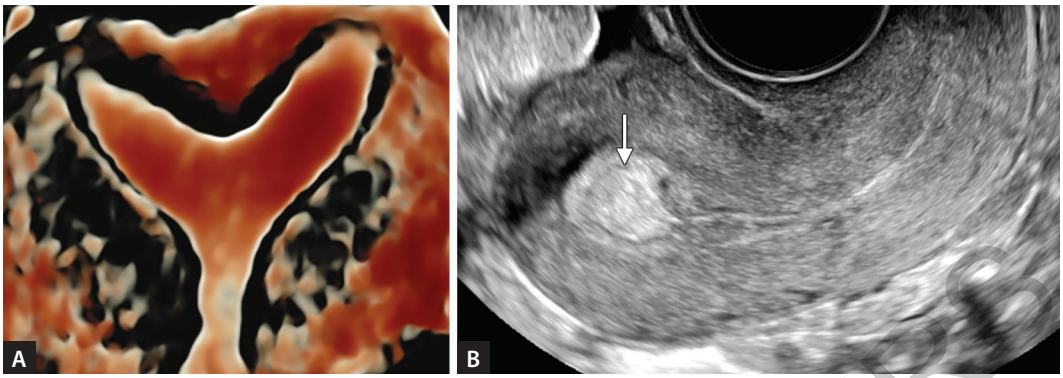

Figs. 1A and B: (A) 3D ultrasound showing subseptate uterus; (B) B-mode ultrasound showing endometrial polyp (arrow).

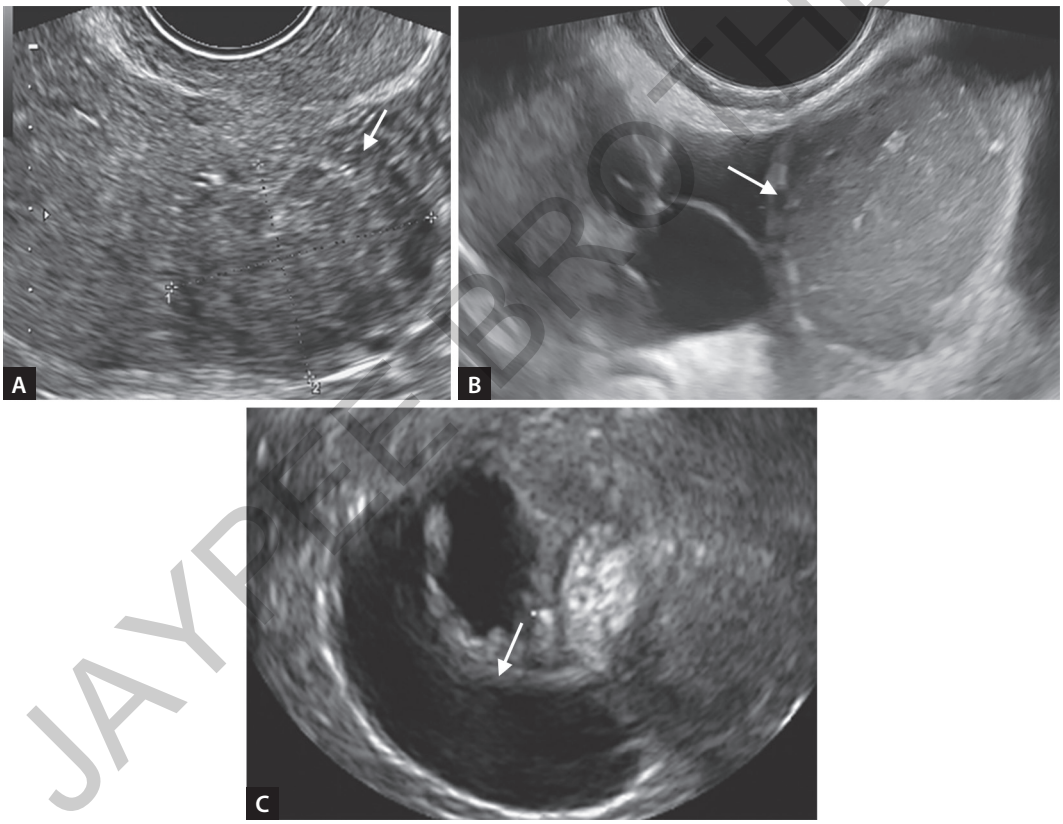

Figs. 2A to C: (A) B-mode ultrasound showing fibroid in uterus (arrow); (B) B-mode ultrasound showing endometrioma (arrow); (C) B-mode ultrasound of hydrosalpinx (arrow).

JAYPEE BROTHERS

BASELINE ULTRASOUND SCAN AND PREOVULATORY SCAN

This has been discussed in detail in the chapter on ultrasound monitoring. Baseline scan is essential to know the ovarian reserve and response. This will help to decide the stimulation protocol and the dose of gonadotropin required. It also will help to diagnose polycystic ovaries (PCO) **(Fig. 3)** and modify the treatment accordingly.

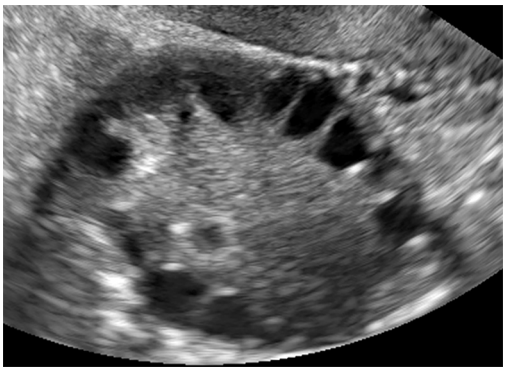

Fig. 3: B-mode ultrasound of polycystic ovary.

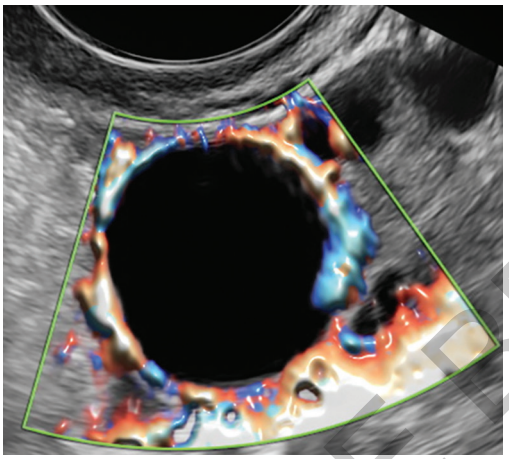

Fig. 4: Color Doppler of mature follicle.

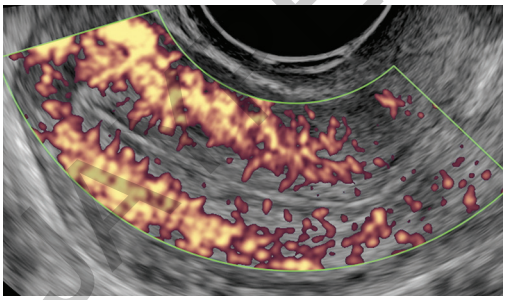

Fig. 5: Power Doppler of receptive endometrium.

Preovulatory scan is done with color Doppler to assess the follicular quality and maturity and endometrial receptivity **(Figs. 4 and 5)**. This is an important guide to decide the stimulation protocol and to add adjuvants to ovulation induction.

ROUTINE LABORATORY INVESTIGATIONS

These include complete blood count, prothrombin time (PT), surface antigen of the hepatitis B (HbsAg), HIV, SGPT, and serum creatinine. Urine routine and microscopy test is to be done. Hormonal investigations required would be serum thyroid-stimulating hormone (TSH) and serum prolactin. Though most practitioners get an infertility package done, it is very important to understand that estrogen, progesterone, follicle-stimulating hormone (FSH), luteinizing hormone (LH), and androgen, all done on the same day, do not have a clinical relevance. These tests may be suggested very selectively, as most practical information about these hormones can be judged by ultrasound and Doppler, which is otherwise also done for monitoring. Insulin resistance test is to be done to confirm or exclude polycystic ovarian syndrome (PCOS) and also to decide the line of treatment.

Insulin resistance is calculated as fasting glucose/insulin, if <4.5, it indicates insulin resistance or 2-hour glucose tolerance and 2-hour insulin response test can be done **(Tables 1 and 2)**.

Any other specific laboratory investigation that may be suggested and dependent on the history may be done.

TABLE 1: Values of glucose on 2-hour glucose tolerance test.

2-hour glucose tolerance test (after 75 g of glucose):
• *Normal:* <140 mg/dL
• *Impaired:* 140–190 mg/dL
• *Noninsulin-dependent diabetes mellitus:* >200 mg/dL

TABLE 2: Insulin levels on 2-hour insulin response test.

2-hour insulin response (after 75 g of glucose):
• *Insulin resistance very likely:* 100–150 µU/mL
• *Insulin resistance:* 151–300 µU/mL
• *Severe insulin resistance:* >300 µU/mL

JAYPEE BROTHERS

TABLE 3: Normal semen analysis parameters according to World Health Organization (WHO), 2010 guidelines.[2]

Seminal parameters	*Lower reference value*
Volume	1.5 mL
pH	7.2
Concentration	15 million/mL
Total number of sperms	39 million/ejaculate
Motility	40% total 32% progressive
Vitality	58% sperms alive/ ejaculate
Morphology	4% normal shape

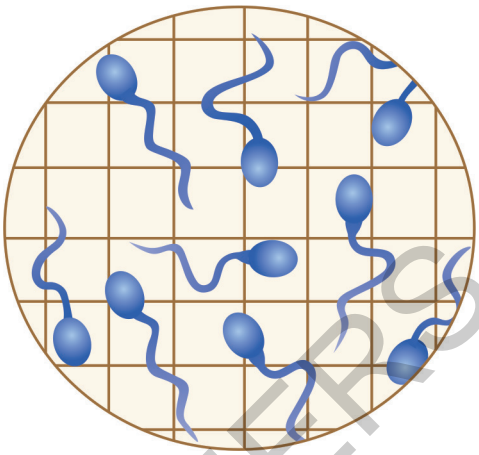

Fig. 6: Diagrammatic presentation of normal postcoital test (PCT) as seen under the microscope.

SEMEN ANALYSIS

It should be done in detail, as this will help to decide which semen wash method should be used for a particular patient and what modifications will be required **(Table 3)**.

These are the normal parameters for a semen sample, but these are not predictors of pregnancy after IUI.[3,4] Total motile sperm count (TMSC) gives a better idea about the same. TMSC is calculated as (volume of the semen sample × concentration of sperms 10^6/mL) × progressive motility.

According to the Dutch gynecological and general practitioner guidelines:[3]

- Mild male subfertility, if TMSC is >3 × 10^6, can conceive with IUI.
- Moderate male subfertility, if TMSC is 1–3 × 10^6, requires IVF.
- Severe male subfertility, if TMSC is <1 × 10^6, requires ICSI
- Post-wash sperm count of 0.8 × 10^6 – 5 × 10^6 TMSC is accepted.[4]

Antisperm antibodies (ASAs) can be tested, if sperm agglutination is found, but its role is doubtful.

POSTCOITAL TEST

In cervical factor, infertility or abnormal postcoital test (PCT) showed no benefit of IUI over 6 months of no treatment.[5] But, it has great psychological impact on the couple when the test is positive, and patient can see the motile sperms on under the microscope **(Fig. 6)**. We routinely do PCT after 10–12 hours of intercourse in preovulatory period. According to WHO criteria, excellent PCT correlates with high pregnancy rate.

Postcoital test parameters according to WHO, 1976:

- *Normal:* (A)—Seven sperms without agglutination
- *Inconclusive:* (B)—One to seven sperms, no agglutination, and good progressive movement
- *Suspected immunological:* (C)—Agglutination regardless of number of sperms per HPF
- *Abnormal:* (D)—Nonmoving sperms only
- *Abnormal:* (E)—No sperms

TUBAL FACTOR

Rubin's test should never be done for assessment of tubal patency, as it is not reliable. For tubal factor, hysterolaparoscopy is a must, which can assess tubo-ovarian relations. It has already been discussed in the chapter on "Indications for IUI", how ovulation occurs. So, only laparoscopy can

JAYPEE BROTHERS

establish tubo-ovarian relation status. I have not done any hysterosalpingography (HSG) since last 20 years for tubal assessment, as it gives incomplete information with low accuracy, and it is a very painful procedure. Blocked tubes in HSG may turn out to be normal and it may further cause infection. If preovulatory scan is done and uterus and ovaries are freely mobile and there is no pathology in the tube, then 3–4 IUIs should be done before laparoscopy. No tubal patency test is done before 30 years of age unless indicated or suspected due to relevant history that may suggest possibility of tubal damage. Tubal pathology, if leads to hydrosalpinx, will be seen on ultrasound or tubal block may be indicated by adhesions. In these cases, laparoscopy is a must. In present era of advanced ultrasound technology, endoscopy should be only therapeutic-operative and not diagnostic. If there is a doubt in fimbrial end status, 3D hysterosalpingocontrast sonography (HyCoSy) can well demonstrate the pathology **(Fig. 7)**.

Saline Infusion Salpingography Technique

Saline infusion salpingography (SSG) is done in mid-proliferative phase (Days 6–10 of a typical 28-day cycle), after menstruation stops but before ovulation occurs, to reduce the risk of disturbing an early pregnancy. Oral analgesic, ibuprofen 400–600 mg may be given 1–2 hours before the procedure. Preprocedural screenings for infections like chlamydia and/or prophylactic oral antibiotics are recommended. Strict asepsis is essential. A detailed transvaginal ultrasound scan is done to assess the position of pelvic organs and to rule out any pathologies, which would come in the way of the procedure. Moreover, any free fluid in pelvis is also checked for.

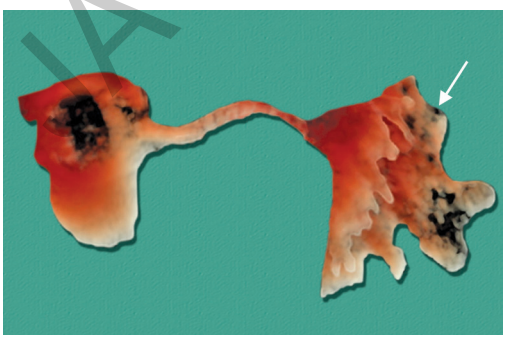

Fig. 7: 3D hysterosalpingocontrast sonography (HyCoSy) image showing a patent unilateral tube with fimbrial end (arrow).

After finishing the primary pre-procedure scan, speculum is placed in the vagina to visualize the cervix. Vagina and cervix are cleaned with antiseptic solution. Cervix is fixed with tenaculum to align it with uterus. An 8F balloon catheter or a cannula, especially devised for saline infusion sonography or hysterosalpingography, is attached to a 10-mL syringe prefilled with saline. The catheter is introduced through cervix into the uterus. Balloon is distended with 1–2 mL of distilled water or normal saline and is placed just beyond the internal os. Alternatives to this, catheter are pediatric feeding tubes or small gage Foley catheter. Once the catheter is fixed, tenaculum and speculum are removed and transvaginal probe is introduced into the vagina for further assessment.

Saline is injected through the catheter slowly. Scanning is done to assess the uterine cavity that is distended by saline and also passage of saline (fluid) seen through the tubes. Spill of saline from fimbrial end is seen as fluid flow surrounding the ovary and its collection in pelvis on B-mode scanning. Absence of spill may indicate blockage. It is not always possible to document the spill from the fimbrial end of individual tube. In such cases, fluid accumulation in pouch of Douglas confirms patency of at least one fallopian tube. In patients with bilateral block, distension of the uterine cavity causes severe pain and no spill is observed.

Adding color Doppler may increase the efficiency and accuracy of SIS for assessment of tubal patency. Large color box is used to

JAYPEE BROTHERS

cover the entire ovary but not to overlap the myometrium, show saline injection will lead to color blush in the color box, indicating a patent tube and no blush confirms block tube. During injection of saline, patient's movement must be strictly restricted to avoid color artefacts.

HyCoSy (Hysterocontrast Salpingography) Technique

The technique for HyCoSy is the same as for saline infusion salpingography. As delineation of the tube is better with HyCoSy, total amount of contrast needed is as less as 2–3 mL per tube. For diagnosis of tubal patency, two to three observation phases per tube are needed, with an observation period of continuous flow of about 10 s. Visualization of long segments of tube beyond intramural part of the tube usually indicates patency, though whole tube must be observed, and spill should be confirmed. Appearance or increase in the fluid in pouch of Douglas may be an indirect sign of tubal patency, the same as for SIS. HyCoSy has several advantages over saline infusion salpingography, like it helps clearer visualization of uterine cavity, better assessment of tubal lumen and fimbriae, clearer visualization of spill, and a more exact localization of site of block. Having defined the contrast filling in the tubes, 3D is switched on and volumes are acquired for each side independently.

Rendering is done in front–back viewing direction. Surface-enhanced mode is used. Threshold is set to make the contrast path more obvious. MagiCut (electronic scalpel) is then used to cut all shadows other than the contrast path. Then HD-live rendering mode is switched on and direction of the light is adjusted to visualize the fimbriae and spill to its best.

Chlamydial antibody test (CAT) is useful to find outpatients with high risk of tubal pathology. Direct questions may be asked to inquire for tubal pathology, in cases where there is a possibility that patient may have missed the specific history or has hidden it for a purpose.

ROUTINE OVARIAN RESERVE TESTS

These are not required before IUI. Baseline ultrasound with antral follicle count (AFC) gives all the information. In IUI, more ova are not required as in IVF. One or two good follicles, if can be produced by ovulation induction, good results can be achieved, and this is possible even in low ovarian reserve. We always depend on AFC rather than anti-Müllerian hormone (AMH). In majority of patients with AMH between 0.3 and 1, 2–3 follicles will almost always develop every cycle and results of IUI are always good. So even though it is a drastic statement, IUI has a definite role in low AMH with advancing age.

Vagios et al.[6] analyzed outcome of 1861 gonadotropin ovulation induction with IUI cycles in 821 patients. Women with low AMH (<0.75 ng/mL) had lower cumulative pregnancy rates over 3 cycles. Women with AMH <0.4 ng/mL, had twice the risk of abortions. But surprisingly women with low AMH had a significantly higher risk of multiple pregnancies. Doses of gonadotropins and method of AMH estimation, having changed now, women with low AMH are more likely to continue with gonadotropin stimulated IUI cycles, while high AMH patients have more anovulatory cycles and so after a trial of few IUI cycles, these patients may require to go for IVF. The practice committee report recommends oral ovarian stimulation in diminished ovarian reserve.[7]

LUTEAL PHASE SCAN

It is essential to assess corpus luteal function and exclude possibility of luteal phase abnormalities, which may be the cause of infertility.

JAYPEE BROTHERS

AGE

Age is the single factor that decreases AFC. Ours being a tertiary center for infertility, majority of the patients come after 8–10 years of infertility and are above 35 years of age. In spite of that, excellent pregnancy rate can be maintained by gonadotropin stimulation and ovulation monitoring with color Doppler even when IUI is done.

OUR DATA

We have 189 IUI pregnancies, in cases with previous 3 or more IVF failures. Majority of these patients were advised ovum donation elsewhere. So, my strong carry home message is "*do not underestimate the strength of IUI*".

According to what is documented in one of the studies, when age of the male partner is >35 years, it may be a factor causative of poor IUI outcome.[8]

I absolutely do not agree with this, as the only factor in male that affects the success of IUI according to my experience is the sperm count. As mentioned earlier, majority of our patients and therefore their male partners are also >35 years of age. This is further discussed in the chapter of factors affecting the success of IUI.

CARRY HOME MESSAGE

- Detailed history including the details of previous IUIs and how were these done.
- Baseline scan is essential to rule out pathologies and decide stimulation protocol.
- Insulin resistance test and stromal volume with 3D ultrasound are important tests for treatment.
- Total motile sperm concentration can give better idea for prognosis.
- Excellent PCT gives positive psychological impact.
- Tubo-ovarian relations can be assessed by laparoscopy only.
- Routine ovarian reserve tests are not required.

REFERENCES

1. Whynott RM, Summers KM, Van Voorhis BJ, Mejia RB. Effect of body mass index on intrauterine insemination cycle success. Fertil Steril. 2021;115(1):221-8).
2. World Health organization. Laboratory Manual for the Examination of Human Semen and Semen-cervical Mucus Interaction, 5th edition. New York: Cambridge University Press; 2010. p. 287.
3. Van Weert JM, Verhoeve H, Mil BW. Diagnostic work up before IUI. In: Cohlen B, Ombelet W (Eds). Intrauterine Insemination: Evidence-based Guidelines for Daily Practice. Boca Raton, London, New York: CRC Press, Taylor and Francis Group; 2014.
4. Van Weert JM, Repping S, Van Voorhis B, Bossuyt P, Van der Veen F, Mil BW. The performance of the postwash total motile sperm count at the time of intrauterine insemination from the prediction of pregnancy: a meta-analysis. Fertil Steril. 2004;82(3):612-20.
5. Steures P, Van der Steeg JW, Hompes PG, Bossuyt PM, Habbema JD, Eijkemans MJ, et al. Effectiveness of intrauterine insemination in subfertile couples with an isolated cervical factor: a randomized clinical trial. Fertil Steril. 2007;88(6):1692-6.
6. Vagios S, Hsu JY, Sacha CR, Dimitriadis I, Christou G, James KF, et al. Pretreatment anti-müllerian hormone levels and outcomes of ovarian stimulation with gonadotropins/intrauterine insemination cycles. Fertil Steril. 2021;116:422-30.
7. Practice Committee of American Society for Reproductive Medicine. Evidence-based treatments for couples with unexplained infertility: a guideline. Fertil Steril. 2020;113:305-22.
8. Henkel R, Maass AG, Schuppe HC, Jung A, Schubert J. Molecular aspects of aging sperm. Fertil Steril. 2005;84(5):1430-7.

JAYPEE BROTHERS

for detailed information on dermatology books, visit our website www.jaypeebrothers.com, for detailed information on dermatology books, visit our websi

Review of DERMATOLOGY

Salient Features

- Detailed topic discussion essential for the latest pattern of PGMEE, focusing on concepts
- Charts and special features of 'How to diagnose in an MCQ' to help in the real-world scenario of deciding the answer in the examination
- Integrated approach with 840 color images interspersed within the text
- 220 hand-drawn illustrations for ease of understanding
- MCQs till November 2024 covered with authentic references from standard dermatology textbooks
- Covers all exams
- Online index

Saurabh Jindal MD DNB DDV (Mumbai) is a leading name in dermatology coaching for PGMEE having over 17 years of experience, having taken over 2000 face-to-face lectures all over the country in the past decade. He did his graduation and postgraduation from the prestigious Grant Medical College and JJ Group of Hospitals, Mumbai, Maharashtra, India. He remained in the academic sphere after his PG, having served as an Assistant Professor and then as an Associate Professor. Numerous PG students trained under him during this time. He has been a teacher in dermatology coaching for PGMEE since 2006 and still takes over 100 lectures every year criss-crossing the country and interacting with students everywhere. This book is an amalgamation of his vast experience in PGMEE coaching over more than a decade and his humble attempt at helping students master a subject that UG students at MBBS level are not exposed to. He can be contacted at **drsaurabhdermatology@gmail.com**.

Printed in India

Available at all medical bookstores or buy online at www.ejaypee.com

JAYPEE BROTHERS
Medical Publishers (P) Ltd.
EMCA House, 23/23-B, Ansari Road, Daryaganj, New Delhi - 110 002, INDIA
www.jaypeebrothers.com

Join us on facebook.com/JaypeeMedicalPublishers
Follow us on instagram.com/JaypeeMedicalPublishers

Shelving Recommendation
DERMATOLOGY

ISBN 978-93-5696-920-9