ypeebrothers.com, for detailed information on medicine books, visit our website www.jaypeebrothers.com, for detailed information on medicine books



An Aid to RESPIRATORY MEDICINE

for Postgraduate Exit Exam

MD, DNB and Diploma

Editor
Susmita Kundu

JAYPEE

Contents

CHAPTER 1: **Chest X-ray** **1**
Susmita Kundu

CHAPTER 2: **Computed Tomography Scan of Thorax** **28**
Susmita Kundu

CHAPTER 3: **USG Thorax** **44**
Susmita Kundu

CHAPTER 4: **Arterial Blood Gas Analysis** **63**
Susmita Kundu, Arya Chaudhuri

CHAPTER 5: **Lung Function Test** **84**
Susmita Kundu, Arya Chaudhuri

CHAPTER 6: **Polysomnography** **116**
Saikat Banerjee

Suggested Readings **129**

Index **131**

CHAPTER

2

Computed Tomography Scan of Thorax

Susmita Kundu

BASIC PRINCIPLES OF COMPUTED TOMOGRAPHY SCAN

- Computed tomography (CT) is based on the fundamental principle that the density of the tissue passed by the X-ray beam can be measured from the calculation of the attenuation coefficient. Using this principle, CT allows the reconstruction of the density of the body, by two-dimensional section perpendicular to the axis of the acquisition system.
- Hounsfield chose a scale that affects the four basic densities, with the following values:
  1. Air = –1,000
  2. Fat = –60 to –120
  3. Water = 0
  4. Compact bone = +1,000

INDICATIONS OF COMPUTED TOMOGRAPHY THORAX

- To confirm the abnormalities found on conventional chest X-ray (CXR).
- To evaluate the clinical signs or symptoms of diseases of the chest, such as cough, shortness of breath, and hemoptysis.
- To evaluate diffuse parenchymal lung disease (DPLD).
- To assess improvement or deterioration of pulmonary diseases following treatment.
- To detect and evaluate lung tumors.
- To assess whether the tumors are responding to treatment or not.
- To evaluate injury to chest.

HIGH-RESOLUTION COMPUTED TOMOGRAPHY TECHNIQUE

- *Slice thickness:* ≤2 mm for nonhelical CT ≤1.5 mm for helical CT.
- High spatial frequency reconstruction algorithm.
- Scan time as short as possible (0.3–0.5 seconds).
- Axial or helical mode of data acquisition.
- Kilovoltage peak (kVp) and milli-Ampere (mA) both per slice as well as optimized for volumetric data acquisition.
- Patient positioning (supine and/or prone).
- State of respiration (inspiration and/or expiration).

JAYPEE BROTHERS

SALIENT ANATOMY (FIG. 1)

- Secondary pulmonary lobule is a polyhedral structure (around 2 cm diameter) with bronchovascular structures in the center and perilobular veins (peripheral interstitium) in the periphery.
- Lymphatics are seen in the center as well as periphery of the lobule.
- Each secondary pulmonary lobule is supplied by a terminal bronchiole and a centrilobular pulmonary artery.
- Terminal bronchiole is thin, does not have any cilia but has muscular wall which makes them a favored location for bronchospasm leading to air trapping.
- Terminal bronchioles give rise to multiple respiratory bronchioles which lead to alveolar ducts.
- Bronchovascular bundle consists of bronchi/bronchioles, arteries, and associated connective tissue.

PATTERNS AND TERMINOLOGIES

Reticular Pattern

- This is one of the commonly seen abnormalities in interstitial lung disease (ILD).
- It manifests as linear opacities on high-resolution computed tomography (HRCT) as a result of thickening of the peripheral interstitium especially interlobular septum.
- Reticular pattern can be smooth, nodular, and irregular.
- Nodular reticular opacities are seen in sarcoidosis, pneumoconiosis, lymphangitis carcinomatosis, and hypersensitivity pneumonitis (HP).
- Irregular reticular pattern as a result of extensive interstitial fibrosis leading to irregular thickening of septae and pulmonary lobule. This pattern is seen in fibrosing ILD such as fibrotic nonspecific interstitial pneumonia (NSIP), usual interstitial pneumonia (UIP), and sarcoidosis.

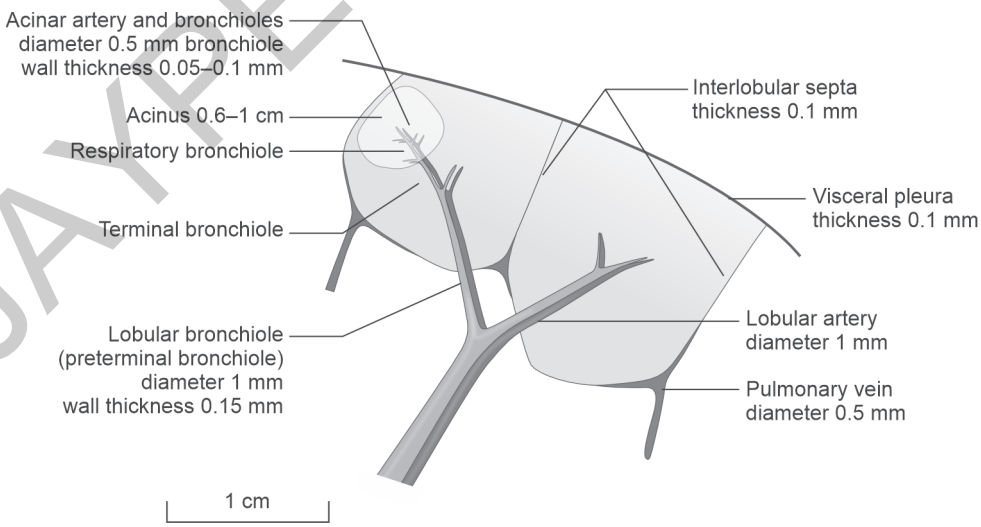

FIG. 1: Anatomy of secondary pulmonary lobule.

JAYPEE BROTHERS

Nodular Pattern

- This pattern consists of discrete nodules of varying size—micronodular (<3 mm), macronodular (3–10 mm) distributed in the pulmonary lobule, single nodule up to 30 mm is solitary pulmonary nodule (SPN).
- Causes may be granulomatous disease, pneumoconiosis, metastasis, etc.
- Centrilobular, perilymphatic, and random—these three types of nodules are distributed in the secondary lobule.
- Perilymphatic nodules are seen along the peripheral interstitium which means nodules are seen along the pleura and fissures on HRCT, e.g., sarcoidosis and other granulomatous diseases.
- Random nodules will not follow any particular pattern of distribution in secondary pulmonary lobule, e.g., miliary tuberculosis (TB), metastasis, etc.

Ground Glass Opacity and Consolidation Pattern

- Consolidation is an abnormal increase in lung density with effacement of pulmonary vessels while in ground glass opacity (GGO) there is no effacement of pulmonary vessels and consolidation also leads to opacification of pulmonary spaces and/or interstitium.
- Alveolar pattern can be seen in acute interstitial pneumonia, acute respiratory distress syndrome (ARDS), *Pneumocystis jirovecii* pneumonia (PJP), bronchoalveolar carcinoma (CA), alveolar hemorrhage, etc.
- Mosaic attenuation is commonly associated with patchy areas of increased/decreased lucency leading to heterogeneous appearance of lung parenchyma due to abnormalities in small airway, peripheral pulmonary vasculature or interstitium.
- Tree in bud pattern is a manifestation of endobronchial spread of infection such as TB or aspiration and characterized by linear branching structures (opacified distal bronchioles) with nodular opacities (acinar).

Cystic Pattern

- Cystic lesions in lung are usually formed by the abnormal dilatation of bronchi/bronchioles.
- Patterns of cystic lesion may look such as cluster of grapes, string of pearls, honey combing, and random cysts.
- Clusters of grapes seen in cystic bronchiectasis due to abnormal dilatation of airways involving a lobe or segment.
- Air fluid level in cystic lesion indicates secondary infection.
- String of pearl pattern is characterized by the presence of multiple cysts in a single row along the pleura.
- Honey combing is relatively smaller thick-walled cysts arranged in multiple layers, seen in fibrosing ILDs.
- Centriacinar emphysema, pulmonary Langerhans cell histiocytosis (PLCH), and leiomyomatosis may present with randomly distributed cysts.

JAYPEE BROTHERS

COMPUTED TOMOGRAPHY THORAX 1

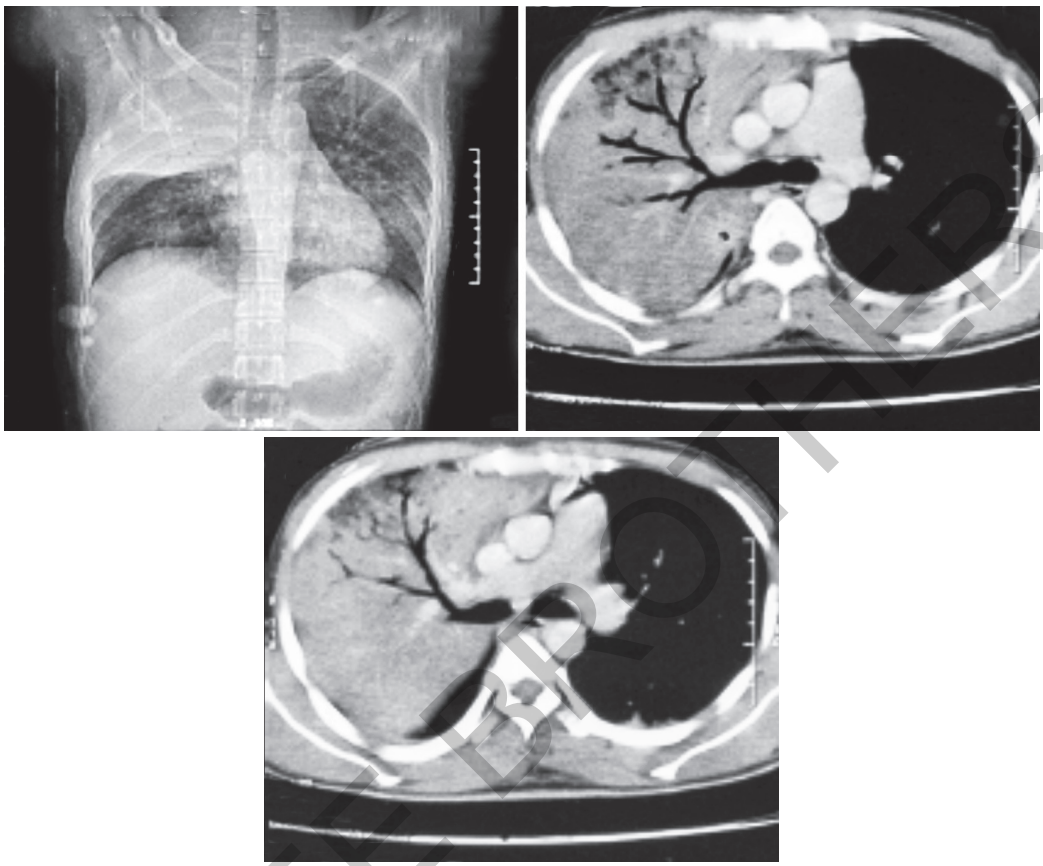

- *Description*: Right upper lobe pneumonia with air bronchogram with bulging fissure sign. Bulging fissure sign is classically seen in *Klebsiella pneumonia*.
- *Final impression*: Right upper lobe community acquired pneumonia.

COMPUTED TOMOGRAPHY THORAX 2A

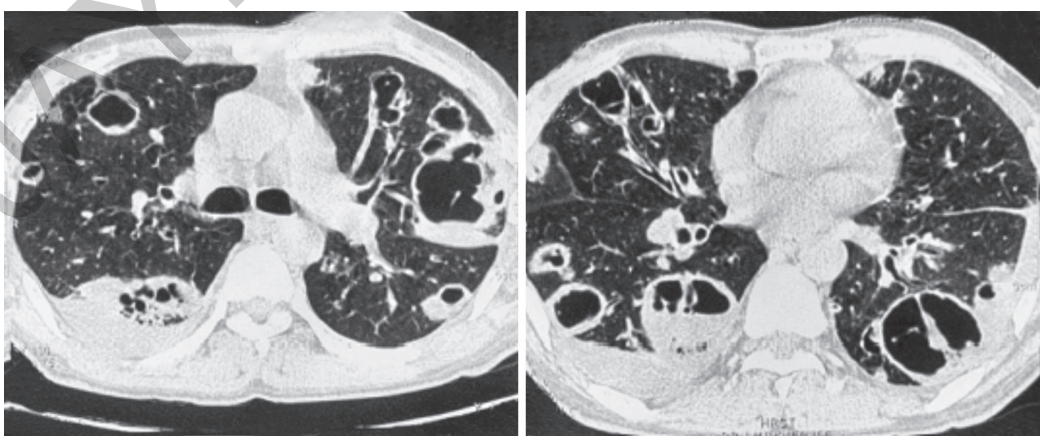

JAYPEE BROTHERS

- *Description*: Bilateral infected cysts/bulla with right minimal pleural effusion and necrotizing pneumonia in right side.
- *Differential diagnosis*:
  - Pulmonary TB
  - Bacterial infection—staphylococcal
  - Cystic bronchiectasis
- *Final impression*: Multiple cavitary lesion following staphylococcal pneumonia.

CHEST X-RAY 2B

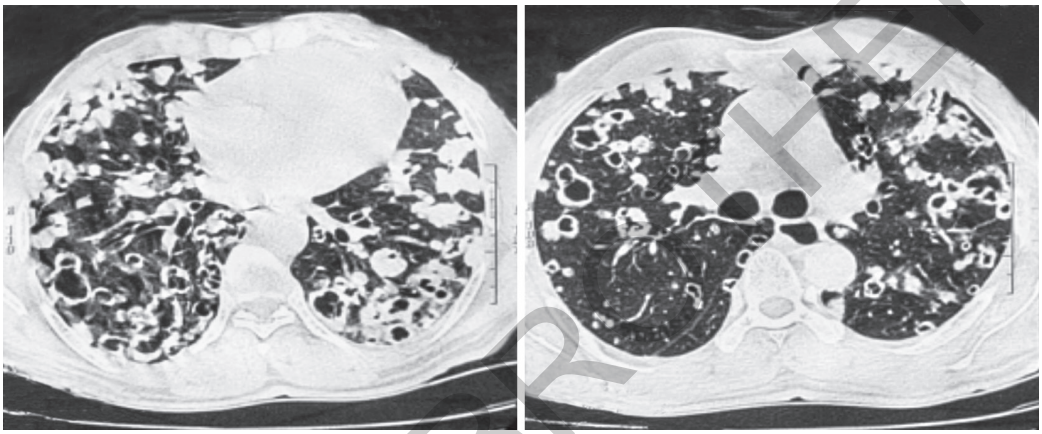

- *Description*: Bilateral extensive small cystic lesion involving all the lobes of lung and bilateral multiple micro and macro nodular opacities.
- *Differential diagnosis*:
  - Bacterial infection—staphylococcal
  - Fungal infection
  - Pulmonary TB
  - Pulmonary metastasis
- *Final impression*: Pneumatocele following to staph infection.

COMPUTED TOMOGRAPHY THORAX 3

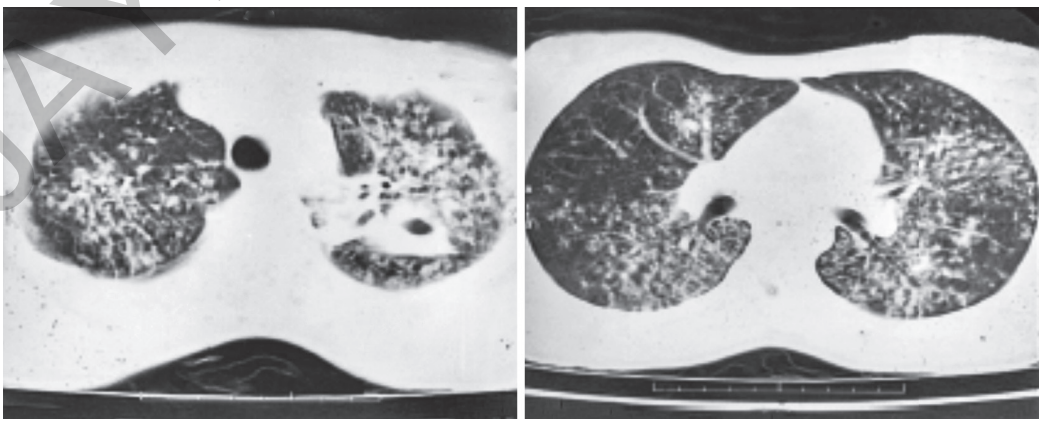

Continued

JAYPEE BROTHERS

Continued

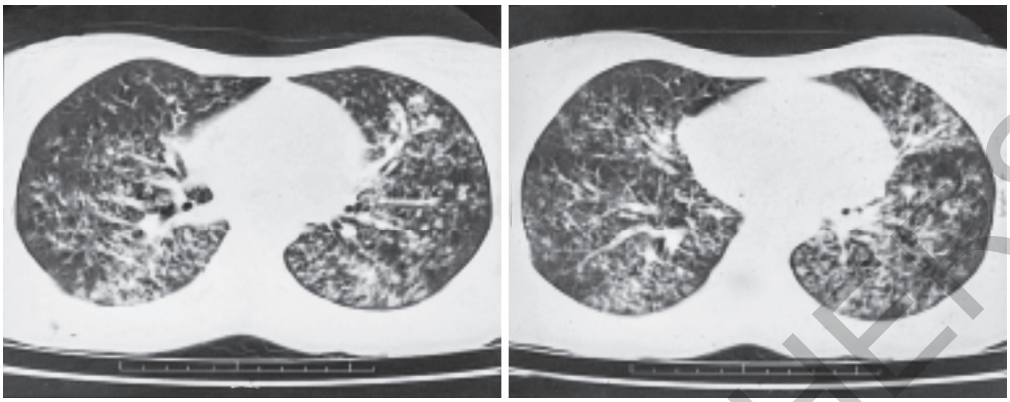

- *Description*: Bilateral extensive miliary shadow with tree in bud and cavity in left upper lobe.
- *Differential diagnosis*:
  - TB
  - Fungal infection
  - Silico-TB
  - Miliary metastasis
- *Final impression*: Pulmonary TB

COMPUTED TOMOGRAPHY THORAX 4

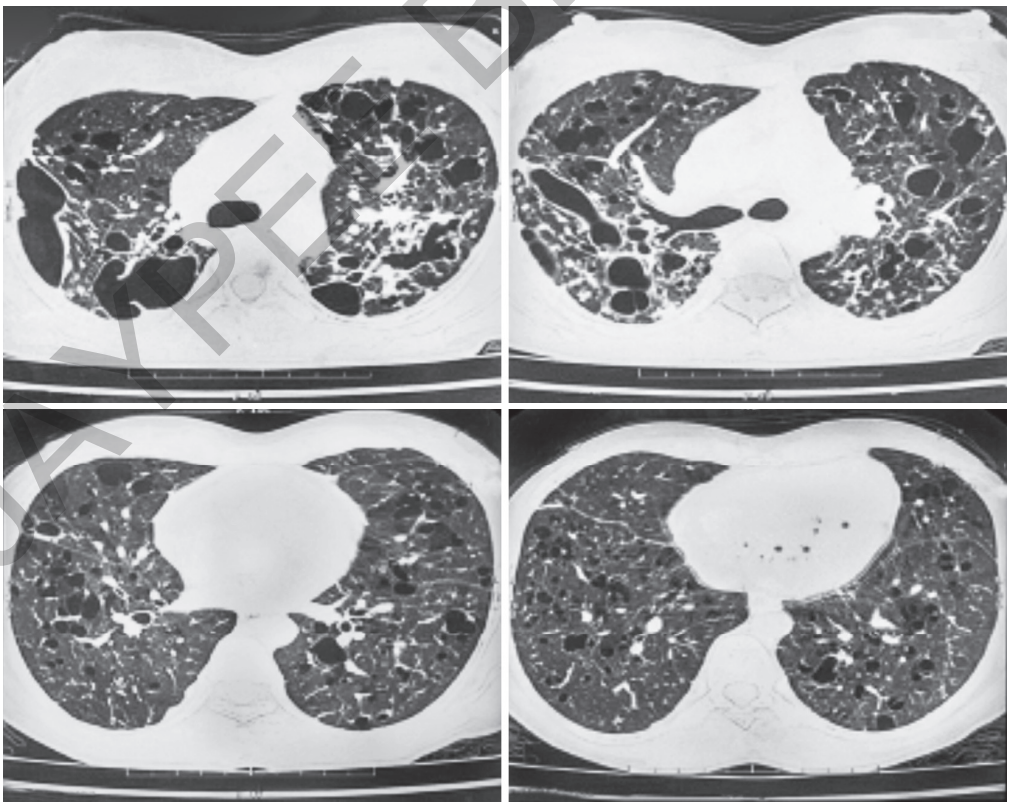

JAYPEE BROTHERS

- *Description*: Bilateral extensive cystic lesion with bilateral upper lobe predominant fibrosis right > left (r>l) with paraseptal emphysema.
- *Differential diagnosis*:
  - PLCH
  - Lymphangioleiomyomatosis (LAM)
  - Post-TB sequelae
- *Final impression*: Pulmonary TB—proven by transbronchial lung biopsy (TBLB)

COMPUTED TOMOGRAPHY THORAX 5

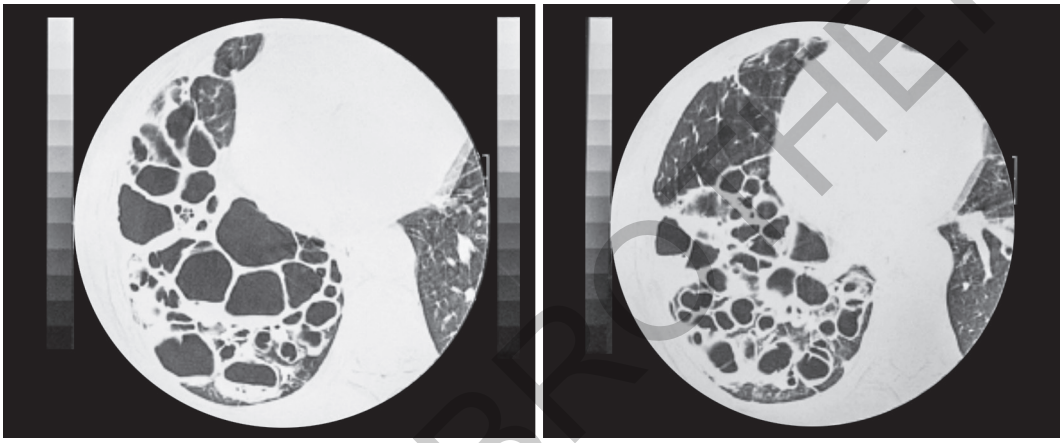

- *Description*: Right lower lobe cystic bronchiectasis.
- *Differential diagnosis*:
  - Following recurrent aspiration pneumonia
  - Post-tubercular sequelae
  - Following recurrent bacterial infection
- *Final impression*: Right lower lobe bronchiectasis due to recurrent bacterial infection since childhood.

COMPUTED TOMOGRAPHY THORAX 6

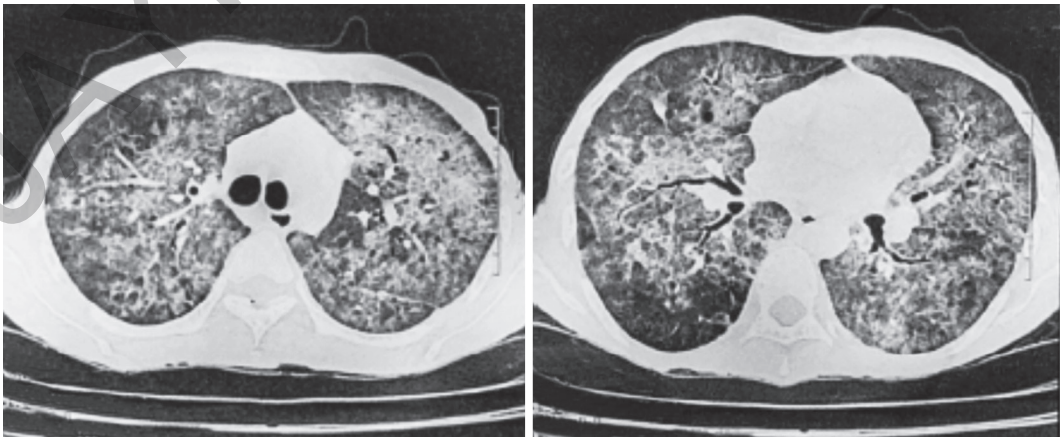

JAYPEE BROTHERS

- *Description*: Bilateral paratracheal, parahilar, and paracardiac extensive GGO.
- *Differential diagnosis*:
  - ARDS
  - Heart failure
  - Acute interstitial pneumonia
  - Cryptogenic organizing pneumonia
  - Uremic lung
- *Final impression*: ARDS

COMPUTED TOMOGRAPHY THORAX 7

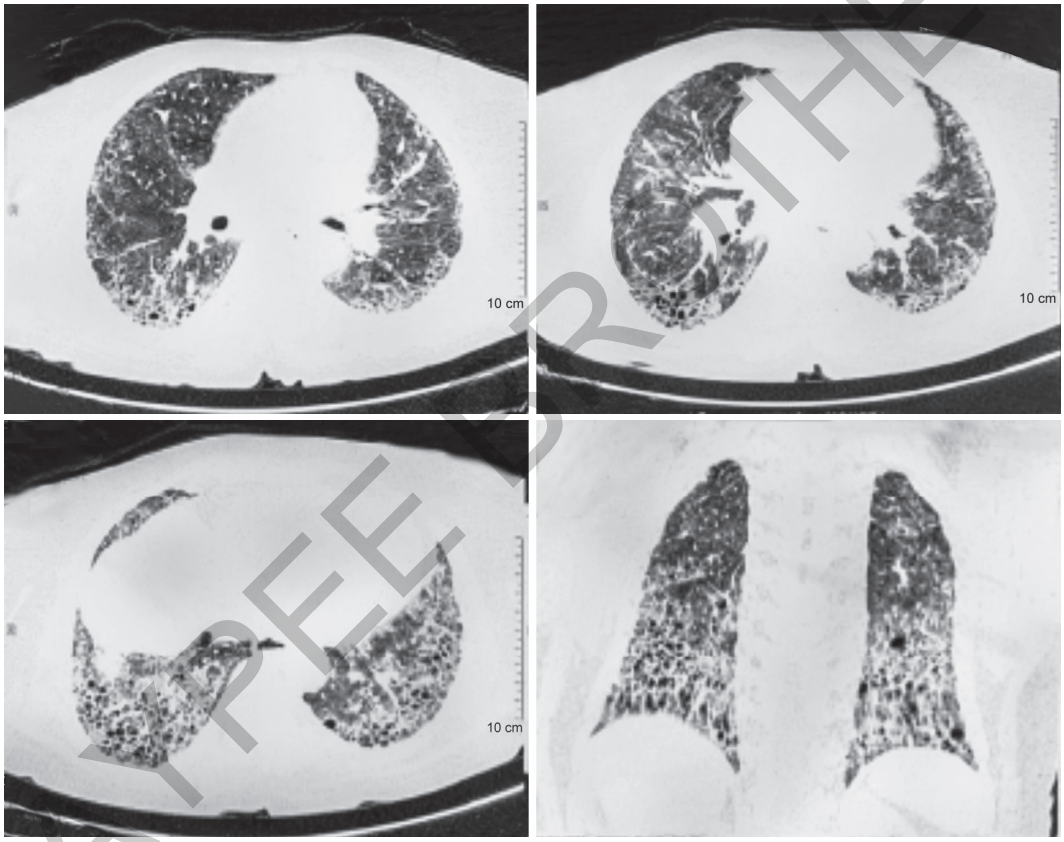

- *Description*: Bilateral, bibasal subpleural honey combing with traction bronchiectasis—UIP pattern. Straight edge sign—isolation of fibrosis to the lung bases with sharp demarcation in the craniocaudal plane without substantial extension along the lateral margins. It suggests collagen vascular disease.
- *Differential diagnosis*:
  - Connective tissue disease (CTD) related ILD
  - Occupational lung disease
  - Drug-induced ILD
  - Idiopathic pulmonary fibrosis (IPF)
- *Final impression*: CTD related ILD with UIP pattern.

JAYPEE BROTHERS

COMPUTED TOMOGRAPHY THORAX 8

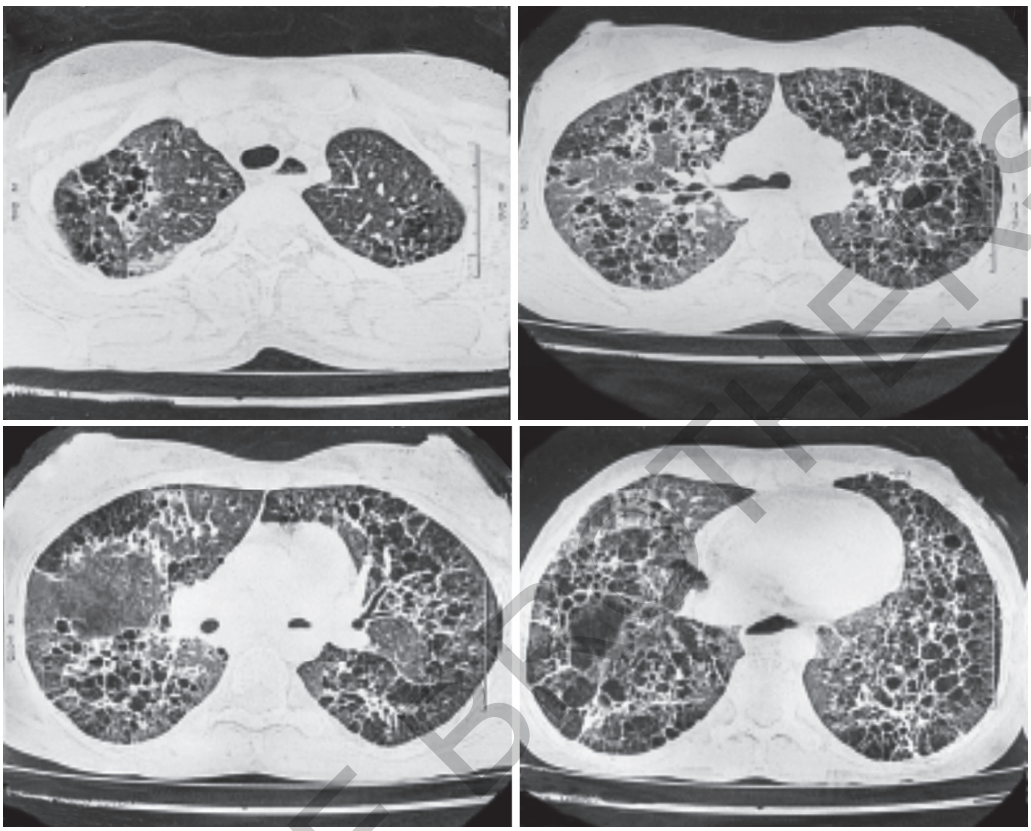

- *Description*: Bilateral extensive reticulation involving all the lobes with few cystic lesions (left) and traction bronchiectasis with GGO with bilateral subpleural honeycombing and dilated oesophagus.
- *Final impression*: Progressive system sclerosis—interstitial lung disease (PSS-ILD) (probable UIP pattern).

COMPUTED TOMOGRAPHY THORAX 9

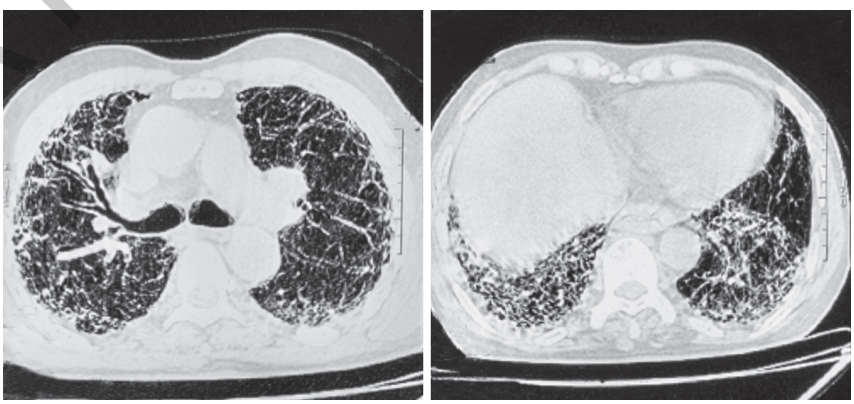

JAYPEE BROTHERS

- *Description*: Bilateral, bibasal subpleural honeycombing with reticulation and traction bronchiectasis—UIP pattern.
- *Final impression*: It is a case of IPF as no other cause detected.

COMPUTED TOMOGRAPHY THORAX 10

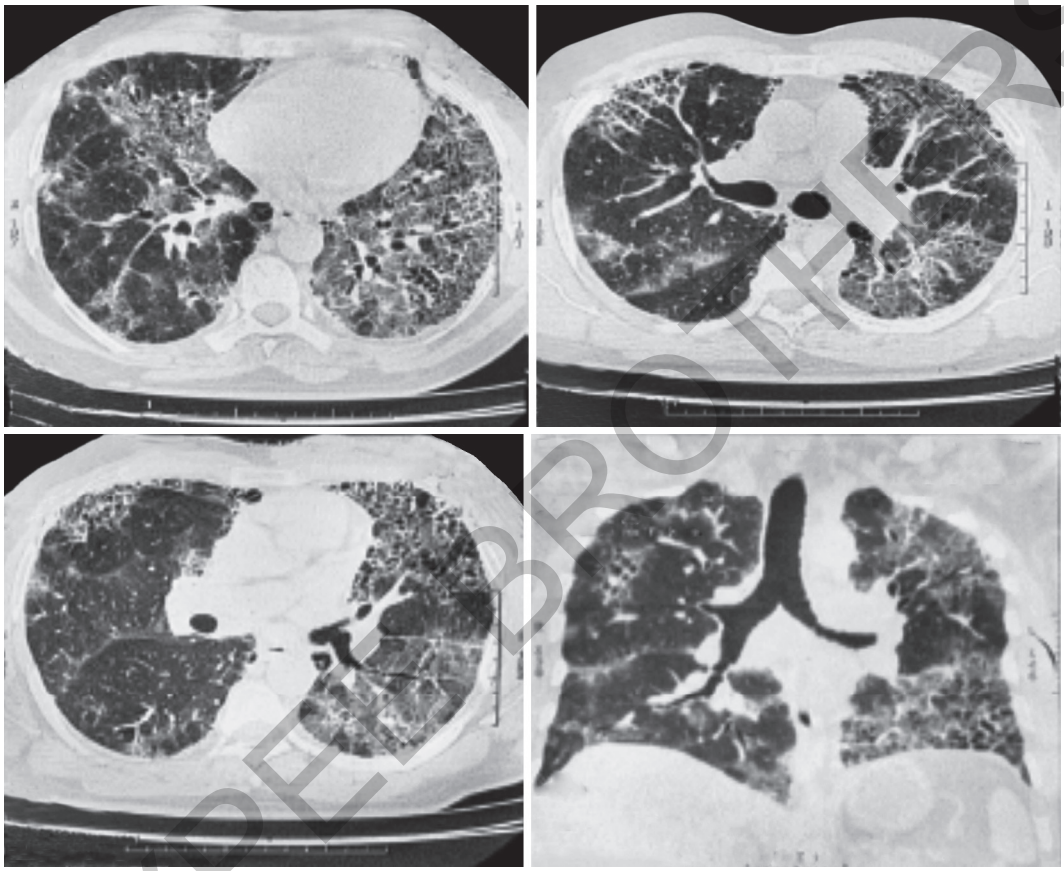

- *Description*: Bilateral extensive GGO with mosaic attenuation with reticulation and traction bronchiectasis—three density sign.
- *Three density sign*: Juxtaposition of lobular regions of low, normal, and high attenuation indicative of mixed infiltrative and obstructive process—suggestive of HP.
- *Final impression*: Chronic HP

JAYPEE BROTHERS

COMPUTED TOMOGRAPHY THORAX 11

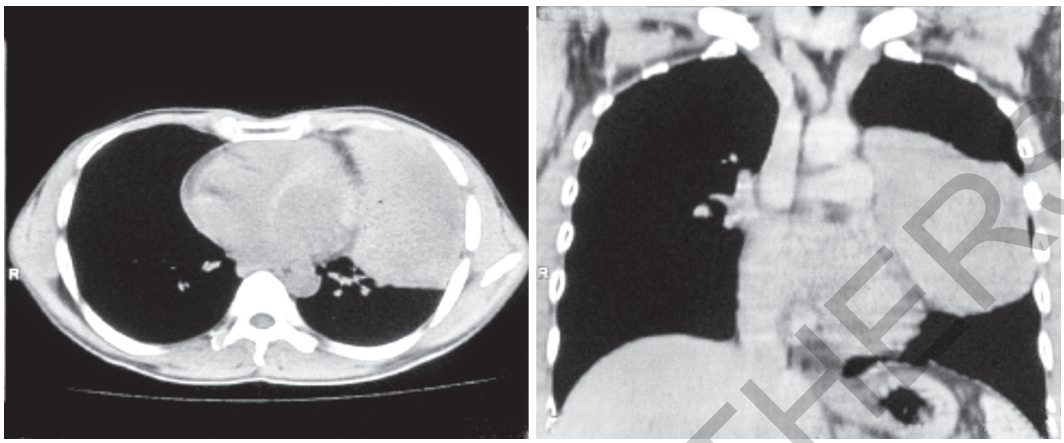

- *Description*: Homogeneous opacity occupying left lingular segment.
- *Differential diagnosis*:
  - Left lung malignancy
  - Left lung benign mass
  - Left upper lobe (lingular) pneumonia
- *Final impression*: Left lung mass in lingular segment.

COMPUTED TOMOGRAPHY THORAX 12A AND B

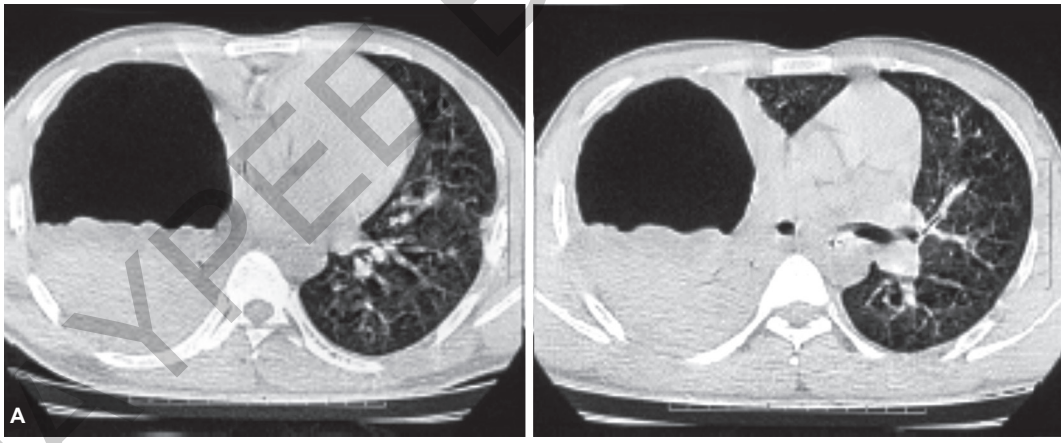

Continued

JAYPEE BROTHERS

Continued

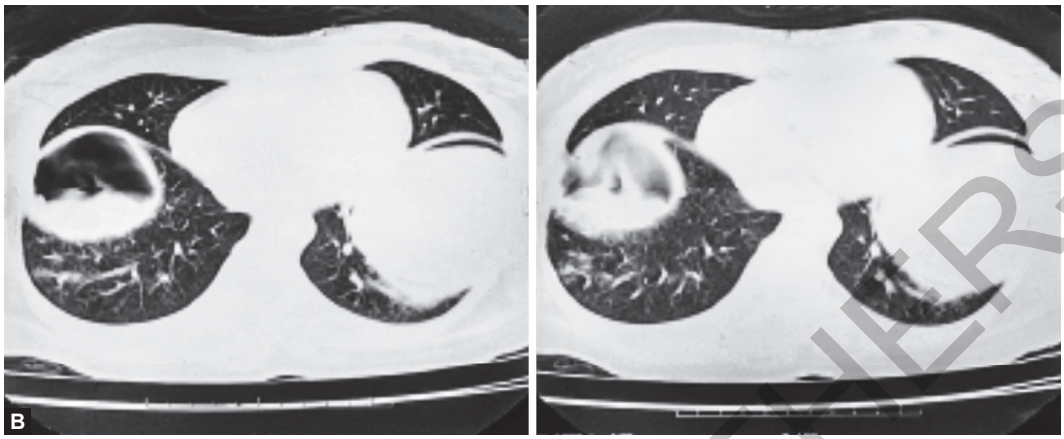

- *Description*: Right sided ruptured hydatid cyst—water lily (camolette) sign
- *Description*: Bilateral ruptured hydatid cyst water lily (camolette) sign on right side meniscus sign on left side.

COMPUTED TOMOGRAPHY THORAX 13

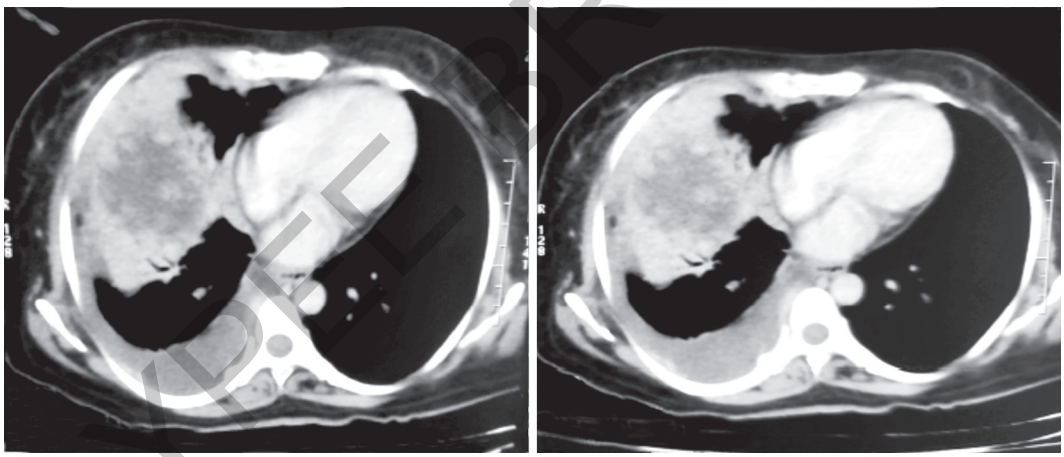

- *Description*: Right sided space occupying lesion (SOL) abutting the chest with central area of necrosis with multiple projections from the wall with right sided pleural effusion.
- *Differential diagnosis*:
  - Right sided malignant SOL
  - Right sided lung abscess
  - Right sided hydatid cyst with multiple daughter cysts
- *Final impression*: Right sided hydatid cyst with multiple daughter cysts—confirmed by echinococcal serology.

JAYPEE BROTHERS

for detailed information on medicine books, visit our website www.jaypeebrothers.com, for detailed information on medicine books, visit our website w

An Aid to RESPIRATORY MEDICINE
for Postgraduate Exit Exam

MD, DNB and Diploma

Salient Features

- Practice-oriented book with insight into chest X-ray, CT scan of thorax, USG thorax, bedside arterial blood gas (ABG), pulmonary function test, and sleep disorders
- Useful for undergraduate, postgraduate, and practitioners
- Reduce the time gap between presentation to the doctors and initiation of treatment with better bedside understanding of the case.

Susmita Kundu MBBS DTM&H MD(TB and Chest Diseases) DNB(RPD) is a Professor and Head, Department of Respiratory Medicine, KPC Medical College, Kolkata, West Bengal. She is an Ex-Professor and Head, Department of Respiratory Medicine, RG Kar Medical College and Hospital, Kolkata, West Bengal. She is an Ex-Chairman, National TB Elimination Programme, West Bengal, India. She has also been a convener, paper setter, and examiner of Diplomate of National Board of Examinations, New Delhi. She is an executive body member of the Association of Chest Physicians, West Bengal, a member of the Indian Chest Society (ICS), and a research guide to both postgraduate and postdoctoral students. She is an expert in fiberoptic bronchoscopy as well as medical thoracoscopy. She has presented papers in both national and international conferences.

Printed in India

Available at all medical bookstores or buy online at www.ejaypee.com

JAYPEE BROTHERS
Medical Publishers (P) Ltd.
EMCA House, 23/23-B, Ansari Road,
Daryaganj, New Delhi - 110 002, INDIA
www.jaypeebrothers.com

Join us on facebook.com/JaypeeMedicalPublishers
Follow us on instagram.com/JaypeeMedicalPublishers

Shelving Recommendation
MEDICINE

ISBN 978-93-5696-937-7