opedics books, visit our website www.ejaypee.com,for detailed information on orthopedics books, visit our website www.ejaypee.com, for detailed information on orthopedics books

6

ies Monographs

opedics books, visit our website www.ejaypee.com,for detailed information on orthopedics books, visit our website www.ejaypee.com, for detailed information on orthopedics books

5

Master Series Monograp

opedics books, visit our website www.ejaypee.com,for detailed information on orthopedics books, visit our website www.ejaypee.com, for detailed information on orthopedics books

4

ies Monographs

opedics books, visit our website www.ejaypee.com,for detailed information on orthopedics books, visit our website www.ejaypee.com, for detailed information on orthopedics books

3

Master Series Monograp

opedics books, visit our website www.ejaypee.com,for detailed information on orthopedics books, visit our website www.ejaypee.com, for detailed information on orthopedics books

2

ries Monographs

arthritis



Editor-in-Chief
Gautam Zaveri

Section Editors
Shubhranshu S Mohanty
Dinshaw Pardiwala

JAYPEE

opedics books, visit our website www.ejaypee.com,for detailed information on orthopedics books, visit our website www.ejaypee.com, for detailed information on orthopedics books

1

Master Series Monographs

Giant Cell Tumors of Bone



Editor-in-Chief
Gautam Zaveri

Section Editors
Ajay Puri
Manish Pruthi

JAYPEE

JAYPEE BROTHERS

Contents

Note from the Editor-in-Chief xi

Note from the Section Editors xiii

Contributors xv

1. **Radiology of the Giant Cell Tumor** 1
   Amit Janu, Amit Choudhari, Aishvarya Shri Rajasimman

2. **Pathology of Giant Cell Tumor of Bone** 15
   Sumathi Vaiyapuri

3. **Curettage in Giant Cell Tumor of Bone** 25
   Manish Pruthi

4. **Giant Cell Tumor: Reconstructing the Defect** 33
   Manish Agarwal

5. **Resection in Giant Cell Tumor of Bone** 47
   Akshay Tiwari

6. **Role of Denosumab in GCT: When, How Much and What are the Problems?** 57
   Bhim Bahadur Shreemal, Vineet Kurisunkal

7. **Does Radiotherapy have a Role in Giant Cell Tumors of Bone?** 67
   Sam David, Jifmi Jose Manjali, Nehal Khanna, Siddhartha Laskar

8. **Noninvasive Methods and Role of Interventional Radiology in Giant Cell Tumors of Bone** 73
   Sanjana Devarmani, Kunal Gala, Nitin Shetty, Suyash Kulkarni

9. **Algorithm for Management of Giant Cell Tumors in Axial and Appendicular Bone** 81
   Ajay Puri

10. **Potential Avenues for Research in Giant Cell Tumor of Bone** 85
    Prakash Nayak

JAYPEE BROTHERS

11. Illustrative Case Examples of Unusual Cases of Giant Cell Tumor **91**

Case 1: Campanacci Grade 3 Giant Cell Tumor of Proximal Tibia: Balance between Disease Control and Function *91*
Manish Pruthi

Case 2: Campanacci Grade 3 Giant Cell Tumor of the Distal Radius with Pathological Fracture Treated with Fibular Autograft Arthroplasty *95*
Vivek Ajit Singh

Case 3: Giant Cell Tumor of the Posteromedial Femoral Condyle *101*
Wan Faisham Nu'man Wan Ismail

Case 4: Campanacci Grade 3 Giant Cell Tumor of Distal Tibia *106*
Ashish Gulia

Case 5: Giant Cell Tumor of the Patella—Concers Regarding Clinical Outcomes and Soft Tissue Limitations *111*
Thomas Baad-Hansen, Ahmed A Abood

Case 6: Recurrent Giant Cell Tumor of Distal Femur Treated with Megaprosthesis *114*
Prateek Hegde

Index **119**

JAYPEE BROTHERS

Contents

Note from the Editor-in-Chief xi

Note from the Section Editors xiii

Contributors xv

1. **Applied Anatomy and Biomechanics of the Knee Joint** 1
   Mihir Patel, Vedant Zaveri, Gautam Zaveri

2. **Etiopathogenesis and Natural History of Knee Osteoarthritis** 13
   Abhay Elhence, Vedant Zaveri, Rajesh Rajnish

3. **Clinical Features, Radiology, and Classification of Knee Osteoarthritis** 19
   Vaibhav Bagaria, Vedant Zaveri

4. **Patellofemoral Osteoarthritis** 31
   Arzan Jesia, Clevio Desouza, Rammohan Yedave, Dinshaw Pardiwala

5. **Nonoperative Treatment of Osteoarthritis Knee** 47
   Biswajit Sahu, Binaya Kumar Mishra

6. **Role of Intra-articular Injections and Orthobiologics in Osteoarthritis Knee** 55
   Vijay D Shetty, Clevio Desouza

7. **Knee Preservation Surgery: Role of Arthroscopy in Osteoarthritis and Prevention of Osteoarthritis** 69
   Abhay Narvekar, Gautam Zaveri

8. **Realignment Procedures for Osteoarthritis Knee** 81
   Bhushan M Sabnis

9. **Role of Unicompartmental Knee Replacement in Knee Osteoarthritis** 95
   Samuel King, Hemant Pandit

10. **Role of Total Knee Arthroplasty for Osteoarthritis Knees** 105
    Pranav Keswani, Shubhranshu S Mohanty

JAYPEE BROTHERS

11. Osteoarthritis Knee: Case Series **123**
Ameet Pispati, Kedar Aher

Case 1: Stage 0—Prearthritis *125*

Case 2: Stage 1—Minor Osteoarthritis—Early Signs and Gentle Interventions *126*

Case 3: Stage 2—Mild Osteoarthritis—Increasing Discomfort and Functional Impairment *127*

Case 4: Stage 3—Moderate Osteoarthritis—Significant Pain and Functional Impairment *129*

Case 5: Stage 4—Severe Osteoarthritis—Significant Pain and Functional Impairment *130*

Case 6: Medial Compartment Osteoarthritis in Older Patient with Pain and Functional Impairment *131*

Case 7: Medial Compartment Knee Osteoarthritis in Young Active Patient *132*

Index **133**

JAYPEE BROTHERS

Contents

Note from the Editor-in-Chief xi

Note from the Section Editors xiii

Contributors xv

1. **ABC of the Pediatric Elbow** 1
   Chasanal Rathod, Ashish S Ranade

2. **Radiology of the Pediatric Elbow** 11
   Tushar Agrawal, Swapnil Keny, Deepak Jain

3. **Typical Supracondylar Humerus Fractures** 21
   Sandeep Vaidya, Mudit Shah

4. **Atypical Supracondylar Humerus Fractures** 35
   Chintan Doshi, Sandeep Patwardhan

5. **Supracondylar Humerus Fractures with Neurovascular Injury** 49
   K Venkatadass, Mandar Agashe

6. **Management of Complications and Delayed Presentation of Supracondylar Humerus Fractures** 59
   Darshan M Kapoor, Premal Naik, Gautam Zaveri

7. **Lateral Condyle Humerus Fractures** 71
   Gauri Patki, Alaric Aroojis

8. **Complications of Lateral Condyle Humerus Fractures** 81
   Sameer Desai, Taral Nagda

9. **Medial Epicondyle Fractures** 91
   Shalin Shah, Maulin Shah

10. **Radial Head and Neck Fractures** 99
    Bhushan Sagade, Rujuta Mehta

11. **Monteggia Fracture-dislocations** 113
    Atul Bhaskar, Khyati Gupta

JAYPEE BROTHERS

12. TRASH Lesions of the Elbow 125
Sukalyan Dey, Rajul Gupta, Kevin J Little, Shital N Parikh

13. Short Notes: Complete Physeal Separation, Radial Head Fractures, Medial Condyle Fractures and Olecranon Fractures 137
Avi Shah, Jaideep Dhamele, Yogendra Singh Shekhawat, Taral Nagda

Index 151

JAYPEE BROTHERS

Contents

Note from the Editor-in-Chief xi

Note from the Section Editors xiii

Contributors xv

1. **Clinical and Surgical Anatomy of the Proximal Tibia** 1
   Siddharth Shah, Sachin Yashwant Kale

2. **Classification of Tibial Condyle Fractures** 11
   Harshad Argekar

3. **Lateral Condyle Fractures** 23
   Kashyap Ardeshana

4. **Medial Condyle Fractures** 47
   Sangeet Gawhale, Kushal Gohil

5. **Bicondylar Fractures** 61
   Vivek Shetty, Shaswat Mishra

6. **Tibial Condylar Fractures with Associated Ligament/Meniscal Injuries** 75
   Swapnil Kothadia, Gautam Zaveri

7. **Malunited Tibial Condyle Fractures** 95
   Mangal Parihar, Girish K Nathani, Amit Kumar Yadav

8. **Fracture Related Infections of the Proximal Tibia** 111
   Vikas M Agashe, Gautam Zaveri

9. **Tibial Plateau Fractures: Case Series** 123
   Jignesh Pandya, Pranav D Shah

   Case 1: Comminuted Medial Condyle Fracture with Anterior Cruciate Ligament and Posterior Cruciate Ligament Involvement *123*

   Case 2: Comminuted Lateral Condyle Fracture with Split Depression and Column Involvement *128*

   Case 3: Bicondylar Tibial Plateau Fracture with Medial Condyle Displacement and Anterior Cruciate Ligament Avulsion *134*

JAYPEE BROTHERS

Case 4: Posterior Bicondylar Tibia Fracture with Posteromedial and Posterolateral Condyle Involvement *139*

Case 5: Isolated Posterolateral Condyle Fracture with Articular Depression *143*

Case 6: Hyperextension Bicondylar Tibial Plateau Fracture with Varus Deformity *149*

Case 7: Posterior Bicondylar Tibial Plateau Fracture with Anterior Cruciate Ligament Avulsion and Coronal Plane Medial Condyle Fracture *154*

Case 8: Zero-column Fractures of the Lateral Tibial Condyle *158*

Index **171**

JAYPEE BROTHERS

Contents

Note from the Editor-in-Chief xiii

Note from the Section Editors xv

Contributors xvii

1. **Failed Fracture Fixation** 1
   Gautam Zaveri

2. **Mechanobiology of Fracture Healing** 5
   Anoop Dhamangaonkar, Gautam Zaveri

3. **Nonunion of Fractures** 15
   Ashish Phadnis, Niharika Virkar

4. **Failed Fixation of Proximal Humerus Fractures** 29
   Gautam Zaveri, Dipit Sahu

   Case 1: Isolated Greater Tuberosity Fracture *32*
   Parag Munshi, Gautam Zaveri

   Case 2: Innovative Management after Failed Fixation of Proximal Humerus Fracture *39*
   J Maheshwari, Dipit Sahu, Aditya Chaubey

   Case 3: Two-part Varus Posteromedial Fracture of Neck of Humerus *44*
   Dipit Sahu, Aditya Chaubey

   Case 4: A Four-part Valgus Impacted Head Split Proximal Humerus Fracture *47*
   Dipit Sahu, Aditya Chaubey

   Case 5: Failure of Locked Plating of a Four-part Proximal Humerus Fracture in the Older Individual *52*
   Dipit Sahu, Aditya Chaubey

   Case 6: Failure of Locked Plate Fixation in a Head-split Fracture-managed by "Sheek-Kebab" Reverse Shoulder Arthroplasty *55*
   Dipit Sahu

5. **Failed Fixation of Fractures of Humeral Diaphysis** 59
   Gautam Zaveri, Prashant Kamble

   Case 1: Fracture Shaft Humerus in an Epileptic Treated with Locked Intramedullary Nail *61*
   Parag Shah, Aditya Chaubey, Aashay Sonkusale, Dipit Sahu

JAYPEE BROTHERS

Case 2: Third Time's a Charm: A Journey Through Two Failed Fixations of a Humeral Shaft Fracture *65*
Prashant Kamble, DD Tanna

Case 3: Bridge to Nowhere: A Case of Failed Anterior Plating in Midshaft Humerus Fracture *70*
Prashant Kamble, Karan Chaudhary

Case 4: Implant Failure Following Inadequate Fixation in Humeral Shaft Fracture: A Case of Neglected Principles Leading to Deformity *75*
Sachin Yashwant Kale

Case 5: Failed Fixation—Fracture Shaft Humerus *80*
Prashant Kamble, Karan Chaudhary

Case 6: Atrophic Nonunion of Proximal Third Humerus Fracture *85*
Abhijit Kale

6. Distal Humerus Fractures **93**
Gautam Zaveri, Prashant Kamble

Case 1: Supracondylar Fracture of Humerus in Young Adult Treated with Closed Pinning *97*
Jignesh Pandya

Case 2: Supracondylar Humerus Fracture Treated with Dual Plating *102*
Sachin Yashwant Kale, Sandeep Deore

Case 3: Failed Fixation Distal Humerus Fracture *106*
Prashant Kamble, Karan Chaudhary

Case 4: Comminuted Supracondylar Fracture of Humerus with Intercondylar Extension *111*
Jignesh Pandya

Case 5: Nonunion Supracondylar Humerus Fracture in an Open Floating Elbow *115*
Hemant Patankar

Case 6: Failed Elbow Fracture Fixation *122*
Satish Mutha, Rohit Somani, Gautam Zaveri

7. Failure of Fixation of the Radius and Ulna Diaphysis **129**
Gautam Zaveri, Parag Lad

Case 1: 15-year-old Ulna Nonunion Following Intramedullary Nailing of Both Bones of the Forearm *131*
Prashant Kamble, Karan Chaudhary

Case 2: Early Deep Surgical Site Infection Following Plating of Both Bones Forearm *136*
Parag Lad

Case 3: Grade 2 Open Monteggia Fracture—Dislocation Treated with Intramedullary Nailing *139*
Kashyap Ardhesana

JAYPEE BROTHERS

Case 4: Fracture Both Bones Forearm in an 80-year-old Treated with Plating *144*
Vikas M Agashe

Case 5: Multiple Failed Fixations of Both Bones Forearm *148*
Hemant Patankar

8. Failed Fixation of Distal Radius Fractures **153**
Gautam Zaveri, Parag Lad

Case 1: From Malposition to Motion: Salvaging a Distal Radius Fixation Error! *156*
Parag Lad

Case 2: Failed Plating for a Volar Barton Fracture *161*
Hemant Patankar, Gautam Zaveri

Case 3: Comminuted Distal Radius Fracture *164*
Hemant Patankar

9. Failed Fixation of Metacarpal and Phalangeal Fractures **169**
Parag Lad, Gautam Zaveri

Case 1: Fracture 5th Metacarpal Neck Fixed with Cross K-wire Fixation *171*
Hemant Patankar, Parag Lad

Case 2: Proximal Phalanx Fracture Fixed to Nonunion *175*
Hemant Patankar, Parag Lad

Case 3: Failed Fixation Proximal Phalanx of Thumb *179*
Hemant Patankar, Parag Lad

Case 4: Malunion Base of Proximal Phalanx with Flexor Tendon Adhesions *182*
Hemant Patankar, Parag Lad

Index **189**

JAYPEE BROTHERS

Contents

Note from the Editor-in-Chief xiii
Note from the Section Editors xv
Contributors xvii

1. **Biomechanics of Implants** 1
Shaligram Purohit, Arjit Vashishtha, Gautam Zaveri

2. **Minimizing Failure of Fracture Fixation in Osteoporotic Bones** 21
DD Tanna, Harshad Argekar, Gautam Zaveri

3. **Failed Fixation Neck of Femur Fractures** 35
Sachin Yashwant Kale, Gautam Zaveri

Case 1: Failed Fixation Fracture Neck Femur: Limitations of Femoral Neck System Implant *38*
Sachin Yashwant Kale

Case 2: Atypical Hip Fracture Followed by Shaft Fracture *42*
Sachin Bhonsle

Case 3: Valgus Osteotomy for Nonunion of a Femur Neck Fracture *47*
DD Tanna

4. **Failed Fixation Intertrochanteric Fractures** 53
Sachin Yashwant Kale, Gautam Zaveri

Case 1: Salvage of Failed Intertrochanteric Fracture Fixation with Total Hip Replacement in a Rheumatoid Patient on Steroids *55*
Vaibhav Bagaria

Case 2: Displaced Comminuted Lateral Wall Intertrochanteric Fracture with Implant Failure *59*
Sachin Yashwant Kale

Case 3: Unstable Intertrochanteric Fracture with Subtrochanteric Extension Failed Fixation 2 Years Post Index Surgery *64*
Sachin Bhonsle

JAYPEE BROTHERS

5. Fixation Failure Subtrochanteric Fractures **69**
Sachin Yashwant Kale, Gautam Zaveri

Case 1: Failed 95° Dynamic Condylar Screw for Subtrochanteric Fracture Salvaged with Revision Fixation and Augmentation Plating *73*
Satish Mutha

Case 2: Failed Subtrochanteric Fracture Fixation Salvaged with a Valgus Osteotomy *77*
Harshad Argekar, Ganesh Rajeshwar Yeotiwad

Case 3: Failed Intramedullary Nailing of Subtrochanteric Fracture—Salvaged with Exchange Nailing and Bone Grafting *80*
Vikas M Agashe, Sanjay Agarwala, Gautam Zaveri

Case 4: Failed Proximal Femoral Nail for a High Subtrochanteric Fracture—Salvaged with an Angled Blade Plate *86*
Harshad Argekar

Case 5: Technical Challenges in Management of Salute Fracture (High Subtrochanteric Femur Fracture) *90*
Vivek Shetty, Raunak Dhawale, Vikas M Agashe

6. Failed Fixation Femoral Shaft Fractures **99**
Sachin Yashwant Kale, Gautam Zaveri

Case 1: Failed Intramedullary Nailing of Diaphyseal Fracture of Femur *102*
Harshad Argekar

Case 2: Infected Nonunion of Femur Managed with Limb Reconstruction System—Acute Docking and Lengthening *107*
Ajit Chalak, Sachin Yashwant Kale

7. Failed Fracture Fixation Distal Femur Fractures **113**
Harshad Argekar

Case 1: Distal Femur Implant Failure Salvaged with Dual Nail-plate Fixation *116*
Sachin Yashwant Kale, Pramod Bhor

Case 2: Salvage for Early Cutout of Distal Femoral Nail *120*
Harshad Argekar, Amit Yadav

Case 3: Medial Support: The Critical Factor in Distal Femur Fracture Fixation Failure *125*
Pradeep Nemade

Case 4: Salvaging an Infected Periprosthetic Fracture *130*
Avinash Date

JAYPEE BROTHERS

8. Fixation Failures of Tibial Condyle Fractures **135**
Harshad Argekar, Gautam Zaveri

Case 1: Nonunion Tibial Condyle Fracture *138*
Vikas M Agashe, Vivek Shetty

Case 2: Proximal Tibia Nonunion *145*
Jignesh Pandya

9. Failed Fixation of Tibial Shaft Fractures **149**
Harshad Argekar, Gautam Zaveri

Case 1: Failed Intramedullary Nail with Infection in Proximal Tibia Treated with Ilizarov Fixator *152*
Ajit Chalak, Tarang Khairnar, Sachin Yashwant Kale

Case 2: Implant Failure in Distal Tibial Fracture Managed with Ankle Arthrodesis Using Ilizarov-assisted Bone Transport *158*
Ajit Chalak, Jayant Gawand, Sachin Yashwant Kale

Case 3: Open Distal Tibia Fracture with Failed Internal Fixation *162*
Jignesh Pandya

Case 4: Infected Nonunion of Distal Tibia Managed with Limb Reconstruction System Assisted Bone Transport *168*
Ajit Chalak, Sachin Yashwant Kale

Case 5: Nonunion Fracture of Distal Third Tibia and Fibula *175*
DD Tanna

Case 6: Hypertrophic Nonunion of Tibial Diaphysis Treated with Dual Fixation and Unitization *179*
Vivek Shetty

10. Fixation Failures Ankle Fractures **185**
Harshad Argekar

Case 1: Early Presentation of Failed Fixation of Distal Tibiofibular Syndesmosis: Management with Syndesmotic Reconstruction and Deltoid Repair *188*
Rajiv Shah, Shivam Shah, Uma Sai Manukonda

Case 2: Delayed Presentation of Syndesmotic Injury: Managed with Syndesmotic Fusion *192*
Rajiv Shah, Shivam Shah, Uma Sai Manukonda

Case 3: Failed Ankle Fracture Fixation in a Diabetic Salvaged with a Tibiotalocalcaneal Fusion *197*
Dhrumin Sangoi

JAYPEE BROTHERS

Case 4: Post-traumatic Ankle Arthritis Secondary to Mistreated Syndesmotic Injury with Multiple Failed Surgeries: Managed with Tibiotalocalcaneal Arthrodesis *201*
Shyam Thakkar

Case 5: Complex Bilateral Calcaneal Malunion with Failed Operative Fixation and Secondary Hindfoot and Forefoot Deformities *205*
Rajiv Shah, Shivam Shah, Uma Sai Manukonda

Case 6: Failed Calcaneal Fracture Fixation Treated with Subtalar Arthrodesis *212*
Pradeep Moonot

Case 7: Neglected Lisfranc Injury *217*
Dhrumin Sangoi

Index **221**

JAYPEE BROTHERS

4 Giant Cell Tumor: Reconstructing the Defect

Manish Agarwal

Introduction

Extended curettage is the preferred treatment for a large majority of giant cell tumors (GCTs). The favored subarticular location of the lesion results in defects that are in close proximity to the articular cartilage and often involve a large volume of the metaphysis. Small volume defects do not challenge the surgeon. However, most of the affected patients are young and expect to be active. Hence, the reconstruction of larger defects has to be done with considerable thought, planning, and may require customization as per the defect and patient expectations. A surgeon has several choices varying from no filling to filling with bone, bone substitute, cement, or a combination of these materials. This chapter discusses the reconstruction of such defects.

The Defect

After a good extended curettage, the surgeon is left with a defect which varies in volume and extent depending on tumor size **(Figs 1A and B)**. Most defects are contained, except in the area of the window made for curettage. On the side of the joint, one has only cartilage or cartilage with varying amounts of subchondral bone. Unsupported articular cartilage over a large area can be a major challenge to optimal reconstruction. The amount of cortical or bony wall defects will also change the construct. Reinforcement with strut bone grafting and/or implant fixation may be needed when more than one-third of the circumference of the bony wall is lost.[1]

Do We Need to Fill the Defect?

The necessity of filling the bone defect left after curettage is still debated. Prosser et al, argue that small voids left behind after curettage do not jeopardize the structural integrity of the bone and can therefore be left alone.[2] The cavities fill up with blood clots, which then get ossified to form bone. Hirn et al, reported outcomes of 146 patients with GCTs in whom the defect created by curettage was left alone without filling.[3] The average time to weight bearing following surgery was 6 weeks. 88% of their patients did not require any further intervention, with some cavities filling completely and others having voids that never filled up. The risk of fracture and osteoarthritis (OA) was higher if voids exceeded

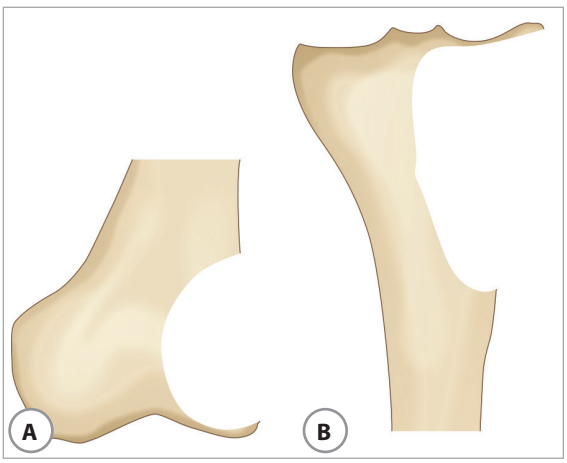

Figs 1A and B: (A) Typical defects after giant cell tumor curettage in the distal femur, and (B) Proximal tibia. Note the subarticular location where the amount of subchondral bone involved is variable. The rest of the defect involves metaphysis extending down to the shaft.

JAYPEE BROTHERS

60cc volume. Likewise, Kundu et al, found the postoperative fracture risk to be higher in unfilled defects of > 70 cc in volume.[4,5] Additionally, they cautioned that cavities with subchondral bone < 5 mm should not be treated without filling, as there was a high risk of articular collapse. Contrarily, Gava et al, in their systematic review, reported that fractures were significantly more common in unfilled cavities and that about 10% of these fractures happened in smaller cavities of < 60 cc volume. They concluded that size or volume alone could not predict the risk of fracture. Bola Adel et al, reported a 19% risk of complications even with cavities < 30 cc.[6]

Leaving bony voids unfilled poses a higher risk of fracture and delays weight bearing. In our opinion, only very small cavities (< 30 cc), with less than one-third loss of cortical circumference, and defects with more than 5 mm of residual subchondral bone after curettage, can be left without filling. Our view concurs with Ward et al, that defects in the proximal tibia or distal femur are often large and, being high-stress zones, cannot be expected to heal to weight-bearing strength in 3 months. Without prolonged support, collapse of the cavity or a fracture is likely.[7] Gava et al, in their systematic review, found that there were no fractures in cases where a plate fixation was used.[5] We therefore recommend a plate fixation wherever there is a high risk of fracture, particularly where more than a third of the bony wall is lost. If there is any doubt in the surgeon's mind, then it is better to use a plate.

The Materials

A number of different materials have been used either alone or in combination to fill postcurettage defects. These include autograft or allograft bone, bone cement, and various artificial bone substitutes.

Bone or Cement?

Bone has the advantage of being a biological material with the ability to remodel once incorporated. However, autograft quantity is limited and can cause donor site morbidity. This morbidity is often related to the volume of graft harvested. Allograft bone has been used alone or in combination with autografts to fill large curettage defects. Buecker et al, showed that a single fibular strut allograft added to morcellized allograft helped in the healing of curettage defects.[8] To improve osteoinductive capability, autogenous graft or bone marrow is added to the morcellized allograft.

For large curettage defects, we have successfully been using a "T" construct that involves wedging a transversely placed iliac crest block in the subchondral region with fibular struts placed longitudinally below the block **(Fig 2)**. The fibular struts can be autogenous or allogenic, and in our experience, the cavity does not require to be filled as the struts prevent collapse while healing occurs **(Figs 3A to C)**. We have used allografts as both morcellized and strut grafts with good results in curettage defects.[9,10] In India, allografts are available as freeze-dried, radiated grafts. Their use is limited by limited availability. Additionally, allografts carry the risk of transmission of infection, as well as a higher risk of wound infection.[5] Bone grafting involves a significant period of protected weight bearing till the graft incorporates. Additionally, diagnosis of tumor recurrence on follow-up radiographs is sometimes difficult to identify after bone grafting, because the graft is generally not densely packed, leaving numerous lytic and sclerotic areas **(Fig 4A)**.

Polymethyl methacrylate (PMMA) or bone cement, on the other hand, is easily available in any quantity, conforms to any irregular defect, and has immediate strength to compression, allowing early weight-bearing. On average, cement-filled cavities allowed weight bearing in a week as opposed to 9 weeks after bone grafting.[5] Cement also works as an adjuvant due to the heat released at polymerization. Additionally, tumor recurrence is easily spotted in cement-filled cavities as a radiolucent defect **(Fig 4B)**.

The benefit of PMMA in reducing local recurrence is still debated. Turcotte et al, in their Canadian

JAYPEE BROTHERS

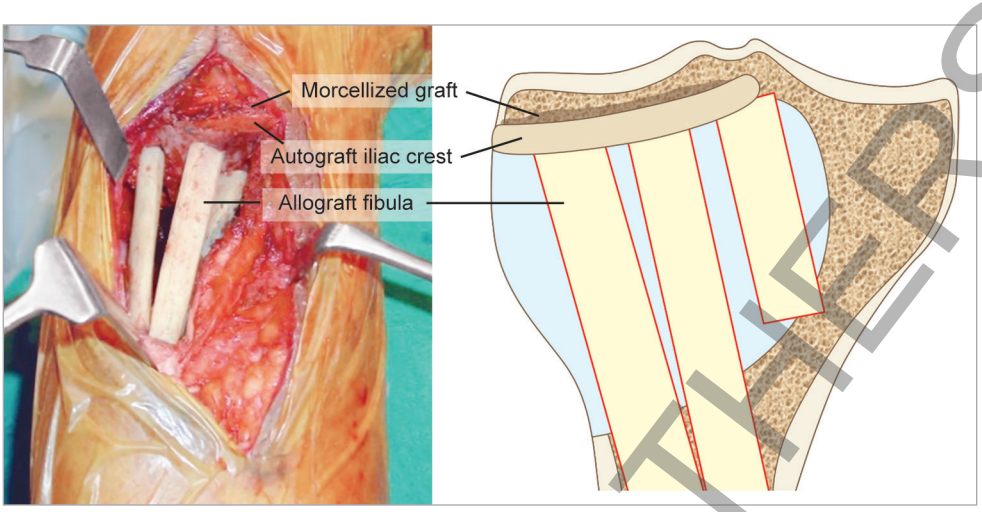

Fig 2: Intraoperative and schematic illustration of the "T" construct. A morcellized graft with an iliac crest flat bicortical piece of graft is used subchondrally, with fibula struts placed longitudinally to support the cavity. The fibula can be an allograft or autograft.

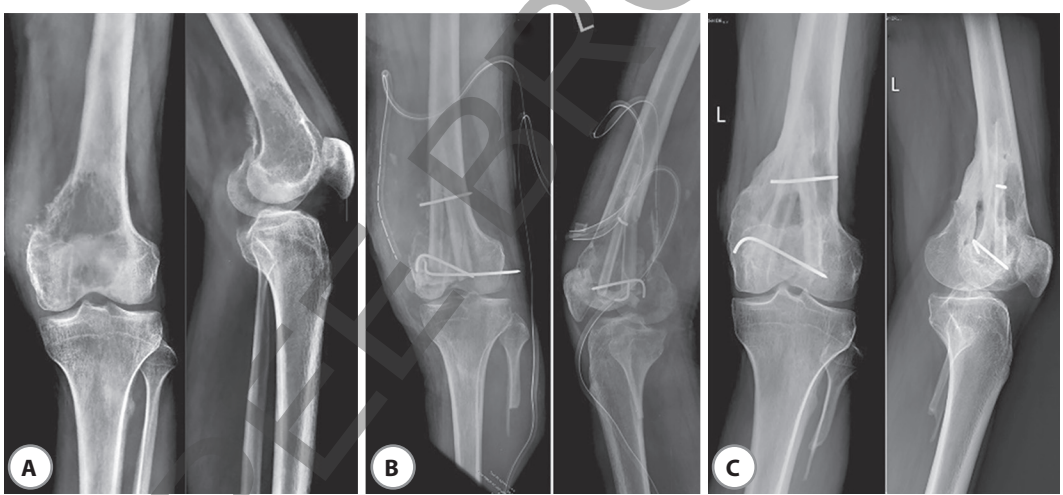

Figs 3A to C: (A) Preoperative radiograph of a patient with GCT in the distal femur showing the large lytic area in the lateral condyle of the femur. (B) Postoperative radiograph showing reconstruction with a "T" construct. Iliac crest bicortical flat graft with some morcellized graft was placed subchondrally, and fibular strut autograft was placed longitudinally. The cavity was not filled. (C) 1-year follow-up radiograph showing the incorporated bone with thickening of the bony walls. The void in the cavity has been filled with bone to a large extent.

Sarcoma group study, did not find any difference in local recurrence between bone grafted and cemented cases.[11] Two systematic reviews of literature that analyzed results of defect reconstruction in several thousand patients could not demonstrate any benefit of cement in reducing local recurrence.[12,5] On the other hand, the Scandinavian Sarcoma study reported by Kivioja et al, and systematic reviews by Vaishya et al, and Zuo et al, found significantly lower local recurrence in PMMA-filled cases compared to bone graft filled cases.[13-15]

JAYPEE PROOFS

Since cement is not strong in torsion, adding Steinman pins or divergent screws to the construct has been advocated **(Figs 5A and B)**. Some cadaveric studies have demonstrated no improvement in biomechanical strength of the construct with the addition of Steinman pins.[16-18] On the other hand, Toy et al, demonstrated that the load to failure in uncontained proximal tibia defects reconstructed with cement was higher when divergent screws were added compared to cement alone or cement with Steinman pins.[19] Irrespective of the above, there is consensus that a locking plate, when added to the construct, will improve the torsional strength and prevent fracture.[5,20]

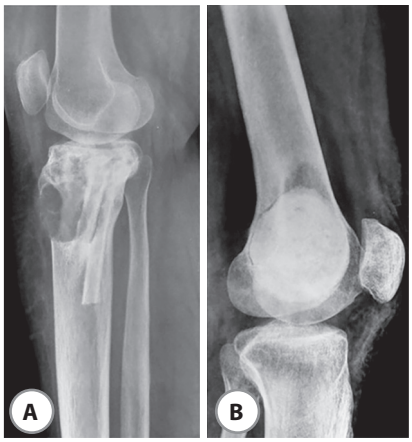

Figs 4A and B: (A) GCT treated with curettage and bone grafting. Note that the recurrence was seen as a large lytic area before it was detected, and (B) Giant cell tumor (GCT) distal femur treated with extended curettage and cementing. This is a 1-year follow-up showing a lucency next to the cement, suggestive of a recurrence. The radiopacity of cement makes it easy to spot this lucency.

We believe that the tumor clearance and use of a high-speed burr are probably more significant in reducing local recurrence rather than the type of material used to fill the cavity. Cement clearly allows early weight bearing and also makes any recurrence easy to spot. We have used cement for these advantages. We do not use Steinman pins or divergent screws with the cement as they make cement removal difficult in case of recurrence. Stainless steel Steinman pins also throw a significant artefact on MRI, making diagnosis of a suspected recurrence difficult. We prefer to use a lateral locking plate if there is a high risk of fracture.

Does Cement Cause Osteoarthritis?

Cement is not the best material directly under the cartilage, as it transmits large forces to the cartilage, which can risk early degeneration of

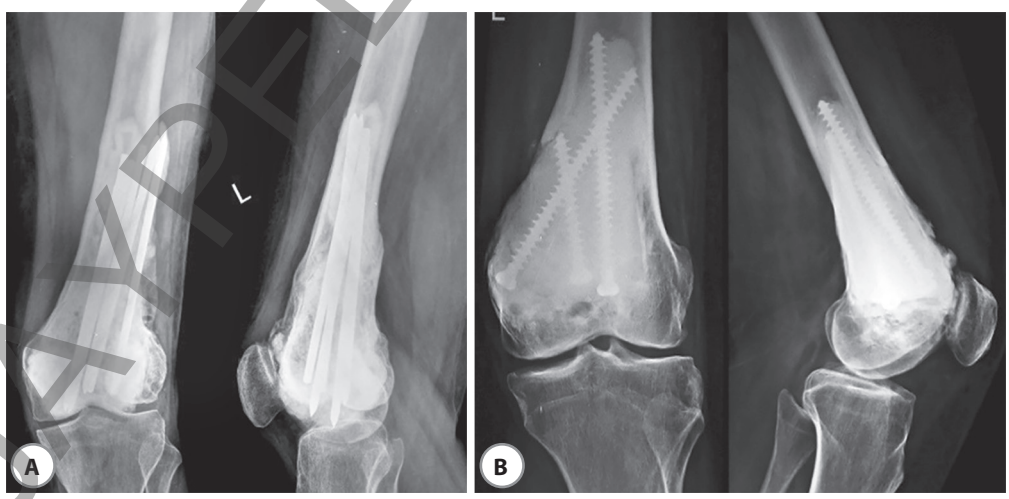

Figs 5A and B: (A) Follow-up X-ray following reconstruction of femoral condyle defect with bone cement and Steinmann pains. (B) Follow-up X-ray following reconstruction with polymethyl methacrylate (PMMA) and divergent screws.

JAYPEE BROTHERS

the joint. Also, heat released during cement curing may injure articular cartilage.[21] So, the big question is whether cement should be used for defect reconstruction in the subarticular area.

Lackman et al, reported that only 1/63 patients developed OA in this scenario, and those with preexisting OA did not have accelerated cartilage wear on follow-up.[22] Ebeid et al, published a minimum 10-year follow-up of 119 patients of GCT treated with extended curettage and cementing alone.[23] Despite cement being placed adjacent to the articular cartilage in almost all their cases, only 21% of their patients developed arthritis (mostly mild), and only 8% developed progression of their OA during follow-up. Even those with radiologically severe arthritis were clinically comfortable, with only one patient requiring knee arthroplasty. Frassica et al, studied the effect of subchondral cement on articular cartilage in dogs.[24] They reported that subchondral stiffness returned to normal in 12 weeks with bone graft, while it recovered to 79% of control with bone cement. They could not demonstrate any adverse effect on cartilage and concluded that subchondral cement is safe. Von Steyern et al, studied nine cases of GCTs around the knee treated with cement within 3.5 mm of cartilage (average 1 mm).[25] They evaluated cartilage damage with delayed gadolinium-enhanced MRI of the cartilage (dGEMRIC) and with biochemical markers like serum cartilage oligomeric matrix protein (COMP). In one patient, there was frank irregularity of the medial condyle but no arthritic changes or functional compromise. In another, there was exposed cement for 15 mm on the femoral condyle with an adjacent tibial cartilage lesion, which remained stable for 10 years and did not compromise function. Although the dGEMRIC study showed some change indicating a glycosaminoglycan loss from cartilage, frank OA developed in only one patient. COMP values were higher, but again, these did not amount to any clinical or radiological evidence of OA. Although their series was small, they could not demonstrate any deleterious effect on the joint, even when little or no space existed between cartilage and cement. In contrast, Tejwani et al, reported two cases of GCT with symptomatic full-thickness cartilage loss following cement exposure.[26] Both cases were treated with arthroscopic surgery. **Figure 6** shows a case where subchondral cement caused

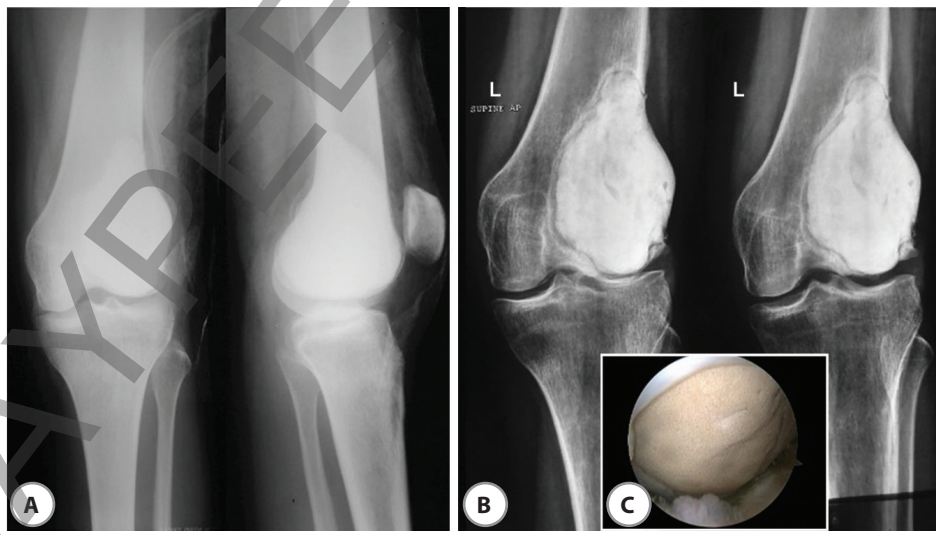

Figs 6A to C: (A) Postoperative radiograph of GCT treated by curettage and cementing. Cement appears next to the cartilage over a large percentage of the subchondral area (B). Two-year follow-up radiograph showing cement protrusion into the joint (C) Arthroscopic picture of the exposed cement in the joint.

JAYPEE BROTHERS

cartilage wear and cement exposure into the joint.

Perhaps, the occurrence of OA after GCT curettage depends on the amount of subchondral bone involved by the tumor rather than whether cement or bone was used to fill the defect. Chen et al, found that the amount of subchondral bone involvement was directly related to the functional score in their series of 28 patients, where bone was used to fill the defect after a curettage.[27] They considered < 3 mm of remaining subchondral bone as subchondral bone involvement and found that for every 10% increase in subchondral bone involvement, there was a 3% reduction of Enneking score in a linear fashion. Xu et al, in a retrospective series of 76 patients with a median follow-up of 35 months, reported a secondary OA rate of 30%, with the incidence being higher when < 10 mm of subchondral bone remained. The incidence of OA in the study population was significantly higher than that seen in their 35-44 year old population.[28] They also found that subchondral bone grafting significantly reduced the incidence of OA from 56.5–29.4%. Though the incidence of OA was high, most cases were mild and not clinically significant. Heijden et al, in their series of 53 patients treated with extended curettage and cementing, analyzed the thickness of subchondral bone and the area of affected subchondral bone to determine their effect on the development of future OA.[29] They reported that the risks of OA were much higher when > 70% of the subchondral bone area was involved compared to < 3 mm subchondral bone remaining.

Bayram et al, recently conducted a systematic review of literature to specifically determine if extended curettage combined with the PMMA technique for the treatment of aggressive bone tumors around the knee led to the development of knee OA.[30] They reported that 61 of 204 (30%) patients developed knee OA. Although this was statistically significant, there were several shortcomings in the papers they considered for the analysis, including the absence of data regarding the distance of the tumor from the articular cartilage or even the body mass index. Both of these could affect the development of OA. At the moment, we do not have any firm evidence that the use of cement will cause or accelerate OA.

The "Sandwich" Reconstruction

Considering the amount of debate on the safety of hard cement directly under the articular cartilage, a logical approach is to build the subchondral area with bone and fill the rest of the cavity with cement. We have been advocates of this "sandwich" reconstruction.[1,9,10,31-33] Our cavities after curettage have generally been of large volume, which would be difficult to fill with autograft alone. We build the subchondral area with the limited amount of available bone and fill the rest of the cavity with cement **(Figs 7A to D)**. Initially, we used to place a layer of Gel foam to prevent cement from mixing with bone.[9] But, now we agree with ElDsouqi et al, that this is not necessary.[34] We use morcellized autograft, morcellized allograft, a combination of the two, or combine morcellized allograft with bone marrow to improve osteoinductive capability. In some cases, we found resorption of allograft bone with articular collapse. So we now use the iliac crest bicortical strut with a small amount of morcellized graft in the subchondral area.[33] In the femoral condyle, we have sometimes used a block femoral head to match the condyle curvature.

Saibaba et al, reported on 36 patients treated with their sandwich consisting of a 5–8 mm thick strut allograft placed subchondrally, a piece of gel foam placed below that, and cement filling up the rest of the cavity.[35] 4 mg of intravenous zoledronic acid was administered postoperatively every month for a total of 6 months. They reported only one recurrence and good Musculoskeletal Tumor Society (MSTS) scores at an average follow-up of 5 years. Kundu et al, too, reported good MSTS scores in 26 patients using morcellized autograft in the subchondral area, but had

JAYPEE BROTHERS

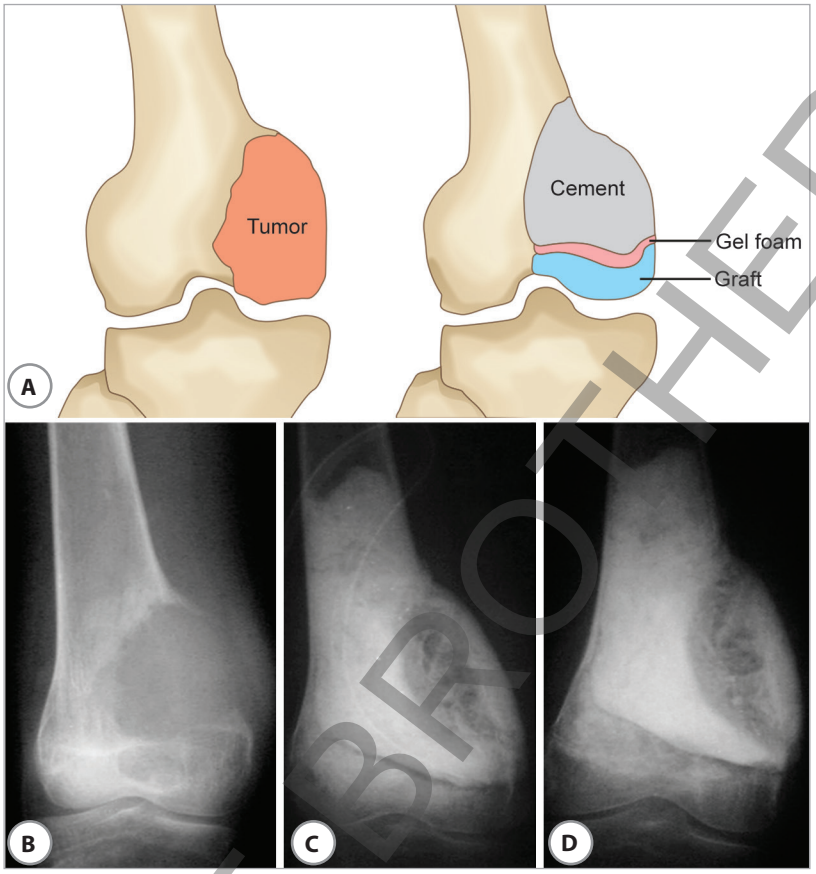

Figs 7A to D: Sandwich reconstruction. (A) Diagrammatic concept. Note that a layer of gel foam is interposed between the bone graft and the cement. We now know that this is not necessary. (B) Preoperative radiograph showing the subarticular tumor in the distal femur confirmed as GCT on a biopsy. (C) Postoperative radiograph showing the "sandwich" reconstruction. Gel foam was interposed between bone and cement, and (D) Radiograph at 1-year follow-up showing good consolidation of the subchondral bone graft.

three recurrences in their series.[36] Both these studies did not look specifically at periarticular fractures or degenerative changes in the cartilage. The real questions with "sandwich" reconstruction are: (1) Does subchondral bone grafting delay or prevent cartilage degeneration, which is attributed to subchondral cement? (2) Does it have a negative impact on local disease control? Benevenia et al, compared two similar groups of GCTs, one treated with "sandwich" reconstruction using strut allograft subchondrally, and the other treated with cement only.[37] They reported significantly lower periarticular fractures and degenerative changes in the articular cartilage with the sandwich technique, with no increase in local recurrence rates. Though the numbers are small in this nonrandomized study, it offers a good insight into possible benefits with the "Sandwich" reconstruction.

Ward and Li recommended a customized approach to reconstruction.[7] Wherever more than 25% of the articular surface is unsupported, they recommend subchondral bone grafting before cementing. Internal fixation was recommended if the cross-sectional area of cement exceeded 50% of the bone in any one view. For extensive articular compromise, which

JAYPEE BROTHERS

they arbitrarily defined as a loss of > 50% of the supporting cortex of the entire bone, massive allograft reconstruction was recommended with the aim of restoring the bone stock should a future arthroplasty be required for the degenerative changes.

On similar lines, our policy has been to use sandwich reconstruction whenever there is < 2 mm of subchondral bone. We use strut autograft iliac crest as described above, and do not use gel foam anymore. As stated previously, instead of adding Steinman pins or screws into the cement, we prefer to use a lateral locking plate if we anticipate a high risk of fracture as when more than a third of the bony circumference is compromised. For younger patients, we have preferred to use the "T construct" as described, using autograft or allograft depending on availability. We have kept these patients on toe touch weight bearing for 3 months, followed by a gradual shift to full weight bearing.

Synthetic Bone Graft Substitutes

Calcium sulfate, also known as gypsum or plaster of Paris, is known to be a biocompatible and resorbable bone defect filler. It can be mixed with drugs like antibiotics, which get released slowly with the resorption of the calcium sulfate. As an injectable paste, calcium sulfate use has been reported for filling cavities after benign tumor curettage with successful outcomes.[38,39] Its use in GCT curettage defects has not gained wide acceptance. The large cavity volume, coupled with early resorption, has probably been a deterrent. Yongkun et al, found no difference in outcomes between calcium sulfate and allograft.[40] Early resorption, before formation of fresh bone, was noted in a few cases. Though resorbable, calcium sulfate is neither osteoinductive nor osteoconductive. Additionally, its ability to provide compressive or torsional strength is doubtful. They are best used for small cavities and may not be suitable for the typical GCT curettage defects.[41]

Calcium phosphate cement (CPC) has longer resorption times and some compressive strength, making it somewhat better than calcium sulfate. There are various formulations of the CPC that change the handling time and setting time.[42,43] Unlike with PMMA, the setting is isothermic and therefore does not endanger the articular cartilage even when placed in close proximity. The compressive strength increases over a week as HA crystallizes. Welch et al, showed that CPC in the subchondral area maintained strength even as resorption of cement and replacement with bone happened over time.[44] This is an advantage when compared to autograft, which loses strength in the first 6 weeks. Takeuchi et al, reported excellent functional outcomes with bone formation around the cement mass in 26 patients of GCT treated with phenol and CPC.[43] The radioopacity persisted for many years after surgery. The isothermic setting of CPC cement prevents thermal cartilage damage, but does this really translate into reduced knee OA? Araki et al, reported on 19 patients of GCT whose postcurettage defects were filled with CPC.[45] At a median follow-up of 131 months, they report OA in 26% of their patients, with two requiring surgical intervention. This is similar to rates reported with PMMA. Though they calculated the surface area of subchondral bone loss, the numbers are too small to deduce any correlation with OA.

Calcium sulfate is known to be absorbed faster than the rate at which bone can form, creating a potential risk for fracture. Calcium phosphate has better load-bearing properties than calcium sulfate, but it takes a long time to be absorbed. Beta TCP creates a porous scaffold for osteoconductive properties. These three materials have been combined together to give a bone graft substitute that has osteoconductive properties and stays for an adequate time before resorption. Gyemi et al, recently reported on outcomes in 39 patients (19 GCT) with PRODENSE (Wright Medical Corporation), which is a fully synthetic bone substitute

JAYPEE BROTHERS

that is a composite calcium sulfate-calcium phosphate ($CaSO_4/CaPO_4$) matrix mixed with beta-tricalcium phosphate (β-TCP) granules.[46] No additional fixation was used. They reported 11 weeks as the time to full weight bearing. They did not experience any complications related to the material, and good radiological incorporation was seen in all their patients. Similar good radiological outcomes have been reported with CERAMENT (Bonesupport, Sweden), another injectable cement containing calcium phosphate and calcium sulfate.[47,48] However, Zrodowsky et al, found a high incidence of seroma discharge from wounds, which settled without needing reoperation.

Bone graft substitutes are an attractive option to fill curettage defects as they offer the functionality of bone, without donor site morbidity of autografts, or risk of infection or disease transmission associated with allograft. They can be used everywhere in any quantity, as tissue banks are not needed. The cement-like setting property allows it to take the shape of the cavity without any voids, and the isothermic setting keeps the cartilage safe even when used in the subchondral area. Drawbacks include their inability to provide the structural strength of strut allografts or autografts. Also, they can be very expensive if large volumes are required. Their resorption rates are not always predictable, and delayed resorption is common. We have used calcium sulfate in one of our patients and had to wash the wound for copious serous discharge and toothpaste-like extrusion of the grafted material. We have used Cerament in one of our cases with a good outcome, but we have no more experience with bone substitutes.

Conclusion

Giant cell tumors are the commonest surgically treated benign bone tumors in India.

Most patients are treated with intralesional surgery, which involves an extended curettage, with/without the use of thermal, chemical, and physical adjuvants. This leaves behind a characteristic subarticular void which requires to be filled, with due consideration being given to the amount of subchondral bone loss, cortical wall defect, and volume of the cavity. Barring very small and well-contained defects that leave > 5 mm subchondral bone, these cavities should be filled with bone graft, bone substitutes, or bone cement, or a combination of these.

Morcellized autograft can be easily used subchondrally, but may not be available in sufficient quantity for a large defect. Autograft fibula struts can be used for complete autograft reconstruction, as the entire cavity does not need to be filled. Alternatively, an allograft, if available, can give very good outcomes. Bone has the advantage of remodeling along lines of force. Additionally, revision surgery for recurrence or arthroplasty for degenerative OA is easier with bone graft reconstruction than with bone cement. However, a period of 3–6 months of protected or partial weight bearing may be required.

Bone cement is readily available. It can mold to the shape of the cavity and also has very good compressive strength, allowing early weight bearing. It also acts as an adjuvant and may help in reducing local recurrence. Its opacity makes any lucency from a recurrence easy to spot on a plain radiograph. There have been concerns about placing cement immediately under the articular cartilage because of its hardness and because of its heat necrosis causing potential. In patients with < 2 mm of residual subchondral bone after curettage, it would be best to use subchondral bone graft or bone substitute for 3–5 mm and then bone cement for the rest of the cavity volume as a "sandwich" reconstruction. **Figures 8A to C** shows the algorithm used by us. The risk of OA with cement is probably exaggerated if some subchondral bone is present. It is likely related to the patient's weight and amount of subchondral bone loss, irrespective of what filling material was used.

Bone graft substitutes are very attractive as they provide all the advantages of bone grafting without any donor site morbidity or need for tissue banks or the thermal necrosis of

JAYPEE BROTHERS