l emergency medicine books, visit our website www.jaypeebrothers.com, for detailed information on intensive care and emergency medicine books

Complimentary Online 34 Videos

Echocardiography
Practical Pocket Guide
for Intensivists and Emergency Medicine Physicians
A Quick Learning Initiative



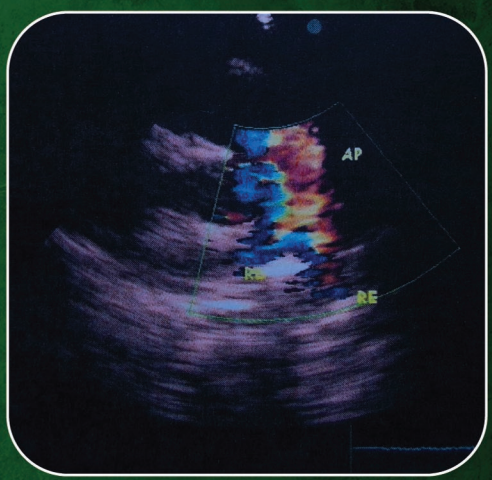

Editors
Puneet Khanna
Gourav Mittal

JAYPEE

Contents

1. **Indications of TTE and TEE in ICU. What is the need to go beyond POCUS to Critical Care Echocardiography? How is Critical Care Echocardiography Different from Cardiologist Echocardiography? 1**
   Mukkelli Vinay Gandhi, Puneet Khanna
2. **Physics in Echocardiography 8**
   Bhavana Kayarat, Puneet Khanna
3. **Basics Including Terminology and Settings 21**
   Gourav Mittal
4. **Artifacts in Echocardiography: Implications for Operating Rooms and Critical Care Units 30**
   Amit Kumar Malviya, Vinay Kumar
5. **Basic Echo Views, Their Strengths, and Shortcomings 37**
   Gourav Mittal, Puneet Khanna
6. **Eyeballing and Gross Estimation of Cardiac Functions 42**
   Gourav Mittal, Puneet Khanna
7. **Left Ventricle Systolic Function and Cardiac Output Estimation: Approach and Clinical Application 46**
   Gourav Mittal, Puneet Khanna
8. **Left Ventricular Diastolic Function 56**
   Gourav Mittal, Puneet Khanna
9. **Right Ventricle Function and Pulmonary Arterial Hypertension 65**
   Gourav Mittal, Puneet Khanna
10. **Clinically Relevant Stenotic Lesion (Mitral and Aortic) Algorithm Along with Step-By-Step Approach 88**
    Gourav Mittal, Puneet Khanna
11. **Clinically Relevant Regurgitant Lesion (Mitral, Aortic, and Tricuspid) 97**
    Gourav Mittal
12. **Prosthetic Valves 107**
    Gourav Mittal, Puneet Khanna
13. **Pericardial Disease (Effusion, Tamponade, and Tamponade Physiology) 112**
    Gourav Mittal
14. **Myocardial Infraction: Various Scenarios and Troubleshooting 120**
    Gourav Mittal

15. Infective Endocarditis 126
Gourav Mittal

16. Pulmonary Embolism and Deep Vein Thrombosis 132
Gourav Mittal, Puneet Khanna

17. Cardiomyopathies 137
Gourav Mittal, Puneet Khanna

18. Echocardiography for Aorta: Differentiation between Dissection and Disruption 145
Gourav Mittal, Puneet Khanna

19. Arrhythmias and Echocardiography: How can We Integrate Electrical and Imaging Together? 151
Puneet Khanna, Gourav Mittal

20. Emergency Intraoperative and Postoperative Echocardiography 155
Richa Saroa, Sanjeev Palta, Avneet Singh

21. Echocardiography in Complications of Percutaneous Interventions 163
Kandaswamy N

22. Fluid for Critically Ill Responsiveness, Tolerance and Removal: Echocardiography Integrated Approach 168
Gourav Mittal, Puneet Khanna

23. Echocardiography in Critically Ill Children 175
Aravindhan Manoharan, Rakesh Lodha

24. Recent Advances: Role of Artificial Intelligence in Critical Care Echocardiography 186
Balaji Rajaram

25. Echocardiography in Cardiac Arrest 193
Nitin Rai

26. Echocardiography in Transplanted Heart 201
Meera Rajeev, Sarvesh Pal Singh

27. Role of Echocardiography in Liver/Renal/Lung Transplantation 208
Kulbhushan Saini, Arshdeep Singh, Ajay Singh

28. Optimizing Patient Outcomes in ECMO Therapy: The Role of Echocardiography 216
Velmurugan Selvam, Shrikanth Srinivasan

29. Comprehensive Echocardiography in Management of Trauma 225
Kapil Dev Soni

30. Echocardiography in Neurocritical Care 231
Kiran Jangra, Gyaninder Pal Singh

31. Training and Competency in Intensive Care Unit Echocardiography 237
Mohd. Luqman, Srikant Behera

32. Flowchart of Echo Approach in Shock Differentiation, Acute Dyspnea, Acute Chest Pain, and Deresuscitation 244
Anant Vikram Pachisa

33. Advanced Echocardiography in Intensive Care Unit: Expanding Horizons 248
Gourav Mittal, Puneet Khanna

34. Transesophageal Echocardiography in the Intensive Care Unit 257
Meera Rajeev, Sarvesh Pal Singh

35. Self Assessment in Critical Care Echocardiography 273
Rakupathy S, Gourav Mittal, Puneet Khanna

Index 311

CHAPTER 8

Left Ventricular Diastolic Function

Gourav Mittal, Puneet Khanna

JAYPEE BROTHERS

INTRODUCTION

Diastolic dysfunction is the inability of the ventricle to fill to its normal end diastolic volume without an inappropriate increase in end diastolic pressure.

BRIEF DISCUSSION

Causes of left ventricular (LV) diastolic dysfunction:

- Elderly age
- Diabetic patient
- Patient with metabolic syndrome
- Hypertensive patient
- Patient with ventricular hypertrophy
- Aortic stenosis
- Restrictive heart disease

PHASES OF DIASTOLE

- *Isovolumetric relaxation:*
  - *Aortic valve (AV) closure [prior to mitral valve (MV) opening]*
- *Early rapid ventricular filling:* E wave
  - *MV opens—majority of LV preload*
- *Mesodiastolic phase/diastasis:*
  - *Low flow*
- *Arterial contraction: A wave*
  - *Contribute 20% of preload*

The heart is a variable-volume pump inserted into a system of elastic tubes with one-way valves, filled with blood. So, the pump function is not only related to the systolic squeeze, but it also depends on the degree of relaxation of the heart chambers, which creates the reserve volume required for an effective ejection. Assessment of cardiac relaxation is an important part of critical care. With echocardiography, we can evaluate diastolic function rapidly and noninvasively. A simplified method looking at the mitral valve inflow with pulse wave Doppler (PWD) and tissue Doppler imaging (TDI) is used by most intensivists.

Diastole is an active energy requiring process. It is not a passive filling of the heart. The ventricle relaxes, untwists, and rapidly descends pulling in blood. With age and in critical illness, the ventricle stiffens. Impaired relaxation causes increased atrial pressure and decreased ventricular filling. High venous pressure is needed to fill a stiff atria and ventricle. This results in venous congestion and low stroke volume, placing patient at risk for both pulmonary edema and hypoperfusion. Diastolic dysfunction is a normal part aging. It is found in patients with a low LV ejection fraction (EF). But it can also exist in patients with normal systolic function. Diastolic function is not improved and may be worsened with alpha and beta agonists like norepinephrine, epinephrine, and dobutamine.

Left ventricular diastolic function is assessed with PWD through the MV and TDI at the mitral valve (MV) annulus. PWD measures velocity of blood flow through the valve into LV during diastolic filling. TDI measures how rapidly the ventricle muscle itself is moving down to allow filling. TDI can be assessed at either the lateral or medial aspect of the MV annulus, but most commonly at the lateral annulus. In general, E/e′ is the most reliable metric parameter.

Things measured in echo to grade DD:
- *E/A ratio*
- *E/e'*
- *LA volume indexes*
- *TR jet velocity*

Other things to complement these parameters are IVRT, DT, and pulmonary venous flow velocities.

ECHO views—formation and pitfalls

Way to assess:
- *View needed:* A4C
- *Pulsed wave Doppler (PWD) via mitral valve:* E and A
  - Place the pulse wave Doppler cursor through the MV.
  - Set the marker within the tip MV leaflets.
  - Identify the E wave and the A wave above the baseline.

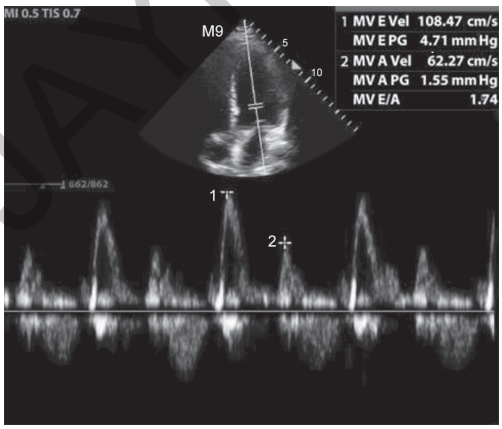

Parameters of interest:
- *E peak velocity*
- *E wave deceleration time*
- *A peak velocity*
- *E/A ratio*
  - E wave represents early diastolic filling and A wave atrial contribution to the left ventricular preload.
  - There is a period of diastasis in between E and A waves.
  - With the envelope, thus obtained, isovolumic relaxation time (IVRT), E and A wave velocities, and E/A ratio can be measured.
  - The normal E wave velocity is 0.8 ± 0.2 m/s and A wave velocity is 0.5 ± 0.2 m/s.

ECG correlation of waves:
- The E wave occurs between the T wave and the QRS.
- The A wave occurs just before or on the QRS.
- *In atrial fibrillation there is no A wave, only the E wave is present.*
- *Measure the peak velocity of the E wave and the A wave.*

Pitfalls:
- L wave during diastasis
- E/A >2—supernormal filling in young people d/t powerful LV suction
- E/A ratio in the presence of AF, MR, mitral annular calcification, left bundle branch block (LBBB), paced rhythm or MS or MVR.
- In these situations, other parameters become helpful.
- Increased LA volume index can also be found physiologically in well-trained athletes with bradycardia.

Tissue Doppler at the lateral mitral:
Valve annulus: e′ and a′
- Select tissue Doppler imaging.

JAYPEE BROTHERS

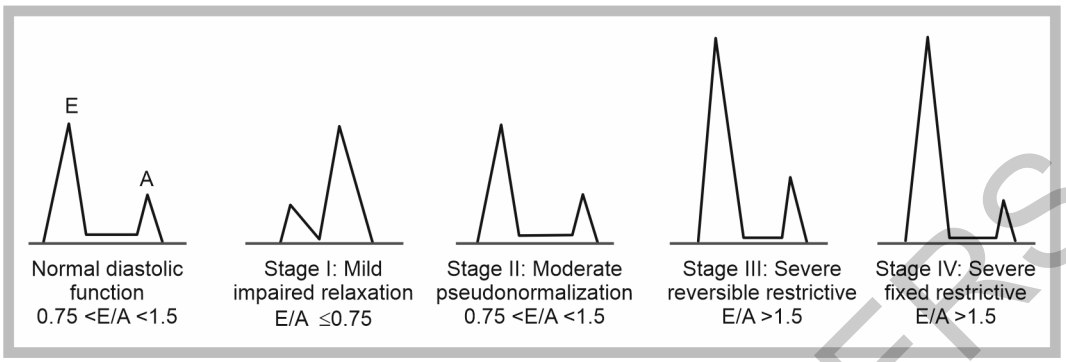

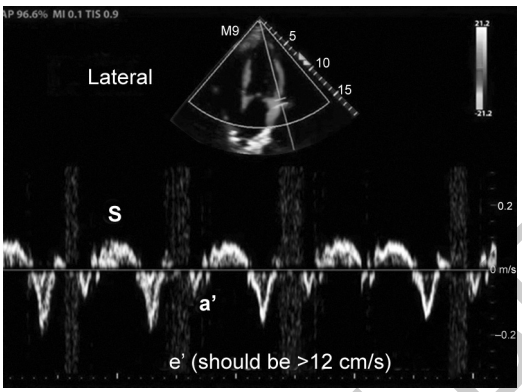

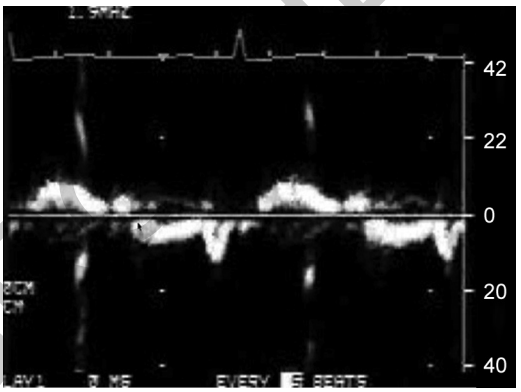

- Place the cursor through the lateral annulus of the mitral valve.
- Set the marker in the thickest part of the annulus.
- Obtain the TDI waveform, save the image
- Identify the e′ wave and the a′ wave.
- *E/e′ Ratio:* Reflects left ventricular end-diastolic pressure (LVEDP)
- *Normally <8:* Elevated >15
- TDI a lateral e′ <10 cm/s and septal <7 cm/s is suggestive of diastolic dysfunction.
- The ratio of E/e′ <8 is normal and a ratio >15 is associated with LV diastolic dysfunction in nonventilated patients.
- A ratio of >12 is sufficient to identify diastolic dysfunction in patients on mechanical ventilation

ECG correlation:
The a′ wave occurs right before the QRS.
Measure the e′ peak, save the measurement.

- Echo assessment of diastolic function is based on the interpretation of a constellation of echo and Doppler measurements.
- No single echo parameter provides a definitive or summary measure of the ventricular PV relationship during diastole.
- If any parameters are abnormal—only reflect isolated changes in relaxation or compliance.
- They are affected by the complex interaction between changes in LV relaxation, LV compliance, LAP, and LA contractility, further complicated by rhythm and loading conditions.

JAYPEE BROTHERS

	Optimization of measurements
1	Obtain a true apical four-chamber view of the heart that excludes the aortic valve
2	Reduce the angle between the ultrasound beam and blood flow (visualized with color Doppler mapping) as much as possible (<20°): • *Mitral inflow:* Translate the transducer from the true apical four-chamber view to a slightly more lateral position
3	*Use a small pulsed-wave Doppler sample volume:* • *Mitral inflow:* 1–2 mm
4	*Place the sample volume adequately:* • *Mitral inflow:* Between the tips of the mitral leaflets
5	• Use a sweep speed of 50 mm/s (appreciation of the influence of the respiratory cycle on Doppler velocities) or 100 mm/s (measurement of flow duration or deceleration time) • Use ECG and respiratory tracings, especially in ventilated patients • Set velocity filter as low as possible (200–600 Hz)
6	Perform all measurements at end expiration (or during apnea) to limit the effects of heart–lung interactions on Doppler velocities

Suspected left ventricular diastolic dysfunction (LVDD):

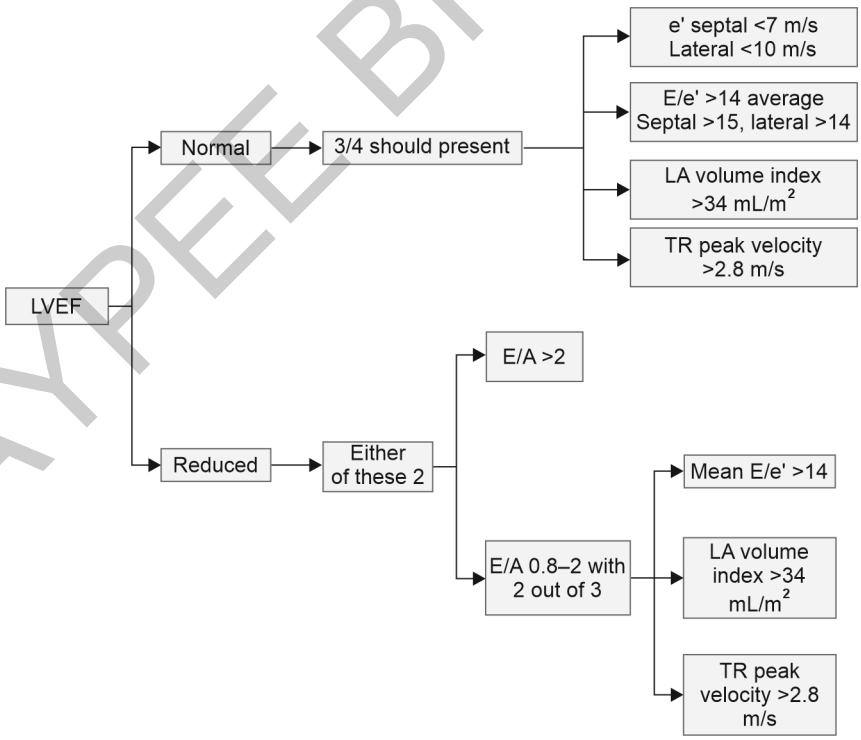

(LVEF: left ventricular ejection fraction)

JAYPEE BROTHERS

Difficult to assess LV volume and TR jet simplified approach as described below:

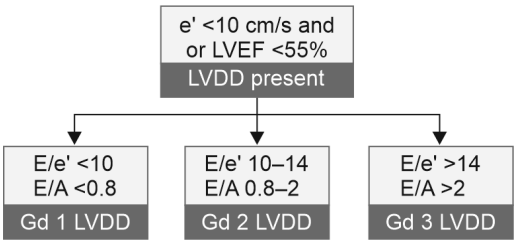

(LVDD: left ventricular diastolic dysfunction; LVEF: left ventricular ejection fraction)

1. Sometimes see E < A in under filled, hyper dynamic hearts
   - *If this is the case, the LV appears under filled, high EF, and e >> 10 cm/s*

For physiological aspect understand as physiology level:

	Normal	***Grade 1***	***Grade 2***	***Grade 3***
LV relaxation	Normal	Impaired	Impaired	Impaired
Left atrial pressure	Normal	Low or normal	Elevated	Elevated
Compliance	Normal	Normal	Reduced	Severely reduced

CASE VIGNETTE 1

A 56-year-old female, known case of hypertension not complaint to medication presented with worsening of shortness of breath and headache. On examination, bilateral lung showed crepitation along with bilateral pitting pedal edema. Peripheries are warm and denied any history of fever, cough, and burning micturition. Vital showed BP of 220/120 mm Hg both arms. As acute care physician started basic resuscitation. How 2D ECHO and lung USG help you to determine diagnosis and guide management?

Differentials:

- Acute pulmonary edema? Accelerated hypertension-induced heart failure with preserved ejection fraction (HfPEF), Sympathetic Crashing Acute Pulmonary Edema (SCAPE)
- Community-acquired pneumonia with heart failure
- Fluid overload secondary to underlying undiagnosed renal dysfunction.

Acute management if underlying diagnosis is SCAPE or accelerated hypertension, acute care can stabilize patient early and can prevent intubation and subsequent mechanical ventilation.

Relying on history no fever and localizing sign puts infective etiology on backseat, no renal dysfunction and fluid administration also puts fluid overload secondary to renal last D/D.

Having acute pulmonary edema in vision, we can perform echo and lung USG to confirm our diagnosis and guide our management.

Sympathetic Crashing Acute Pulmonary Edema (SCAPE) occurs due to a *vicious spiral* involving increasing sympathetic outflow, excessive afterload, and progressively worsening heart failure. Since SCAPE is a vicious spiral, this may develop very rapidly

JAYPEE BROTHERS

(hence the terminology "flash pulmonary edema"). With aggressive therapy, it may *resolve* very rapidly as well.

The central, defining pathophysiological feature of SCAPE is pathologically elevated afterload due to systemic vasoconstriction and hypertension.

SCAPE patients may be euvolemic or hypovolemic. The problem is a *shift* of fluid into the lungs, rather than hypervolemia.

Three stages of progression are:

1. *Stage 1:* Distension of small pulmonary capillaries due to increased left atrial pressure
2. *Stage 2:* Interstitial edema
3. *Stage 3:* Flooding of alveolar space causing hypoxia

ECHO:
Views:
For assessing LV diastolic dysfunction and LA filling pressure:

- A4C LV focused
- Perform systolic function and diastolic function
- Inferior vena cava (IVC) screening for size and variability

Lung USG: ≥1 zone with ≥3 B-lines (one positive zone) on each hemithorax

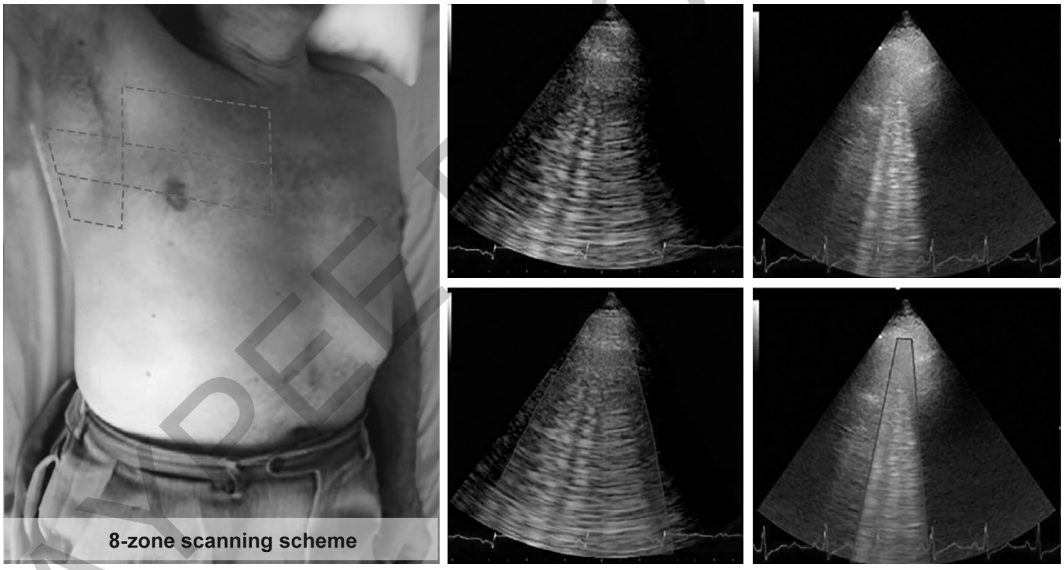

JAYPEE BROTHERS

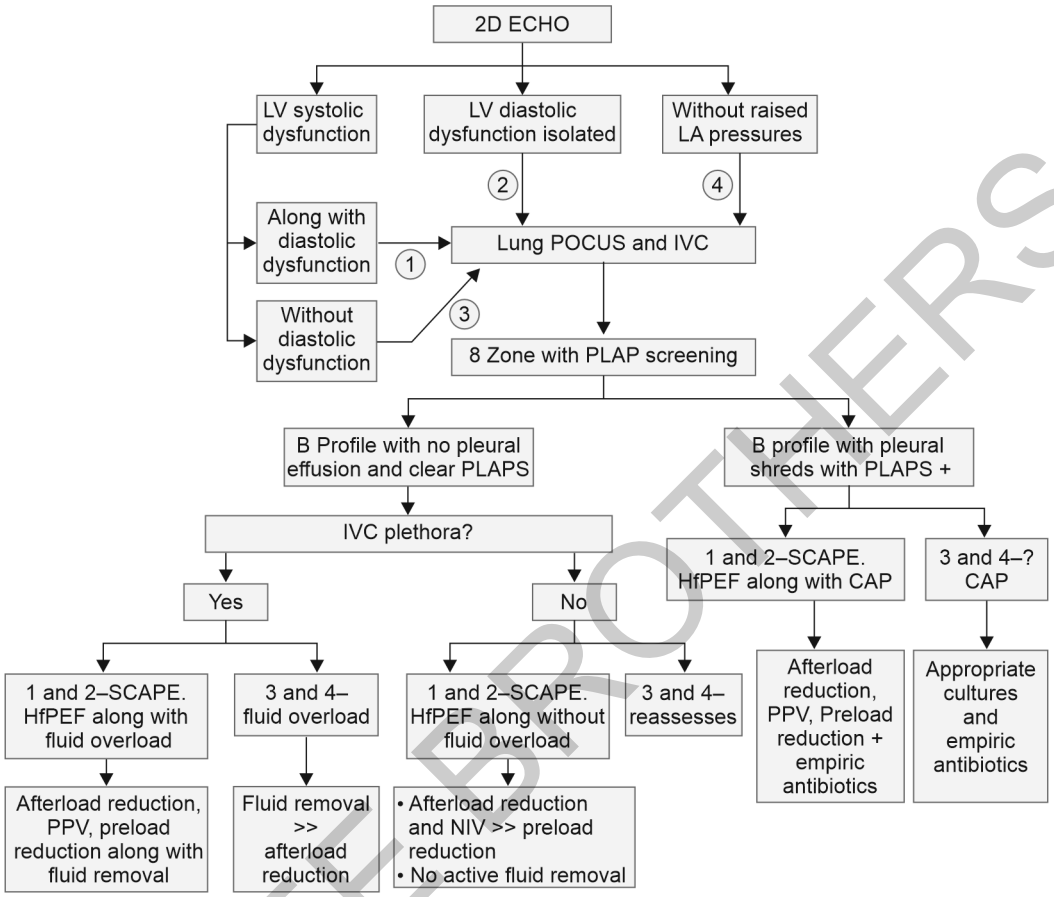

(HfPEF: heart failure with preserved ejection fraction; SCAPE: sympathetic crashing acute pulmonary edema; PLAPS: posterolateral alveolar and/or pleural syndrome; LA: left atrium; LV: left ventricle)

CASE VIGNETTE 2

A 33-year-old male with known case of long-standing hypertension received positive pressure ventilation for 7 days in view of viral pneumonia and acute respiratory distress syndrome (ARDS). Baseline cardiac functions were normal except presence of LV hypertrophy. After resolution of primary condition you attempted weaning, but he failed 2 SBT trials, work of breathing increased and oxygenation worsens as spontaneous breathing trial attempted. History of long-standing hypertension, grossly positive cumulative positive fluid balance along with gross edematous appearance you suspected weaning induced cardiac dysfunction. How echo will help you to reach diagnosis?

Answer:

First we briefly discussed pathophysiology of weaning-induced cardiac failure.

JAYPEE BROTHERS

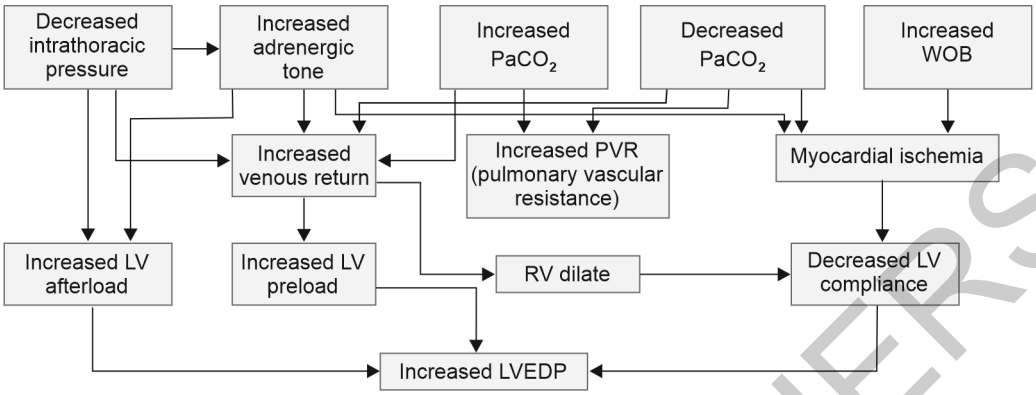

(LVEDP: left ventricular end-diastolic pressure; $PaCO_2$: partial pressure of arterial carbon dioxide; PaO_2: arterial oxygen pressure)

View required: Similar to previous case

Diagnostic accuracy of 2D ECHO for identifying weaning-induced cardiac dysfunction—E/e' before SBT >12.5 and >14.5 after SBT have sensitivity of 75% and specificity of 95.8% both increase if clubbed with increased in brain natriuretic peptide (BNP)/pro-BNP >12% after SBT and lung USG (B profile in nondependent area after SBT)

Q1. How POCUS helps you to manage this case once diagnosis of weaning-induced cardiac dysfunction becomes certain?

CHEOPS bundle is helpful in managing diastolic dysfunction in ICU.

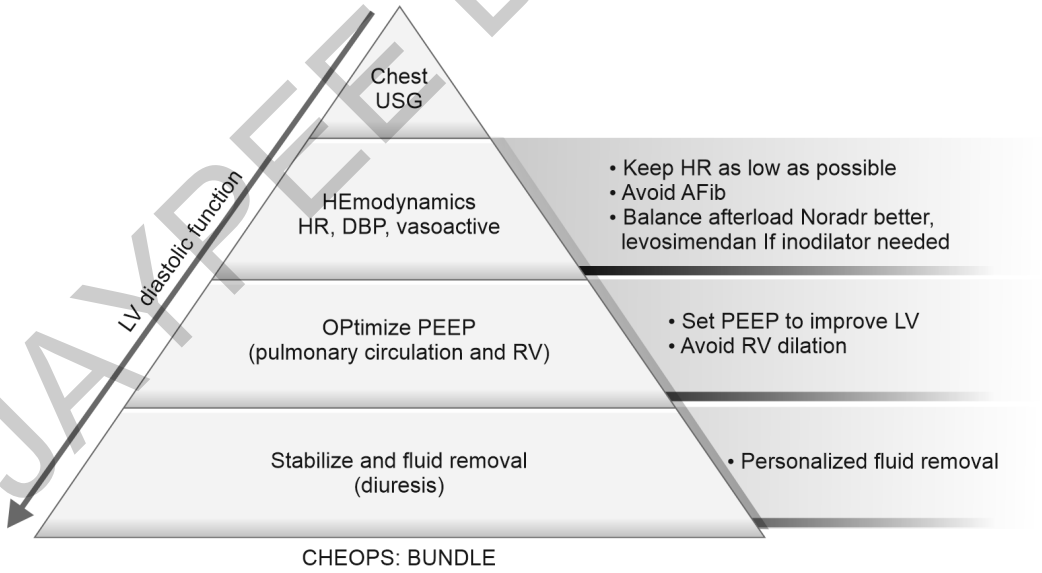

(HR: heart rate; DBP: diastolic blood pressure; PEEP: positive end expiratory pressure)

JAYPEE BROTHERS

Q2. Any proposed algorithm for personalized fluid removal?

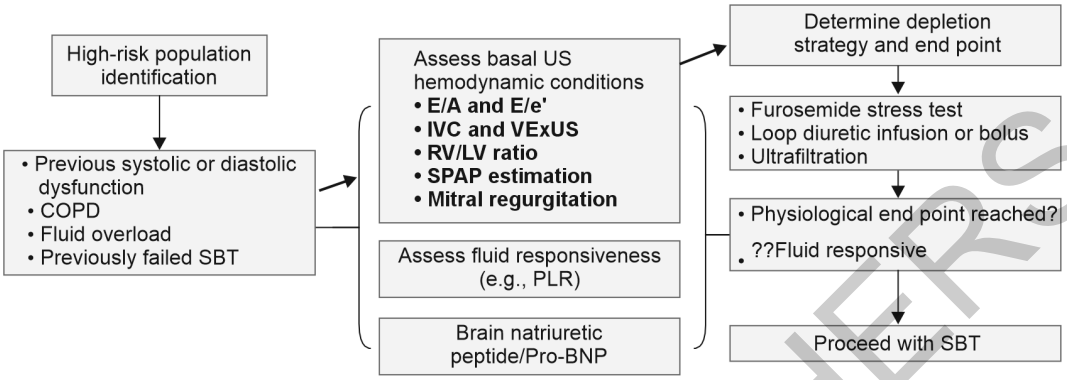

(BNP: brain natriuretic peptide; COPD: chronic obstructive pulmonary disease)

Points to remember:

- Diastole is an active energy requiring process. It is not a passive filling of the heart.
- With echocardiography, we can evaluate diastolic function rapidly and non-invasively. A simplified method looking at the mitral valve inflow with pulse wave Doppler (PWD) and tissue Doppler imaging (TDI) is used by most intensivists.
- E/e′ is the most reliable metric parameter.
- Suspect in elderly, diabetic, hypertensive patients.
- One important modifiable factor in weaning failure, always screen for before attempting weaning and look for if weaning failure happened comparing to before weaning E/e'.

	E–A Ratio	e' (cm/sec)	E/e'
Normal	E>A	>8	<8
Imparied	A>E (2:1)		<8
Pseudo-normal	E>A	<8	8–15
Restrictive	E>>A (3:1)	<8	>15

JAYPEE BROTHERS

for detailed information on intensive care and emergency medicine books, visit our website www.jaypeebrothers.com, for detailed information on in

Echocardiography Practical Pocket Guide

for Intensivists and Emergency Medicine Physicians: A Quick Learning Initiative

For intensivists, emergency physicians, and other healthcare professionals working in the intensive care unit (ICU), the integration of ultrasound into daily practice is no longer a luxury—it is a necessity. The quick, noninvasive imaging provided by ultrasound enables real-time, bedside assessments of critically ill patients, allowing for rapid diagnoses and prompt interventions.

The book also features a QR code linking to short videos and additional resources for residents seeking more in-depth explanations or demonstrations. By scanning the QR code, residents can quickly access these resources, allowing them to reinforce their theoretical knowledge.

Puneet Khanna MD is an Additional Professor, Department of Anesthesiology, Pain Medicine and Critical Care, All India Institute of Medical Sciences (AIIMS), New Delhi, India. He did his MD and Senior Residency from AIIMS, New Delhi and after a brief stint as an Assistant Professor at the Postgraduate Institute of Medical Education and Research (PGIMER), Chandigarh, he came back to his alma mater. He is extremely passionate about his work and has a keen interest in academics and research. He has close to a two-hundred publications in both national and international journals to his credit.

Gourav Mittal DM (Critical Care Medicine) is an Associate Consultant, Max Super Specialty Hospital, Noida, Uttar Pradesh, India. He completed his DM from AIIMS, New Delhi, and earned his MD with a bronze medal from PGIMER, Chandigarh. A certified Intensivist, he specializes in transthoracic and transesophageal echocardiography (TTE and TEE), integrating bedside echocardiography and point-of-care ultrasound (POCUS) into clinical practice for real-time diagnosis and management of critically ill patients.

He is skilled in advanced hemodynamic monitoring and tailored ventilator strategies, focusing on optimizing cardiovascular management and improving patient outcomes in the intensive care unit (ICU). Passionate about innovation, he explores the combination of traditional practices such as Ayurveda and music therapy with modern medical technologies, offering an integrative approach to patient care. He has also authored numerous book chapters in critical care, contributing to knowledge transfer in his field.

Printed in India

Available at all medical bookstores or buy online at www.ejaypee.com

JAYPEE BROTHERS
Medical Publishers (P) Ltd.
EMCA House, 23/23-B, Ansari Road,
Daryaganj, New Delhi - 110 002, INDIA
www.jaypeebrothers.com

Join us on facebook.com/JaypeeMedicalPublishers
Follow us on instagram.com/JaypeeMedicalPublishers

Shelving Recommendations
INTENSIVE CARE AND EMERGENCY MEDICINE

ISBN 978-93-5696-968-1