ooks, visit our website www.ejaypee.com, for detailed information on neurology books, visit our website www.ejaypee.com, for detailed information on neurology books

4th Edition

Volume 4

s, visit our website www.ejaypee.com, for detailed information on neurology books, visit our website www.ejaypee.com, for detailed information on neurology books

4th Edition

Volume 3

s, visit our website www.ejaypee.com, for detailed information on neurology books, visit our website www.ejaypee.com, for detailed information on neurology books

4th Edition

Volume 2

visit our website www.ejaypee.com, for detailed information on neurology books, visit our website www.ejaypee.com, for detailed information on neurology books

4th Edition

Volume 1

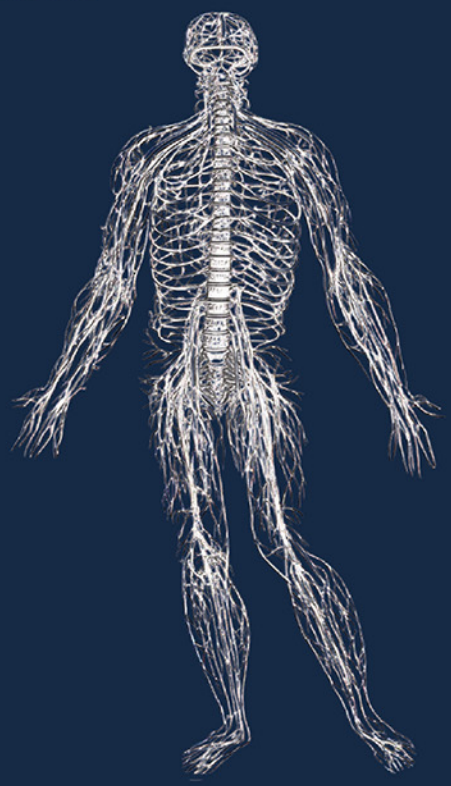

Consulting Editors
Prakash Narain Tandon
Ravi Ramamurthi

Editors
Sanjay Behari
MC Vasudevan
Anil Pande
Poodipedi Sarat Chandra

Associate Editors
Krishna Kumar G
Mangalkumar Girish Rachatte

Ramamurthi and Tandon's Textbook of NEUROSURGERY

Foreword
Anil Nanda

JAYPEE

Contents

VOLUME 1

Section 1: History

Section Editor: **Anil Pande**

1.1 History of Indian Neurosurgery 3
Anil Pande, Poodipedi Sarat Chandra, Thimmappa Hegde

- Timelines of the Ancient Indian Medical Tradition *3*
- Ancient Indian Period *3*
- Sushruta: The Father of Surgery *6*
- "Modern" Period (18th to 20th Century) *7*
- Neurosurgical Training *11*
- Microneurosurgery Workshops *12*
- Stereotactic and Functional Surgery *12*
- Spinal Neurosurgery in India *13*
- Paediatric Neurosurgery *13*
- Peripheral Nerve Surgery *14*
- Neurovascular Surgery in India *14*
- Epilepsy Surgery *14*
- Organised Neurosurgery *15*
- Textbooks of Neurosurgery *16*
- History and Historians *16*

1.2 Evolution of Neurosurgical Techniques..... 19
Thimmappa Hegde, Poodipedi Sarat Chandra

- Trephining in Neolithic Period *19*
- The Edwin Smith Surgical Papyrus *19*
- Ancient Greek–Roman Period *20*
- Ancient Chinese Period *21*
- Ancient Persian Period *22*
- Neurosurgical Techniques in the Medieval Period (AD 500–1500) *22*
- Neurosurgical Techniques in the Renaissance (AD 1500–1700) *22*
- Neurosurgical Techniques in the Pre-Listerian Period (AD 1700–1846) *23*
- Neurosurgical Techniques in the Pre-Horsley Period (AD 1846–1890) *23*
- Development of Contemporary Neurosurgical Techniques *25*
- Craniotomy *27*
- Suction and Irrigation *27*
- Brain Retractors *27*
- Haemostasis *28*
- Operating Microscope in Neurosurgery *29*
- Development of High-speed Drills *29*
- The Birth of Subspecialities and the Neurosurgery Residency Programme *29*
- Development of Neurosurgical Techniques in Surgery for Brain Tumours *30*
- Functional Stereotactic and Image-guided Surgery *33*
- Surgery for Epilepsy *33*
- Surgery for Movement Disorders *34*
- Surgery for Intractable Pain *35*
- Surgery for Trigeminal Neuralgia *35*
- Psychosurgery *35*
- Stereotactic Surgery *35*
- Paediatric Neurosurgery *36*
- Spinal Neurosurgery *36*
- Peripheral Nerve Neurosurgery *37*
- Minimally Invasive Neurosurgery *37*
- Evidence-based Neurosurgery *38*

1.3 History of Microneurosurgery..... 43
Thimmappa Hegde, Poodipedi Sarat Chandra

- Development of Various Microneurosurgical Techniques *44*

Section 2: Microsurgical Anatomy

Section Editors: **Sukhdeep Singh Jhawar, Abhidha Shah**

2.1 An Overview of White Fibres of the Brain and its Surgical Implications 51
Abhidha Shah, Sukhdeep Singh Jhawar, Atul Goel

- Classification of White Fibres of the Brain *51*
- Surgical Implications of the Classification *61*

2.2 Microsurgical Anatomy of the Medial Surface of the Brain: the Limbic System and Surgical Implications..... 63
Abhidha Shah, Sukhdeep Singh Jhawar, Atul Goel

- Medial Surface of Frontal Lobe *63*
- Medial Surface of the Parietal Lobe *64*
- Medial Surface of the Occipital Lobe *64*
- Limbic Lobe *65*

- Limbic Circuits *71*
- White Fibre Correlates of Amygdalohippocampectomy Through the Middle Temporal Gyrus Approach *72*

2.3 Microsurgical White Matter Anatomy of the Lateral Surface of the Brain, Insula, and the Central Core of the Brain 76
Abhidha Shah, Sukhdeep Singh Jhawar, Atul Goel

- Frontal Lobe *76*
- Central Lobe *77*
- Parietal Lobe *78*
- Occipital Lobe *79*
- Temporal Lobe *80*
- Insula *80*
- Central Core of the Brain *83*

2.4 Microsurgical Anatomy of the Basal Surface of the Brain 86
Abhidha Shah, Sukhdeep Singh Jhawar, Atul Goel

- Basal Surface of the Frontal Lobe *86*
- Basal Surface of the Occipital Lobe *90*
- Basal Surface of the Temporal Lobe *90*
- Surgical Relevance *91*

2.5 Microsurgical Anatomy of the Brainstem 94
Sukhdeep Singh Jhawar, Abhidha Shah, Maximiliano Nunez, Atul Goel

- Midbrain *95*
- Pons *100*
- Medulla *106*
- Floor of Fourth Ventricle *111*
- Organisation of White Fibres of the Brainstem *112*
- Pons *118*
- Medulla *118*

2.6 Microsurgical Anatomy of the Ventricular System 120
Sukhdeep Singh Jhawar, Abhidha Shah, Atul Goel

- Anatomy of the Ventricular System *120*
- Clinical Significance *123*

2.7 An Overview of Spinal Vascular Anatomy and Spinal Angiography 124
Abhidha Shah, Sukhdeep Singh Jhawar, Atul Goel

- Vascular Anatomy of the Spinal Cord *124*
- Spinal Angiography *126*

2.8 Brain Mapping and Connectomics 128
Abhidha Shah, Sukhdeep Singh Jhawar, Atul Goel

- Preoperative Brain Mapping *128*
- Intraoperative Brain Mapping *128*
- Postoperative Brain Mapping *129*
- Connectomics *129*

Section 3: Diagnostics

Section Editor: **Manjari Tripathi**

3.1 Electrodiagnosis 137
Jasmine Parihar, Priya Gupta, Manjari Tripathi

- Nerve Conduction Studies *137*
- Electromyography *138*
- Insertional Activity *139*
- Spontaneous Activity *139*
- Motor Unit Action Potentials *139*
- Electrodiagnostic Findings in Nerve Injury *140*
- Evoked Potentials *141*
- Some Common Diseases and their Electrophysiological Findings *145*

3.2 Intracranial Pressure 148
Ravi Ramamurthi, Nigel Peter Symss

- Anatomy and Physiology *148*
- Volume–Pressure Relationship *151*
- Pathology of Increased Intracranial Pressure *153*
- Intracranial Pressure Monitoring *154*
- Future Advances *160*

3.3 Neuro-ophthalmology 165
Meenakshi Pande, Soundari Sivagnanam

- Essential Neuro-ophthalmic Evaluation *165*
- Visual Pathway *166*
- Brain Tumours and Neuro-ophthalmic Findings *173*
- Sellar and Suprasellar Region *175*
- Intracranial Aneurysms *175*
- Neuro-ophthalmology of Orbital Tumours *176*
- Idiopathic Intracranial Hypertension *177*

3.4 Neuro-otology 180
Raghu Nandhan, Kiran Natarajan, Sathiya Murali, Mohan Kameswaran

- Diagnostic Neurotology *180*
- Quantitative Tests for Vestibular Function *180*
- Static Testing *181*
- Dynamic Testing *182*
- Special Vestibular Tests *191*
- Quantitative Tests for the Auditory System *193*
- Electrophysiological Tests *194*

3.5 Neuroendocrinology 201
Leelavathy Kandaswamy, Ravi Ramamurthi, Ravindranath Kapu

- Embryology of Pituitary *201*
- Prolactin *202*
- Growth Hormone *203*
- Adrenocorticotropic Hormone and Cortisol *204*
- Thyroid *206*

- Gonadotropins *208*
- Antidiuretic Hormone (Vasopressin) *209*

3.6 Intraoperative Monitoring 213
Krothapalli Srinivasa Babu, Vedantam Rajshekhar

- Special Needs of Intraoperative Monitoring *213*
- Choosing an Intraoperative Monitoring Machine *214*
- Bipolar and Monopolar Electrical Stimulation *218*
- Evoked Potentials *219*
- Direct Cortical Stimulation *229*
- Mapping and Monitoring Functional Cortical and Subcortical Tissues *230*
- Motor Nuclei and Nerve Stimulation *231*
- Intraoperative Electrophysiological Multimodality Monitoring *233*
- Is There Evidence for Utility of IOM? *233*

3.7 Conventional Radiology 237
Ravi Ramamurthi, Goutham Cugati

- Plain X-ray of the Skull *237*
- Imaging of the Spine *243*

3.8 Basic Principles of CT Scan and MRI Scan 245
Adhithyan Rajendran, Veena Noronha

Part A: Basics of Computed Tomography *245*
- Basic Physics *245*
- Types of Scanning Techniques *245*
- Computed Tomography Terminologies *247*
- Window Level and Window Width *247*
- Slice Thickness *247*
- Pitch *248*
- Image Post Processing *248*
- Computed Tomography Contrast Media *249*
- Advanced CT Imaging Techniques *249*

Part B: Physical Principles of Magnetic Resonance Imaging *253*
- Basic Principles of Magnetic Resonance Imaging *253*
- Instrumentation *255*
- Commonly Used Pulse Sequences *257*
- Magnetic Resonance Contrast *258*
- Magnetic Resonance Angiography *258*
- Advanced Magnetic Resonance Imaging Techniques *259*

3.9 Radiology: Intracranial Tumours 272
Adhithyan Rajendran, Chandrasekharan Kesavadas, Rakesh Jalali

- Imaging Modalities *272*
- Approach to Brain Tumours *272*
- Advanced Neuroimaging of Brain Tumours *273*
- World Health Organisation Classification of Brain Tumours 2021 *283*
- Tumour-mimicking Lesions *311*
- Post-surgical Imaging *312*
- Radiation Necrosis Versus Tumour Recurrence *314*

3.10 Radiology: Intracranial Infections 317
Adhithyan Rajendran, Bejoy Thomas

- Pyogenic Infections *317*
- Mycobacterium Tuberculosis Infection *322*
- Neurocysticercosis *323*
- Neurobrucellosis *326*
- Anthrax Meningoencephalitis *326*
- Viral Infections of the Brain *326*
- Fungal Infections *330*
- Others *332*

Section 4: Congenital

Section Editor: **Natarajan Muthukumar**

4.1 Embryology: Skull and Vertebral Column 341
Deepak Kumar Gupta, Harshavardhan Biradar, Natarajan Muthukumar

- Development of the Vertebral Column *341*
- Development of the Skull *347*

4.2 Embryology: Brain and Spinal Cord 352
Deepak Kumar Gupta, Harshavardhan Biradar, Natarajan Muthukumar

- Development of the Central Nervous System *352*
- Development of the Brain *357*
- Postnatal Growth of the Brain *366*

4.3 Congenital Malformations of Cerebrum 368
NK Venkatramana, Pravin Salunke

- Development and Pathogenesis *368*
- Concepts, Causes, and Classification *370*
- Structural Imaging *371*
- Functional Imaging *371*
- Clinico-radiological Features *372*
- Heterotopias *375*
- Management *378*
- Prognosis *379*
- Recurrence Risk *379*

4.4 Encephalocoele 383
Ashok Kumar Mahapatra, Ved Prakash Maurya

- Incidence of Encephalocoeles *383*
- Embryology *383*
- Classification of Encephalocoeles *384*
- Associated Pathology *384*
- Clinical Presentation *385*
- Anterior Encephalocoeles *387*
- Rare Clinical Features *389*
- Management *391*
- Treatment *392*

4.5 Intracranial Arachnoid Cysts 399
Santosh Mohan Rao Kanangi, Chidambaram Balasubramaniam, Vani Santosh

- Embryology and Anatomy *399*
- Pathogenesis of Cyst Expansion *402*
- Pathology *402*
- Intracranial Cysts *405*
- Spinal Cysts *417*

4.6 Craniosynostoses: Fundamental Principles of Management 424
Suhas Udayakumaran

- Definition, Classification, and Nomenclature of Craniosynostoses *424*
- Primary Craniosynostoses *424*
- Goals of Operative Management *425*
- Management of Craniosynostoses *429*
- Strategy and Timing of Surgery *430*
- Principles of the Operative Procedure in Craniosynostoses *430*
- Distraction Osteogenesis in the Management of Craniosynostoses *434*
- Endoscopic Management of Craniosynostoses *434*
- Management of Other Associated Clinical Issues *434*

4.7 Spinal Dysraphic States 440
NK Venkatramana

- Prevalence *440*
- Embryology *440*
- Aetiology *441*
- Symptomatology *441*
- Assessment *441*
- Prenatal Diagnosis *441*
- Radiological Assessment *441*
- Management *442*
- Surgical Treatment *442*
- Patient Selection *443*
- Surgical Technique *443*
- Tethered Cord Syndrome *444*
- Split Cord Malformations *450*
- Compound or Composite Split Cord Malformation *452*
- Dermal Sinus *452*
- Syndromes of the Tethered Cord *453*
- Tethered Cord Syndrome in Adults *453*
- Neurogenic Bladder with Conus at Normal Position *453*

4.8 Congenital Hydrocephalus 458
NK Venkatramana

- History *458*
- Embryology *459*
- Cerebrospinal Fluid Production and Absorption *459*
- Aetiology and Pathophysiology of Hydrocephalus *460*
- Definition of Hydrocephalus *461*
- Classification *461*
- Clinical Features *461*
- Investigations *462*
- Treatment *464*
- Intellectual Outcome *468*
- Special Types of Hydrocephalus *470*

4.9 Syringomyelia 477
Suresh Nair, Adesh Shrivastava, Girish Menon, B Ravimohan Rao

- Terminology and Classification *477*
- Aetiopathogenesis *478*
- Mechanism of Syrinx Formation *478*
- Mechanism of Syrinx Propagation *481*
- Symptomatology *481*
- Imaging *483*
- Natural History *484*
- Management *484*
- Causes of Surgical Failure and their Prevention *489*

4.10 Paediatric Brain Death Certification and Guidelines in India 493
Deepak Kumar Gupta, Kokkula Praneeth, Anna Teresa Mazzeo

- Definition of Cadaveric Donors According to WHO *493*
- Members of Brainstem Death Certification Board *493*
- Stepwise Approach for Potential Donor Identification and Brainstem Death Certification *494*
- Commonly Encountered Issues/Questions in Brain Death Certification/Diagnosis *498*

4.11 Paediatric Brain Abscess and Focal Suppurative Infections 502
Suhas Udayakumaran, Chiazor Udochukwu Onyia

- Epidemiology and Predisposing Factors *502*
- Pathology and its Treatment Implications *504*
- Microbiology *505*
- Management *505*
- Evaluation *506*
- Imaging in Cerebral Abscess *507*
- Treatment *507*

4.12 Paediatric Spinal Deformities 516
Sandip Chatterjee, Syed Khizar Uz Zaman

- Historical Overview *516*
- Embryology of the Spine *516*
- Terminologies *517*

- Congenital Causes of Spinal Deformity *518*
- Classification of Congenital Vertebral Anomalies *518*
- Syndromes Associated with Vertebral Anomalies *518*
- Types of Hemivertebrae *519*
- Special Congenital Vertebral Anomalies *519*
- Natural History of Congenital Scoliosis *521*
- Evaluation *521*
- Nonoperative Treatment *522*
- Operative Treatment *522*
- Basic Procedures for Surgical Treatment *522*
- Acquired Spinal Deformities *523*
- Paediatric Post-traumatic Spinal Deformity *526*
- Paediatric Spinal Deformity Associated with Intramedullary Tumours and Laminectomy *527*

Section 5: Head Injuries

Section Editor: **Deepak Agrawal**

5.1 Epidemiology of Head Injury 531

Pawan Kumar Verma, Rajkumar, Samir Kumar Kalra, Ashok Kumar Mahapatra

- Epidemiology *531*
- Type of Injury and Disability *533*
- Aetiology of Head Injury and Age Distribution *534*
- Gender and Head Injury *535*
- Reasons for Road Accidents in India *535*
- Socioeconomic Implication of Head Injury *536*

5.2 Biomechanics of Head Injury 539

Deepak Agrawal, Ashok Kumar Mahapatra

- Types of Mechanical Forces *539*
- Mechanism of Specific Injuries *541*
- Future Research *542*

5.3 Pathology in Trauma 544

Susarla Krishna Shankar, Pulak Nigam

Part A: Pathology of Head Injuries 544

- Types of cortical Traumatic Brain Injury *545*
- Pathology of Traumatic Head Injury in Children *559*
- Traumatic Brain Injury in Other Areas of the Brain *560*
- Cellular/Molecular Response to Brain Injury *565*
- Use of Magnetic Resonance Imaging in Assessing the Traumatic Brain Injury *570*
- Neuropathology of Post-traumatic Sequelae *571*
- Recent Advances *572*

Part B: Pathology and Pathogenesis of Spinal Cord Injury 579

- Classification of Spinal Cord Injuries *579*
- Pathophysiological Progression in Spinal Cord Injury *585*
- Therapeutic Strategies for Spinal Cord Injury *585*

5.4 Concussion Brain 591

Sandeep Vaishya, Vibha Gaonkar, Manbachan Singh Bedi

- Epidemiology *591*
- Risk Factors, Aetiology, and Mechanism of Injury *591*
- Pathophysiology *592*
- Clinical Features *594*
- Evaluation *594*
- Management *594*
- Complications *595*
- Prognosis *595*
- Chronic Traumatic Encephalopathy *595*

5.5 Cerebral Contusions 598

Ravi Ramamurthi, Nigel Peter Symss

- Contusion *598*
- Laceration *600*

5.6 Diffuse Axonal Injury 610

Ved Prakash Maurya, Raj Kumar, Ashok Kumar Mahapatra

- Pathophysiology *610*
- Pathology of Traumatic Diffuse Axonal Injury *612*
- Incidence of Traumatic Diffuse Axonal Injury *613*
- Clinical Presentation *613*
- Diagnostic Studies *614*
- Differential Diagnosis *615*
- Management of Traumatic Diffuse Axonal Injury *615*
- Prognosis *616*

5.7 Fat Embolism 619

Agasti Krishna Reddy, Poonam Mohanty

- Aetiology *619*
- Pathophysiology *620*
- Clinical Features of Fat Embolism Syndrome *620*
- Neurological Abnormalities *620*
- Diagnosis *621*
- Differential Diagnosis *623*
- Management *623*
- Prognosis *623*

5.8 Paediatric Head Injuries 625

Santosh Mohan Rao Kanangi, Chidambaram Balasubramaniam, Bala Ramachandran

- Growth and Development *626*
- Clinical Aspects *627*
- Injuries in the Various Age-groups *631*

- Radiological Features of Paediatric Head Injuries *638*
- Management of a Paediatric Head Injury *638*
- Critical Care *640*
- Outcome *649*

5.9 Clinical Assessment of a Head-injured Patient 655
Rajkumar, Pawan Kumar Verma, Ashok Kumar Mahapatra

- Initial Assessment *655*
- Clinical History *656*
- General Physical Examination *657*
- Neurological Assessment *657*
- Sensory and Local Examination *660*
- Red Flag Signs *660*
- Brain Death *660*

5.10 Current Management of Fluid and Electrolyte Imbalances in Head Injury 662
Rewati Raman Sharma, Apollina Sharma, Sanjay Pawar, Shyam Keshao Babhulkar, Ashok Kumar Mahapatra

- General Considerations *662*
- Clinical Assessment of Fluid and Electrolytes in Head Injury *666*
- Understanding Water Excess in Hyponatraemic States *667*
- Management: Corrections of Sodium and Fluid Imbalances *670*

5.11 Scalp Injuries 676
Agasti Krishna Reddy

- Historical Aspects *676*
- Anatomy *676*
- Description of Scalp Injuries *677*
- Management *679*
- Future Perspectives *686*

5.12 Acute Subdural Haematoma 688
Anil Kumar Bhoohalli Chikkanna, Kamlesh Singh Bhaisora, Ashutosh Kumar

- Epidemiology *688*
- Pathophysiology *689*
- Clinical Presentation *689*
- Diagnostic Evaluation *689*
- Treatment Strategies *689*
- Spontaneous Resolution of Acute Subdural Haematoma *690*
- Progression to Chronic Subdural Haematoma *690*
- Nonsurgical Approach *691*
- Surgical Recommendations for Acute Subdural Haematoma *691*
- Timing of Surgery *692*
- Prognosis *692*

5.13 Extradural Haematoma 694
Ashok Kumar Mahapatra, Raj Kumar, Ved Prakash Maurya

- Epidemiology *694*
- Pathophysiology *694*
- Clinical Presentation *695*
- Diagnosis *695*
- Management *695*
- Posterior Fossa Extradural Haematoma *697*
- Morbidity and Mortality *698*

5.14 Traumatic Intracerebral Haematomas 702
Ravi Ramamurthi, Nigel Peter Symss

- Classification *702*
- Incidence *702*
- Intracerebral Haemorrhage *702*
- Immediate Intracerebral Haemorrhages *703*
- Clinical Features *706*
- Radiology *707*
- Regional Cerebral Blood Flow Measurement *707*
- Guidelines for the Treatment of Traumatic Intracerebral Haemorrhage *708*
- Prognostic Factors *709*
- Prevention of Traumatic Intracerebral Haemorrhage *709*

5.15 Traumatic Brainstem Haemorrhage 712
Deepak Agrawal, Rajesh Meena, Ashok Kumar Mahapatra

- Incidence *712*
- Mechanism of Injury *712*
- Clinical Presentation *713*
- Radiology *715*
- Treatment *717*
- Outcome in Patients with Brainstem Haematoma *717*

5.16 Complications and Sequelae of Head Injury 720
Karthigeyan Madhivanan, Manju Mohanty, Sunil Kumar Gupta

- Post-traumatic Seizures *720*
- Post-traumatic Hydrocephalus *723*
- Paroxysmal Sympathetic Hyperactivity *724*
- Heterotopic Ossification *725*
- Post-traumatic Brain Injury Endocrine Dysfunction *726*
- Cerebrospinal Fluid Fistula *727*
- Post-traumatic Amnesia *729*
- Post-concussive Syndrome *730*
- Neurobehavioural Sequelae of Traumatic Brain Injury *731*
- Neuropsychiatric Sequelae *733*
- Somatic Symptoms *736*

5.17 Cranioplasty 747
Virendra Deo Sinha, Chakrabarty Amit, Sharma Ramesh, Suresh Narain Mathuriya

- Timing of Reconstruction *747*
- Importance of Adequate Skin Cover *749*
- Cranioplasty Material *749*
- Autografts and their Preservation *749*
- Polymethylmethacrylate *750*
- Titanium *750*
- Polyetheretherketone *750*
- Porous Hydroxyapatite *751*
- Cranioplasty with 3D Mould *751*
- Surgical Tips *752*
- Recovery in Cognition Following Cranioplasty *752*
- Hydrocephalus and Cranioplasty *753*
- Cerebrospinal Fluid Dynamics after Decompressive Craniectomy and Cranioplasty *753*
- Cranioplasty in the Paediatric Population *753*
- Syndrome of Trephine *754*
- Complications after Cranioplasty *755*

5.18 Maxillofacial Injuries 758
Arun Kumar Singh, Draun Upadhyay, Mamta Singaram

- General Principles *758*
- Clinical Evaluation of Facial Injuries *758*
- Imaging *759*
- Soft-tissue Injury of the Face *759*
- Mandibular Fractures *760*
- Maxillary Fractures *761*
- Fractures of Zygoma *763*
- Nasal Fractures *763*
- Naso-orbito-ethmoid Fractures *764*
- Panfacial Fractures *764*
- Paediatric Injuries *766*
- Fractures of the Facial Skeleton (Midface and Mandible) *766*

5.19 Traumatic Cerebrospinal Fluid Fistulae 768
Ravi Ramamurthi, Amit Kapoor

- Cerebrospinal Fluid Rhinorrhoea *768*
- Cerebrospinal Fluid Otorrhoea *772*
- Spinal Post-traumatic Cerebrospinal Fluid Leak *772*
- Traumatic Pneumocephalus *773*

5.20 Missile Injuries of the Brain 776
Harjinder Singh Bhatoe

- Historical Perspective *776*
- Applied Ballistics *777*
- Physical Effects of Missile Wounding *778*
- Pathophysiology *778*
- Evaluation and Initial Management *780*
- Imaging *780*
- Operative Management *780*
- Problem of Retained Intracranial Fragments *781*
- Adjuncts to Operative Management *782*

5.21 Endocrine Abnormalities Following Traumatic Brain Injuries 785
Deepak Kumar Gupta, Ashok Kumar Mahapatra

- Screening for Traumatic Brain Injury-induced Hypopituitarism *786*
- Who should Undergo Immediate Hormonal Replacement? *787*
- Who should Undergo Further Follow-up before Hormone Replacement? *788*
- Pathogenesis of Endocrinal Abnormalities *788*
- Clinical Signs and Symptoms of Hypopituitarism *790*
- Endocrinological Symptoms of Hypopituitarism in Traumatic Brain Injury *790*
- Investigations *791*
- Treatment of Hypopituitarism *793*
- Endocrine Abnormalities in Paediatric TBI *793*

5.22 Optic Nerve Injury 798
Ashok Kumar Mahapatra, Deepak Kumar Gupta

- Anatomical and Pathological Considerations *798*
- Pathology *799*
- Pathophysiology of Optic Nerve Injury *800*
- Pathological Anatomy *801*
- Clinical Features *802*
- Investigations *803*
- Treatment of Optic Nerve Injury *806*
- International Optic Nerve Trauma Study *812*
- Outcome and Factors Influencing Outcome *813*
- Chiasmal Injury *816*

5.23 Deep Brain Stimulation in Traumatic Brain Injury 820
Kanwaljeet Garg, Deepak Agrawal

- Disorders of Consciousness *820*
- Management of Patients with Disorders of Consciousness *820*
- Role of Neuromodulation Including Deep Brain Stimulation in Traumatic Brain Injury *821*
- How does Deep Brain Stimulation Work in Disorders of Consciousness? *821*
- Target Nuclei for Deep Brain Stimulation in Disorders of Consciousness *821*
- Surgical Nuances of Deep Brain Stimulation in Traumatic Brain Injury Patients *821*
- Results of Deep Brain Stimulation in Disorders of Consciousness Related to Traumatic Brain Injury *821*
- Difficulties in Interpretation of Literature *822*
- Future Directions *822*

5.24 Hinge Craniotomy for Surgical Management of ICP 824
Chirag Jain, Bhagavatula Indira Devi, Dhananjaya Ishwar Bhat, Dhaval P Shukla

- Intracranial Hypertension and the Role of Decompressive Craniectomy *824*
- Complications of Decompressive Craniectomy *825*
- Introduction of Hinge Craniotomy *825*
- Surgical Technique of Hinge Craniotomy *825*
- Evidence for Hinge Craniotomy *826*

5.25 Biomarkers in Traumatic Brain Injury 829
Chirag Jain, Bhagavatula Indira Devi, Gugamsetti Sai Phaneendra, Dhaval P Shukla, Dhananjaya Ishwar Bhat

- Mild Traumatic Brain Injury *829*
- Moderate and Severe Traumatic Brain Injury *829*
- Sampling *830*
- What is an Ideal Biomarker in Traumatic Brain Injury? *830*
- Biomarkers in Traumatic Brain Injury *830*
- Magnetic Resonance Imaging as a Biomarker in Traumatic Brain Injury *832*
- Where do Biomarkers Stand in TBI Management? *833*
- Limitations *834*

Section 6: Spinal Injuries

Section Editor: **JKBC Parthiban**

6.1 Assessment and Emergency Management of Acute Spinal Injuries 839
Anil Pande, Mangalkumar Girish Rachatte

- Initial Trauma Evaluation *839*
- Preadmission Spine Immobilisation *840*
- Transport of Spinal Injured Patient *840*
- Evaluation and Triage *841*
- Clinical Evaluation *841*
- Spinal Injury Grading Systems *843*
- Spinal Shock *843*
- Spinal Cord Neuropraxia *843*
- Whiplash Injuries *843*
- Spinal Injury Syndromes *843*
- Central Cord Syndrome *845*
- Spinal Instability *846*
- Radiological Assessment *846*
- Spinal Screening *848*
- Classification and a Brief Overview of Spinal Trauma *848*
- Occipitocervical Dislocation *848*
- Occipital Condyle Fractures *849*
- Atlas Fractures *849*
- Axis (C2) Fractures *849*
- Atlantoaxial Dislocation *850*
- OS Odontoideum *850*
- Combination Fractures of C1–C2 *851*
- Subaxial Cervical Spine Trauma (C3–T1) *851*
- Nutrition in Spinal Injury Patients *852*
- Medical and Pharmacologic Management *853*
- Traction *853*
- Orthotic Devices in Spine Trauma *854*
- Surgery *854*
- Paediatric Spine Injuries *855*
- Outcome Scores *856*
- Future Goals *856*

6.2 Biomechanics of the Spine 862
Anil Pande, Poonam Mohanty, Jhoshithaa Ramesh

- Historical Background *862*
- Biomechanical Terminology *863*
- Biomechanical Testing Methods *865*
- Role of Imaging in Biomechanics *866*
- Brief Normal Anatomy of the Spine *866*
- Special Regional Anatomy *869*
- Stability and Instability of Spine *871*
- Neural Control *871*
- Role of the Musculature *871*
- Spinal Instability and Columns *871*
- Evans Flagpole Concept *873*
- Whiteside's Construction Crane Analogue of the Spine *873*
- Biomechanics and Axial Traction *873*
- Biomechanics of Trauma *873*
- Applied Biomechanics *873*
- Biomechanics of Spine Deformity *874*
- Biomechanics of Cord Injury *874*
- Biomechanics of Bone Grafts *874*
- Biomechanics of Spinal Implants *874*
- Future of Biomechanics *875*

6.3 Injuries of the Craniovertebral Junction and Upper Cervical Spine 882
Poodipedi Sarat Chandra, Vamsi Krishan Yerramneni

- Surgical Anatomy *882*
- Clinical Features *883*
- Occipitocervical Dissociation *884*
- Occipitocervical Instability *884*
- Condylar Fractures *885*
- Atlas Fractures *885*
- Rupture of the Transverse Ligament *887*
- Odontoid Fractures *887*
- Traumatic Spondylolisthesis (Hangman's Fracture) *889*
- Options of Surgical Procedures for Craniovertebral Junction Trauma *891*

6.4 Injuries of the Subaxial Cervical Spine 897
Anil Pande, Ravindranath Kapu, Mangalkumar Girish Rachatte

- Historical Background *897*
- Anatomical Correlates of the Subaxial Cervical Spine *898*
- Mechanisms and Types of Injury *900*
- Classification of Subaxial Cervical Spine Injuries *900*
- Management *903*
- Examination *904*
- Investigations (Imaging of the Subaxial Cervical Spine in Trauma) *904*
- Treatment *906*
- Conservative *906*
- Guidelines *907*
- Lateral Mass Fractures *908*
- Post-traumatic Disc *910*
- Outcome *911*
- Complications *913*
- Paediatric Subaxial Spine Injuries *915*
- Geriatric Subaxial Spine Injuries *915*
- Delayed Subaxial Spine Instability *916*
- Future Trends and Preventive Neurosurgery *916*

6.5 Whiplash Injury 921
Harjinder Singh Bhatoe

- Mechanism and Pathology *921*
- Clinical Profile and Prognosis *922*
- Chronic Whiplash Injury *922*
- Imaging and Investigations *922*
- Management *923*

6.6 Thoracolumbar Injuries 925
Ramakrishna Easwaran

- Demographics *925*
- Aetiology *925*
- Predisposing Factors *926*
- Biomechanics *926*
- Clinical Features and Assessment *927*
- Assessment Scales *927*
- Associated Injuries *928*
- Imaging *929*
- Classification *930*
- Concept of Instability *933*
- Management *933*
- Open Spine Injuries *948*

6.7 Sacral Spine Injury 955
Ramakrishna Easwaran

- Relevant Anatomy *955*
- Incidence *955*
- Classifications and Mechanism of Injury *955*
- Clinical Features *956*
- Associated Injuries *957*
- Diagnostic Tests *957*
- Management *959*
- Complications of Surgery *962*
- Prognosis *962*

6.8 Penetrating Spinal Injuries 964
Harjinder Singh Bhatoe

Missile Injuries 964
- Location of Wound *964*
- Applied Ballistics *964*
- Approach to a Patient with Missile Injuries of the Spine *967*
- Current Management *973*
- Sequelae *973*

Non-missile Penetrating Spinal Injury (Stab Injury) 974
- Approach *975*

Section 7: Peripheral Nerve

Section Editor: **Bhagavatula Indira Devi**

7.1 Neurosurgical Anatomy of Brachial Plexus and Lumbosacral Plexus 981
Sumit Sinha, Mohammed Nadeem, Harsh Deora

Brachial Plexus 981
- Roots, Spinal Nerve, and Branches *982*
- Trunks and Divisions *982*
- Cords and Terminal Branches *982*
- Types of Brachial Plexus and its Anatomical Variations *983*
- Branches of the Brachial Plexus: Detailed Overview *984*
- Infraclavicular Plexus: Detailed Overview *984*
- Surgical Exposure of the Supraclavicular Plexus *985*

Surgical Anatomy of the Lumbosacral Plexus 986
- Lumbar Plexus Overview *986*
- Terminal Branches of the Lumbar Plexus: Detailed Overview *988*
- Accessory Obturator Nerve (L3–L4) *988*
- Femoral Nerve Anatomy and Branching (L2–L3–L4) *990*
- Sacral Plexus Configuration and Function *990*
- Functional Implications and Clinical Significance *991*
- The Great Sciatic Nerve *991*
- Common Peroneal Nerve (External Popliteal Nerve) *992*
- Anatomy and Branching of the Internal and External Plantar Nerves *993*

7.2 Preclinical Workup of Brachial Plexus Injuries 995
Mangalkumar Girish Rachatte
- Detailed History and Clinical Examination *997*
- Clinical Examination *998*
- Motor Examination *1000*
- Diagnostic Studies *1005*
- Nerve Conduction Studies *1007*
- Ultrasound Evaluation *1009*

7.3 Management of Brachial Plexus Injuries..... 1011
Chirag Jain, Dhananjaya Ishwar Bhat, Dhaval P Shukla, Bhagavatula Indira Devi
- Clinical Anatomy *1011*
- Clinical Features *1011*
- Diagnosis *1013*
- Management *1015*
- Outcome *1021*

7.4 Site Specific Management of Individual Peripheral Nerve Injuries 1024
Manish Singh Sharma, Robert James Spinner
- Management *1024*
- Common Peripheral Nerve Injuries *1025*
- Investigations *1029*
- Treatment *1030*
- Pain Management *1032*
- Monitoring *1032*
- Results *1032*

7.5 Entrapment Syndromes 1036
Poodipedi Sarat Chandra, Veer Singh Mehta, Shreyash Rai, Kuntal Kanti Das
- Traumatic and Entrapment Neuropathies *1036*

7.6 Management of Neoplasms Involving the Peripheral Nervous System 1053
Ketan Desai, Alay Vipulbhai Khandhar, Paurush Pasricha
- Benign Peripheral Nerve Sheath Tumours *1053*
- Benign Tumours of Non-neural Sheath Origin *1058*
- Malignant Peripheral Nerve Sheath Tumours *1061*

7.7 Management of Neuropathic Pain 1068
Chetna Shamshery, Shivani Rastogi
- Pain Assessment *1069*
- Non Pharmacological Treatment of Neuropathic Pain *1070*
- Pharmacological and Interventional Management of Neuropathic Pain *1072*
- Phenotypic Approach for Management of Neuropathic Pain *1076*

7.8 Recent Advances in Peripheral Nerve Surgery and its Role in Restorative Neurosurgery 1080
Mustafa Nadi, Rajiv Midha
- Contemporary Advances in Peripheral Nerve Surgery *1080*
- Modern Innovations in Peripheral Nerve Restorative Surgical Measures *1084*

7.9 General Principles of Management of Peripheral Nerve Injuries 1092
Soumen Kanjilal, Priyadarshi Dikshit, Kuntal Kanti Das
- Anatomy *1092*
- Classification of Nerve Injuries *1092*
- Mechanism of Injury *1093*
- Mechanism of Recovery *1093*
- Clinical Presentation *1094*
- Management of Peripheral Nerve Injuries *1095*
- Principles of Surgical Nerve Repair *1096*
- Postoperative Management *1097*

VOLUME 2

Section 8: Infections

Section Editor: **Ashis Pathak**

8.1 Brain Abscess..... 1103
Ramesh Vengalathur Ganesan, Dharkar Subhash Ravindra, Vimal Roy Sardana, Devendra Purohit
- Incidence *1103*
- History *1103*
- Aetiopathogenesis *1103*
- Microbiology of Brain Abscess *1105*
- Pathogenesis of Development of Brain Abscess and Capsule Formation *1105*
- Clinical Features *1108*
- Laboratory Investigations *1108*
- Radiological Investigations *1109*
- Treatment *1111*
- Complications *1114*
- Outcome and Prognosis *1114*

8.2 Scalp and Skull Infections 1118
Ravi Ramamurthi, Goutham Cugati, Poonam Mohanty

- Scalp Lacerations *1118*
- Postoperative Scalp Infection *1118*
- Craniotomy and Scalp Infection *1118*
- Deep Brain Stimulation and Scalp Infection *1119*
- Pin Site Scalp Infection *1120*
- Others *1120*
- Diagnosis *1120*
- Management *1120*
- Skull Osteomyelitis *1121*

8.3 Subdural Empyema 1125
Ashis Pathak, Khandelwal Niranjan, Suresh Narain Mathuriya

- Epidemiology *1125*
- Aetiology and Pathogenesis *1125*
- Clinical Presentation and Course *1126*
- Imaging *1126*
- Microbiology *1126*
- Spinal Subdural Empyema *1127*
- Management *1127*
- Prognosis *1129*

8.4 Spinal Epidural and Intramedullary Abscess 1131
Ashish Suri, Ravi Sharma, Shashwat Mishra

- Spinal Epidural Abscess *1131*
- Intramedullary Abscesses in the Spinal Cord *1133*
- Spinal Intramedullary Tuberculomas *1133*

8.5 Tuberculosis of the Central Nervous System 1136
Prakash Narain Tandon, Anil Pande

- History *1136*
- Pathogenesis *1136*
- Central Nervous System Tuberculosis *1137*
- Intracranial Tuberculomas *1138*

8.6 Tuberculous Meningitis 1154
Prakash Narain Tandon, Anil Pande

- Incidence *1154*
- Aetiopathogenesis *1154*
- Early Diagnosis *1155*
- Laboratory Investigations *1155*
- Late Diagnosis and Complications *1156*
- Sequelae and Outcomes *1161*

8.7 Tuberculosis of the Spine 1168
Anil Pande, Rahul Srinivasan

- Incidence *1168*
- History *1168*
- Pathology and Pathogenesis *1168*
- Clinical Presentation *1171*
- Investigations *1171*
- Treatment *1175*
- Minimally Invasive Tuberculosis Spine Surgery *1179*
- Craniovertebral Tuberculosis *1180*
- Cervical Tuberculosis *1181*
- Complications *1183*
- Outcomes *1183*
- Future Directions *1183*

8.8 Surgery for Leprosy 1187
Sridhar Krishnamurthy

- Historical Review *1187*
- Epidemiology *1187*
- Pathology of Nerve Involvement *1188*
- Clinical Features of Neuritis *1189*
- Differential Diagnosis *1189*
- Treatment *1190*
- Paralytic Deformities *1191*
- Dynamic Tendon Transfer *1191*
- Miscellaneous Surgical Conditions *1192*

8.9 Cysticercosis 1195
Bhawani Shanker Sharma, Anmol Singh Randhawa

- Typical Life Cycle of *Taenia Solium* *1195*
- Epidemiology *1196*
- Pathology of Neurocysticercosis and its Associated Clinical Characteristics *1196*
- Intracranial Hypertension and Hydrocephalus *1198*
- Diagnosis *1198*
- Other Diagnostic Tests *1199*
- Treatment Options *1201*
- Surgical Treatment *1202*
- Treatment of Parenchymal Cysticercosis *1205*
- Treatment of Extraparenchymal Cysticercosis *1205*
- Prevention *1206*

8.10 Hydatid Disease 1212
Dharkar Subhash Ravindra, Vikram Muthusubramanian

- Parasitology *1212*
- Epidemiology *1212*
- Cerebral Echinococcosis *1212*
- Hydatid Disease of the Cranium *1216*

8.11 Other Parasitic Infestations of the Brain 1219
Sridhar Krishnamurthy, Vikram Muthusubramanian

- Coenurosis Cerebralis *1219*
- Schistosomiasis (Bilharziasis) *1219*
- Parasitology *1219*
- Cerebral Schistosomiasis *1220*
- Spinal Schistosomiasis *1221*
- Paragonimiasis *1222*
- Strongyloidiasis *1223*
- Trichinosis *1224*
- Cerebral Sparganosis Mansoni *1225*
- Visceral and Ocular Larva Migrans *1225*

8.12 Spinal Hydatidosis 1230
Harjinder Singh Bhatoe

- Life Cycle and Spinal Implantation *1230*
- Incidence *1230*
- Pathogenesis and Pathology *1231*
- Clinical Features *1231*
- Imaging *1232*
- Serological Diagnosis *1232*
- Surgical Management *1233*
- Medical Management *1233*
- Percutaneous Aspiration, Injection, Reaspiration *1233*
- Prevention of Echinococcosis *1234*

8.13 Fungal Infections 1236
Anil Pande, Sandhya Rupa Palit

- Brief Evolutionary History of CNS Fungi *1236*
- General Considerations *1236*
- Predisposing Factors *1236*
- Classification *1237*
- Pathogenesis *1237*
- Clinical Features *1238*
- Diagnosis *1241*
- Cryptococcosis *1245*
- Aspergillosis *1246*
- Blastomycosis *1246*
- Coccidioidomycosis *1246*
- Candidiasis *1246*
- Mucormycosis *1247*
- Fusarium *1247*
- *Penicillium* *1247*
- *Histoplasmosis* *1247*
- *Pseudallescheria Boydii* *1247*
- Dematiaceous Fungi *1248*
- Treatment *1248*
- Prognosis and Outcomes *1251*

8.14 Viral Infections 1257
Ravi Ramamurthi, Ravindranath Kapu, Rahul Srinivasan

- Herpes Simplex Encephalitis *1258*
- Herpes Zoster (Varicella Zoster) *1258*
- Ramsay Hunt Syndrome *1259*
- Reye's Syndrome *1260*
- Creutzfeldt–Jakob Disease *1261*
- Polyoma Virus *1261*
- Rabies Virus *1261*
- Enterovirus Central Nervous System Infections *1261*
- H1N1 Virus *1261*
- Epstein–Barr Virus *1262*
- Cytomegalovirus *1262*
- Human Herpes Virus 6 *1262*
- Japanese Encephalitis *1262*
- Covid-19-related Implications *1263*

8.15 Acquired Immunodeficiency Syndrome and the Neurosurgeon 1267
Poodipedi Sarat Chandra, Vivek Tandon

- Historical Perspective *1267*
- The Virus *1267*
- Pathogenesis *1267*
- Clinical Features *1268*
- Neurological Manifestations of Acquired Immunodeficiency Syndrome *1268*
- Primary Central Nervous System Lymphoma *1269*
- Progressive Multifocal Leukoencephalopathy *1271*
- Toxoplasmosis *1271*
- Meningitis *1271*
- Tubercular Infection *1273*
- Acquired Immunodeficiency Syndrome Encephalopathy and Acquired Immunodeficiency Syndrome Dementia Complex *1273*
- Human Immunodeficiency Virus Myelopathy *1273*
- Peripheral Nervous System *1273*
- Cerebrovascular Disease *1274*
- Other Uncommon Neurological Presentations *1274*
- Diagnosis of Human Immunodeficiency Virus *1274*
- Management of Intracranial Lesions *1274*
- Biopsy in Acquired Immunodeficiency Syndrome *1274*
- General Management of Human Immunodeficiency Virus Infections *1275*
- Risks in Health Professionals *1275*
- Additional Precautions When Caring for Known Human Immunodeficiency Virus Positive and High-risk Patients *1276*
- Transmission from Health Workers to Patients *1276*
- Precautions for Infected Health Workers *1276*
- Invasive Procedures to be Avoided by E-Antigen or Human Immunodeficiency Virus Positive Health Workers *1276*

Section 9: Vascular Disorders

Section Editor: **Paritosh Pandey**

9.1 Subarachnoid Haemorrhage 1281
Arivazhagan Arimappamagan, Subhas Konar, BA Chandramouli

- Epidemiology *1281*
- Aetiology *1281*
- Clinical Features *1282*

- Misdiagnosis of Subarachnoid Haemorrhage *1283*
- Investigations *1284*
- Management of Subarachnoid Haemorrhage *1286*
- Patient Outcome Following Subarachnoid Haemorrhage *1288*
- Perimesencephalic Subarachnoid Haemorrhage *1289*

9.2 General Principles of Management of Intracranial Aneurysms 1294
Paritosh Pandey

- Demography *1294*
- Genetics *1294*
- Landmark Trials *1294*
- Clinical Features *1295*
- Aneurysmal Subarachnoid Haemorrhage Symptoms and Signs *1296*
- Treatment and Investigations *1296*
- Medical Management *1298*
- Definitive Management of Aneurysm *1299*
- Surgical Nuances of Aneurysmal Clipping *1299*
- Endovascular Considerations for Aneurysmal Coiling *1300*

9.3 Clipology for Clipping of Aneurysms..... 1303
Poodipedi Sarat Chandra

- Historical Perspective *1303*
- Basic Physics of Aneurysm Clips *1305*
- Types of Clip Application *1305*

9.4 Vasospasm and its Management..... 1310
Anil Pande, Ravi Ramamurthi

- Brief Historical Overview of Vasospasm *1310*
- Incidence *1311*
- Chronology *1311*
- Risk Factors for Developing Vasospasm *1312*
- Site of Occurrence *1312*
- Classification and Grading of Vasospasm *1313*
- Experimental Models for Studying Vasospasm *1314*
- Aetiopathogenesis of Vasospasm *1314*
- Biology of Cerebral Blood Vessels *1315*
- Vasculopathy *1316*
- Trauma of Manipulation of the Arteries *1316*
- Hypothalamus and Sympathetic Plexus *1316*
- Apoptosis and Vasospasm *1317*
- Cascade of Events before and after Vasospasm *1317*
- Early Brain Injury *1317*
- Clinical Features of Vasospasm *1317*
- Investigations *1317*
- Treatment *1320*
- Pharmacological Prevention of Vasospasm *1321*
- Lumbar and Cisternal Drainage *1323*
- Timing of Surgery in Relation to Vasospasm *1323*
- Surgery *1324*
- Outcome *1324*

9.5 Cerebral Protection 1333
Ramesh Vengalathur Ganesan, Ravikant Palur, Ganesh K Murthy

- Pathophysiology of Injury to the Central Nervous System *1333*
- Protective Mechanism Against Oxygen-free Radicals *1335*
- Modalities of Cerebral Protection *1336*
- Pharmacological Therapies *1336*
- Non-pharmacological Therapies *1341*

9.6 Paraclinoid Aneurysms..... 1348
Vijendra Kumar Jain, Sanjay Behari, Bernard Lyngdoh

- Neuroanatomy *1348*
- Clinical Presentation *1353*
- Special Radiological Considerations *1353*
- Therapeutic Options *1354*

9.7 Internal Carotid Artery Bifurcation Aneurysms... 1365
Ashish Suri, Ravi Sharma

- Epidemiology *1365*
- Natural History *1365*
- Morphology *1365*
- Anatomy *1366*
- Anterior Choroidal Artery *1366*
- Perforators *1366*
- Aetiopathogenesis *1367*
- Classification Systems of ICABAs *1367*
- Role of Conservative Management *1368*
- Operative Nuances of Microsurgical Clipping *1368*
- Role of Endovascular Management *1369*
- Outcomes and Future Directions *1370*

9.8 Anterior Communicating Artery Aneurysms 1373
Robin P Sengupta, Anil Pande

- Incidence *1373*
- Aetiology *1373*
- Surgical Milestones in the Management of Anterior Communicating Artery Aneurysms *1374*
- Microsurgical Anatomy of the Anterior Communicating Artery Complex *1375*
- Anterior Communicating Artery Complex *1376*
- Clinical Features *1377*
- Investigations *1378*
- Management *1382*
- Pre-operative Measures *1382*
- Treatment *1383*
- Approaches to Anterior Communicating Artery Aneurysms *1383*
- Giant Anterior Communicating Artery Aneurysms *1387*

- Fusiform Anterior Communicating Artery Aneurysms *1388*
- Blister-like Anterior Communicating Artery Aneurysms *1388*
- Kissing Anterior Communicating Artery Aneurysms *1388*
- Clipping and Coiling Debate *1388*
- Complications *1388*
- Outcomes *1389*

9.9 Distal Anterior Cerebral Artery Aneurysm..... 1395
Dwarakanath Srinivas, Manish Beniwal, Gyani Zail Singh Birua

- Anatomy and Pathophysiology *1395*
- Clinical Presentation *1396*
- Diagnostic Evaluation *1396*
- Treatment Options *1397*

9.10 Middle Cerebral Artery Aneurysms..... 1400
Navneet Singla, Vivek Gupta, Suresh Narain Mathuriya

- Presentation *1400*
- Types *1400*
- Middle Cerebral Artery *1401*
- Sylvian Fissure and Arachnoid Membranes *1403*
- Sylvian Veins *1404*
- Investigations *1404*
- Angiographic Anatomy of the Middle Cerebral Artery *1407*
- Surgical Technique *1407*
- Surgery *1408*
- M1 Segment Aneurysm *1412*
- Giant Middle Cerebral Artery Aneurysm *1413*
- Dissecting Aneurysm *1414*
- Distal Middle Cerebral Artery Aneurysms *1414*
- Unruptured Middle Cerebral Artery Aneurysms *1414*
- Intraoperative Neuromonitoring *1415*
- Endovascular Treatment of Middle Cerebral Artery Aneurysms *1415*
- Clipping versus Coiling *1421*

9.11 Posterior Circulation Aneurysms..... 1425
Ashish Suri, Ravi Sharma

- Microsurgical Anatomy of Posterior Circulation *1425*
- Incidence *1426*
- Clinico-radiological Evaluation and Surgical Management *1427*
- Endovascular Management *1435*

9.12 Giant Intracranial Aneurysms 1437
Manish Singh Sharma, Ashutosh Kumar, Sanjay Behari

- Pathophysiology *1437*
- Management *1438*

9.13 Unruptured Intracerebral Aneurysms 1448
Suresh Nair, Girish Menon, Adesh Shrivastava

- Epidemiology and Prevalence *1448*
- Natural History of Unruptured Intracerebral Aneurysms *1448*
- Risk of Rupture *1448*
- Risk Prediction Scores *1452*
- Management *1453*
- Screening *1454*
- Surveillance Imaging *1454*
- Future Direction *1454*

9.14 Multiple Intracranial Aneurysms 1457
Mahmoud Rashidi, Anthony Sin, Anil Nanda, Saurabh Sinha, Paritosh Pandey

- Incidence *1457*
- Risk Factors for Multiple Intracranial Aneurysms *1457*
- Aneurysm Distribution *1459*
- Institutional Experience *1460*
- Illustrative Case *1460*
- Prediction of Rupture Site *1461*
- Treatment *1461*
- Outcome *1462*

9.15 Infectious Intracranial Aneurysms 1465
Arun Gowda Keelara, Kuntal Kanti Das, Anant Mehrotra, Awadhesh Kumar Jaiswal, Sanjay Behari, Vivek Vaid, Vijendra Kumar Jain

- Historical Background *1465*
- Incidence *1465*
- Aetiopathogenesis *1465*
- Clinical Features *1466*
- Diagnostic Evaluation and Radiological Features *1466*
- Natural History *1468*
- Management Considerations *1469*

9.16 Intracavernous Aneurysms..... 1473
Bhawani Shanker Sharma, Pankaj Somani, Veer Singh Mehta

- Aetiology and Natural History *1473*
- Anatomy of Intracavernous Aneurysm *1473*
- Pathophysiology *1474*
- Types of Intracavernous Aneurysm *1474*
- Rupture Predicting Scores *1474*
- Clinical Features *1475*
- Investigations *1476*
- Differential Diagnosis *1477*
- Treatment *1477*
- Preoperative Evaluation *1482*
- Postoperative Management *1485*
- Complications *1485*
- Graft Problems *1485*

9.17 Intra-operative Rupture of Aneurysms and its Management 1492
Poodipedi Sarat Chandra, Ramesh Doddamani

- Aneurysms at Risk of Intra-operative Rupture *1492*
- Strategies to Prevent Intra-operative Rupture *1492*
- Intra-operative Rupture of Aneurysm *1495*

9.18 Vascular Malformations of the Brain 1499
Ravi Ramamurthi, Anil Pande

- Classification *1499*
- Arteriovenous Malformations *1499*
- Haemodynamics of Arteriovenous Malformation *1506*
- Investigations *1506*
- Causes for Angiographically Occult Arteriovenous Malformations *1509*
- Grading of Arteriovenous Malformations *1510*

9.19 Surgical Management of Cerebral Arteriovenous Malformations 1516
Atul Goel

- Indications for Surgery *1516*
- Surgical Planning *1516*
- Type of Arteriovenous Malformation Nidus *1516*
- Epidemiology and Natural History *1525*
- Arteriovenous Malformations: Congenital or Dynamic? *1525*
- A Randomised Trial of Unruptured Brain Arteriovenous Malformations (ARUBA) *1525*
- Classification of Arteriovenous Malformation *1525*
- Preoperative Embolization *1526*
- Assessment of a Patient for Surgery *1527*
- Issues in Planning the Surgery *1527*
- Imaging Studies *1527*
- Angiographic Characterisation of Arteriovenous Malformation *1528*
- Indicators of "High-flow" Arteriovenous Malformation *1528*
- Location of the Arteriovenous Malformation *1528*
- Surgery *1528*
- Postoperative Care *1530*
- Awake Craniotomy and Brain Mapping *1530*
- Bilateral Parafalcine Approach for Arteriovenous Malformations Located in the Interhemispheric Fissure *1530*
- Stereotactic Radiosurgery *1531*

9.20 Embolization of Intracranial Vascular Malformation 1532
Anil Karapurkar, Sourabh Jain, Rakesh Singh, Sai Prashanth PR

- Investigations *1534*
- Indications for Treatment *1535*
- Contraindications for Treatment *1536*
- Timing of Treatment *1536*
- Embolization *1537*
- Complications *1545*

9.21 Stereotactic Radiosurgery for Cerebral Arteriovenous Malformations 1552
Manjul Tripathi, Ganapathy Krishnan

- History of Stereotactic Radiosurgery for Arteriovenous Malformation *1552*
- Therapeutic Options for an Intracranial Arteriovenous Malformation *1553*
- Introduction to Stereotactic Radiosurgery *1554*
- Radiosurgery-based Grading Systems *1554*
- Decision-making in Radiosurgery *1554*
- Radiobiological Effects of SRS on AVM *1556*
- Clinical Presentation *1556*
- Investigations *1557*
- Stereotactic Radiosurgery for Cerebral AVMS: The Procedure *1557*
- Large Arteriovenous Malformation *1563*
- Repeat Radiosurgery *1564*

9.22 Vein of Galen Malformations 1570
Anil Nanda, Paritosh Pandey

- Anatomical Considerations and Classification *1570*
- Clinical Features *1571*
- Diagnostic Investigations *1571*
- Treatment *1572*
- Outcome *1574*

9.23 Cerebral Cavernous Malformations 1576
Chandrashekhar Eknath Deopujari, Nirbha S Ghurye, Suhas Malineni, Chandan B Mohanty, Vikram S Karmarkar, Krishna Shroff

- Epidemiology *1576*
- Aetiopathogenesis *1576*
- Molecular Biology *1577*
- Gross Pathology and Histological Features *1577*
- Clinical Features *1578*
- Imaging *1580*
- Clinical Management *1581*
- Illustrative Cases Showing Radiological, Intraoperative, and Postoperative Images *1582*

9.24 Other Vascular Malformations of the Brain 1589
Dheeraj Vishwakarma, Harkaran Sahni, Daljit Singh

- Dissecting Aneurysm *1589*
- Venous Angioma *1590*

9.25 Carotid Cavernous Fistula 1594
Daljit Singh, Harkaran Sahni, Shankara Ram Choudhary

- History *1594*
- Anatomy of the Cavernous Sinus *1594*

- Classification *1596*
- Symptoms And Signs *1597*
- Investigations *1597*

9.26 Dural Arteriovenous Fistulas 1604
Rushabh Mulchand Chheda, Anil Kumar Bhoohalli Chikkanna, Kavindra Singh, Arun Kumar Srivastava, Vivek Singh, Kamlesh Singh Bhaisora

- Embryology and Pathophysiology *1604*
- Aetiology *1604*
- Classification *1605*
- Natural History *1605*
- Clinical Features *1608*
- Treatment for Cranial Dural Arteriovenous Fistulas *1609*
- Modes of Management *1609*
- Stereotactic Radiosurgery *1610*
- Dural Arteriovenous Fistulas in Specific Locations: Surgical Considerations *1611*
- Complications of Treatment *1613*
- Endovascular versus Surgical Treatment *1614*

9.27 Embolization of Spinal Vascular Malformation 1618
Anil Karapurkar, Rakesh Singh, Ahamed Subir, Riddhi Patel

- Classification of Spinal Vascular Malformations *1618*
- Vascular Supply of the Spinal Cord *1618*
- Clinical Presentation *1620*
- Investigations *1620*
- Treatment *1622*

9.28 Spontaneous Intracerebral Haemorrhage..... 1633
Rajesh Boyina Jagadeeshwar Rao

- Risk Factors *1633*
- Emergency Diagnosis and Assessment of Intracranial Haemorrhage and its Causes *1634*
- Diagnosis *1634*
- Pathophysiology *1634*
- Prognosis *1636*
- Management *1636*
- Surgical Management *1638*

9.29 Cerebral Revascularisation 1644
Nithin Raj SD, Girish Menon

- Classification/Nomenclature *1644*
- Indications *1644*
- Choice of Procedure *1646*
- Preoperative Evaluation *1646*
- Surgical Principles and Bypass Techniques *1647*
- Complications *1648*
- Outcome and Recommendations *1649*
- Emerging Trends and Technologies in Cerebral Bypass Surgery *1649*
- Promising Research and Potential Advancements in the Field *1649*

9.30 Moyamoya Disease 1652
Hitesh Inder Singh Rai, Amol Raheja

- Pathophysiology *1652*
- Symptomatology *1652*
- Diagnosis *1652*
- Management *1654*
- Pearls *1658*

9.31 Endovascular Management of Intracranial Aneurysms 1661
Paritosh Pandey

- Evolution of Endovascular Treatment *1661*
- Why Endovascular Management Trials *1661*
- Clinical Aspects and Case Selection *1662*
- Endovascular Embolization Techniques *1663*

9.32 Flow Diversion in the Treatment of Intracranial Aneurysms 1680
Gagan Dhall, Saman Arfaie, Christopher Pasarikovski, Johnston Jr Te, Anish Kapadia, Christine Hawkes, Leodante da Costa, Ashish Kumar

- Principle of Flow Diversion and Mechanism of Action *1680*
- Design Evolution and Era of Disruptive Innovation in Flow Diversion Technology *1682*
- Indications for Flow Diversion *1683*
- Antiplatelet Therapy and Flow Diversion *1687*
- Complications Associated with Flow Diversion *1688*
- Current Evidence and Literature Review *1693*
- Endosaccular Flow Diversion *1693*

9.33 Management of Cervical Carotid Artery Disease 1697
Paritosh Pandey, Sunil V Furtado, Mayank Mangwani, Bharat Nayak

- Epidemiology *1697*
- Pathogenesis *1697*
- Landmark Prospective Randomised Trials *1698*
- Evaluation of Carotid Stenosis *1698*
- Medical Management *1699*
- Indication for Intervention *1700*
- Carotid Endarterectomy *1700*
- Carotid Stenting *1702*

9.34 Endovascular Thrombectomy Techniques in Acute Ischaemic Stroke..... 1706
Jitender Saini, Ankit Arora, Paritosh Pandey

- First-generation Devices *1707*
- Second-generation Devices (Stent Retrievers) *1708*
- Third-generation Devices *1710*
- Current Stroke Thrombectomy Techniques *1711*
- Techniques Employing Stent Retriever and Large-bore Aspiration Catheter *1712*
- Patient Eligibility for Mechanical Thrombectomy *1715*

- General Anaesthesia versus Conscious Sedation for Mechanical Thrombectomy *1716*
- Endovascular Therapy in Posterior Circulation Strokes *1717*

Section 10: Tumours of Spine

Section Editor: **Anil Pande**

10.1 Clinical Features and Diagnosis of Tumours of the Spine and Spinal Cord 1723

Ravi Ramamurthi, Santosh Mohan Rao Kanangi

- Historical Background *1723*
- Classification *1723*
- Tumours of the Spinal Cord *1723*
- Tumours of the Vertebral Column *1724*
- Pathophysiology of Cord Compression *1724*
- Symptoms and Signs of Spinal Compression *1725*
- Clinical Features of Tumours at Different Levels *1728*
- Alignment of Cord Segments and Vertebrae *1731*
- Differential Diagnosis *1732*
- Functional Scores in Spinal Cord Disease *1732*

10.2 Vertebral Tumours 1735

Deepu Banerji, Pallav Garg, Manoj Jain, Sanjay Behari

- Benign Tumours of the Spine *1735*
- Primary Malignant Tumours of the Spine *1739*
- Pathogenesis *1742*
- Clinical Presentation *1743*
- Radiological Evaluation *1744*
- Management *1745*

10.3 Benign Spinal Intradural Extramedullary Tumour 1748

Trimurti Dattayraya Nadkarni, Poonam Mohanty

- Historical Consideration *1748*
- Classification and Terminology *1748*
- Genetic Aspects *1751*
- Clinical Symptoms and Signs *1751*
- Diagnostic Imaging *1752*
- Saito's Technique *1757*
- Minimally Invasive Approaches *1757*
- Need for Spinal Fusion *1757*
- Adjuvant Therapy and Radiosurgery *1758*

10.4 Intramedullary Tumours 1761

Bhawani Shanker Sharma, Manish Singh Sharma

- History *1761*
- Aetiopathology *1761*
- Histological Subtypes *1761*
- Clinical Features—Symptoms *1762*
- Clinical Examination *1763*
- Investigations *1763*
- Management *1763*
- Special Instruments/Technology *1764*
- Surgical Steps *1765*
- Postoperative Management *1768*
- Postoperative Complications *1768*
- Adjunctive Treatment *1769*
- Prognosis *1769*
- The All India Institute of Medical Sciences Experience *1770*

10.5 Congenital Tumours of Spine 1773

Chandrashekhar Eknath Deopujari, Chandan B Mohanty, Harshal N Agarwal

- Epidermoid and Dermoid Cysts *1773*
- Sacrococcygeal Teratoma *1775*
- Lipoma *1777*
- Neurenteric Cyst *1779*
- Arachnoid Cyst *1780*

10.6 Paediatric Spinal Tumours 1786

NK Venkatramana

- Historical Overview *1786*
- Epidemiology *1786*
- Pathology *1786*
- Classification *1786*
- Clinical Presentation *1787*
- Laboratory Investigations *1788*
- Therapeutic Considerations *1789*
- Evoked Potential Monitoring *1793*
- Complications *1793*
- Adjuvant Therapy *1794*

10.7 Spinal Dermoid and Epidermoid Cysts 1799

Sandip Chatterjee, Rohan Roy

- Aetiopathogenesis *1799*
- Epidemiology *1799*
- Management *1800*
- Postoperative Care and Rehabilitation *1801*

Section 11: Disc Disease and Other Spinal Pathologies

Section Editor: **Vedantam Rajshekhar**

11.1 Cervical Disc Disease 1805

Anil Pande, Ravi Ramamurthi

- Epidemiology *1805*
- Pathophysiology *1806*
- Symptomatology *1806*
- Evaluation *1806*
- Management *1807*
- Posterior Microsurgical Approaches *1811*
- Minimally Invasive Cervical Disc Surgery *1811*
- Complications *1812*
- Outcomes *1813*

11.2 Cervical Spondylotic Myelopathy 1817
Anil Pande, Haridharan V, Parthiban Jutty Krishnaiyer Bala Chandra

- Historical Background *1817*
- Incidence *1818*
- Natural History *1818*
- Aetiopathogenesis *1818*
- Clinical Features *1820*
- Differential Diagnosis *1821*
- Imaging *1821*
- Management *1824*
- Surgical Management *1825*
- Complications *1827*
- Outcomes *1828*

11.3 Cervical Ossification of the Posterior Longitudinal Ligament 1834
Anil Pande, Ravi Ramamurthi, Divya Swaminathan

- Incidence and Prevalence *1834*
- Aetiopathogenesis *1834*
- Pathology *1835*
- Classification of Ossification of the Posterior Longitudinal Ligament *1836*
- Microsurgical Anatomy of the Posterior Longitudinal Ligament *1836*
- Clinical Presentation and Natural History *1837*
- Management *1838*
- Computed Tomography Scan and Computed Tomography Myelography *1838*
- Treatment *1840*
- Outcome *1845*

11.4 Thoracic Disc Disease 1852
Ravi Ramamurthi, Nigel Peter Symss, Rahul Srinivasan

- Pathology *1852*
- Clinical Features *1852*
- Differential Diagnosis *1853*
- Investigations *1853*
- Treatment *1853*
- Complications *1855*
- Outcome of Surgery *1855*
- Conservative Management *1856*

11.5 Lumbar Disc Disease 1858
Manas Kumar Panigrahi, Ambresh Ambajirao Kalyankar

- Historical Perspectives *1858*
- Anatomy and Biomechanics of the Lumbar Intervertebral Disc *1858*
- Pathophysiology of Degenerative Disc Disease *1859*
- Clinical Features *1860*
- Differential Diagnosis *1862*
- Investigations *1862*
- Conservative Management *1864*
- Operative Management *1866*
- Procedures for Lumbar Discectomy *1866*
- Complications and Management *1870*
- Rehabilitation after Lumbar Disc Surgery *1870*
- Prognosis *1871*
- Controversies in Management *1871*
- Radiation Exposure to the Surgeon and the Patient in Minimally Invasive Spine Surgery *1873*
- Artificial Disc Technology *1874*

11.6 Lumbar Canal Stenosis 1878
Manas Kumar Panigrahi, Savitr Sastri BV

- Anatomy *1878*
- Pathogenesis *1878*
- Natural History *1879*
- Clinical Features *1879*
- Investigations—Imaging *1880*
- Differential Diagnosis *1881*
- Treatment *1882*
- Results *1885*

11.7 Lumbar Spondylolisthesis 1887
Ramakrishna Easwaran, Rahul Srinivasan

- Classification and Aetiology *1887*
- Grading *1889*
- Marchetti and Bartolozzi Classification *1890*
- Spine Deformity Study Group *1890*
- Clinical Features and their Basis *1890*
- Investigations *1892*
- Management *1895*

11.8 Skeletal Fluorosis 1906
Deme Raja Reddy, Pulak Nigam

- Fluoride Exposure *1907*
- Pathophysiology of Skeletal Fluorosis *1908*
- Clinical Presentation and Neurological Manifestations *1911*
- Investigations *1914*
- Pathology of Skeletal Fluorosis *1919*
- Differential Diagnosis *1920*
- Treatment *1921*

11.9 Osteoporosis and Vertebral Compression Fracture 1927
Ramakrishna Easwaran, Sundararajan Srinivasan

- Definition *1927*
- Criteria for Diagnosis of Osteoporosis *1927*
- Pathophysiology of Osteoporosis *1927*
- Clinical Features *1928*
- Investigations *1929*
- Treatment *1932*

11.10 Transarticular Fixation Technique 1942
Atul Goel

- Facts about Facets *1942*
- Indications of Spinal Fixation *1943*

- Camille's Technique of Trans Articular Fixation *1943*
- Surgical Technique *1943*
- Advantages of Trans Articular Fixation Technique *1945*

Section 12: Pathology of Intracranial Tumours

Section Editor: **Mitra Ghosh**

12.1 Central Nervous System WHO 2021: Updates..... 1951
Manali Ranade, Sridhar Epari

- General Updates *1951*
- Newly Recognised Entities *1952*
- Important Tumour-specific Updates *1952*

12.2 Pathogenesis of Tumours of the Nervous System 1956
Deepti AN

- Genetic Factors *1956*
- Molecular Pathogenesis Based on Somatic Alterations *1956*
- Meningiomas *1964*
- Cancer Predisposition Syndromes Involving the Nervous System *1964*
- Single-nucleotide Polymorphisms *1967*
- Non-genetic Factors *1967*

12.3 Germ Cell Tumours of the Central Nervous System 1972
Sushila Jaiswal

- Sex Predisposition *1972*
- Location *1972*
- Pathogenesis *1972*
- Radiological Features *1972*
- Clinical Features *1973*
- Classification *1973*
- Pathology *1973*
- Role of Serum/Cerebrospinal Fluid Tumour Markers in Germ Cell Tumour *1975*
- Role of Biopsy in Germ Cell Tumour *1975*
- Role of Surgery in Germ Cell Tumour *1976*

12.4 Embryonal Tumours of the Central Nervous System 1978
Rajalakshmi P

- Medulloblastoma *1978*
- Atypical Teratoid/Rhabdoid Tumour *1982*
- Cribriform Neuroepithelial Tumour *1984*
- Embryonal Tumour with Multilayered Rosettes *1984*

12.5 Tumours of Meninges 1989
Yashaswini Nallacheruvu, Lakshmi Manasa Perubhotla, Sundaram Challa

Meningioma ***1989***

- Incidence *1989*
- Risk Factors *1989*
- Sites *1990*
- Gross Pathology *1990*
- Histopathology *1990*
- Atypical Meningioma *1990*
- Anaplastic Meningioma *1990*
- Immunohistochemistry and Proliferation *1992*
- Molecular Diagnostic Tests *1994*
- Molecular Genetics *1994*
- *NF2*-Mutated Meningiomas *1996*
- Non-*NF2* Mutated Meningiomas *1997*
- Epigenetic Changes *1998*
- Prognosis and Implications for Treatment *1998*
- Mesenchymal and Non-meningothelial Tumours Involving the Central Nervous System *2000*
- Solitary Fibrous Tumour *2001*
- Haemangioblastoma *2002*
- Intracranial Mesenchymal Tumour, FET::CREB Fusion-positive *2005*
- Capicua Transcriptional Repressor-rearranged Sarcoma *2006*
- Primary Intracranial Sarcoma *DICER1*-mutant *2007*
- Chordoma *2007*

12.6 Pituitary Adenomas/Pituitary Neuroendocrine Tumours, Sellar, and Suprasellar Lesions 2013
Geeta Chacko, Ranjani Jayachandran

- Pituitary Adenoma/Pituitary Neuroendocrine Tumour *2013*
- Pituitary Adenomas/Pituitary Neuroendocrine Tumours of Specific Cell Type *2014*
- Prognosis of Pituitary Adenoma/Pituitary Neuroendocrine Tumour *2022*
- Molecular Pathology *2022*
- Adamantinomatous Craniopharyngioma *2022*
- Pituicyte-derived Tumours *2024*
- Post-irradiation Sarcoma *2026*
- Non-neoplastic Lesions of the Sella Turcica *2026*

12.7 Lymphomas and Metastatic Tumours of Nervous System 2031
Yashaswini Nallacheruvu, Faiq Ahmed, Sundaram Challa

- Primary Diffuse Large B-cell Lymphoma of the Central Nervous System *2031*
- Immunodeficiency-associated Central Nervous System Lymphoma *2036*
- Lymphomatoid Granulomatosis *2037*

- Intravascular Large B-cell Lymphoma *2037*
- Miscellaneous Rare Lymphomas *2037*
- Metastases to the Central Nervous System *2038*

12.8 Cerebral Oedema in Relation to Neoplasia of Nervous System 2049
Pulak Nigam, Susarla Krishna Shankar, Mitra Ghosh

- Blood-brain Barrier *2050*
- Cerebrospinal Fluid and Hydrocephalus *2051*
- Aquaporins in the Brain *2052*
- Cerebral Oedema *2053*
- Cerebral Neoplasms and Associated Oedema *2054*
- Secondary Effects of Cerebral Oedema-elevated Intracranial Pressure *2057*
- Recent Advances *2058*

12.9 Tumour Markers in Tumours of Nervous System 2061
Deepti AN

- Types of Tumour Markers *2061*
- Methods to Detect Tumour Markers *2061*
- Tissue-based Tumour Markers *2062*
- Immunohistochemistry-based Diagnostic Tumour Markers *2062*
- Diagnostic and Prognostic Tumour Markers Detected by Molecular Methods *2068*
- Predictive Tumour Markers *2072*
- Emerging Biomarkers *2073*
- Liquid Biomarkers *2073*

12.10 Tumours of Cranial and Peripheral Nerves 2076
Lakshmi Manasa Perubhotla, Anita Mahadevan, Sundaram Challa

- Schwannoma *2076*
- Neurofibroma *2081*
- Perineurioma *2084*
- Hybrid Nerve Sheath Tumours *2085*
- Malignant Melanotic Nerve Sheath Tumour *2085*
- Malignant Peripheral Nerve Sheath Tumours *2086*
- Cauda Equina Neuroendocrine Tumour *2088*

12.11 Tumours of the Choroid Plexus 2092
Rajalakshmi P

- The World Health Organisation Classification *2092*
- Genetics, Epigenetics, and Molecular Features *2092*
- Choroid Plexus Papilloma *2092*
- Atypical Choroid Plexus Papilloma *2093*
- Choroid Plexus Carcinoma *2094*

12.12 Pineal Parenchymal Tumours 2097
Sushila Jaiswal

- Clinical Features *2097*
- Radiological Features *2097*
- Pineocytoma *2098*
- Pineal Parenchymal Tumour with Intermediate Differentiation *2099*
- Pineoblastoma *2101*
- Desmoplastic Myxoid Tumour: *SMARCB1*-mutant *2102*
- Papillary Tumour of the Pineal Region *2102*
- Pineal Anlage Tumour *2103*
- Mixed Pineocytoma-pineoblastoma *2103*

12.13 Glioneuronal and Neuronal Tumours 2105
Rajalakshmi P

- Ganglioglioma *2105*
- Gangliocytoma *2108*
- Desmoplastic Infantile Ganglioglioma and Desmoplastic Infantile Astrocytoma *2109*
- Dysembryoplastic Neuroepithelial Tumour *2109*
- Diffuse Glioneuronal Tumour with Oligodendroglioma-like Features and Nuclear Clusters *2112*
- Papillary Glioneuronal Tumour *2112*
- Rosette-forming Glioneuronal Tumour *2113*
- Myxoid Glioneuronal Tumour *2114*
- Diffuse Leptomeningeal Glioneuronal Tumour *2114*
- Multinodular and Vacuolating Neuronal Tumour *2116*
- Dysplastic Cerebellar Gangliocytoma (Lhermitte–Duclos Disease) *2117*
- Central Neurocytoma *2118*
- Extraventricular Neurocytoma *2120*
- Cerebellar Liponeurocytoma *2121*

12.14 Molecular Biology of Central Nervous System Tumours 2127
Anil Tarigopula, N Sadiya

- Gliomas, Glioneuronal, and Neuronal Tumours *2127*
- Glioblastoma *IDH* Wildtype *2129*
- Pilocytic Astrocytoma *2131*
- Glioneuronal and Neuronal Tumours *2135*
- Atypical Teratoid/Rhabdoid Tumour *2142*
- Cribriform Neuroepithelial Tumour *2143*
- Pineal Tumours *2143*
- Choroid Plexus Tumours *2146*
- Tumours of the Sellar Region *2150*
- Genetic Tumour Syndromes Involving the Central Nervous System *2150*
- Detection of Single Nucleotide Variations and Small Insertions/Deletions *2151*
- Detection of Copy Number Variations *2152*
- Detection of Fusions *2152*

12.15 Pathology of Adult-type Diffuse Gliomas 2158
Manali Ranade, Sridhar Epari

- Adult-type Diffuse Gliomas *2158*

VOLUME 3

Section 13: Cranial and Intracranial Tumours

Section Editors: **Anand Balasubramaniam, Aliasgar V Moiyadi**

13.1 Clinical Features of Intracranial Tumours..... 2169
Ravi Ramamurthi, Santosh Mohan Rao Kanangi

- Importance of Clinical Assessment *2169*
- Raised Intracranial Pressure—Pathogenesis *2170*
- Effects of Raised Intracranial Pressure on Various Structures *2170*
- Signs and Symptoms of Raised Intracranial Pressure *2171*
- Signs of Interference with Local Functions *2175*

13.2 Adult Diffuse Lower-grade Gliomas..... 2190
Aliasgar V Moiyadi, Salman T Shaikh

- Pathology/Classification Scheme of Adult Diffuse Gliomas (Including Molecular Biology) *2190*
- Epidemiology *2191*
- Pathophysiology and Natural History *2192*
- Clinical Features *2192*
- Diagnostic Evaluation *2192*
- Therapeutic Options *2196*
- Prognosis *2198*
- Management of Recurrences *2198*

13.3 Cerebellar Astrocytomas..... 2201
Ramakrishna Easwaran

- Historical Perspectives *2201*
- Incidence *2201*
- Classification of Cerebellar Glial and Neuronal Tumours *2201*
- Pathology *2201*
- Clinical Presentation *2205*
- Neuroradiology *2206*
- Management *2208*
- Prognosis *2211*

13.4 Brainstem Gliomas 2215
Poodipedi Sarat Chandra, Veer Singh Mehta

- Classification *2215*
- Pathology *2218*
- Clinical Features *2219*
- Neuroradiology *2221*
- Management *2221*

13.5 Hypothalamic–Optic Pathway Glioma 2227
Ramakrishna Easwaran

- Incidence *2227*
- Pathology *2227*
- Clinical Features *2229*
- Investigations *2230*
- Management *2231*
- Prognosis *2234*

13.6 Glioblastoma 2239
Aliasgar V Moiyadi, Rajesh Krishna Pathiyil

- Pathology *2239*
- Epidemiology *2241*
- Aetiology *2241*
- Pathogenesis *2241*
- Clinical Features *2242*
- Imaging *2243*
- Treatment *2245*
- Advances *2247*
- Prognosis *2249*
- Management of Recurrences *2249*

13.7 Ependymal Tumours 2256
Harjinder Singh Bhatoe, Mangalkumar Girish Rachatte, Poonam Mohanty

- Classification *2256*
- Incidence *2257*
- Origin *2257*
- Location *2257*
- Clinical Profile *2258*
- Pathology *2258*
- Imaging *2258*
- Spinal Ependymomas *2259*
- Management *2261*
- Adjunctive Therapy *2263*
- Prognosis *2264*
- Myxopapillary Ependymoma *2265*
- Parasacral Ependymomas *2265*
- Intra-abdominal Ependymomas *2265*

13.8 Medulloblastomas..... 2268
Bhawani Shanker Sharma, Anurag Srivastava

- Aetiology *2268*
- Pathophysiology *2268*
- Gross Appearance *2269*
- Histopathology *2269*
- Molecular Subtypes of Medulloblastoma *2269*
- Clinical Features *2272*

- Investigations *2272*
- Risk Stratification on Staging *2273*
- Management *2273*
- Radiation Therapy *2276*
- Chemotherapy *2277*
- Immunotherapy *2279*

13.9 Brain Metastasis 2283

Sarthak Mehta, Harsh Deora

- Epidemiology *2283*
- Mechanisms of Metastasis *2284*
- Molecular Signatures in Metastasis *2284*
- Clinical Presentation *2285*
- Targeted Therapies *2287*
- Leptomeningeal Disease *2293*
- Prognosis and Survival *2293*
- Quality of Life and Future Directions *2296*

13.10 Colloid Cysts 2297

Nigel Peter Symss, Ravi Ramamurthi

- Regional Embryology of the Third Ventricle *2297*
- Incidence *2297*
- Familial Colloid Cyst *2297*
- Incidental Colloid Cyst *2298*
- Natural History of Colloid Cysts of the Third Ventricle *2298*
- Pathology *2298*
- Location *2298*
- Clinical Features *2299*
- Investigations *2300*
- Differential Diagnosis *2301*
- Treatment *2301*
- Complication Avoidance in Transcallosal Transforaminal Approach to Colloid Cysts *2302*
- Endoscopic Approach for Colloid Cyst *2303*
- Endoscopic Versus Microsurgical Resection of Colloid Cysts *2303*
- Paediatric Colloid Cysts *2303*

13.11 Choroid Plexus Tumours 2306

MC Vasudevan, Krishna Kumar G

- History *2306*
- Aetiology and Epidemiology *2306*
- Clinical Course *2307*
- Investigations *2307*
- Treatment *2308*

13.12 Pineal Region Tumours: Clinical Features and Management 2311

Ramakrishna Easwaran

Introduction to the Pineal Gland *2311*

- History *2311*
- Nomenclature *2311*
- Anatomy *2311*
- Physiology *2311*
- Pathology *2312*
- Symptoms and Signs *2322*
- Neuroimaging *2325*
- Tumour Markers *2327*
- Management *2328*
- Prognosis *2331*

Surgical Approaches to Pineal Region Tumours *2331*

- Surgical Anatomy *2331*
- Endoscopic Approach *2332*
- Stereotactic Approach *2333*
- Microsurgical Approaches *2333*
- Infratentorial Supracerebellar Approach *2335*
- Occipital Transtentorial Approach *2336*
- Choosing the Best Surgical Approach *2338*

13.13 Pituitary Tumours: An Overview 2349

Ravi Ramamurthi, Anil Pande

- Historical *2349*
- Anatomy of the Pituitary Gland and its Surroundings *2349*
- Symptoms and Signs *2354*
- Treatment *2355*

13.14 Prolactinomas 2359

Sreenath Rajeev, Darshan Ravi, Vamshi Reddy, Niroop BS, Jabbar Khader, Deepti Narasimhaiah, Easwer Hariharan Venkat, Prakash Nair

- Epidemiology *2359*
- Physiology *2359*
- Pathology *2359*
- Lactotroph Pituitary Neuroendocrine Tumour *2360*
- Signs and Symptoms *2361*
- Investigations *2362*
- Biochemical Evaluation *2362*
- Magnetic Resonance Imaging in Prolactinoma *2363*
- Management *2363*
- Recent Advances in Therapeutics *2364*
- Cystic Prolactinoma *2366*

13.15 Growth Hormone-secreting Pituitary Adenomas 2369

HR Darshan, Sreenath Rajeev, Pooja Chaudhary, Jabbar Khader, Deepti Narasimhaiah, Rajalakshmi P, Easwer Hariharan Venkat, Prakash Nair

- Epidemiology *2369*
- Pathogenesis *2369*
- Clinical Features *2369*
- Investigations *2371*
- Imaging *2372*
- Pathology *2373*
- Treatment *2376*

13.16 Cushing's Disease and Syndrome 2382
Deepu Banerji, Sanjay Behari

- Normal Hypothalamic-pituitary-adrenal Axis *2382*
- Aetiopathology *2382*
- Clinical Features *2383*
- Endocrine Evaluation *2385*
- Diagnostic Evaluation *2386*
- Management *2387*

13.17 Other Secreting Adenomas of the Pituitary 2394
Deepu Banerji, Archana Juneja

- Physiology of the Pituitary Thyroid Axis *2394*
- Pathology *2394*
- Clinical Presentation *2395*
- Evaluation *2395*
- Dynamic Testing *2395*
- Radiological Diagnosis *2396*
- Therapy *2396*

13.18 Nonfunctioning Pituitary Adenoma 2399
Manas Kumar Panigrahi, M Manoranjitha Kumari, Ankur Patni

- Histopathological Classification *2399*
- Clinical Features *2401*
- Management of Nonfunctioning Pituitary Adenomas *2402*
- Treatment *2403*
- Outcome *2406*
- Hormonal Recovery After Surgery *2406*
- Follow-up *2407*
- Adjuvant Treatment *2407*

13.19 Pituitary Apoplexy 2410
Pranati Sharma, Anandh Balasubramaniam

- Historical Perspective *2410*
- Epidemiology *2410*
- Pathophysiology *2411*
- Precipitating Factors *2411*
- Presentation *2412*
- Grading *2413*
- Differential Diagnosis *2413*
- Imaging *2414*
- Management *2414*
- Outcomes *2415*
- Follow-up *2415*

13.20 Giant Invasive Pituitary Adenomas 2418
Atul Goel

- Historical Perspectives *2418*
- Cavernous Sinus Dural Walls—Relevance to Pituitary Surgery *2419*
- Giant Pituitary Tumours *2419*
- Surgical Strategy *2423*
- Radiation Treatment *2427*
- Bleeding and Pituitary Tumours/Pituitary Apoplexy *2428*
- Histological Examination *2428*

13.21 Perioperative Endocrine Management 2430
Leelavathy Kandaswamy, Murthy S

- Multidisciplinary Disease Management *2430*
- Preoperative Assessment *2430*
- Preoperative Management *2431*
- Early Postoperative Evaluation/Management (Up to 2 Weeks) *2432*
- Late Postoperative Evaluation/Management (After 1 Month) *2435*

13.22 Empty Sella Syndrome 2439
Ravi Ramamurthi, Murali Mohan S, Chaitanya RS

- Pathogenesis *2439*
- Primary Empty Sella *2440*
- Secondary Empty Sella *2443*

13.23 Diencephalic Syndrome 2447
Anil Pande

- Diencephalon *2447*
- Clinical Features *2447*
- Management *2449*
- Treatment *2450*
- Outcomes *2451*

13.24 Other Tumours of the Sellar Region 2453
Sanjay Behari, Anooj Chatley, Abrar Ahad Wani, Manoj Jain

- Pituitary Carcinoma *2453*
- Granular Cell Tumours *2455*
- Neurohypophyseal Gliomas *2455*
- Germ Cell Tumours *2456*
- Chordomas *2457*
- Metastatic Tumours to the Sellar Region *2458*
- Rathke's Cleft Cyst *2459*
- Hamartomas, Choristomas, and Gangliocytomas of the Sellar Region *2460*
- Tumour-like Conditions *2461*
- Lymphocytic Hypophysitis *2462*
- Mucocoele *2463*
- Sarcoidosis *2463*
- Histiocytosis X (Langerhans' Cell Histiocytosis) *2464*
- Cavernous Angioma of Cavernous Sinus *2464*
- Miscellaneous Tumours *2465*

13.25 Craniopharyngioma 2470
Suresh Sankhla, Anshu Warade, Ghulam M Khan

- Historical Perspective *2470*
- Pathology *2470*
- Incidence *2471*
- Clinical Features *2471*

- Endocrine Manifestations *2472*
- Imaging *2472*
- Treatment *2475*
- Genetics *2489*
- Treatment Summary *2490*

13.26 Paediatric Gliomas..... 2499
Siddharth Srinivasan, Ajay Hegde, Girish Menon

- Classification and Nomenclature *2499*
- Genetic/Molecular Characteristics of Paediatric Gliomas *2500*
- Clinical Presentation and Diagnosis *2501*
- Management *2501*
- Special Considerations *2504*
- Outcome and Prognosis *2504*

13.27 Dermoids and Epidermoids..... 2507
Ravi Ramamurthi, Amit Kapoor, Krishna Kumar G

- Epidermoids *2507*
- Dermoids *2514*

13.28 Teratomas..... 2520
Ravi Ramamurthi, Krishna Kumar G, Amit Kapoor

- Incidence *2520*
- Pathogenesis *2521*
- Pathology *2521*
- Clinical Features *2521*
- Imaging *2522*
- Treatment *2522*

13.29 Vestibular Schwannomas..... 2526
Sunil Kumar Gupta, Sushant Kumar Sahoo, Chandrashekhar Gendle, Ashish Aggarwal

- History and Evolution *2526*
- Epidemiology, Natural History, Clinical Features *2527*
- Natural History *2527*
- Clinical Features *2528*
- Surgical Anatomy of the Cerebellopontine Angle *2530*
- Pathology *2532*
- Neuroimaging of Vestibular Schwannoma *2534*
- Differential Diagnosis *2536*
- Neuro-otological Workshop *2537*
- Management Strategies *2539*
- Surgical Techniques *2540*
- Intraoperative Neuromonitoring during Vestibular Schwannoma Surgery *2544*
- Facial Nerve and Hearing Preservation *2546*
- Complications and their Management *2547*
- Gamma Knife Radiosurgery for Vestibular Schwannoma *2550*
- Targeted Therapy *2552*
- Bilateral Vestibular Schwannoma *2552*
- Controversies in Bilateral Vestibular Schwannoma Management *2553*
- Cystic Vestibular Schwannoma *2553*

13.30 Trigeminal Schwannomas..... 2561
Bhawani Shanker Sharma, Shashank R Ramdurg, Shubhrashankha Sen

- Surgical Anatomy *2561*
- Surgical Pathology *2561*
- Clinical Presentation *2562*
- Radiological Diagnosis *2563*
- Differential Diagnosis *2563*
- Surgical Techniques *2564*
- Postoperative Course *2566*
- Role of Radiosurgery *2566*

13.31 Jugular Foramen Lesions..... 2568
Siddhartha Ghosh, Anil Pande

- Anatomical Considerations *2568*
- Pathology *2569*
- Clinical Manifestations *2569*
- Neuroimaging *2570*
- Surgical Approaches *2571*
- Postoperative Complications *2577*

13.32 Other Intracranial Schwannomas..... 2581
Ashish Suri, Ravi Sharma, Shashwat Mishra

- Lower Cranial Nerve Schwannomas *2581*
- Facial Nerve Schwannomas *2584*
- Schwannomas of the Ocular Motor Nerves *2585*

13.33 Phakomatoses..... 2589
Kavindra Singh, Anant Mehrotra, Soumen Kanjilal, Kuntal Kanti Das, Awadhesh Kumar Jaiswal

- Neurofibromatosis *2589*
- Tuberous Sclerosis Complex *2594*
- Von Hippel–Lindau Disease *2596*
- Neurocutaneous Angiomatosis *2597*

13.34 Convexity Meningiomas..... 2600
MC Vasudevan, Krishna Kumar G

- Incidence *2600*
- Location *2600*
- Clinical Features *2600*
- Anterior Convexity Meningiomas *2601*
- Median Convexity Meningiomas *2601*
- Posterior Convexity Meningiomas *2601*
- Temporal Convexity Meningiomas *2601*
- Imaging *2601*
- Differential Diagnosis *2604*
- Surgical Management *2605*
- Prognosis *2606*
- Recurrence *2606*
- Long-term Outcome *2607*

13.35 Parasagittal and Falx Meningiomas 2610
MC Vasudevan, Krishna Kumar G

- Clinical Features *2610*
- Imaging *2611*
- Classification of Parasagittal Meningiomas Based on the Involvement of the Superior Sagittal Sinus *2612*
- Radiological Classification of Falcine Meningiomas and its Surgical Approaches *2614*
- Treatment *2615*
- Prognosis *2616*

13.36 Olfactory Groove Meningioma and Suprasellar Meningiomas 2618
Manas Kumar Panigrahi, Manoranjitha Kumari

- Operative Anatomy and Differential Diagnosis *2618*
- Clinical and Radiological Findings *2619*
- Surgical Approaches *2620*
- Outcome *2623*
- Other Modalities of Treatment and Recent Advances *2623*

13.37 Sphenoid Wing Meningiomas 2625
Ashutosh Kumar, Vandan Raiyani, Arun Kumar Srivastava, Sanjay Behari

- Classification of Sphenoid Wing Meningiomas *2625*
- Clinical Presentation *2627*
- Preoperative Evaluation *2629*
- Management *2630*
- Surgical Strategies for Lateral and Middle Sphenoid Wing Meningiomas *2630*
- Surgical Strategies for Clinoidal Meningiomas *2631*
- Surgical Strategies for Cavernous Meningiomas *2632*
- Surgical Strategies for Spheno-orbital Meningiomas *2633*
- Surgical Outcome *2633*
- Adjuvant Therapy *2635*

13.38 Tentorial Meningiomas 2640
Sanjay Behari, Suyash Singh

- Surgical Anatomy of the Tentorium Cerebelli *2640*
- Etiological Risk Factors for Tentorial Meningioma *2641*
- Symptomatology *2641*
- Radiological Evaluation of Tentorial Meningioma *2641*
- Classification of Tentorial Meningioma *2642*
- Preoperative Embolization for Tentorial Meningioma *2643*
- Management of Tentorial Meningioma *2643*
- Microsurgical Nuances and Corridors for Tentorial Meningioma *2643*
- Prognosis of Tentorial Meningioma *2648*

13.39 Posterior Fossa Meningiomas 2651
Amitabha Chanda

- Epidemiology *2651*
- Aetiopathogenesis and Pathology *2651*
- Classification *2654*
- Clinical Features *2655*
- Imaging Studies *2658*
- Diagnostic Challenges *2661*
- Treatment *2661*
- Results and Prognosis *2671*

13.40 Petroclival Meningiomas 2678
Suresh Nair, Adesh Shrivastava, Girish Menon, B Ravimohan Rao, Mathew Abraham

- Surgical Anatomy *2678*
- Radiological Evaluation *2679*
- Surgical Management of Petroclival Meningiomas *2679*
- Retrosigmoid Approach *2680*
- Lateral Transpetrosal Approaches *2680*
- Anterolateral Approaches *2683*
- Anterior Endonasal Endoscopic Approach *2684*
- Role of Radiosurgery for Petroclival Meningiomas *2685*

13.41 Foramen Magnum Meningiomas 2687
Roee Ber, Shrivastava RK, Chandranath Sen

- Tumours at the Foramen Magnum *2688*
- General Perioperative Evaluation *2688*
- Posterior/Posterolateral Suboccipital Approach *2689*
- Extreme Lateral Transcondylar Approach *2690*
- Extended Endoscopic Endonasal Approaches to Skull Base *2693*
- Radiosurgery *2695*

13.42 Intraventricular Meningiomas 2697
Harjinder Singh Bhatoe, Prakash Singh, Vibha Dutta

- Origin *2697*
- Pathology and Clinical Course *2698*
- Imaging *2698*
- Surgical Management *2700*
- Results Following Surgery *2701*
- Histopathology *2702*

13.43 Haemangioblastoma 2704
Dwarakanath Srinivas, Keyur Gopal Bhai Shah

- History *2704*
- Epidemiology *2704*
- Clinical Features *2704*

- Radiological Features *2706*
- Von Hippel–Lindau Disease *2706*
- Natural History *2707*
- Pathogenesis *2708*
- Management *2709*
- Surgical Resection *2710*

13.44 Primary Central Nervous System Lymphomas 2721
Shreyash Rai, Kuntal Kanti Das, Awadhesh Kumar Jaiswal, Sanjay Behari

- Epidemiology *2721*
- Pathology of Primary Central Nervous System Lymphoma *2721*
- Diagnostic Criteria for Primary Diffuse Large B-cell Lymphoma of the Central Nervous System *2722*
- Clinical Presentation *2722*
- Conditions Associated with Increased Risk of Primary CNS Lymphomas *2723*
- Investigations *2723*
- Management *2725*

13.45 Intracranial Melanomas and Other Tumours 2730
Bhawani Shanker Sharma, Harsh Deora, Sumit Sinha

- Classification of Pigmented Tumours in the Central Nervous System *2730*
- Pathological and Genetic Alterations *2730*
- Solitary Versus Diffuse Primary Intracranial Melanomas *2730*
- Primary Pigmented Lesions *2731*
- Other Pigmented Central Nervous System Lesions *2735*

13.46 Tumours of the Skull 2737
Ravi Ramamurthi, Anil Jackson

- Incidence *2737*
- Anatomical Considerations *2737*
- Classification *2737*
- Diagnostic Evaluation *2738*
- Management *2739*
- Primary Tumours of the Skull *2741*
- Tumours Involving the Skull by Direct Extension *2748*
- Pseudotumours *2752*

13.47 Clival Chordomas..... 2763
Chandranath Sen, Zane Schnurman

- Natural History *2763*
- Pathological Features *2763*
- Clinical Features *2763*
- Imaging Features *2764*
- Principles of Surgical Management *2764*
- Radiation Treatment *2766*
- Outcomes after Adoption of the Endoscopic Endonasal Approach *2766*
- Illustrative Cases *2767*

13.48 Overview of Radiation Therapies in Central Nervous System Malignant Tumours..... 2774
Resham Srivastava, Shaleen Kumar

- Epidemiology of Brain Tumours *2774*
- Aetiology *2774*
- Classification *2774*
- Principles of Radiotherapy *2774*
- Stereotactic Radiotherapy and Stereotactic Radiosurgery *2775*

13.49 Adjuvant Therapies for Malignant Brain Tumours 2786
Ved Prakash Maurya, Raj Kumar, Ashok Kumar Mahapatra

- Chemotherapy *2786*
- Blood-brain Barrier *2786*
- Tumour Heterogeneity *2787*
- Drug-drug Interaction *2787*
- Tumour Resistance *2787*
- Newly Diagnosed Glioblastoma *2787*
- Treatment of Recurrent Gliomas *2788*
- Immunotherapy *2788*
- Gene Therapy *2790*
- Genome Editing Therapies *2790*
- Target Therapies *2790*
- P53 Replacement *2790*

Section 14: Skull Base Surgery

Section Editor: **Deepu Banerji**

14.1 Skull Base Surgery: An Overview 2795
Sunil Kumar Gupta, Pravin Salunke, Sivashanmugam Dhandapani

- History and Evolution of Skull Base Surgery *2795*
- Principles of Skull Base Surgery *2796*
- Transition in Surgical Management of Skull Base Tumours *2804*

14.2 Approaches to the Lateral Skull Base 2807
Atul Goel, Dattatraya Mazumdar

- Ideal Approach *2807*
- Surgical Considerations *2807*
- Surgical Approaches to the Lateral Skull Base *2809*
- Selection of Approaches *2829*

14.3 Reconstruction of the Skull Convexity and Base 2837
Atul Goel, Dattatraya Mazumdar

- History *2837*
- Anatomical Considerations *2838*
- Surgical Considerations *2838*

14.4 Orbital Tumours 2853
Aadil S Chagla

- Gross Surgical Anatomy *2853*
- Types and Incidence of Orbital Tumours *2856*
- Clinical Features of Orbital Tumours *2857*
- Investigations *2859*
- Management of Orbital Tumours *2860*
- Different Orbital Tumours *2866*

14.5 Surgical Approaches to Anterior Skull Base 2874
Sivashanmugam Dhandapani, Apinderpreet Singh

- Anatomical Background *2874*
- Choosing the Optimal Approach *2875*
- Minimal Invasive or Keyhole Anterior Skull Base Approaches *2876*
- Lateral Approaches *2876*
- Pterional Approach *2876*
- Orbito-pterional and Orbito-zygomatic variants *2877*
- Median Approaches *2879*
- Frontal/Bifrontal Approach *2879*
- Fronto-orbital/Basal (extended) Bifrontal Approach *2880*
- Minimal Invasive/Keyhole Approaches *2880*
- Lateral Supraorbital Keyhole Approach *2881*
- Subarachnoid Access and Corridors *2882*

Section 15: Craniovertebral Junction

Section Editor: **Pravin Salunke**

15.1 Evaluation of Congenital Craniovertebral Junction Anomalies 2887
Karthigeyan Madhivanan, Pravin Salunke

- Relevant Embryology *2887*
- Pathogenesis Underlying Craniovertebral Junction Instability *2888*
- Clinical Features *2889*
- Specific Anomalies *2893*
- Imaging the Craniovertebral Junction *2894*

15.2 Management of Craniovertebral Junction Anomalies: Anterior Approach 2900
Sushil Vasant Patkar, Pradnya Patkar

- Evolution of Anterior Craniovertebral Surgery *2900*
- Anterior Unilateral Submandibular Retropharyngeal Technique for Craniovertebral Anomalies *2901*
- Complications *2907*
- Discussion *2908*
- Rationale for Revival of Anterior Approach to Craniovertebral Junction *2910*

15.3 Basilar Invagination and Atlantoaxial Dislocation: Reduction, Deformity Correction, and Realignment Using the DCER Technique 2916
Poodipedi Sarat Chandra

- Indications *2916*
- Investigations *2917*
- Planning Surgical Strategy *2918*
- Postoperative Management *2930*
- Discussion *2931*

15.4 Management of Congenital Craniovertebral Junction Anomalies and Instability 2936
Karthigeyan Madhivanan, Pravin Salunke

- C1–2 Joints—Perfect Combination of form and Function *2936*
- Congenital Osseous Anomalies and the Concept of Progressive Multiplanar Instability *2937*
- Preoperative Radiological Evaluation *2938*
- Surgical Correction *2940*
- Use of Intraoperative Adjuncts *2947*
- Postoperative Care and Follow-up *2947*
- Complications and Avoidance *2948*
- Alternative Surgical Techniques to Manage Craniovertebral Junction Anomalies—Pros and Cons *2950*
- Special Considerations *2953*
- Future *2954*

15.5 Craniovertebral Junction Tumours 2958
Arun Kumar Srivastava

- Tumours of the Craniovertebral Junction *2958*
- Clinical Presentation *2959*
- Diagnostic Evaluation *2959*
- Surgical Approaches to Craniovertebral Junction Tumours *2964*
- Posterior Surgical Approaches to the Craniovertebral Junction *2965*
- Approach Selection *2967*

15.6 Complications and their Avoidance in Surgery for Complex Craniovertebral Junction Anomalies 2970
Komal Prasad Chandrachari

- Surgery at the Craniovertebral Junction *2971*
- Complications of Surgery for Complex Craniovertebral Junction Anomalies *2971*
- Tools and Techniques for Reducing Complications *2972*

15.7 Transpharyngeal Approach to Craniovertebral Junction 2977
Arnold H Menezes

- Assessment of Nutritional Status *2978*
- Decision Tree for Treatment of Craniocervical Junction Abnormalities *2979*

- Preoperative Cervical Traction *2980*
- Operative Technique of the Transoral–Transpalatopharyngeal Approach *2981*
- Special Circumstances *2983*
- Postoperative Management *2984*
- Management of Immediate Postoperative Complications as well as Delayed Complications *2986*
- Lessons Learnt from the Trans-oropharyngeal Approach to the Craniovertebral and Cervicomedullary Junction *2986*

15.8 Chiari Malformations 2988
Rabi Narayan Sahu, Karthigeyan Madhivanan, Pravin Salunke, Sunil Kumar Gupta

- History *2988*
- Types of Chiari Malformation *2988*
- Pathophysiological Differences *2990*
- Clinical Presentation *2990*
- Pathophysiology *2992*
- Diagnostic Evaluation *2992*
- Management Considerations *2993*
- Trends and Controversies in Management *2995*
- Treatment Complications *2998*
- Chiari Malformation in Craniosynostosis *2998*
- Disease Prognosis *2999*

Section 16: Stereotaxy

Section Editor: **Manjul Tripathi**

16.1 Stereotaxy: General Principles 3005
Jitin Bajaj, Manjul Tripathi

- History *3005*
- Equipment *3005*
- Stereotactic Frame *3006*
- The Centre of Arc Principle *3006*
- Indications for Stereotactic Surgery *3006*
- Workflow of Stereotactic Brain Surgery *3007*
- Robotic Systems *3010*
- Complications *3011*
- Pearls and Pitfalls *3011*

16.2 Stereotaxy for Brain Tumours 3013
Jitin Bajaj, Manjul Tripathi

- Setup *3013*
- Indications of Stereotaxy for Brain Tumours *3013*
- Complication Avoidance *3014*
- Future Implications *3015*
- Case Scenarios *3015*

16.3 Involuntary Movements: Anatomy and Pathophysiology 3018
Srinivasan AV

- Major Basal Ganglia Pathways *3019*
- Functional Organisation of the Basal Ganglia and Other Pathways *3020*

16.4 Surgical Management of Parkinson's Disease 3023
Shejoy P Joshua, Dilip Panikar

- Physiological Basis for Interventions *3023*
- History *3023*
- Electrophysiology: Microelectrode Recording *3026*
- Stereotactic Principles and Technique *3027*
- Lesioning Procedures *3029*
- Deep Brain Stimulation *3030*
- Programming *3031*
- Outcomes *3031*
- Complications *3032*
- Alternate Targets, Newer Techniques, and Advances in Technology *3033*
- Advances in Technology *3035*
- Newer Techniques *3036*

16.5 Surgery for Movement Disorders 3041
Paresh Kishorchandra Doshi, Raghuram Gopalakrishnan

- History of Movement Disorder Surgery in India *3041*
- History of Movement Disorder Surgery—World (Excluding India) *3041*
- Tremors *3042*
- Dystonia *3045*
- Complications *3047*
- Surgery for Movement Disorders: Future Directions *3048*

16.6 Gamma Knife Radiosurgery 3056
Nishanth Sadashiva, Manjul Tripathi

- History and Evolution of Gamma Knife Radiosurgery *3056*
- Current Uses of Gamma Knife Radiosurgery *3061*

16.7 Psychosurgery 3075
Ravi Ramamurthi, Santosh Mohan Rao Kanangi, Balasubramaniam

- History of Psychosurgery *3075*
- Limbic System Anatomy—Newer Perspectives *3077*
- Hypothalamus *3082*
- Classification of Psychiatric Disorders—an Outline *3084*

- An Overview of the Common Psychiatric Maladies Amenable to Psychosurgery (Neuroanatomy and Clinical Features) *3084*
- Imaging in Psychiatry *3085*
- Procedures Used in Modern Psychosurgery *3086*
- Outcome Measurements in Psychosurgery *3096*
- Newer Modalities of Treatment in Psychosurgery *3097*
- Ethics of Functional Neurosurgery *3100*
- Appendix 1: The Yale-Brown Obsessive-Compulsive Scale (Y-BOCS) *3101*
- Appendix 2: Item Hamilton Rating Scale for Depression *3102*

16.8 Robotics in Neurosurgery 3108
Ramesh Doddamani, Poodipedi Sarat Chandra

- Historical Perspective *3108*
- Types of Robots *3108*
- Applications in Neurosurgery *3109*

16.9 Neural Transplantation and Stem Cell 3133
Prakash Narain Tandon, Manjul Tripathi, Tiainla Jamir

- Historical Background *3133*
- Embryonic Stem Cells *3135*
- Nine Myths About Stem Cells *3138*
- Other Uses of Stem Cells *3140*
- Expansion of Haematopoietic Stem Cells *3140*
- Recent Advances *3141*

16.10 Stereotaxy for Cerebral Palsy 3147
Sampathkumar M, Pawan Kumar Verma, TS Kanaka, Ramamurthi Balasubramaniam

- Historical Aspects *3147*
- Definition *3147*
- Aetiology *3147*
- Pathophysiology *3148*
- Clinical Features *3148*
- Classification of Cerebral Palsy *3149*
- Management *3149*

VOLUME 4

Section 17: Pain

Section Editor: **Ramakrishna Easwaran**

17.1 Pain: Anatomy and Physiology 3163
Ravi Ramamurthi, Santosh Mohan Rao Kanangi

- Definitions of Pain *3163*
- Anatomical and Physiological Considerations *3164*
- Organisation of the Spinal Cord *3166*
- Pain Pathways in the Spinal Cord *3168*
- Neuropharmacology of Pain *3171*
- Chronic Pain Syndromes *3173*
- Neuropathic Pain *3177*
- Chronic Regional Pain Syndrome *3177*
- References *3182*

17.2 Neurosurgical Management of Pain 3186
Rushabh Mulchand Chheda, Ashutosh Kumar, Jayesh Sardhara

- Classification *3186*
- Recent Updates *3186*
- History of Pain Surgery *3187*
- Treatment Strategies *3187*
- Current Status and Future Directions *3199*

17.3 Trigeminal Neuralgia 3204
Ramakrishna Easwaran

- History *3204*
- Surgical Anatomy of the Trigeminal Nerve *3204*
- Incidence *3205*
- Diagnostic Classification and Criteria *3206*
- Clinical Features *3206*
- Differential Diagnosis *3208*
- Pathology *3209*
- Imaging *3212*
- Treatment *3213*

17.4 Glossopharyngeal and Other Cranio-facial Neuralgias 3227
Priyadarshi Dikshit, Soumen Kanjilal, Shreyash Rai, Anil Kumar Bhoohalli Chikkanna, Sasapardhi Sudhir Bisan, Awadhesh Kumar Jaiswal

- Glossopharyngeal Neuralgia *3227*
- Treatment *3229*
- Geniculate Neuralgia *3232*
- Sphenopalatine (Sluder) Neuralgia *3233*
- Miscellaneous Neuralgias *3234*

17.5 Microvascular Decompression 3238
Soumen Kanjilal, Awadhesh Kumar Jaiswal, Pawan Kumar Verma, Anant Mehrotra, Kuntal Kanti Das, Priyadarshi Dikshit

- Pathophysiology *3238*
- Factors Influencing Neurovascular Compression *3239*
- Trigeminal Neuralgia *3239*
- Hemifacial Spasm *3244*
- Essential Hypertension *3245*

- Type 2 Diabetes Mellitus and Dyslipidaemia *3246*
- Glossopharyngeal Neuralgia *3246*

17.6 Regional Block for Neurosurgeons 3248
Devendra Gupta, Nidhi Singh

- Regional Anaesthesia Technique for Cranial Surgeries *3249*
- Anaesthesia Techniques for Spine Surgeries *3254*

17.7 Interventions for Pain Management..... 3270
Mary Abraham

- Lateral Cutaneous Nerve of the Thigh Block *3271*
- Epidural Steroid Injections *3271*
- Pain Procedures for Facet Joint Arthropathy *3275*
- Sacro-iliac Joint Procedures *3277*
- Sympathetic Blocks *3278*
- Head and Neck Pain Blocks *3280*

Section 18: Epilepsy

Section Editor: **Poodipedi Sarat Chandra**

18.1 Epilepsy: An Overview..... 3285
Dinesh Nayak S, Radhakrishnan K

- Magnitude of the Problem *3285*
- Basic Mechanisms of Epileptogenesis *3286*
- Classification of Seizures and Epilepsies *3286*
- Genetics of Epilepsies *3288*
- Natural History of Epilepsies *3289*
- Differential Diagnosis of Epilepsies *3290*
- Investigation of Epilepsies *3291*
- Neuropathology of Epilepsies *3295*
- Treatment of Epilepsies *3296*
- Community Awareness and Attitude Towards Epilepsy *3297*
- Problems Associated with Long-standing Epilepsy *3297*

18.2 The Molecular and Cellular Basis of Epileptogenesis..... 3301
Arpna Srivastava, Sonali Kumar, Aparna Banerjee Dixit, Jyotirmoy Banerjee

- Epileptogenesis *3301*
- Molecular and Cellular Basis of Epileptogenesis *3302*
- Role of Kinases in Epileptogenesis *3308*
- Histone Modifications *3309*
- Methylation *3309*
- Noncoding RNAs *3310*
- Role of Glia in Epilepsy *3310*
- Therapeutic Implications *3311*

18.3 Neuropathology of Drug-refractory Epileptic Lesions..... 3318
Rakesh Kumar Gupta, Mehar Chand Sharma

- Causes *3318*
- Proposed Amendments to the ilae Classification Scheme of Focal Cortical Dysplasia *3323*
- mMCD with Oligodendroglial Hyperplasia in Epilepsy *3323*
- Tumours and Epilepsy *3323*

18.4 Medical Management of Epilepsy..... 3328
Jasmine Parihar, Manjari Tripathi

- Classification of Seizures and Epilepsy *3328*
- Mechanism of Action of Anti-seizure Medications *3329*
- Management of Epilepsy *3329*
- Medical Therapy *3330*
- Treatment of Underlying Condition *3333*
- Identifying and Avoiding Precipitating Factors *3333*
- Surgical Treatment of Epilepsy *3333*
- Management of Status Epilepticus *3333*
- Other Modes of Management *3333*

18.5 Post-traumatic Epilepsy 3336
Raghu Samala, Manjari Tripathi, Poodipedi Sarat Chandra

- Risk Factors *3336*
- Pathophysiology *3337*
- Diagnosis *3338*
- Role of Antiepileptic Drugs *3339*
- Role of Surgery *3340*
- Our Experience *3341*
- Illustrative Cases *3341*
- New Areas of Research *3342*

18.6 Neuropsychological Assessment as a Part of Preoperative Workup for Persons with Drug-resistant Epilepsy..... 3345
Ashima Nehra, Shivani Sharma

- What is the Role of Neuropsychological Assessment in Drug Refractory Epilepsy and Why is it Important? *3345*
- How Can the Neuropsychological Assessment Help the Clinician? *3346*
- How can the Clinician Aid the Neuropsychological Assessment? *3347*
- How can the Neuropsychological Assessment Benefit the Patient? *3347*
- What is Cognitive Screening and How it is Different from Neuropsychological Assessment? *3348*
- Next Obvious Question then is, Who can Carry out Screening and Assessment? and Where? *3348*

- How can Neuropsychological Assessment be done and What are the Important Considerations in Interpreting these Results? *3349*
- If Advisable, when should the Assessment be done? *3349*

18.7 Role of Single-photon Emission Computed Tomography and Positron Emission Tomography for Epilepsy Surgery 3352
Madhavi Tripathi, Prateek Kaushik, Chandrasekhar Bal

- Radiotracers in PET and SPECT and their Mechanisms of Uptake *3352*
- Pathophysiological Basis of Perfusion SPECT and FDG-PET/CT *3352*
- Interpretation of Brain Perfusion Single-photon Emission Computed Tomography *3354*
- Interpretation of FDG-PET/CT *3354*
- Current Evidence and Recommendations on Use of SPECT and PET in DRE *3355*
- Positron Emission Tomography in Autoimmune Epilepsy *3356*

18.8 The Stereo Electroencephalography (SEEG) and Other Invasive EEG Techniques 3360
Manjari Tripathi, Poodipedi Sarat Chandra

- Invasive Electroencephalography *3360*
- Technique of Stereoelectroencephalography *3363*
- Outcomes of Stereoelectroencephalography Monitoring followed by Surgery *3366*

18.9 Magnetoencephalography for Epilepsy 3368
Manjari Tripathi, Jasmine Parihar, Kirandeep Kaur

- Magnetoencephalography: An Overview *3368*
- Source Localisation of Ictal and Interictal Discharges in Magnetoencephalography *3370*
- Magnetoencephalography in Comparison to Other Neuroimaging Modalities *3372*
- Utility of Magnetoencephalography in Presurgical Evaluation for Epilepsy *3372*
- Looking Ahead: Exciting Avenues for Research in Magnetoencephalography *3374*

18.10 Intraoperative Electrocorticography 3377
Manjari Tripathi, Poodipedi Sarat Chandra

- Historical Background *3377*
- Indications *3377*
- Potential Advantages of Electrocorticography *3379*
- Limitations of Electrocorticography *3380*

18.11 Surgery for Epilepsy: General Principles 3384
Poodipedi Sarat Chandra, Ramesh Doddamani, Madhavi Tripathi, Chandrasekhar Bal, Ajay Garg, Manjari Tripathi

- Burden of Epilepsy Surgery in India *3385*
- Pre-operative Evaluation and Indications for Epilepsy Surgery *3385*
- Temporal Lobe epilepsy *3389*
- Focal Cortical Dysplasias *3391*
- Long-term Outcomes of Epilepsy Surgery *3391*
- Neuromodulation *3394*

18.12 Surgery for Temporal Lobe Epilepsy 3397
Malla Bhaskara Rao, Jayanti Mani, Ajinkya Rewatkar

- Pathology *3397*
- Presurgical Evaluation *3398*
- Surgical Treatment *3402*
- Outcome Assessment *3406*

18.13 Hemispherectomy/Hemispherotomy and Multilobar Resections/Disconnections 3409
Poodipedi Sarat Chandra, George Dorfmuller

Hemispherectomy/Hemispherotomy *3409*
- Historical Perspective *3409*
- Pathology *3410*
- Preoperative Investigations *3411*
- Aetiology, Natural History, and Timing of Surgery *3414*
- Goals of Surgery *3414*
- Surgical Approaches *3414*
- Outcomes and Complications of Hemispherotomy *3441*

Multilobar Resections and Disconnections *3444*
- Underlying Pathologies *3444*
- Presurgical Evaluation *3444*
- Structural and Functional Imaging *3445*
- Surgery *3445*
- Multilobar Resection for Epilepsy—Published Series *3450*
- Surgical Outcomes *3451*
- Complications *3451*

18.14 Corpus Callosotomy for Drug-resistant Epilepsy 3458
Mohit Agarwal, Manjari Tripathi, Poodipedi Sarat Chandra

- Rationale of Corpus Callosotomy *3458*
- Surgical Procedure *3459*
- Outcome *3459*
- Complications *3461*
- Recent Advances in Surgical Techniques *3461*

18.15 Multiple Subpial Transection Surgery for Epilepsy 3464
Nishanth Sadashiva, Arivazhagan Arimappamagan

- Rationale of the Procedure *3464*
- Patient Selection *3464*
- Surgical Procedure *3465*
- Hippocampal Multiple Subpial Transection *3465*
- Surgical Outcomes *3466*

18.16 Hypothalamic Hamartomas: Overview and Current Concepts in Management 3469
Ramesh Doddamani, Manjari Tripathi, Poodipedi Sarat Chandra

- Epidemiology and Aetiopathogenesis *3469*
- Clinical Presentation *3469*
- Evaluation of Hypothalamic Hamartoma *3471*
- Management of Hypothalamic Hamartoma *3471*

18.17 Vagal Nerve Stimulation for Drug Refractory Epilepsy and Other Methods of Neuromodulation 3481
Poodipedi Sarat Chandra, Ramesh Doddamani, Manjari Tripathi

- Vagal Nerve Stimulation *3481*
- Deep Brain Stimulation for Epilepsy *3488*
- Responsive Neurostimulation *3489*
- Other Targets for Neuromodulation *3489*

18.18 Long-term Outcomes of Epilepsy Surgery and Post-Epilepsy Pharmacotherapy 3491
Poodipedi Sarat Chandra, Ramesh Doddamani, Manjari Tripathi

- Assessment of Seizure Outcomes *3491*
- Quality of Life and Memory following Epilepsy Surgery *3491*
- Does Surgery "Cure" the Patients? *3492*
- Predictors of Outcome *3493*
- Withdrawal of Antiseizure Medication Following Epilepsy Surgery *3493*

Section 19: Movement Disorders

Section Editor: **Milind Deogaonkar**

19.1 Classification of Movement Disorders..... 3497
Adreesh Mukherjee, Sanjay Pandey

- Parkinsonian (Hypokinetic) Disorders *3497*
- Hyperkinetic Disorders *3500*
- Genetic Nomenclature *3502*

19.2 Cerebral Circuits Responsible for Movement Disorders 3504
Pawan Kumar Verma, Kuntal Kanti Das

- Cerebral Circuits of Movement: Anatomical Consideration *3504*
- Normal Neurophysiology of Movements *3506*
- Neurophysiology of Movement Disorders *3507*
- Anatomical Principle of Surgical Treatment *3509*

19.3 Medical Management for Movement Disorders 3514
Hema Krishna P, Asish Vijayaraghavan, Divya KP, Syam Krishnan

- Medical Management of Parkinsonism *3515*
- Management of Motor Symptoms *3516*
- Other Drugs for Parkinsonism *3518*
- Management of Hyperkinetic Movement Disorders *3519*
- Treatment of Other Hyperkinetic Disorders *3523*

19.4 Deep Brain Stimulation for Movement Disorders 3527
Krishnakumar Kesavapisharady

- Mechanism of Deep Brain Stimulation *3527*
- Indications for Deep Brain Stimulation *3527*
- Deep Brain Stimulation Workflow *3528*
- Deep Brain Stimulation Targets *3528*
- Surgical Steps in Deep Brain Stimulation *3528*
- Long-term Outcome of Deep Brain Stimulation *3530*
- Complications of Deep Brain Stimulation *3530*
- Recent Advances *3531*

19.5 Parkinson's Disease 3533
Priyanka Samal, Sachidananda Swain, Vinay Goyal

- History *3533*
- Epidemiology *3533*
- Risk Factors *3533*
- Genetics in Parkinson's Disease *3534*
- Pathophysiology *3534*
- Clinical Features *3534*
- Other Motor Features and Deformity *3536*
- Management of Parkinson's Disease *3537*
- Pharmacological Treatment of Parkinson's Disease *3537*
- Drugs Used in Parkinson's Disease *3537*
- Treatment of Parkinson's Disease *3538*
- Non-pharmacological Treatment of Parkinson's Disease *3538*
- Surgical Therapy *3538*
- Deep Brain Stimulation *3539*
- Levodopa-carbidopa Intestinal Gel *3539*

19.6 Dystonia 3543
Manmohan Singh, Roopa Rajan, Kanwaljeet Garg

- Definition and Classification *3543*
- Evaluation of Dystonia *3544*
- Medical Management of Dystonia *3544*
- Surgical Management *3544*

19.7 Paediatric Movement Disorders 3551
Mahendra Thakre, Divyani Garg, Charulata Savant Sankhla

- Epidemiology *3551*
- Classification of Paediatric Movement Disorder *3552*
- Hyperkinetic Disorders *3552*
- Ataxia in Children *3560*

- Benign Paroxysmal Movement Disorders in Childhood *3563*
- Hypokinetic Movement Disorders *3563*
- Functional Movement Disorders *3564*
- Approach to the Child with a Movement Disorder *3566*

19.8 Botulinum Toxin in Movement Disorder 3569
Jayantee Kalita, Nagendra B Gutti

- Mechanism of Action *3569*
- Botulinum Toxin in Movement Disorders *3570*
- Role of Botulinum Toxins in Other Movement Disorders *3596*

19.9 Expanding Indications of Deep Brain Stimulation 3600
Raj Agarbattiwala, Paresh Kishorchandra Doshi

- Indications in Movement Disorders *3600*
- Indications in Psychiatric Disorders *3601*
- Indications in Other Neurological Disorders *3603*

19.10 Lesional Surgery for Movement Disorders 3607
Milind Sankhe, Bharat Jain, Pooja Salunkhe

- History *3607*
- Indications *3607*
- Targeting and Localisation *3608*
- Neurophysiological Localisation *3610*
- Procedure *3611*
- Complications *3613*
- Advantages of Lesioning *3613*
- Lesioning Modalities *3613*

19.11 Radiosurgery for Movement Disorders 3618
Aman Batish, Kanwaljeet Garg, Manjul Tripathi

- Movement Disorders Commonly Treated Using Gamma Knife Lesioning *3618*
- Patient Selection for Gamma Knife Lesioning *3619*
- Procedural Considerations for Gamma Knife Lesioning *3619*
- Indications *3619*
- Outcomes and Complications *3620*
- Advantages and Disadvantages of Gamma Knife Lesioning over Other Lesioning Techniques *3624*

19.12 Rarer Movement Disorders and their Management..... 3627
Milind Deogaonkar

- Classification of Rare Movement Disorders *3627*
- Uniqueness in Management of Rare Movement Disorders *3628*
- Progressive Supranuclear Palsy *3628*
- Multiple System Atrophy *3629*
- Corticobasal Degeneration *3629*
- Kufer–Rakeb Syndrome *3630*
- Hereditary Ataxias *3630*
- Hereditary Spastic Paraparesis *3631*
- Dystonia *3631*
- Chorea *3632*

Section 20: Neuro-endoscopy

Section Editors: **YR Yadav, Jitin Bajaj**

20.1 Developmental Overview of Neuroendoscopy 3637
Dattaraj Parmanand Sawarkar, Mohit Agrawal

- History of Endoscopy *3637*
- Initial Development of Neuroendoscopy *3638*
- Decline of Neuroendoscopy *3639*
- Technological Advances and Revival of Neuroendoscopy *3639*
- Current Perspective *3639*
- History of Neuroendoscopy in India *3640*

20.2 Neuroendoscopy: Scope and Controversy 3643
Yad Ram Yadav, Jitin Bajaj

- Advantages and Limitations *3643*
- Learning Curve in Endoscopy *3643*
- Controversies in Neuroendoscopy *3643*
- Future of Endoscopy *3644*

20.3 Learning Neuroendoscopy: Tip and Tricks..... 3646
Yad Ram Yadav, Jitin Bajaj, Shailendra Ratre, Muddaiah Narayana Swamy, Vijay Parihar, Mallika Sinha, Ketan Hedaoo, Jitendra Shakya, Mukesh Sharma, Jayant Patidar

- Advantages and Limitations of Endoscopy *3646*
- Learning Endoscopy *3647*
- Adjuvants in Endoscopic Learning *3658*
- How to Assess Competency? *3658*
- Which Model is Better for Learning? *3659*
- Is Skills Transfer Possible from one Method to Another? *3659*
- Skill Laboratory in Training Neuroendoscopy *3659*
- Status of Simulation Training for Residents in India *3659*

20.4 Endoscopic Third Ventriculostomy: Indications, Technique, and Controversies..... 3663
Subodh Raju, Abhirama Chandra Gabbita

- History and Evolution of Endoscopic Third Ventriculostomy *3663*
- Indications for Endoscopic Third Ventriculostomy *3663*
- Contraindications for Endoscopic Third Ventriculostomy (Relative) *3665*
- Preoperative Imaging *3665*

- Favourable Radiological Features *3665*
- Operative Technique *3665*
- Alternative Sites *3668*
- Adjuncts *3668*
- Endoscopic Third Ventriculostomy Success Score *3669*
- Outcome *3669*
- Complications *3670*
- Controversies *3670*

20.5 Endoscopic Third Ventriculostomy: Complication Avoidance 3674
Yad Ram Yadav, Jitin Bajaj, Shailendra Ratre, Muddaiah Narayana Swamy, Vijay Parihar, Mallika Sinha, Ketan Hedaoo, Jitendra Shakya, Mukesh Sharma, Jayant Patidar

- Complications and their Avoidance *3674*
- Intraventricular Bleeding and its Prevention *3675*

20.6 Secondary Endoscopic Third Ventriculostomy 3680
Vikram S Karmarkar, Chandrashekhar Eknath Deopujari

- Ventriculoperitoneal Shunts and Endoscopic Third Ventriculostomy *3680*
- Technique *3681*
- Challenges/Complications *3685*
- Rationale and Literature *3688*

20.7 Flexible Neuro-endoscopy 3690
Subodh Raju

- History and Evolution *3690*
- Evolution *3691*
- Design *3691*
- Complications *3701*

20.8 Endoscopic Management of Deep-seated Tumour and Spontaneous Intracerebral Haemorrhage 3704
Yad Ram Yadav, Jitin Bajaj, Shailendra Ratre, Muddaiah Narayana Swamy, Vijay Parihar, Mallika Sinha, Ketan Hedaoo, Jitendra Shakya, Mukesh Sharma, Jayant Patidar

- Endoscopy for Spontaneous Deep-seated Intracerebral Haematoma *3704*
- Endoscopic Management of Deep-seated Tumour *3710*

20.9 Endoscopic Management of Third Ventricular Colloid Cyst 3715
Jitin Bajaj, Poodipedi Sarat Chandra

- Preoperative Workup *3715*
- Anaesthesia and Position *3715*
- Surgical Steps *3715*
- Two-port Technique *3716*
- Tubular Retractor Technique *3716*
- Handling of Bleeding *3717*
- Postoperative Care *3717*
- Follow-up *3717*
- Complications, Avoidance, and their Management *3717*
- Few Case Scenarios *3718*
- Discussion *3718*

20.10 Endoscopic Management of Arachnoid Cysts 3722
Manas Kumar Panigrahi, Chiragkumar Patel

- Sylvian Fissure Arachnoid Cyst *3722*
- Suprasellar Arachnoid Cyst *3723*
- Lateral Ventricle Arachnoid Cyst *3724*
- Quadrigeminal Arachnoid Cyst *3725*
- Posterior Fossa Arachnoid Cyst *3726*

20.11 Endoscopic Management of Intraventricular Tumours 3730
Bhawani Shanker Sharma, Anchal Chauhan

- Surgical Management *3730*

20.12 Endoscopic Surgery of Intracranial Aneurysms 3738
Bhawani Shanker Sharma, Tshering Dorjee Sherpa, Anurag Srivastava

- Microsurgery for Intracranial Aneurysms *3738*
- Neuroendoscopy *3738*
- Roles of Endoscope in Aneurysmal Surgery *3739*

20.13 Endoscopic Carpal Tunnel Release 3747
Jitin Bajaj, Poodipedi Sarat Chandra

- Symptoms *3747*
- Anatomy of the Carpal Tunnel *3747*
- Preoperative Assessment *3748*
- Management *3748*
- Open versus Endoscopic Carpal Tunnel Release *3749*
- Surgical Technique *3749*
- Early versus Late Surgery *3750*
- Common Endoscopic Systems for Carpal Tunnel Release *3750*
- Complications *3750*

20.14 Endoscopic-assisted Craniectomies for Craniosynostosis: "Beyond Just Simple Suturectomy" 3752
Subodh Raju, Abhirama Chandra Gabbita

- Scaphocephaly *3754*
- Anterior Plagiocephaly *3756*
- Trigonocephaly *3757*
- Contraindications *3759*
- Post Surgery *3759*
- Discussion and Controversies *3760*

20.15 Endoscopic Anatomy of Nose/Paranasal Sinuses and Flaps Used in Endoscopic Endonasal Skull Base Reconstruction..... 3764
Govind Bhuskute, Jaskaran S Gosal, Prakash Nair, Daniel M Prevedello, Ricardo Carrau

- Septum *3764*
- Inferior Turbinate *3765*
- Middle Turbinate *3766*
- Superior Turbinate *3766*
- Middle Meatus *3766*
- Sphenoid Sinus *3768*
- Frontal Sinus *3771*
- Flaps for Skull Base Reconstruction *3772*
- Regional Extranasal Pedicled Flaps *3775*
- Free Flaps *3776*

20.16 Expanded Endonasal Endoscopy 3777
Sivashanmugam Dhandapani, Sushant Kumar Sahoo, Rijuneeta Gupta

- Endoscopic Anatomy of the Skull Base *3777*
- Types of Expanded Endonasal Approaches *3778*
- The Arachnoid Planes and Tumours *3779*
- Patient Positioning *3779*
- Sino-nasal Exposure *3779*
- Transsphenoidal Transtuberculum/ Transplanum Approach *3779*
- Transcavernous Approach *3782*
- Trans-pterygoid Approach *3782*
- Transcribriform Approach *3783*

20.17 Endoscopic Management of CSF Rhinorrhoea..... 3788
Bhawani Shanker Sharma, Kapil Sindhu, Anmol Anant Dobriyal

- Diagnosis *3788*
- Treatment *3789*
- Surgery *3789*
- Postoperative Care *3792*

20.18 Endonasal Endoscopic Approach to Orbital Tumours 3794
Awadhesh Kumar Jaiswal, Ravi Sankar Manogaran, Anant Mehrotra, Kuntal Kanti Das, Soumen Kanjilal, Guramritpal Singh

- Rationale of Endonasal Endoscopic Approach *3794*
- Indications *3795*
- Contraindication *3795*
- Preoperative Radiological Evaluation *3795*
- Surgical Instruments Required in this Procedure *3795*
- Anaesthesia *3795*
- Surgical Technique *3795*
- Advantages and Disadvantages of Endonasal Endoscopic Approach to the Orbit *3796*
- Complications and their Management *3801*
- Limitations *3801*
- Current Status of Endonasal Endoscopic Approach to the Orbit *3801*

20.19 Optic Nerve Decompression 3802
Arun Kumar Srivastava, Kalyan Chidambaram, Ramandeep Singh Virk, Ravi Sankar Manogaran

- Aetiology and Pathophysiology *3802*
- Evaluation *3803*
- Surgical Techniques *3803*
- Complications *3805*
- Outcome *3806*

20.20 Endoscopic Techniques in Epilepsy Surgery 3807
Ramesh Doddamani, Poodipedi Sarat Chandra

- Types of Epilepsy Surgery *3807*

20.21 Endoscopic Management of Chronic Subdural Haematoma..... 3822
Yad Ram Yadav, Shailendra Ratre, Muddaiah Narayana Swamy, Vijay Parihar, Mallika Sinha, Jitin Bajaj, Ketan Hedaoo

- Pathophysiology *3822*
- Presentation *3822*
- Aetiology *3822*
- Diagnosis and Neuroimaging *3822*
- Treatment *3823*
- Discussion *3825*
- Complications, their Avoidance and Management *3829*

20.22 Endoscopic Vascular Decompression for Trigeminal Neuralgia and Hemifacial Spasm 3831
Jitin Bajaj, Shailendra Ratre, Yad Ram Yadav

- Diagnosis and Preoperative Workup *3831*
- Indications of Endoscopic Vascular Decompression *3831*
- Contraindications *3832*
- Surgical Procedure *3832*
- Discussion *3834*
- Neurovascular Conflict *3834*
- Visualisation *3834*
- Complications and their Avoidance *3835*
- Advantages and Limitations of the Endoscopic Technique *3835*
- Hemifacial Spasm *3836*

20.23 Endoscopic Transoral Approach to Atlanto-axial Dislocation 3838
Yad Ram Yadav, Jitin Bajaj, Shailendra Ratre, Muddaiah Narayana Swamy, Vijay Parihar, Mallika Sinha, Ketan Hedaoo, Jitendra Shakya, Mukesh Sharma, Jayant Patidar

- Indications and Contraindications *3838*
- Clinical Presentation *3838*
- Preoperative Assessment and Workup *3839*
- Extent of Surgical Resection *3839*

- Surgical Procedure *3839*
- Results and Discussion *3843*
- Advantages and Limitations of the Approach *3843*

20.24 Endoscopic Transcervical Approach for Craniovertebral Junction 3846

Muddaiah Narayana Swamy, Yad Ram Yadav, Vijay Parihar, Shailendra Ratre, Mallika Sinha, Jitin Bajaj, Ketan Hedaoo, Mukesh Sharma, Jitendra Shakya, Jayant Patidar

- Surgical Anatomy *3846*
- Patient Suitability *3846*
- Indications *3846*
- Contraindications *3846*
- Advantages *3847*
- Disadvantages *3847*
- Radiological Investigations *3847*
- Additional Investigations *3848*
- Instrumentation *3848*
- Position *3848*
- Surgical Procedure *3848*
- Anterior Release, Odontoidectomy, and Reconstruction *3848*
- Complications *3849*
- Review of Literature *3850*

20.25 Endoscopic Management of Chiari Malformation Type 1 3851

Shailendra Ratre, Muddaiah Narayana Swamy, Vijay Parihar, Mallika Sinha, Jitin Bajaj, Ketan Hedaoo, Yad Ram Yadav

- Definition *3851*
- Presenting Signs and Symptoms *3851*
- Imaging *3851*
- Management *3851*
- Discussion *3853*
- Complication Avoidance *3854*

20.26 Endoscopic Anterior Cervical Discectomy (Disc-preserving) 3856

Yad Ram Yadav, Shailendra Ratre, Muddaiah Narayana Swamy, Vijay Parihar, Mallika Sinha, Jitin Bajaj, Ketan Hedaoo, Mukesh Sharma, Jayant Patidar

- Indication *3856*
- Contraindication *3856*
- Imaging *3856*
- Surgical Procedure *3856*
- Tips *3858*
- Limitations *3859*

20.27 Endoscopic Cervical Laminectomy for Cervical Spondylotic Myelopathy 3861

Jitin Bajaj, Shailendra Ratre, Vijay Parihar, Ketan Hedaoo, Mallika Sinha, Muddaiah Narayana Swamy, Yad Ram Yadav

- Preoperative Workup *3861*
- Indications *3861*
- Contraindications *3862*
- Anaesthesia *3862*
- Positioning and Incision *3862*
- Surgical Procedure *3862*
- Postoperative Care *3864*
- Discussion *3864*
- Anterior versus Posterior Approach *3866*
- Microendoscopic Laminotomy versus Conventional Laminoplasty *3866*
- Laminoplasty *3866*
- Midline Approach Microendoscopic Interlaminar Decompression *3866*

20.28 Endoscopic Management of Intradural Extramedullary Tumours 3868

Sivashanmugam Dhandapani, Chandrashekhar Gendle

- Patient Selection *3868*
- Preoperative Evaluation *3868*
- Position and Localisation *3868*
- Entry Point and Trajectory *3869*
- Choice of Access Port *3869*
- Incision, Entry, and Docking *3870*
- Illumination and Visualisation *3870*
- Bony Exposure *3871*
- Durotomy *3871*
- Tumour Handling *3871*
- Dural Closure *3872*
- Results and Complications *3872*

20.29 Endoscopic Interlaminar Management of Lumbar Disc and Lumbar Canal Stenosis 3875

Jayant Patidar, Jitin Bajaj, Yad Ram Yadav, Mukesh Sharma, Ketan Hedaoo, Mallika Sinha, Shailendra Ratre, Vijay Parihar, Muddaiah Narayana Swamy

- Indications for Endoscopic Interlaminar Approach *3876*
- Preoperative Assessment *3877*
- Surgical Approach *3877*
- Postoperative Care *3880*
- Complications *3880*
- Reoperation *3882*
- Advantages *3882*
- Limitations *3882*
- Outcome *3882*

20.30 Transforaminal Endoscopy for Lumbar Symptomatic Degenerative Spine 3884

Satishchandra Gore, Onkar Sudame, Amit Surana, Alok Gadkari

- Short History and Evolution of Transforaminal Lumbar Endoscopy *3884*

Symptom Generator Detection, Confirmation and Targeting under Local Anaesthesia in Awake Aware Patient, and Not only Smaller Incision ***3886***

- Fundamental Question and the Answer by Learning and Putting it Back: Gore Matrix *3887*

- Better Simplified 3Z3W Anatomy of Functional Spinal Unit Concepts, Better Correlation of Symptoms, Image, and Pathology *3887*
- Three Zones with Nine Targets: Concepts for Back Pain, Sciatica, and Claudication *3890*

Standard Operating Procedure: Evolved Endoscopic Surgery of the Disc for Back and Leg Pain and Variations as per Locations, Types, and Migrations *3892*

- Advantages of Transforaminal Endoscopy Access and Surgery *3905*
- Newer Realities about Posterior Wall of Canal Ligamentum Flavum and Stenosis *3907*
- Open Surgery for Disc and Stenosis needs Change *3907*
- Limitations of Transforaminal Classic Access in Stenosis and New Evolving Concepts of Smrutii System *3909*
- References: Few Publications Covering Entire TFE and Related Issues *3910*

20.31 Endoscopic Management for Tethered Cord Syndrome 3912

Soumen Kanjilal, Anant Mehrotra, Priyadarshi Dikshit, Kuntal Kanti Das, Awadhesh Kumar Jaiswal

- Preoperative Plan *3912*
- Surgical Technique *3912*
- Complications *3916*

20.32 Exoscopes in Neurosurgery: Microneurosurgery sans Microscope 3918

Bhanu Pratap Singh Chauhan, Vijay Parihar, Shailendra Ratre, Ketan Hedaoo, Jitin Bajaj, Mallika Sinha, Jayant Patidar, Mukesh Sharma, Muddaiah Narayana Swamy, Yad Ram Yadav

- Description of Various Exoscopes *3921*
- Illustrative Cases *3925*

20.33 Endoscopic Management of Hydrocephalus 3930

Aaron Mohanty, Krishna Kumar G

- History of Endoscopy in the Management of Hydrocephalus *3930*
- Normal Endoscopic Anatomy *3931*
- Approach *3931*
- Instrumentation *3932*
- Stabilisation and Guiding Devices *3933*
- Endoscopic Procedures for Obstructive Hydrocephalus *3933*

20.34 Endoscopic Brain Tumour Surgery 3944

Manas Kumar Panigrahi, M Manoranjitha Kumari, Asit Roy

- Endoscopic Instruments *3944*
- Endoscope in Supratentorial Brain Tumour Surgery *3946*
- Endoscopic-assisted Microsurgery *3951*
- Endoscopic Skull Base Surgery *3953*

20.35 Complication Avoidance in Endoscopic Endonasal Surgeries 3960

Bhawani Shanker Sharma, Anmol Singh Randhawa

- Training *3960*
- Patient Selection *3961*
- Knowledge of Anatomy and Imaging *3961*
- Preoperative Preparation *3961*
- Instrumentation *3961*
- Complications *3962*
- Surgical Step-wise Complications and their Avoidance and Treatment *3963*
- Endocrine *3973*

Section 21: Miscellaneous

Section Editor: **Sanjay Behari**

21.1 Anaesthesia in Neurosurgery 3983

Aurobinda Kanungo, Akila Suresh, S Vasudevan

- Cerebral Physiology *3983*
- Pharmacology of Anaesthetic Agents *3985*
- Perioperative Anaesthetic Management *3990*

21.2 Positioning in Neurosurgery 4002

Manmohan Singh, Ravi Sharma

- Basic Tenets of Neurosurgical Positioning *4002*
- Cranial Positions *4003*
- Spinal Procedures *4008*
- Peripheral Nerve *4009*

21.3 Operation Theatre for Neurosurgery 4010

Abhinith Shashidhar, Malla Bhaskara Rao

- Surgical Team *4010*
- Operating Room Etiquette *4011*
- Designing of an Operation Theatre *4011*
- Operating Room Set-up *4012*
- Operation Theatre Workflow *4012*
- Requirements of the Operating Room *4013*
- Basic Operating Room Set-up *4013*
- Airconditioning and Airflow within the Theatre *4013*
- Zoning and Areas within the Operation Theatre Complex *4013*
- Safety in the Operating Room *4015*
- Sterility in Neurosurgical Operation Theatre *4015*
- Advances in Neurosurgical Operation Theatre *4016*

21.4 Basic Neurosurgical Instruments 4019

Easwer Hariharan Venkat, HR Darshan, N Ram Kishan, Bhushan S Akhade

- Retractor Systems *4019*
- Scissors *4021*
- Aneurysm Clips and Applicators *4021*

- Neurosurgical Drills *4022*
- Kerrison's Punches *4023*
- Equipment for Endoscope-assisted Microsurgery *4023*
- Operating Microscopes *4025*
- Head Fixation System *4026*
- Coagulation Forceps *4026*
- Cavitron Ultrasonic Surgical Aspirator *4027*
- Forceps *4027*
- Needle Holder *4028*
- Suction *4028*

21.5 Navigation in Brain and Spine Surgery 4031
Anup P Nair, Dilip Panikar

- History *4031*
- Navigation and Stereotaxy *4034*
- Registration *4035*
- Benefits and Applications of Neuronavigation *4035*
- Navigation in Spine Surgery *4038*
- Recent Advances in Navigation *4042*

21.6 Principles and Practice of Neurorehabilitation 4046
Abhishek Srivastava, Navita Purohit Vyas, Faiz Mohamed, Sreejith Choorapra

- Concepts in Neurorehabilitation *4046*
- Neurorehabilitation Team *4046*
- Evaluation of a Person for Rehabilitation *4048*
- Medical Management in Rehabilitation *4049*
- Structured Rehabilitation Programs *4051*
- Advances in Neurorehabilitation *4053*

21.7 Telemedicine for the Neurosurgeon 4058
Ganapathy Krishnan

- Neurosurgical Intensive Care *4059*
- Tele-Neurorehabilitation *4061*
- Telemedicine and Neurosurgical Practice in the COVID-19 Era *4062*
- Specific Clinical Illustrations *4063*
- Telestroke *4063*
- Neurotrauma *4064*
- Mobile Telemedicine *4064*
- Tele Radiosurgery *4064*
- Empowerment in Rural India: Relevance to Neurosciences *4064*
- Educational Videoconferencing *4065*
- Telesurgery *4065*
- Concerns about Telemedicine *4065*

21.8 Quality of Death in Neurosurgical Practice 4069
Ganapathy Krishnan

- Death in Neurological Practice *4069*
- Personal Clinical Illustrations from Neurosurgical Practice *4070*
- What is Good Death? *4070*
- Concepts of Good Death around the World *4070*
- What is Bad Death? *4071*
- Assisted Dying *4071*
- Death Cafés *4071*
- Quality of Death Index *4072*
- COVID-19 Fatalities Epitomising "Bad Deaths" *4072*

21.9 Ethics in Neurosurgery 4075
Sandip Chatterjee, Phelix Rufus

- Guidelines and their Implications *4075*
- Principles of Patient Care *4076*
- Principles for Professional Efficiency *4077*
- Dealing with a Paediatric Patient *4077*
- Treatment Withdrawal *4077*
- Directives for End-of-life Care in Terminally Ill Patients *4077*
- Social Responsibility *4078*
- Training the Next Generation *4078*
- Principles of Clinical Research *4078*
- Brain Death *4078*

21.10 Adult Neurocritical Care 4080
Aurobinda Kanungo, Akila Suresh, G Sathya Kumar

- Organisation of Neurocritical Care Unit *4080*
- Managing the Critically Ill Patient *4080*

21.11 Awake Craniotomy 4092
Amitabha Chanda

- Neuroanatomy of Motor and Language Cortical Areas *4092*
- Indications and Patient Selection *4093*
- Neuroimaging *4094*
- Preoperative Assessment and Preparation *4095*
- Technique *4098*
- Complications and Management *4099*
- Uses and Benefits *4099*

21.12 Neural Prosthesis and Auditory Brainstem Implant 4105
Poonam Mohanty, MC Vasudevan, Mohan Kameswaran

- Auditory Brainstem Implant *4105*
- Historical Background *4105*
- Breakthrough *4106*
- The Long Revolutionary Path *4106*
- Device Design and Functional Aspects *4106*
- Indications for Auditory Brainstem Implant *4107*
- Side and Age of Implantation *4107*
- Surgical Aspects *4107*
- Outcomes of Auditory Brainstem Implant *4109*
- ALNC-PGINS Experience with Auditory Brainstem Implant *4109*

21.13 Basal Cisternostomy in Traumatic Brain Injury ... 4112
Parthiban Jutty Krishnaiyer Bala Chandra

- Hypothesis and Rationale *4112*
- Indications *4113*
- Surgical Technique *4114*
- Postoperative Care *4118*
- Research and Literature *4120*

21.14 Shunts in Neurosurgical Practice 4128
Dattatraya Muzumdar, Srikant Balasubramaniam, Survendra Kumar R Rai

- Cerebrospinal Fluid Dynamics *4129*
- Types of Shunts and their Indications *4129*
- Technique of Cerebrospinal Fluid Shunting *4130*
- Shunt Hardware and Physics *4135*
- Adjustable Cerebrospinal Fluid Shunt Valves *4145*
- Shunt Assessment *4147*

21.15 Surgery for Spasticity 4150
Aniruddh Kumar Purohit, Jagan Mohan Reddy K

- Mechanism of Generation of Spasticity and Basis of Action of Various Procedures *4150*
- Treatment Protocol *4151*
- Classification *4154*
- Nonablative Segmental (Spinal Circuit) Procedures *4154*
- Nonablative Suprasegmental Procedures—Central Procedures *4155*
- Ablative Segmental (Spinal Circuit) Procedures *4155*

21.16 Normal Pressure Hydrocephalus 4164
Ved Prakash Maurya, Vandan Raiyani, Sanjay Behari

- Incidence *4164*
- Aetiology *4164*
- Criteria for Diagnosis *4166*
- Clinical Features of Idiopathic Normal Pressure Hydrocephalus *4167*
- Differential Diagnosis of Normal Pressure Hydrocephalus *4168*
- Diagnosis *4168*
- Surgical Management of Idiopathic Normal Pressure Hydrocephalus *4174*

Current Recommendations of the iNPH Guidelines for iNPH Diagnosis and Use of Supplemental Prognostic iNPH Tests for Identifying Shunt-responsive Patients *4174*

- Type of Shunt *4175*
- Valve Selection *4175*
- Clinical Scales for Assessing Outcome *4176*
- Management of Patients who Fail to Improve or Those Who Deteriorate Clinically Following Shunt Placement *4176*

21.17 Idiopathic Intracranial Hypertension 4185
Suresh Bapu R Kandallu, Vishwaraj Ratha, Syed Ibrahim T, Deivanai Sundaram N

- Diagnostic Criteria *4185*
- Symptoms and Signs *4185*
- Imaging Studies and Radiologic Criteria *4186*
- Pathophysiology *4188*
- Medical Management *4191*
- Surgical Management *4192*
- Bariatric Surgery in Idiopathic Intracranial Hypertension *4194*
- Idiopathic Intracranial Hypertension Masquerading as Spontaneous Cerebrospinal Fluid Rhinorrhoea *4195*

21.18 Artificial Intelligence and Appropriate Technology in Neurosurgery 4199
Mangalkumar Girish Rachatte, Jhoshithaa Ramesh

- Evolving Appropriate Technologies *4201*
- Machine Learning *4201*
- Deep Learning *4201*
- Big Data in Neurosurgery *4201*
- History of Artificial Intelligence in Neurosurgery *4202*
- Neuroimaging and Diagnostics *4202*
- Preoperative Planning *4203*
- Epilepsy *4203*
- Intraoperative Applications *4203*
- Postoperative Outcome Prediction *4204*
- Neurosurgical Training *4205*
- Artificial Intelligence Tools *4205*
- Technology *4205*
- Risks and Challenges *4208*
- Potential Drawbacks of Using Artificial intelligence in Neurosurgery *4208*
- Ethical Considerations *4209*
- Future of Artificial Intelligence in Neurosurgery *4209*

Index ..... *I-i-xxviii*

2.5

CHAPTER

Microsurgical Anatomy of the Brainstem

Sukhdeep Singh Jhawar, Abhidha Shah, Maximiliano Nunez, Atul Goel

JAYPEE BROTHERS

INTRODUCTION

The brainstem is a highly complex structure that plays a vital role in connecting the forebrain with the spinal cord **(Figs. 1 to 3)**. It consists of three main parts: the midbrain, pons, and medulla. Unlike the cerebral hemispheres, the architecture of the brainstem is incredibly intricate, with a high density of fibres and grey cell nuclei. Various fibre bundles traverse the brainstem, connecting the forebrain to the spinal cord. However, the brainstem differs significantly from both the lower spinal cord and the upper cerebral hemispheres.

One of the distinctive features of the brainstem is the systematic rearrangement of these fibre bundles at different levels. Additionally, the brainstem serves as the termination point for some tracts, while others originate from this region. Excepting first two cranial nerves, all other cranial nerve nuclei and nerve fasciculi either end or begin in the brainstem. This unique arrangement adds to the complexity of brainstem anatomy.

In recent studies, researchers have utilised advanced techniques such as fibre dissection to explore the intricate anatomy of the brainstem. Through these methods, the relationship between major white fibre pathways and clusters of grey matter nuclei has been elucidated. This research has led to the development of a novel system for categorising fibre tracts in the brainstem into zones.[5] This classification system provides valuable insights into brainstem anatomy, particularly for surgeons operating in this region. Understanding these intricate structures and their relationships is crucial for ensuring safe and precise neurosurgical procedures in the brainstem.

In this chapter, the white fibre tracts in the brainstem are dissected from multiple perspectives, including the dorsal, ventral, and lateral aspects, offering a three-dimensional

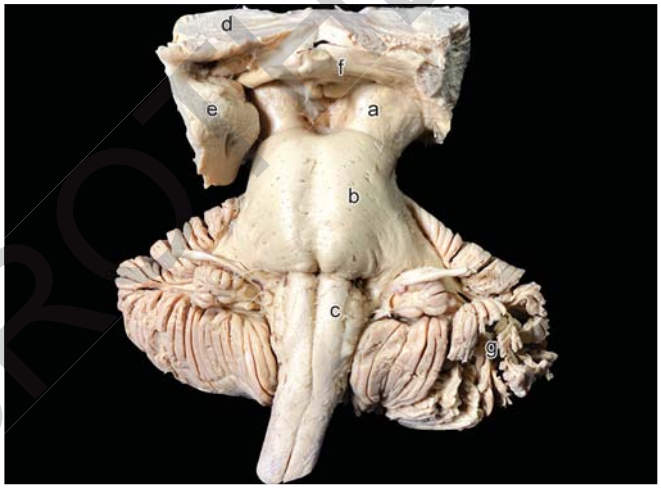

Fig. 1: Ventral view of the brainstem with its parts: (a) midbrain, (b) pons, (c) medulla, (d) thalamus, (e) temporal lobe, (f) optic chiasm, and (g) cerebellum.

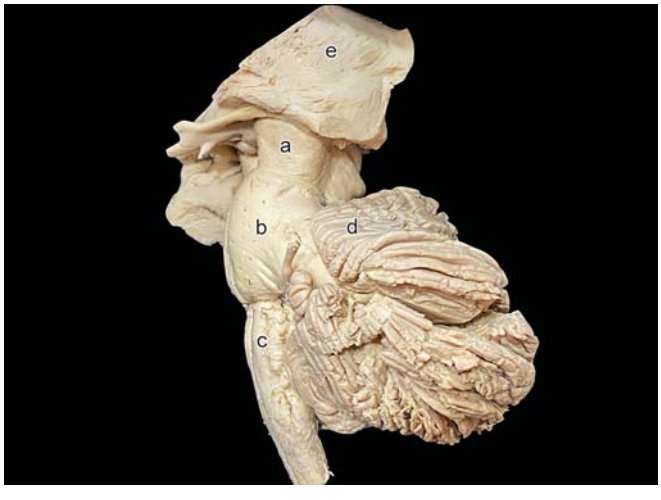

Fig. 2: Lateral view of the brainstem: (a) midbrain, (b) pons, (c) medulla, (d) cerebellum, and (e) thalamus.



Fig. 3: Dorsal view of the brainstem and cerebellum as it lies in the cranial cavity: (a) posterior surface of the midbrain, (b) cerebellum, (c) thalamus, (d) superior colliculus, (e) inferior colliculus, (f) pineal body, (g) third ventricle, and (h) massa intermedia.

view of its internal structure. The brainstem is examined in its entirety, with a focus on the anterior, posterior, and lateral corridors. This comprehensive approach enables a thorough exploration of the external and internal architecture of white matter tracts and grey matter nuclei within the brainstem.

Each of the three parts of the brainstem—midbrain, pons, and medulla—is described externally and internally to outline the course of longitudinal tracts and cranial nerve nuclei. This detailed examination provides valuable insights into the complex structure and function of the brainstem, enhancing our understanding of its role in the central nervous system.

MIDBRAIN

Extent

The midbrain, also known as the mesencephalon, is a relatively short and constricted part of the brainstem. It extends superiorly from the optic tracts to the pontomesencephalic sulcus inferiorly. The midbrain serves as a critical connection between the pons and cerebellum below and the diencephalon and cerebral hemispheres above **(Figs. 4 and 5)**. To establish its boundary with the diencephalon, an imaginary line is drawn between the mammillary bodies and the posterior commissure.[5]

Parts/Divisions

The midbrain itself has two main divisions: The cerebral peduncles ventrally and the tectum dorsally. Each cerebral peduncle comprises the crus cerebri ventrally and the tegmentum dorsally,[1] with these two components separated by a darkly pigmented lamina known as the substantia nigra **(Fig. 4B)**. The division between the cerebral peduncle and the tectum is marked by an oblique plane that crosses the cerebral aqueduct.

The dorsal portion of the midbrain, referred to as the tectum, includes four rounded eminences known as the corpora quadrigemina. In addition to the corpora quadrigemina, there is also a pretectal area within the dorsal tectum.

External Features

Anterior Corridor: Cerebral Peduncles

The crus cerebri, situated on the ventral surface of the midbrain, is the most prominent part of this region. The crus cerebri, also known as the cerebral peduncles, resembles two cylindrical masses or pillars on either side of the midbrain, resting on the upper portion of the pons. These structures are typically hidden from an anterior view due to the presence of mesial temporal lobe structures, and they become visible when the parahippocampal gyrus is retracted laterally **(Figs. 4A and B)**.

An interesting analogy for the crus cerebri is that they resemble the Greek mythological figure "Atlas" holding up the celestial heavens (cerebrum) with his two arms (the cerebral peduncles).[4] These peduncles converge in a downward and backward direction, extending from the optic chiasm superiorly to the pontomesencephalic junction inferiorly. The space between these two cerebral peduncles forms a deep cleft known as the interpeduncular fossa, which contains the posterior perforated substance. This fossa has an inverted triangular shape, with its apex pointing inferiorly and its base superiorly. The apex is formed by the superior foramen caecum, and the base is demarcated by the mammillary bodies. The interpeduncular fossa is bordered laterally by the medial surfaces of the cerebral peduncles. The lower portion of the cerebral peduncles houses the interpeduncular ganglion, a grey matter nucleus, while the upper part of the cerebral peduncle contributes to forming the floor of the third ventricle **(Figs. 4C and D)**.

Additionally, the trochlear nerve, emerging from the dorsal surface of the brainstem, crosses the cerebral peduncle from behind forwards. The medial surface of the cerebral peduncle features a linear vertical groove known as the oculomotor sulcus, from which the oculomotor nerve exits the midbrain **(Figs. 4A to D)**.

JAYPEE BROTHERS

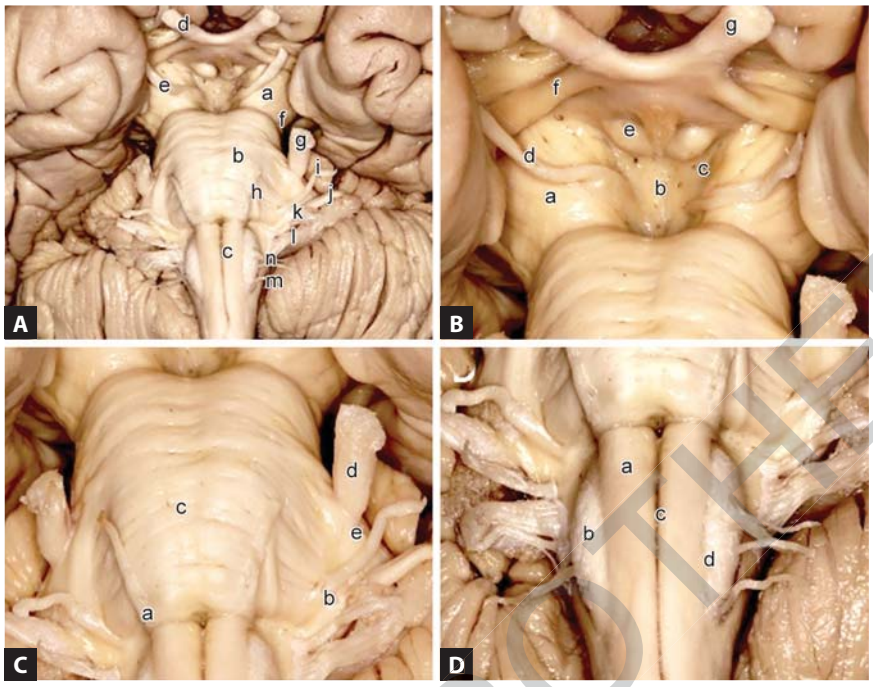

Figs. 4A to D: Ventral view of brainstem. (A) Brainstem can be divided into three distinctive morphological parts consisting of the midbrain, pons, and medulla from above downwards. Superiorly, the brainstem (midbrain) is continuous with structures forming the thalamus, hypothalamus, and cerebral hemispheres. Inferiorly, it is continuous with the spinal cord (medulla); (a) midbrain, (b) pons, (c) medulla, (d) optic nerve, (e) oculomotor nerve, (f) trochlear nerve, (g) trigeminal nerve, (h) abducens nerve, (i) facial nerve, (j) vestibulocochlear nerve, (k) glossopharyngeal nerve, (l) vagus nerve, (m) cranial part of accessory nerve, and (n) hypoglossal nerve. (B) Ventral view of midbrain; when viewed from the anterior aspect, the midbrain has two prominent converging fibre bundles called cerebral peduncles, which are separated by a deep fissure known as interpeduncular fossa. This fissure is wider superiorly than inferiorly. The medial surface of the peduncle forms the lateral boundary of the interpeduncular fossa, and is marked by a longitudinal furrow, the oculomotor sulcus. The oculomotor nerve can be seen emerging from the medial aspect of both peduncles from the depth of the interpeduncular fossa. Paired mammillary bodies can be seen forming the roof of this fossa; (a) cerebral peduncles, (b) interpeduncular fossa, (c) oculomotor sulcus, (d) oculomotor nerve, (e) mammillary bodies, (f) optic tract, and (g) optic nerve. (C) The pons is the most prominent part of the brainstem ventrally. It extends from the pontomesencephalic sulcus superiorly to the pontomedullary sulcus inferiorly. The abducens, facial, and vestibulocochlear nerve emerge from the pontomedullary sulcus inferiorly. The anterior surface has a shallow vertical median groove for the basilar artery called sulcus basilaris. Near the midpontine level the trigeminal nerve emerges, which is taken as a landmark to define the plane of junction between the pons and middle cerebellar peduncle. The transverse pontine fibres come together to form the middle cerebellar peduncle; (a) abducens nerve, (b) facial and vestibulocochlear nerves, (c) sulcus basilaris, (d) trigeminal nerve, and (e) middle cerebellar peduncle. (D) The medulla oblongata is pyramidal in shape, with a broad upper end separated from the pons by pontomedullary sulcus and narrow lower end continuous with the spinal cord. A plane passing transversely below the pyramidal decussation and above the first pair of cervical nerves is taken as the lower limit of medulla oblongata. The anterior median fissure extends along the entire length of the medulla oblongata ventrally. The upper part of the lateral compartment of the medulla contains oval prominences called olive. Its lower part is only partly continuous with the spinal lateral funiculus. The last four cranial nerves emerge from the medulla as two sets of rootlets from the anterolateral and posterolateral sulcus respectively; (a) pyramids, (b) olive, (c) anterior median fissure, and (d) anterolateral sulcus.

JAYPEE BROTHERS

Lateral Corridor

The lateral side of each peduncle exhibits a longitudinal groove known as the lateral mesencephalic sulcus. This sulcus effectively separates the outer aspect of the midbrain into two sections: one to the front and one to the back. The foremost part of the cerebral peduncle **(Fig. 5A)** takes up the outer portion at the front of the peduncle, while the posterior part is comprised of the lemniscal triangle. The lemniscal triangle is enclosed anteriorly by the lateral mesencephalic sulcus, on the upper-rear by the inferior brachium, and on the lower-rear by the superior cerebellar peduncle. This triangle consists of the nerve fibres belonging to the lateral lemniscus, which travel in a backward and upward direction, eventually disappearing below the inferior colliculus **(Fig. 5B)**.



Figs. 5A to C: Midbrain. (A) Close-up view of the ventral part of the midbrain: (a) cerebral peduncle, (b) interpeduncular fossa and posterior perforated substance, (c) pontomesencephalic sulcus, (d) optic tract, (e) mammillary body, (f) parahippocampal gyrus of temporal lobe, (g) pons, and (h) thalamus. (B) Close-up view of the lateral part of the midbrain: (a) cerebral peduncle, (b) lateral mesencephalic sulcus, (c) lemniscal triangle, (d) tectal plate, (e) pons, (f) middle cerebellar peduncle, (g) cerebellum, (h) thalamus, (i) optic tract, and (j) mammillary body. (C) Close-up view of the dorsal part of the midbrain: (a) superior colliculus, (b) inferior colliculus, (c) pulvinar of thalamus, (d) third ventricle, (e) massa intermedia, (f) cruciate sulcus, (g) superior brachium, (h) inferior brachium, (i) pineal body, and (j) superior surface of cerebellum.

JAYPEE PROOFS

Posterior Corridor: Corpora Quadrigemina

The tectum of the midbrain's consists of the corpora quadrigemina, which are further divided into the superior and inferior colliculi **(Fig. 5C)**. These are four rounded elevations positioned on the upper surface of the midbrain, covered partially by the splenium of the corpus callosum, and partially obscured by the pulvinar of the thalamus on both sides **(Fig. 5C)**. The colliculi are situated anteriorly and superiorly in relation to the superior medullary velum and superior cerebellar peduncle, and posteriorly and inferiorly in relation to the third ventricle and posterior commissure.[1-3] Therefore, they are situated behind the third and fourth ventricles. The superior and inferior colliculi exist as paired semicircular structures separated by a cruciate sulcus. The vertical portion of this sulcus extends upward, forming a slight depression where the pineal body is located, partially covering the superior colliculi. A white band known as the frenulum veli emerges from the lower end of the cruciate sulcus and extends downward to the superior medullary velum. The trochlear nerve emerges below the inferior colliculus on either side of the frenulum veli and then travels forwards along the lateral aspect of the cerebral peduncle **(Fig. 5C)**. The inferior colliculi are hemispherical and

appear more prominent than the superior colliculi.[1-3] The superior colliculi are linked to the visual pathway, while the inferior colliculi are associated with the auditory pathway.

Fibres emerge from the lateral aspect of each colliculus and project upwards to the thalamus to form the superior and inferior brachium **(Fig. 5C)**. The superior brachium ascends upwards and outwards, passing between the pulvinar and the medial geniculate body before entering the lateral geniculate body. Some of its fibres enter the optic tract directly. The inferior brachium originates from the inferior colliculus and travels forwards and upwards, eventually disappearing beneath the cover of the medial geniculate body.

Internal Features

When observing a cross-section of the midbrain, its internal structure can be divided into three distinct parts: The crus cerebri, the tegmentum, and the tectum **(Figs. 6A to H)**. The dorsal midbrain comprises the tegmentum, which includes the red nucleus, and the tectum, represented by the quadrigeminal plate. Meanwhile, the ventral midbrain encompasses the cerebral peduncle and the substantia nigra **(Figs. 6F to H)**.

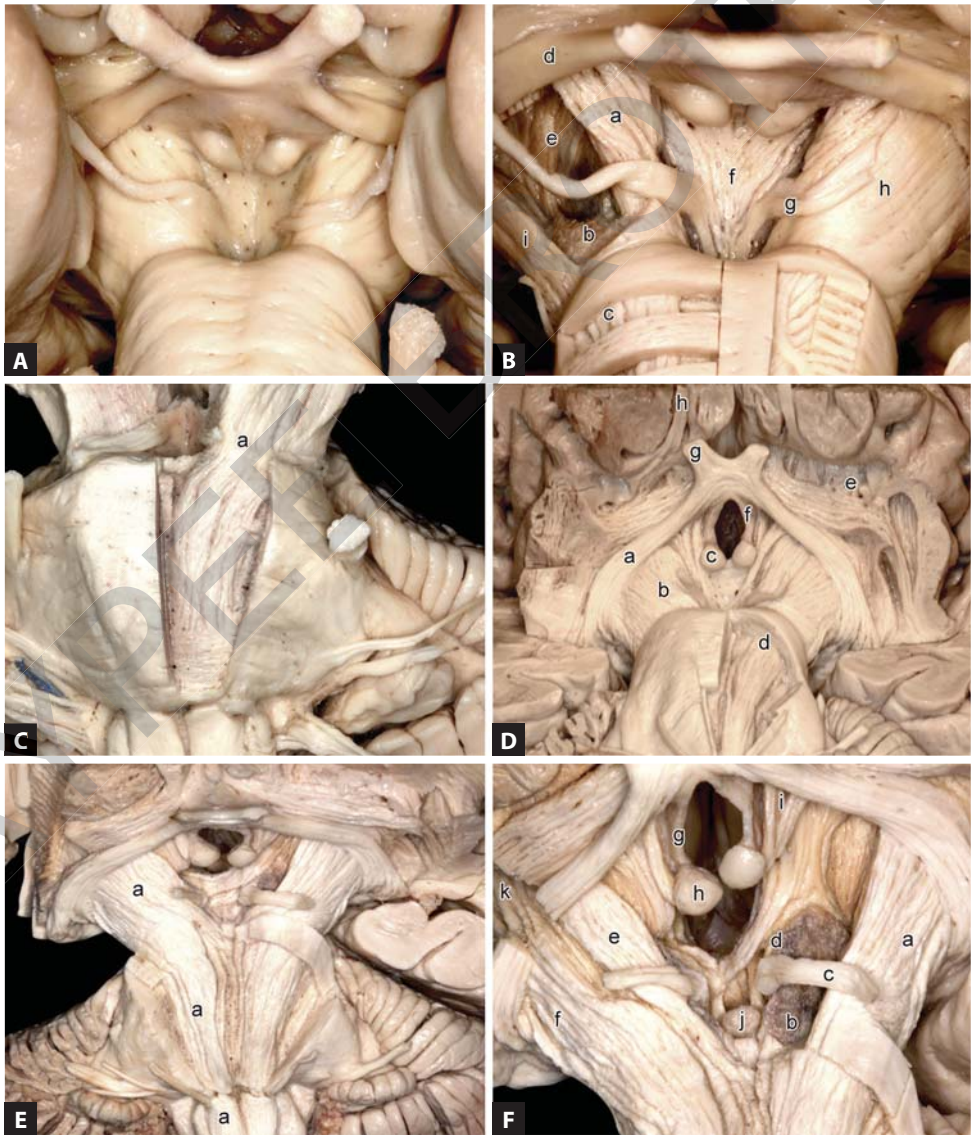

Figs. 6A to F

JAYPEE BROTHERS

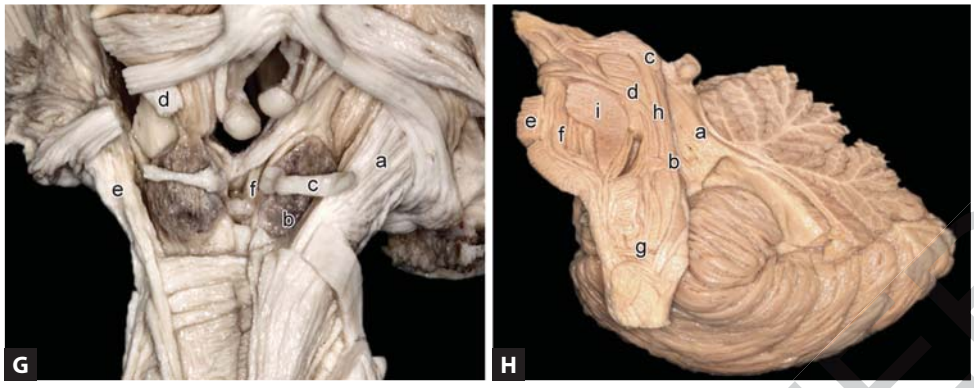

Figs. 6G and H

Figs. 6A to H: Fiber dissection of the midbrain. (A) The midbrain traverses the hiatus in the tentorium cerebelli, connecting the pons and cerebellum with the forebrain. Ventrally the cerebral peduncles can be seen as dominating cylindrical structures converging towards the pons as they descend. These bundles are separated by a midline fissure called the interpeduncular fossa which is wider superiorly. The oculomotor nerve can be seen emerging from medial aspect of both peduncles from the depth of interpeduncular fossa. The upper limit is demarcated laterally by the optic tracts and medially by the floor of the third ventricle. The uncus of the mesial temporal lobe can be seen covering the cerebral peduncles on both sides; (B) Each cerebral peduncle is semilunar in cross-section and consists entirely of longitudinal bundles of efferent fibres, which arise from different parts of the cerebral cortex. After removal of some part of the cerebral peduncle deeply pigmented semilunar lamina can be seen which is called substantia nigra. Corticospinal and corticonuclear fibres occupy middle two-thirds of peduncle. Corticopontine fibres arise in cerebral cortex and end in nuclei pontis. They can be grouped into frontopontine, from the frontal lobe situated in the medial fifth of the crus and temporopontine fibres from the temporal lobe situated in the lateral part of the peduncle; (a) frontopontine fibres in the crus cerebri, substantia nigra, (c) corticospinal tract continuing into the pons, (d) optic tract, (e) medial lemniscus, (f) interpeduncular fossa, (g) oculomotor nerve, (h) cerebral peduncle, and (i) temporopontine fibres in the crus cerebri; (C) Corticospinal fibres can be traced down into the pons as a well-defined fibre bundle, more so in the lower pons, before entering into the medullary pyramids; (a) corticospinal tract entering the pons from the midbrain; (D) Anterior parts of the temporal lobes have been removed on both sides to show the upper limit of the midbrain. Fibre bundles of the crus cerebri can be seen in relation to the optic tract before entering the midbrain. The corticospinal fibres on the left side are traced downwards into the pons on the way to the medullary pyramids; (a) optic tract, (b) corticospinal tract in the cerebral peduncle, (c) mammillary bodies, (d) corticospinal tract entering the pons, (e) anterior perforated substance, (f) fornix, (g) optic nerve, and (h) olfactory tract; (E) Ventral view of b the brainstem in another specimen showing the corticospinal fibre tract extending from the midbrain to the upper medulla on both sides. The oculomotor nerve can be seen emerging from the interpeduncular sulcus; (a) corticospinal tract as it traverses the midbrain, pons, and medulla; (F) Close-up view of the same specimen showing the crus cerebri with the substantia nigra. The oculomotor nerve emerges from the interpeduncular fossa on the medial aspect of the substantia nigra. Part of the red nucleus is visible dorsomedial to the substantia nigra; (a) corticospinal fibres, (b) substantia nigra, (c) oculomotor nerve, (d) substantia nigra, (e) fronto-pontine fibres, (f) temporo-pontine fibres, (g) fornix, (h) mammillary body, (i) red nucleus, (j) interpeduncular nucleus, (k) internal capsule; (G) The corticospinal tract is removed on the right side and partially on the left side exposing the deep midbrain structures. The convex ventral surface of the substantia nigra is visible. It is thicker medially and reaches up to the lateral crural sulcus; (a) corticospinal tract, (b) substantia nigra, (c) oculomotor nerve, (d) cut frontopontine fibres, (e) temporopontine fibres, and (f) fasciculus retroflexus; (H) Midsagittal section of the brainstem showing fibre dissection of the midbrain, pons, and medulla. Fibres of the superior cerebellar peduncle can be seen going from the dentate nucleus to the red nucleus and thalamus and forms the lateral wall of the superior half of the roof of the fourth ventricle. The medial longitudinal fasciculus runs just ventral to the cerebral aqueduct and close to the midline near the floor of the fourth ventricle. The medial longitudinal fasciculus passes lateral and ventral to the oculomotor nucleus and ascends to end in the interstitial nucleus (of Cajal) in the lateral wall of the third ventricle, just above the cerebral aqueduct. The medial lemniscus, when viewed from the lateral aspect ascends through the pons forming a concave shape facing ventrally. In the midbrain, it ascends in the dorsolateral part of the tegmentum in the angle between the red nucleus and substantia nigra; (a) superior cerebellar peduncle, (b) medial longitudinal fasciculus, (c) lateral lemniscus, (d) medial lemniscus, (e) corticopontine fibres, (f) corticospinal fibres, (g) pyramidal decussation, (h) central tegmental tract, and (i) middle cerebellar peduncle.

JAYPEE BROTHERS

Ventral Midbrain

The ventral part of the midbrain has the following: Cerebral peduncle, interpeduncular fossa and posterior perforated substance, pontomesencephalic sulcus, optic tract, mammillary body, parahippocampal gyrus of temporal lobe, pons, and thalamus **(Fig. 5A)**.

White fibres: In the ventral midbrain, there are white fibres within the cerebral peduncle, which is semilunar

in shape and houses three distinct fibre groups: The corticospinal, corticonuclear, and corticopontine fibres. The corticonuclear fibres originate in the cerebral cortex and terminate in cranial nerve nuclei and other brainstem nuclei. The corticospinal fibres, primarily a part of the pyramidal tract, start in the cerebral cortex and extend into the pons and medulla. Corticopontine fibres originate in the cerebral cortex and end in the pontine nuclei, dividing into two groups: frontopontine fibres from the frontal lobe and temporopontine fibres from the temporal and occipital lobes. To understand the arrangement of these fibres, the cerebral peduncle can be divided into five parts. The medial one-fifth consists of the corticonuclear fibres (geniculate fasciculus) and the corticopontine fibres (frontopontine fibres—Arnold's fasciculus). The middle three portions house the corticospinal tract (CST). The lateral one-fifth contains the corticopontine fibres (temporopontine fibres—Turk's fasciculus) **(Figs. 6C and D)**.[1-3]

Grey matter: In terms of grey matter in the ventral midbrain, the pigmented substantia nigra is the most prominent mass. Its dark colour results from the presence of pigmented neurons **(Figs. 6F and G)**. It extends transversely from the oculomotor sulcus on the medial side to the lateral mesencephalic sulcus on the lateral side. Vertically, it extends from the subthalamic region superiorly to the upper surface of the pons inferiorly. In cross-section, the substantia nigra appears as a semilunar transverse band with a dorsal concavity.

Dorsal Midbrain

White fibres: Moving to the dorsal midbrain, it contains various white fibre bundles, including the superior cerebellar peduncle, tectobulbar fibres, rubrospinal tract, rubrothalamic tract, medial longitudinal fasciculus (MLF), medial lemniscus, spinal lemniscus, trigeminal lemniscus, and lateral lemniscus. The medial portion of the midbrain, from ventral to dorsal, houses the MLF, tectospinal tract, decussation of the superior cerebellar peduncle, dorsal and ventral tegmental decussations, and rubrospinal tract. The central tegmental tract (CTT) and the lemniscal system lie laterally to these tracts. The lemniscal system includes the medial lemniscus, trigeminal lemniscus, spinal lemniscus, and lateral lemniscus, from medial to lateral.

Decussations: The midbrain contains three significant decussations: The dorsal and ventral tegmental decussations and the decussation of the superior cerebellar peduncle. Tegmental decussations occur at the level of the superior colliculus. The dorsal tegmental decussation is formed by the decussation of the tectobulbar tract connecting the superior colliculus to the medulla. The ventral tegmental decussation is made up of intersecting fibres from the rubrospinal fasciculus, connecting the red nucleus to various spinal cord nuclei. The superior cerebellar peduncle decussates at the level of the inferior colliculus. This peduncle is an efferent fibre system carrying fibres from the dentate nucleus to the opposite red nucleus and the ventral spinocerebellar tracts.

Grey matter: Grey matter in the dorsal midbrain, consist of: the nuclei of the third, fourth, fifth cranial nerves, the red nucleus, the interpeduncular ganglion, the substantia nigra, and the reticular formation. The red nucleus, positioned in the anterior part of the tegmentum, extends from the posterior part of the subthalamic region superiorly to the inferior one-third of the cerebral peduncle inferiorly. The interpeduncular ganglion occupies the lower third of the cerebral peduncle. The oculomotor and trochlear nuclei lie dorsal to the red nucleus, with the oculomotor nucleus positioned superior to the trochlear nucleus. The oculomotor nucleus is further divided into three parts: The main motor nucleus, Perlia's nucleus, and Edinger–Westphal nucleus.[2] It is located near the midline at the junction of the lower half of the superior colliculus and the upper half of the inferior colliculus, between the cerebral aqueduct dorsally and the decussation of the superior cerebellar peduncle ventrally. The intramesencephalic segment of the oculomotor nerve traverses inside and along the medial side of the red nucleus, exiting the midbrain in the lateral wall of the interpeduncular fossa from the oculomotor sulcus **(Figs. 6F and G)**.[1] The trochlear nucleus, situated below the oculomotor nucleus, is at the level of the lower half of the inferior colliculi. The trochlear nerve fibres exit the nucleus, loop dorsally around the aqueduct, and emerge on each side of the frenulum veli at the lower margin of the inferior colliculus. The neurons of the reticular formation are distributed between the red nucleus and the central grey matter, extending posteriorly up to the colliculi and the posterior commissure.[1-3]

PONS

Extent

The pons, aptly named as the "bridge", serves as the connecting link between the cerebrum and the cerebellum.

JAYPEE BROTHERS

It is positioned between the midbrain (mesencephalon) and the medulla (rhombencephalon).[2,3,5] The pons extends vertically from the pontomesencephalic sulcus at its superior end to the pontomedullary sulcus at its inferior end. On the ventral aspect of the pons, the abducens, facial, and vestibulocochlear nerves emerge from the pontomedullary sulcus

Parts/Divisions

The pons is anatomically divided into two parts by the trapezoid body and the medial lemniscus. These divisions create a ventral base and a dorsal tegmentum within the pons.

External Features

Anterior Corridor

The anterior corridor of the pons, also known as the basis pontis, presents a distinctive and prominent structure on its ventral surface **(Figs. 1, 2, 5, and 7)**. Running along its anterior surface is a shallow, vertical median furrow called the sulcus basilaris, which accommodates the basilar artery. Most of the ventral surface of the pons is occupied by the descending CSTs. Towards the lateral edges, the middle cerebellar peduncle (brachium pontis) blends with the ventral surface of the pons. The point where the trigeminal nerve emerges marks the boundary between the pons and the middle cerebellar peduncle. The facial nerve emerges from the pontomedullary sulcus in the space between the olive and the inferior cerebellar peduncle of the medulla oblongata. The fibres of the vestibular nerve enter the medulla oblongata on the medial side of the cochlear fibres and pass between the inferior peduncle and the spinal tract of the trigeminal nerve **(Figs. 7A to H)**.[1]

Lateral Corridor

The lateral surface of the pons features two significant structures: the middle cerebellar peduncle and the trigeminal nerve. The middle cerebellar peduncle consists of transverse pontine fibres that originate from the pontine nuclei in the basis pontis. At the midpontine level, the trigeminal nerve becomes visible as it emerges laterally on the lateral surface of the pons. The trigeminal nerve has two components: A small motor root located superomedially and a larger sensory root inferiorly and laterally **(Figs. 7A and B and 8)**.

On either side of the lower part of the pons, there is a region known as the cerebellopontine angle **(Figs. 7G and H)**. This area is closely associated with the facial, vestibulocochlear, and glossopharyngeal nerves.

Posterior Corridor

The dorsal section of the pons is an integral component of the floor of the fourth ventricle, and a more detailed description of it will be provided in the section dedicated to the fourth ventricle. The upper part of the roof of the fourth ventricle is constructed by the superior cerebellar peduncle and the superior medullary velum **(Figs. 9A to F)**.

Internal Features

The ventral region of the pons primarily comprises horizontal and vertical bundles of white fibres interspersed with a limited amount of grey matter. In contrast, the dorsal tegmental portion is predominantly composed of grey matter, which includes the reticular formation and various intrinsic brainstem nuclei.

Dorsal Pons

The grey matter located at the base of the pons consists of scattered pontine nuclei, which play a significant role in generating the pontocerebellar pathway.

Ventral Pons

White fibres: The white matter in the ventral pons is organized into three transverse bundles and one longitudinal bundle. The longitudinal fibre bundles include the CSTs, corticonuclear tract, and corticopontine tract. The transverse fibres are referred to as transverse pontine fibres, and they are grouped into three bundles based on their relationship to the descending CST **(Figs. 7B and C)**.

The outermost transverse fibres, known as the stratum superficiale pontis, are relatively thick and run anterior to the CST. The middle layer of transverse fibres, referred to as the stratum complexum, runs between the longitudinally oriented fibres of the CST, effectively separating them. The third and innermost layer, called the stratum profundum pontis, passes posterior to the pyramidal pathway (CST).[2,5]

As the longitudinal fibres of the corticopontine tract, cortinuclear tract, and CSTs descend from the crus cerebri, they initially enter the pons in a compact arrangement but

JAYPEE BROTHERS

quickly disperse into distinct fascicles. These fascicles are separated by pontine nuclei and transverse pontine fibres **(Figs. 7A to H)**. These fascicles then converge again into compact tracts, eventually emerging as the medullary pyramids at the pontomedullary junction.

The prominent appearance of the ventral pons is primarily due to the forward projection of the superficial transverse fibres by the longitudinally running CSTs. The corticopontine fibres, originating from the cerebrum, terminate on the pontine nuclei, which in turn give rise to the pontocerebellar fibres. The corticonuclear fibres of the pons end in the trigeminal, abducens, and facial nuclei. Consequently, the medial half of the pons is predominantly composed of the longitudinal CST, while the lateral half or peritrigeminal area primarily consists of transverse fibres originating from the pontine nuclei. These transverse pontine fibres converge to form the middle cerebellar peduncle.

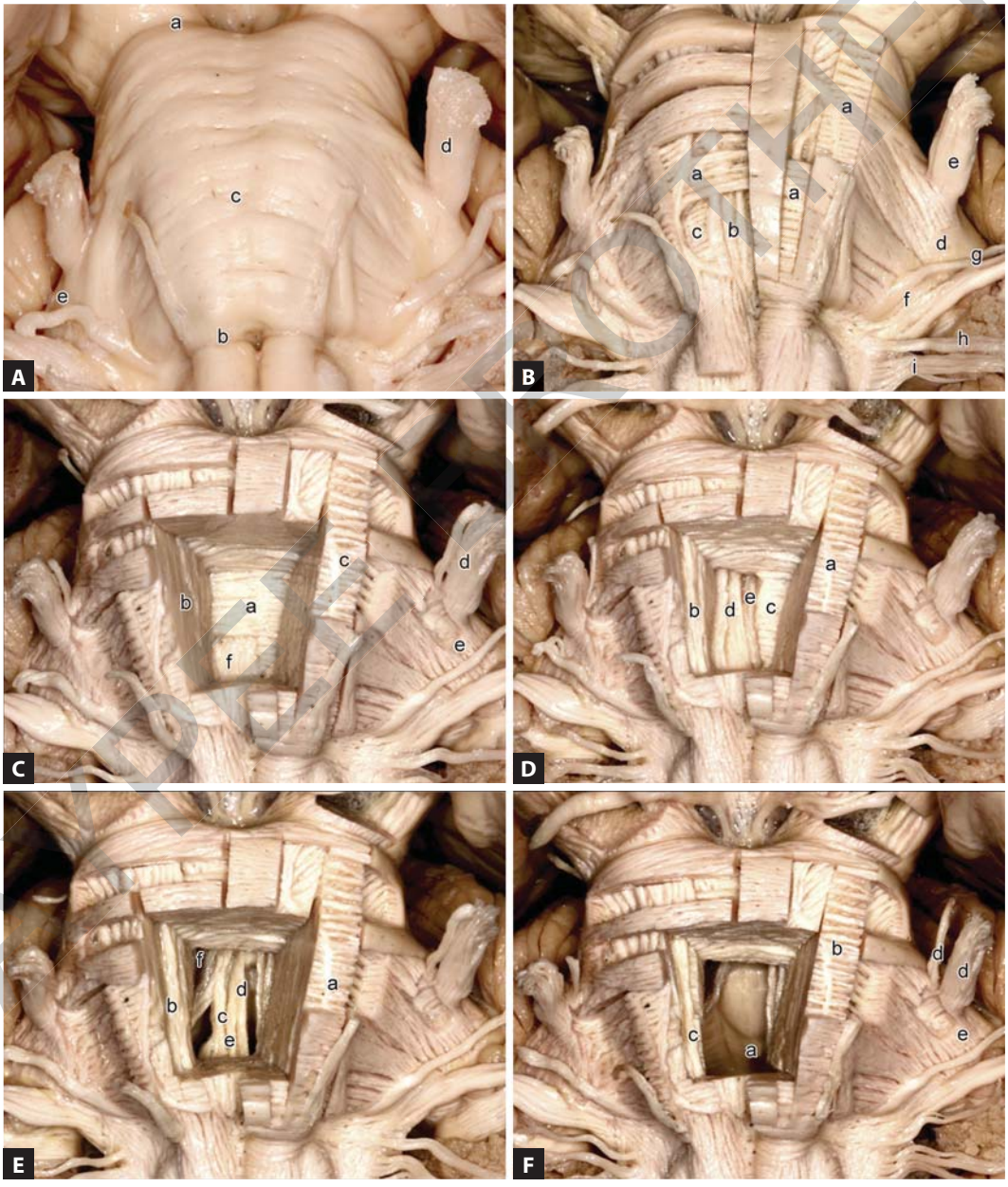

Figs. 7A to F

JAYPEE BROTHERS

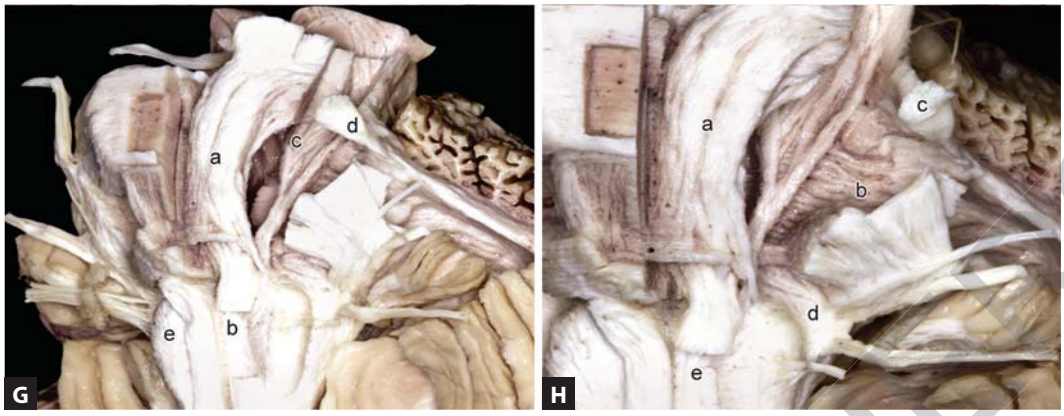

Figs. 7G and H

Figs. 7A to H: Fiber dissection of ventral pons. (A) The pons is the most prominent part of the brainstem on the ventral aspect and is located between the pontomesencephalic sulcus superiorly and the pontomedullary sulcus inferiorly. The inferior site of transition from pons to medulla is demarcated superficially by the ventrolateral sulcus in which the abducens, facial, and vestibulocochlear nerves emerge. Near the midpontine level the trigeminal nerve emerges on each side with a small superomedial motor root and a large inferolateral sensory root; (a) pontomesencephalic sulcus, (b) pontomedullary sulcus, (c) sulcus basilaris, and (d) trigeminal nerve, (e) abducens nerve; (B) The ventral pons has been dissected to demonstrate the longitudinal and transverse fibres tracts. Transverse fibres form three bundles of superficial, middle, and deep transverse fibre projections based on the relation to the longitudinal descending corticospinal fibres. Superficial transverse fibres can be seen as a thick layer of fibres on the ventral surface of the pons, ventral to the descending fibres of the corticospinal tract. The middle fibres run between the fibres of the corticospinal tract. The transverse pontine fibres collect together to form the middle cerebellar peduncle; (a) superficial transverse pontine fibres (stratum superficiale pontis), (b) corticospinal tract, (c) middle transverse pontine fibres (stratum complexum), (d) middle cerebellar peduncle, (e) trigeminal nerve, (f) vestibulocochlear nerve, (g) facial nerve, (h) glossopharyngeal nerve, and (i) vagus nerve; (C) The deep transverse fibres lie on the dorsal aspect of the corticospinal fibres. They course to the lateral border of the pons, where they form part of the middle cerebellar peduncle; (a) deep transverse pontine fibres (stratum profundum pontis), (b) corticospinal tract, (c) superficial transverse pontine fibres (stratum superficiale pontis), (d) trigeminal nerve, (e) middle cerebellar peduncle, and (f) medial lemniscus; (D) The dorsal or tegmental part of the pons is exposed after dissecting the deep transverse fibres. It is chiefly composed of the upward continuation of the reticular formation and grey matter of the medulla oblongata. More dorsal and adjacent to the deep transverse fibres is the flattened lemniscus band of ascending longitudinal fibre tracts. The medial lemniscus lies on either side as a flattened oval bundle, related laterally to the trigeminal and spinal lemniscus; (a) superficial transverse pontine fibres (stratum superficiale pontis), (b) corticospinal tract, (c) deep transverse pontine fibres (stratum profundum pontis), (d) medial lemniscus, and (e) medial longitudinal fasciculus; (E) On dissecting deep to the medial lemniscus, the next longitudinal fibre bundle is the medial longitudinal fasciculus, which is paramedian, ventral to the fourth ventricle, near the abducens nucleus with the facial fibres ascending lateral to this. The other longitudinal tract related laterally and ventrally is the central tegmental tract, which connects the red nucleus with the inferior olivary nucleus; (a) superficial transverse pontine fibres (stratum superficiale pontis), (b) corticospinal tract, (c) central tegmental tract, (d) medial longitudinal fasciculus, (e) tectospinal tract, and (f) locus coeruleus; (F) The fourth ventricle is visible here as a cavity in the pons. The upper portion of the roof of the fourth ventricle is formed by the superior cerebellar peduncle and superior medullary velum; (a) fourth ventricle, (b) superficial transverse pontine fibres (stratum superficiale pontis), (c) corticospinal tract, (d) trigeminal nerve (motor root is medial, sensory root is lateral), and (e) middle cerebellar peduncle; (G) Left oblique lateral view of fibre dissection of the pons; corticospinal fibres can be seen converging to the medullary pyramids as a compact bundle after traversing the ventral pons and the transverse fibres. Behind this is the medial lemniscus which forms a flat lamina of fibres extending from the median raphe. The medial lemniscus, when viewed from the lateral aspect, ascends through the pons forming a concave shape facing ventrally. The trigeminal nerve can be seen entering the upper margin of the anterior aspect of the pons, where its fibres can be seen entering perpendicular to the transverse pontine fibres going into the cerebellum via the middle cerebellar peduncle; (a) corticospinal tract, (b) medullary pyramid, (c) medial lemniscus, (d) trigeminal nerve, and (e) olive; (H) Close-up view of the same specimen shows the transverse running fibres of the middle cerebellar peduncle. The facial nerve can be seen to emerge at the lower border of the pons in the interval between the olive and the inferior peduncle of the medulla oblongata. The fibres of the vestibular nerve enter the medulla oblongata on the medial side of the cochlear fibres, and pass between the inferior peduncle and spinal tract of the trigeminal nerve; (a) corticospinal tract, (b) middle cerebellar peduncle, (c) trigeminal nerve, (d) facial and vestibulocochlear nerves, and (e) medullary pyramid.

JAYPEE BROTHERS

Grey matter: The grey matter located at the base of the pons consists of scattered pontine nuclei, which play a significant role in generating the pontocerebellar pathway.

Dorsal pons: In the dorsal or tegmental region of the pons, we find an upward extension of the reticular formation, as well as the grey matter found in the medulla oblongata. This area is characterised by white fibres, various grey matter masses within the brainstem, and the nuclei of cranial nerves. It is divided by a median raphe, although this division does not extend into the basilar portion of the pons, as it is obscured by the transverse pontine fibres.

White fibres: Dorsal to the ventral portion of the lower pons lies a structure called the trapezoid body, comprised of transversely oriented fibres that can be challenging to dissect due to their complex intermingling.[4,5]

The trapezoid body is formed by crossing fibres that originate in the ventral cochlear nuclei and then ascend laterally and superiorly as the lateral lemniscus. The region behind the trapezoid body, in proximity to the ventral pons, is occupied by important ascending tracts. The medial lemniscus is a longitudinally extended flat layer adjacent to the midline, situated just dorsal to the trapezoid body. When viewed from a lateral perspective, the medial lemniscus ascends through the pons, forming a concave shape facing dorsally **(Figs. 7G and H)**. Lateral to the medial lemniscus are the trigeminal and spinal lemnisci. Further laterally, in the upper pons, is the lateral lemniscus. Positioned even more dorsally, in proximity to the median raphe or midline, are the MLF, tectospinal tract, vestibulospinal tract, and rubrospinal tract. Lateral to these is the CTT and the spinal tract of the trigeminal nerve.

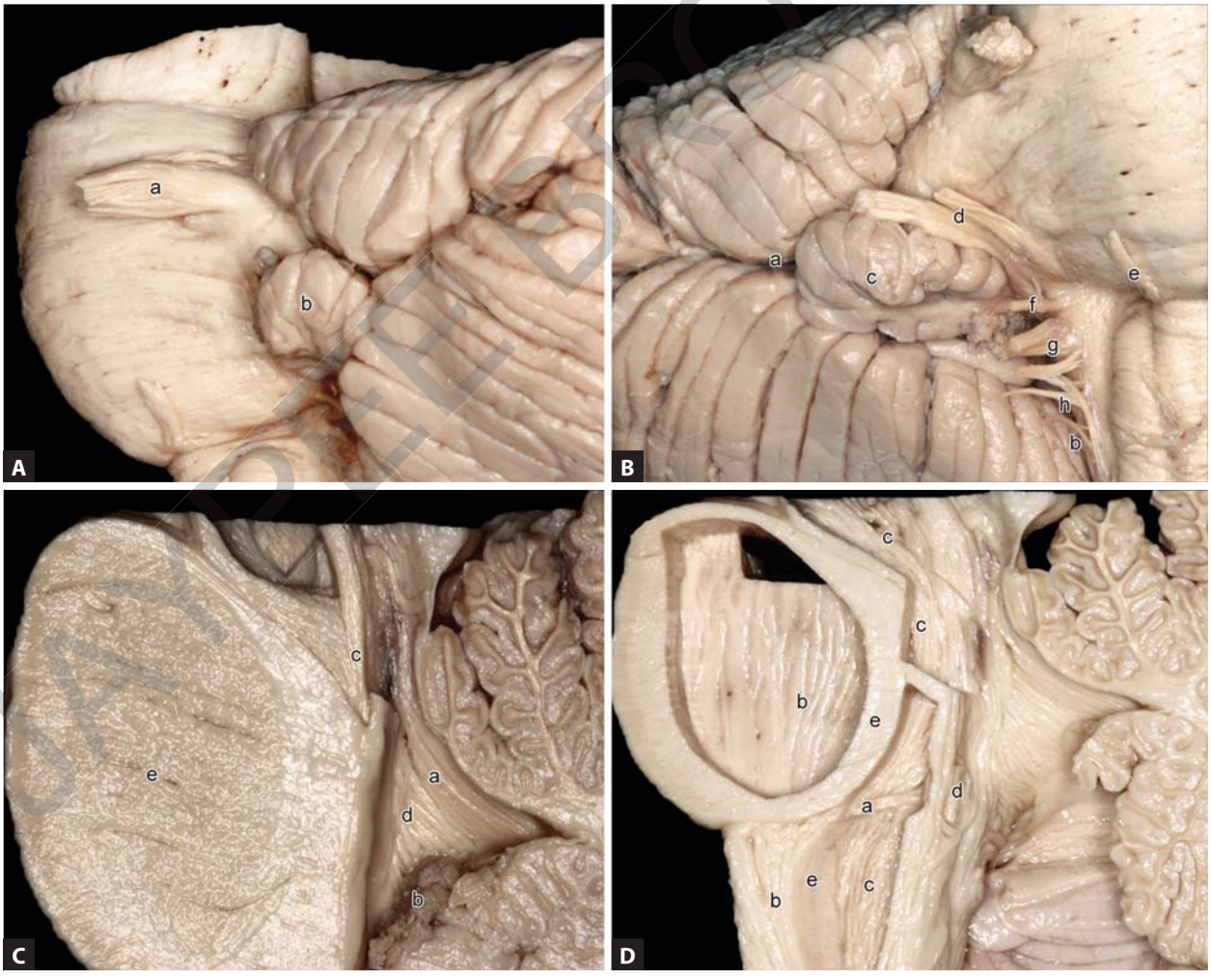

Figs. 8A to D

JAYPEE BROTHERS

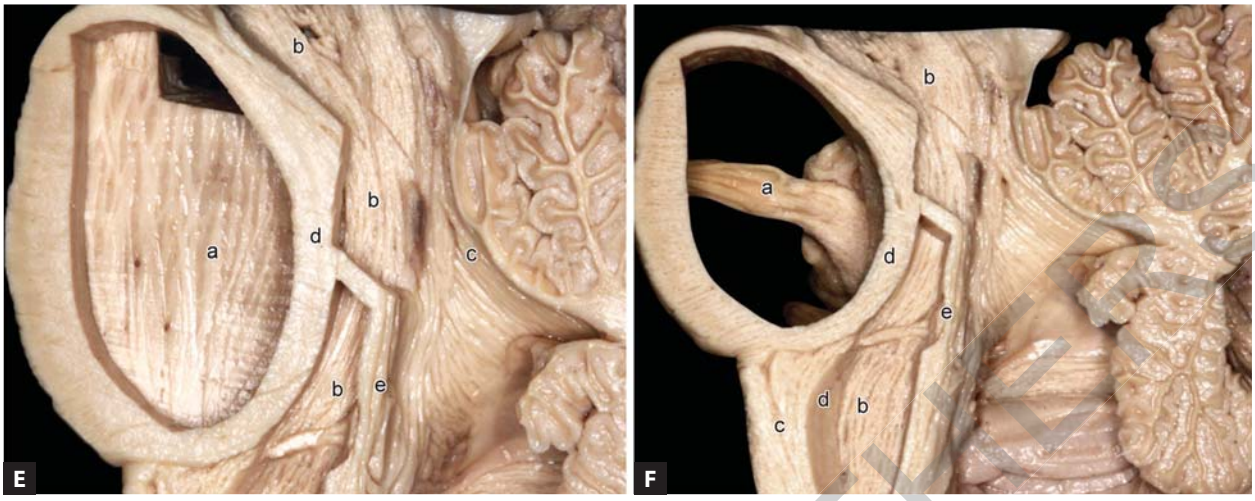

Figs. 8E and F

Figs. 8A to F: Fiber dissection of the midsagittal section of the pons. (A) Lateral view of the cerebellopontine angle; the trigeminal nerve can be seen arising from the upper margin of the ventral aspect of the pons. Below this is the flocculus of the cerebellum, which is an irregular lobular extension from the nodule of the vermis situated between the middle cerebellar peduncle and the biventral lobule of the cerebellum; (a) trigeminal nerve, and (b) flocculus. (B) Ventral view of the flocculus and its relation to cranial nerves; the cerebellopontine and cerebellomedullary fissure can be seen converging behind the flocculus. Fibres of the facial and vestibulocochlear nerves can be seen arising from the pontomedullary junction medial to the flocculus. The glossopharyngeal, accessory, and vagus nerves enters the posterolateral sulcus of the medulla medial and inferior to the flocculus; (a) cerebellopontine fissure, (b) cerebellomedullary fissure, (c) flocculus, (d) facial and vestibulocochlear nerves, (e) abducens nerve, (f) glossopharyngeal nerve, (g) vagus nerve, and (h) cranial part of accessory nerve. (C) Midsagittal view showing the roof of the fourth ventricle; the upper portion of the roof is formed by the superior peduncle and superior medullary velum. And the lower portion, by the inferior medullary velum. The epithelial lining of the ventricle is covered by the tela choroidea and tenia of the fourth ventricle; (a) superior cerebellar peduncle, (b) tela choroidea, (c) medial longitudinal fasciculus, (d) fourth ventricle, and (e) pons. (D) Fibre dissection of midsagittal section of pons; fibres of the abducens nerve can be seen arising from the abducens nucleus located near the floor of the fourth ventricle in a paramedian location in the lower half of the pons. Fibres, after emerging, pass ventrally and descend through the reticular formation and medial lemniscus and traverse the ventral pons to emerge at its inferior border; (a) abducens nerve fibres, (b) corticospinal tract, (c) central tegmental tract, (d) medial longitudinal fasciculus, and (e) medial lemniscus. (E) Sagittal view of the brainstem showing fibre dissection of the medial lemniscus and medial longitudinal fasciculus; the medial longitudinal fasciculus extends close to the midline and ventral to the floor of the fourth ventricle and ends in the interstitial nucleus of Cajal in the lateral wall of the third ventricle. The medial lemniscus ascends from the sensory decussation on each side as a flattened tract, near the median raphe. The tract increases in size as it ascends to the pons. When viewed from the side, as seen here, the medial lemniscus can be seen ascending through the pons forming a concave shape facing ventrally. In the midbrain, it forms a curved lamina dorsolateral to the substantia nigra to terminate in the thalamus; (a) corticospinal tract, (b) central tegmental tract, (c) superior cerebellar peduncle, (d) medial lemniscus, and (e) medial longitudinal fasciculus. (F) Midsagittal view of the motor and sensory root of the trigeminal nerve passing through the substance of the pons after removal of a portion of the dorsal pons; the nerve can be seen going towards the motor and main sensory nucleus close to its posterior surface and along the line of the lateral margin of the fourth ventricle. The sensory nucleus is lateral to the motor and beneath the superior cerebellar peduncle; (a) trigeminal nerve, (b) central tegmental tract, (c) corticospinal tract, (d) medial lemniscus, and (e) medial longitudinal fasciculus.

Grey matter: The remainder of the dorsal part of the pons contains the upward extension of the reticular formation from the medulla oblongata. Among these scattered nerve cells, there are some prominent clusters of grey matter, including the superior olivary nucleus and the nuclei associated with the trigeminal, abducens, facial, and vestibulocochlear nerves. From lateral to medial, and at different levels within the pons, these structures include the dorsal and ventral cochlear nuclei, the main sensory nucleus of the trigeminal nerve, the motor nucleus of the trigeminal nerve, the nuclei of the lateral lemniscus, and the facial nucleus. Positioned more medially are the vestibular nuclei and the abducens nucleus. These nuclei will be discussed in more detail in the section dedicated to the floor of the fourth ventricle.

JAYPEE BROTHERS

MEDULLA

Extent

The medulla oblongata stretches from the superior boundary, where it connects with the pons, to the inferior boundary, where it transitions into the spinal cord. The border between the medulla and the spinal cord is defined by a horizontal plane that lies below the pyramidal decussation.

Parts/Divisions

The medulla oblongata has a pyramidal shape, with its wider upper end extending towards the pons, while its narrower lower end seamlessly continues into the spinal cord **(Figs. 9A to F)**. The central canal of the spinal cord extends into the lower half of the medulla oblongata and then opens into the cavity of the fourth ventricle in its upper half. As a result, the medulla oblongata can be divided into two parts: A lower closed segment that contains the central canal and an upper open part that corresponds to the lower portion of the fourth ventricle.

External Features

The surface of the medulla is characterised by a series of fissures and sulci that divide it into three distinct regions **(Figs. 9A and B)**. In the midline, ventrally, the anterior median fissure, and dorsally, the posterior median sulcus are the upward extensions of corresponding features observed in the spinal cord. These two sulci bisect the medulla into two halves. The anterior median fissure extends along the entire length of the ventral medulla. It terminates at the lower border of the pons as an enlarged, triangular structure known as the foramen caecum **(Figs. 9D and E)**. The lower end of the anterior median fissure is interrupted by the obliquely intersecting fibres of the pyramidal decussation **(Fig. 9F)**. The posterior median fissure exists solely in the closed portion of the medulla oblongata and gradually becomes

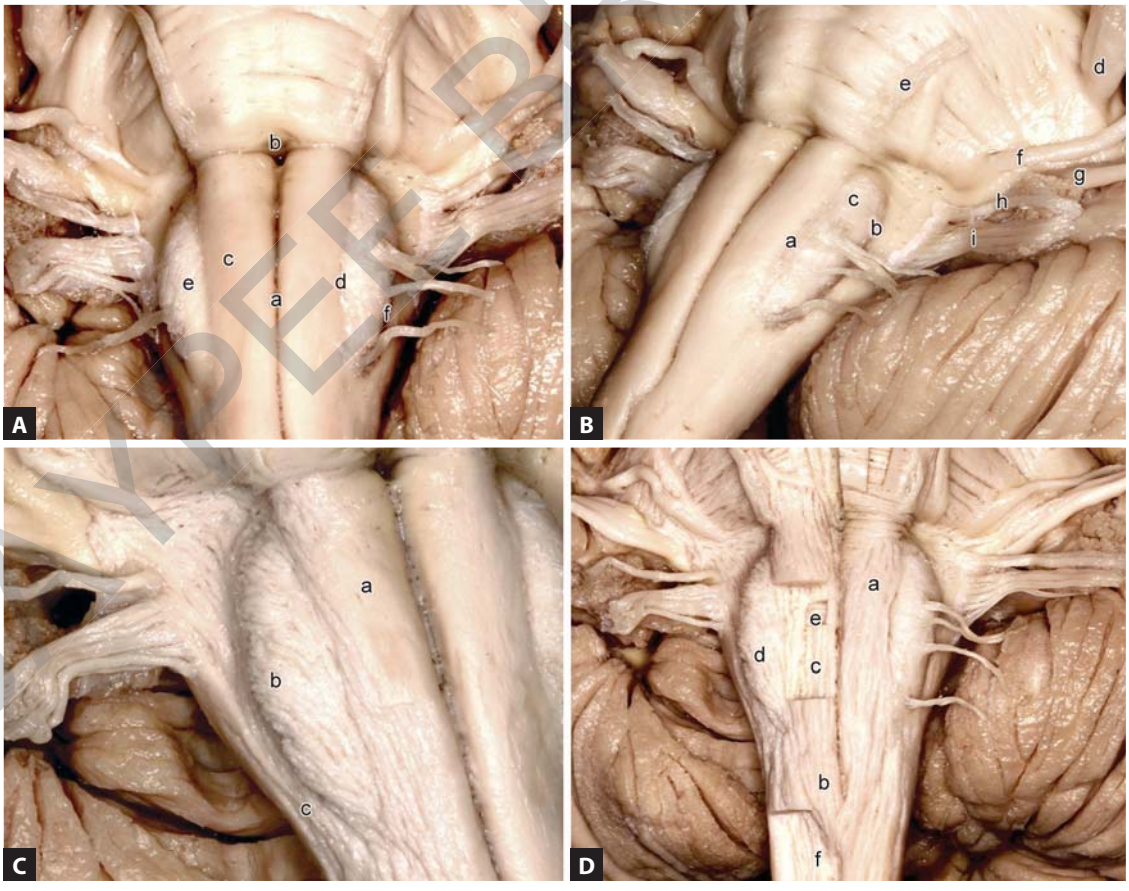

Figs. 9A to D

JAYPEE BROTHERS

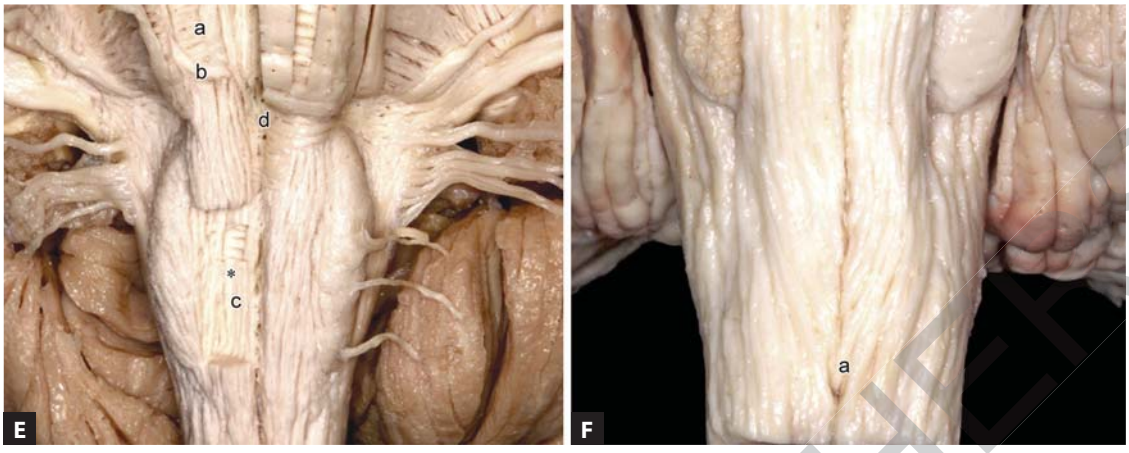

Figs. 9E and F

Figs. 9A to F: Superficial fibre dissection of the medulla oblongata. (A) The medulla oblongata is pyramidal in shape with its broad extremity being directed upwards towards the pons, while its narrow, lower end is continuous with the spinal cord. The medulla oblongata extends from the lower margin of the pons to a plane passing transversely below the pyramidal decussation and above the first pair of cervical nerves. The anterior median fissure ends superiorly at the lower border of the pons into a small triangular depression called the foramen caecum, and its lower end is interrupted by the pyramidal decussation. The region between the anterolateral sulcus and posterolateral sulcus is the lateral compartment. Its upper part contains an oval prominence called the olive, and the lower part is only partly continuous with the spinal lateral funiculus. Hypoglossal rootlets can be seen, emerging from the anterolateral sulcus, whereas, the accessory, vagus, and glossopharyngeal nerves are visible entering through the posterolateral sulcus; (a) anterior median fissure, (b) foramen caecum, (c) pyramid, (d) anterolateral sulcus, (e) olive, and (f) hypoglossal nerve rootlets. (B) Oblique lateral view of the medulla showing the lateral region. The lateral district is limited in front by the anterolateral sulcus and the roots of the hypoglossal nerve, and posteriorly by the posterolateral sulcus and the roots of the accessory, vagus, and glossopharyngeal nerves. The olive can be seen in the upper part, while its lower part is of the same width as the lateral funiculus of the spinal cord, and appears on the surface to be a direct continuation of it; (a) anterolateral sulcus, (b) posterolateral sulcus, (c) olive, (d) trigeminal nerve, (e) abducens nerve, (f) facial nerve, (g) vestibulocochlear nerve, (h) rootlets of the glossopharyngeal nerve, and (i) rootlets of the vagus nerve. (C) Oblique lateral view of olive with superficial fibre dissection. Some fibres, termed the anterior external arcuate fibres, emerge from the fissure and curve lateralwards and upwards over the surface of the medulla oblongata to join the inferior peduncle. The ventral spinocerebellar fasciculus is continued upward on the lateral surface of the medulla oblongata in the same relative position it occupies in the spinal cord until it passes under cover of the external arcuate fibres. It passes beneath these fibres just dorsal to the olive and ventral to the roots of the vagus and glossopharyngeal nerves, and it continues upward through the pons along the dorsolateral edge of the lateral lemniscus. The dorsal spinocerebellar fasciculus is carried into the inferior peduncle in the posterior district; (a) pyramid, (b) anterior external arcuate fibres, and (c) ventral spinocerebellar fasciculus. (D) Fibre dissection of the anterior and lateral district of medulla. The two pyramids contain the motor fibres which pass from the brain to the medulla oblongata and spinal cord. Pyramidal fibres can be seen decussating in the lower medulla; (a) pyramid, (b) pyramidal decussation, (c) medial lemniscus, (d) olive, (e) olivo-olivary fibres, and (f) uncrossed fibres of the corticospinal tract. (E) Close-up view of the upper end of the medulla at the pontomedullary junction. The corticospinal fibres can be seen here as a compact bundle at the lower end of the pons as they continue along either side of the anterior median fissure into the medullary pyramids. Its upper end is slightly constricted, and between it and the pons, the fibres of the abducens nerve emerge; (a) corticospinal tract, (b) abducens nerve, (c) medial lemniscus, and (d) foramen caecum. The asterisk shows the area where the corticospinal tracts have been cut. (F) View of the lower end of the medulla showing the pyramidal decussation. Approximately two-thirds of the fibres of the corticospinal tract leave the pyramids in successive bundles, and decussate in the anterior median fissure, forming what is termed the pyramidal decussation; (a) pyramidal decussation.

shallower from below upwards. It ultimately disappears around the middle of the medulla oblongata, where the central canal widens into the cavity of the fourth ventricle.

Each half of the medulla is demarcated by two sulci: The anterolateral sulcus and the posterolateral sulcus, which are also extensions of the corresponding sulci observed in the spinal cord.[4] The anterolateral sulcus is aligned with the ventral roots of spinal nerves, from which the fibres of the hypoglossal nerve emerge in a linear arrangement. Similarly, the posterolateral sulcus is in line with the dorsal nerve roots of the spinal cord, from which the rootlets of the accessory, vagus, and glossopharyngeal nerves emerge. Based on the presence of these sulci, each half of the medulla oblongata is further subdivided into three distinct districts: Anterior, middle, and posterior.

JAYPEE BROTHERS

Anterior Corridor

The anterior district is located between the anterior median fissure and the anterolateral sulcus and is primarily occupied by the pyramids **(Figs. 9A to C)**. After crossing the midline in the region of the lower part of the anterior median fissure, these fibres continue descending in the posterior section of the lateral funiculus of the spinal cord as the lateral corticospinal fasciculus.[5] The remaining fibres, situated in the lateral part of the pyramid, do not cross the midline but descend as the anterior corticospinal fasciculus into the anterior funiculus on the same side. Additionally, the sixth cranial nerve can be observed emerging from the pontomedullary sulcus anterior to the pyramids.

Lateral Corridor

The lateral district is bordered anteriorly by the anterolateral sulcus and posteriorly by the posterolateral sulcus. The roots of the hypoglossal nerve emerge from the anterolateral sulcus, while the roots of the accessory, vagus, and glossopharyngeal nerves emerge from the posterolateral sulcus **(Fig. 9B)**. The upper part of the lateral district features a prominent oval mass known as the olive. The olive does not extend all the way up to the pons. Just before reaching the pons, there is a small depression at the upper end of the olive, referred to as the supraolivary fossa. This is where the facial nerve and nervus intermedius emerge. Another depression, called the lateral fossa, lies posterior to the supraolivary fossa, from which the vestibulocochlear nerves emerge. The lower portion of the lateral district is of similar width to the lateral funiculus of the spinal cord and appears to be a direct continuation of it **(Fig. 9C)**. Only a few fibre bundles that constitute the lateral column of the spinal cord continue to ascend within the lateral district. The lateral CST from the lateral funiculus of the spinal cord curves medially at the pyramidal decussation, assuming its position in the anterior district of the opposite side. The dorsal spinocerebellar fasciculus continues its upward path within the inferior cerebellar peduncle. Therefore, only the ventral spinocerebellar fasciculus continues in the lateral district of the medulla, beneath the external arcuate fibres originating from the lateral spinal funiculus **(Fig. 9C)**.

Posterior Corridor

The posterior district lies between the posterior median sulcus and the posterolateral sulcus and houses the tracts entering from the posterior funiculus of the spinal cord **(Fig. 9C)**. These tracts are the fasciculus gracilis medially and the fasciculus cuneatus laterally.[1] These fasciculi terminate in rounded elevations known as the gracile and cuneate nuclei. Lateral to the cuneate fasciculus, there is an elevation formed by the spinal nucleus of the trigeminal nerve and its associated tract. This elevation is referred to as the tuberculum cinereum or the trigeminal tubercle (not to be confused with the tuber cinereum in the floor of the third ventricle).[1] The posterior surface of the upper medulla forms the lower portion of the floor of the fourth ventricle. This fossa is flanked on either side by the inferior cerebellar peduncles. The features of this part of the medulla are described in more detail in the context of the floor of the fourth ventricle.

Internal Features

The internal arrangement of grey and white matter in the lower closed part of the medulla resembles that of the spinal cord. However, as we move higher into the medulla, changes occur due to the presence of the fourth ventricle. The grey matter, which in the spinal cord forms a continuous H-shaped column, undergoes significant modifications and subdivisions in the medulla oblongata. Additionally, due to the expansion of the central canal of the spinal cord, certain parts of the grey matter that were centrally located in the spinal cord are displaced into the floor of the fourth ventricle.

White Fibres

A detailed dissection of fibre tracts in this region is quite challenging, but an overall understanding of the relationships between pyramidal tracts, central grey matter, and dorsal ascending tracts has been studied and is elaborated **(Figs. 9 and 10)**.[1]

Starting dorsally, the gracile and cuneate fasciculi, or the dorsal columns, continue upward into the lower part of the medulla oblongata, where they terminate in the gracile and cuneate nuclei. Second-order neurons, originating from these nuclei (internal arcuate fibres), pass forward through the neck of the posterior column. These fibres curve forward, decussate in the midline with corresponding fibres of the opposite side, and run upward immediately behind the CST as a flattened band known as the medial lemniscus. This decussation is also referred to as the sensory decussation and is located superior to the pyramidal decussation of motor fibres. Further laterally, the medial lemniscus is joined by the ipsilateral anterior

JAYPEE BROTHERS

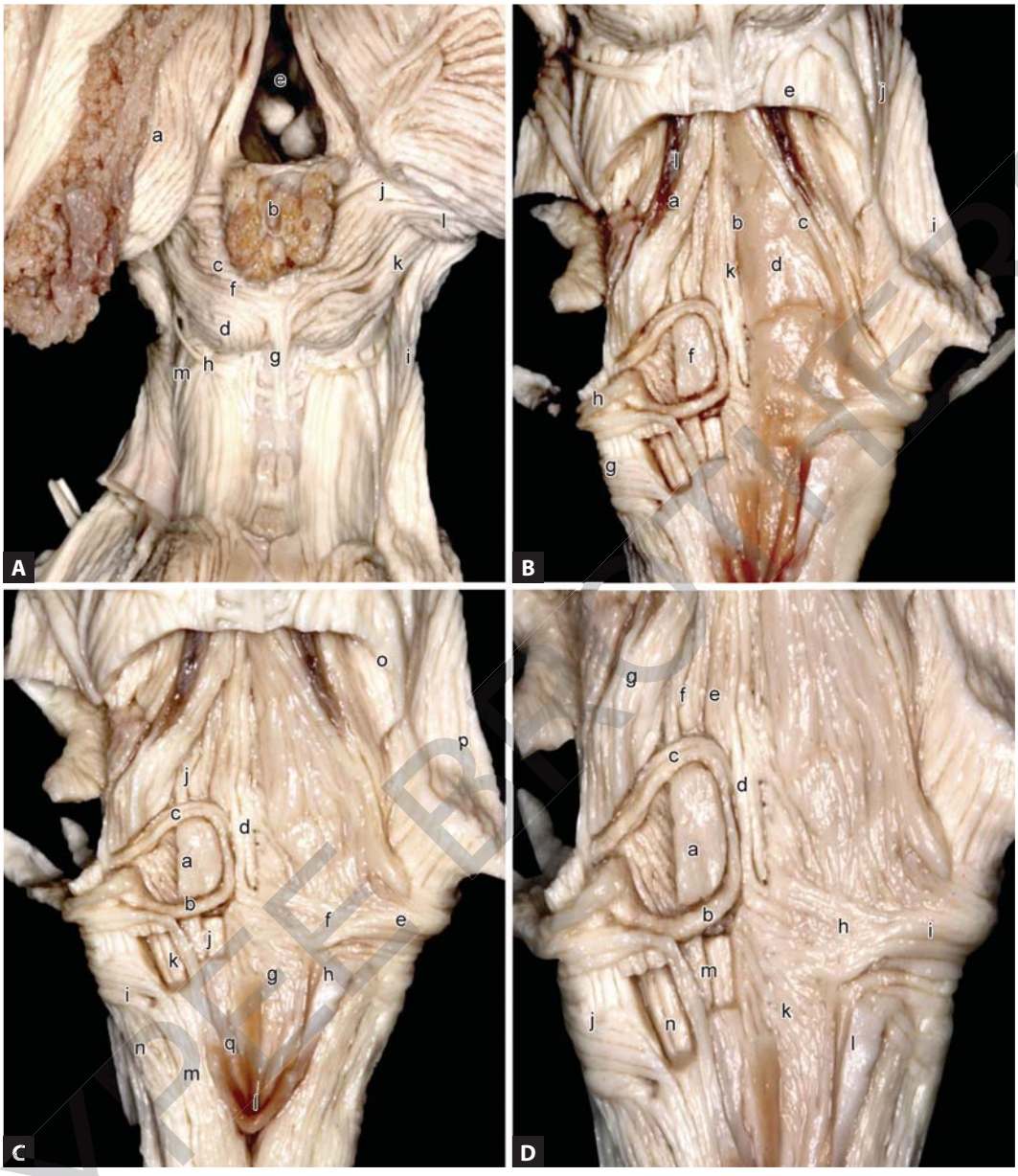

Figs. 10A to D: Fibre dissection of the dorsal midbrain and floor of the fourth ventricle. (A) Posterior view of the brainstem with superficial fibre dissection of the pulvinar, pineal gland, tectal plate, and superior cerebellar peduncle. Corpora quadrigemina can be seen here, above and in front of the superior medullary velum and superior peduncle, and below and behind the third ventricle and posterior commissure. The superior and inferior colliculi can be seen separated from one another by a crucial sulcus. The pineal body is a cone-like structure, which projects backwards and partly obscures the superior colliculi. From the inferior end of the longitudinal sulcus, a white band, termed the frenulum veli, is prolonged downwards to the anterior medullary velum; on either side of this band the trochlear nerve emerges. The superior brachium extends laterally from the superior colliculus, and, passing between the pulvinar and medial geniculate body, is partly continued into an eminence called the lateral geniculate body, and partly into the optic tract. The inferior brachium passes forwards and upwards from the inferior colliculus and disappears under cover of the medial geniculate body; (a) pulvinar of the thalamus, (b) pineal body, (c) superior colliculus, (d) inferior colliculus, (e) third ventricle, (f) cruciate sulcus, (g) frenulum veli, (h) trochlear nerve, (i) superior cerebellar peduncle, (j) superior brachium, (k) inferior brachium, (l) medial geniculate body, and (m) lateral lemniscus. (B) The roof has been removed on both sides exposing the floor of the fourth ventricle also called the rhomboid fossa. One side superficial fibre dissection has been done, while preserving the ependymal floor on the other side. The fossa is divided into three parts—superior, intermediate, and inferior. The superior part is triangular and limited laterally by the superior cerebellar

Contd...

JAYPEE BROTHERS

Contd...

peduncle and its base is represented by an imaginary line at the level of the upper ends of the superior fovea. The intermediate part extends from this level to that of the horizontal portions of the taeniae of the ventricle. The inferior part is triangular, and its downwardly directed apex, named the calamus scriptorius, is continuous with the central canal of the closed part of the medulla oblongata. The facial colliculus, which overlies the nucleus of the abducens nerve and ascending portion of the root of the facial nerve can be seen on the right side after fibre dissection. The hypoglossal trigone is visible on the left side as a triangular region in lower part. The trigone is seen to consist of a medial and a lateral area separated by a series of oblique furrows. The medial area corresponds with the upper part of the nucleus of the hypoglossal nerve, the lateral with a small nucleus, the nucleus intercalatus; (a) mesencephalic tract of the trigeminal nerve, (b) medial sulcus, (c) sulcus limitans, (d) superior fovea, (e) superior cerebellar peduncle, (f) abducens nucleus, (g) inferior cerebellar peduncle, (h) facial nerve, (i) middle cerebellar peduncle, (j) lateral lemniscus, (k) medial longitudinal fasciculus, and (l) locus coeruleus. (C) Superficial fibre dissection of the floor of the fourth ventricle and facial colliculus. The most superficial layer of the floor of the fourth ventricle is an ependymal lining and a subependymal layer of glia has been removed on the left. The abducens nerve nucleus and the facial nerve fibres looping around it form the elevation on the floor of the fourth ventricle called as the facial colliculus. The fibres of the facial nerve pursue a tortuous course in the substance of the pons. At first, they pass backwards and medially until they reach the rhomboid fossa, close to the median sulcus, where they are collected into a round bundle; this passes upwards and forwards, producing an elevation, in the rhomboid fossa, and then takes a sharp bend, and arches laterally through the substance of the pons. The ascending part of the internal genu of the facial nerve is medially related to the fibres of the medial longitudinal fasciculus. Lateral to the fovea is a rounded elevation of vestibular area extending into the lateral recess where it forms a feebly marked swelling, the auditory tubercle. White fibrous strands called striae medullares can be seen crossing the vestibular area and medial eminence and disappear into the median sulcus. Caudal to the inferior fovea between the hypoglossal triangle and lower part of the vestibular area is the vagal triangle overlying the dorsal vagal nucleus; (a) abducens nucleus, (b) inferior fibres of the facial nerve, (c) superior fibres of the facial nerve, (d) medial longitudinal fasciculus, (e) vestibular area, (f) striae medullaris, (g) hypoglossal trigone, (h) region of the solitary nucleus and tract, (i) inferior cerebellar peduncle, (j) central tegmental tract, (k) spinal tract of trigeminal nerve, (l) area postrema, (m) fasciculus gracilis, (n) fasciculus cuneatus, (o) superior cerebellar peduncle, (p) middle cerebellar peduncle, and (q) vagal trigone. (D) Close-up view of the rostral and intermediate floor of the fourth ventricle. Fibre dissection done to demonstrate the facial colliculcus with facial nerve fibres, medial longitudinal fasciculus, trigeminal mesencephalic tract, and central tegmental tract. The trigeminal mesencephalic tract ascends deep to the floor of the fourth ventricle between the superior cerebellar peduncle laterally, sulcus limitans medially, central tegmental tract ventrally, and locus coeruleus dorsally. The central tegmental fasciculus is a group of efferent fibres from the red nucleus to the inferior olivary nucleus. The central tegmental tract is located deep to the locus coeruleus and trigeminal mesencephalic tract and dorsal to the medial lemniscus; (a) abducens nucleus, (b) inferior fibres of the facial nerve, (c) superior fibres of the facial nerve, (d) medial longitudinal fasciculus, (e) suprafacial safe entry zone, (f) central tegmental tract, (g) mesencephalic nucleus and tract of the trigeminal nerve, (h) striae medullares, (i) acoustic tubercle, (j) inferior cerebellar peduncle, (k) hypoglossal trigone, (l) region of nucleus and tract of solitarius, (m) infrafacial safe entry zone, and (n) spinal tract of the trigeminal nerve.

and lateral spinothalamic tracts, with fibres derived from the cells of the grey matter on the opposite side of the spinal cord. These anterior and lateral spinothalamic tracts ascend as the spinal lemniscus.

Lateral to the pyramids and the olive, the white matter of the medulla consists of the spinocerebellar tracts. The ventral and dorsal spinocerebellar tracts ascend from the spinal cord to occupy the lateral district of the medulla, located between the olivary nucleus and the inferior cerebellar peduncle. Both the ventral and dorsal spinocerebellar pathways ultimately reach the cerebellar vermis via the superior and inferior cerebellar peduncles, respectively. Additionally, lateral to the spinocerebellar tracts is the inferior cerebellar peduncle.

On the ventral aspect of the medulla, the white matter consists of the corticospinal and corticonuclear fibres. The CSTs form the bulk of the pyramids. The corticonuclear fibres occupy the posterior and medial portion of the pyramids and reach the ambiguous and hypoglossal nuclei. On the surface of the pyramids and the olive, transverse fibres known as the anterior external arcuate fibres are visible. These fibres are said to originate in the arcuate nucleus, traverse over the surface of the pyramids and the olive, and then enter the inferior cerebellar peduncle. The arcuate nucleus is located on the anterior and medial aspect of the pyramid close to the midline. Other white matter tracts within the substance of the medulla include the MLF and the tectospinal tracts medially, and the vestibulospinal, rubrospinal, and reticulospinal tracts laterally. Further laterally, lies the spinal tract of the trigeminal nerve.

Grey Matter

The grey matter of the medulla oblongata comprises nuclei of the cranial nerves and native grey matter specific to the medulla. Here is a breakdown of the major components:

JAYPEE BROTHERS

- *Motor nuclei:*
  Hypoglossal nucleus: This nucleus is a continuation of the base of the anterior horn of the spinal cord into the medulla. In the closed part of the medulla, it is located anterolateral to the central canal but moves to the midline in the floor of the fourth ventricle, forming an eminence known as the hypoglossal trigone **(Fig. 9C)**. Nerve roots emerge from the ventral side of the nucleus, passing forwards between the reticular formation and emerging from the anterolateral sulcus.

  Nucleus ambiguus: This nucleus represents the somatic motor nucleus of the glossopharyngeal, vagus, and cranial portion of the accessory nerves. It is a continuation of the dorsolateral cell group of the anterior column of the spinal cord into the medulla.[1] Fibres of the nucleus ambigus pass dorsally, approaching the floor of the fourth ventricle, where they bend laterally and anteriorly to join the fibres of the dorsal nucleus.
- *Sensory nuclei:*
  Dorsal nucleus: Also known as the sensory or terminal nucleus, it constitutes the base of the posterior horn of the spinal cord and extends on the dorsal portion of the central canal in the closed part of the medulla.[1] In the upper portion, it shifts laterally in the floor of the fourth ventricle. This nucleus receives sensory fibres from the glossopharyngeal and vagus nerves and, further laterally, from the vestibular part of the acoustic nerve and the sensory root of the facial nerve. Higher up, it forms the locus coeruleus, a mass of pigmented cells where some sensory fibres of the trigeminal nerve seem to end.

  Nucleus of the solitary tract: This sensory nucleus receives afferent visceral (taste) fibres from the facial, glossopharyngeal, and vagus nerves. It is situated dorsal to the central canal in the closed portion of the medulla and moves posterolaterally to the dorsal motor nucleus of the vagus in the upper open part of the medulla.[1]

  Nucleus of the spinal tract of the trigeminal nerve: This nucleus, the lateralmost of the cranial nerve nuclei in the medulla, lies lateral to the cuneate nucleus in the closed portion, and further upwards, both the tract and the nucleus are present medial to the inferior cerebellar peduncle.

  Gracile and cuneate nuclei: Represented on the surface of the medulla by the gracile and cuneate tubercles, these nuclei are responsible for proprioception and fine touch.

  Inferior olivary nucleus: This nucleus appears on the surface of the medulla as the olive and is involved in motor control.

  Dorsal and medial accessory olivary nuclei: These nuclei are situated on the ventral and dorsal aspects of the inferior olivary nucleus, respectively, contributing to various motor functions and coordination.

  These nuclei collectively form the intricate network of grey matter within the medulla oblongata, playing crucial roles in sensory and motor functions.

FLOOR OF FOURTH VENTRICLE

External Features

The floor of the fourth ventricle, also known as the rhomboid fossa due to its shape, is in the posterior part of the brainstem and constitutes the ventral wall of the fourth ventricle **(Figs. 10A to D)**. It is divided into three parts: Superior, intermediate, and inferior **(Figs. 10B and C)**.

Superior portion: This part of the floor is triangular, with its apex pointing superiorly and its base facing inferiorly. It is bounded laterally by the superior cerebellar peduncles. The base is an imaginary line passing through the upper ends of the superior fovea.

Intermediate portion: This area lies between the superior and inferior triangles and extends from the upper parts of the superior fovea superiorly to the horizontal portion of the taenia inferiorly. It is limited laterally by the middle cerebellar peduncle and the lateral recesses of the fourth ventricle inferiorly **(Figs. 10C and D)**.

Inferior portion: This is also triangular in shape but inverted, with the apex pointing inferiorly and the base superiorly. The apex of this part is known as the calamus scriptorius, which continues with the central canal. The inferior portion is bounded laterally by the inferior cerebellar peduncles.

The floor of the fourth ventricle presents several distinct features. The median sulcus divides it into two halves, and on each side of this sulcus lies an elevation known as the medial eminence, which is flanked laterally by the sulcus limitans **(Fig. 10B)**.

JAYPEE BROTHERS

The superior part of the medial eminence is distinguished by the facial colliculus, formed by the abducens nerve nucleus and the ascending portion of the facial nerve fibres. As you move downwards, the medial eminence transitions into a triangular area called the hypoglossal trigone. This trigone contains a medial region formed by the hypoglossal nucleus and a lateral area composed of the nucleus intercalatus, separated by oblique furrows. The sulcus limitans, forming the lateral border of the medial eminence, deepens at its superior and inferior ends to create the superior and inferior fovea. The superior fovea, which is triangular, is bounded by the superior cerebellar peduncle, the vestibular area, and the sulcus limitans. It accommodates the main sensory and motor nuclei of the trigeminal nerve, with the locus coeruleus positioned ventrally.

The inferior fovea constitutes the vagal trigone, greyish in appearance and covering the dorsal nucleus of the vagus nerve **(Figs. 10B and C)**. Adjacent to these foveae lies the vestibular area, extending into the lateral recess. Within this area, the auditory tubercle is prominent. Winding around the inferior cerebellar peduncle are fibrous strands known as striae medullares, a component of the cochlear division of the acoustic nerve, which disappear into the median sulcus.

Further caudal to the inferior fovea and between the hypoglossal triangle and the lower part of the vestibular area lies the vagal triangle, overlying the dorsal vagal nucleus. This triangle is traversed below by a narrow translucent ridge called the funiculus separans. Adjacent to this ridge, between it and the gracile tubercle, is a small tongue-shaped area known as the area postrema **(Figs. 10A to D)**. These delineations and structures contribute to the complex anatomy of the floor of the fourth ventricle.

Internal Structure of the Floor of the Fourth Ventricle

The internal structure of the floor of the fourth ventricle reveals the relationship of the deep structures to the surface. The most superficial layer of the floor of the fourth ventricle is composed of the ependymal lining and a subependymal layer of glial cells.

Facial colliculus: The facial colliculus is an elevation on the floor of the fourth ventricle and is formed by the nucleus of the abducens (VI) nerve and the facial (VII) nerve fibres looping around it **(Figs. 10C and D)**. The nucleus of the facial nerve is situated deep within the reticular formation of the pons, on the dorsal aspect of the superior olivary nucleus. The nerve fibres arising from the facial nerve nucleus follow a tortuous course within the substance of the pons.

Course of the facial nerve fibres: The facial nerve fibres initially pass dorsally and medially, until they reach the lower pole of the abducens nucleus near the rhomboid fossa. Here, they collect into a round bundle, which passes upwards and forwards on the medial side of the nucleus, creating an elevation in the rhomboid fossa. Near the upper pole of the nucleus, these fibres take a sharp bend and arch laterally through the substance of the pons **(Fig. 10D)**. This ascending portion of the internal genu of facial nerve fibres is located medially in relation to the fibres of the MLF.

Medial longitudinal fasciculus: The MLF courses adjacent to the midline near the floor of the fourth ventricle and connects the third, fourth, and sixth cranial nerve nuclei **(Fig. 10D)**. It plays a crucial role in coordinating eye movements and gaze.

Trigeminal nerve (V): After reaching its motor and main sensory nucleus in the pons, the trigeminal nerve divides into a rostrally directed trigeminal mesencephalic nucleus tract and a caudally directed spinal tract. The trigeminal mesencephalic tract ascends deep to the floor of the fourth ventricle, positioned between the superior cerebellar peduncle laterally, the sulcus limitans medially, the CTT ventrally, and the locus coeruleus dorsally **(Fig. 10D)**.

Central tegmental tract: The CTT is a group of efferent fibres that originate from the red nucleus in the dorsomedial region of the midbrain and descend ipsilaterally. It passes dorsally through the decussation of the superior cerebellar peduncle and laterally to the MLF. The CTT is located deep to the locus coeruleus, the trigeminal mesencephalic tract, and dorsal to the medial lemniscus.

Understanding the internal structure of the floor of the fourth ventricle is essential for comprehending the anatomical and functional relationships of cranial nerves and pathways in this region.

ORGANISATION OF WHITE FIBRES OF THE BRAINSTEM (FIGS. 11 TO 13)

The major bulk of the brainstem is made up of white fibres and within it is the interspersed grey matter. The grey matter of the brainstem consists of nuclei of the cranial nerves and some native brainstem nuclei. The white matter

JAYPEE BROTHERS

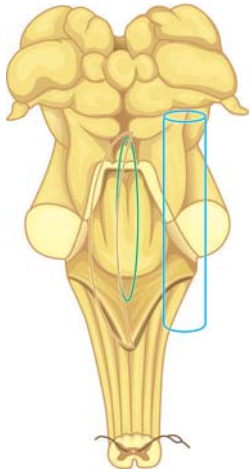

Fig. 11: Schematic dorsal view of the brainstem showing the division of white fibres into three zones. Blue cylinder—zone 1 or outermost zone, yellow crescent—zone 3 or middle zone, green oval—zone 2 or innermost zone.

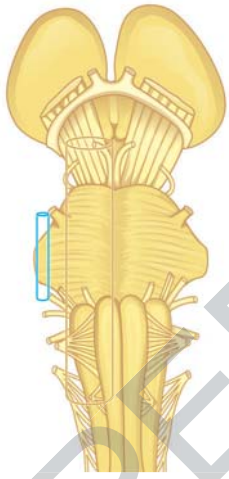

Fig. 12: Schematic ventral view of the brainstem showing the zones. Blue cylinder—zone 1 or outermost zone (note: Most of the fibres in zone 1 are seen on the dorsal aspect of the brainstem). Yellow cylinder—zone 2 or middle zone; zone 3 has not been depicted in this image as it lies in the centre of the brainstem and is better visualised from the dorsal aspect.

of the brainstem can be said to be composed of three types of fibres.[4] These fibres are arranged into three zones within the brainstem, with each zone playing a distinct role in connecting different regions of the central nervous system.

Zone 1 (outermost zone): Short projection fibres originate in the brainstem and project to the cerebellum or adjacent geniculate bodies. Examples include the superior, middle, and inferior cerebellar peduncles, superior and inferior brachium, and the lateral lemniscus.

Zone 2 (middle zone): Moving inwards, zone 2 encompasses traversing fibres and long projection fibres. Traversing fibres of the brainstem include those fibres that just pass the brainstem on their way to and from the cortex, diencephalon and the cerebellum. These include the CST, the spinal lemniscus and the dorsal and ventral spinocerebellar tracts. Long projection fibres connect the brainstem to the cerebral cortex, diencephalon, and spinal cord. This section of fibres consists of both ascending and descending fibres and includes the medial lemniscus, the trigeminal lemniscus, the corticobulbar fibres, the corticopontine fibres, and the reticulospinal, the rubrospinal, and the vestibulospinal tracts.

Zone 3 (innermost zone): Occupying the innermost region around the midline are association fibres linking the brainstem nuclei with each other and the spinal cord. Examples of such fibres include the MLF, tectobulbar tract, and CTT. These three zones maintain their relative positions throughout the brainstem, except at points where fibres decussate or cross over the midline.

Decussations are found at various levels of the brainstem, such as the rubrospinal tract, tectobulbar tract, and superior cerebellar peduncle in the midbrain; the middle cerebellar peduncle and trapezoid body in the pons; and the pyramidal decussation and medial lemniscus decussation in the medulla.

This three-zone model creates a visual representation akin to concentric circles within the brainstem: Zone 1 forming the outer circle, followed by zone 2, and finally, zone 3 at the central core around the midline. This organisation helps in conceptualising the diverse and intricate pathways of the white matter of the brainstem **(Figs. 11 and 13)**.

Zone 1

The cerebellar peduncles, lateral lemniscus, and brachia are essential white matter pathways that connect different regions of the brainstem and facilitate various sensory and motor functions.

Superior Cerebellar Peduncle

Origin: This is derived from the cells of the dentate nucleus of the cerebellum.[1]

Function: It serves as the main efferent pathway of the cerebellum, carrying output signals from the cerebellum to various targets in the brain, including the red nucleus, thalamus, and the nucleus of the oculomotor nerve.

JAYPEE BROTHERS

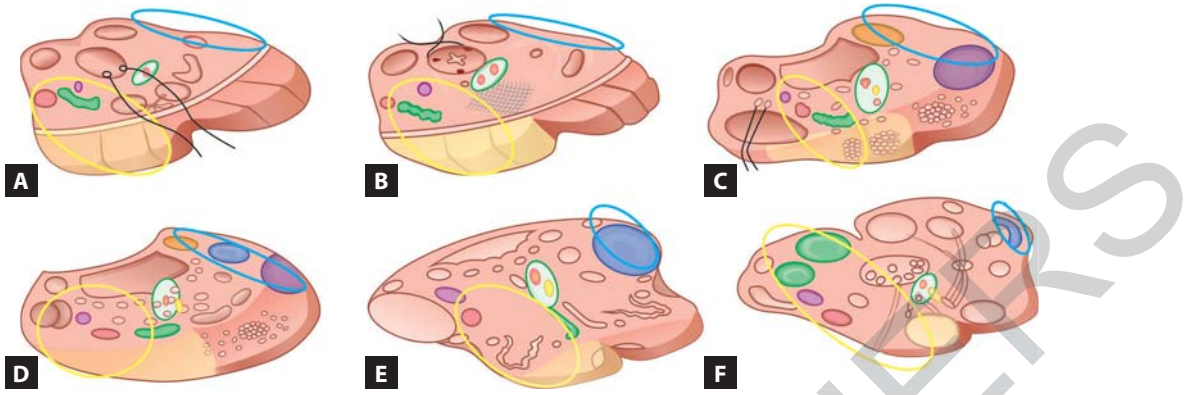

Figs. 13A to F: Schematic representation of cut section at various levels in the brainstem showing the various zones. Zone 1—blue (colour coding of tracts: Green colour—medial geniculate body and lateral lemniscus, olive green colour—superior cerebellar peduncle, pink colour—middle cerebellar peduncle, purple colour—inferior cerebellar peduncle), zone 2—yellow (colour coding of tracts: Light orange—corticospinal and corticobulbar tracts, light blue colour—medial lemniscus and gracile and cuneate fasciculi at the level of obex, dark pink colour—spinal lemniscus, brown colour—trigeminal lemniscus) zone 3—green (colour coding: Yellow—medial longitudinal fasciculus, red—tectospinal tract). (A) Cut section of the midbrain at the level of the superior colliculus. Zone 1 includes the superior cerebellar peduncle, the lateral lemniscus, and the superior brachium. Zone 2 includes from ventral to dorsal the corticospinal and corticonuclear tracts, the medial lemniscus, the spinal lemniscus, and the mesencephalic tract of the trigeminal. Zone 3 includes the medial longitudinal fasciculus, the central tegmental tract, and the tectobulbar tracts; (B) Cut section of the midbrain at the level of the inferior colliculus. Zone 1 includes the superior cerebellar peduncle, the lateral lemniscus, and the inferior brachium. Zone 2 includes from ventral to dorsal the corticospinal and corticonuclear tracts, the medial lemniscus, the spinal lemniscus, and the mesencephalic tract of the trigeminal. Zone 3 includes the medial longitudinal fasciculus, the central tegmental tract, and the tectobulbar tracts; (C) Cut section of the pons at the level of the trigeminal nuclei. Zone 1 includes the superior cerebellar peduncle and the middle cerebellar peduncle. Zone 2 includes from ventral to dorsal the corticopontine and the corticospinal fibres, the medial lemniscus, the spinal lemniscus, and the trigeminal lemniscus. Zone 3 includes the medial longitudinal fasciculus, the central tegmental tract, and the tectobulbar tracts; (D) Cut section of the pons at the level of the facial colliculus. Zone 1 includes the middle and the inferior cerebellar peduncle. Zone 2 includes from ventral to dorsal the corticopontine and the corticospinal fibres, the medial lemniscus, the spinal lemniscus, and the trigeminal lemniscus. Zone 3 includes the medial longitudinal fasciculus, the central tegmental tract, and the tectobulbar tracts; (E) Cut section of the medulla at the level of the olivary nuclei. Zone 1 includes the inferior cerebellar peduncle. Zone 2 includes from ventral to dorsal the corticopontine and the corticospinal fibres, the medial lemniscus, the spinal lemniscus, and the trigeminal lemniscus. Laterally, it includes the dorsal spinocerebellar tracts. Zone 3 includes the medial longitudinal fasciculus, the central tegmental tract, and the tectobulbar tracts; (F) Cut section of the medulla at the level of the obex. Zone 1 includes the inferior cerebellar peduncle. Zone 2 includes from ventral to dorsal the corticopontine and the corticospinal fibres, the spinal lemniscus, the trigeminal lemniscus, and the fasciculus gracilis and cuneatus. Laterally, it includes the dorsal and ventral spinocerebellar tracts. Zone 3 includes the medial longitudinal fasciculus, the central tegmental tract, and the tectobulbar tracts.

Decussation: The fibres undergo a complete decussation ventral to the cerebral aqueduct, meaning that fibres from one side of the cerebellum cross over to the opposite side of the brainstem.

Middle Cerebellar Peduncle

Origin: This is composed of fibres arising from the cells of the pontine nuclei of the opposite side (corticopontine fibres) **(Figs. 7A to H)**.

Function: It acts as the main afferent pathway of the cerebellum, conveying input signals from the cerebral cortex (specifically, the pontine nuclei) to the cerebellar cortex.

Arrangement: The fibres are organised into superficial and deep fasciculi. The superficial fasciculus arises from the superficial and middle transverse fibres of the pons and is distributed to specific lobules on the inferior surface of the cerebellar hemisphere and the folia close to the vermis. The deep fasciculus comprises most of the deep transverse fibres of the pons.

Inferior Cerebellar Peduncle

Origin: This consists of fibres from various sources, including the dorsal spinocerebellar fasciculus of the spinal cord, olivary nuclei, vestibular fibres, reticular formation, gracile and cuneate nuclei, and ventral spinocerebellar tract.

JAYPEE BROTHERS

Function: It carries sensory information from the spinal cord and other sources to the cerebellum, contributing to the role of the cerebellum in motor coordination and balance.

Pathway: The fibres ascend upward and lateral initially, forming part of the lateral walls of the fourth ventricle, then bend backwards to enter the cerebellum between the superior and middle peduncles **(Figs. 10A to D)**.

Lateral Lemniscus

Origin: It arises from the cochlear nuclei (acoustic striae), superior olivary nucleus, and the trapezoid body.[1]

Function: It carries auditory information, processing sound-related signals, thereby contributing to auditory reflexes.

Pathway: The fibres ascend upwards, reaching the ipsilateral or contralateral inferior colliculus. Some fibres extend further to the thalamus and the auditory areas of the cerebral hemispheres.

Superior Brachium

Origin: It contains corticotectal fibres originating from the visual cortex, adjacent parietal lobe, and frontal eye fields.

Function: These fibres are involved in visual processing and eye movement control, terminating in the superior colliculus, a structure associated with visual reflexes and eye movements.

Inferior Brachium

Origin: It comprises short projection fibres of the auditory pathway, originating in the inferior colliculus.

Function: It carries auditory signals, transmitting information related to sound processing from the inferior colliculus to the medial geniculate body, a part of the thalamus specialised for auditory functions.

These pathways and their interactions are crucial for various sensory and motor functions, highlighting the intricate connectivity within the brainstem and its role in processing and integrating different types of information.

Zone 2

Zone 2 in the organisation of white fibres in the brainstem includes various fibre tracts and pathways that traverse through the brainstem and connect it to other regions of the central nervous system.

Corticospinal Tract

Origin: CSTs consist mainly of fibres originating from neurons in the motor area of the cerebral cortex. These fibres project down to the anterior horn cells of the spinal cord.

Pathway: After passing through the corona radiata and internal capsule, the CST fibres enter the brainstem as a discrete bundle and traverse through the cerebral peduncles of the midbrain, ventral pons, and the pyramidal region of the medulla **(Figs. 6 and 7)**.

Decussation: Just rostral to the spinomedullary junction, most of the corticospinal fibres cross the median plane at the pyramidal decussation. This crossing allows them to continue as the lateral CST in the spinal cord **(Figs. 9A to F)**.[1]

Function: CSTs play a crucial role in controlling voluntary motor functions.

Medial Lemniscus

Origin: The medial lemniscus is formed by fibres from the gracile and cuneate nuclei. These fibres proceed towards the midline as internal arcuate fibres.

Decussation: These fibres cross the midline at the sensory decussation, turning upwards to form the medial lemniscus.

Pathway: In the medulla, the medial lemniscus ascends from the sensory decussation between the median raphe and the inferior olivary nucleus. It then moves laterally and increases in size as it ascends to the pons and the midbrain.[1] When viewed from the side as seen here, the medial lemniscus ascends through the pons forming a concave shape facing dorsally **(Figs. 7G and H)**. In the midbrain, it ascends in the dorsolateral part of the tegmentum in the angle between the red nucleus and the substantia nigra.

Destination: Fibres in the medial lemniscus continue their rostral course to end in the lateral and medial ventral posterior nuclei of the thalamus.

Function: This pathway is involved in transmitting tactile and proprioceptive sensory information.

Trigeminal Tract

Origin: The trigeminal nerve enters the brainstem in the middle of the pons, just superior to the middle cerebellar

JAYPEE BROTHERS

peduncle **(Figs. 7 and 8)**. It courses towards the fourth ventricle to reach the trigeminal motor and sensory nuclei. The trigeminal nerve can be seen entering the upper margin of the anterior aspect of the pons, where its fibres can be seen entering perpendicular to the transverse pontine fibres, which go into the cerebellum via the middle cerebellar peduncle.

Two tracts originate from the trigeminal nuclei in the pons: the ascending tract towards the midbrain (mesencephalic tract) and the descending tract towards the spinal cord (spinal tract).

Pathway: The trigeminal mesencephalic tract ascends deep to the floor of the fourth ventricle between the superior cerebellar peduncle laterally, sulcus limitans medially, CTT tract ventrally, and locus coeruleus dorsally **(Figs. 10A to D)**.

The spinal tract runs caudally and is related to various structures, including the inferior cerebellar peduncle, medial lemniscus, gracile and cuneate nuclei, and the dorsal horn of the spinal cord. The spinal tract runs caudally as far as the C3 level of the spinal cord and then merges with Lissauer's tract in the dorsal horn of the spinal cord.

Function: The trigeminal tract carries sensory and motor information related to the trigeminal nerve (cranial nerve V).

Dorsal and Ventral Spinocerebellar Tracts

Origins: The dorsal spinocerebellar tract arises from the nucleus dorsalis or Clarke's column in the thoracic and upper lumbar spinal cord, primarily consisting of uncrossed fibres. The ventral spinocerebellar tract originates in the lumbosacral enlargement of the spinal cord and comprises mainly crossed fibres.

Pathway: These spinocerebellar tracts ascend through the brainstem, with the dorsal tracts entering the cerebellum via the inferior cerebellar peduncle and the ventral tracts ascending to the pons and entering the cerebellum via the superior cerebellar peduncle.[1]

Function: The spinocerebellar tracts are involved in transmitting proprioceptive sensory information from the lower limbs to the cerebellum.

Spinal Lemniscus

Composition: The spinal lemniscus includes the spinothalamic tracts originating in the spinal cord. These tracts cross in the anterior commissure and ascend upwards.

Location: In the medulla, the spinal lemniscus lies dorsal to the inferior olivary nucleus and medial to the spinocerebellar tracts.[1] In the pons, it lies lateral to the medial and trigeminal lemniscus and medial to the middle cerebellar peduncle.

Pathway: In the midbrain, the spinal lemniscus is dorsolateral to the red nucleus and dorsal to the medial lemniscus.

Function: The spinal lemniscus is involved in transmitting sensory information, particularly pain and temperature, to the brain.

These structures and fibre tracts in zone 2 contribute to the transmission of sensory and motor information through the brainstem and further up the central nervous system.

Zone 3

Zone 3 of the brainstem contains important white matter structures that play roles in coordinating eye movements, as well as connecting various brainstem nuclei.

Medial Longitudinal Fasciculus

Location: The MLF is a compact fibre bundle situated in a paramedian location near the floor of the fourth ventricle, extending through the midbrain, pons, and upper medulla **(Figs. 7D and E, 8E, and 10D)**.

Function: The MLF interconnects several nuclei, including the oculomotor, trochlear, abducens, vestibular, spinal accessory, and reticular nuclei. It plays a crucial role in coordinating conjugate (horizontal) eye movements, as well as neck movements related to gaze control.

Pathway: At the level of the midbrain, it is found paramedian between the cerebral aqueduct dorsally and the decussation of the superior cerebellar peduncle ventrally.[1] The MLF passes ventrolateral to the oculomotor nuclei where it mixes with the intramesencephalic segment of the oculomotor nerve and ends in the interstitial nucleus of Cajal, in the lateral wall of the third ventricle. At the level of the lower half of the inferior colliculus, the MLF connects to the trochlear nucleus and travels near the floor of the fourth ventricle and adjacent to the midline of the pons **(Fig. 10D)**. It curves ventrally at the lower edge of the facial colliculus, approaches the medial lemniscus, and

JAYPEE BROTHERS

passes ventral to the hypoglossal triangle. The MLF retains its position relative to the central grey matter through the midbrain, pons, and upper medulla. In the lower medulla, it is displaced ventrally by successive decussation of the medial lemnisci and lateral CSTs, to continue in the anterior spinal fasciculus.

Central Tegmental Tract

Origin: CTT comprises efferent fibres originating from the red nucleus in the midbrain.

Pathway: At the level of the midbrain, CTT originates from the dorsomedial red nucleus and descends ipsilaterally, passing dorsally through the superior cerebellar peduncle decussation, and lateral to the MLF.[1] **(Figs. 10A to D)** CTT is located deep to the locus coeruleus and trigeminal mesencephalic tract and dorsal to the medial lemniscus.

Function: CTT is involved in conveying motor signals from the red nucleus to the inferior olivary nucleus, contributing to motor coordination and control.

Tectobulbar and Tectospinal Tracts

Origin: Both these tracts originate in the superior colliculus, a structure associated with visual and auditory reflexes.

Pathway: These tracts carry signals from the superior colliculus to the brainstem and spinal cord. The fibres destined for the spinal cord curve ventrally around the periaqueductal grey matter, cross to the opposite side as the dorsal tegmental decussation, and then continue downward in the midline as the tectospinal tract.[4] The tectobulbar tract also runs close to the MLF and terminates in the paramedian pontine reticular formation.

Function: The tectospinal tract is involved in coordinating reflexive head and eye movements in response to visual and auditory stimuli. The tectobulbar tract plays a role in coordinating head and neck movements.

These structures in zone 3 are essential for coordinating various motor functions and are interconnected, allowing for the integration of sensory input and the generation of appropriate motor responses, particularly related to eye and head movements.

Brainstem Safe Entry Zones

The arrangement of brainstem fibres into three zones—zone 1, zone 2, and zone 3—provides a useful framework for identifying safe entry points during surgical procedures.[1]

Zone 1, located at the outermost perimeter of the brainstem, primarily comprises white fibres. Entry into the brainstem through this zone is relatively safer and carries a lower risk of causing major neurological deficits compared to other areas.

Zone 2, lying deeper and medial to zone 1, includes significant grey matter nuclei of the brainstem alongside crucial ascending and descending white fibres. While entry into this zone offers narrower avenues, it provides access for targeted tumour removal due to its inclusion of essential neural pathways.

Zone 3, situated in the deepest region near the midline of the brainstem, consists of fibres that connect various brainstem nuclei to each other and some motor cranial nerve nuclei. This area presents a more intricate and delicate region for surgical intervention due to its critical neural connections.

Understanding these zones aids surgeons in identifying relatively safer pathways for entry into the brainstem during surgical procedures, helping to minimise the risk of causing significant neurological damage while accessing and treating brainstem tumours.

Approaching tumours in specific areas of the midbrain requires a precise understanding of the anatomy and entry points. Here are the key approaches for different zones of the midbrain:

Lateral midbrain: Tumours located on the lateral aspect of the midbrain can be approached through the lateral mesencephalic sulcus and the lemniscal triangle. The boundaries for this approach are the lateral mesencephalic sulcus anteriorly, the inferior brachium posterosuperiorly, and the superior cerebellar peduncle posteroinferiorly. The depth of this approach is confined by the dorsal medial lemniscus dorsally and the red nucleus ventrally.[1]

Ventral midbrain: The ventral part of the midbrain houses fibres from zone 2, including the corticospinal, corticobulbar, frontopontine, and temporopontine fibres. For tumours in this area, the commonly used safe entry zone is through the sulcus located lateral to the exit of the oculomotor nerve.[5] This approach traverses the frontopontine fibres in the medial portion of the cerebral peduncle. The boundaries are the CSTs laterally and the red nucleus in the depth.

Dorsal midbrain: Lesions in the dorsal midbrain and tectal plate can be approached through the supracollicular and infracollicular areas. The supracollicular avenue involves an incision just rostral to the superior colliculus, limited

JAYPEE BROTHERS

in depth by the aqueduct medially and the mesencephalic tract of the trigeminal and the CTT laterally.[1] The infracollicular approach is through the frenulum and above the trochlear nerve, restricted by the aqueduct in the depth. Lateral entry is limited by the superior cerebellar peduncle and the lateral lemniscus, and depth-wise by the mesencephalic tract of the trigeminal and the CTT.

Each approach targets specific areas within the midbrain, and understanding these zones and their boundaries is crucial for surgeons when planning and executing procedures for tumour removal in the midbrain.

Lateral cerebral peduncle approach to ventral midbrain tumours: The approach through the lateral cerebral peduncle offers a novel way to access ventral midbrain tumours.[5] This method targets the lateral one-fifth portion of the cerebral peduncle, mainly composed of the corticopontine fibres. These fibres, associated with parieto-occipito-temporal pontine tracts (Turk's fasciculus), originate from the cortex and traverse medially to reach the midbrain through the retrolenticular portion of the internal capsule. They enter the lateral one-fifth of the midbrain and are speculated to be involved in pursuit eye movements.

The entry point for this approach lies 5 mm anterior to the lateral mesencephalic sulcus and about 5 mm superior to the fourth nerve. This specific point enables access to ventral midbrain tumours within the cerebral peduncles. The approach trajectory is towards the interpeduncular cistern, taking into consideration the structures limiting its path: CSTs ventrally, substantia nigra dorsally, and the red nucleus and medial lemniscus at the depth.

The direction of the incision is crucial; a vertical incision aligns with the parieto-occipito-temporal pontine fibres, ensuring their splitting without damaging their course. A transverse incision might compromise the vertically traversing fibres.

During this approach, you might encounter the posterior cerebral artery superiorly, the superior cerebellar artery inferiorly, and the trochlear nerve as it courses from the dorsal aspect of the midbrain toward the cavernous sinus.

This method offers a direct trajectory to the lesion and aligns well with microscopic views when utilising the lateral supracerebellar, transtentorial, or subtemporal routes. Its safety and efficacy have been noted, particularly due to the natural displacement of structures by the tumour, facilitating dissection along a favourable plane.

PONS

Navigating through the pons for surgical access involves distinct approaches due to the complex neural structures present in different regions.

Ventrolateral pons: A purely ventral entry into the pons is challenging due to the CST. However, accessing tumours anterior to the medial lemniscus in the ventral pons can be done via the middle cerebellar peduncle (zone 1).[1] The safest entry point is the area below and in front of the trigeminal nerve and above the facial nerve. This approach exposes the superficial and middle layers of the transverse pontine fibres, the pontine nuclei, and the deep layer of transverse pontine fibres. The limits of exposure are the CST ventromedially and the medial and spinal lemnisci in the depth. Caution is required to avoid injury to the fibres of the fifth, sixth, and seventh cranial nerves while making incisions in their proximity.

Dorsal pons: Accessing the dorsal pons involves entry through the floor of the fourth ventricle. Above the facial colliculus, the entry is limited by the MLF medially, facial nerve fibres running above the colliculus inferiorly, the sulcus limitans laterally, and the frenulum veli superiorly (zone 2).[1] Below the facial colliculus, the safe entry points are in the intermediate part of the fourth ventricle, demarcated by the facial nerve fibres below the colliculus, the tela choroidae inferiorly, the MLF medially, and the facial and nucleus ambiguus laterally (also zone 2). These areas, relatively devoid of major structures, offer avenues to approach lesions in the pons.

Each entry point has its considerations and risks, necessitating a precise understanding of the anatomy to ensure safe and effective approaches for surgical interventions in the pons.

MEDULLA

The medulla, much like other brainstem areas, requires strategic approaches due to its intricate structures and fibre arrangements.

Ventral Medulla

The ventral part, mainly occupied by the CST, can be accessed via the preolivary and postolivary sulci. The preolivary sulcus lies between the pyramid medially and the olive laterally. Access is made below the rootlets of the

JAYPEE BROTHERS

hypoglossal nerve and above the C1 nerve rootlets. The postolivary sulcus, situated between the olive medially and the inferior cerebellar peduncle laterally, allows entry ventral to the rootlets of the glossopharyngeal and vagal nerves. The depth of this approach is limited by the spinal lemniscus and the nucleus ambiguus.

Dorsal Medulla

Entry into the dorsal medulla involves various sulci: the posterior median sulcus, the posterior intermediate sulcus, and the posterior lateral sulcus. Typically, the entry point is below the obex.

Each entry point into the medulla necessitates careful consideration of surrounding structures and landmarks to minimise risks and ensure a safe approach to lesions or tumours in this region.

REFERENCES

1. Akiyama O, Matsushima K, Nunez M, et al. Microsurgical anatomy and approaches around the lateral recess with special reference to entry into the pons. J Neurosurg. 2018;129(3):740-51.
2. Párraga RG, Possatti LL, Alves RV, et al. Microsurgical anatomy and internal architecture of the brainstem in 3D images: surgical considerations. J Neurosurg. 2016;124(5):1377-95.
3. Shah A, Jhawar SS, Goel A. The lateral cerebral peduncle approach to ventrally placed intra-axial midbrain tumors: A technical note. J Clin Neurosci. 2021;89:226-31.
4. Shah A, Jhawar SS, Nunez M, et al. Brainstem Anatomy: A Study on the Basis of the Pattern of Fiber Organization. World Neurosurg. 2020;134:e826-46.
5. Yagmurlu K, Rhoton AL Jr, Tanriover N, et al. Three-dimensionalmicrosurgical anatomy and the safe entry zones of the brainstem. Neurosurgery. 2014;10(Suppl 4): 602-19; discussion 619-20.

JAYPEE BROTHERS

for detailed information on neurology books, visit our website www.ejaypee.com, for detailed information on neurology books, visit our website www.ejaypee.com, for det

Ramamurthi and Tandon's Textbook of NEUROSURGERY

Since the publication of the 3rd edition of *Ramamurthi and Tandon's Textbook of Neurosurgery* in 2012, the field of neurosurgery has witnessed remarkable advancements and transformative breakthroughs. The rapid evolution of diagnostic and therapeutic techniques has redefined surgical precision, patient outcomes, and treatment options. This classic Indian textbook of neurosurgery continues to be an indispensable neurosurgical resource, upholding its legacy as the cornerstone of neurosurgical education and practice.

The 4th edition of *Ramamurthi and Tandon's Textbook of Neurosurgery* has been 2 years in the making and has been meticulously updated to reflect the dynamic landscape of neurosurgery, incorporating the latest innovations and practices. Nearly all the chapters have been rewritten, and a few have been updated. This edition brings together a network of experts who have curated and refined the content to ensure both scientific accuracy and practical relevance. Building on the legacy of previous editions, this volume is more comprehensive and insightful. It covers a vast spectrum of topics through 21 well-organised sections, bridging the gap between traditional wisdom and modern advances. Upholding the traditions of *Sushruta Samhita*, the first textbook of surgery, chapters on Microsurgical Anatomy and Connectomics are new additions. Completely new sections on minimally invasive endoscopic neurosurgery, epilepsy surgery, and functional neurosurgery make this a very comprehensive textbook. This edition integrates cutting-edge innovations including artificial intelligence and appropriate technology for neurosurgery, highlighting its impact on preoperative planning and decision-making.

This textbook will be an essential companion for neurosurgeons, residents, and students alike, globally. Enriched with detailed illustrations, case studies, and practical guidance, it will help in training young neurosurgeons and also the experienced practitioners to bridge up-to-date theory with current neurosurgical practice.

Shelving Recommendation
NEUROLOGY

ISBN 978-93-5696-981-0

Buy from ejaypee

JAYPEE BROTHERS