brothers.com, for detailed information on ophthalmology books, visit our website www.jaypeebrothers.com, for detailed information on ophthalmology books

Subjects Covered

- Optics—Basics
- General Anatomy and Physiology
- Ocular Anatomy and Physiology
- Pathology, Microbiology, Pharmacology and Ocular Pharmacology
- Critical Care—Basics



TEXTBOOK FOR DIPLOMA IN OPTOMETRY

I YEAR

As per the Syllabus & Curriculum of DO

Highlights

- Includes Optic Basis, General and Ocular Anatomy
- Special Emphasis on Critical Care

Ajay Kumar Bhootra
Sumitra Agarwal

JAYPEE

Contents

1. Optics—Basics **1**

- Light: Definition and Theory *1*
- Reflection and Refraction *5*
- Diffraction and Dispersion *7*
- Transmission and Absorption *10*
- Geometrical Optics *12*
- Spherical Lenses *14*
- Astigmatic and Toric Lenses *18*
- Prism *23*
- Vergence of Light *26*
- Magnification of Lenses *27*
- Homocentric Lenses System: Gauss Theorem *28*
- Optical Aberration of Images: Spherical Aberration and Chromatic Aberration *30*
- LASER: Fundamentals *33*
- Schematic and Reduced Eye: Angle Alpha *37*
- Visual Acuity *42*
- Mydriasis and Cycloplegics *54*
- Subjective Refraction *55*
- Simple and Toric Transposition *59*
- Spherical Equivalent *63*
- Accommodation and Convergence *66*

2. General Anatomy and Physiology **74**

- General Orientation about Parts of Human Body *74*
- Animal Cells, Cell Organelles and their Functions *85*
- Human Tissues, Types, Structure and Functions *88*
- Osteology *93*
- Joints *96*
- Skin and Appendages *99*
- Gastrointestinal Tract *105*
- Respiratory Tract *111*
- Urinary Tract *117*
- Male Reproductive System *118*
- Female Reproductive System *120*
- The Endocrine System *121*
- Brain and Spinal Cord *124*
- Blood Composition and Functions *127*
- Gross Structure of Functions of Sensory Organs *129*
- Basic Gross Structure of Heart, Vessels *132*
- Immune System *137*

3. Ocular Anatomy and Physiology **140**

- Orbit and Contents of Orbit *140*
- Eyeball: Comprehensive Anatomy *145*
- Segments of the Eyeball *146*
- Structural Components of Eyeballs *146*

- Extraocular Muscles: Gross Structure, Origin, Insertion, Nerve Supply and Action *148*
- Blood Supply to Eye and Nerve Supply to Eye *150*
- Gross, Microscopic Anatomy, Blood and Nerve Supply of Conjunctiva *152*
- Gross, Microscopic Anatomy, Blood and Nerve Supply of Cornea *155*
- Gross, Microscopic Anatomy, Blood and Nerve Supply of Sclera *158*
- Gross, Microscopic Anatomy, Blood and Nerve Supply of Uvea *160*
- Gross, Microscopic Anatomy, Blood and Nerve Supply of Lens *164*
- Gross, Microscopic Anatomy, Blood and Nerve Supply of Angle of Anterior Chamber *166*
- Physiology of Aqueous Production and Drainage *168*
- Gross, Microscopic Anatomy, Blood and Nerve Supply of Vitreous *170*
- Gross, Microscopic Anatomy, Physiology, Blood and Nerve Supply of Retina *172*
- Gross, Microscopic Anatomy, Physiology, Blood and Nerve Supply of Optic Nerve *178*
- Gross, Microscopic Anatomy, Physiology, Blood and Nerve Supply of Visual Pathway *180*
- Gross, Microscopic Anatomy, Physiology, Blood and Nerve Supply of Pupillary Pathway *184*

4. Pathology, Microbiology, Pharmacology and Ocular Pharmacology 189
- Basic Steps of Acute and Chronic Inflammation *189*
- Basics of Necrosis and Apoptosis *193*
- Basics of Shock *195*
- Basics of Disorder of Blood Coagulation System *198*
- Modes of Disease Transmission and Prevention of Infection *200*
- Basics of Disorder of Immune System of Body *203*
- Adverse Effects and Side effects of Drugs *208*
- Routes of Drug Administration *210*
- Basic Idea about Types of Bacteria, Virus and Fungi *212*
- Sterilization and Method of Sterilization used in Hospitals *217*
- Basic Idea of Analgesics: Opioid and NSAIDs *219*
- Basic Idea of Antimicrobials *221*
- Basic Idea of Anti-H_1 Histamines and Corticosteroids *226*
- Antiglaucoma Drugs *230*
- Dyes used in Ophthalmology *231*
- Artificial Tears and Other Drugs used in Dry Eyes *233*
- Topical Antimicrobials and NSAIDs and Steroid used in Eye *234*
- Mydriasis and Cycloplegics *236*
- Various Methods of Administrating Drugs to the Eyes *237*

5. Critical Care—Basics 240
- Hand Hygiene and Prevention of Cross Infection *240*
- Basic Life Support and Cardiopulmonary Resuscitation *245*

Index *251*

3
CHAPTER

Ocular Anatomy and Physiology

Ajay Kumar Bhootra, Sumitra Agarwal

ORBIT AND CONTENTS OF ORBIT

The bony orbital cavity **(Fig. 3.1)** is the site that houses the eyeball, along with its associated muscles, nerves, blood vessels, lacrimal glands and fat as packing. At the entrance it is 35 mm in height and 40 mm in width and is 40 mm deep antereoposteriorly. In all seven bones make up the orbit as shown in **Flowchart 3.1**.

These bones also form the part of the face as well as the cranium.

Boundaries of the Orbit

The boundaries of the orbit are a roof, a floor, a lateral wall and a medial wall.

Roof of the Orbit

The roof of the orbit is formed by the orbital plate of the frontal bone in front and by the lesser wing of sphenoid bone at the back. Anterolaterally lies the lacrimal fossa, which houses the lacrimal gland. Anteromedially, half a centimeter from the margin is the trochlear fossa, to

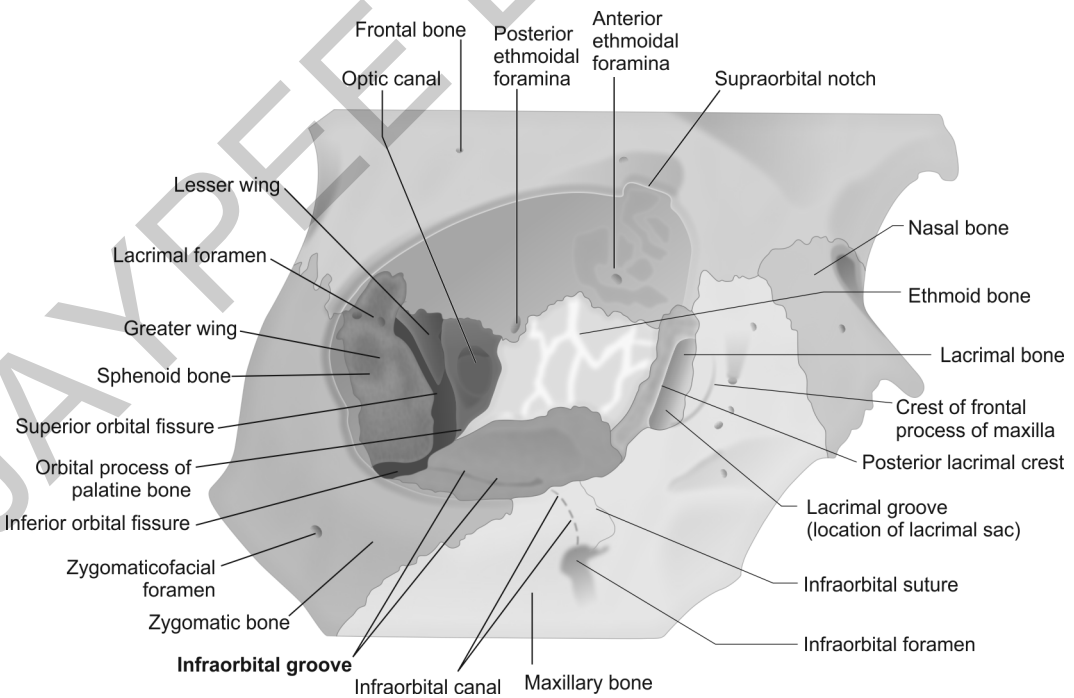

Fig. 3.1: Orbital cavity.

JAYPEE BROTHERS

Flowchart 3.1: Orbital bones.

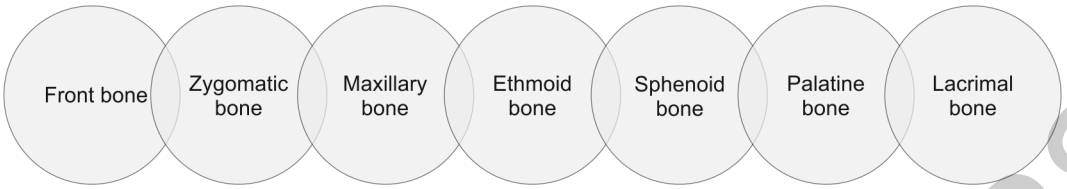

which the trochlea or pulley of the superior oblique muscle is attached. The roof is thin and can be pierced by a sharp object. In some old age people the roof may even be absent.

Floor of the Orbit

The floor of the orbit is made up of three bones. The orbital plate of maxilla makes up the major part. The zygomatic bone contributes anterolaterally, while posteriorly a tiny part of floor is made up of palatine bone. The inferior oblique muscle arises from the floor of the orbit slightly lateral to the opening of the nasolacrimal canal.

Medial Wall

The medial wall of the orbit comprises of four bones. The ethmoid is the thinnest bone in the orbit that forms the greater part. The body of sphenoid forms the most posterior part and the lacrimal bone and the frontal process of the maxilla also contribute anteriorly. Lacrimal fossa is situated anteriorly. This is bounded by the anterior and posterior lacrimal crests.

Lateral Wall

The lateral wall is the thickest and separates the orbit from the middle cranial fossa posteriorly, and from the muscular temporal fossa anteriorly. Two bones form the lateral wall. The zygomatic bone forms the anterior one-third and the greater wing of the sphenoid forms the posterior two-third. Between the lateral wall and the posterior part of the roof lies the superior orbital fissure.

Contents of Orbit

Eyeball, muscles, lacrimal glands, fats and connective tissue, orbital fascia, nerves, and vessels are important contents of the orbit **(Fig. 3.2)**.

Eyeball

The adult size human eyeball or globe is a hollow spheroid of about 25 mm in diameter. The eyeball occupies only about one-fifth of the volume of the orbit and is situated anteriorly in the orbit just within the protective orbital margin.

Muscles

Six extraocular muscles that include four rectus muscles—superior, inferior, medial and lateral rectus and two obliques superior and inferior obliques lie within the orbit. These muscles are responsible for the eye movement. Levator palpebrae superioris is another important muscle that also lies inside the orbit. This muscle is responsible for elevating the upper eyelid.

Lacrimal Gland

Lacrimal gland consists of two portions—orbital and palpebral. The orbital portion is lodged in the superior-lateral corner of the roof of the orbit. It produces tears. The anterior border of the

JAYPEE BROTHERS

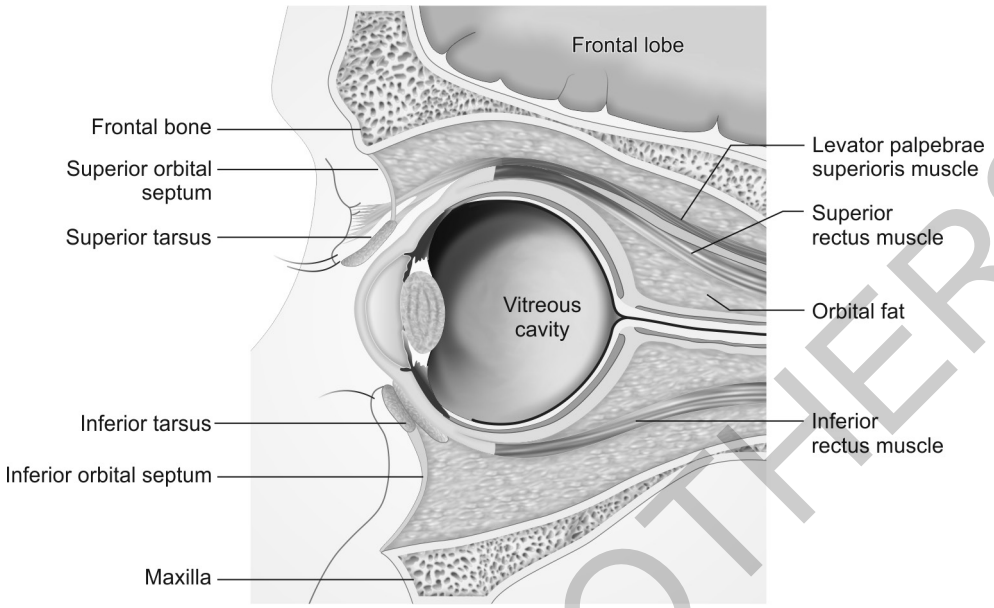

Fig. 3.2: Orbit cross-section view.

gland is sharp and is in contact with the septum orbitale. The gland is supplied by the lacrimal artery and sometimes a branch of the infraorbital also joins it. The nerves to the gland are mainly the lacrimal and sympathetic but sometimes a twig from the great superficial petrosal nerve also supplies it.

Fat and Connective Tissue

The orbit, or eye socket, is surrounded by fats and connective tissue that serve essential functions in protecting and supporting the eyeball and other structure. Adipose tissue surrounds the eyeball and acts as cushion, protecting the eyeball from impacts and injuries. The connective tissue in the orbit provides structural support and helps to hold the various components of the eye and surrounding structures in place. It forms the framework for the orbit, securing the extraocular muscles, nerves, blood vessels, and other tissues within the confined space of the eye socket.

Orbital Fascia

Orbital fascia, also known as the periorbita or periorbital fascia, is a specialized layer of connective tissue that surrounds and forms the outermost covering of the orbit (eye socket). It is a dense and fibrous tissue that provides structural support and helps to hold the various structures within the orbit in place. Orbital fascia is a crucial component of the orbit that contributes to the stability, protection, and proper functioning of the eye and its associated structures within the eye socket.

Nerves

The orbit contains several important nerves that play crucial roles in transmitting sensory and motor information to and from the eye and its surrounding structures. The bony orbit contains optic nerve, sensory nerve, motor nerve, sympathetic nerve.

The optic nerve is actually referred to as cranial nerve II, the optic nerve is responsible for transmitting visual information from the retina of the eye to the brain's visual centers. It

JAYPEE BROTHERS

carries the nerve impulses generated by light-sensitive cells in the retina, allowing us to perceive images and process visual information.

The sensory nerves of the orbit are branches of the ophthalmic division of the trigeminal nerve, which is Cranial nerve V. These sensory nerves provide innervation to various structures within and around the orbit, allowing us to perceive sensations from the eye and its surroundings. The main sensory nerves are—lacrimal nerve, frontal nerve, nasociliary. These sensory nerves play a crucial role in providing feedback about the environment surrounding the eye and help in maintaining the eye's health and function. They allow us to perceive sensations such as touch, pain, and temperature in and around the orbit, contributing to our overall sensory experience and eye protection.

Motor nerves of the orbit are responsible for controlling the movements of the eye by innervating the extraocular muscles. These muscles work together to enable various eye movements, allowing us to focus on objects and navigate our visual field. The main motor nerve involved in eye movements is the oculomotor nerve (cranial nerve III). It is one of the cranial nerves responsible for eye movements. It innervates four of the six extraocular muscles.

- **Superior rectus:** This muscle moves the eye upward.
- **Inferior rectus:** This muscle moves the eye downward.
- **Medial rectus:** This muscle moves the eye inward, toward the nose.
- **Inferior oblique:** This muscle moves the eye upward and away from the midline.

Trochlear nerve (cranial nerve IV) innervates the superior oblique muscle, which plays a role in rotating the eye downward and away from the midline. Abducens nerve (cranial nerve VI) controls the lateral rectus muscle, which moves the eye outward, away from the nose.

Sympathetic and parasympathetic nerves are the part of autonomous nervous system. They synapse at the ciliary ganglion which is situated behind the globe within the orbit. From there they enter into the eye. Sympathetic innervation provides pupillodilator innervations to the iris, vasoconstriction fibers to the blood vessels of the eye and also innervate melanocytes of the uveal tract. Parasympathetic nerves supply the sphincter papillae that contract the pupil and ciliary muscles. It also supplies the smooth muscle component of levator palpebrae superioris.

Vessels

The orbit contains a network of blood vessels that supply oxygen and nutrients to the various structures within the eye and its surrounding tissues. These blood vessels are:

- **Ophthalmic artery:** The ophthalmic artery is a branch of the internal carotid artery and is the primary arterial supply to the orbit. It provides blood to the eyeball, extraocular muscles, optic nerve, and surrounding tissues.
- **Central retinal artery:** The central retinal artery is a branch of the ophthalmic artery. It enters the optic nerve and supplies blood to the retina, which is essential for visual function.
- **Lacrimal artery:** The lacrimal artery is a branch of the ophthalmic artery that supplies blood to the lacrimal gland, which produces tears.
- **Ciliary arteries:** The ciliary arteries are branches of the ophthalmic artery that supply blood to the ciliary body, iris, and other parts of the anterior segment of the eye.
- **Supraorbital artery:** This artery supplies blood to the forehead and the upper eyelid.
- **Infraorbital artery:** This artery supplies blood to the lower eyelid and the skin of the cheek.
- **Ethmoidal arteries:** These arteries supply blood to the ethmoid sinuses and other structures in the nasal cavity.

The venous drainage of the orbit is accomplished through a system of veins that correspond to the arteries' distribution. The veins drain into the superior ophthalmic vein, which then connects to the cavernous sinus and other venous systems in the head.

JAYPEE BROTHERS

Openings into the Orbit

Orbit has several openings through which various structures enter or exit the orbit. These openings allow for the passage of nerves, blood vessels, and other vital structures that support the eye's function. The main openings of the orbit are:

- **Optic canal (optic foramen):** This is a small opening located at the back of the orbit, near the apex. The optic canal allows the passage of the optic nerve (cranial nerve II) and the ophthalmic artery, which supplies blood to the eye.
- **Superior orbital fissure:** This elongated opening is situated between the lesser and greater wings of the sphenoid bone. It permits the passage of several structures, including the oculomotor nerve (cranial nerve III), trochlear nerve (cranial nerve IV), ophthalmic division of the trigeminal nerve (cranial nerve V1), abducens nerve (cranial nerve VI), and various veins.
- **Inferior orbital fissure:** This opening is located between the lateral wall of the orbit and the greater wing of the sphenoid bone. It allows the passage of the maxillary division of the trigeminal nerve (cranial nerve V2) and various veins.
- **Superior and inferior orbital sulci:** These are grooves on the orbital walls where the lacrimal gland and its duct, along with some blood vessels, are located.

Annulus of Zinn

The annulus of Zinn is a tendinous ring that spans the optic foramen and the middle part of the superior orbital fissure. The superior rectus, medial rectus, the lateral rectus and the inferior rectus take their origins from the annulus. The following structures enter the orbit through the annulus:

- Optic nerve
- Ophthalmic artery
- Nasociliary nerve
- Superior and inferior division of IIIrd nerve
- VI nerve
- Sympathetic root of the ciliary ganglion

Optic Canal

The optic canal, also known as the optic foramen, is a bony passageway located at the back of the orbit (eye socket). It is a crucial anatomical feature through which the optic nerve (cranial nerve II) and the ophthalmic artery travel to reach the eye and its associated structures.

Periorbita

Periorbita is a thin layer of connective tissue that covers the surface of the orbital bones. The tissue is loosely attached to the bones. However, this attachment is strong at the orbital margins, at orbital fissures, at optic canal in the lacrimal fossa and at the suture lines.

Ciliary Ganglion

It is a small ganglion of about 2 mm situated at the posterior part of the orbit between the optic nerve and lateral rectus muscle. It plays a crucial role in regulating the function of certain eye structures, particularly those involved in controlling the pupil size and the shape of the lens for near vision.

JAYPEE BROTHERS

EYEBALL: COMPREHENSIVE ANATOMY

The eyeball is a complex organ responsible for vision **(Fig. 3.3)**. It is an oblate spheroid due to flattening from above downwards. Its anteroposterior diameter is approximately 24 mm in adults, which measures about 17.5 mm at birth and 20 to 21 mm at puberty. The horizontal and vertical diameter diameters are approximately 23.5 mm and 23 mm respectively. In females all diameter are relatively smaller than those in males. The approximate weight of the adult eyeball is 7 g.

Coats of Eyeball

The eyeball, or globe, is composed of three main coats or layers, each with its distinct functions and structures. These coats provide protection, support, and contribute to the proper functioning of the eye. The three coats of the eyeball are:

Outer Coat

Outer coat is the dense strong wall which is fibrous and protects the intraocular contents. Anterior 1/6th of this coat is cornea and posterior 5/6th is the sclera. Cornea is set in the sclera like a watch glass.

Middle Coat

The middle coat is the vascular coat that supplies nutrition to various structures of the eyeball. It consists of three parts which are iris, ciliary body and choroid.

Inner Coat

The inner coat is the nervous coat which is retina and optic nerve. The retina is the innermost layer of the eyeball, composed of light-sensitive cells called photoreceptors. These cells convert incoming light into electrical signals, which are then transmitted through the optic nerve to the brain's visual processing centers. The optic nerve is a bundle of nerve fibers that connects the retina to the brain. It carries the visual signals from the retina to the brain, allowing us to perceive and interpret visual information.

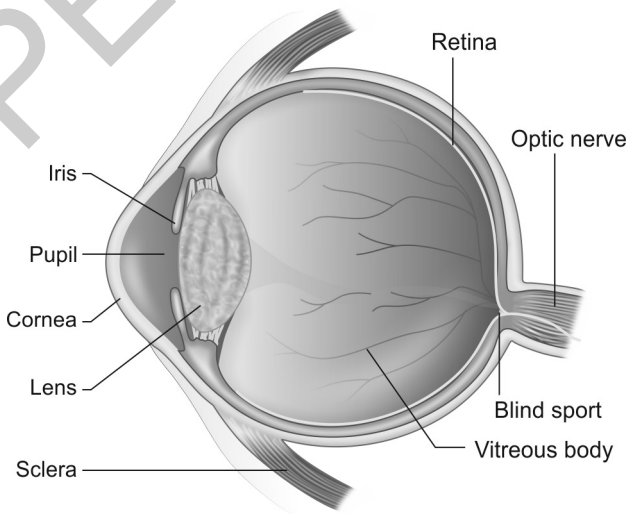

Fig. 3.3: Cross-section view of eye.

JAYPEE BROTHERS

SEGMENTS OF THE EYEBALL

The eyeball can be divided into two main segments:
1. The anterior segment
2. The posterior segment

The anterior eye is the front portion of the eyeball that includes the structures located in front of the lens. The posterior eye is the back portion of the eyeball and includes the structures located behind the lens. **Table 3.1** shows the different organs of the two segments.

Table 3.1: Two segments of eye.

Anterior segment of eye	***Posterior segment of eye***
Cornea	Vitreous humor
Conjunctiva	Retina
Iris	Macula
Pupil	Optic nerve
Lens	Choroid
Ciliary body	Sclera
Aqueous humor	
Anterior chamber	
Posterior chamber	
Trabecular meshwork	

Anterior chamber is bounded anteriorly by the back of the cornea and posteriorly by the iris and part of ciliary body. The anterior chamber is about 3 mm deep in the center in normal adults. It is shallower in hyperopes and deeper in myopes but is almost equal in both eyes of an individual. It contains about 0.25 mL of the aqueous humor.

Posterior chamber is a triangular space bounded anteriorly by the posterior surface of the iris and part of ciliary body, posteriorly by crystalline lens and its zonules and laterally by the ciliary body.

The central points on the maximal convexities of the anterior and posterior curvatures of the eyeball are called anterior and posterior poles. The axis of the eyeball passes through the poles. The equator lies at the midpoint between the poles. The line joining the poles is the meridian.

STRUCTURAL COMPONENTS OF EYEBALLS

The various components of the eye can be grouped into three main categories based on their functions as shown in **Table 3.2**.

Each group of organs plays a vital role in maintaining the health and proper functioning of the eye. The refractive organs focus light onto the retina, the supportive organs provide structural integrity and nourishment, and the protective organs shield the eye from external elements and help maintain a healthy environment for optimal vision.

The eyeball is a complex organ responsible for vision and consists of various structures working together to capture, focus, and transmit visual information to the brain. A brief description of these structures is as follows:

Sclera

The outermost layer of the eyeball, the sclera, is a tough, white, and fibrous tissue that provides structural support and protection to the inner delicate structures.

Table 3.2: Components of eye categorized in three different groups.

Refractive components	***Supportive components***	***Protective components***
Cornea	Sclera	Eyelids
Crystalline lens	Choroid	Eye lashes
Aqueous	Ciliary body	Conjunctiva
Vitreous	Ciliary processes	Lacrimal gland
	Zonules	Lacrimal apparatus
	Vitreous	

JAYPEE BROTHERS

Cornea

The transparent, dome-shaped cornea is the front part of the eye, covering the iris and pupil. It is responsible for refracting light and accounts for most of the eye's focusing power.

Iris

The colored part of the eye, the iris, surrounds the pupil and controls the amount of light entering the eye by adjusting its size. The iris contains muscles that contract or dilate the pupil based on the amount of light available.

Pupil

The black circular opening at the center of the iris, the pupil, allows light to enter the eye and reach the retina.

Lens

Lens is located behind the iris. The crystalline lens helps further focus light onto the retina. The lens changes its shape through a process called accommodation to adjust focus for near and distant objects.

Retina

The retina is a delicate, light-sensitive layer that lines the back of the eye. It contains specialized photoreceptor cells, namely rods and cones, which convert light into electrical signals.

Optic Nerve

The optic nerve (cranial nerve II) is a bundle of nerve fibers that carry visual information from the retina to the brain's visual centers.

Choroid

The choroid is a vascular layer between the retina and sclera that supplies blood and nutrients to the retina.

Ciliary Body

The ciliary body is a ring-shaped structure that contains ciliary muscles, which change the shape of the lens during accommodation. It also produces aqueous humor, a fluid that maintains the eye's intraocular pressure.

Aqueous Humor

The aqueous humor is a clear fluid that fills the anterior chamber and provides nutrients to the cornea and lens.

Vitreous Humor

The vitreous humor is a gel-like substance that fills the large space in the back of the eye. It helps maintain the eye's shape and plays a role in light transmission.

Fovea

The fovea is a small depression in the central part of the retina and contains a high concentration of cones, providing the sharpest vision and color perception.

JAYPEE BROTHERS

EXTRAOCULAR MUSCLES: GROSS STRUCTURE, ORIGIN, INSERTION, NERVE SUPPLY AND ACTION

There are six extraocular muscles that suspend the eyeball in the orbit **(Figs. 3.4A to E)**. The four recti are straight which arise from annulus of Zinn and from the adjacent periorbita and tend to pull the eyeball into the orbit. The two obliques have bony origins and tend to pull the globe forward. Eye movements are the results of action of these extraocular muscles. The six extraocular muscles that are designed to stabilize and move the eyes are shown in **Flowchart 3.2**.

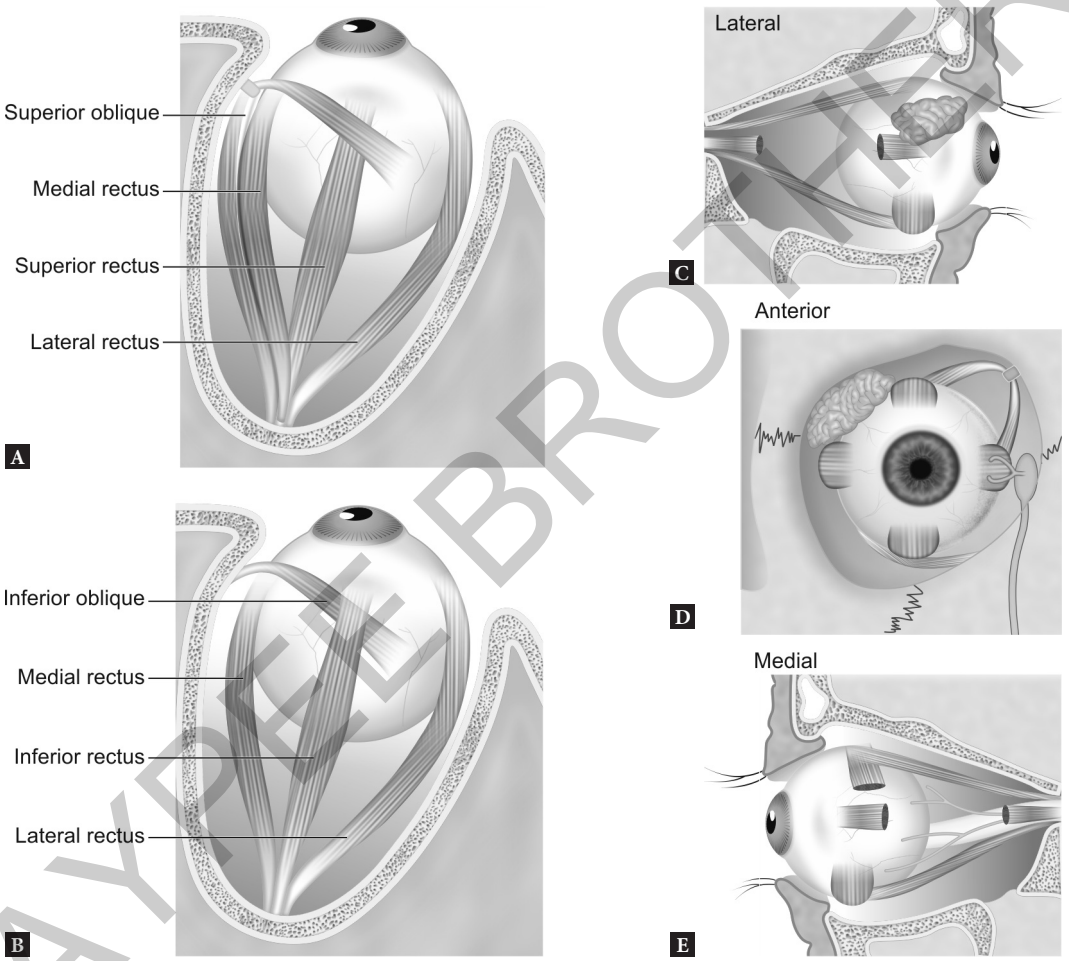

Figs. 3.4A to E: (A) Ocular muscles of right eye viewed from above; (B) Ocular muscles of right eye viewed from below; (C to E) Ocular muscles of right eye viewed laterally, anteriorly and medially.

Flowchart 3.2: Six extraocular muscles.

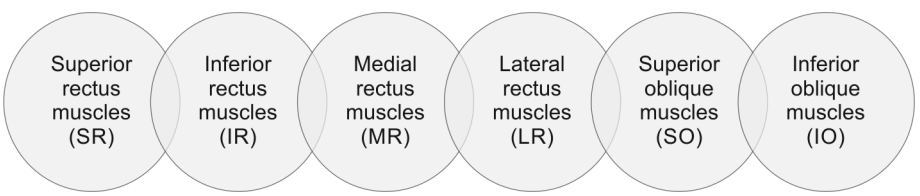

JAYPEE BROTHERS

These muscles are attached to the globe by broad, flat, thin insertions and at the back of the eye in the annulus of Zinn. The only muscle which is not attached in the annulus area is the inferior oblique which is attached nasally at the anterior floor of the orbit.

Extraocular muscles are striated skeletal muscles and like all other skeletal muscles, extraocular muscles are also made of fibers. They are among the fastest muscles in the body. The speed and precision of extraocular muscles are unsurpassed anywhere in the body. Extraocular muscles are highly fatigue resistant, yet the mechanism involved in the fusion process is so highly complex that it may result in muscle fatigue, resulting into disruption of the fusion mechanism.

Extraocular muscles work in pairs to control the eye's movement in various directions and coordinate binocular vision, allowing us to see objects in three dimensions. The balanced functioning of these muscles is critical for precise eye movements and optimal visual perception. During movements, certain muscles increase their activity while others decrease it. The specific action of the six extraocular muscles for eye movement depends on the position of the eye at the time of muscles' contraction. Horizontal eye movements are rather simple. Increased activity of the lateral rectus will direct the pupil laterally, while increased activity of the medial rectus will direct it medially. However, movements of the eyes above or below the horizontal plane are little complicated. Dysfunction of these muscles can lead to eye movement disorder and problem with ocular alignment. **Table 3.3** shows the actions and other anatomical relevance of extraocular muscles.

Table 3.3: Extraocular muscles: Origin, insertions, innervation, action, length and blood supply.

Extraocular muscles	***Origin***	***Insertion***	***Innervation***	***Action***	***Blood supply***	***Length***
Superior rectus muscles	Upper part of annulus of Zinn	Superior aspect of eyeball	CN III (oculomotor nerve)	Elevation, adduction and incycloduction	Lateral muscular ophthalmic artery	42 mm long
Inferior rectus muscles	Inferior part of annulus of Zinn	Inferior aspect of eyeball	CN III (oculomotor nerve)	Depression, adduction, and excycloduction	Medial muscular ophthalmic artery	40 mm long
Medial rectus	Annulus of Zinn	Medial aspect of eyeball	CN III (oculomotor nerve)	Adduction	Medial muscular ophthalmic artery	40.8 mm long
Lateral rectus	Lateral portion of annulus of Zinn	Lateral aspect of eyeball	CN VI (abducens)	Abduction	Lateral muscular ophthalmic artery	40.5 mm long
Superior oblique	Sphenoid bone (superior to annulus of Zinn)	Superior posterior aspect of eyeball	CN IV (trochlear)	Incycloduction, abduction, and depression	Ophthalmic artery (trochlear artery)	Longest of all muscles
Inferior oblique	Maxillary bone (anterior to annulus of Zinn)	Inferior posterior aspect of eyeball	CN III (oculomotor nerve)	Excycloduction, elevation and abduction	Ophthalmic artery (anterior ethmoidal artery)	37 mm long

JAYPEE BROTHERS

BLOOD SUPPLY TO EYE AND NERVE SUPPLY TO EYE

Blood Supply to Eye

The blood supply to the eye is provided by a network of arteries and veins that deliver oxygen and nutrients to its various structures **(Fig. 3.5)**. The main blood vessels supplying the eye are as follows:

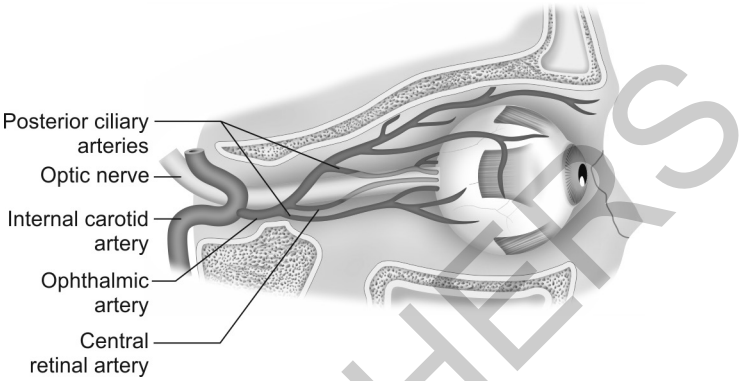

Fig. 3.5: Blood supply to eye.

Ophthalmic Artery

The ophthalmic artery is the main supplier of blood to the eye. It arises from the internal carotid artery, which is a major blood vessel in the neck. The ophthalmic artery enters the orbit through the optic canal and branches into multiple smaller arteries that supply different parts of the eye, including the retina, ciliary body, and iris.

Central Retinal Artery

This is a branch of the ophthalmic artery that enters the optic nerve and supplies blood to the retina, which is essential for vision. The central retinal artery enters the eye through the optic nerve and appears at the optic disc. After that it is divided into four branches to supply to the four quadrants of the retina.

Posterior Ciliary Arteries

These arteries supply blood to the choroid, ciliary body, and parts of the optic nerve.

Anterior Ciliary Arteries

These arteries supply blood to the anterior part of the eyeball, including the conjunctiva and the extraocular muscles.

Venous drainage of the eye is achieved through a system of veins that correspond to the arterial distribution. The major veins draining the eye include the central retinal vein, which carries deoxygenated blood from the retina, and the vortex veins, which drain the choroid.

Nerve Supply to Eye

The eye receives its nerve supply from various cranial nerves that control its movements, provide sensory information, and regulate its functions. These cranial nerves originate in the brain and traverse through the skull to reach the eyeball and its associated structures. They play a vital role in transmitting visual information, controlling eye movements, and maintaining proper eye alignment. The main cranial nerves involved in the nerve supply to the eye are shown in **Flowchart 3.3**.

Flowchart 3.3: Nerve supply to eye.

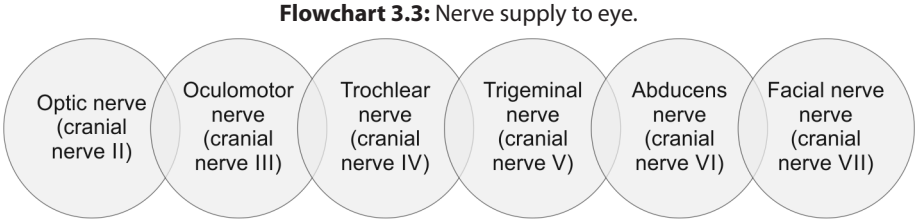

JAYPEE BROTHERS

Optic Nerve (Cranial Nerve II)

The optic nerve is responsible for carrying visual information from the retina to the brain's visual centers. It carries the signals generated by light-sensitive cells in the retina and delivers them to the visual centers in the brain, allowing us to perceive vision. The optic nerve is not involved in motor control but is crucial for vision.

Oculomotor Nerve (Cranial Nerve III)

The oculomotor nerve innervates four of the six extraocular muscles (superior rectus, inferior rectus, medial rectus, and inferior oblique), which control eye movements. The oculomotor nerve also innervates the levator palpebrae superioris muscle, which raises the upper eyelid.

Trochlear Nerve (Cranial Nerve IV)

The trochlear nerve innervates the superior oblique muscle, which is involved in rotating the eye downward and away from the midline.

Trigeminal Nerve (Cranial Nerve V)

The ophthalmic division of the trigeminal nerve provides sensory innervation to the cornea, conjunctiva, and skin of the eyelids.

Abducens Nerve (Cranial Nerve VI)

The abducens nerve controls the lateral rectus muscle, which is responsible for moving the eye outward, away from the nose, thus helping in abduction.

Facial Nerve (Cranial Nerve VII)

The facial nerve innervates the muscles of facial expression, including the orbicularis oculi muscle, responsible for blinking and closing the eyelids.

Check Your Progress—1

State whether the following statement are true or false:

1. Adipose tissue surrounds the eyeball and acts as cushion, protecting the eyeball from impacts and injuries.
2. The connective tissue in the orbit provides structural support and helps to hold the various components of the eye and surrounding structures in place.
3. Optic foramen is a small opening located at the back of the orbit, near the apex.
4. Posterior chamber of the eye is located in the anterior segment of the eye.
5. The fovea is a small depression in the central part of the retina and contains a high concentration of cones, providing the peripheral vision and color perception.
6. The optic nerve is also known as cranial nerve IV.

⁂ True ⁂ True ⁂ True ⁂ True ⁂ False ⁂ True

Learner's Activity—1

Q1. Write a brief note on the contents of orbit.

SUGGESTED READING

1. Jogi R. Basic Ophthalmology, 5th edition. Jaypee Brothers Medical Publishers (P) Ltd; 2023.
2. Khurana AK, Khurana I. Modern System of Ophthalmology Anatomy and Physiology of Eye, 3rd edition. CBS Publishers; 2020.

JAYPEE BROTHERS

for detailed information on ophthalmology books, visit our website www.jaypeebrothers.com, for detailed information on ophthalmology books, visit our webs

TEXTBOOK FOR
DIPLOMA IN OPTOMETRY
I YEAR

Salient Features

- A rich treasury of information on various facets of optometry.
- Simple and concise, yet comprehensive resources.
- Easy to understand and comprehend.
- Includes fundamentals of light, general and ocular anatomy, pathology, pharmacology, and microbiology.
- A great resource for beginners.

Ajay Kumar Bhootra B Optom DOS FAO FOAI FCLI ICLEP FIACLE (Australia) Diploma in Sportvision (UK), an Optometrist, Ocularist and Novelist, has been working with Himalaya Optical for more than 35 years. He has written several books in different categories. Two of his books have also been published in international languages. Besides, he has been the key person in developing training materials for the employees of his company Himalaya Optical. Currently, he is working on a nonfiction title as well as the third edition of two of his books on optometry. You can know more about Ajay at: www.ajaykrbhootra.com.

Sumitra Agarwal BHMS DMBS MD (Bio) M Optom B Optom DOS Diploma in Sportvision (UK), an Optometrist, Ocularist and a Homeopathic Practitioner, is the founder of Artificial Eye Company and Ted Speaker. She has been practicing as a low vision and rehabilitation specialist for more than 20 years and is very active on YouTube.

Printed in India

Available at all medical bookstores
or buy online at www.jaypeebrothers.com



JAYPEE BROTHERS
Medical Publishers (P) Ltd.
EMCA House, 23/23-B, Ansari Road,
Daryaganj, New Delhi - 110 002, INDIA
www.jaypeebrothers.com

Join us on facebook.com/JaypeeMedicalPublishers

Shelving Recommendation
OPHTHALMOLOGY

ISBN 978-93-5696-993-3