y books, visit our website www.ejaypee.com, for detailed information on ophthalmology books, visit our website www.ejaypee.com, for detailed information on ophthalmology books

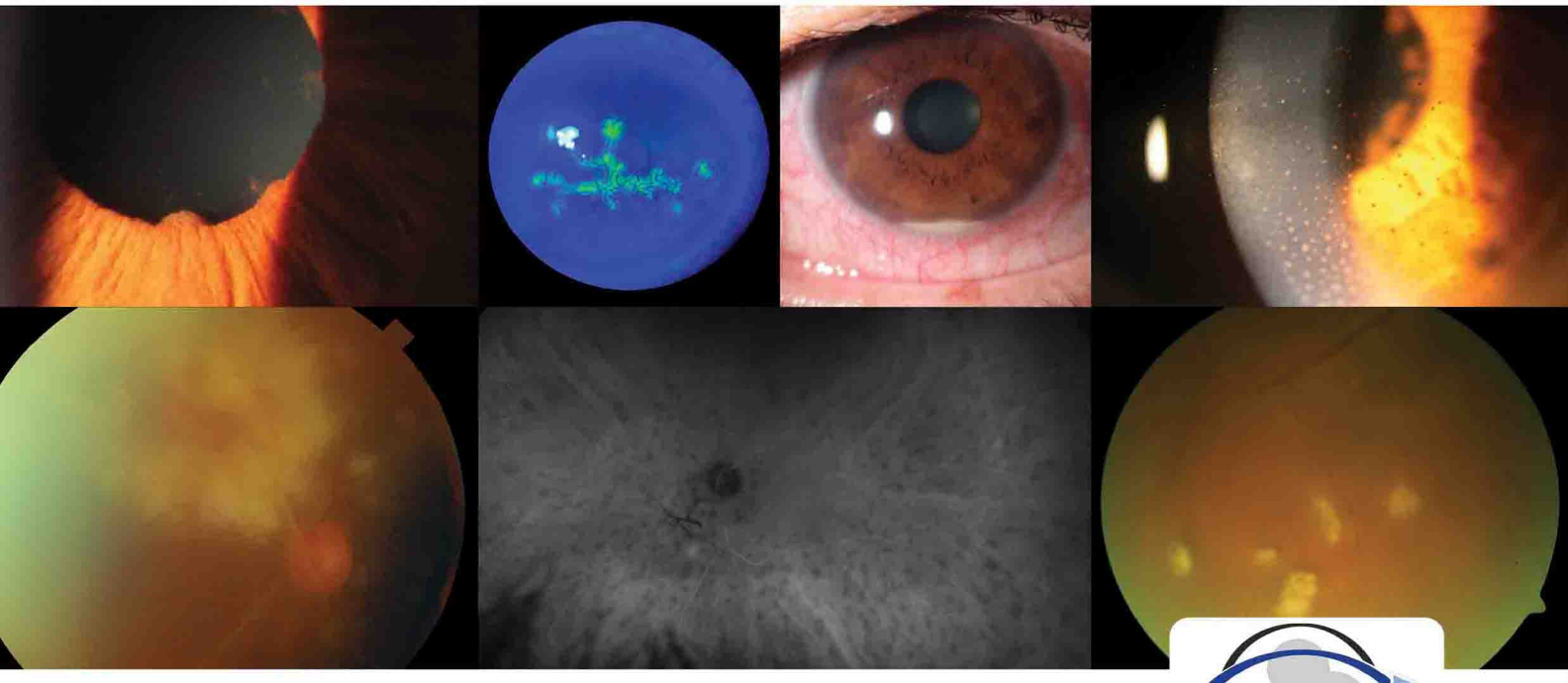

Under the Aegis of International Uveitis Study Group

IUSG International Uveitis Study Group 1978

Case Studies in UVEITIS

Real Cases & Practical Insights

Editors
Alejandra de-la-Torre
Meghan Berkenstock
Germán Mejía-Salgado
John H Kempen
Reema Bansal
Vishali Gupta

Forewords
James T Rosenbaum
Amod Gupta
Philip Ian Murray
Manabu Mochizuki
Rubens Belfort Jr

JAYPEE

Contents

1. **Anterior Uveitis** 1
Alejandra de-la-Torre, Rupesh Agrawal, Miranda Gehrke, Stephan Thurau, Armin Taghavi Eraghi, Uwe Pleyer, Jonathan Malcolm Chavan, SR Rathinam, Germán Mejía-Salgado, Meghan Berkenstock, Reema Bansal, Vishali Gupta, John H Kempen

2. **Intermediate Uveitis** 21
John H Kempen, Jyotirmay Biswas, François Willermain, Alejandro Fonollosa, Anshukita, Aurélie Le, Jose Manuel Cachero Rodríguez, Germán Mejía-Salgado, Meghan Berkenstock, Vishali Gupta, Alejandra de-la-Torre

3. **Posterior Uveitis** 44
Carlos Pavesio, Katerina Lazari, Sofia Androudi, Charlotte van Meerwijk, Marc de Smet, Araniko Pandey, Janet Davis, Germán Mejía-Salgado, Meghan Berkenstock, Vishali Gupta, John H Kempen, Alejandra de-la-Torre

4. **Panuveitis** 65
Reema Bansal, Lucia Sobrin, Jie Sun, Ariel Schlaen, Agustina Nieddu, Sapna Gangaputra, Russel Dinh, Germán Mejía-Salgado, Meghan Berkenstock, John H Kempen, Alejandra de-la-Torre, Vishali Gupta

5. **Scleritis** 84
Peter McCluskey, Alexander Newman, Sibel Kadayifcilar, Figen Bezci Aygun, Cristhian Urzúa, Marcelo Vega-Codd, Germán Mejía-Salgado, Meghan Berkenstock, Reema Bansal, Vishali Gupta, John H Kempen, Alejandra de-la-Torre

6. **Ocular Toxoplasmosis** 102
Alejandra de-la-Torre, Germán Mejía-Salgado, Justine R Smith, Lisia Barros Ferreira, Daniel Vitor Vasconcelos-Santos, Laura Camila Ramírez-Márquez, Rubens Belfort Jr, Guilherme Macedo Souza, Meghan Berkenstock, Reema Bansal, Vishali Gupta, John H Kempen

7. **Ocular Tuberculosis** 127
Vishali Gupta, Atul Arora, Ahana Sen, Sudharshan S, Luca Cimino, Pietro Gentile, Talluri Ronnie Abhishek, Soumyava Basu, Germán Mejía-Salgado, Meghan Berkenstock, Reema Bansal, John H Kempen, Alejandra de-la-Torre

8. **Ocular Syphilis** 157
Mark Westcott, Ahmed Sallam, Francesco Pichi, Mudit Tyagi, Ahmed Shakarchi, Yanny Pérez Jimenez, Shravya Choudhary Bala, Germán Mejía-Salgado, Meghan Berkenstock, Reema Bansal, John H Kempen, Alejandra de-la-Torre, Vishali Gupta

9. **Herpetic Anterior Uveitis** 177
Massimo Accorinti, Matteo Menean, Elisabetta Miserocchi, Neofytos Mavris, Radgonde Amer, Daniele de Geronimo, Alejandra de-la-Torre, Germán Mejía-Salgado, Meghan Berkenstock, Reema Bansal, John H Kempen, Vishali Gupta

10. **Acute Retinal Necrosis** 203
Bahram Bodaghi, Sofia Androudi, Athanasios Pappas, J Fernando Arevalo, Jacob S Heng, Carsten Heinz, Charlotte Wortmann, Germán Mejía-Salgado, Meghan Berkenstock, Reema Bansal, John H Kempen, Alejandra de-la-Torre, Vishali Gupta

11. **RNA Viruses and Uveitis** 220
Piergiorgio Neri, Shravya Choudhary Bala, Mudit Tyagi, Pallavi Goel, Manisha Agarwal, Radhika Sriram, Padmamalini Mahendradas, Sara Prischak, Vishali Gupta, Germán Mejía-Salgado, Alejandra de-la-Torre, Reema Bansal, John H Kempen, Meghan Berkenstock

12. Ocular Complications of HIV and AIDS 233
Derrick Smit, Israel Mendez, Jennifer Thorne, Maria Carolina Kuba, Andre Luiz Land Curi, Linda Visser, Sara Prischak, Vishali Gupta, Reema Bansal, John H Kempen, Alejandra de-la-Torre, Meghan Berkenstock

13. Juvenile Idiopathic Arthritis-associated Uveitis 251
Meghan Berkenstock, Alessandra Pagliara, Claudia Fabiani, Sara Abdel Jalil, Radgonde Amer, Panayiotis Maghsoudlou, Athimalaipet V Ramanan, Sara Prischak, Vishali Gupta, Alejandra de-la-Torre, Reema Bansal, John H Kempen

14. Ocular Complications of Behçet's Disease 268
Ilknur Tugal-Tutkun, Merve Inanç Tekin, Pinar Ozdal, Wijden Nabi, Moncef Khairallah, Shruthika Bhimewar, Kalpana Babu Murthy, Ramesh Jois, Maggie Feng, Vishali Gupta, John H Kempen, Reema Bansal, Alejandra de-la-Torre, Meghan Berkenstock

15. Non-Infectious Posterior Uveitis (NIPU) 298
Janet Davis, Lawrence Chan, Anita Agarwal, Alessandro Feo, Shahin Faghihi, David Sarraf, Russel Dinh, Sapna Gangaputra, Maggie Feng, Vishali Gupta, Marc de Smet, John H Kempen, Reema Bansal, Alejandra de-la-Torre, Meghan Berkenstock

16. Systemic Therapy for Non-infectious Uveitis 334
Miguel Cordero-Coma, Israel Mendez, Jennifer Thorne, Emebet Getahun Tabor, John H Kempen, Jia-Horung Hung, Quan Dong Nguyen, Maggie Feng, Vishali Gupta, Marc de Smet, Reema Bansal, Alejandra de-la-Torre, Meghan Berkenstock

17. Local Therapy for Non-infectious Uveitis 359
Quan Dong Nguyen, Eugenia Ramos-Davila, Maria Carmela Saturno, Marc de Smet, Ngoc Trong Tuong Than, Jia-Horung Hung, Maggie Feng, Vishali Gupta, Reema Bansal, Alejandra de-la-Torre, John H Kempen, Meghan Berkenstock

18. Drug-induced Uveitis 382
James P Dunn, Eugenia Ramos-Davila, James T Rosenbaum, Jennifer Hu, Lucia Sobrin, Wenbo Ding, Maggie Feng, Nimesh Patel, Vishali Gupta, Marc de Smet, Reema Bansal, Alejandra de-la-Torre, John H Kempen, Meghan Berkenstock

Index 405

CHAPTER 16

Systemic Therapy for Non-infectious Uveitis

Miguel Cordero-Coma, Israel Mendez, Jennifer Thorne, Emebet Getahun Tabor, John H Kempen, Jia-Horung Hung, Quan Dong Nguyen, Maggie Feng, Vishali Gupta, Marc de Smet, Reema Bansal, Alejandra de-la-Torre, Meghan Berkenstock

JAYPEE BROTHERS

INTRODUCTION

Systemic therapy for non-infectious uveitis prevents ocular damage and vision loss, particularly in chronic or bilateral cases. Immunomodulatory agents, including corticosteroids, antimetabolites, calcineurin inhibitors, and biologics, have transformed the management of ocular inflammation by targeting underlying immune dysregulation. Early and individualized systemic treatment controls intraocular inflammation and reduces the cumulative burden of corticosteroid-related side effects. Understanding the immunopathogenesis of non-infectious uveitis allows clinicians to tailor therapy according to disease severity, anatomic location, and associated systemic conditions with improved long-term visual outcomes and quality of life.

THEMATIC LECTURE: PRACTICAL TIPS FOR SYSTEMIC THERAPY IN NON-INFECTIOUS UVEITIS

The management of non-infectious uveitis remains challenging for several reasons. First, it is a heterogeneous condition with many different clinical pictures under the same umbrella term.[1] Secondly, there is a lack of universally accepted therapeutic guidelines, as well as standardized criteria for treatment response and monitoring. Finally, therapeutic options remain limited, and many immunosuppressive agents are currently used off-label.

When comparing anterior with posterior pole-involving, non-infectious uveitis, patients with anterior uveitis have a limited disease course with a lower incidence of ocular complications.[2] The prognosis for inflammation restricted to the anterior chamber is better, and topical treatment is effective. This is why patients with anterior uveitis are treated initially with topical corticosteroids, and systemic therapy is reserved for select cases. On the other hand, non-anterior uveitis patients have a prolonged disease course with a higher incidence of ocular complications, a worse overall prognosis, and limited efficacy of topical treatments.[3-5] Systemic immunosuppressive therapy is the preferred initial treatment, leaving intraocular corticosteroid injections reserved for selected cases or to treat complications, such as macular edema **(Fig. 1)**.

The classic management of non-infectious uveitis is summarized in the stepladder algorithm shown in **Flowchart 1**. Corticosteroids are the initial common therapy for all patients. For those patients with severe, vision-threatening disease, immunosuppressive medications or even alkylating agents are used. Coadjuvant therapy with intravitreal or periocular corticosteroid injections or surgery is used by the clinician at their discretion.

As previously mentioned, corticosteroids were the mainstay of treatment, given the immediate anti-inflammatory effect.[6-9] However, the side effect profile is long, and as a class, corticosteroids display a tachyphylaxis phenomenon with increasing doses needed to maintain the same clinical effect with continued use.[6,7,10]

Analyzing causes of long-term vision loss from uveitis shows that macular damage remains the main risk factor.[2] The most important question to prevent complications is when should immunosuppression be started? The goal should be preservation of visual function starting in the early stages of the disease when inflammation is reversible.[11] Treatment delays result in irreversible structural damage, including atrophy of the external layers of the retina and fibrosis.

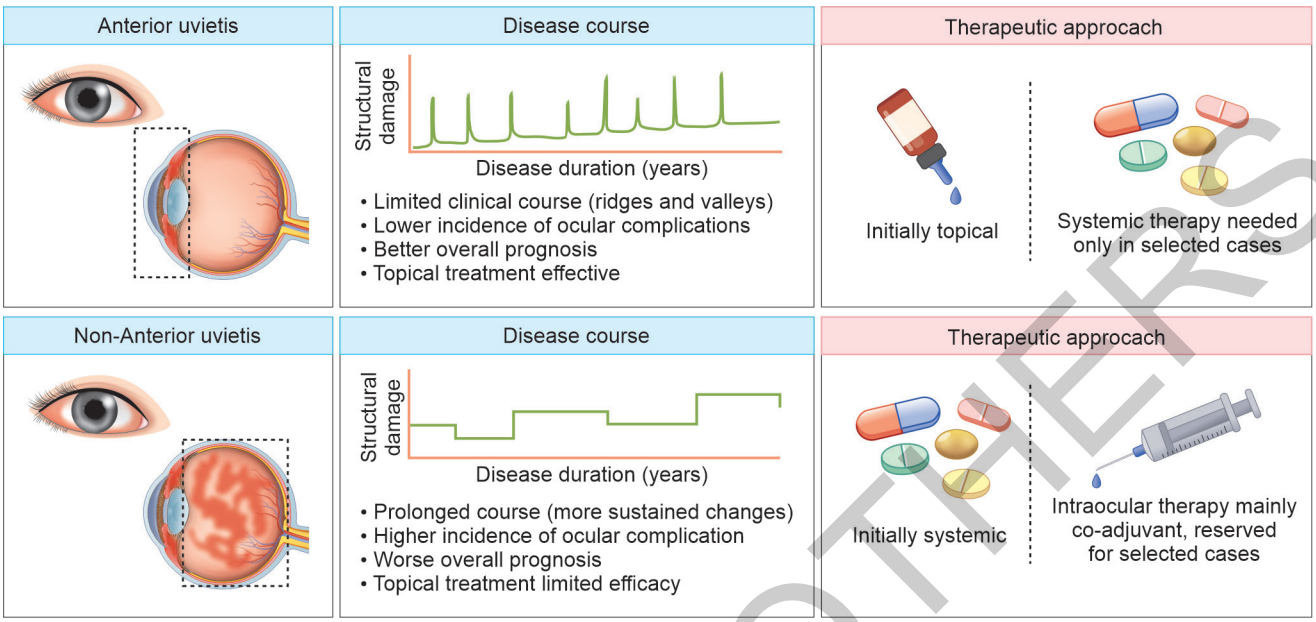

Fig. 1: A schematic diagram contrasting the locations of inflammation, disease course, and treatments for anterior versus non-anterior, non-infectious uveitis.
Source: Uveitis Course - Grand Rounds 16. International Uveitis Study Group (IUSG). June 14, 2025. Available at: https://youtu.be/2UVTU7oztTc?si=y7tNEsxDMokFr6uw.

Flowchart 1: A stepladder algorithm for management of non-infectious uveitis based on severity.

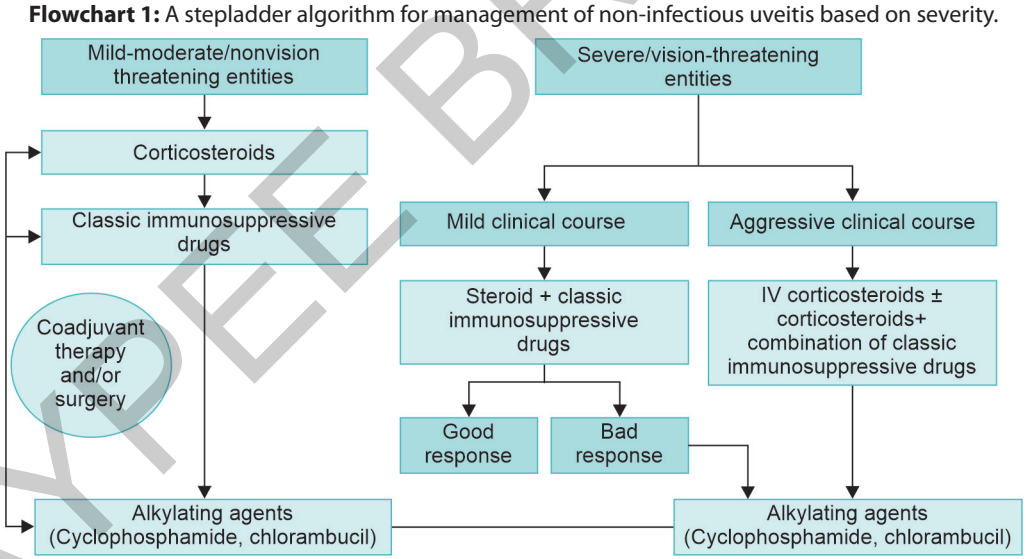

Source: Uveitis Course - Grand Rounds 16. International Uveitis Study Group (IUSG). June 14, 2025. Available at: https://youtu.be/2UVTU7oztTc?si=y7tNEsxDMokFr6uw.

The Fundamentals of Care for Uveitis (FOCUS) initiative published guideline indications for initiating systemic immunosuppressive therapy as summarized by four indications: ocular and anatomic, therapeutic, severity in adults, and severity in children.[12] The latter was specifically included regarding the treatment of juvenile idiopathic arthritis (JIA)-associated uveitis. These guidelines can help to decide when to start systemic immunosuppressive therapy, which can be challenging **(Box 1)**.

Many factors influence the choice of an immunosuppressive medication in patients with non-infectious uveitis.[13-15] Some of these factors are related to patient characteristics, such as the uveitis severity and location. Non-patient-related factors include failure or side effects from prior immunosuppressive drugs and cost.

JAYPEE BROTHERS

Several years ago, the Spanish Society of Uveitis initiated a project to develop treatment recommendations for systemic immunosuppressive therapy for patients with both anterior and non-anterior uveitis. This was also supported by the Spanish Societies of Rheumatology, Immunology, and Internal Medicine. The project included a systematic review, meeting of expert panels, two Delphi rounds, and a final external evaluation.[16-18] The generated clinical statements provide evidence, a recommendation grade, a level of agreement, and guidance for the clinical care of patients with a complex disease history.

Regarding conventional immunomodulators and immunosuppressants, most are used off-label and have a more limited efficacy when compared to corticosteroids.[19-21] Furthermore, each has a specific side effect profile that can lead to discontinuation, as seen in **Table 1**. Efficacy is even lower when results are analyzed to include concurrent use of low doses of corticosteroids.[22-25]

Biologic agents filled the need for more effective, non-corticosteroid immunosuppression, first with anti-tumor necrosis factor (TNF) alpha inhibitors.[26-30] When comparing the discontinuation rates based on tolerability, safety, and patient preference, adalimumab or infliximab were stopped less frequently than conventional immunosuppressive medications **(Table 2)**.[31]

Beyond efficacy and tolerability, the third reason for worldwide use of biologic agents is quality of life. **Table 3** shows aspects of quality of life improved with the use of infliximab over traditional immunosuppressive agents, even in more severe cases of inflammation, such as Behçet's disease-associated uveitis.[32]

This led to the initial approval of adalimumab, then other biologic agents for patients with refractory or severe vision-threatening inflammation early in the disease course. Biologics replaced alkylating agents in these clinical scenarios, with the latter used only in select circumstances **(Flowchart 2)**.

Using the algorithm in **Flowchart 2**, deciding which patients should have treatment escalated to the use of biologic therapies and when to make the change becomes clearer. Factors to consider are the presence of inflammation refractory to conventional therapy, poor visual acuity, or bilateral disease in a working-age group. Additionally, other considerations requiring biologic agent use include systemic diseases associated with aggressive ocular inflammation, such as Behçet's disease, or in situations where conventional immunosuppressants or corticosteroids are contraindicated, such as in pregnancy and diabetes **(Table 4)**.

BOX 1: A summary of the four indications for starting systemic immunosuppressive therapy based on the FOCUS initiative.

Indications for initiating systemic therapy:

- *Ocular and anatomic* Acute sight-threatening, chronic persistent, macular involvement, binocular sight-threatening.
- *Therapeutic* Regional failure to respond to periocular/topical steroids, systemic failure to steroids, steroid intolerance, need for steroid-sparing effect.
- *Severity (adults)* VA worse than 20/100, Increase of vitreous haze >2, relapse of CME, disease that impacts quality of life
- *Severity (child's/JIA)* VA at presentation, posterior uveitis. glaucoma, advanced cataract, CME, synechiae, band keratopathy, hypotony, rubeosis iridis

(CME: cystoid macular edema; JIA: juvenile idiopathic arthritis; VA; visual acuity)

Source: Uveitis Course - Grand Rounds 16. International Uveitis Study Group (IUSG). June 14, 2025. Available at: https://youtu.be/2UVTU7oztTc?si=y7tNEsxDMokFr6uw.

TABLE 1: A summary of the efficacy over time of non-corticosteroid, systemic immunosuppressive therapies alone, and with concurrent use of low-dose prednisone.

Drug	*Success at 1 year*	*≤10 mg prednisone*	*Discontinued within 1 year*
Mycophenolate	73%	55%	12%
Cyclosporine	52%	36%	11%
Methotrexate	66%	58%	16%
Azathioprine	62%	47%	24%

Source: Uveitis Course - Grand Rounds 16. International Uveitis Study Group (IUSG). June 14, 2025. Available at: https://youtu.be/2UVTU7oztTc?si=y7tNEsxDMokFr6uw.

TABLE 2: A comparison of the reasons for medication discontinuation based on efficacy, tolerability, safety, and patient preference between methotrexate (MTX), mycophenolate mofetil (MMF), azathioprine (AZA), adalimumab (ADA), and infliximab (IFX).

IMT	*MTX*	*MMF*	*AZA*	*ADA*	*IFX*	*P-value*
Medication discontinued for any reason	159 (51.3%)	48 (53.3%)	29 (44.6%)	97 (43.1%)	24 (34.3%)	0.005
Discontinued for reasons other than efficacy (tolerability, safety, and patient preference)	131 (42.3%)	44 (48.9%)	24 (48.9%)	50 (22%)	13 (18.6%)	>0.0001

Source: Uveitis Course - Grand Rounds 16. International Uveitis Study Group (IUSG). June 14, 2025. Available at: https://youtu.be/2UVTU7oztTc?si=y7tNEsxDMokFr6uw.

JAYPEE BROTHERS

TABLE 3: The National Eye Institute (NEI) 25 Visual Function Questionnaire showing areas of significant quality of life improvements in patients with Behçet's disease using infliximab biologic therapy.

NEI 25-item visual function questionnaire composite and subscale score in patients with Behçet's disease before and after receiving infliximab therapy	*p-value before versus after infliximab (IFX)*
General health	<0.0001
General vision	0.0001
Ocular pain	0.0002
Near activities	0.0001
Distance activities	0.0001
Social functioning	0.0001
Mental health	0.0001
Role difficulties	0.0001
Dependency	0.0001
Driving	0.0059
Color vision	0.0209
Peripheral vision	0.0004
Composite score	0.0001

Source: Uveitis Course - Grand Rounds 16. International Uveitis Study Group (IUSG). June 14, 2025. Available at: https://youtu.be/2UVTU7oztTc?si=y7tNEsxDMokFr6uw.

TABLE 4: A summary table of the factors for and against the use of biologics as the treatment choice for patients with non-infectious uveitis.

Treatment of Nina with biologic therapy	
Favors	***Against***
• Refractory to conventional therapy	• Good response
• Poor visual acuity (affected/fellow eye)	• Good visual acuity (OU)
• Bilateral	• Unilateral
• Young working-age patients	• Old/retired/sedentary patients
• Theoretically aggressive associated diseases (i.e., Behçet's)	• Theoretically mild (less aggressive) associated disease
• Aggressive clinical courses	• Mild/moderate clinical courses
• Associated conditions that contra-indicate or complicate the use of corticosteroids or conventional immunomodulatory therapy (IMT) (e.g., diabetes and obesity)	• Absence of these conditions

Source: Uveitis Course - Grand Rounds 16. International Uveitis Study Group (IUSG). June 14, 2025. Available at: https://youtu.be/2UVTU7oztTc?si=y7tNEsxDMokFr6uw.

Flowchart 2: Current management of mild or severe, non-infectious uveitis in the era of biologic agent availability.

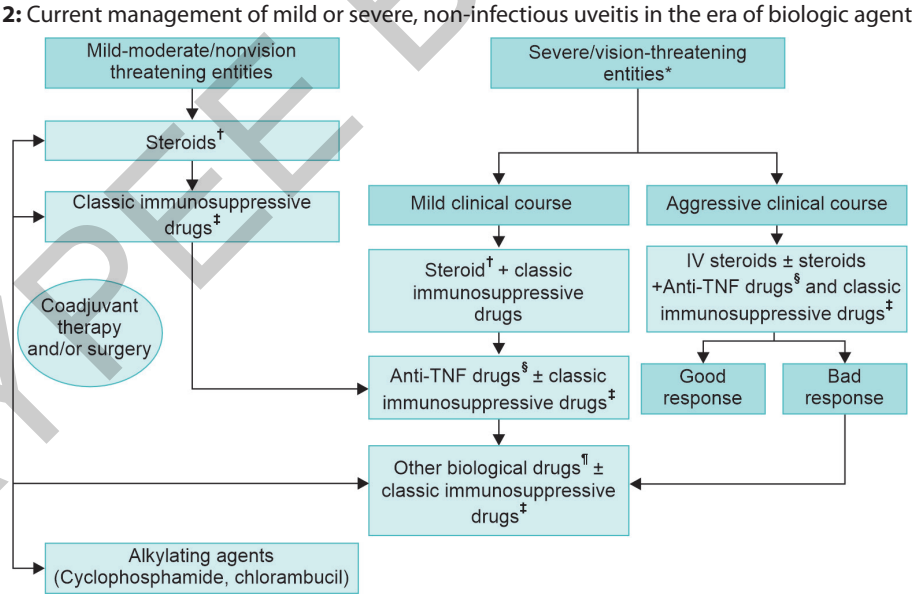

*Behceet disease, Juvenile Idiopathic Arthritis, Sympathetic Ophthalmia, Peripheral Ulcerative Keratitis, Scleritis, and Severe Choroidopathies (e.g. Serpiginous choroiditis)
†Topical, local, or regional and/or systemic
‡Methotrexate, azathioprine, mycophenolate mofetil, cyclosporine
§First-line anti-TNF drugs are infliximab and adalimumab
¶Other anti-TNF (golimumab, certolizumab), interferon, tocilizumab, rituximab
Source: Uveitis Course - Grand Rounds 16. International Uveitis Study Group (IUSG). June 14, 2025. Available at: https://youtu.be/2UVTU7oztTc?si=y7tNEsxDMokFr6uw.

JAYPEE BROTHERS

TABLE 5: Summary tables showing the available biologic agents with evidence and recommendation level reported by the FOCUS initiative.

Originator biologic	*Evidence level*	*Recommendation level*
Antitumor necrosis factor (anti-TNF)		
Infliximab	2B AU, 3B IU, 3B-4 PU, and 5 PanU	B-C
Adalimumab	1B AU, 2B IU, 4 PU, and 5 PanU	A
Golimumab	4	C
Etanercept	2B	B
Certolizumab	-	D
Anti-interleukin 1		
Anakinra/ canakinumab	4	C
Gevokizumab	2B	C
Anti-interleukin 2		
Daclizumab	2B-4	B
Anti-interleukin 6		
Tocilizumab	4	C
Sarilumab	-	D
Anti-interleukin 17		
Secukinumab	1B IU, 2B PU, and PanU	B
Anti-CD20		
Rituximab	2B	C
Anti-CD52		
Alemtuzumab	2B	C
Interferons		
Interferons alfa-2a and 2b	2B AU, 3B IU, 4 PU and PanU, 5 RV	B
Pegylated interferon alfa-2b	2B	C
Interferon beta	2B	C
Others		
IV immunoglobulins	2B	C

IU: intermediate uveitis, PU: posterior uveitis, PanU: panuveitis.
Source: Uveitis Course - Grand Rounds 16. International Uveitis Study Group (IUSG). June 14, 2025. Available at: https://youtu.be/2UVTU7oztTc?si=y7tNEsxDMokFr6uw.

The FOCUS initiative published tables listing the available biologic agents with their evidence and recommendation levels.[12] The only immunosuppressant with an A recommendation level was adalimumab due to the on-label approval and randomized controlled trial (RCT) data. However, there is an increased use of all of the biologics listed worldwide in **Table 5**.

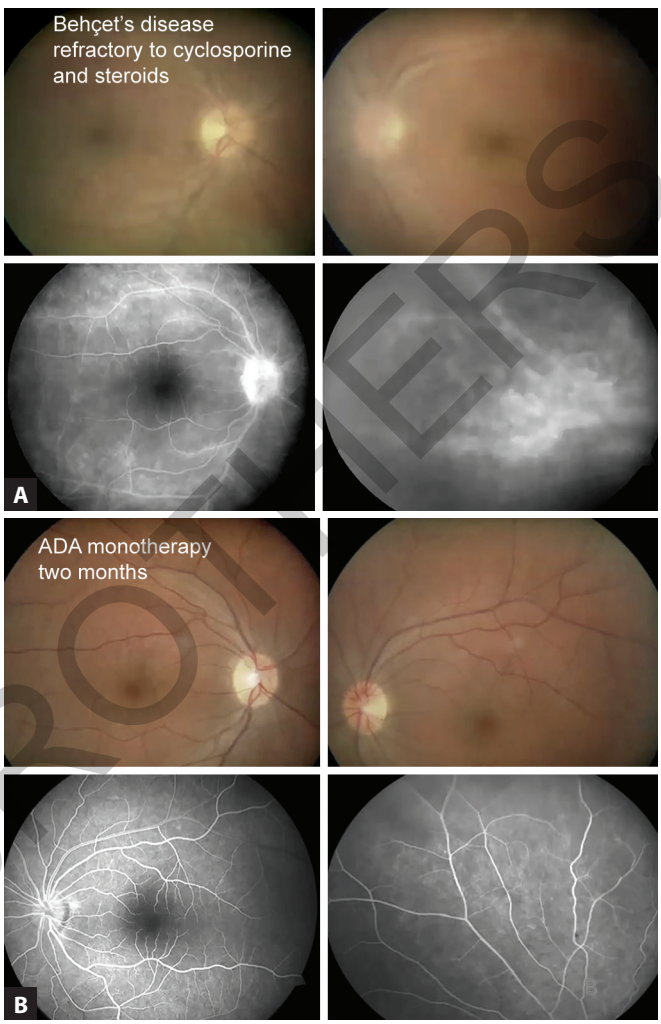

Figs. 2A and B: Color fundus photos (top, A) showing haze in both eyes in a patient with active Behçet's disease-associated uveitis. Fluorescein angiography of the right eye shows diffuse fern-like leakage (bottom, A). Two months after the start of adalimumab, there is less vitreous haze on color fundus photos (top, B) and minimal leakage on repeated fluorescein angiography in the left eye (bottom, B).
Source: Uveitis Course - Grand Rounds 16. International Uveitis Study Group (IUSG). June 14, 2025. Available at: https://youtu.be/2UVTU7oztTc?si=y7tNEsxDMokFr6uw.

Excluding issues unrelated to medical practice, such as higher costs, bureaucracy to obtain insurance approvals, and legal issues, here are some tips on how to proceed with immunosuppressive therapy in certain clinical scenarios. In a patient with panuveitis associated with Behçet's disease that is refractory to cyclosporine and corticosteroids, a TNF medication would be the next step in treatment if there were clinically active vitritis and retinal vasculitis. **Figures 2A and B** show the imaging results in a patient with this clinical picture after 2 months

JAYPEE BROTHERS

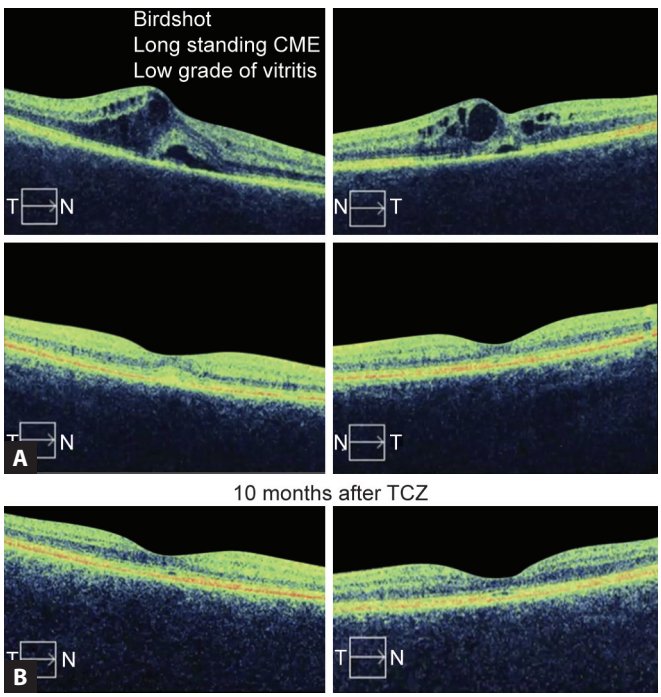

Figs. 3A and B: An OCT of the macula in a patient with Birdshot chorioretinitis showing the presence of cystoid macular edema (top) and gradual improvement and resolution of the edema after 10 months of tocilizumab monotherapy (bottom).
Source: Uveitis Course - Grand Rounds 16. International Uveitis Study Group (IUSG). June 14, 2025. Available at: https://youtu.be/2UVTU7oztTc?si=y7tNEsxDMokFr6uw.

of adalimumab therapy, showing a complete resolution of the clinical inflammation.

In the example of a patient with Birdshot chorioretinitis with long-standing cystoid macular edema and low-grade vitritis, the use of an interleukin 6 (IL-6) blocking biologic agent could be a better choice **(Figs. 3A and B)**. Long-standing edema evolves into atrophy, especially affecting the inner retina.

Another medically complex condition is Susac syndrome. In these cases, there needs to be an individualized therapeutic approach that is tailored to the patient. Treatment plans may require the use of all therapeutic modalities from traditional immunosuppressants to biologics to alkylating agents to control the underlying inflammation.

Once the decision to treat with an immunosuppressive agent has been made and the medication has been selected, the time needed to evaluate for efficacy is variable. The time until the full effect of the medication is obtained depends on the activity of an associated systemic disease, the location and severity of the uveitis, and the class of immunosuppressive medication. If 3–6 months have elapsed and inflammation is still present, questioning if the patient is administering the drug correctly at the appropriate dose and time is appropriate.[33,34] Time intervals will vary between agents, with a shorter time of action for biologics compared with classic immunosuppressive medications. There are paradoxical situations that occur with the use of immunosuppressive agents, such as having the quiet, better-seeing eye develop inflammation. In this case, a therapeutic response should be defined as quiescence in the better-seeing eye for preservation of visual function.

Assessing clinical efficacy requires assessment of the visual acuity in both eyes and a thorough clinical examination, scoring inflammation based on the Standardization in Uveitis Nomenclature (SUN) grading scales.[4] Additional imaging studies using a multimodal approach are needed. OCT scans can assess the central macular thickness, whereas a fluorescein angiogram can show details of the retinal vasculature.[35] Additional testing with autofluorescence, visual fields, and electroretinography should be performed at the discretion of the clinician. Posterior pole involving non-infectious uveitis requires a multimodal imaging approach to provide a comprehensive, in-depth evaluation for both monitoring and treatment decisions.

The concept of response to treatment remains ill-defined: complete, partial, or none. Current disease activity scales do take into account imaging test results, which are crucial for determining the response to treatment. Concepts including activity, worsening, and therapeutic failure would be beneficial as they give a more complete and comprehensive evaluation of the treatment of response and monitoring. In short, there is an unmet need regarding the development of a disease activity score in uveitis patients that incorporates data from many imaging and serologic tests to provide a complete assessment of clinical activity and the therapeutic response **(Fig. 4)**.[16,36-41]

Regarding monitoring safety, uveitis specialists can initiate the treatment independently or in a multidisciplinary approach. This includes checking for the presence of underlying infectious diseases before the initiation of immunosuppression, assessment of clinical inflammation prior to and after the start of treatment, and reminding the patient to follow dosing instructions and avoid live vaccines. This approach is important because it gives the opportunity to share the burden of management

JAYPEE BROTHERS

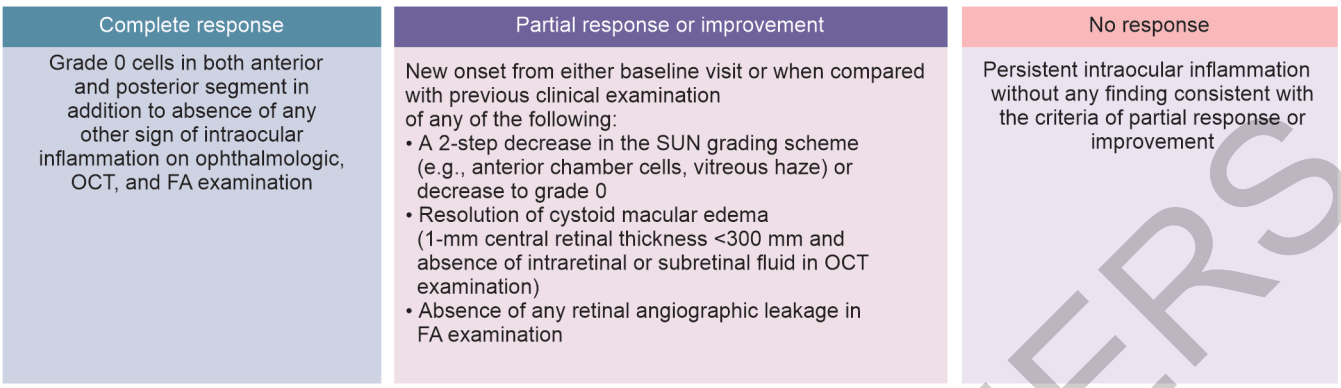

Fig. 4: A schematic showing proposed definitions for complete, partial, and no response to treatment in patients with non-infectious uveitis.
Source: Uveitis Course - Grand Rounds 16. International Uveitis Study Group (IUSG). June 14, 2025. Available at: https://youtu.be/2UVTU7oztTc?si=y7tNEsxDMokFr6uw.

with the patient and other medical specialists as prompt initiation of therapy leads to improved visual outcomes.

Therapeutic decision-making will be challenging. During the course of treatment, measurement of drug levels or antibody formation can be helpful in situations where there is a partial or no response.[36,42] Most of the research on this topic revolves around adalimumab, but this approach can be applied to many other biologic and non-biologic treatments. This clarifies the clinical situation by assessing for antibody formation, low drug levels, or if the patient is refractory to the mechanism of action of the drug when the response is less than expected. In the setting of low drug levels, making sure the drug is being taken correctly is also important. Monitoring of serum drug levels also gives the opportunity to establish a therapeutic range and aid in decision-making to optimize or discontinue an immunosuppressant. The goal is to plan ahead for unexpected events, such as altering dosing or switching agents to avoid a flare.[9,43]

How long to keep patients on immunosuppressive therapies is another difficult question. There has been work on drug retention rates on adalimumab, with >50% of patients at 60 months still taking the medication with concurrent immunomodulatory therapy.[44,45] Factors predictive of discontinuation included using adalimumab as a second or third-line agent due to efficacy and the development of adverse events.

In summary, there is solid evidence supporting the use of systemic immunosuppression in patients with non-infectious uveitis. Second, the goal is to preserve visual function through the early institution of immunosuppressive agents. The decision-making should be structured, standardized, and based on the available evidence. While this is not always possible, recommendations should be followed and treatment decisions should be supported with drug levels. Finally, treatment algorithms that incorporate drug levels and imaging results in the definition of response to therapy are needed.

CLASSIC, NON-INFECTIOUS ANTERIOR UVEITIS MANAGED WITH CORTICOSTEROIDS

Red Eye, Deeper Roots

Personal Data

A 14-year-old female presented from the emergency department with a 1-week history of right eye pain, redness, and light sensitivity.

History of Present Illness

The symptoms progressively worsened with the development of blurry vision in the right eye. She reported this was the first occurrence and she had no past medical, surgical, or trauma history. She was not taking any medications, and the review systems were completely unremarkable.

Physical Exam

On initial evaluation, the vision at near was J10 with pinhole improvement to J3 in the right eye and J1+ in the left eye. Her right eye was injected with the formation of a hypopyon **(Fig. 5)**.

JAYPEE BROTHERS

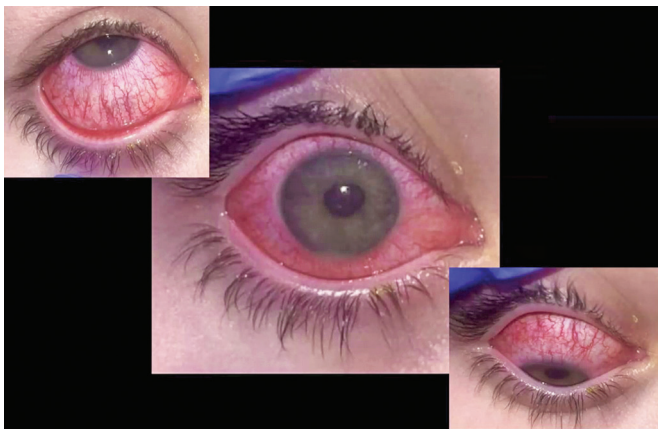

Fig. 5: An external color photograph of the right eye showing an inferior hypopyon and conjunctival injection.
Source: Uveitis Course - Grand Rounds 16. International Uveitis Study Group (IUSG). June 14, 2025. Available at: https://youtu.be/2UVTU7oztTc?si=y7tNEsxDMokFr6uw.

Slit Lamp Examination (Table 6)

Table 6 summarizes the initial examination findings.

TABLE 6: Slit lamp examination of a patient having classic, noninfectious anterior uveitis managed with corticosteroids.

OD	*Parameter*	*OS*
J10 ph J3	BCVA	J1+
14 mm Hg	IOP	12 mm Hg
Reactive ptosis	Lids/Lashes	Normal
2+ injection	Conjunctiva	White and quiet
Inferior fine KPs	Cornea	Clear
3+ cell, <0.2 mm hypopyon versus fibrin collection inferiorly	Anterior chamber	Deep and quiet
Prominent vessels, no transillumination defects, fibrin across pupil, posterior synechiae clockwise from 1 to 4 o'clock	Iris	Normal
Hazy view	Lens	Clear
Hazy view with a red reflex	Vitreous	Normal
Grossly normal optic nerve, vessels, periphery, and macula	Fundus	Normal

(BCVA: best corrected visual acuity; IOP: intraocular pressure; KPs: keratic precipitates; ph: pinhole)

Ancillary Testing

To assess for occult chorioretinal involvement or retinal vasculitis, a wide-field fluorescein angiogram was performed, which was normal in both eyes.

Uveitis Workup

The serologic workup had a negative syphilis IgG, RPR, QuantiFERON gold, and Lyme antibodies. A chest X-ray was also performed, which was normal. However, the patient was positive for the human leukocyte antigen B27 (HLA-B27) antigen.

Initial Treatment

At the top of the differential diagnosis for this patient was HLA-B27-associated anterior uveitis, Behçet's disease-associated anterior uveitis, or sarcoid-associated anterior uveitis. Endophthalmitis was less likely given the lack of precipitating risk factors and a normal posterior pole examination. The patient was started on one drop of prednisolone acetate 1% every hour while awake in the right eye with cyclopentolate 0.5% twice a day. Once the labs were negative for an underlying infectious process, the patient started oral prednisone 40 mg daily with a decrease every 3 days to suppress the inflammation faster: 30, 25, 20, 15, 12.5, 10, 7.5, 5, and 2.5 mg.

Follow-up

The patient was seen 4 weeks later, and the vision had improved to 20/25 in the right eye. She was taking prednisolone acetate 1% four times a day and continuing the oral prednisone taper. On examination, the synechiae was broken, and only pigment remained on the anterior capsule **(Fig. 6)**.

The treatment plan was to finish the oral prednisone and prednisolone acetate 1% tapers and to monitor for inflammation recurrence. Cyclopentolate drops were also discontinued. A rheumatology referral was placed to assess for occult spondyloarthropathy.

Discussion

A short burst of oral corticosteroids can be helpful in cases of fulminant HLA-B27 anterior uveitis to achieve quiescence faster. It is one of a handful of situations where a taper of oral corticosteroids for active inflammation should be done quickly. It is important to note that the most common cause of hypopyon formation in the United States is HLA-B27-associated anterior uveitis. However, in other parts of the world, Behçet's disease may be a

JAYPEE BROTHERS

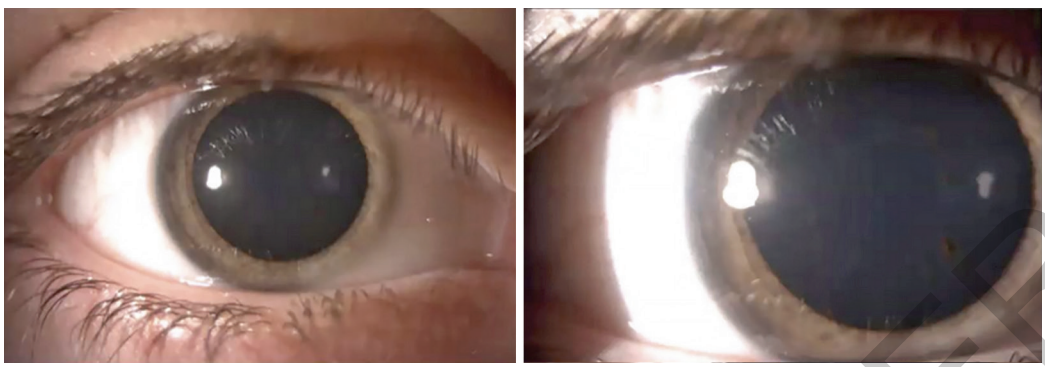

Fig. 6: An external color photograph of the right eye 4 weeks after presentation showing no posterior synechiae and resolution of the conjunctival injection.
Source: Uveitis Course - Grand Rounds 16. International Uveitis Study Group (IUSG). June 14, 2025. Available at: https://youtu.be/2UVTU7oztTc?si=y7tNEsxDMokFr6uw.

more likely diagnosis. In the case of Behçet's disease-associated uveitis with a hypopyon, treatment with high-dose prednisone is needed along with the concurrent start of an immunosuppressive agent, as corticosteroids alone will not lead to remission. The presence of a hypopyon and retinal vasculitis is an indication for starting with a biologic immunosuppressive agent over a conventional immunosuppressant. One severe episode of inflammation can lead to retinal infarction and irreparable structural damage. In this case, the fluorescein angiography showed no posterior involvement. Given the positive HLA-B27 antigen and no inflammation on fluorescein angiography, we would not start immunosuppression unless there were multiple, frequent, or severe flares.

A very important point for consideration regarding HLA-B27 positivity is the occult presence of an associated systemic disease. The Spondyloarthritis-Eye (SpEYE) and Dublin Uveitis Evaluation Tool (DUET) studies showed the underdiagnosis of rheumatologic manifestations of HLA-B27 positivity in patients with uveitis.[46,47] Therefore, it is important to investigate symptoms of arthritis, low back pain, and stiffness on a review of systems. Up to 50% of the patients either had spondyloarthritis or axial arthritis in the aforementioned studies. Early diagnosis prevents long-term sequelae of spinal curvature through immunosuppression, physical therapy, and exercise.

PANUVEITIS REQUIRING CORTICOSTEROID USE

Case Presentation

Personal Data

A 39-year-old male presented with blurred vision and floaters in both eyes for 2 months.

TABLE 7: Slit lamp examination of a patient having panuveitis requiring corticosteroid.

OD	*Parameter*	*OS*
6/36	BCVA	6/18
14 mm Hg	IOP	14 mm Hg
2+ injection	Conjunctiva	2+ injection
Endothelial dusting	Cornea	Endothelial dusting
2+ cell, 2+ flare	Anterior chamber	2+ cell, 2+ flare
Normal	Iris	Normal
Clear	Lens	Clear
2+ cell	Vitreous	2+ cell
Optic disc edema, small whitish chorioretinal lesions	Fundus	Optic disc edema, small whitish chorioretinal lesions

(BCVA: best corrected visual acuity, IOP: intraocular pressure; KPs: keratic precipitates)

History of Present Illness

The change in vision was accompanied by bilateral eye redness and photophobia. He had no past medical history or recent systemic illnesses.

Physical Examination

The best corrected vision was 6/26 in the right eye and 6/18 in the left eye. In both anterior chambers, 2+ cell and 2+ flare were noted. Posteriorly, optic nerve edema and white chorioretinal lesions were noted on fundoscopy.

Slit Lamp Examination

The slit lamp exam findings are summarized in **Table 7**.

JAYPEE BROTHERS

Ancillary Testing

Optical coherence tomography scans of the retina showed macular and optic nerve edema with vitreous cells in the right eye. In the left eye, only vitreous cells were noted **(Fig. 7)**.

Uveitis Workup

Syphilis serologies and a tuberculin skin test were negative. A chest x-ray was also normal.

Initial Treatment

The patient started one drop of dexamethasone every hour in both eyes, atropine 1% twice per day in both eyes, prednisolone 20 mg daily, and calcium and vitamin D3 supplements to be taken daily.

Follow-up

Two weeks later, on re-evaluation, the vision in the right eye was 6/36 and 6/9 in the left eye. He had trace cells in both anterior chambers, and the chorioretinal lesions had resolved. He gradually tapered the dexamethasone eye drop weekly to a maintenance dose of once per day. The prednisolone was tapered to 5 mg/day as a maintenance dose.

Two weeks later, the best corrected vision in the right eye had improved from 6/36 to 6/9, and the left eye had improved from 6/18 to 6/6. There were no signs of inflammation, and the patient was advised to continue 5 mg of prednisolone per day and a drop of dexamethasone daily in both eyes as a maintenance dose until he could see an ophthalmologist while working abroad. Unfortunately, 3 months later, he returned with decreased vision in the right eye to 6/60 that corrected to 6/24. Similarly, in the left eye, there was a decrease to 6/18 with correction to 6/12. On slit lamp examination, there were fine keratic precipitates in both eyes and 2+ anterior chamber cells. Also noted were bilateral vitreous cells and snowballs. Further testing with OCT imaging showed cystoid macular edema in both eyes and choroidal elevation between the macula and the optic disc in the right eye only **(Fig. 8)**.

Given the clinical activity seen in both eyes, high-dose prednisolone was started orally at 60 mg/day for 1 week with the use of prednisolone acetate 1% every hour while awake in both eyes. Additionally, he was given calcium 600mg and vitamin D3 100 international units supplements to be taken orally once a day. One week later, the vision in the right eye improved to 6/60 and with correction to 6/12. The vision in the left eye also improved to 6/18 and to 6/9 with correction, with a concurrent improvement in the inflammation to 0.5+ cell in both anterior chambers. The oral prednisolone was tapered gradually over several weeks to a maintenance dose of 7.5 mg/day with one drop

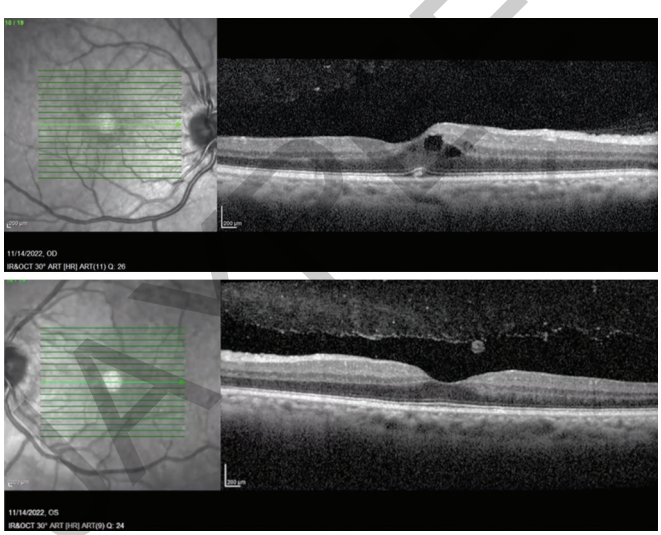

Fig. 7: An optical coherence tomography (OCT) scan of the retina in the right eye (top) shows macular edema and cells in the posterior vitreous, while the left eye scan (bottom) showed a preserved foveal contour with the presence of vitreous cells.
Source: Uveitis Course - Grand Rounds 16. International Uveitis Study Group (IUSG). June 14, 2025. Available at: https://youtu.be/2UVTU7oztTc?si=y7tNEsxDMokFr6uw.

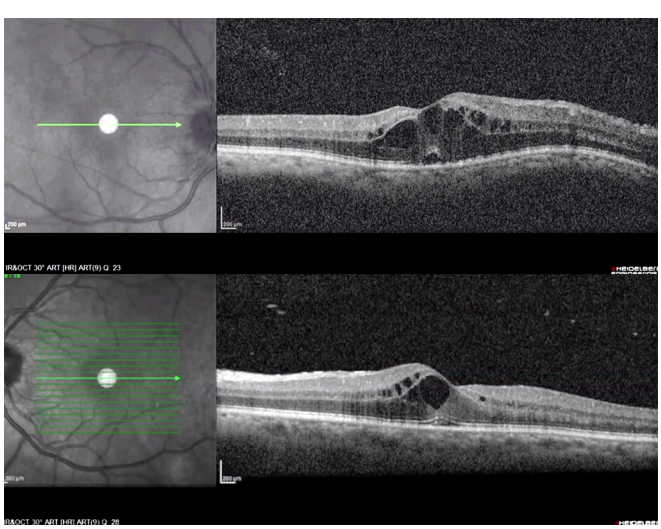

Fig. 8: An optical coherence tomography (OCT) scan of the macula in the right eye (top) showing macular edema with choroidal elevation between the macula and the optic disc. An OCT scan of the left eye also showed macular edema (bottom).
Source: Uveitis Course - Grand Rounds 16. International Uveitis Study Group (IUSG). June 14, 2025. Available at: https://youtu.be/2UVTU7oztTc?si=y7tNEsxDMokFr6uw.

AMIR BROTHERS



Fig. 9: An optical coherence tomography (OCT) scan through the macula of the left eye showing choroidal elevation and thickening (red arrow).
Source: Uveitis Course - Grand Rounds 16. International Uveitis Study Group (IUSG). June 14, 2025. Available at: https://youtu.be/2UVTU7oztTc?si=y7tNEsxDMokFr6uw.

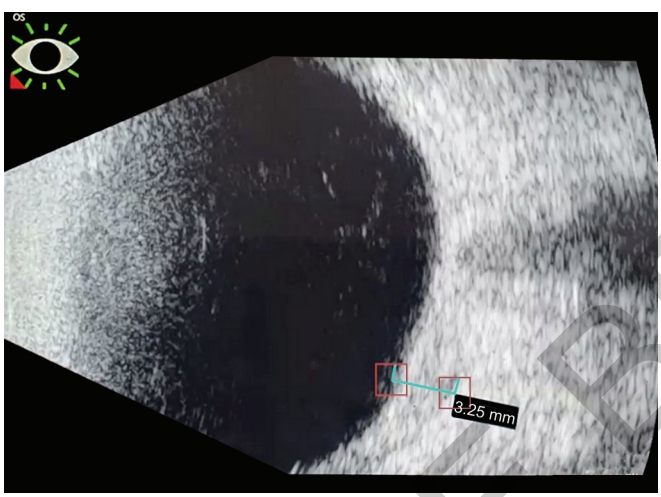

Fig. 10: A B-scan ultrasound of the left eye showing diffuse choroidal thickening that measured 3.25 mm. Vitreous debris is also noted.
Source: Uveitis Course - Grand Rounds 16. International Uveitis Study Group (IUSG). June 14, 2025. Available at: https://youtu.be/2UVTU7oztTc?si=y7tNEsxDMokFr6uw.

of dexamethasone in both eyes, resulting in control of the inflammation for 1 year.

He then presented with a headache and pain in the left eye. The vision in the right eye was 6/12 and 6/9 in the left eye. On examination, there was 1+ anterior chamber cell in the left eye, and both eyes had optic disc hyperemia. On OCT imaging, there was choroidal thickening noted in the macula **(Fig. 9)** of the left eye that measured 3.25 mm with a diffuse, hyperechoic signal on B-scan ultrasonography **(Fig. 10)**.

Repeat testing for tuberculosis with a purified protein derivative (PPD) test was negative, along with an interferon gamma release assay serologic test. He

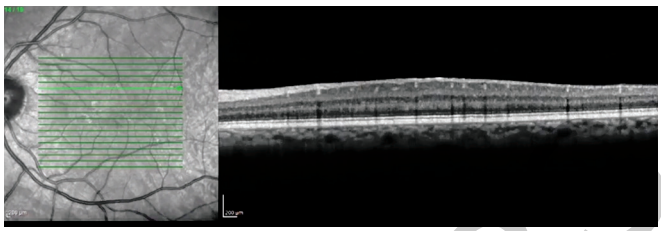

Fig. 11: An optical coherence tomography (OCT) scan of the left eye showing resolution of the choroidal thickening seen in **Figure 9**.
Source: Uveitis Course - Grand Rounds 16. International Uveitis Study Group (IUSG). June 14, 2025. Available at: https://youtu.be/2UVTU7oztTc?si=y7tNEsxDMokFr6uw.

was started on methotrexate 10 mg weekly for systemic immunosuppression, which was gradually increased weekly by 2.5 mg up to 20 mg weekly with folic acid supplementation. In addition, oral prednisolone 5 mg/day was continued. An OCT of the left eye clearly showed resolution of the choroidal thickening in addition to achieving clinical quiescence **(Fig. 11)**. The most recent follow-up occurred in May 2025 after 1 year of methotrexate use, and his vision with correction was 6/6 in both eyes with no sign of inflammation.

Discussion

This case illustrates how we often approach managing disease with just corticosteroids due to cost constraints in Ethiopia. While it works well to achieve quiescence in many patients, others require the start of non-corticosteroid immunosuppression. Herein, I will talk about conventional immunosuppression.

After excluding infectious etiologies start with the induction of high dose corticosteroids, either topically or with both topical and oral formulations, to quickly achieve control of the active inflammation. Once quiescence is achieved, gradually reduce the dose to see if the inflammation remains controlled, as in the first case. If not, the next step is to identify a minimal suppressive dose to continue, as in the second case. In chronic cases, the goal is to use the minimal suppressive corticosteroid dose with non-corticosteroid immunosuppressive agents. Vision is preserved through the use of maintenance dosing to prevent recurrent inflammation. Unfortunately, most of the immunosuppressive mediations used to treat ocular inflammation do not result in remission in all cases, except alkylating agents. Thus, control of inflammation is the goal using a combination of immunosuppressive agents.

JAYPEE BROTHERS

Defining a safe, minimal, suppressive dose is not evidence-based. Previous literature on the development of cataracts from the Systemic Immunosuppressive Therapy for Eye Diseases Cohort Study (SITE) suggests that one drop of prednisolone acetate 1% every other day is a safe dose.[48] The risk of cataract formation with topical corticosteroid use increases in a dose-dependent manner.[49] In addition, a drop of prednisolone acetate 1% once a day has almost doubled the risk of elevated intraocular pressure.[48] Comparatively, oral prednisolone 7.5 mg/day, or preferably 5 mg/day, is well tolerated with no increased risk of intraocular pressure elevation per the Multicenter Uveitis Steroid Treatment (MUST) Trial. With the development of new non-corticosteroid immunosuppressive medications, tapering to 5 mg of oral prednisone per day is more achievable.[50] The paper entitled "Guidelines for the Use of Immunosuppressive Drugs in Patients with Ocular Inflammatory Disorders: Recommendations of an Expert Panel," by Jabs et al., contains a lot of information on how to manage oral corticosteroid tapering and non-corticosteroid immunosuppressant management.[6] I will talk about some of the principles and recommend it as a reference guide.

There are three major indications for the use of immunosuppressive therapies. First, if the suppressive dose of oral corticosteroids is higher than 7.5 mg/day (ideally 5 mg/day) or management with the equivalent of prednisolone acetate 1% requires two or more drops per day with the development of elevated intraocular pressures or cataract, then the start of a corticosteroid sparing agent is warranted.[6] Secondly, in rare cases where corticosteroid therapy fails to control the inflammation, non-corticosteroid therapy should be initiated. However, very carefully reconsider the possibility of an infectious etiology as corticosteroids are the strongest agent to induce control of inflammation. Finally, there are specific diseases that should be treated early or initially with immunosuppression. Examples include Behçet's disease-associated uveitis with posterior pole involvement, Birdshot retinochoroiditis, serpiginous choroiditis not associated with tuberculosis, necrotizing scleritis (which is associated with higher mortality in cases due to systemic vasculitis), and mucous membrane pemphigoid with cicatrizing conjunctivitis.[6] There are arguably others, such as multifocal choroiditis and panuveitis or sympathetic ophthalmia. The use of immunosuppressive drugs has increased with more experience and confidence in terms of the safety and preservation of vision over time.

The classes of non-corticosteroid immunosuppressive agents used include the antimetabolites, T-cell inhibitors, alkylating agents, and the calcineurin inhibitors: cyclosporine and tacrolimus. The antimetabolites are relatively contraindicated in patients with liver disease, and the calcineurin inhibitors are relatively contraindicated in patients with renal disease and hypertension. At an age of ≥55 years, the risk of immunosuppressive agent discontinuation tripled in the SITE study.[50]

Table 8 is a summary slide that Dr. Douglas Jabs created for the MUST trial based on the aforementioned paper discussing the expert opinion on the use of immunosuppressants.[6,51] Escalating to the highest tolerated dose, with the exception of the alkylators, and

TABLE 8: Non-biologic, non-corticosteroid immunosuppressive drug dose recommendations for use in the treatment of ocular inflammatory disorders.

Drug	*Initial dose*	*Typical range*
Azathioprine	2 mg/kg/day	100–200 mg/day
Methotrexate	15 mg/week	15–25 mg/week
Mycophenolate	1 gm BID	1–1.5 g BID
Cyclosporine (Neoral)	2 mg/kg BID	1.5–2.5 mg/kg BID
Cyclosporine (Sandimmune)	2.5 mg/kg BID	1.5–2.5 mg/kg BID
Tacrolimus	1 mg BID	0.03–0.08 mg/kg/day
Cyclophosphamide	2 mg/kg/day	100–200 mg/day
Chlorambucil	0.1 mg/day	6–12 mg/day

Courtesy: MUST Research Group.
Source: Jabs DA, Rosenbaum JT, Foster CS, Holland GN, Jaffe GJ, Louie JS, et al. Guidelines for the use of immunosuppressive drugs in patients with ocular inflammatory disorders: recommendations of an expert panel. Am J Ophthalmol. 2000;130(4):492-513.
Source: Uveitis Course - Grand Rounds 16. International Uveitis Study Group (IUSG). June 14, 2025. Available at: https://youtu.be/2UVTU7oztTc?si=y7tNEsxDMokFr6uw.

JAYPEE BROTHERS

then lowering to the dose that still achieves quiescence has been the trend. For example, I use methotrexate dosing of 20 mg/week, whereas the First-line Antimetabolites as Steroid-sparing Treatment Trial (FAST) used 25 mg weekly.[52]

The next question is *which agent should I use?* The FAST trial was led by Dr. Nisha Acharya, who initially polled the American Uveitis Society and found that methotrexate and mycophenolate mofetil were the two most popular agents.[52] She and her colleagues from around the world compared methotrexate and mycophenolate in a randomized clinical trial, and methotrexate was proven to be non-inferior. It is also cheaper than mycophenolate. Another antimetabolite, azathioprine, has not been compared with anything other than in the SITE study.[53] It is popular in less developed countries and is reasonably inexpensive. In summary, methotrexate and azathioprine are the inexpensive options, and in the SITE study, the efficacy of all of the antimetabolites was similar. Methotrexate was slightly better, but this difference was not statistically significant. T-cell inhibitors and calcineurin inhibitors have also been successfully used to treat ocular inflammation. The efficacy of cyclosporine, per the SITE data, is less than that of the antimetabolites.[53] However, this may be due to increased use at the National Eye Institute location in the study, and since every visit was part of a protocol, they may have been more aggressive about documenting +0.5 anterior chamber cells. If you counted 0.5+ cells as a success, cyclosporine performed better. Many would argue that you should combine a calcineurin inhibitor with an antimetabolite if you are going to use combination therapy. However, this is becoming less popular with the availability of biologic agents.

The primary result of the FAST trial was treatment success in 66.7% in the methotrexate group versus 57.1% in the mycophenolate group [95% confidence interval (CI), –5.3–21.8%]; odds ratio (OR) 1.5 (95% CI: 0.81 to 2.81); $p = 0.20$.[52] Note that the OR for success by 6 months was considerable. There were 50% higher odds of success with methotrexate. However, the confidence interval crossed 1.0, and the result was not statistically significant. However, it did formally prove that methotrexate was non-inferior.

Moving on to alkylating agents, which arguably are the only class of immunosuppressive agents that induce remission. Slightly less than two-thirds of patients tolerate therapy per the SITE data.[50] Most of the data were from patients treated for mucous membrane pemphigoid. There is a short-term, high-dose approach with chlorambucil where the dose is escalated quickly and is stopped once the patient begins to become aplastic on complete blood count (CBC) studies. Remission occurs shortly thereafter. The use of alkylators is limited due to a high incidence of sterility, in as many as half of patients. It requires weekly monitoring with a CBC and urinalysis. There is also an increased risk of cancer, which was not found in the SITE studies.[50] Due to these potential side effects, the class is a less popular treatment option.

In our case, it was not clear early on that immunosuppression was needed. It seemed that with low-dose topical and oral corticosteroids, the patient could be managed with continued quiescence. Anatomically, panuveitis cannot be managed with topical therapy alone. However, as severity increased with time, it became clear that additional therapy would be needed. We view methotrexate as the first-line antimetabolite, based on the FAST study, the cost, and its availability in Ethiopia. After initiation of methotrexate, we assess for tolerance through symptom query and monitoring for toxicity from laboratory tests. If the initial drug fails, we can either try another agent in the same class, change to a calcineurin inhibitor or a T-cell inhibitor, or advance to a biologic. Anecdotally, we are not seeing an increase in infections in Ethiopia with the use of methotrexate and azathioprine. In contrast, more infections may occur if we had access to TNF inhibitors, as one out of three patients has developed disseminated tuberculosis.

Another consideration with immunosuppression use is the time to efficacy. As seen in both the SITE Study and the FAST trial, conventional agents take longer to work. In the FAST Trial, it took 4 months or longer before there was a 50% success rate in achieving quiescence. The primary outcome was achieving quiescence at 6 months. Therefore, 4–6 months is the time period needed to see if an antimetabolite is effective in controlling inflammation.[52] This may require the use of high-dose corticosteroids in the interim to maintain control of the inflammation. This trend drives an increase in TNF inhibitor use since, as a class, they are faster in achieving treatment success.[54]

What baseline testing is needed prior to starting conventional immunosuppressive agents? First, obtain laboratory testing to assess for potential contraindications. For antimetabolites, check for hepatitis B and C. Clinically assess for hypertension or serologically for renal disease when considering cyclosporine and tacrolimus use. Address if pregnancy could be present or is contemplated in the next few months. For azathioprine,

JAYPEE BROTHERS

check thiopurine methyltransferase levels to assess for a homozygous deficiency, which could lead to decreased drug metabolization and aplastic anemia or leukopenia. Unfortunately, this test is not widely available across the globe. In addition to the above, baseline testing should also include liver enzymes and a CBC.

Regarding pregnancy, there is a review by the European League Against Rheumatism on the use of immunosuppressive therapy.[55] Many of our patients are reproductive-age women. Looking at the rates of intermediate, posterior, and panuveitis alone, 60–65% are female. If starting immunosuppressive therapy, avoidance of pregnancy through contraception or complete abstinence should be discussed. Both the United States Food and Drug Administration (FDA) and the European Medicines Agency require labels that warn against using immunosuppressive therapy in pregnancy. Some agents, such as methotrexate, mycophenolate, and alkylators, are frankly contraindicated. Methotrexate has been used off-label to induce abortions, leading to fetal loss or malformations. Even males have been advised to wait 3 months after stopping antimetabolites before impregnating their partner. Cyclosporine and tacrolimus have not been associated with excess malformations. Tacrolimus does have a Food and Drug Administration (FDA) warning label, but there was a transplant study registry that showed no excess malformations. Azathioprine also has not been found to be associated with malformations or adverse pregnancy outcomes. Although, the label still warns against use in pregnancy. Therefore, these would be options if a patient were pregnant and needed more treatment than corticosteroids alone. Corticosteroids have traditionally been thought to be a safe approach during pregnancy. However, there are suggestions that there is a higher risk of preterm birth at doses even in the 5–10 mg range. There is also an increased risk of maternal infection. There is a placental enzyme that partially protects the fetus against the effects of corticosteroids. All Janus kinase (JAK) inhibitors should be avoided in pregnancy, as there is insufficient data to evaluate them. There was some concern about reproductive issues in men taking JAK inhibitors, which did not reach statistical significance in more recent studies. Other agents considered relatively safe during pregnancy, although less commonly used for the treatment of uveitis, include sulfasalazine, hydroxychloroquine, colchicine, and intravenous immunoglobulins. Anti-TNF inhibitors also appear to have a generally favorable safety profile in this setting. Although crude analyses initially suggested a higher rate of congenital malformations, this association was not observed after adjustment for disease severity and other methodological factors. Sulfasalazine has also been reported to affect male fertility by reducing sperm count and motility; however, this effect is reversible and may decrease the likelihood of conception during treatment.

For the longitudinal follow-up of these patients, at each visit, it is important to query about treatment side effects and to encourage patients to mention even minor things. Additionally, it is ideal to follow the weight if a patient is taking oral corticosteroids. This is especially important in children on oral corticosteroids, which is a treatment that should be limited due to many side effects, including short stature from early epiphyseal closure. Sometimes in Ethiopia, due to resource restrictions, we monitor height as well. Repeating laboratory studies to assess for changes in liver enzymes and a CBC should be conducted at least every 3 months, or more frequently if there are abnormalities or an immunosuppressive agent was recently started. Consider magnesium testing for patients taking calcineurin inhibitors. The paper by Jabs et al. provides a detailed framework for clinical and laboratory monitoring tailored to each immunosuppressive agent. In clinical practice, laboratory testing is commonly performed at baseline, at 1 month, at 2 months, and subsequently every three months. In patients with stable and consistently normal laboratory results for more than one year, some clinicians may extend the monitoring interval to every six months.

Once a successful, suppressive regimen is established at the lowest dose possible, treatment should continue for at least 2 years of quiescence or for longer. We have little data on the rates of remission of all of the uveitides, with most of the literature focusing on intermediate uveitis and chronic anterior uveitis. Even in these conditions, the remission rate is not high and is similarly low for anterior scleritis. Dose adjustments may be required due to side effects or switching agents if a drug is not well tolerated. During maintenance therapy, occasional flares may occur related to immune stimulation, such as trauma, immunization, and illness. The minimal suppressive dose may need to be changed under these circumstances, whether that is a temporary discontinuation for an infection to heal or increased dosing for recurrent flares. A major flare should be treated with a full reinduction of oral corticosteroids at 1 mg/kg of ideal body weight, and a smaller flare with a partial reinduction. A rule of thumb is to double the corticosteroid dose at which the patient was last quiet if a flare occurs during a taper.

JAYPEE BROTHERS

The MUST trial established systemic therapy as the first-line maintenance therapy for posterior pole involving uveitis.[51] Not only was it non-inferior to long-acting intraocular implants, but came with a lower cost. The 7-year results show the visual acuity in the cohort receiving systemic immunosuppression was superior to those receiving a long-acting corticosteroid implant. The FAST trial has well-established methotrexate as the first-line agent unless there are systemic or lifestyle contraindications.[52] The data from the SITE study mirror those of the MUST trial 7-year results, where there was an initial improvement in vision with induction and then stability of improvement in most uveitides over time.

A commonly posed question is: What is the safety of systemic immunosuppression? The SITE Study looked at the long-term incidence of death and cancer.[50] Given 10 years of median follow-up time, methotrexate, azathioprine, mycophenolate, cyclosporine, and TNF inhibitors are safe with respect to both mortality and cancer. Furthermore, data from the MUST papers argue well for short-term safety, even in the follow-up phase of the study.[51] More infections requiring treatment occurred in the systemic arm, but this trend may have been the result of treatment bias.

In short, we want to choose the treatment that achieves clinical quiescence and avoids complications as much as possible. Complications can be managed if there is no better treatment option given patient-specific limitations. However, use of systemic immunosuppression has been associated with the development of fewer intraocular complications, such as cataract and elevated intraocular pressures.[56] While some complications are reversible with surgery, treatment of macular edema with additional local corticosteroid therapies as adjunctive treatments can improve vision based on clinical observation studies. However, the clinician must be patient and give conventional immunosuppressive drugs the appropriate time to reach full effect.

In summary, systemic immunosuppression should be considered the first-line treatment. Methotrexate is a reasonable first choice worldwide, and while not as effective, it is safer than using high-dose oral corticosteroids. With monitoring and dose adjustments, conventional immunosuppressants can effectively treat ocular inflammation.[50,51,56,57] Usage requires a level of skill and attention by the physician for monitoring and cooperation by the patient. Carefully consider pregnancy and monitoring for side effects on an individual basis. Despite a several-month lag to attain full efficacy, the best corrected visual acuity can be maintained, and ocular complications can be prevented with use. With more treatment options available after approval of biologic medications, there are additional treatment strategies at our disposal, as described in the next case.

NONINFECTIOUS UVEITIS MANAGED WITH BIOLOGIC THERAPY

Case Presentation

Personal Data

A 16-year-old female developed decreased vision in the left eye more than the right eye for 2 weeks.

History of Present Illness

The change in vision was accompanied by flashes in both eyes. Her prior ophthalmic history was limited to astigmatism in both eyes and hyperopia in the right eye and myopia in the left eye. Her past medical history was remarkable for acute T-cell lymphoblastic leukemia, for which she was on chemotherapy for the past 6 months. She also had a history of bilateral hip osteonecrosis related to systemic corticosteroid use.

Physical Examination

The visual acuity was 20/30 in both eyes, and 1+ cells were seen in the anterior vitreous of the left eye. The fundus exam showed temporal macular hemorrhages in the right eye and multiple retinal infiltrates peripherally with adjacent hemorrhages in both eyes **(Figs. 12A and B)**.

Slit Lamp Examination

The slit lamp examination is summarized in **Table 9**.

Ancillary Testing

Fundus autofluorescence images showed hyper-autofluorescence in the areas of exudates and hypoautofluorescence in areas of hemorrhage **(Figs. 13A and B)**. Fluorescein angiography showed early and late blocking in areas of retinal hemorrhage and late leakage in areas with exudation in the periphery with adjacent non-perfusion **(Figs. 14 and 15)**. OCT scans of the retina showed outer retinal damage with thinning and loss of the retinal contour with a preretinal membrane and subretinal fluid in the right eye. The OCT scans of the macula in the left eye showed temporal retinal thinning, disorganization,

JAYPEE BROTHERS

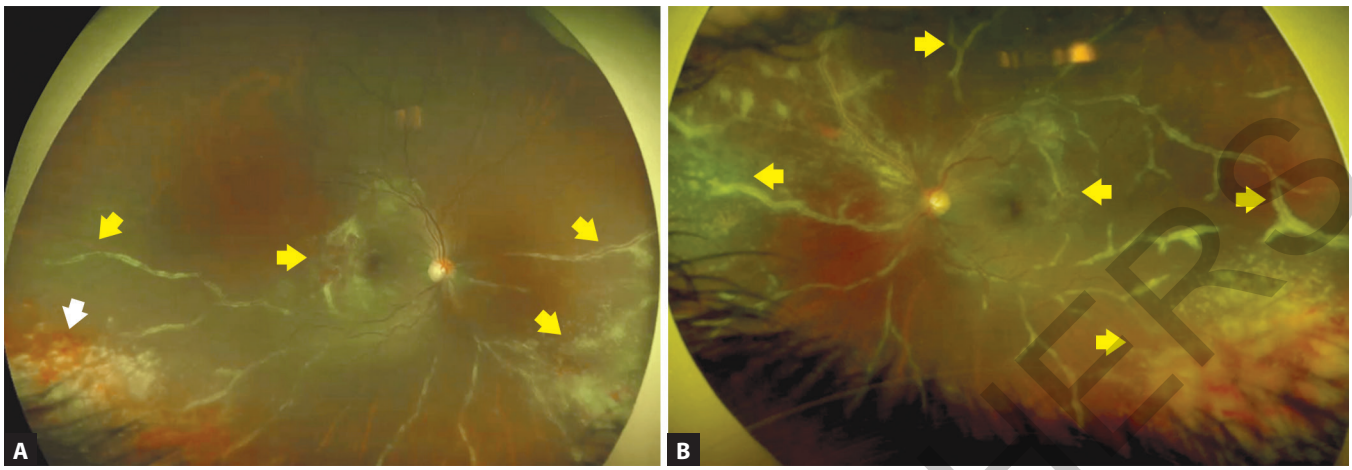

Figs. 12A and B: Color fundus photos of both eyes showing exudates surrounding the vessels with surrounding hemorrhages (yellow arrows).
Source: Uveitis Course - Grand Rounds 16. International Uveitis Study Group (IUSG). June 14, 2025. Available at: https://youtu.be/2UVTU7oztTc?si=y7tNEsxDMokFr6uw.

TABLE 9: Slit lamp examination of a patient having noninfectious uveitis managed with biologic therapy.

OD	*Parameter*	*OS*
20/30	BCVA	20/30-2
16 mm Hg	IOP	20 mm Hg
White and quiet	Conjunctiva	White and quiet
Clear	Cornea	Clear
Deep and quiet	Anterior chamber	Deep and quiet
Round and reactive	Iris	Round and reactive
Clear	Lens	Clear
Normal	Vitreous	1+ cell
Hemorrhages temporal to the macula. Multiple retinal infiltrates surrounding the vessels into the periphery with adjacent hemorrhages	Fundus	Infiltrates along blood vessels with surrounding hemorrhages in the periphery

(BCVA: best corrected visual acuity; IOP: intraocular pressure)

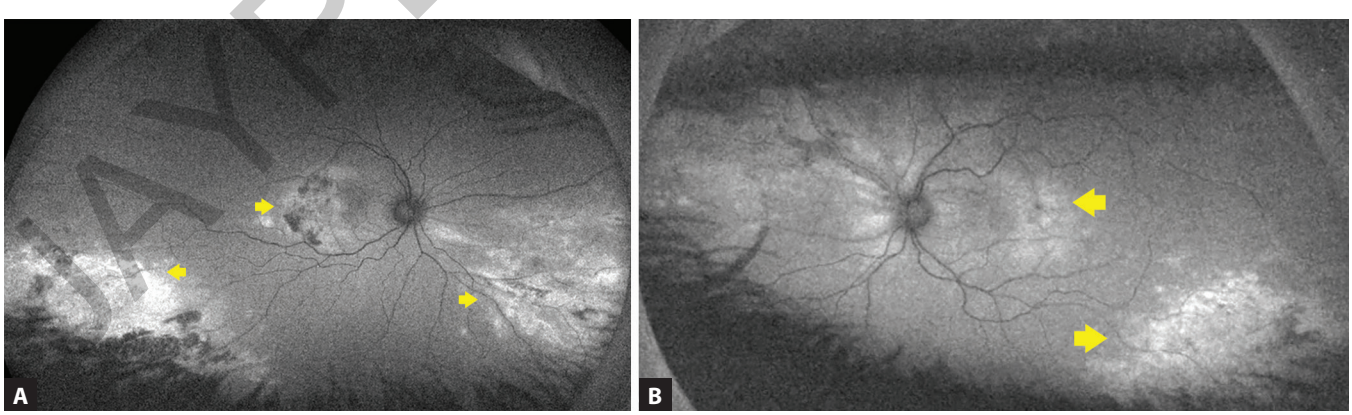

Figs. 13A and B: Fundus autofluorescence images of both eyes showing hyperautofluorescence in the areas of exudates (yellow arrows) and hypoautofluorescence in areas of hemorrhage.
Source: Uveitis Course - Grand Rounds 16. International Uveitis Study Group (IUSG). June 14, 2025. Available at: https://youtu.be/2UVTU7oztTc?si=y7tNEsxDMokFr6uw.

JAYPEE BROTHERS

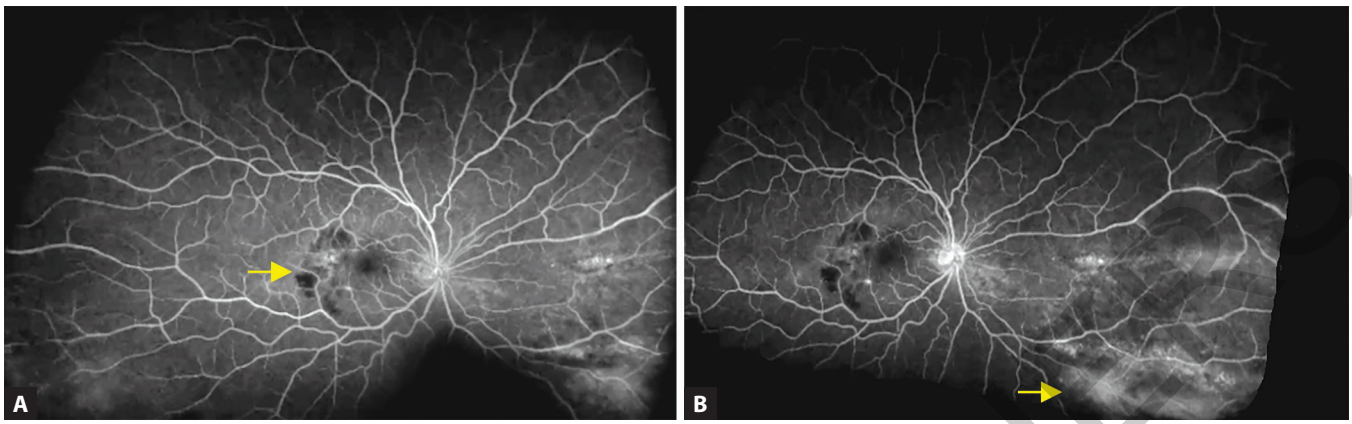

Figs. 14A and B: Fluorescein angiography of the right eye showing early and late blocking in areas of retinal hemorrhage (yellow arrow, left) and in the left eye, late leakage in areas with exudation in the periphery (yellow arrow, right).
Source: Uveitis Course - Grand Rounds 16. International Uveitis Study Group (IUSG). June 14, 2025. Available at: https://youtu.be/2UVTU7oztTc?si=y7tNEsxDMokFr6uw.



Fig. 15: Fluorescein angiography of the left eye showing peripheral capillary nonperfusion in areas adjacent to vessels with exudation and late leakage (yellow arrow).
Source: Uveitis Course - Grand Rounds 16. International Uveitis Study Group (IUSG). June 14, 2025. Available at: https://youtu.be/2UVTU7oztTc?si=y7tNEsxDMokFr6uw.

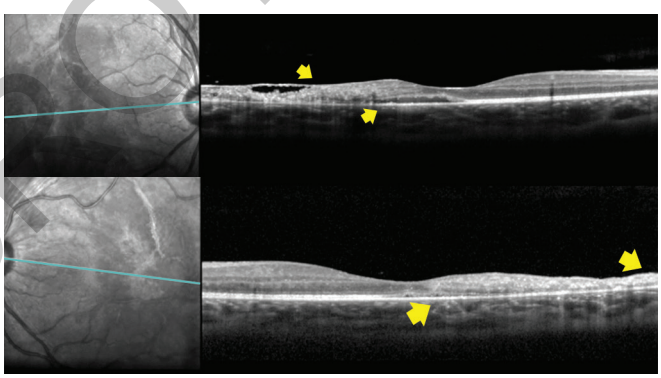

Fig. 16: An optical coherence tomography (OCT) scan of the retina of the right eye (above) showing outer retinal damage with loss of retinal structure and epiretinal membrane formation (top yellow arrow). Subretinal fluid was also present (bottom yellow arrow). In the left eye, temporal retinal thinning with fluid separation in the central fovea is denoted by yellow arrows (bottom image).
Source: Uveitis Course - Grand Rounds 16. International Uveitis Study Group (IUSG). June 14, 2025. Available at: https://youtu.be/2UVTU7oztTc?si=y7tNEsxDMokFr6uw.

and a mild, shallow fluid separation in the central fovea **(Fig. 16)**.

Uveitis Workup

At the top of the differential diagnosis were infectious etiologies, namely *Cytomegalovirus* (CMV) retinitis, versus inflammatory etiologies, such as Behçet's disease-associated uveitis. Other diagnoses that were considered were acute retinal necrosis, progressive outer retinal necrosis, syphilitic retinitis, or leukemic retinopathy. Laboratory testing showed leukopenia with a very low CD4 count. Additional testing was negative and included HLA-B27, B51, and A29. There were also negative results for the QuantiFERON, syphilis serologies, HIV, toxoplasma antibodies, and PCR for varicella zoster and herpes simplex. She was serologically positive for CMV immunoglobulin G (IgG) and immunoglobulin M (IgM) antibodies, with CMV deoxyribonucleic acid (DNA) also detected. An anterior chamber paracentesis and injection of intravitreal foscarnet in both eyes was performed. A positive PCR result for CMV in the aqueous sample confirmed the diagnosis of CMV retinitis.

JAYPEE BROTHERS

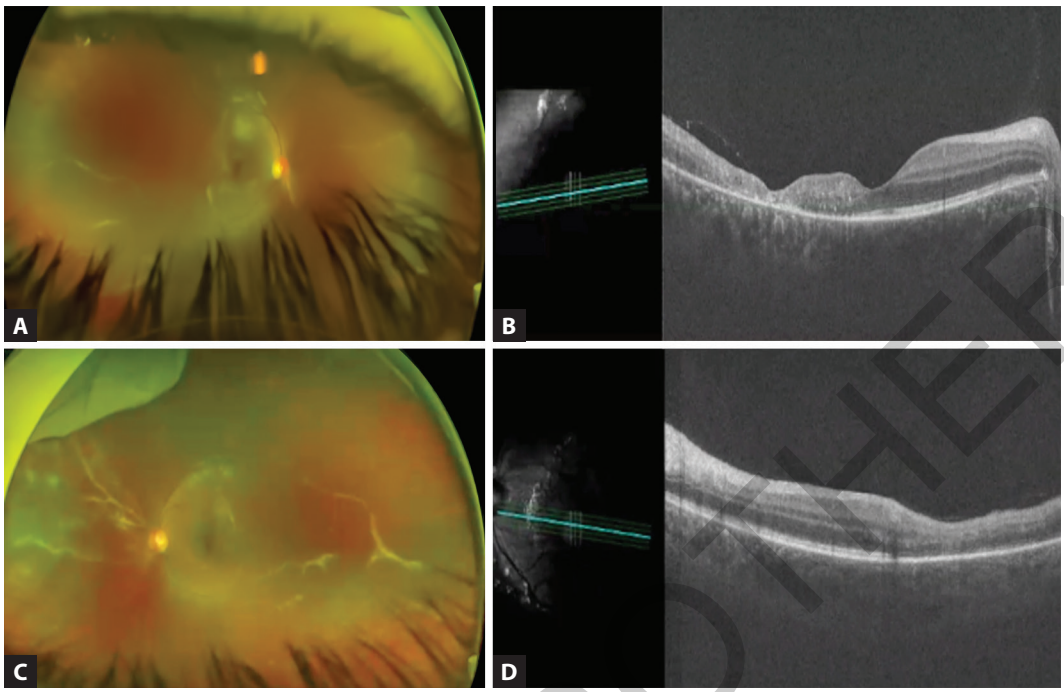

Figs. 17A to D: Color fundus photos of the right (top left) and left eye (bottom left) showing decreased retinal infiltrates along the vasculature. Optical coherence tomography (OCT) scans of the right eye (top right) show loss of retinal contour with atrophy nasal to the macula, with resolution of the subretinal fluid. An OCT scan of the left eye (bottom right) shows atrophy temporal to the macula without subretinal fluid after 2 weeks of treatment.
Source: Uveitis Course - Grand Rounds 16. International Uveitis Study Group (IUSG). June 14, 2025. Available at: https://youtu.be/2UVTU7oztTc?si=y7tNEsxDMokFr6uw.

Initial Treatment

Intravitreal foscarnet injections were administered in both eyes every 3 days. Only two injections were required in total, as intravenous ganciclovir 5 mg/kg every 12 hours was initiated at the same time. The treatment was then changed to oral valganciclovir 900 mg twice a day prior to discharge from the hospital.

Follow-up

Two weeks later, there was a decrease in the retinal infiltrates along the vasculature with an absence of subretinal fluid in both eyes **(Figs. 17A to D)**.

After 6 weeks, the patient's vision returned to 20/20 in both eyes, and valganciclovir 900 mg twice a day was continued. On posterior pole examination, the retinal infiltrates were nearly resolved and replaced with scarring. By 10 weeks after presentation, there was scarring in the periphery with resolution of all retinal infiltrates **(Fig. 18)**.

However, 3 months later, the patient experienced blurry vision in the left eye for 1 week, leading to a repeated evaluation in the clinic. She had discontinued valganciclovir after completing her course of chemotherapy. The visual acuity in the right eye was 20/20 and 20/30 in the left eye. Slit lamp examination showed 0.5+ cells in the anterior

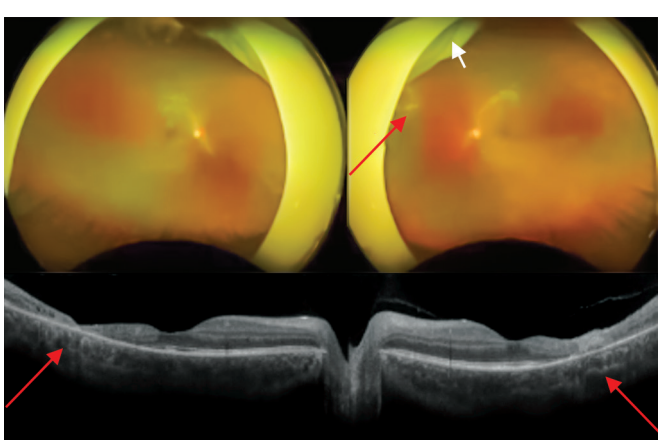

Fig. 18: Color fundus photos of both eyes after 10 weeks of treatment (top) showing no retinal exudates and peripheral scarring (red arrow). Optical coherence tomography (OCT) scans of the right (left bottom) and left eyes (right bottom) show continued resolution of subretinal fluid and retinal atrophy (red arrows).
Source: Uveitis Course - Grand Rounds 16. International Uveitis Study Group (IUSG). June 14, 2025. Available at: https://youtu.be/2UVTU7oztTc?si=y7tNEsxDMokFr6uw.

JAYPEE BROTHERS

vitreous in both eyes. A dilated fundus exam showed no retinal infiltrates, only scarring in the right eye. There was also a lack of infiltrates in the left eye with inactive scars. However, there were new pink elevated areas temporal to the macula from subretinal fluid **(Fig. 19)**.

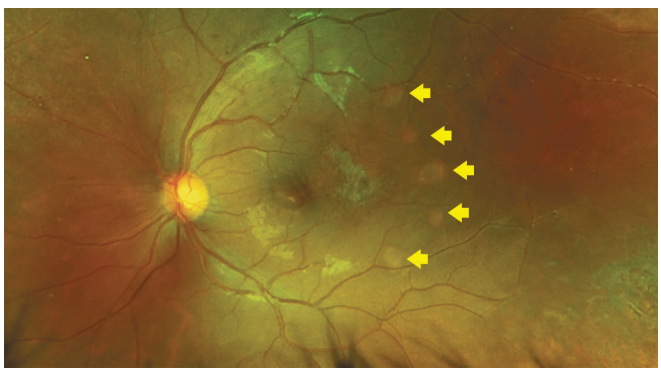

Fig. 19: A color fundus photograph of the left macula showing areas of subretinal fluid temporally (yellow arrows).
Source: Uveitis Course - Grand Rounds 16. International Uveitis Study Group (IUSG). June 14, 2025. Available at: https://youtu.be/2UVTU7oztTc?si=y7tNEsxDMokFr6uw.

Fluorescein angiography was repeated in both eyes and showed late leakage of the optic discs and small vessel capillary leakage in the peripheral retinas. Additionally, hyperfluorescence of the subretinal fluid pockets and capillary non-perfusion in the periphery were noted **(Figs. 20A and B)**. OCT scans of the retina showed intraretinal fluid in both eyes with subretinal fluid only in the left eye **(Figs. 21A and B)**.

Laboratory testing was repeated and showed both the white blood cell count and the CD4+ count had increased to the normal range, and no CMV DNA was detected in the serum. The differential diagnosis had changed, given the new clinical picture to include reactivation of CMV retinitis, immune recovery uveitis (IRU), and leukemic retinopathy. With normal white blood cell and CD4+

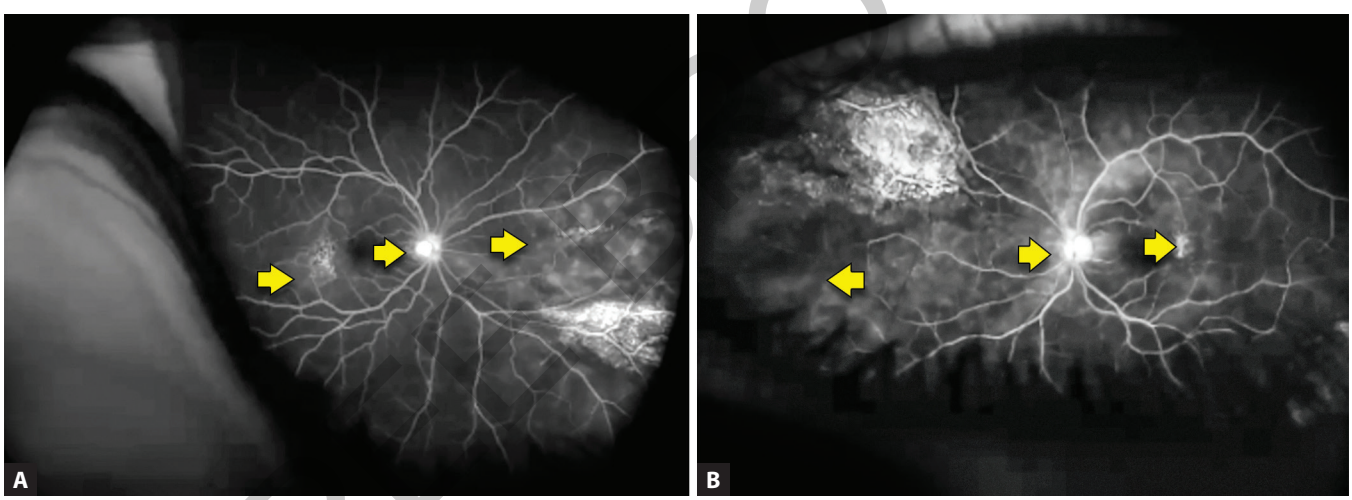

Figs. 20A and B: Fluorescein angiography images of the right (left) and left eye (right) that show bilateral, late optic disc leakage (center arrows). In the right eye, there is capillary leakage (yellow arrows). In the left eye, there is capillary non-perfusion (left arrow) and hyperfluorescence of the subretinal fluid pockets temporal to the macula (right arrow).
Source: Uveitis Course - Grand Rounds 16. International Uveitis Study Group (IUSG). June 14, 2025. Available at: https://youtu.be/2UVTU7oztTc?si=y7tNEsxDMokFr6uw.

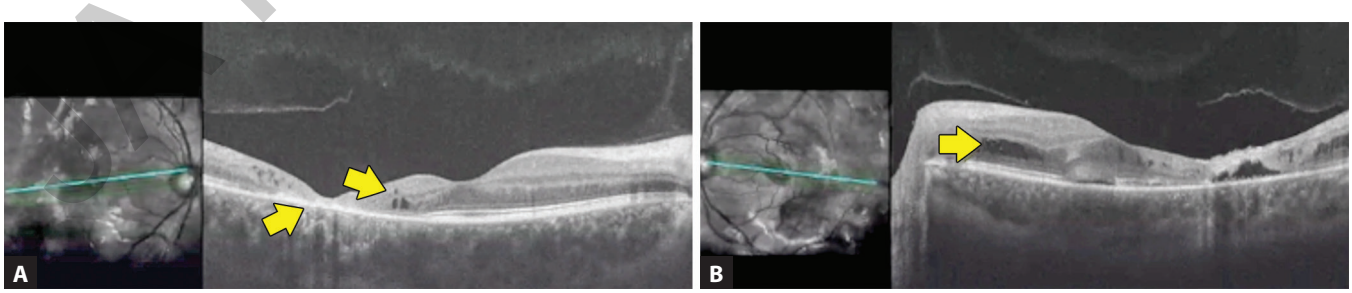

Figs. 21A and B: Optical coherence tomography (OCT) scans of the right eye (left) and the left eye (right) show areas of new intraretinal edema bilaterally (yellow arrows).
Source: Uveitis Course - Grand Rounds 16. International Uveitis Study Group (IUSG). June 14, 2025. Available at: https://youtu.be/2UVTU7oztTc?si=y7tNEsxDMokFr6uw.

counts, leukemic retinopathy and active retinitis from CMV were much less likely. The patient was diagnosed with IRU, and valganciclovir 900 mg twice a day was restarted. While systemic corticosteroids are the gold standard treatment for IRU, given the history of osteonecrosis, this class of medication was contraindicated. A better choice was a biologic agent: Either a TNF inhibitor or an IL-6 inhibitor. The patient was admitted and given 1 g of intravenous methylprednisolone for 2 days with transition to a rapid oral corticosteroid taper while concurrently starting tocilizumab 8 mg/kg intravenously per month.

After three cycles of tocilizumab, there was a marked decrease in leakage in the periphery on fluorescein angiography in both eyes, with an absence of subretinal fluid in the right eye. After seven infusions, the leakage had almost completely resolved and the vision in the right eye remained at 20/25, but improved to 20/20 in the left eye.

While IRU has been reported in patients with acquired immunodeficiency syndrome (AIDS) after the start of combination antiretroviral therapy, there are nowadays more cases of IRU seen in patients on chemotherapy and with non-AIDS immunodeficiencies. IRU is a late sequelae of CMV retinitis, with the greatest risk factor being increasing CD4+ cell counts to a level of ≥100 cells/μL or a decreasing number of human immunodeficiency virus copies.[58-60]

The first-line treatment for cystoid or intraretinal edema associated with IRU is corticosteroid therapy: topically or systemically.[61,62] In the literature, intravitreal injection of aflibercept has also been attempted with a third-line option of systemic IL-6 inhibition. The rationale supporting IL-6 inhibition in uveitic macular edema secondary to non-infectious uveitis is rooted in the STOP-Uveitis Study conducted by Dr. Yasir Sepah.[63] The findings of the study showed there was a significant reduction of cystoid macular edema at 6 months after the initiation of tocilizumab infusions.

In summary, CMV retinitis can occur in patients with an immune deficiency, and IRU arises with recovery of the immune system as CD4+ cell counts normalize. IL-6 receptor antagonists, such as tocilizumab, offer a therapeutic approach for IRU.

Discussion

This case illustrates several different points. The diagnosis of CMV retinitis and IRU was straightforward. The challenge lay in how to treat the patient based on available options, given the absolute contraindication to oral corticosteroids with the history of osteonecrosis. In our initial work with IRU, we published that using a local corticosteroid injection is possible.[64] However, that was not appropriate for this patient because of her very young age and the higher risk of developing ocular hypertension and cataracts. The patient's parents also did not want to proceed with a periocular or intravitreal corticosteroid injection. As we know from the literature, the use of immunomodulatory therapies such as mycophenolate, methotrexate, and cyclosporine does not have a strong record of treating uveitic macular edema. Since the macular edema was significant and acute, we focused on starting a biologic agent. Adalimumab is the only currently approved biologic medication for the treatment of non-infectious intermediate, posterior, and panuveitis based on the efficacy shown in the VISUAL Studies.[65,66] However, resolution of uveitic macular edema with the use of adalimumab can take months.

What about another anti-TNF inhibitor, infliximab? While infliximab can decrease small vessel leakage, there is not as much in the literature on the effect on macular edema. Given the patient's comorbidities and the above findings on macular edema resolution with TNF inhibitors, we chose to treat with tocilizumab. The STOP-Uveitis study and several studies from both Spain and France support role of IL-6 inhibition in treating uveitis.[63,67,68] Even intravitreal IL-6 inhibitors have been investigated for the treatment of uveitis and macular edema.[69] Systemic IL-6 inhibitor therapy has also shown significant benefits in treating uveitic macular edema with an acceptable safety profile.[68]

What about other biologic agents? Again, the only biologic that has been approved in the United States for the treatment of non-infectious uveitis is adalimumab. However, uveitis specialists often employ other agents off-label, including IL-17, IL-1, and IL-23 inhibitors. We also have prescribed JAK inhibitors, such as tofacitinib, but studies have shown variable efficacy of this drug class in controlling intraocular inflammation. We learned from the HUMBOLDT study that the JAK inhibitor, filgotinib, showed significant ability to control both macular edema and uveitis.[70] Unfortunately, the trial was terminated for business reasons. Fortunately, other trials are assessing the efficacy of another JAK inhibitor, brepocitinib, which is a JAK1-tyrosine kinase 2 inhibitor with promising phase 2 results in the NEPTUNE study. Currently, the phase 3 CLARITY trial is ongoing in the United States, Europe, South America, and Asia.

JAYPEE BROTHERS

Case Studies in UVEITIS

Real Cases & Practical Insights

Salient Features

- Covers over 50 real-life uveitis cases from international experts
- Highlights the importance of practical and step-by-step clinical reasoning with diagnostic pearls
- Emphasizes on geographic, immunological, and etiological diversity
- Moreover, it covers infectious, noninfectious, and masquerade syndromes
- Includes high-quality images, laboratory workups, and treatment follow-up
- Ideal for ophthalmologists, immunologists, and trainees in uveitis.

This volume has been developed under the auspices of the International Uveitis Study Group (IUSG), an esteemed body of global experts in ocular inflammation. The editors represent diverse regions and subspecialties within ophthalmology, bringing together a wealth of clinical, academic, and research experience.

Alejandra de-la-Torre MD PhD is a member of the Education Committee for the International Uveitis Study Group and Chair of the IUSG Ambassadors Program. She is a leading authority on ocular toxoplasmosis and its immunopathogenic mechanisms, with significant contributions to the understanding of regional variations in this disease.

Meghan Berkenstock MD is a member of the Education Committee for the International Uveitis Study Group and is recognized for her research in drug-induced uveitis and ocular adverse events with the use of immunotherapies and targeted cancer agents.

Germán Mejía-Salgado MD is a research assistant in the Immunology Unit at the School of Medicine and Health Sciences, Universidad del Rosario, and made significant contributions to the development of the chapters and the editorial work of this book.

John H Kempen MD MPH MHS PhD is Director of the Education Committee for the International Uveitis Study Group. He is globally recognized for his research in epidemiology/the burden of disease, and also for clinically oriented research, clinical care and education in ocular inflammatory diseases.

Reema Bansal MD PhD FAMS is a Professor of Uveitis and Vitreo-Retinal Surgery in PGIMER, Chandigarh, India, and is a member of the Education Committee for the International Uveitis Study Group (IUSG).

Vishali Gupta MD is a world-renowned expert in intraocular inflammation and infections. She chairs the Vitreoretina and Uvea Services at PGI Chandigarh, India, and currently serves as President of the International Uveitis Study Group (IUSG).

Shelving Recommendation
OPHTHALMOLOGY

ISBN 978-93-6616-023-8



Buy from ejaypee



JAYPEE BROTHERS