ite www.ejaypee.com, for detailed information on pediatric books, visit our website www.ejaypee.com, for detailed information on pediatric books, visit our website www.ejaypee.com,

2nd Edition

IAPS Textbook of PEDIATRIC SURGERY



Complimentary Online 11 Videos (Duration 30 Minutes)

Editors
Ramesh Babu
Sumitra Kumar Biswas
Vikesh Agrawal

Co-Editors
Rajeev G Redkar
Prakash Agarwal

Forewords
Subir K Chatterjee
VR Ravikumar

JAYPEE

Contents

SECTION 1: Basic Science

1. **Applied Anatomy in Pediatric Surgery.....3**
   Sumitra Kumar Biswas, Vikesh Agrawal
2. **Applied Physiology, SIRS and MODS in a Surgical Child..... 22**
   Arvind Sinha, Revathy Menon
3. **Airway Management, Mechanical Ventilation, and Extracorporeal Membrane Oxygenation 36**
   Samir Shah, Daniel Nigri, Madeline Lebar
4. **Perioperative Fluid Therapy..... 54**
   Abirami Krithiga
5. **Perioperative Blood Component Therapy 66**
   Tanmay Motiwala, Aruna Abhyankar
6. **Venous Access in Children..... 76**
   MM Zameer, Prakash Agarwal
7. **Lasers in Pediatric Surgery..... 83**
   Rahul Kumar Gupta, Subhasis Saha
8. **Pediatric Anesthesia and Pain Management..... 91**
   Pradnya Sawant, Mridul Dua
9. **Applied Pediatric Radiology 105**
   Nitesh Kumar Sharma, Simmi K Ratan, Sujoy Neogi, Vikesh Agrawal
10. **Applied Pediatric Nuclear Medicine 140**
    Anand Alladi, Mamatha B
11. **Ethical Considerations in Pediatric Surgery 154**
    Yogesh Kumar Sarin, Raghav Narang
12. **Consent and Medicolegal Issues in Pediatric Surgery 162**
    Nilesh Tank, Harsh Atul Hirani
13. **Transition of Care from Pediatric to Adolescent..... 172**
    Vipul Upadhyay
14. **Research Methodology and Basic Statistics 175**
    Prabudh Goel, Ramesh Babu, Prativa Choudhury
15. **Artificial Intelligence in Pediatric Surgery 190**
    Vinayak S Rengan, Vikesh Agrawal, Pradeep Kumar Gupta

SECTION 2: Trauma

16. **Triage, Resuscitation, and Damage Control Surgery..... 203**
    Satya Sree Balija, Enono Yhoshu, Mahendra Kumar Jangid
17. **Head Injury and Cervical Spine Injury..... 215**
    Jitin Bajaj, Yad Ram Yadav, Sumitra Kumar Biswas
18. **Thoracic Trauma..... 225**
    Dasmit Singh Khokar, Venkatesh KL
19. **Abdominal Trauma 238**
    Bikasha Bihary Tripathy, Aditya Arvind Manekar, Dasmit Singh Khokar
20. **Genitourinary Trauma and Sexual Abuse 249**
    Minakshi Nalbale-Bhosale, Sujay Pal

SECTION 3: Abdomen

21. **Neonatal Ascites** 267
Sukrit Singh Shah, Subhasis Roy Choudhary

22. **Abdominal Wall Defects** 274
Manjusha Sailukar, Devendra Vinayak Taide

23. **Inguinal Hernia and Hydrocele** 283
Sarita Bhagwat, Ravindra Ramadwar

SECTION 4: Esophagus and Gastrointestinal Tract

24. **Esophageal Atresia** 297
Ravi P Kanojia, Nitin J Peters, Shivani Dogra, Subhasis Roy Choudhary

25. **Achalasia Cardia and Other Motility Disorders** 308
Vijai Datta Upadhyaya, Pujana Kanneganti

26. **Esophageal Replacement: Gastric Pull-up and Gastric Tubes** 318
Rajendra Saoji

27. **Colonic and Jejunal Interposition for Esophageal Replacement in Children** 329
Shilpa Sharma, Devendra K Gupta

28. **Gastroesophageal Reflux** 337
Prakash Agarwal, Sandeep Motiwale

29. **Infantile Hypertrophic Pyloric Stenosis** 348
Himanshu Acharya, Rajpal Singh Sisodiya, Vinayakumar Shelke

30. **Jejunoileal Atresia** 357
Paras R Kothari, Abhaya R Gupta

31. **Disorders of Gastrointestinal Rotation and Fixation** 363
Kirtikumar J Rathod, Ayushi Vig

32. **Meconium Ileus and Related Diseases** 374
Monika Bawa, Shailesh Solanki

33. **Gastrointestinal Tract Duplication and Cysts** 384
Ajay Naik, Dhananjay D Vaze

34. **Vitellointestinal Duct and Urachal Abnormalities** 393
Subhasis Saha, Kuntal Bhaumik

35. **Intussusception** 401
Anant Bangar, Surendra Singh

36. **Gastrointestinal Polyps** 410
Sunita Singh, Intezar Ahmed

37. **Appendicitis** 422
Amar Shah, HPS Miglani

38. **Necrotizing Enterocolitis** 439
Rakesh Shah

39. **Anorectal Malformations** 446
Hemanshi Shah, Charu Sharma, Vikesh Agrawal

40. **Hirschsprung Disease** 466
Kanishka Das, Suravi Mohanty

41. **Inflammatory Bowel Disease** 480
Mansha Jiwane, Ashish Jiwane

42. **Intestinal Stoma and its Care** 497
Jiledar Rawat, Gurmeet Singh

43. **Pediatric and Adolescent Obesity** 510
Mohit Bhandari, Susmit Kosta, Manoj Reddy, Winni Mathur

44. **Intestinal Failure and Rehabilitation** 521
Parshotam Gera, Zubin Grover

SECTION 5: Liver, Pancreas, and Spleen

45. **Cholelithiasis** 535
Jai Kumar Mahajan

46. **Choledochal Cyst** 548
Ankur Mandelia, Veereshwar Bhatnagar

47. **Biliary Atresia** 561
Rajeev G Redkar

48. **Extrahepatic Portal Hypertension** 569
Basant Kumar, Rajendra Saoji

49. Pediatric Liver Transplantation 585
Ashwin Rammohan, Priya Ramachandran, Mohamed Rela

50. Pancreatic Disorders 596
Sanjay Rao, Prakash Agarwal

51. Diseases of Spleen 614
Rakesh Joshi, Jaishri Ramji

SECTION 6: Thorax

52. Structural Anomalies of the Airways 629
Rajesh Nathani, Sanjay Rao

53. Airway Foreign Bodies 640
Muneer Abas Malik

54. Empyema and Pleural Infections in Children 652
Rasiklal S Shah, Suyodhan Reddy, Manika Boipai

55. Congenital Diaphragmatic Hernia 661
Sandesh V Parelkar, Beejal Sanghvi, Rahul Kumar Gupta

56. Congenital Bronchopulmonary Malformations 674
Arun Kumar L, Sundeep Kisku, Manoj Joshi

57. Deformities of the Chest Wall 688
Bipin Puri, Raju Vaishya, Sanat Kumar Khanna

SECTION 7: Genitourinary Tract

58. Renal Anomalies of Development, Number, and Fusion 699
Arun Prasad D, Swathi Chigicherla

59. Pelviureteric Junction Obstruction 711
Heera T, Ramesh Babu, Rajamani G, Raghul M

60. Duplication Anomalies of Upper Urinary Tract 725
Shandip Kumar Sinha, Meera Luthra

61. Urinary Tract Infections and Vesicoureteric Reflux 736
VVS Chandrasekharam

62. Primary Obstructive Megaureter and Ureterocele 748
Velmurugan Rajendran, V Vignesh Rajendran

63. Posterior Urethral Valves 760
Mehak Sehgal, Minu Bajpai

64. Bladder–Bowel Dysfunction 769
Poonam Guha Vaze, Rupa Banerjee, Saibal Chakraborty

65. Neurogenic Bladder 782
Ravi Kishore Barla SS, Sudipta Sen, Jeenepalli Srinivasa Kishore

66. Exstrophy-Epispadias Complex 791
SN Kureel, Rakesh Joshi, Archika Gupta, Bharati Kulkarni

67. Hypospadias 813
Shivaji Mane, Dasmit Singh Khokar

68. Urethral Duplication 831
Vikesh Agrawal, Heera T

69. Testicular Torsion 840
Anwesa Chakraborty, Vidya Bangalore Umashankar

70. Undescended Testis 847
Anjan Kumar Dhua, Rasiklal S Shah, Gali Divya

71. Phimosis and Related Disorders of Prepuce 866
Kumaravel Sambandan

72. Uterovaginal Anomalies 875
Pavai Arunachalam, Sudipta Sen, Harish Jayaram, Mainak Deb

73. Differences in Sex Development 888
Pradnya S Bendre, Arka Banerjee, Gayatri Munghate

74. **Prune Belly Syndrome** 909
Lakshmi Sundararajan, Abraham Cherian

75. **Urolithiasis** 915
Ramesh Babu, Senthil Ganesh Kamaraj

76. **Pediatric Renal Transplantation** 928
Shubha AM, Vidyadhar Mali

77. **Urinary Diversion** 945
Aniruddh Deshpande, Bandar Alsahn, Ashish Jiwane

78. **Office Pediatric Urology** 962
Deepak Goel, Roshan Chanchalani

SECTION 8: Tumors

79. **Lymphovascular Anomalies** 973
R Madhu, S Jegadeesh

80. **Lymphadenopathy and Lymphomas in Children** 987
Ramesh Santhanakrishnan, Pooja Gujjal Chebbi, Manur Grurajachar Janaki

81. **Soft Tissue Sarcoma** 999
Archana Puri, Viji G, Vaibhav Garg

82. **Extracranial Germ Cell Tumors** 1019
Bibekanand Jindal, Swaminathan Keerthivasagam, Sagar Jawale

83. **Wilms' Tumor** 1035
Prabudh Goel, Anjan Kumar Dhua, Sandeep Agarwala

84. **Neuroblastoma** 1056
Sushmita Bhatnagar

85. **Hepatoblastoma and Other Liver Tumors** 1071
Sajid S Qureshi, Priya Mathews, Vasundhara Smriti, Monica Bhagat

86. **Gonadal Tumors** 1085
Veerabhadra Radhakrishna, Krishna Kumar Govindarajan

87. **Ovarian Pathology in Children** 1098
Prakash Agarwal

88. **Adrenal Tumors and Other Diseases** 1105
Rohit Kapoor, Himanshu Acharya, Ankur Mandelia

89. **Genitourinary Rhabdomyosarcoma** 1122
Monica Bhagat, Sajid S Qureshi, Raj Kishore Bagdi

90. **Chemotherapy in Pediatric Oncology** 1130
Dhaarani Jayaraman, Archika Gupta

91. **Radiotherapy** 1138
Shalini Mishra, Anjali K Pahuja, Richa

SECTION 9: Miscellaneous

92. **Neck Sinuses and Swellings** 1159
Kishore Panjwani, Nijagal Mutt JB, Rajpal Singh Sisodiya

93. **Torticollis and Fibromatosis Colli** 1170
Vijay K Kundal, Akshat Sudhanshu, Manjusha Sailukar

94. **Tropical Pediatric Surgery** 1178
Krishna Kumar Govindarajan, Yogesh Kumar Sarin, Aravindh Radhakrishnan

95. **Hydatid Cyst** 1191
Prema Menon, Kishore Panjwani

96. **Cleft Lip and Palate** 1203
Parthapratim Gupta

97. **Pediatric Thermal Burn and Postburn Deformities** 1219
Pawan Agarwal, Sujata Sarabahi

98. **Congenital Hand Anomalies** 1235
MR Thatte, Pawan Agarwal

99. Neural Tube Defects 1261
Anand Alladi, Santosh J Karmarkar, Mamatha B

100. Hydrocephalus 1277
Vaibhav Pandey, Ruchira Nandan, Gaurav Shandilya

101. Craniosynostosis 1291
Rajiv Agarwal, Devisha Agarwal

102. Patent Ductus Arteriosus, Pericardium and Vascular Rings 1298
Neville AG Solomon, Swaminathan V, Nithin Kapoor N

103. Pediatric Orthopedics 1318
P Gopinath Menon, V Rohit Gopinath, TR Ashok

104. Antenatal Diagnosis and Counseling 1336
Vikesh Agrawal, Ramesh Babu, Ravindra M Vora, Rekha Agrawal

105. Fetal Surgery: Recent Advances 1347
Mohan K Abraham, Vivek Krishnan

106. Pediatric Robotic Surgery 1358
Rohit Kapoor, Ankur Mandelia

107. Decision Making in Pediatric Surgery 1372
Vishesh Jain, Shivani Phugat, Prabudh Goel, Vikesh Agrawal

108. Evidence-based Pediatric Surgery 1387
Roshan Chanchalani, Prabudh Goel, Vikesh Agrawal

Index 1397

39

CHAPTER

Anorectal Malformations

Hemanshi Shah, Charu Sharma, Vikesh Agrawal

JAYPEE BROTHERS

INTRODUCTION

Anorectal malformations (ARMs) comprise a spectrum of disorders which are popularly known, albeit incorrectly, as imperforate anus. ARM has been described as long ago as the second century ad. In the 16th century, the pelvic anatomy of ARM was first described. Neonatal treatment in the form of local incision was tried before colostomy was introduced in the 18th century. Amussat described the first proctoplasty in 1835. With the availability of antibiotics and advanced anesthesia care, interest in ARM was renewed. Douglas Stephens meticulously studied the anatomy of individual variants which culminated in International classifications based on embryology. He also proposed a rational approach to various subtypes of malformations. After 1982, when De Vries and Alberto Pena described posterior sagittal anorectoplasty (PSARP), the management and prognosis of ARM has dramatically changed. Currently, the role of laparoscopic-assisted pull-through and its long-term results are under assessment.

INCIDENCE

Incidence of ARM is estimated to be 2–2.5 per 10,000 live births, with significant geographic variations. Various reports confirm high prevalence of ARM in Southeast Asian countries and low prevalence in European countries. Certain subtypes such as rectal atresia and pouch colon are predominantly seen in India.

It occurs more frequently in males (55–70%) than in females. Approximately 52% of lesions in boys are high and 48% are low, while in girls 65% are low and 35% are high. In males, the most common defect is rectourethral fistula followed by perineal fistula. In females, the common defect is anovestibular fistula followed by the cutaneous perineal fistula. Rectovaginal fistulas are very rare. Rectovesical fistulas occur in 10% and ARM without fistula occurs in 5%.

ETIOLOGY

The etiology of ARM is multifactorial. Genetic factors are considered to play a major role in ARM. Mutation of three important loci on the chromosome 7q39 (SHH, EN2, and HLXB9) is implicated. Recent studies suggest that Gli2 transcription factor is an important factor for the normal development of the hindgut. Chromosomal abnormalities are present in approximately 11% (Cuschieri and EUROCAT group), most frequently in patients with anal stenosis.

Exposure of drugs such as thalidomide, benzodiazepines (commonly lorazepam), adriamycin, and retinoic acid during fetal development increases the risk of ARM. Maternal infections with toxoplasmosis or cytomegalovirus have also been postulated as possible causes. Poor nutritional status, particularly folic acid deficiency, is implicated in the etiology of rectal atresia.

The incidence of ARM is more frequent in first-degree relatives. ARM occurs at the rate of 2–8% in patients with trisomy 21. The incidence is more in African Americans than Caucasians. Down syndrome is reported to be associated with ARM sans fistula.

EMBRYOLOGICAL BASIS

The primitive cloaca differentiates into the dorsal anorectum and the ventral urogenital sinus by the vertical urorectal septum (Tourneux fold). This partitioning is completed by two lateral folds called Rathke's plica. Simultaneously, the anal canal is developed from proctodeum which fuses with the rectum and gets canalized. Recent studies suggest that abnormal development of the cloaca and the cloacal membrane leads to ARM. The anal canal is displaced ventrally and ends either in the perineum or forms a rectourinary fistula. Smaller defects of the dorsal cloacal membrane early in gestation lead to an anocutaneous fistula while larger

defects result in major malformations with genitourinary fistulae or cloacal anomalies. Associated absence of striated muscle mesenchyme leads to poor development of sphincteric muscle complex.

Pouch colon is believed to be due to early arrest of cloacal partition by the urorectal septum. Pouch colon has also been attributed to obliteration of inferior mesenteric artery in early fetal life. Rectal atresia is postulated to be secondary to intrauterine thrombosis of the rectal vasculature.

SURGICAL ANATOMY

In patients with ARM, the anus is either ectopic or absent. Ectopic nature of the anus is determined by Reissner's index which is the ratio of distance between mid-anus to fourchette (base of scrotum in males) and mid-anus to coccyx. Normal values are <0.34 in females and <0.47 in males. In low or intermediate ARM, the site of anus may be marked by a depressed anal pit, hyperpigmentation or hypertrophied median raphe, and bucket handle deformity while these findings are absent in cases of high ARM. The perineal body is absent. Anoderm is poorly developed with decreased sensitivity.

In case of high ARM, the hindgut is blind ending and ectatic. It is technically outside the levator sling with foreshortening of the pelvic cavity and hypoplasia of the glutei, sacral deficiency, and underdeveloped external genitalia. The sphincter complex has deep vertical fibers which interdigitate with the superficial horizontal fibers and the parasagittal fibers at right angles. The deep component is a strictly midline structure held laterally at the ischiorectal fat pockets with poor representation in high anomalies. The superficial component has parasagittal fibers, which run perpendicular to the deep component and interdigitate anteriorly and posteriorly and also superiorly with the vertical fibers. In high ARM, the potential striated sphincter complex is severely hypoplastic and better developed close to the sacrum rather than at the site of anal dimple. Muscle fibers of internal anal sphincter (IAS) localized around the fistulae are hypoplastic. External anal sphincter (EAS) fibers are hypoplastic and malpositioned, more anteriorly displaced by the absence of rectum. The longitudinal muscle fibers of the rectum fail to traverse through the EAS to the anal skin, predisposing the tendency for mucosal prolapse of the rectum.

The adventitial layer surrounding the rectum is of importance as all the autonomic nervous supply to the bladder and rectum is embedded in it. The sympathetic supply comes from the thoracolumbar outflow and from the hypogastric nerves to enter the pelvis medial to the internal iliac vessels and anterior to the rectum. The pelvic plexus or the inferior hypogastric plexus are oriented in parasagittal plane anterolateral to the surface of the rectum and they accompany the corresponding blood vessels. They communicate behind the rectum and the bladder neck. Lower down the nerves innervate the corpora cavernosa and the prostate at 5'o clock and 7'o clock to the prostatic capsule and at 3'o clock and 9'o clock over the urethral sphincter after which they finally enter the corpora.

There is malformation of the extramural nerve supply. There may be associated tethering of cord, spinal dysraphism, caudal regression, and damaged or atypical nervi erigentes. Nerve plexus is absent at the perineum as it ends at the level of the hindgut.

In patients with ARM, especially with high malformations, the perineum and the pelvic musculature are severely underdeveloped and hypoplastic. The levator ani and its nerve supply are deficient in the midline. Anal sphincter and the puborectalis sling are poorly developed, the later being shifted more anteriorly and be closely applied to urogenital tract.

CLASSIFICATION

In 1970, *International classification* of ARM was proposed based on the principles of normal and abnormal anatomy and ARM was divided into high, intermediate, and low types **(Table 39.1)**.

The *Wingspread classification* (1984) updated and simplified the International classification. *Pena's classification* further simplified the system by focusing on the need for a colostomy during neonatal period. It combines structural anatomy with surgical management. *Krickenbeck classification* (2005) is based on the frequency of various subtypes and it allows management outcomes to be measured **(Table 39.2)**.

ASSOCIATED ANOMALIES

Anorectal malformations can be syndromic (chromosomal or genetic) or nonsyndromic (either sporadic or familial). There is a low rate of association in families with an autosomal dominant inheritance pattern reported. Chromosomal abnormalities are present in approximately 11% (Cuschieri and the EUROCAT group), most frequently

JAYPEE BROTHERS

TABLE 39.1: Original international classification of anorectal malformations.

Type of anomaly	*Female*	*Male*
High	• *Anorectal agenesis:* – Without fistula (rectal agenesis) – *With fistula:* - Rectocloacal fistula - High rectovaginal fistula • Rectal atresia	• *Anorectal agenesis:* – Without fistula (rectal agenesis) – *With fistula:* - Rectovesical fistula - Rectoprostatic urethral fistula • Rectal atresia
Intermediate	• *Anal agenesis:* – Without fistula – With fistula - Low rectovaginal fistula - Rectovestibular fistula • Anorectal stenosis	• *Anal agenesis:* – Without fistula – With fistula - Rectobulbar urethral fistula • Anorectal stenosis
Low	• *At normal anal site:* – Covered anus complete – Covered anal stenosis • *At perineal site:* – Anocutaneous fistula – Anterior perineal anus • *At vulvar site:* – Vulvar anus – Anovulvar fistula – Anovestibular fistula	• *At normal anal site:* – Covered anus complete – Covered anal stenosis • *At perineal site:* – Anocutaneous fistula – Anterior perineal anus
Rare forms	• Anal membrane stenosis • Imperforated anal membrane • Perineal groove • Perineal canal • Persistent cloaca	• Anal membrane stenosis • Imperforated anal membrane

TABLE 39.2: Krickenbeck classification of anorectal malformation (ARM).

Major clinical groups	• Perineal (cutaneous) fistula • *Rectourethral fistula:* – Bulbar – Prostatic • Rectovesical fistula • Vestibular fistula • Cloaca • ARM with no fistula • Anal stenosis
Rare/regional variants	• Pouch colon • Rectal atresia/stenosis • Rectovaginal fistula • H-type fistula • Others

in patients with anal stenosis. Down syndrome and cat eye syndrome are the chromosomal anomalies frequently associated with ARM. It is seen in 2–8% of patients with Down syndrome. The triad of anorectal stenosis (low ARM), anterior sacral defect, and a presacral mass, was first described by Currarino in 1981. **Table 39.3** summarizes the syndromes associated with ARM.

Associated anomalies are more common in boys (52–63%) and patients with high ARM (44–67%). *VACTERL* is diagnosed when three or more of the components are present and it occurs in 10% of ARM.

Besides syndromes, isolated anomalies may also coexist with ARM. Genitourinary anomalies occur in 21–61% of high ARM. Undescended testes occur in up to 19% of ARM. Vertebral and spinal anomalies are associated with supralevator lesions, the incidence being 4.6–40%. Common anomalies are partial or complete sacral agenesis, tethered cord, hemivertebrae and diastematomyelia. Gastrointestinal anomalies are uncommon (10–25%); the most common being tracheoesophageal fistula (13%) followed by duodenal atresia. Cardiac malformations occur in 9–20% of high and low ARM; ventricular septal defect, and tetralogy of Fallot are the most common.

JAYPEE BROTHERS

TABLE 39.3: Syndromes associated with anorectal malformation (ARM).

Syndromes	*Characteristics*
Townes–Brocks syndrome	ARM, hand and external ear malformations. *Other:* Cardiac and genitourinary anomalies
Pallister–Hall syndrome	Hypothalamic hamartoma, polydactyly, ARM, and respiratory anomalies
VACTERL association	Vertebral anomalies (fusion, hypoplasia), anorectal malformations, cardiac malformations, tracheoesophageal fistula, renal anomalies (renal agenesis, hypoplasia, or cystic dysplasia), and limb anomalies (unilateral or bilateral radial or thumb hypoplasia)
Sirenomelia	Fusion of the lower limbs at a varying level and degree, with inability to perform normal movements and rotation; ARM, genital, renal, gastrointestinal, cardiac, and skeletal defects
Caudal regression syndrome	Spinal column agenesis, ARM, and genitourinary anomalies; pulmonary hypoplasia and cardiac malformations may also be associated
Currarino syndrome	Triad of ARM, sacral bone defect, and presacral mass
Opitz-G syndrome	Hypertelorism, hypospadias, swallowing difficulties
Fraser syndrome	Cryptophthalmos, syndactyly
CHARGE association	Coloboma, heart anomaly, choanal atresia, growth retardation, genital anomalies, and ear anomalies
EEC syndrome	Ectrodactyly ectodermal dysplasia cleft lip/palate
Goldenhar syndrome	Hemifacial microsomia, craniofacial, cardiac, vertebral, renal, and central nervous system defects

ANTENATAL DIAGNOSIS AND COUNSELING

Prenatal ultrasonography (USG) is less sensitive and specific for the diagnosis of ARM. The absence of the circular rim of hypoechogenicity in the perineum (which refers to the presence of anus) is described as imperforate anus on prenatal scan. Although it is possible to visualize the anus using three-dimensional (3D) ultrasound, frequently it is obscured by the position of the fetal heel and it may be misleading in some subtypes such as rectal atresia. Enterolithiasis and dilated fetal colon may be indirect evidence of ARM. Suspected ARM on antenatal ultrasound may warrant fetal magnetic resonance imaging (MRI) in the third trimester for confirmation. In fetuses with ARM (mainly rectourethral fistulae in the male and long common-channel cloacal anomalies in the female), there is mixing of urine and meconium, resulting in heterogeneous T1 and T2 signal intensity in the bladder and rectum. On antenatal diagnosis, parents should be counseled as to the likely outcome and the preferred center of delivery, ideally in a tertiary care center with pediatric surgical services.

CLINICAL PRESENTATION

Anorectal malformation is diagnosed at birth during routine neonatal examination. Delayed diagnosis is not uncommon in rectal atresia and anal stenosis because of the deceptively normal appearing anal opening. Late presentation is also common with home deliveries and in female children with wide fistula. All neonates diagnosed with ARM must undergo detailed assessment of associated anomalies. Presence of excessive oral secretions and central cyanosis implies VACTERL anomaly. History of meconuria or pneumaturia is suggestive of rectourinary fistula. Poor development of anal dimple, anal ridge, natal cleft, and buttocks are harbingers of poor outcome in terms of continence. Male and female subtypes differ significantly in their clinical management and hence they are, henceforth, discussed separately.

MALE ANORECTAL MALFORMATIONS

Neonatal Examination

Meticulous examination of a newborn male perineum will reveal several vital clues of ARM. Presence of meconium in the urine or at the urethral meatus is a "tell-tale" sign of rectourinary fistula. In low ARM such as anocutaneous (perineal) fistula the median raphe of the scrotum may be thickened due to the presence of a subepithelial fistulous tract. The fistulous tract may contain a speck of meconium ("black pearl" sign) or epithelial debris ("white pearl" sign)

JAYPEE BROTHERS

(Fig. 39.1); there may also be a midline skin tag, described as "bucket-handle" deformity **(Fig. 39.2)**. On the other hand, in high ARM the perineum will be flat due to poor development of sphincter complex and parasagittal fibers **(Fig. 39.3)**. Although in rectal atresia the anus may externally appear normal, a stiff red rubber catheter cannot be negotiated >2 cm beyond the anal verge. Anal stenosis is diagnosed when the opening is devoid of corrugations and if it does not admit 10-Fr catheter. The normal size of anus is described as 1.3 + (3 × birth weight in kg) in millimeters. In anal membrane stenosis, the anus is normal in position but covered by a thin epithelial lining through which meconium can be seen bulging **(Fig. 39.4)**.

Neonatal Investigations

Plain Radiography

In addition to assessing associated anomalies, neonatal investigations are aimed to deduce the level of ARM which is very vital for proper management. An upside-down inversion X-ray (invertogram), first described by Wangensteen and Rice, is no longer practiced. It is replaced by cross-table lateral prone X-ray taken at 18–24 hours after birth. The neonate is placed in prone position with hips flexed such that both femurs are superimposed and the center of X-ray beam is focused over the greater trochanter. The level of the blind ending rectum is delineated by swallowed air.



Fig. 39.1: Black pearl sign of anocutaneous fistula (perineal fistula).



Fig. 39.3: Flat perineum of high anorectal malformations.



Fig. 39.2: "Bucket-handle" deformity of low anorectal malformations in male.



Fig. 39.4: Anal membrane stenosis.

JAYPEE BROTHERS

The radiographs are assessed not by the distance between the skin and the blind ending rectum, but by bony landmarks. The pubococcygeal (PC) line is an imaginary line extending from the center of the boomerang-shaped pubic bone to the lower end of the sacrum (not coccyx!). This line corresponds to the bladder neck, verumontanum, and reflection of the pelvic peritoneum from the rectum to the prostate in males and the external os of the cervix in females. The "I" point lies at the inferior end of the comma-shaped ischial bone. The imaginary "I" line is drawn parallel to the PC line through the "I" point. It corresponds to the urethral bulb in males and the upper end of the perineal body in females. In high anomalies, the distal gas bubble ends superior to the PC line **(Fig. 39.5)**; in intermediate anomalies, it crosses the PC line but ends at or above the "I" line **(Fig. 39.6)** and in low anomalies, the gas bubble extends well below the "I" point to reach the skin **(Fig. 39.7)**. The fallacies of interpreting radiographs are summarized in **Table 39.4**.

An erect X-ray of the abdomen and chest (infantogram) is helpful in ruling out colorectal perforation and pouch colon **(Fig. 39.8)**. They are also invaluable in detecting associated skeletal and spinal anomalies such as spina bifida and hemivertebrae. Radiological assessment of sacrum helps to assess the neurological innervation of the pelvic floor muscles and predict continence. Deficiency of 4th and 5th sacral vertebrae is associated with normal innervation of the bladder and levator ani. Deficiency of

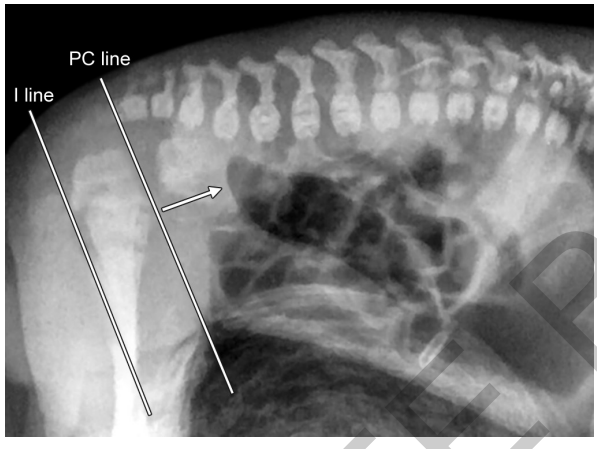

Fig. 39.5: The prone cross-table lateral X-ray of high anorectal malformation (ARM). Pubococcygeal (PC) and "I" lines are marked. Rectal gas ends well above the PC line (arrow).

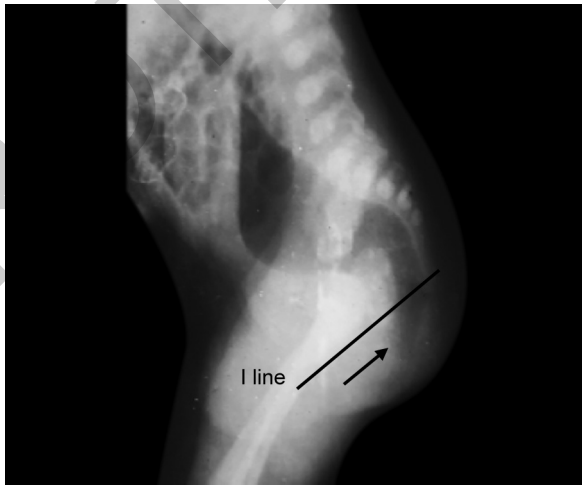

Fig. 39.7: In low anorectal malformation (ARM), rectal gas (arrow) reaches almost close to skin.

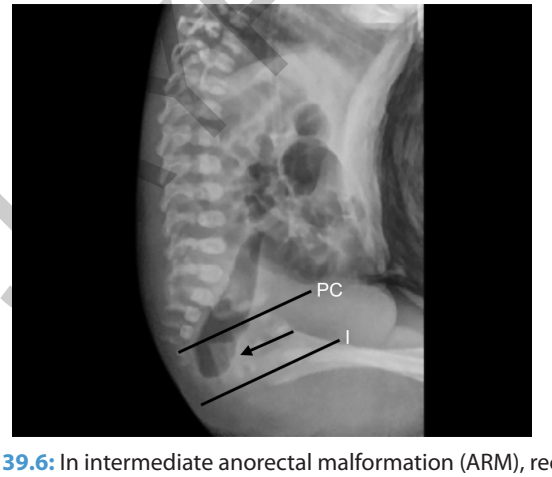

Fig. 39.6: In intermediate anorectal malformation (ARM), rectal gas (arrow) is seen between pubococcygeal (PC) and "I" lines.

TABLE 39.4: Fallacies of interpreting prone cross-table lateral X-rays of anorectal malformation (ARM).

Misleadingly high ARM	*Misleadingly low ARM*
• Imaging done before 18–24 hours of birth (insufficient time for the swallowed air to reach the terminal bowel) • Meconium plug blocking air from reaching the terminal bowel • Active contraction of the levator ani/sphincter muscle complex because of vigorous crying which pushes the rectal gas upward • Escape of gas through a fistula • Distortion by X-ray magnification	• Pelvic floor muscles relaxed/hypotonic • Sacral anomaly • Gas in the vagina/ bladder may be mistaken for gas in the distal bowel • Over distended bowel due to too much delay since birth

JAYPEE BROTHERS

3rd, 4th, and 5th sacral vertebrae is accompanied with abnormal neuromuscular development. Deficiencies of 1st or 2nd sacral segments are associated with poorly developed and innervated levator ani and pelvic floor musculature and incontinence. If only one or two vertebrae show a hemisacral defect, then there may not be a clinical neuromuscular deficit. Degree of postoperative continence is predicted by the sacral ratio, the distance from the lowest point of the sacrum to the lowest point of the sacroiliac joints divided by the distance from the iliac crests to the lowest point of the sacroiliac joints on anteroposterior (AP) or lateral X-rays. Normal sacral ratio is 0.74 (anteroposterior view) and 0.77 (lateral view).



Fig. 39.8: Pouch colon showing the characteristic single large gas bubble occupying more than half of the abdominal diameter. It may be easily mistaken for pneumoperitoneum of bowel rupture. Unlike that of pneumoperitoneum the gas shadow is never seen in subdiaphragmatic space in pouch colon.

Lesser values imply poor neuromuscular development leading to impaired continence.

Ultrasonography

Primary role of neonatal USG is to identify associated genitourinary anomalies. Increasingly transperineal USG is also used to identify the level of blind ending rectum. Spinal ultrasound before sacral ossification (up to 3 months of age) can pick up tethered cord and other spinal anomalies. Echocardiography is essential to rule out cardiac anomalies.

Magnetic Resonance Imaging

In most of the cases, plain radiography with ultrasound is sufficient for planning definitive procedure by defining the level of pouch and fistula. MRI, in addition to delineation of the type and level of ARM, allows accurate assessment of the sphincter muscle complex. It is useful in patients with rare and complex anomalies for preoperative evaluation and planning. MRI is also better in diagnosing associated anomalies, especially that of the spinal cord, spine, and the urogenital system. The evaluation of ARM is guided by ARGUS (anorectal, genitourinary, and sacral anomalies) protocol.

Neonatal Management

Management of a male neonate with ARM depends upon the level of malformation, physical condition of the newborn, and presence of associated anomalies. **Table 39.5** summarizes the therapeutic approach.

TABLE 39.5: Surgical management of male neonate with anorectal malformation (ARM).

Level of ARM	***Confounding factors***	***Preferred management***
Low ARM	Immaterial	Cutback anoplasty
Intermediate ARM	• Adequate birth weight • Early presentation • Minimal abdominal distension • No associated anomalies	Primary PSARP (single-stage definitive procedure)
	• Low birth weight baby • Delayed presentation • Tense abdominal distension • Associated major anomalies	*Staged procedure* • *Stage 1:* Colostomy at birth • *Stage 2:* Definitive procedure (PSARP or LAARP) at around 3–6 months of age • *Stage 3:* Colostomy closure after 6 weeks of stage 2
High ARM	Immaterial	

(PSARP: posterior sagittal anorectoplasty; LARP: laparoscopic anorectoplasty)

JAYPEE BROTHERS

FEMALE ANORECTAL MALFORMATIONS

Neonatal Examination

Unlike male, ARM imaging is seldom required to diagnose female ARM. Simple bedside examination with counting the number of perineal orifices will establish the correct diagnosis in most of the cases. Normally there are three orifices, namely the urethra, vagina, and anus. Any abnormality of the number and position of these orifices holds the diagnostic clue **(Figs. 39.9 to 39.11 and Table 39.6)**. Clinical features of rectal atresia, anal membrane, and anal stenosis are similar to that of male patients.



Fig. 39.9: Single opening in female perineum is diagnostic of persistent cloaca.

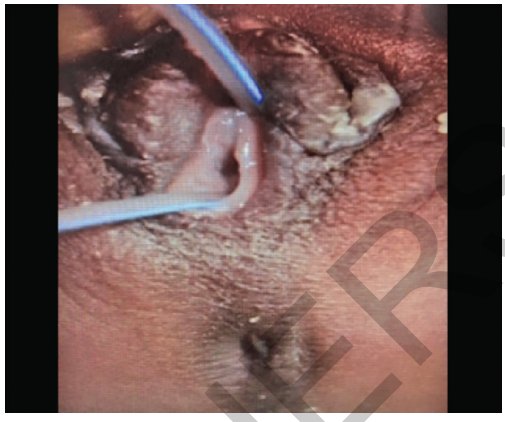

Fig. 39.10: Two openings in perineum suggest: (1) Rectovaginal fistula if it is meconium-stained [rarely anorectal malformation (ARM) with Müllerian agenesis will mimic this]; (2) Anorectal agenesis without fistula if it is not stained with meconium.



Fig. 39.11: Triple opening is diagnostic of anovestibular or rectovestibular fistula. Ability to pass a probe in rectum is diagnostic of anovestibular fistula.

TABLE 39.6: Clinical examination in a female neonate with anorectal malformation (ARM).

Number and location of perineal orifices		***Meconium staining***	***Diagnosis***
Single opening		Yes	Cloaca
		No	Anorectal agenesis with urogenital sinus
Two openings		Yes	• Rectovaginal fistula • Vestibular fistula with MRKH
		No	Anorectal agenesis without fistula
Three openings (position of the third orifice)	Normal site	Yes	• Perineal canal • Perineal groove
		No	Rectal atresia
	In vestibule	Yes	• Vestibular fistula • Vestibular anus
	In perineum	Yes	• Anterior perineal anus • Perineal fistula

(MRKH: Mayer-Rokitansky-Küster-Hauser syndrome)

JAYPEE BROTHERS

Neonatal Investigations

Abdominal USG, babygram, and echocardiography are done to rule out associated anomalies. Unlike male ARM radiographs are usually not necessary in the diagnosis of female ARM. The cross-table lateral X-ray is required in patients when meconium is not seen at the perineum even after 24 hours.

Management Principles

Patients with vestibular fistula with adequate deflation of bowel may be maintained on rectal washouts and a primary repair is done at the age of 6–8 weeks. Cloaca requires a high diversion stoma along with management of hydrocolpos. Similarly, inadequate bowel deflation despite the presence of fistula as it is seen in pouch colon, pure anorectal agenesis or rectovaginal fistula requires a temporary diverting colostomy in the neonatal period. Management of perineal fistula and rectal atresia are identical to that of male patients.

TECHNICAL CONSIDERATIONS

Diversion Colostomy

Usually, a high sigmoid colostomy is preferred; however, right transverse colostomy may be required in high ARM or cloaca. Although Pena considers a divided descending colostomy as the ideal stoma, many pediatric surgeons prefer a defunctioning loop stoma so as to decrease the operative time in a sick neonate. Taking into consideration the ergonomics and logistics of a future laparoscopic pull through procedure, a "lateralized high sigmoid loop colostomy" can be adapted as described by Agrawal et al. While positioning a right transverse stoma in a neonate with a distended sigmoid colon, care must be taken to not mistakenly exteriorize the sigmoid colon in the right hypochondrium. This will lead to postoperative sinking of the stoma and compromise of its function. The subsequent pull through procedure will also become difficult. The misplaced stoma may warrant refashioning before definitive surgery.

Characteristics of an Ideal Colostomy

- Adequate defunctioning of colon is the primary goal.
- Fecal matter should not spill-over into the distal loop resulting in formation of fecaloma.
- Distal unused colon should be short enough permitting easy irrigation of rectal blind loop.
- Adequate size of distal stoma allowing easy egress of urine from distal segment in patients with a large rectourinary fistula. This is essential to prevent hyperchloremic acidosis and recurrent urinary tract infections.
- Stoma as distal as possible allowing formed stool as liquid stool is difficult to manage.
- Adequate length of distal loop should be left over permitting tension-free pull through.
- Good fixation to prevent prolapse.

Colostomy Care

After the colostomy is established, on-table wash out of the distal bowel must be done to completely evacuate meconium. Thereafter, daily distal bowel washouts must be started and stressed upon. This prevents accumulation of mucous, development of pouchitis, formation of fecaloma in the blind loop of the bowel, dilated sigmoid, and long-term constipation after definitive surgery. Colostomy bags are impractical in small infants. The effluent is better managed by absorbent cloth pads tied over the stoma. Peristomal excoriation is avoided by applying liberal amount of zinc oxide cream.

Investigations for Staged Approach

In staged approach, definitive repair of rectum is done at 6–12 weeks of age. The intervening period allows evaluation of the pathological anatomy and associated malformations. Injection of water-soluble contrast in the distal bowel loop (pressure-augmented distal colostogram) is essential to delineate the level of the blind ending rectum, length of bowel available for pull-through repair, presence of fecaloma or rectal ectasia, and any fistula to the urinary system. High pressure injection using a Foley balloon catheter is essential to avoid artifacts caused by the resistance of striated muscle complex **(Fig. 39.12)**. A distal colostogram is required in female patients with rectal agenesis, pouch colon, or cloaca. Micturating cystourethrography is essential to diagnose coexisting vesicoureteral reflux (VUR). In most cases, plain and contrast radiography with ultrasound is sufficient for defining the level of pouch and fistula. MRI is invaluable in deducing the developmental status of the sphincter muscle complex and structure of the pelvic floor. MRI is also useful in rare and complex anomalies. It is also useful in diagnosing associated spinal and urinary anomalies.

Posterior Sagittal Anorectoplasty

Most of the male ARM and some of the high female ARM can be successfully managed with the posterior sagittal

JAYPEE BROTHERS



Fig. 39.12: Pressure-augmented distal colostogram showing high anorectal malformation (ARM) with rectourethral fistula. Contrast in seen entering the bladder and urethra.

anorectoplasty (PSARP) without the need for an abdominal approach. However, each case should be individualized depending on the nature of malformation.

An adequate-sized Foley catheter is inserted into the bladder. Often, in patients with a large fistula, the catheter may enter the rectum. Recatheterization should be attempted using a stiffer tube or with the aid of a catheter guide under cystoscopic control. If all these attempts are unsuccessful, catheter can be relocated into the urethra during the surgery under direct vision. A guidewire may be put into the fistula during cystoscopy in such cases to ease dissection of the fistula.

In prone jack-knife position, the anterior and posterior limits of the sphincter muscle complex are marked with the help of an electrical (galvanic current) muscle stimulator. Posterior sagittal incision extends from mid-sacrum to the anterior point of the marked future neoanus. Skin, subcutaneous tissue, parasagittal fibers, levator, and muscle complex are divided successively keeping strictly in midline. Coccyx is either split in the midline or excised, especially in patients with rectoprostatic fistula for better exposure. Blind dissection at this level can lead to neural damage. The rectum is opened in the midline up to the fistula. A stay suture is placed at the fistula orifice. The rectum is dissected laterally on either side to facilitate the anterior dissection. Anteriorly, the rectum above the level of fistula shares a common wall with the urinary tract. The rectum is separated from the urethra in a submucosal plane for approximately 5–10 mm above the fistula. After this, a full thickness anterior dissection is resumed. A circumferential perirectal dissection is performed to gain enough length to reach the perineum. The fibrovascular bands and vessels that hold-back the rectum are cauterized and divided. Vascularity of the pull-through rectum is based on the intramural plexus of vessels. Care is taken to ensure dissection is being done close to the rectal wall to prevent damage to pelvic nerves. The fistula is closed with submucosal interrupted sutures. Megarectum may require size reduction by posterior tapering. The limits of sphincter complex are confirmed once again with the help of electrical stimulator. These are seen as the crossing of the voluntary muscle complex (parallel to the rectum) perpendicular to the parasagittal fibers (parallel to the lower skin incision). The perineal body is then reconstructed. The rectum is placed in front of the levator and within the limits of the muscle complex. The posterior limit of the muscle complex is reapproximated behind the rectum. Some bites are taken through the rectum so as to fix the rectum and avoid rectal mucosal prolapse later. Anoplasty is then performed with 16 interrupted mucocutaneous stitches. The ischiorectal fossa and the subcutaneous tissue are reapproximated in the midline and the wound is closed. Postoperatively, orals are started the same evening. Broad-spectrum antibiotics are administered and Foley catheter is kept for 5–7 days.

Abdominal Pull-through

Patients with high rectoprostatic fistula and bladder neck fistula need an abdominal approach for fistula ligation and rectal pouch dissection. In patients with high anomalies, the common wall between the rectum and urinary tract is shorter making dissection easier. Abdominal mobilization of bowel can be combined with a posterior sagittal approach to create a rectal channel.

Laparoscopic Anorectoplasty for Anorectal Malformation

The first laparoscopic-assisted anorectoplasty for repair of ARM was presented by Georgeson in 2000. Rectoprostatic fistula (T-shaped insertion with lack of common wall), rectovesical fistula and high rectovaginal fistula are ideal candidates for laparoscopic anorectoplasty (LARP).

A 5-mm camera port is placed at the umbilicus and two working ports are placed according to the site of the colostomy. In patients with a transverse stoma, one port is placed in the right iliac fossa and another in the mid

JAYPEE BROTHERS

clavicular line at the level of the umbilicus. In patients with sigmoid stoma one is placed at the mid clavicular line, just below the liver and another in the right anterior axillary line at the level of the umbilicus. Circumferential rectal dissection is started from the peritoneal reflection. The dissection continues inferiorly along the anterior and lateral rectal walls. The terminal branches of the sigmoid and superior rectal arteries are divided to gain adequate bowel length. The fistula is ligated and divided. After retraction of the mobilized colon, the pubococcygeus is identified on the pelvic floor. A trocar is passed through a midline sagittal incision in the perineum (site of neoanus) at the site of maximal muscle contraction and advanced while staying strictly in the midline just posterior to the urethra, under laparoscopic guidance. The tract is dilated up to 10–12 mm and the distal rectum is pulled down into the perineum along the rectal channel. The rectum is retracted cephalad and fixed to avoid prolapse and anoplasty is completed.

Improved surgical exposure of the fistula, rectal mobilization without the need for extensive perineal dissection, exact placement of the bowel through the muscle complex, faster recovery, and shorter hospital stay are some of the advantages of LARP. Care must be taken to avoid damage to the urethra, bladder neck, and ureters during passage of the perineal trocar to create the rectal channel. Intraoperative peritoneal contamination and urethral diverticulum from residual stump of fistula are complications peculiar to LARP.

The introduction of 3D laparoscopy represents a significant advancement in the surgical management of high ARMs, particularly rectoprostatic urethral fistulas. Unlike conventional two-dimensional (2D) laparoscopy, which lacks stereoscopic vision and depth perception, 3D systems offer enhanced spatial orientation, improved hand-eye coordination, and superior precision. These advantages translate into reduced operative time, decreased physical discomfort (notably eye strain and musculoskeletal fatigue), and lower mental stress for the operating surgeon, as demonstrated in recent pediatric studies. While both 2D and 3D laparoscopic-assisted anorectal pull-through (LAARP) procedures yield comparable clinical outcomes in terms of safety and complication rates, 3D laparoscopy significantly improves the surgical ergonomics and operative efficiency. This evolution underscores the potential for broader application of 3D technology in pediatric minimally invasive surgery, particularly in technically demanding procedures like LARP **(Figs. 39.13A and B)**.

Laparoscopy Assisted Modified Posterior Sagittal Anorectoplasty

Liem et al., described a versatile surgical approach for the correction of ARMs, including vestibular fistula, rectovaginal fistula, and rectobulbar and prostatic fistulas. This method combines the benefits of open and laparoscopic-assisted techniques, facilitating precise dissection and optimal placement of the rectum within the sphincter complex. By integrating minimally invasive access with selective perineal dissection (supralevator), the approach minimizes trauma to surrounding structures and avoids puborectalis division akin to Stephen's

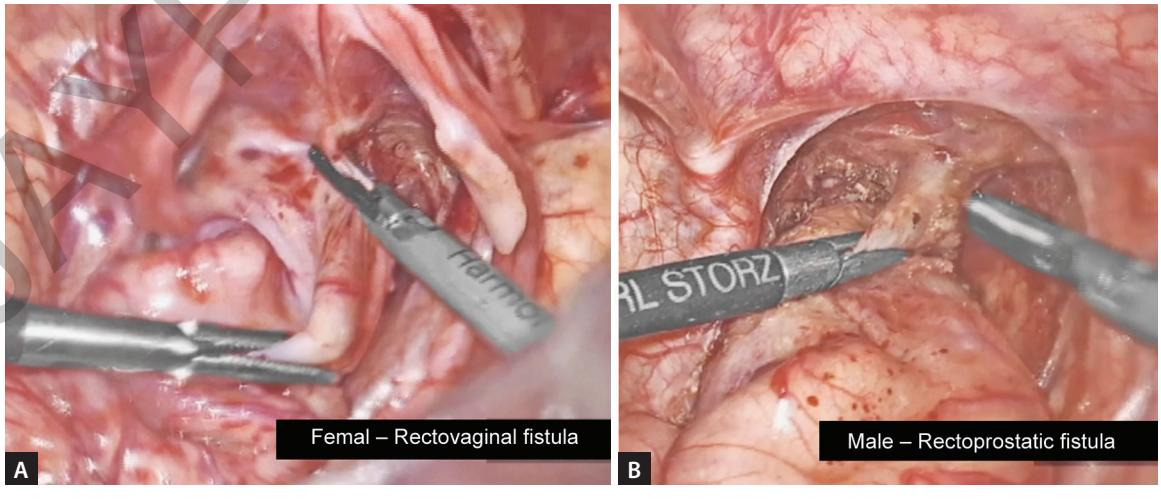

Figs. 39.13A and B: Three-dimensional (3D) laparoscopic anorectoplasty.

JAYPEE BROTHERS

approach, enhances visualization of fistulous tracts, and improves postoperative outcomes across a spectrum of ARM types **(Figs. 39.14A to C)**.

Single-staged versus Staged Repair of Anorectal Malformation

Traditionally high ARM is managed by staged approach. Recently, there has been a paradigm shift toward single-staged procedures as they have decreased morbidity, low mortality, good outcome, and low cost of care. Improved continence of single-staged repair is attributable to better cognitive development in the first year of life. Sensation of rectal fullness is essential for development of cortical representation of rectum and hence continence. The other advantages of single-staged repair are: (1) Early initiation of brain-defecation reflex and potential for better toilet training/continence, (2) Easy dissection due to virgin tissue planes with no fibrosis due to pouchitis, (3) No need for bowel preparation, (4) Avoidance of colostomy and its related complications, and (5) Lesser physical and psychological stress to the parents, child, and surgeon **(Figs. 39.15A and B)**.

The transperineal intracath meconiolysis and evacuation (TIME) technique is designed by Agrawal et al., to address colonic distention in neonates undergoing one-stage laparoscopic anorectoplasty (OSLARP) for high ARMs with high rectourinary fistula **(Figs. 39.16A to C)**. The principle involves perioperative decompression of the dilated bowel to optimize the laparoscopic working space. The technique begins with a 16G intracath inserted transperineally through anal site into the rectal pouch. Warm saline and 2% N-acetylcysteine are instilled to dissolve and evacuate meconium, thereby decompressing the bowel. Once adequate space is achieved, standard laparoscopic ports are placed, and the procedure proceeds with laparoscopic dissection, division of the fistula, and

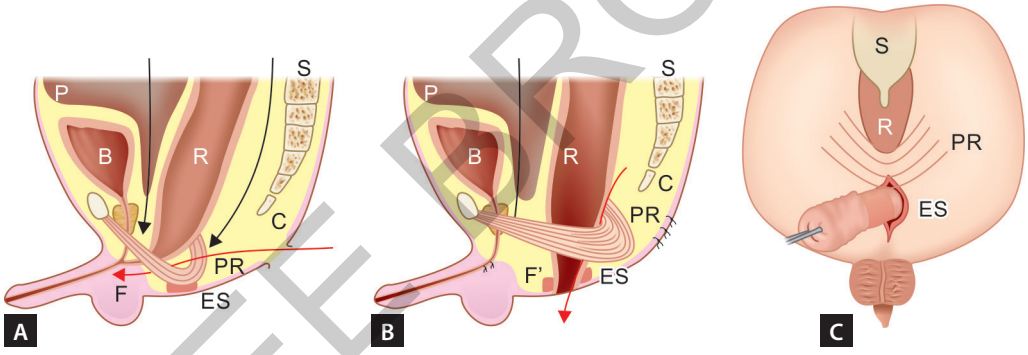

Figs. 39.14A to C: Laparoscopy assisted modified posterior sagittal anorectoplasty (PSARP) (A–C) Schematic diagram explaining laparoscopic-assisted modified posterior sagittal anorectal pull-through.

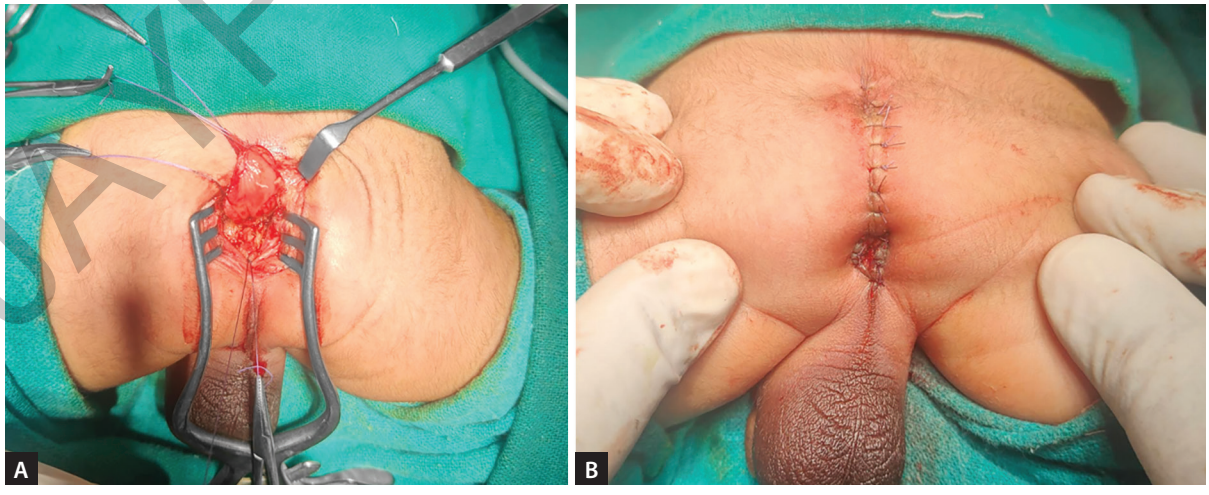

Figs. 39.15A and B: Single stage posterior sagittal anorectoplasty (PSARP).

JAYPEE BROTHERS

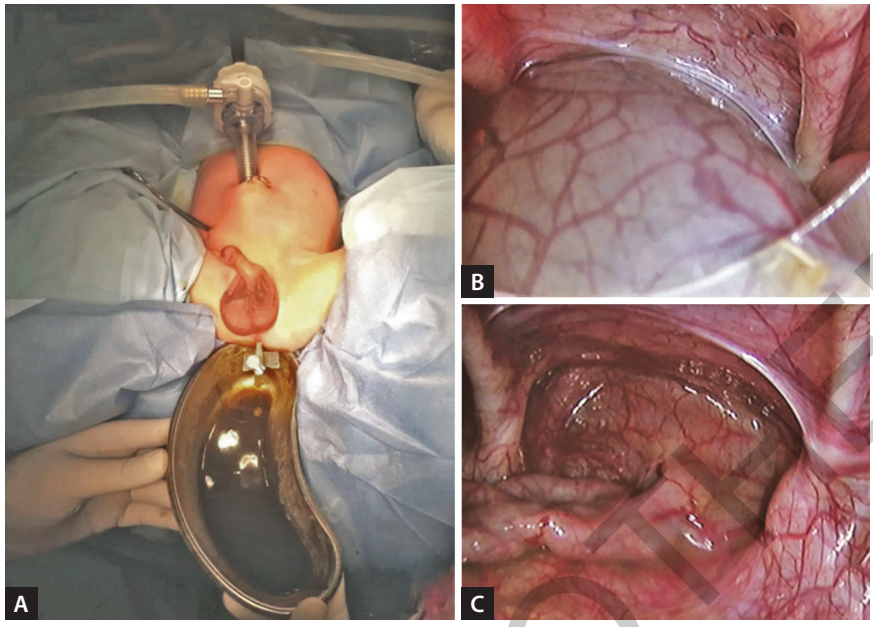

Figs. 39.16A to C: Single stage laparoscopic anorectoplasty (LARP) (transperineal intracath meconiolysis and evacuation technique). *Source:* Adapted from Agrawal V, Sharma D, Tiwari A, Mishra R, Acharya H. Transperineal intracath meconiolysis and evacuation technique of "distended" bowel evacuation for one-stage laparoscopic anorectoplasty for high anorectal malformations in males. J Laparoendosc Adv Surg Tech A. 2020;30(6):701-5.

pull-through of the rectum as per conventional LARP. This approach enables effective laparoscopic correction of rectourinary fistulas in neonates without prior colostomy.

A full-term, adequate weight, and vitally stable neonate with a low or intermediate malformation, in the absence of significant cardiac anomaly or abdominal distension is the ideal candidate for primary repair in the hands of an experienced surgeon. Absolute contraindications for single-staged repair are the presence of other severe life-threatening congenital malformations, sepsis, or necrotizing enterocolitis with pneumoperitoneum, extreme prematurity, and persistent cloaca.

Single-staged repairs do not allow adequate time to investigate associated malformations of the urinary tract. Consequently, the genitourinary tract is at greater risk of operative injury. Moreover, in the absence of fecal diversion the risk of wound infection and dehiscence can be higher.

Technical Variations in Surgery for Female Anorectal Malformation

Most of the female ARM can be treated using PSARP; however, high rectovaginal fistula requires an abdominal approach/LAARP. Depending upon the level of rectal fistula, extent of PSARP dissection is modified as limited PSARP and minimal PSARP. Since majorities of female ARM are characterized by adequate bowel decompression through a wide fistula they are primarily repaired at 6–8 weeks. As the rectum shares a common wall with the bladder and urethra in male, the rectum in female ARM shares a common wall with the vagina. Meticulous separation of these with sharp dissection is essential for successful outcome. As most of the malformations have an externally visible fistula, female ARM can also be repaired by anterior sagittal anorectoplasty (ASARP) in supine lithotomy position.

Mayer-Rokitansky-Küster-Hauser (MRKH) syndrome with vestibular fistula is a rare variant of female ARM in which the vagina is absent. Here, the rectal fistula which opens into the vestibule can be left in situ to function as a blind ending vagina or anastomosed to the uterus if present, and the transected proximal rectum is mobilized distally to form the neoanus.

RARE AND REGIONAL VARIANTS

Congenital Pouch Colon

Congenital pouch colon (CPC), a rare form of ARM prevalent in North India, is characterized by extremely huge dilatation of terminal end of rectum along with variable

JAYPEE BROTHERS

degree of foreshortened colon. It is also known as pouch colon syndrome. It is more common in males. CPC may also be associated with rectal atresia or cloaca. The dilated rectal end, the pouch, lacks *Taenia coli*, haustrations, and appendices epiploicae. Varying length of colon which is massively dilated, receives an abnormal and aberrant vascular supply and has a large fistulous communication with the urogenital system. Histopathology shows thin and disorganized muscle layers with either normal ganglionosis, hypoganglionosis, aganglionosis, or neuronal hypoplasia. Depending upon the degree of foreshortened proximal colon, Narasimha Rao et al. classified CPC into four subtypes: Type 1 with near normal colon length while type 4 with ileum directly draining into the rectal pouch. Clinical presentation is identical to high ARM, but with gross abdominal distension. Erect abdominal radiographs showing hugely dilated bowel with a single large fluid level occupying more than half of the abdomen is characteristic of CPC.

Management of CPC is controversial and long-term outcome is poor. The ligation of colovesical fistula is recommended in the neonatal period to avoid urinary tract infections and hyperchloremic metabolic acidosis. Depending on the general condition of the patient and associated anomalies, a proximal colostomy or ileostomy with or without excision of pouch and fistula division is done in the neonatal period. Definitive procedure is pouch excision with pull-through of colon or ileum.

Coloplasty of the pouch to preserve colonic length is not recommended as the pouch does not function well due to abnormal muscular and neural elements. Pouch excision which is followed by increased stool frequency for 3–6 months following surgery settles down with growth of the child, bowel adaptation, and dietary modifications. Long-term prognosis and quality of life depends on the amount of proximal colon left behind.

Rectal Atresia

Rectal atresia is also a rare form of ARM (incidence 1–2%) which, in contrast to CPC, is common in South India. In this rectum and anal canal are well formed but are discontinuous with the blind rectum ending at or above PC line. The sphincter complex is well developed. Etiology of rectal atresia is thought to be an intrauterine vascular accident analogous to jejunoileal atresia. Cause of fetal vascular thrombosis is believed to be intrauterine infection or maternal folic acid deficiency.



Fig. 39.17: Contrast study done in a rectal atresia patient with Hegar dilator in the blind-ending anus.

Clinical presentation is similar to high ARM, however, with normal looking anal opening in the perineum. Diagnosis is often delayed due to the normal looking anal opening. Inability to pass a stiff red rubber catheter beyond 1.5–3 cm from the anal verge is diagnostic of rectal atresia. Forceful manipulation of catheter has the risk of rectal perforation and must be avoided. Unlike other ARM, associated anomalies are rare. During radiography placement of a red rubber catheter or Hegar's dilator in the anus helps in assessing the distance between the blind ends of the rectum and the anal canal **(Fig. 39.17)**. Based on the distance between the blind ends, Dorairajan classified rectal atresia into four types; type 1 being just a thin membranous partition while type 4 with >2 cm gap. Type 1 is easily cured by endoscopic incision of the membrane in the neonatal period while other types are managed in line with high ARM. Transanal, end-to-end, and rectorectal anastomosis by pull through of the proximal segment has also been described.

Rectal Stenosis

Patients with rectal stenosis may be managed with regular rectal dilatations. Alternatively, Y-V flap anoplasty can be done to widen the anal opening. The prognosis is excellent as the sphincter muscle complex is well developed.

Perineal Groove

This is an exclusively female form of ARM wherein a mucosa lined canal extends between the normal anus and

JAYPEE BROTHERS

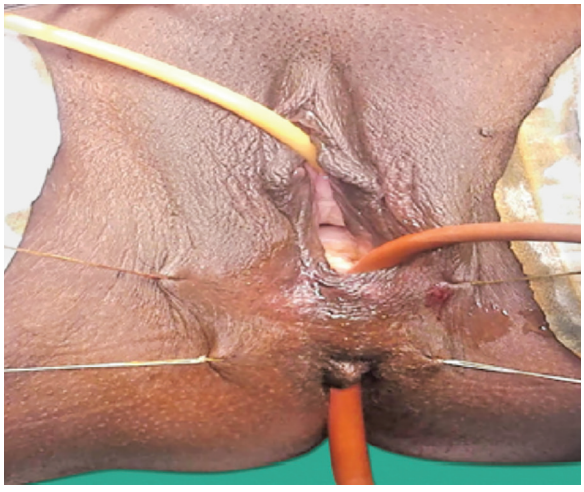

Fig. 39.18: Perineal canal in a female.

vaginal introitus. Fecal soiling of vagina can be avoided by excising the mucosal strip.

Perineal Canal

Perineal canal is a peculiar form of female ARM wherein a mucosal tunnel connects lower vagina with a stenotic anus at normal anatomical site **(Fig. 39.18)**. Passing of stools though vestibule results in recurrent labial abscesses. Various operative procedures such as vestibuloanal pull-through, anterior rectal wall pull-through, limited PSARP, endorectal pull-through, and direct excision have been reported. Recurrence and wound dehiscence are very common in all of them. Prognosis in terms of continence is usually good.

H-Fistula

H-fistula is the male equivalent of perineal canal wherein a fistula from normal rectum to urinary tract leads to frequent urinary tract infection (UTI). It is rare and associated with major urethral anomalies. It is managed in line with intermediate ARM. Associated urethral stenosis or atresia needs suprapubic cystostomy followed by urethral dilatation. If this fails, an urethroplasty is indicated.

Persistent Cloaca

Cloaca is the common channel of the rectum, vagina, and urethra that opens externally as a single opening. Its incidence is 1 in 250,000 live births and occurs predominantly in females. The length of the common channel ranges from 1 to 7 cm. Short cloaca is to be distinguished from rectovaginal fistulae. Clinical presentation is identical to high ARM. Associated hydrocolpos may present as a palpable suprapubic lump. The distended vagina presses upon the bladder causing hydroureteronephrosis. This necessitates drainage of the hydrocolpos by intermittent catheterizations, pigtail drainage, or a vaginostomy along with a diversion colostomy during the neonatal period.

Definitive reconstruction of persistent cloaca, especially long common-channel variety, should be undertaken by well experienced surgeons at 1 year of age. Cystogenitoscopy should be done prior to definitive surgery to determine the length of the common channel and location of orifices. Patients with long channel usually have a complex anatomy. 3D reconstruction of computed tomography (CT) scan and/or MRI may be useful in defining the common channel length and anatomy. Fecal and urinary continence with normal sexual function are the final treatment goals. However, in severe forms, neither may be achieved.

In 60% of patients, the common channel length is <3 cm. Repair is achieved by posterior sagittal approach with total urogenital mobilization (TUM). The common channel is opened and the rectum is separated from the vagina. The urethra and vagina are mobilized as a single unit with preserved common blood supply and the suspensory ligaments attached to the pubis are divided. Vagina is mobilized all around and fixed at the introitus. A smooth urethra with a visible opening in the introitus is provided which facilitates clean intermittent catheterization (CIC). The flaps from the common channel are used to create neolabia. The perineal body is reconstructed and rectum is placed within the sphincter muscle complex.

If the common channel length is >3 cm, then TUM is not sufficient and posterior sagittal ano-recto-vagino-urethroplasty (PSARVUP) is required. Laparotomy and extended transabdominal urogenital mobilization are then needed. If the vagina is septate or duplicated both hemivagina are tubularized to form a single vagina to reach the introitus (vaginal switch operation). If the native vagina is very small it is left intact converting it into urethra and a neovagina is designed from isolated segment of sigmoid colon or ileum.

Functional prognosis with regard to fecal continence depends on the length of common channel. Approximately 20% of patients with channel length <3 cm and 70% of those with channel >3 cm develop urinary incontinence, for which CIC is recommended.

JAYPEE BROTHERS

Posterior Cloaca

It is a rare variant of ARM in which the urethra and vagina are fused to form a urogenital sinus that opens in or immediately anterior to the rectal wall. The most relevant difference between a typical cloaca and the posterior cloaca is that, in the latter, the anus is normally located and has a normal sensate pectinate line with well-developed sphincter mechanism. Thus, the potential for full continence is excellent. A single opening at the anal site discharges both urine and fecal matter. The surgical management involves preservation of anus, TUM through the perineal route and preservation of the sphincter muscle complex.

POSTOPERATIVE COMPLICATIONS AND MANAGEMENT

Postoperative Care

Anal dilatations are started 2 weeks after definitive surgery. A dilator that fits snugly into the anus is passed twice daily by the parents, increasing the size of the dilator every week till it reaches the appropriate size for age. After adequate dilatation, the colostomy is closed and the frequency of dilatation is gradually reduced. Dilatations are vital to avoid stricture of the neoanus.

Dietary modifications with adequate roughage and plenty of oral fluids are advised to keep the stools soft. In addition to the above, daily home enemas are administered which are gradually tapered so as to habituate the neorectum for periodic evacuations.

Perioperative Complications

- Wound infection and dehiscence are uncommon in patients with a diversion stoma; but the risk is high in single-staged surgery. Perineal scarring following infection will hamper the final outcome in terms of continence and cosmesis.
- Rectal retraction (inadequate mobilization or ischemia of mobilized bowel), rectal prolapse (improper fixation of redundant rectum), rectal stricture (ischemia due to overenthusiastic bowel mobilization), and stenosis of neoanus (improper dilatation) are mostly technical in origin and are avoidable.
- Rectourinary/vaginal fistula occurring in postoperative period may be either the original fistula that was missed during surgery or a new found fistula due to technical issues. Adequate full thickness mobilization of the anterior rectal wall and avoidance of overlapping suture lines are important to avoid fistula formation.
- Persistent urogenital sinus occurs in patients with misdiagnosed cloaca.
- Posterior urethral diverticulum or stricture complicates inappropriate technique of fistula ligation.
- Neurogenic bladder secondary to nerve damage during rectal mobilization is devastating.

Long-term Complications

Fecal Incontinence

Fecal incontinence is seen in 25% of ARM. Despite having good control over bowel, patients with low ARM frequently suffer from constipation, chronic fecal impaction, and overflow incontinence (pseudoincontinence). In contrast, patients with high ARM and those with abnormal sacrum or associated spinal deformity suffer from true incontinence. Proper clinical, radiological, and functional assessments are essential to distinguish true incontinence from pseudoincontinence **(Table 39.7)**.

Several scoring systems are developed to document the degree of fecal incontinence but none of them are universally acceptable or applicable.

Based on the assessment, patients are categorized into three groups:

1. *Patients with constipation and pseudoincontinence:* This group consists of patients with low ARM, cloaca with common channel <3 cm length, those with well-developed sphincter complex, and those who underwent an otherwise technically sound repair. In fact, good continence leading to constipation, fecaloma, and secondary megarectum is the cause of trouble. It is best avoided by treating constipation by laxatives, dietary adjustments, and routine rectal washouts for several years after surgery until the bowel regains regular evacuation. Persistent constipation may require surgical resection or reduction of megarectum.
2. *Patients with true incontinence of technical origin:* These patients who have otherwise good prospects of excellent continence suffer incontinence due to technical inadequacy of repair. MRI frequently confirms the rectum having been routed outside or eccentrically to one side of the sphincter complex. They may be benefited by a redo surgery to reroute the misplaced rectum.

Patients with a poor prognosis malformation, sacral anomalies, poor sphincter, and excised rectum do

JAYPEE BROTHERS

TABLE 39.7: Evaluation of a patient with incontinence after definitive surgery for anorectal malformation (ARM).

Assessment criteria	*True incontinence*	*Pseudoincontinence*
Clinical assessment: • Anal stenosis • Anal tone • Palpable fecaloma • Sacrum	• Present • Poor • Absent • Deficient	• Absent • Good • Present • May be intact
Radiological assessment: • Fecal mass in plain X-ray • Spine X-ray • MRI spine • MRI of pelvis • Contrast enema • Anal endosonography	• Absent • Vertebral bone may be defective • May have abnormal cord • Poorly developed sphincter or pulled through rectum lying outside the sphincter • Normal appearing rectum (Similar to MRI)	• Present • May have normal vertebra • Tethered cord common • Well-developed sphincter and rectum within it • Hugely dilated rectum (secondary rectal ectasia) (Similar to MRI)
Electromanometry: • Electromyography • Manometry	• Poor electrical activity of sphincters • Reflex relaxation of distended rectum and contraction on command are absent	• Good electrical activity of sphincters • Relaxation is impaired but contraction maintained

(MRI: magnetic resonance imaging)

TABLE 39.8: Bowel management program.

Patient type	*True incontinence*	*Pseudoincontinence*
Initial management	• Parental counseling • Aggressive emptying of colon by repeated enemas within 1-week (normal saline enema, glycerine, soapy water, and phosphate enema can be chosen according to the age) • Monitoring of bowel cleansing by daily X-rays	
Dietary advice	Constipating diet	Laxative diet
Medications	• Antidiarrheal (e.g., loperamide) • Bulk-forming agents (e.g., pectins)	Oral laxatives (e.g., lactulose, paraffin)
Enema	Small nonconcentrated type	Daily enema if unresponsive to above
Surgery	Malone antegrade colonic enema (MACE) procedure, gracilis sling, artificial sphincter	Resection of the megacolon

not fare better after a redo procedure. Patients with hypoplastic muscles and flat perineum may require reinforcement and substitution of levator ani muscle.

3. *Patients with true incontinence of biological origin:* Patients with long-channel cloaca, sacral anomalies, hypoplastic sphincters, flat perineum, and associated spinal defects belong to this group. They are unlikely to benefit from a redo procedure. They are better treated by "bowel management program (BMP)" **(Table 39.8)**. BMP is an artificial method of making incontinent patients socially acceptable by periodic evacuation of bowel thereby creating a pseudo-continent state. BMP of true incontinence (hypermotile colon) and pseudoincontinence (hypomotile colon) differs considerably. The program also needs modification for the individual patient as per age, dietary preferences, parental compliance, and social circumstances. Alternatively, patients with persistent true incontinence may be subjected to experimental treatments. Sphincter substituting procedures such as gracilis muscle flap plasty, autobionic dynamic graciloplasty, and exobionic implanting have been described. However, all these procedures have very high complication rates and their long-term efficacy is not well documented.

Bowel dysfunction, either constipation or incontinence, improved significantly during adolescence. Proper bowel management program and dietary adjustments results in a reasonably good quality of life.

JAYPEE BROTHERS

Urinary Function

Patients with sacral anomalies and those having operative injury to pelvic nerves develop life-long urinary incontinence. They are best managed by CIC. Mitrofanoff stoma and bladder augmentation may facilitate CIC. Recurrent UTI may require uroprophylaxis or antibiotic treatment.

Sexual Function

In 40% of males with high or intermediate ARM and sacral anomalies, erectile dysfunction, and impaired ejaculation are noted. Operative injury to vas and nerve erigentes also contributes to male infertility and erectile dysfunction. Vaginal and uterine septa, vaginal agenesis, and stenosis of neovagina are responsible for female infertility and dyspareunia.

Impaired Growth and Development

Children with ARM are at risk for gross-growth deficits, developmental delays, and motor dysfunction. Hence, monitoring their nutritional status and periodic developmental assessment are essential for comprehensive physical and mental development.

CONCLUSION

Anorectal malformations encompass a wide spectrum of congenital anomalies involving the distal rectum and anus, often associated with genitourinary and spinal anomalies. With advances in embryological understanding, surgical anatomy, and operative techniques—especially PSARP and minimally invasive approaches—treatment outcomes have significantly improved. Tailored surgical strategies, early diagnosis, and long-term bowel management programs are critical for ensuring optimal functional and psychosocial outcomes in these children.

A brief decision-making algorithms for male and female neonates with ARM are depicted in **Flowcharts 39.1 and 39.2**.

Flowchart 39.1: Algorithm for management of female anorectal malformation (ARM).

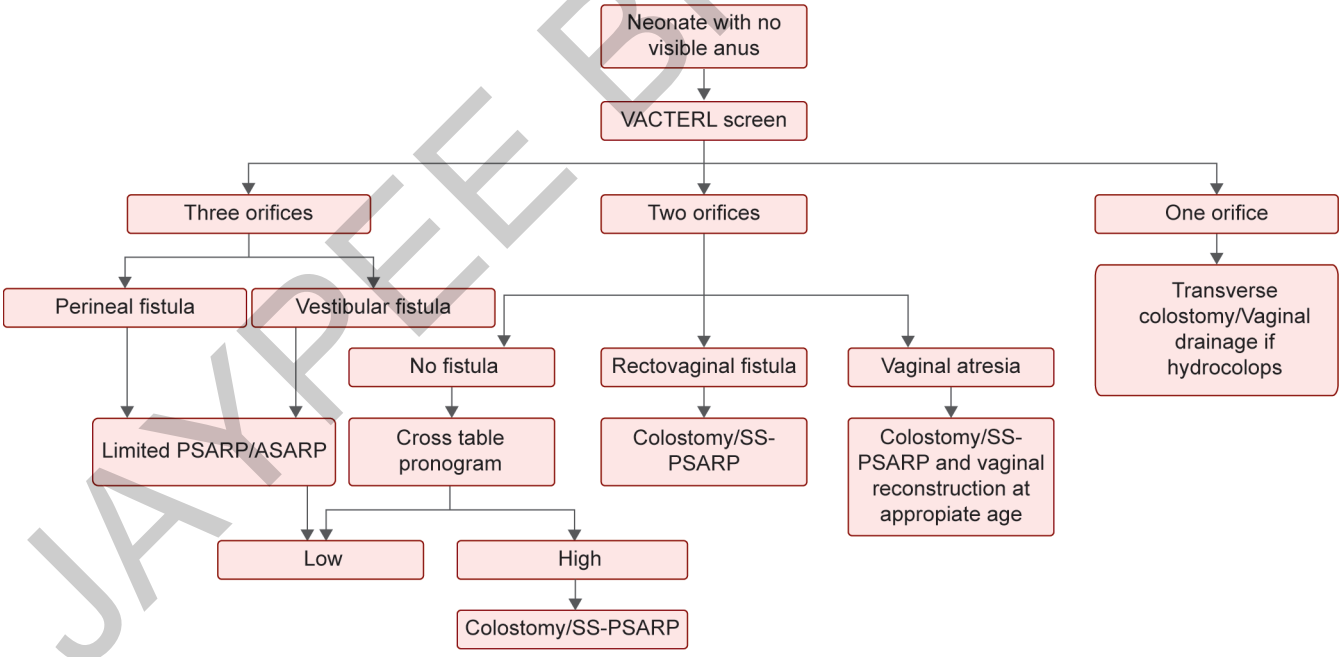

1. SS-PSARP: Single stage posterior sagittal anorectoplasty (applicable only if baby is stable and surgeon is technically experienced).
2. Presence of pouch colon shall alter the mode of management in individualized manner.
3. Whenever in doubt about the location of fistula/technical expertise to perform definite procedure is not immediately available, then a diversion should be performed.

(ASARP: anterior sagittal anorectoplasty; VACTERL: vertebral defects, anal atresia, cardiac defects, tracheoesophageal fistula, renal anomalies, and limb abnormalities)

JAYPEE BROTHERS

Flowchart 39.2: Algorithm for management of male anorectal malformations (ARM).

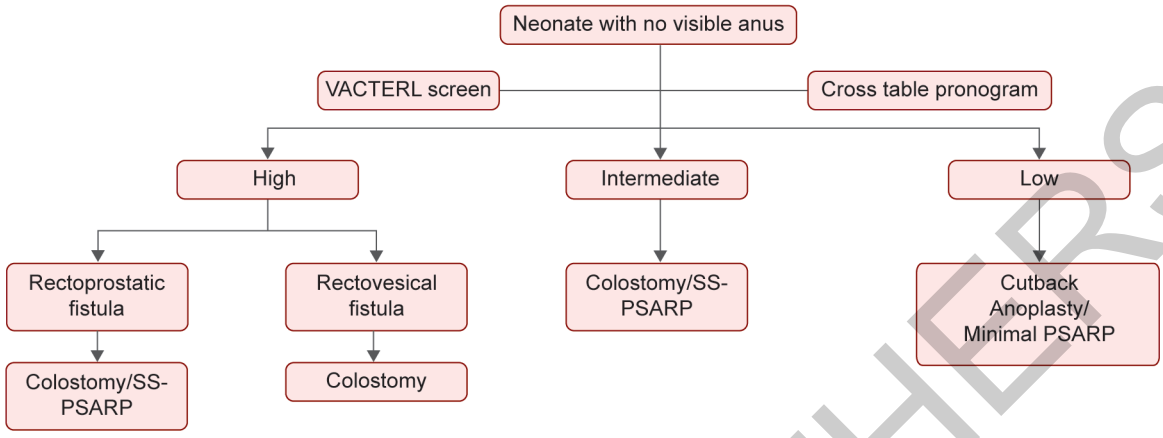

1. SS-PSARP: Single stage posterior sagittal anorectoplasty (applicable only if baby is stable and surgeon is technically experienced).
2. Presence of pouch colon shall alter the mode of management in individualized manner.
3. Whenever in doubt about the location of fistula/technical expertise to perform definite procedure is not immediately available, then a diversion should be performed.

(ASARP: anterior sagittal anorectoplasty; VACTERL: vertebral defects, anal atresia, cardiac defects, tracheoesophageal fistula, renal anomalies, and limb abnormalities)

KEY POINTS

- *Incidence and geography:* ARM affects 2–2.5 per 10,000 live births, with higher frequency in males and increased incidence of pouch colon in North India and rectal atresia in South India.
- *Common fistulas:* Most common in males is rectourethral fistula (bulbar > prostatic); in females, it is anovestibular fistula.
- *Genetics and risk factors:* SHH, EN2, and HLXB9 mutations on chromosome 7q are implicated; thalidomide and maternal infections [e.g., cytomegalovirus (CMV)] increase risk.
- *Radiological assessment:* Cross-table lateral X-ray at 18–24 hours distinguishes high, intermediate, and low ARM based on rectal gas in relation to PC and "I" lines.
- *Sacral ratio:* Calculated on anteroposterior (AP)/lateral X-ray; values <0.74 (AP) or <0.77 (lateral) predict poor neuromuscular development and continence prognosis.
- *Staged versus single-stage repair:* Single-stage PSARP or LARP is preferred in stable neonates with low/intermediate ARM; staged repair indicated in high ARM or sick infants.
- *Pouch colon:* Characterized by a massively dilated pouch colon with fistulous urogenital communication; requires pouch excision, not coloplasty.
- *Rectal atresia:* Normal anus with blind-ending rectum; Hegar or catheter-based diagnosis. Managed by transanal or staged pull-through depending on gap.
- *Posterior cloaca:* Rare variant with normal anus but shared vaginal-urethral sinus opening posteriorly. Treated by urogenital mobilization, preserving anorectal continuity.
- *Perineal canal:* A female-specific tunnel between vagina and stenosed anus, often recurrently infected; treated with vestibuloanal pull-through or limited PSARP.
- *MRI in planning:* Used to assess sphincter complex development and rectal positioning, especially in redo surgeries or cloaca repair.
- *Fecal incontinence types:*
  - *Pseudoincontinence:* Due to constipation/megarectum in low ARM.
  - *True incontinence:* Due to high ARM, poor sacrum, or technical failure.
  - *Biological incontinence:* Due to cloaca, hypoplastic sphincters.
- *Bowel management program:* Tailored based on colon motility; includes enemas, dietary adjustments, laxatives (pseudo), or antidiarrheals (true incontinence).
- *Postoperative dilatation:* Begins 2 weeks postdefinitive surgery; crucial to prevent neoanal stenosis and prolapse. Continued until colostomy closure and for years afterward.

JAYPEE BROTHERS

FURTHER READING

1. Agrawal V, Gupta S, Liêm NT, Acharya H, Sharma D. Laparoscopic-assisted modified posterior sagittal anorectoplasty for rectobulbar urethral fistula of anorectal malformation: A prospective study. J Indian Assoc Pediatr Surg. 2022;27(2):216-22.
2. Agrawal V, Sharma D, Tiwari A, Mishra R, Acharya H. Transperineal intracath meconiolysis and evacuation technique of "distended" bowel evacuation for one-stage laparoscopic anorectoplasty for high anorectal malformations in males. J Laparoendosc Adv Surg Tech A. 2020; 30(6):701-5.
3. Agrawal V, Sulya D, Acharya H, Tiwari A, Sharma D. Impact of "Lateralizing" the Sigmoid Colostomy on Port Ergonomics in Laparoscopic Anorectoplasty for High Anorectal Malformations. Eur J Pediatr Surg. 2022;32(2):177-83.
4. Agrawal V, Tiwari A, Sharma D, Mishra R, Acharya H. Comparison of 3D vs 2D laparoscopic-assisted anorectal pull-through (LAARP) for high anorectal malformations in children. Asian J Endosc Surg. 2021;14(3):424-31.
5. Bhatnagar V. Assessment of postoperative results in anorectal malformations. J Indian Assoc Pediatr Surg. 2005; 10(2):80-5.
6. Bischoff A, Levitt MA, Bauer C, Jackson L, Holder M, Peña A. Treatment of fecal incontinence with a comprehensive bowel management program. J Pediatr Surg. 2009;44(6):1278-84.
7. Boemers TML, Beek FJA, Bax NMA. Guidelines for the urological screening and initial management of lower urinary tract dysfunction in children with anorectal malformations— the ARGUS protocol. BJU Int. 1999; 83(6):662-71.
8. Chadha R, Bagga D, Malhotra CJ, Mohta A, Dhar A, Kumar A. The embryology and management of congenital pouch colon associated with anorectal agenesis. J Pediatr Surg. 1994;29(3):439-46.
9. Dorairajan T. Anorectal atresia. In: Stephens FD, Smith ED, Paul NW (Eds). Anorectal Malformations in Children. New York, NY: Liss; 1988. pp. 105-10.
10. Gangopadhyay AN, Pandey V. Anorectal malformations. J Indian Assoc Pediatr Surg. 2015;20(1):10-5.
11. Gupta DK, Sharma S. Congenital pouch colon—then and now. J Indian Assoc Pediatr Surg. 2007;12(1):5-12.
12. Hutson JM, Holschneider AM (Eds). Anorectal Malformations. Heidelberg: Springer; 2006.
13. Levitt MA, Pena A. Anorectal malformations. Orphanet J Rare Dis. 2007;2:33-46.
14. Levitt MA, Pena A. Cloacal malformations: lessons learned from 490 cases. Semin Pediatr Surg. 2010;19(2):128-38.
15. Pena A, Bischoff A, Breech L, Louden E, Levitt MA. Posterior cloaca—further experience and guidelines for the treatment of an unusual anorectal malformation. J Pediatr Surg. 2010;45(6):1234-40.
16. Pena A. Anorectal malformations. Semin Pediatr Surg. 1995;4(1):35-47.
17. Spouge D, Baird PA. Imperforate anus in 700,000 consecutive live-born infants. Am J Med Genet. 1986; (Suppl 2):151-61.

JAYPEE BROTHERS

for detailed information on pediatric books, visit our website www.ejaypee.com, for detailed information on pediatric books, visit our website www.ejaypee.com, for detailed information

IAPS Textbook of PEDIATRIC SURGERY

Salient Features

- *Diamond Jubilee Edition:* Released in the 60th year of IAPS, marking six decades of academic and professional excellence
- *Comprehensive Coverage:* Contains 108 chapters encompassing the whole spectrum of pediatric surgery
- *Evidence-based Content:* Chapters written and reviewed by leading experts with focus on evidence-based practice
- *Practical Orientation:* Includes algorithms, stepwise approaches, and case-based discussions for real-life surgical decision-making
- *Enhanced Learning Tools:* Case scenarios, key points, illustrations, and videos make it learner-friendly and engaging
- *Multigenerational Editorial Team:* A blend of senior wisdom, mid-career evidence-driven approach, and youthful innovation
- *Continuity of Vision:* Built upon the foundation of the first edition with guidance from its editors, symbolizing growth and academic continuity
- *Completely Indian Authorship:* Conceived, written, and edited entirely by Indian pediatric surgeons, showcasing national expertise globally
- *Trusted Reference:* Designed not only for postgraduate students and trainees but also as a dependable reference for practicing pediatric surgeons
- *Spirit of IAPS:* The cover and design reflect unity, science, knowledge, and compassion with IAPS at the center, symbolizing the association's philosophy



Ramesh Babu MS MCh FRCS (Glas) FRCS (Edin) FRCS (Paed) FIAPS, FSPU PhD (Paed Urol) currently serves as Professor and Course Director of Pediatric Urology at Sri Ramachandra Institute of Higher Education and Research, Chennai, Tamil Nadu, India. He served as the Chairman of Society of Pediatric Urology (SPU) and the President of Indian Association of Pediatric Surgeons (IAPS). He is a Reviewer in many international journals and is an editorial board Member of Pediatric Surgery International. He is a Member of several reputed associations like ESPU and HIS. He has authored over 120 peer-reviewed publications, written five textbooks, and has a notable H-index of 20.



Sumitra Kumar Biswas MS MCh is the President of Indian Association of Pediatric Surgeons (IAPS). He is currently working as a Professor in the Department of Pediatric Surgery, NRS Medical College and Hospital, Kolkata, West Bengal, India, after retiring from West Bengal Medical Education Service as Professor and Head of the Department of Pediatric Surgery, Nil Ratan Sircar Medical College, Kolkata. He served at various educational bodies during his service and published more than 50 papers in national and international journals. Since 1985, he has been active in IAPS and was Member of the EC of IAPS and Research Section. In 35 years of his career as Teacher, he shaped the future of numerous students as surgeons and pediatric surgeons.



Vikesh Agrawal MS MCh FSPU FIAPS is Professor and Head, Department of Pediatric Surgery, Netaji Subhash Chandra Bose Government Medical College, Jabalpur, Madhya Pradesh, India, and Secretary General of the Indian Association of Pediatric Surgeons (IAPS). He is Ex-Scholar in Pediatric Urology at the University of Michigan, USA. With over 100 publications, book chapters, and editorial contributions, he earlier served as Founder Honorary Secretary and Chair of the Society of Pediatric Urology of IAPS and as Deputy Registrar (Academics) at Madhya Pradesh Medical Science University. He has been instrumental in revitalizing the new IAPS, fostering Yuva leadership under senior mentorship, and leading the Second Edition of the *IAPS Textbook of Pediatric Surgery*. His blend of academic excellence, institutional leadership, and social commitment—evident in over 2,500 surgeries in underserved areas and the establishment of India's first NHM-funded Pediatric Surgery Unit—embodies his vision of *Evidence, Eminence, and Expectations* in modern pediatric surgery.

Shelving Recommendation
PEDIATRIC

ISBN 978-93-6616-041-2

Buy from ejaypee

JAYPEE BROTHERS