visit our website www.jaypeebrothers.com, for detailed information on otolaryngology books, visit our website www.jaypeebrothers.com

diginerve®
A Jaypee Initiative
• Video Lectures • Dr. Wise AI Chatbot
• Question Bank • Notes
Download App

5th Edition

Practical ENT





As per the Competency-based Medical Education Curriculum (NMC)

Vikas Sinha

JAYPEE

Contents

Chapter 1: History Taking in ENT 1

Chapter 2: History and Examination of Ear 5

Chapter 3: History and Examination of Nose and Paranasal Sinuses 36

Chapter 4: Examination of Oral Cavity 60

Chapter 5: Examination of Salivary Glands 68

Chapter 6: Examination of Tonsil and Pharynx 70

Chapter 7: Examination of Larynx 76

Chapter 8: Examination of Neck (Excluding the Thyroid Gland) 93

Chapter 9: Examination of Thyroid Gland 100

Chapter 10: Examination of Cranial Nerves 104

Chapter 11: Images in ENT 112

Chapter 12: Informed Consent 117

Chapter 13: Operations in ENT 119

- Tonsillectomy *119*
- Adenoidectomy *123*
- Mastoidectomy *124*
- Tympanoplasty *127*
- Myringotomy *130*
- Tracheostomy *131*
- Esophagoscopy *137*
- Bronchoscopy *139*
- Laryngoscopy *141*
- Antral Puncture Washout *142*
- Rules of Correct Aseptic Surgical Procedure *143*

Chapter 14: Audiology 150

- Pure Tone Audiometry *152*
- Impedance Audiometry (Tympanometry) *156*

Chapter 15: Calorimetry 160

Chapter 16: Applied Anatomy of Bones 163

Chapter 17: Instruments 168

- Index of ENT Instruments *168*
- Bull's Eye Lamp *171*
- Instruments for Tonsil and Throat Surgery *173*
- Instruments for Nasal and Sinus Surgery *178*
- Instruments for Ear Surgery *185*
- Instruments for Larynx, Trachea and Esophagus *192*

Chapter 18: Frequently Asked Questions (FAQs) **198**
- ❖ Ear *198*
- ❖ Nose and Sinuses *206*
- ❖ Tonsil *215*
- ❖ Larynx *221*
- ❖ Cranial Nerves *223*

Chapter 19: Case Presentation in ENT **225**

Index *231*

2 CHAPTER

History and Examination of Ear

COMPLAINTS (EN 2.1, EN 2.3)

Complaints are being recorded in the chronological order, i.e., the complaint, which occurred first, should be recorded first, the subsequent complaints next in the descending order.

For example

- Ear discharge for last 2 years
- Deafness for last 1 year
- Vertigo for 8 months
- Pain, headache for 4 months
- Ringing in the ear for 15 days
- Facial asymmetry for 5 days.

The complaints should be recorded in that order only, as discharge was the first complaint, so it should be recorded first followed by deafness, vertigo, pain, headache, and so on.

HISTORY OF PRESENTING ILLNESS (EN 2.1, EN 2.3)

i. **Discharge**
ii. **Deafness**
iii. **Vertigo**
iv. **Pain**
v. **Tinnitus**
vi. **Autophony**
vii. **Facial nerve palsy**
viii. **Fever**
ix. **Headache**

JAYPEE BROTHERS

i. **Discharge (EN 4.6):** Following points are to be observed:

1. **Smell:**
   - Foul smelling discharge indicates squamous (atticoantral/unsafe) type of otitis media (suspicion of cholesteatoma). Mucosal (tubotympanic/safe) type of otitis media can also have foul smelling discharge if it is secondarily infected
   - Non-foul smelling discharge indicates mucosal (tubotympanic/safe) type of otitis media.
2. **Consistency:**
   - If discharge forms a string, it indicates the discharge from the middle ear as mucus secretory glands (Goblet cells) are present only in the middle ear
   - If discharge is non-string forming, it indicates discharge from the external ear, as no mucus secretory glands are present in the external ear. This discharge may be due to furunculosis or rarely from the parotid abscess.
3. **Color:**
   - The normal color of pus is creamish yellow. In pseudomonas infection, it is greenish in color.
4. **Blood Stained Discharge:**
   - In mucosal (tubotympanic/safe) type disease, the discharge is not blood stained. If it is blood stained, it indicates presence of granulation tissue in the middle ear, which is more common in squamous (atticoantral/unsafe) type of otitis media. The blood stained discharge may also present in underlying malignancy.
5. **Watery Discharge:**
   - Clear watery discharge occurs in cerebrospinal fluid (CSF) otorrhea.
6. **Quantity:**
   - Scanty discharge indicates squamous (atticoantral/unsafe) type of otitis media while moderate to profuse discharge points towards mucosal (tubotympanic/safe) type of otitis media.
     - Profuse discharge: If discharge comes out of ear canal and stains the pillow during sleep
     - Moderate discharge: If discharge remains in the external auditory canal
     - Scanty discharge: If the tip of swab stick is stained by the discharge.
7. **Active /Inactive /Quiescent Stage of Discharge:**
   - Active stage: If discharge is present

JAYPEE BROTHERS

- Inactive stage: If discharge is not present for minimum 3–6 weeks
- Quiescent stage: If discharge is absent for a few days but reappears in between and again.

ii. Deafness (EN 4.12): Following points are to be observed:

1. Sudden or gradual deafness: Gradual deafness occurs in chronic suppurative otitis media (CSOM) while sudden deafness occurs in viral diseases or in fracture of the temporal bone
2. Degree of deafness: Mild, moderate or severe type of deafness. (Details can be found in the tuning fork test)
3. Fluctuation of deafness: Fluctuating deafness occurs in secretory otitis media as different head position causes difference in deafness, especially when fluid is thin. Hearing is usually better in supine position when patient is lying on the bed but alters on getting up (erect position). Fluctuation of deafness also occurs in Meniere's disease and in perilymph fistula
4. Deafness at the time of discharge: Does deafness increase or decrease at the time of discharge? Usually at the time of discharge deafness should increase as it means flare-up of disease. But in case of ossicular disruption, discharging fluid inside the middle ear causes good medium for the sound transmission and patient may find improvement of hearing at the time of discharge
5. Deafness at crowded place: In otosclerosis, patient hears better in the crowded place; this is called Paracusis Willisii
6. Distortion of sound: Sound is heard at different pitch in the affected ear. It is called diplacusis and occurs in Meniere's disease
7. Alteration of deafness with vertigo: In Meniere's disease before the onset of vertigo, deafness increases but returns to near normal after the attack of vertigo. But with every subsequent attack of vertigo, hearing deteriorates and deafness increases (which is of sensorineural type).

iii. Vertigo (EN 4.19): It is the false sense of orientation.

Following points are to be observed:

1. Presence or absence of vertigo: Presence of vertigo with ear discharge indicates intracranial or threatening intracranial complications
2. Types of vertigo: Patient himself is moving, the surrounding is moving, sense of unsteadiness, sensation of to-and-fro, up-and-down movement or falling off suddenly (known as "drop attacks" or "utricular crises")

JAYPEE BROTHERS

All these types of vertigo are present in Meniere's disease.
(Meniere's disease: It is a disorder of endolymphatic labyrinth characterized by attacks of vertigo, deafness, and tinnitus.)

3. Vertigo in particular position: Benign positional paroxysmal vertigo (BPPV) causes vertigo in particular head position
4. Vertigo with deafness: Deafness increases before the onset of vertigo in Meniere's disease
5. Vertigo without deafness: Occurs typically in vestibular neuronitis
6. Vertigo associated with neck movements: In cervical spondylosis, the compression of vertebral artery by the osteophytes may cause vertigo.

iv. Pain (EN 4.1):

1. Nature of pain: Sharp, throbbing or lancinating pain occurs in acute otitis media. Continuous, dull throbbing pain occurs in furunculosis of ear.
2. Site of pain:
   - Pain in front of ear at tragus is probably due to furunculosis
   - Pain deep inside the ear is probably due to middle ear
   - Pain behind the ear at the mastoid tip may be due to infected gland at the mastoid region
   - Pain below the ear in the cleft between ramus of mandible and mastoid process is frequently due to the eustachian tube infection (called salpingitis) or it may arise from the parotid region.

   Referred pain: *Five T's for referred otalgia: (1) Tongue, (2) Teeth, (3) Tonsil, (4) Temporomandibular joint, (5) Throat, i.e., pharynx and larynx*
   (Referred otalgia occurs as the sensory center of the mandibular nerve receives impulses from the lingual as well as auriculotemporal nerve)
3. Chewing movement: Chewing movement increases the pain in furunculosis.

v. Tinnitus (EN 4.21):

It is the subjective sensation of sound in the ear. Just as pain is the sign of irritation of the sensory nerves, tinnitus is the sign of irritation of the cochlear mechanism.

JAYPEE BROTHERS

1. Types of Tinnitus:
   a. Subjective tinnitus: Subjective tinnitus is audible only to the patient and usually indicates an abnormality in the
      i. Auditory system, for example, acoustic neuroma, Meniere's disease; drugs like aspirin and quinine
      ii. Systemic diseases like anemia, hypertension, and diabetes mellitus.
   b. Objective tinnitus: Objective tinnitus can be heard by examiner as well as by the patient himself and is often due to the pathology outside the ear like palatal myoclonus, glomus tumor.
2. Unilateral/bilateral tinnitus: Acoustic neuroma produces unilateral tinnitus, while in otosclerosis, there is usually bilateral tinnitus
3. Tinnitus with vertigo: Before the onset of vertigo in Meniere's disease, tinnitus increases and it is at times the warning signal to the patient about impending vertigo
4. Tinnitus with deafness: It occurs in Meniere's disease and occasionally in otosclerosis
5. High-pitched tinnitus: It occurs in acute suppurative otitis media (ASOM).

vi. Autophony:

Feeling of excessive loudness of one's own voice occurs in acute suppurative and nonsuppurative otitis media, and patulous eustachian tube.

vii. Facial Asymmetry (Facial Nerve Palsy) (EN 4.18):

1. Facial nerve palsy with ear discharge: In squamous (atticoantral/unsafe) type of otitis media, cholesteatoma may cause facial nerve palsy
2. Facial nerve palsy with deafness: It occurs in acoustic neuroma
3. Facial nerve palsy with intact, normal tympanic membrane and without any history of ear discharge occurs in Bell's palsy.

viii. Fever:

Fever is present in ASOM and acute mastoiditis.

ix. Headache:

Headache is present in brain abscess and lateral sinus thrombophlebitis.

JAYPEE BROTHERS

EXAMINATION OF EAR (EN 2.2)

The examination of ear is carried out with Bull's eye lamp and forehead mirror. The Bull's eye lamp is kept on the left side of patient approximately 1 foot away from the patient at the level of Pinna.

Method of Examination

The patient should sit very erect with his head 10-12 inches forward from the back of the chair. While examining the patient, surgeon's both legs should be together on the right side so that patient can walk to the examination place and sit down on the stool without doctor changing his position and legs. For the examination of ear, the light should be focused at the tragus through forehead mirror.

Otoscopic Examination (EN 2.3)

For Otoscopic examination of the right ear, pull the Pinna with left hand. Hold the otoscope with right hand with little fingers resting on the cheek of the patient, so that, if patient moves the head otoscope also moves along with the ear without causing pain to the patient (Refer to Chapter 17 Instruments **Fig. 3** Page 172)

Box 1: Examine the following things.

1. Pinna—Size, any congenital anomaly, level of two Pinna
2. Pre-auricular region—Pre-auricular sinus, Accessory tragus
3. Post-auricular region—Scar of previous surgery, edema of post auricular region (Griesinger sign), any swelling or fistula, any lymph node, "ironing of mastoid"
4. Post-auricular sulcus—Obliterated in furunculosis by edema
5. Protrusion of Pinna—"Erection of Pinna"
6. Tenderness—Tenderness at mastoid process and at cymba conchae, Tenderness of tragus (Tragus sign)
7. External auditory canal—Pinna is pulled upward, outward and backward to make external auditory canal straight in adults but in children Pinna is pulled downward and backward to make external auditory canal straight. Examine the external auditory canal for the presence of wax, fungus, foreign body or any abnormality like collaural fistula, atresia or fissures of Santorini, etc.
8. Tympanic membrane—Observe the following things:
   a. Color of tympanic membrane
   b. Perforation
      i. Types: Central, Subtotal, Marginal perforation, Attic perforation
      ii. Number of perforation
      iii. Size of perforation

JAYPEE BROTHERS

iv. Margin of perforation
v. Shape of perforation
vi. Site of perforation
vii. Middle ear mucosa
viii. Coralization

c. Handle of malleus—normal, foreshortened
d. Cone of light—present or absent
e. Quadrant of tympanic membrane
f. Granulation or polyp
g. Retraction pocket
h. Incudostapedial joint
i. Congestion- "Cartwheel appearance"
j. Mobility of tympanic membrane

9. Fistula test
10. Examination of Facial Nerve
11. Tunning Fork Test- Rinne's test, Weber's test, Absolute Bone Conduction Test (ABC Test)

i. Pinna (EN 4.2):

1. Size of pinna:
   - Normal size pinna
   - Large pinna is called macrotia
   - Small pinna is called microtia
   - Absence of pinna is called anotia.

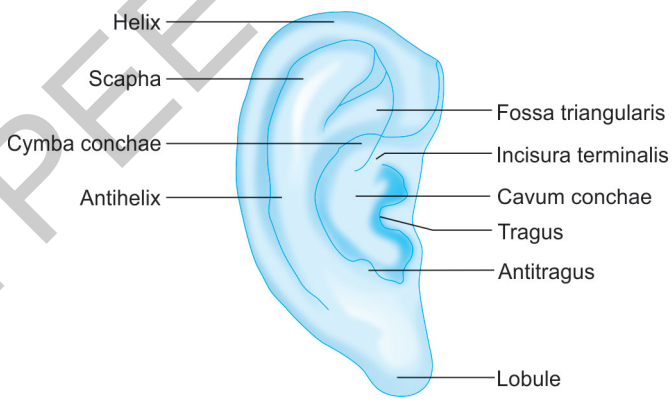

Fig. 1: Pinna.

2. Congenital anomaly like:
   - Prominent Darwin tubercle (i.e., tubercle present at upper part of helix)
   - Bat ear (i.e., absence of antihelix)
   - Wildermuth ear (when antihelix is more prominent than helix).

JAYPEE BROTHERS

3. Thickened or cauliflower pinna is the end result of perichondritis of pinna.
4. Low set of ears: The upper limit of pinna corresponds to level of eyebrow and the lower limit corresponds to the base of alae nasi. The horizontal interpalpebral line projected posteriorly if it passes above the ear, it suggests the low set of ear. It occurs in Treacher Collins syndrome.

(Treacher Collins' syndrome consists of deformed malar bones, lower eyelids notched, deficient lashes medially, microtia and meatal stenosis or atresia with malformation of middle and/or inner ear.)

ii. Pre-auricular Region (EN 4.2): Observe the presence or absence of:

1. Pre-auricular sinus
   (Pre-auricular sinus occurs due to the incomplete fusion of auricular tubercle.)
2. Accessory tragus
   (Accessory tragus is due to the presence of auricular tubercle on other part of first or second cleft depression.)

iii. Post-auricular Region (EN 4.2): Observe:

1. Scar of previous surgery
2. Edema at post-auricular region. It is called Griesinger's sign. It is due to thrombosis of mastoid emissary vein and indicating thrombophlebitis of the sigmoid sinus. *This clinical sign is named after "Wilhelm Griesinger", a German psychiatrist and neurologist*
3. Any swelling or fistula
4. Any lymph node
5. Palpate the mastoid process. In acute mastoiditis, the periosteum of mastoid process is thickened due to periostitis called "ironing of mastoid".

iv. Post-auricular Sulcus (EN 4.2):

Post-auricular sulcus is obliterated in furunculosis by edema if the boil is situated on the posterior surface of external auditory canal but post-auricular sulcus is maintained in mastoid abscess.

v. Protrusion of Pinna (EN 4.2):

Pinna is forward and outward in furunculosis while forward, outward and downward in mastoid abscess ("erection of pinna") **(Fig. 2)**.

JAYPEE BROTHERS



Fig. 2: Right pinna in acute subperiosteal mastoid abscess.

Table 1: Difference between furunculosis edema and acute otitis media with mastoiditis.

Furunculosis	*Acute otitis media with mastoiditis*
1. *Presence of boil with normal tympanic membrane*	1. *There is no boil and tympanic membrane is congested*
2. *Pain is dull throbbing till boil is incised or bursts with scanty yellow discharge*	2. *Sharp piercing pain with mucus discharge from the ear*
3. *Movement of pinna and pressure on tragus increases the pain*	3. *Not so in otitis media*
4. *Hearing improves after introducing small size ear speculum*	4. *Hearing is altered*
5. *Obliteration of postauricular sulcus*	5. *Postauricular sulcus is not altered*
6. *Pinna is pushed forward and outward*	6. *Pinna is pushed forward, outward and downward*
7. *Both the pinna are at the same level if looked from behind*	7. *Affected pinna is at a lower level*
8. *Mastoid X-ray is normal*	8. *Mastoid X-ray may show cloudiness of mastoid air cells*

vi. Tenderness: Examine the:

1. Tenderness at the mastoid process and at the cymba conchae. Tenderness at this region signifies mastoiditis

   Three-finger test: Keep one finger at cymba conchae, second finger over posterior border of mastoid and third finger at mastoid tip. Maximum tenderness under first finger signifies tenderness over suprameatal triangle.

JAYPEE BROTHERS

(The surgical importance of cymba conchae is that suprameatal triangle lies under it and can be felt through it. The mastoid antrum lies deep to the triangle.)

2. Tenderness of tragus (Tragus sign) indicates furunculosis at the anterior wall of external auditory canal
3. Tenderness of pinna indicates perichondritis.

(Tenderness along the course of internal jugular vein in the neck and localized edema over the thrombosing internal jugular vein is seen in lateral sinus thrombophlebitis.)

Furunculosis: It is a staphylococcal infection of hair follicles or sebaceous glands present in the skin of outer cartilaginous part of the external auditory canal. It is treated by antibiotic and local wick of 10% ichthammol glycerine.

Mastoidism: Presence of mastoid tenderness without mastoiditis is called "mastoidism". It occurs in ASOM in first few days due to tension in the middle ear. The tenderness disappears after tension is relieved in the middle ear.

Meningismus: Localized meningitis without viable organism in the spinal fluid

vii. External Auditory Canal (EN 4.2):

Pinna is pulled upward, outward and backward to make external auditory canal straight in adults but in children, bony canal is not developed so pinna has to be pulled downward and backward to make external auditory canal straight. Examine the external auditory canal for the presence of wax, fungus, discharge, keratosis obturans, osteoma, foreign body, or any abnormality like collaural fistula, atresia or fissures of Santorini, etc.

Wax: Wax is the accumulated secretion from ceruminous glands. The impacted wax may cause pain, deafness, tinnitus, and even vertigo. It is softened by glycerine-sodium bicarbonate ear drops and removed by aural syringing.

Fungus: It is called otomycosis. It is caused by Aspergillus niger (black colored) and Candida albicans (white colored).

Collaural fistulae: It has an upper opening in the floor of external auditory meatus and a lower opening behind the angle of jaw at the anterior border of sternomastoid.

Exostoses: It is the most common benign tumor in the meatus. It arises from the posterior wall of bony meatus as rounded swelling. The repeated entry of cold water into the external meatus in swimming and diving is the primary cause of this condition.

JAYPEE BROTHERS

Keratosis obturans: In this condition, meatus is blocked by a mass consisting of wax, desquamated epithelium and cholesterol. Its pressure effect causes absorption of bone and widening of the meatus. Mass is softened by sodium bicarbonate ear drop followed by syringing. Removal of mass is difficult and requires general anesthesia. The regular observation is necessary to prevent the reformation.

Malignant otitis externa: It usually occurs in elderly diabetic patient. Granulation tissue is found in the meatus at the junction of cartilaginous and bony canal. Seventh cranial nerve palsy may occur which is a bad prognostic sign. The treatment consists of aural toilet, local and intravenous gentamicin.

Fissure of Santorini: It is the deficiency of cartilaginous meatus and may provide a pathway for infection between the parotid gland, the external auditory canal and superficial mastoid tissue.

Foreign bodies in the ear: It may be insect—living or dead, maggots, plastic objects, or food grain. It is removed by aural syringing.

viii. Tympanic Membrane (Fig. 3) (EN 4.4):

The tympanic membrane separates the external ear from the middle ear and functionally is part of middle ear. It is pearly gray in color and oval in shape measuring about 9 mm in the horizontal and about 10 mm in vertical diameter. Total area of tympanic membrane is about 90 mm^2 with an effective vibrating area of 55 mm^2. The tympanic membrane at its periphery is attached to a bony ring called annulus tympanicus. The bony ring is deficient above—the notch of Rivinus and the drum attached to this part is called pars flaccida or Shrapnell's membrane (The Shrapnell's membrane is flaccid hence it is called pars flaccida.) The rest of drum is called pars tensa.

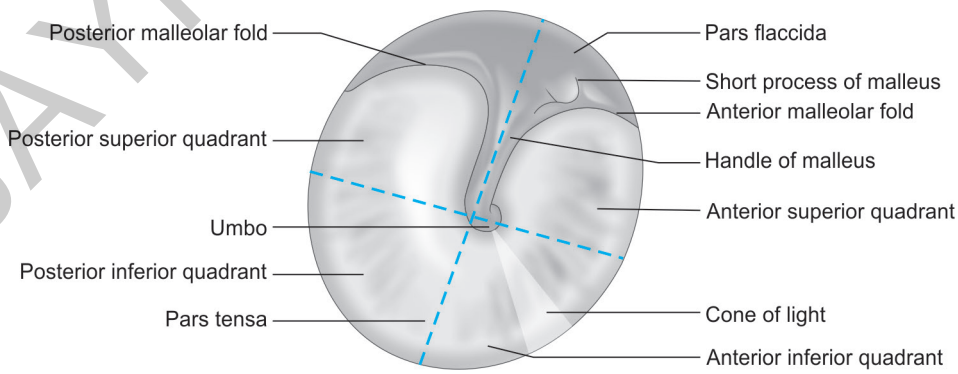

Fig. 3: Right tympanic membrane.

JAYPEE BROTHERS

Observe following things:

1. Color: Red and congested tympanic membrane is found in ASOM. Pale and amber color tympanic membrane may be found in few cases of secretory otitis media. Flamingo-pink blush (Schwartze sign) is seen in 10% cases of otosclerosis. It indicates active phase of the disease.
2. Perforation:
   i. Types of perforation: Central, marginal, or attic perforation

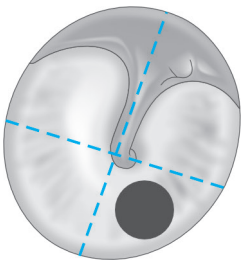

Fig. 4: Central perforation.

Central Perforation

Central perforation is that perforation which is found in pars tensa and surrounded all around by tympanic membrane **(Fig. 4)**. It is found in mucosal (tubotympanic/safe) type of otitis media.

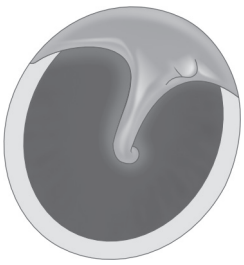

Fig. 5: Subtotal perforation.

Subtotal Perforation

Subtotal perforation: It is the large central perforation, and annulus is present only as a rim ***(Fig. 5)***

Total perforation: When annulus is not present and destroyed all around

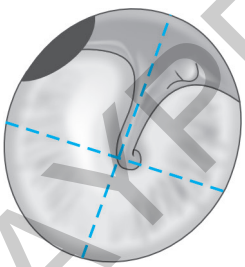

Fig. 6: Marginal perforation.

Marginal Perforation

Marginal perforation is that perforation which is not surrounded all around by tympanic membrane **(Fig. 6)**.

It is usually associated with secondary acquired cholesteatoma.

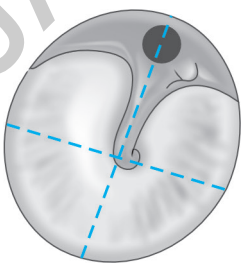

Fig. 7: Attic perforation.

Attic Perforation

Attic perforation is situated in the attic region **(Fig. 7)**. It indicates primary acquired cholesteatoma.

Marginal and attic perforations are found in squamous (atticoantral/unsafe) type of otitis media.

JAYPEE BROTHERS

for detailed information on otolaryngology books, visit our website www.jaypeebrothers.com, for detailed information on otolaryngol

Practical ENT

Salient Features

- Practical ENT book which is based on competency-based medical education curriculum of NMC.
- This book is truly practical, unique, and to the point. All important practical competencies are covered.
- An excellent resource for the undergraduate medical students commencing his/her ward posting and practical instruction in otolaryngology.
- A good refresher prior to the examination.
- The book would also serve as a useful resource for postgraduate students to reappraise them of the "must know" facts of the subject, especially so with regard to the sections on X-rays, operations, audiology, osteology, instruments, and FAQs.
- A very comprehensive synopsis of basic otolaryngology.
- The book elegantly captures the essence of ENT.

Vikas Sinha MBBS MS (ENT) passed MBBS in 1983 from Patliputra Medical College Dhanbad, Bihar, (Jharkhand), India and MS (ENT) in 1987 from Rajendra Medical College (RIMS), Ranchi, Bihar (Jharkhand). He was Lecturer ENT at Mahatma Gandhi Institute of Medical Sciences, Sevagram, Wardha, Maharashtra, India, and he is past Associate Professor, Professor and Head of the Department ENT at BJ Medical College Ahmedabad, Gujarat, India and afterwards Dean (Principal), Professor ENT at MP Shah Government Medical College, Jamnagar, Gujarat, Government Medical College, Bhavnagar, Gujarat, and Shantabaa Medical College, Amreli, Gujarat. He is Honorary ENT surgeon of Governor of Gujarat and was given a "Certificate of Honor" by the Association Otolaryngologists of India and Gujarat State Branch of Otolaryngologists of India, for writing the book, Practical ENT. He was the Honorary Editor of National Journal of Otorhinolaryngology and Head and Neck Surgery. He was awarded a fellowship for Rhinoplasty in 2006 at Asan Medical Center, Seoul, South Korea, and in 2007 at Marienhospital, Stuttgart, Germany. He is the National Faculty for Rhinoplasty and has been invited several times at state, national and international conferences of ENT to deliver lecture on Rhinoplasty. He has performed live surgery in India and abroad. He has also designed an award-winning innovative model for teaching bronchoscopy. He has several national and international papers and more than 100 publications in different journals in India. He is MBBS and MS Examiner of several universities in India and has been Medical Council of India assessor and DNB ENT examiner. He is the PhD guide in ENT. He was conferred with "Fellow of Otolaryngology" by the Indian Academy of Otorhinolaryngology—Head and Neck Surgery, listed in 6th Edition of Marquis Who's Who of US in Science and Engineering in 2002–2003. He was conferred with "Jewel of India" Award in 2009.

Printed in India

Available at all medical bookstores or buy online at www.ejaypee.com

JAYPEE BROTHERS
Medical Publishers (P) Ltd.
EMCA House, 23/23-B, Ansari Road,
Daryaganj, New Delhi - 110 002, INDIA
www.jaypeebrothers.com

Join us on facebook.com/JaypeeMedicalPublishers
Follow us on instagram.com/JaypeeMedicalPublishers

Shelving Recommendation
OTOLARYNGOLOGY

ISBN 978-93-6616-088-7