brothers.com, for detailed information on dental books, visit our website www.jaypeebrothers.com, for detailed information on dental books



Essential Manual of Preclinical Prosthodontics



Highlights

- Includes OSCE/OSPE types question answer useful for practical exam preparation
- Contains more than 1,100 high quality color illustrations

Paranjay Prajapati
Sneha Kulkarni

2nd Edition

JAYPEE

Contents

Section I: Complete Denture

1. **Overview of Prosthodontics.....3**
Paranjay Prajapati, Sneha Kulkarni
- ❑ Definition *3*
- ❑ Aims *3*
- ❑ Branches of Prosthodontics *4*
- ❑ Prosthesis: Types and Classification *4*

2. **Introduction to Complete Denture 8**
Sneha Kulkarni, Paranjay Prajapati
- ❑ Definition *8*
- ❑ Surfaces of Complete Denture *8*
- ❑ Parts of a Complete Denture *9*
- ❑ Steps in Fabrication of Complete Denture *12*

3. **Anatomical Landmarks..... 13**
Paranjay Prajapati, Sneha Kulkarni
- ❑ Definition *13*
- ❑ Objectives of Knowing the Anatomic Landmarks *13*
- ❑ Classification *13*

4. **Anatomical Landmarks: Edentulous Maxillary Arch 15**
Paranjay Prajapati, Sneha Kulkarni
- ❑ Classification *15*
- ❑ Primary Stress Bearing Areas (Primary Supporting Areas) *15*
- ❑ Secondary Stress Bearing Areas (Secondary Supporting Areas) *16*
- ❑ Relief Areas *17*
- ❑ Valve Forming Areas (Limiting Areas) *18*

5. **Anatomical Landmarks: Edentulous Mandibular Arch 22**
Paranjay Prajapati, Sneha Kulkarni
- ❑ Supporting Areas (Stress Bearing Areas) *22*
- ❑ Relief Areas *24*
- ❑ Valve Forming Structures (Limiting Areas) *25*

6. **Impression Trays 28**
Paranjay Prajapati, Sneha Kulkarni
- ❑ Definition *28*
- ❑ Ideal Requirements *28*
- ❑ Classification *28*
- ❑ Stock Trays *31*
- ❑ Custom Tray/Special Tray/Individualized Tray *32*

7. **Complete Denture Impression..... 36**
Paranjay Prajapati, Sneha Kulkarni
- ❑ Definition *36*
- ❑ Objectives of Complete Denture Impression Making *36*
- ❑ Impression Techniques for Making Edentulous Impression *37*
- ❑ Types of Edentulous Impression *37*
- ❑ What Should be Recorded in an Impression? *38*
- ❑ Primary Impression *38*
- ❑ Rationale/Need *38*
- ❑ Materials Used for Making Primary Impression *38*
- ❑ Impression Trays for Primary Impression *39*
- ❑ Final Impression/Secondary Impression *39*
- ❑ Final Impression Making *40*
- ❑ Rationale/Need *40*
- ❑ Various Impression Materials Used for Edentulous Impression *41*

8. **Dental Cast..... 43**
Paranjay Prajapati, Sneha Kulkarni
- ❑ Definition *43*
- ❑ Types of Dental Cast *44*
- ❑ Ideal Requirements of the Cast *44*
- ❑ Parts of Dental Cast *45*

9. **Spacer and Spacer Designs..... 46**
JR Patel, Paranjay Prajapati
- ❑ Uses *46*
- ❑ Materials Used for Making Spacer *47*
- ❑ Thickness of Spacer *47*

- ❑ Spacer Designs *47*
- ❑ Spacer Thickness for Different Impression Material *49*
- ❑ Tissue Stops *49*
- ❑ Uses *50*

10. Record Base 51
Paranjay Prajapati, Sneha Kulkarni

- ❑ Definition *51*
- ❑ Classification *51*
- ❑ Diagnostic Uses *52*
- ❑ Ideal Requirements *52*
- ❑ Advantages and Disadvantages of Denture Bases *52*

11. Mean Value Articulator..... 54
Paranjay Prajapati, Sneha Kulkarni

- ❑ Definition *54*
- ❑ Classification *54*
- ❑ Mean Value Articulator *58*

12. Indexing the Cast..... 63
Paranjay Prajapati, Sneha Kulkarni

- ❑ Indexing *63*
- ❑ Requirements *63*
- ❑ Armamentarium *63*
- ❑ Types *63*

13. Prosthetic Teeth 67
Rajesh Sethuraman, Paranjay Prajapati

- ❑ Classification of Prosthetic Teeth *67*
- ❑ Acrylic Teeth *67*
- ❑ Porcelain Teeth *68*
- ❑ Composite Teeth *69*
- ❑ Acrylic Teeth with Amalgam Inserts/ Stops *69*
- ❑ Acrylic Teeth with Metal Occlusion *69*
- ❑ Anatomical Teeth *69*
- ❑ Semi-anatomical Teeth *70*
- ❑ Nonanatomic Teeth *71*
- ❑ The Prosthetic Teeth Set *72*

14. Teeth Selection: Brief Overview..... 73
Rajesh Sethuraman, Paranjay Prajapati

- ❑ Definition *73*
- ❑ Objectives of Teeth Selection *73*
- ❑ Anterior Teeth Selection *73*
- ❑ Posterior Teeth Selection *75*
- ❑ Dentogenic Concept (SPA Guidelines) *77*

15. Lines, Planes, and Curves in Prosthodontics..... 78
YG Naveen, Jignesh Chaudhari

- ❑ Lines in Prosthodontics *78*
- ❑ Planes in Prosthodontics *79*
- ❑ Curves in Prosthodontics *79*
- ❑ Curves in Natural Dentition *80*
- ❑ Compensating Curve *81*

16. Complete Denture Occlusion: An Overview 83
Rajesh Sethuraman, JR Patel

- ❑ Definition *83*
- ❑ Objectives *83*
- ❑ Differences Between Natural and Artificial Occlusion *83*
- ❑ Classification *84*
- ❑ Theories of Occlusion *84*
- ❑ Types/Concepts of the Complete Denture Occlusion *84*
- ❑ Neutrocentric Concept of Occlusion *85*

17. Making Primary Impression of Maxillary and Mandibular Edentulous Foundations..... 86
Paranjay Prajapati, Sneha Kulkarni

- ❑ Instruments and Materials *86*
- ❑ Making Primary Impression *86*
- ❑ Steps in Manipulation of Impression Compound/Impression Material *90*

18. Pouring/Making of Dental Cast 93
Paranjay Prajapati, Sneha Kulkarni

- ❑ Methods of Making Cast *93*

19. Adaptation of Spacer on Primary Cast..... 101
Paranjay Prajapati, Sneha Kulkarni

- ❑ Armamentarium *101*
- ❑ Adaptation of Wax Spacer on Mandibular Primary Cast *104*

20. Fabrication of Custom Tray on Maxillary and Mandibular Primary Casts..... 106
Paranjay Prajapati, YG Naveen

- ❑ Armamentarium *106*

21. Fabrication of Denture Base/Record Base 112
Paranjay Prajapati, Sneha Kulkarni

- Sprinkle-on Method *112*
- Finger Adapted Dough Method *114*
- Forming Resin Sheet to Fabricate Record Base *117*
- Fabrication of Record Base by Shellac Baseplate *117*
- Fabrication of Record Base by Light Cure Acrylic Resin *122*

22. Fabrication of Occlusal Rims 126
Paranjay Prajapati, Sneha Kulkarni

- Armamentarium *126*
- Fabrication of Maxillary Occlusal Rim *126*
- Fabrication of Mandibular Occlusal Rim *130*

23. Mounting Occlusal Rims on Articulator 133
Paranjay Prajapati, Sneha Kulkarni

- Armamentarium *133*

24. Arrangement of Artificial Teeth 140
Rajesh Sethuraman, Paranjay Prajapati

- Sequence of Arrangement of Teeth *140*
- Armamentarium *140*
- Arranging Maxillary Anterior Teeth *141*
- Arrangement of Maxillary Canine *144*
- Arrangement of Mandibular Anterior Teeth *146*
- Arrangement of Maxillary Posterior Teeth *150*
- Arrangement of Maxillary First Premolar *150*
- Arrangement of Maxillary Second Premolar *151*
- Arrangement of Maxillary First Molar *152*
- Arrangement of Maxillary Second Molar *153*
- Arrangement of Mandibular Posterior Teeth *155*
- Arrangement of Mandibular First Premolar *156*
- Arrangement of Mandibular Second Premolar *156*
- Arrangement of Mandibular First Molar *157*
- Arrangement of Mandibular Second Molar *160*
- Teeth Arrangement Using Nonanatomical (Zero Degree) Posterior Teeth *161*
- Brief Notes on Class II and Class III Teeth Arrangement *162*

25. Wax-up of Complete Denture 165
Paranjay Prajapati, YG Naveen

- Armamentarium *165*
- Wax-up of Maxillary Complete Denture *165*
- Wax-up of Mandibular Complete Denture *168*

26. Processing of Waxed-up Denture 171
Paranjay Prajapati, Sneha Kulkarni

- Flasking Procedure *171*
- Dewaxing Procedure (Wax Elimination Procedure) *176*
- Packing the Acrylic Resin in the Mould *178*
- Heat Processing/Curing/ Polymerization *183*
- Deflasking Procedure *184*
- Remount Procedure and Selective Grinding *185*

27. Finishing and Polishing of Complete Denture 186
Paranjay Prajapati, Jignesh Chaudhari

- Finishing the Denture *186*
- Polishing the Denture (Pumicing the Denture) *188*

28. Repair of Fractured Denture 191
JR Patel, Jignesh Chaudhari

- Preparation of Working Cast *191*
- Repair of Fracture Denture *192*

Section II: Removable Partial Denture

29. Removable Partial Denture 197
Paranjay Prajapati, Jignesh Chaudhari

- Definitions *197*
- Treatment Objectives of Removable Partial Denture *197*

30. Classification of Partially Edentulous Arch 198
Paranjay Prajapati, Jignesh Chaudhari

- Ideal Requirements of Classification *198*

- Kennedy's Classification *198*
- Applegate's Rules for Applying the Kennedy Classification *199*
- Some Common Classifications for Partially Edentulous Arch *200*

31. Components of Acrylic Partial and Cast Partial Denture 201
Paranjay Prajapati, Jignesh Chaudhari

- Components of Acrylic Partial Denture *201*
- Components of Cast Partial Denture *201*

32. Maxillary Major Connectors 203
Paranjay Prajapati, Jignesh Chaudhari

- Major Connector *203*
- Maxillary Major Connectors *203*

33. Mandibular Major Connectors 206
Paranjay Prajapati, Rajesh Sethuraman

- Mandibular Major Connectors *206*

34. Minor Connectors 208
JR Patel, YG Naveen

- Functions *208*
- Types *208*

35. Direct and Indirect Retainers 211
Rajesh Sethuraman, Paranjay Prajapati

- Retainers *211*
- Direct Retainer *211*
- Indirect Retainers *216*

36. Rest and Rest Seat 217
JR Patel, YG Naveen

- Definition *217*
- Functions of Rest *217*
- Types of Rest *217*
- Rest and Rest Seat Form *217*

37. Survey Lines and Surveyor 219
Paranjay Prajapati, Rajesh Sethuraman

- Survey Lines *219*
- Classification of Survey Lines *219*
- Surveyor *220*

38. Fabrication of Removable Partial Denture 222
Paranjay Prajapati, YG Naveen

- Fabrication of Record Based on Maxillary and Mandibular Partially Edentulous Casts *222*
- Fabrication of Occlusion Rims *223*
- Mounting of Casts on Articulator *224*
- Teeth Arrangement and Wax Up Procedure *224*
- Processing of Removable Partial Denture *224*

Section III: Fixed Partial Denture

39. Fixed Partial Denture 231
Paranjay Prajapati, Rajesh Sethuraman

- Definition *231*
- Parts of Fixed Partial Denture *231*
- Types of Crown *231*

40. Principles of Tooth Preparation: A Brief Overview 233
Paranjay Prajapati, Rajesh Sethuraman

- Rationale of Tooth Preparation *233*
- Principles of Tooth Preparation *233*

41. Pontic, Retainers, and Connectors ... 236
Paranjay Prajapati, Rajesh Sethuraman

- Pontic *236*
- Retainer *236*
- Connectors *238*

42. Tooth Preparation to Receive all Ceramic Crown 239
Paranjay Prajapati, Rajesh Sethuraman

- Tooth Preparation *239*
- Finishing of Preparation *243*

43. Tooth Preparation to Receive all Metal Crown 245
Paranjay Prajapati, Rajesh Sethuraman

- Tooth Preparation *245*
- Finishing of Preparation *248*

44. Fabrication of Three Unit Fixed Partial Denture 249
Paranjay Prajapati, Rajesh Sethuraman

- Instruments and Materials *249*
- Procedure *249*

45. Restoration of Endodontically Treated Tooth 254
Rajesh Sethuraman, Paranjay Prajapati

- Rationale for Use of Post *254*

- ❑ Classification of Post *254*
- ❑ Procedure for Post and Core Treatment *254*
- ❑ Procedure and Pictorial Representation of Post and Core Treatment *255*

Section IV: Maxillofacial Prosthodontics

46. Introduction to Maxillofacial Prosthesis 259
Paranjay Prajapati, Rajesh Sethuraman

- ❑ Maxillofacial Prosthetics/ Prosthodontics *259*
- ❑ Classification of Maxillofacial Prosthesis *259*
- ❑ Objectives of Maxillofacial Prosthesis *259*
- ❑ Materials Used for Fabrication of Maxillofacial Prosthesis *260*
- ❑ Types of Maxillofacial Prosthesis *260*

47. Introduction to Implant Prosthesis .. 263
Rajesh Sethuraman, YG Naveen

- ❑ Definition *263*
- ❑ Indications *263*
- ❑ Implant Prosthetic Components *263*
- ❑ Single Tooth Replacement *264*
- ❑ Replacement of Multiple Missing Teeth *264*

48. Fabrication of Obturator 266
Rajesh Sethuraman, Paranjay Prajapati

- ❑ Objectives *266*
- ❑ Types *266*
- ❑ Obturator *266*

Section V: Instruments and Equipment

49. Instruments for Removable Prosthodontics 273
Paranjay Prajapati, Rajesh Sethuraman

- ❑ Rubber Bowl *273*
- ❑ Mixing Spatula *273*
- ❑ Wax Knife *274*
- ❑ Plaster Knife *274*
- ❑ Wax Spatula *274*
- ❑ Wax Carver *274*
- ❑ Scissors *274*
- ❑ Dappen Dish *275*
- ❑ Spirit Lamp *275*
- ❑ Bunsen Burner *275*
- ❑ Chip Blower *275*
- ❑ Hot Plate/Hot Plate Spatula *276*
- ❑ Porcelain Cup with Lid *276*
- ❑ Dental Flasks *276*
- ❑ Clamps *276*
- ❑ Glass Plate *276*
- ❑ Glass Slab and Mixing Spatula *276*
- ❑ Mixing Pad and Spatula *277*
- ❑ Acrylic Trimmer *278*
- ❑ Sandpaper Mandrel *278*
- ❑ BP Blade (Bard-Parker Blade) and Handle *279*
- ❑ Rag Wheel *279*

50. Instruments for Fixed Prosthodontics 280
Paranjay Prajapati, Rajesh Sethuraman

- ❑ Rotary Instruments for Tooth Preparation *280*
- ❑ Diamond Points *280*
- ❑ Contra-Angle Handpiece *281*
- ❑ Air Rotor Handpiece *281*
- ❑ Friction Grip to Latch Converter *282*

51. Equipments Used in Prosthodontic Laboratory 283
Paranjay Prajapati, Rajesh Sethuraman

- ❑ Plaster Dispenser *283*
- ❑ Bunsen Burner *283*
- ❑ Model Trimmer *283*
- ❑ Bench Lathe *284*
- ❑ Hydraulic Press *284*
- ❑ Dewaxing Unit *284*
- ❑ Acrylizer Unit *284*
- ❑ Deflasking Unit *285*

52. Cleaning and Caring of the Instruments 286
Paranjay Prajapati, Rajesh Sethuraman

- ❑ Rubber Bowls *286*
- ❑ Wax Manipulation Instruments *286*
- ❑ Glass Slab *286*
- ❑ Glass Plate *286*
- ❑ Model Trimmer *286*

Section VI: Dental Materials

53. Dental Materials Used in Prosthodontics 289
Paranjay Prajapati, Rajesh Sethuraman, Sneha Kulkarni

Gypsum Products 289
- ❑ Dental Biomaterials *289*

Impression Materials 290
- ❑ Impression Materials in Dentistry *290*

Dental Waxes 292
- ❑ Modeling Wax *292*
- ❑ Sticky Wax *292*
- ❑ Prefabricated Patterns for Cast Partial Denture *293*
- ❑ Inlay Wax *293*
- ❑ Pattern Wax *293*

Denture Base Resin 293
- ❑ Self-cure Acrylic Resin *293*
- ❑ Heat-cure Acrylic Resin *294*
- ❑ Light-cure Acrylic Resin *294*

Alloys and Dental Ceramic 294
- ❑ Nickel-chrome Alloys *294*
- ❑ Cobalt-chromium Alloys *295*
- ❑ Dental Porcelain or Ceramic *295*

Finishing and Polishing Agents 295
- ❑ Sand Paper *295*
- ❑ Emery Paper *296*
- ❑ Pumice *296*

Separating Medium 296
- ❑ Types *296*

SECTION VII: OSCE/OSPE/ Spotter Section

54. OSCE/OSPE/Spotter Section 301

55. Viva Voce Questions-Answers 324

Index 333

CHAPTER 24

Arrangement of Artificial Teeth

Rajesh Sethuraman, Paranjay Prajapati

JAYPEE BROTHERS

INTRODUCTION

Correct selection of artificial teeth and their correct arrangement is critical factor determining success and acceptance of prosthesis by patient. Varieties of artificial teeth are available in market. They are selected according to patient's need for aesthetic and other factors. This chapter describes regarding the arrangement of artificial teeth for complete denture.

SEQUENCE OF ARRANGEMENT OF TEETH

The sequence of arrangement of teeth has been shown in **Table 24.1**.

Table 24.1: Sequence of arrangement of teeth.

S. No.	*Teeth*	*Sequence*
1.	Maxillary anteriors	Right side
2.	Maxillary anteriors	Left side
3.	Mandibular anteriors	Right side
4.	Mandibular anteriors	Left side
5.	Maxillary posteriors	Right side
6.	Maxillary posteriors	Left side
7.	Mandibular posteriors	Right side
8.	Mandibular posteriors	Left side

ARMAMENTARIUM

Mean value articulator with mounted maxillary and mandibular occlusion rims on final cast **(Fig. 24.1)**.

- MacIntosh sheet
- Acrylic teeth on tooth card
- Glass plate
- Wax spatula
- Wax knife
- Lecron's carver
- Spirit lamp/burner.

Mark midline on maxillary occlusal rim with sharp instrument like carver **(Fig. 24.2)**. Extend this midline on cast and mounting plaster with pencil or marker. This will guide

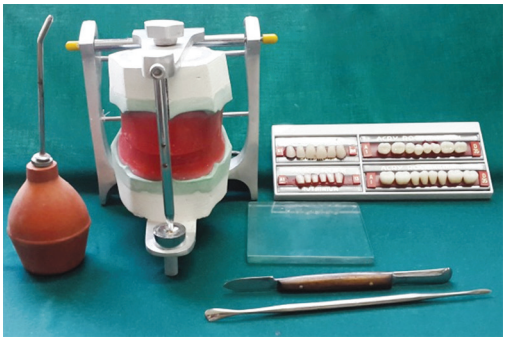

Fig. 24.1: Mounting on articulator.



Fig. 24.2: Mark the midline on the cast using pencil or marker.

during teeth arrangement when midline on wax rim is not clear.

While teeth arrangement, position of every tooth is finalized according to its relation with adjacent tooth, relation with glass plate (serve as occlusal plane), relation with rim contour, mesiodistal inclination, and labiolingual inclination.

ARRANGING MAXILLARY ANTERIOR TEETH

Arrangement of Maxillary Central Incisor

Step 1

Select anterior teeth according to arch shape, facial type, and other factors **(Fig. 24.3)**.

Heat wax spatula and pool wax from labial surface of maxillary occlusion rim where central incisor is to be placed **(Figs. 24.4A and B)**.



Fig. 24.3: Maxillary anterior teeth.

Step 2

Take out central incisor from tooth card **(Fig. 24.5)**. Clean carding wax from ridge lap area. Soften the wax in the area again with wax spatula. Place the central incisor in the position and set it according to the set up angulations given in **Table 24.2** and **Figures 24.6A and B**.

When viewed from front, the long axis of maxillary central incisor is positioned almost parallel to the vertical axis **(Figs. 24.7)**.

When viewed occlusally, the incisal edge of central incisor should follow the labial contour of maxillary wax rim. When viewed from side, the central incisor is sloped labially about 12–15° **(Figs. 24.8A and B)**.

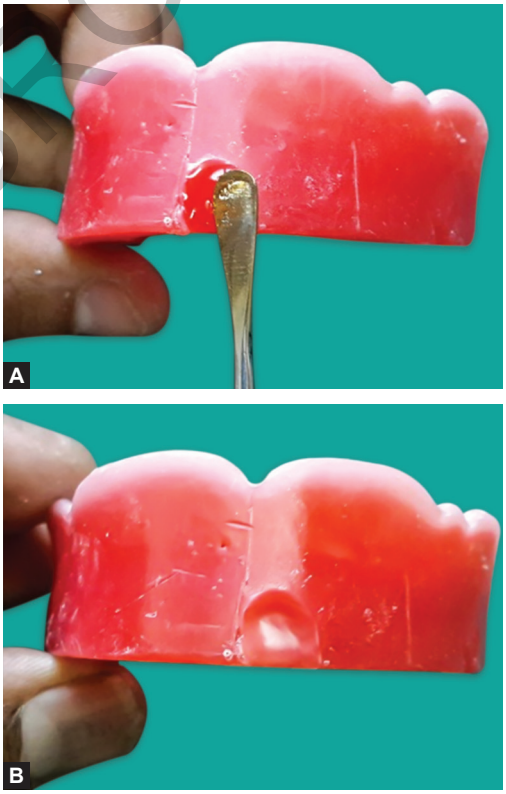

Figs. 24.4A and B: Scooping out the modeling wax in central incisor area.

JAYPEE BROTHERS



Fig. 24.5: Arranging the central incisor.

Table 24.2: Maxillary central incisor arrangement guidelines.

Mesiodistal inclination	Slightly mesially inclined so that central incisors meet at midline at their incisal one-third
Labiolingual inclination	Slightly labially inclined. Incisal edge is placed more labially than neck
Relation of incisal edge to horizontal plane	Incisal edge touches the horizontal plane
Relation when viewed occlusally	Distal end of incisor should be rotated to follow the contour

Step 3

Seal the central incisor in finally determined position with hot wax spatula. Chill the wax rim in cold water to set the wax and secure the incisor position **(Fig. 24.9)**.

Arrangement of Maxillary Lateral Incisor

Step 1

Take out lateral incisor from tooth card and clean carding wax from ridge lap area **(Figs. 24.10A and B)**. Heat wax spatula and remove wax from labial surface of maxillary occlusion rim in area where lateral incisor to be placed. Soften the area with hot wax spatula and arrange lateral incisor accordingly reference chart given in **Table 24.3**.

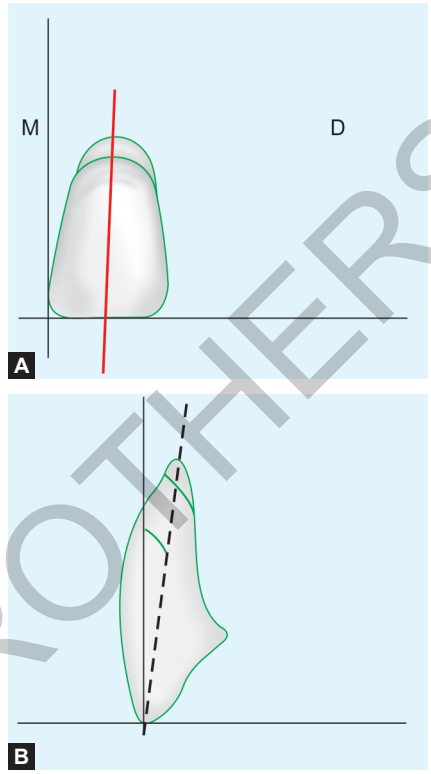

Figs. 24.6A and B: Maxillary central incisor—frontal view and side view.

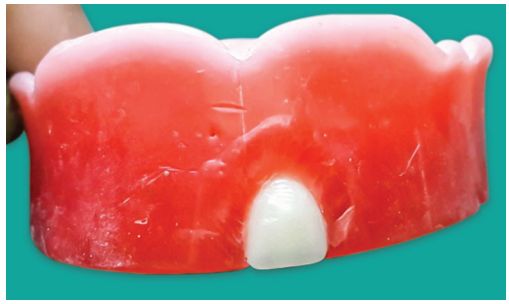

Fig. 24.7: Position of maxillary central incisor.

Step 2

Seal the lateral incisor in finally determined position with hot wax spatula. Put the wax rim

JAYPEE BROTHERS





Figs. 24.8A and B: Placement of central incisor—occlusal view and side view.



Fig. 24.9: Central incisor arranged in position.

in cold water to set the wax and tooth **(Figs. 24.11 and 24.12)**.

The incisal edge should be parallel to glass plate. Incisal edge is 1 mm above from the glass plate. The neck of the lateral incisor is inclined distally. Distal part of lateral incisor edge is rotated to follow labial contour of wax rim (**Fig. 24.13**A and B).





Figs. 24.10A and B: Scooping out the modeling wax in lateral incisor area.

Table 24.3: Maxillary lateral incisor arrangement guidelines.

Mesiodistal inclination	The incisal one-third is more mesially inclined (neck distally inclined)
Labiolingual inclination	It is more mesially inclined than central incisor with neck depressed
Relation of incisal edge to horizontal plane	It is parallel to horizontal plane. Should not touch the plane. Should be 1 mm above the plane
Relation when viewed occlusally	The distal edge is more rotated to follow contour of the rim

JAYPEE BROTHERS

While arranging lateral incisor focus to make incisal edge parallel to glass plate, the neck of lateral incisor will be inclined distally by default.



Fig. 24.11: Lateral incisor placed in position.

ARRANGEMENT OF MAXILLARY CANINE

Step 1 (Figs. 24.14 and 24.15)

Take out canine from tooth card and clean carding wax from ridge lap area. Heat wax spatula and remove wax from labial surface of maxillary occlusion rim in area corresponding to canine space. Soften the area with hot wax spatula and arrange canine accordingly the reference chart given in **Table 24.4**.

Step 2

Seal the canine in finally determined position with hot wax spatula. Put the wax rim in cold water to set the wax and tooth **(Fig. 24.16)**.

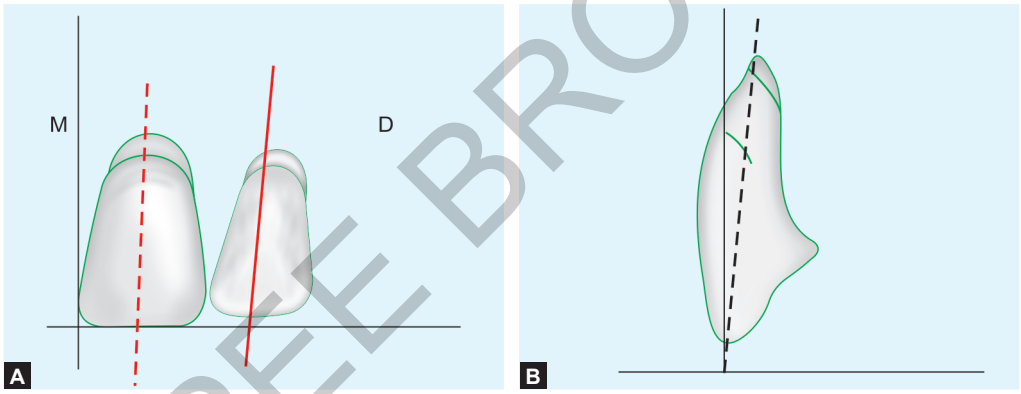

Figs. 24.12A and B: Maxillary lateral incisor—frontal view and side view.



Figs. 24.13A and B: Lateral incisor in position—frontal view and side view.

JAYPEE BROTHERS

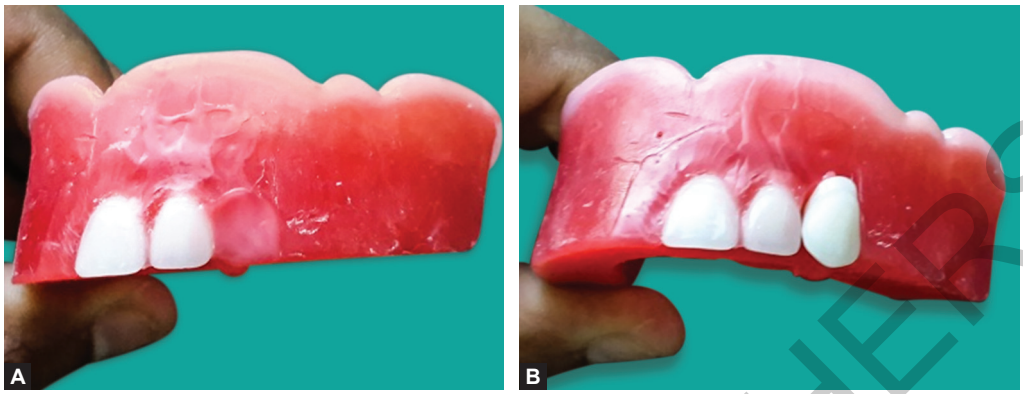

Figs. 24.14A and B: Scooping out the modeling wax in canine area and placement of canine in position.

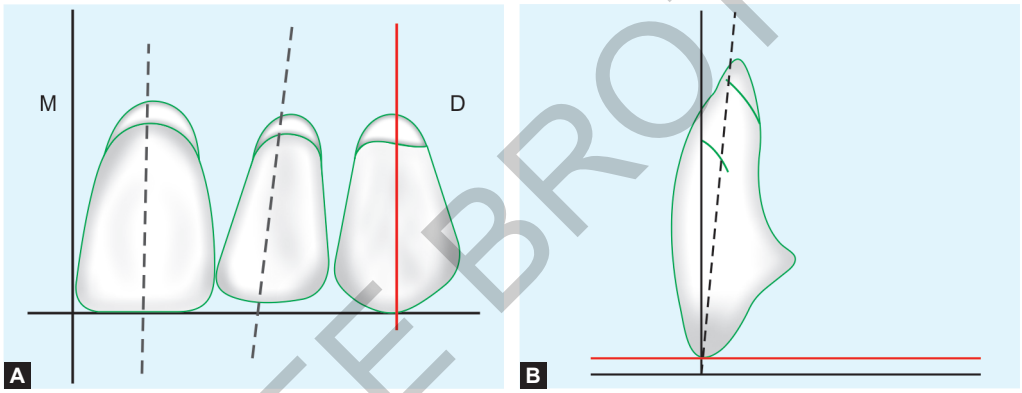

Figs. 24.15A and B: Maxillary canine—frontal view and side view.

Table 24.4: Maxillary canine arrangement guidelines.	
Mesiodistal inclination	Placed vertically with no mesial or distal inclination
Labiolingual inclination	Placed vertically upright. No specific inclination
Relation of incisal edge to horizontal plane	Tip of the canine should touch the horizontal plane
Relation when viewed occlusally	Distal half of canine is rotated to follow rim contour

When viewed from front, only mesial slope of canine is visible. The neck of canine (cervical area) is more prominent compared to centrals.



Fig. 24.16: Canine arranged in position—frontal view.

JAYPEE BROTHERS



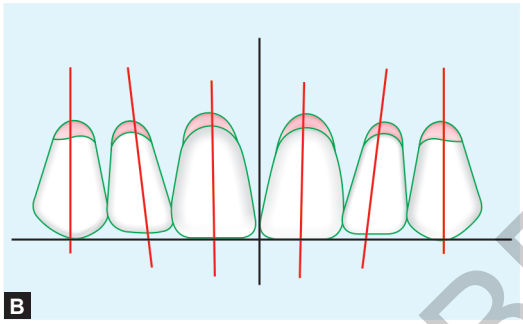

Figs. 24.17A and B: All maxillary anterior teeth arranged in position.

Repeat the arrangement for other side of the arch and complete arrangement of all six maxillary anterior teeth **(Figs. 24.17A and B)**.

Remove excess wax from palatal surface. Heat the curved end of wax knife and slowly remove the wax without applying any pressure, otherwise it may change the tooth position **(Figs. 24.18A and B)**.

ARRANGEMENT OF MANDIBULAR ANTERIOR TEETH

Mandibular anterior teeth are arranged slightly lingually than maxillary anterior teeth. Vertical and horizontal overlap should be attained **(Fig. 24.19)**.

Remove the vertical pin from the articulator before arranging the mandibular anterior teeth.





Figs. 24.18A and B: Removal of excess wax from palatal surface after teeth arranged in position.



Fig. 24.19: Mandibular anterior teeth.

Arrangement of Mandibular Central Incisors

Step 1

Remove part of wax from the area and soften remaining wax. Place the central incisor so that the long axis is parallel to vertical axis when viewed from front. The mesial surface of the central incisor should coincide with the midline

JAYPEE BROTHERS

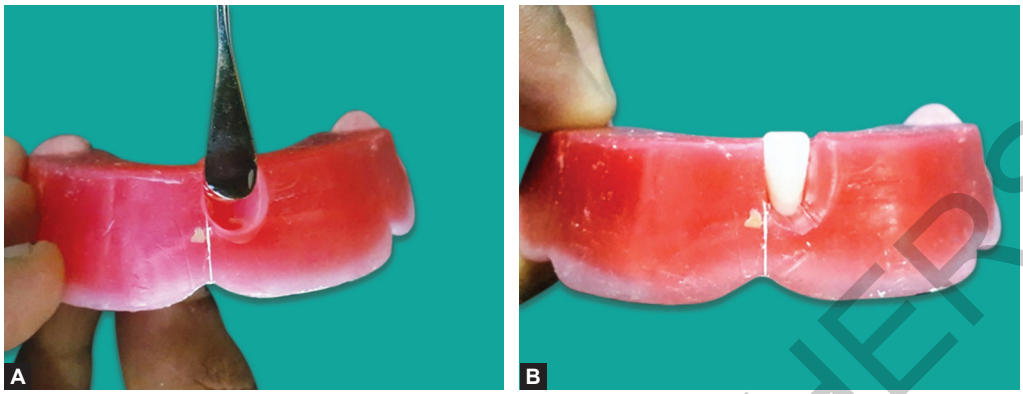

Figs. 24.20A and B: Scooping out the wax and placing mandibular central incisor.

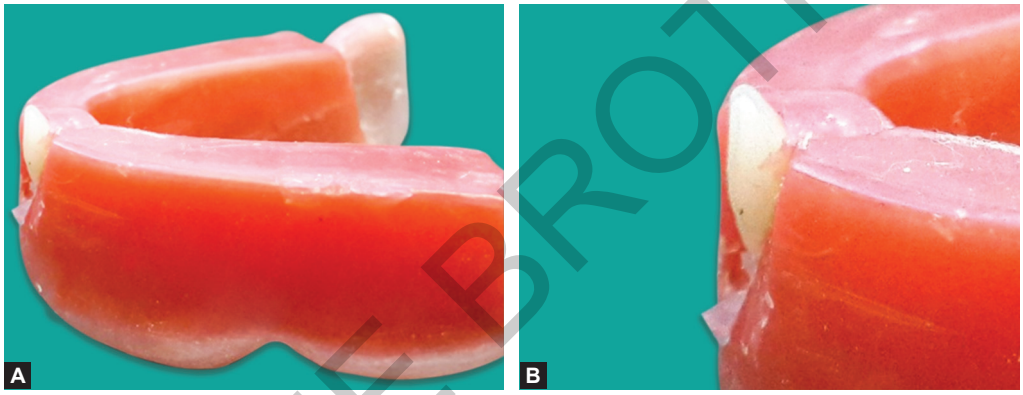

Figs. 24.21A and B: Placement of mandibular central incisor—side view.

marked on the wax occlusal rim and also with the maxillary teeth midline **(Figs. 24.20A and B)**.

Step 2

Make it sloped slightly labially (labial inclination) with neck depressed **(Figs. 24.21A and B)**.

Step 3

Place the incisal edge 0.5–1 mm above the occlusal plane **(Fig. 24.22)**.

The incisal edges of mandibular anteriors are placed 0.5–1 mm above the occlusal plane. This is essential to create overbite.

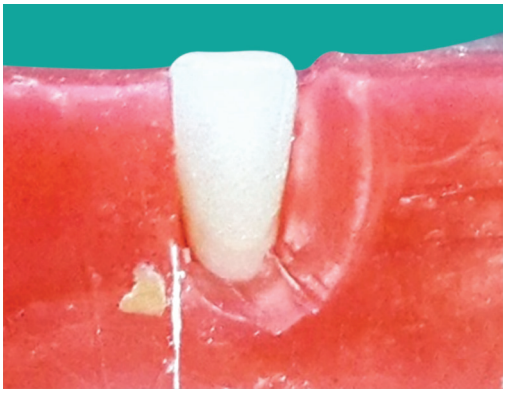

Fig. 24.22: Placement of mandibular central incisor—front view.

JAYPEE BROTHERS

Arrangement of Mandibular Lateral Incisors

Step 1

Remove part of wax from the area and soften remaining wax. Place the lateral incisor so that long axis is parallel to vertical axis **(Fig. 24.23)**.

Make it sloped slight labially (labial inclination) with neck depressed. Distal end of incisor edge follows rim contour. Its incisal edge is 0.5–1 mm above the occlusal plane **(Figs. 24.24A and B)**.



Fig. 24.23: Scoop out wax and place lateral incisor.

Arrangement of Mandibular Canine

Step 1

Remove part of wax from the area and soften remaining wax. Place the canine such that the long axis is inclined slightly toward midline (mesial inclination) when viewed from front **(Figs. 24.25A and B)**.

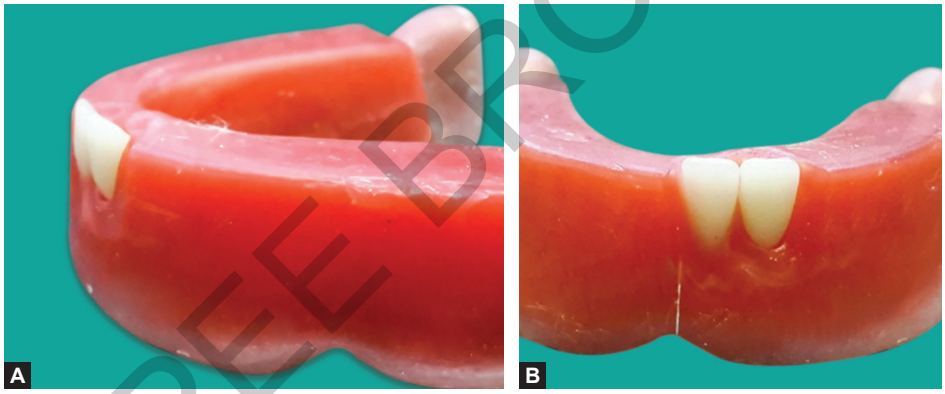

Figs. 24.24A and B: Placement of mandibular lateral incisor—side view and front view.

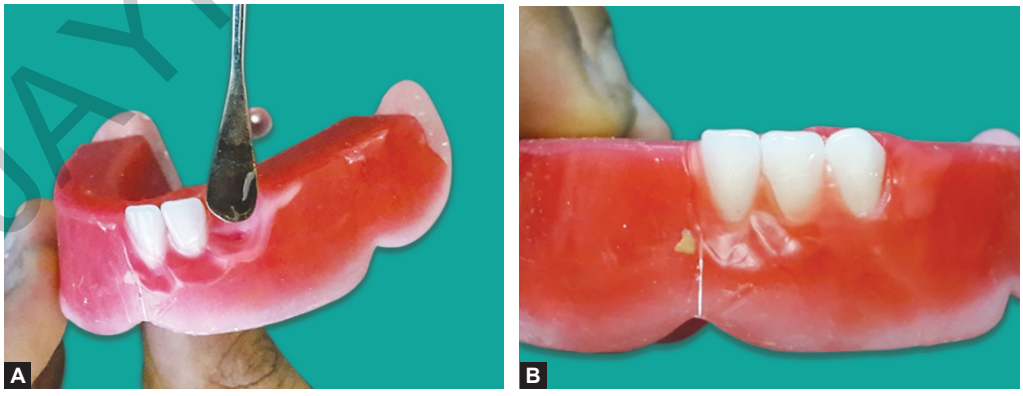

Figs. 24.25A and B: Scoop out wax and placement of canine.

JAYPEE BROTHERS

Step 2

It is also slightly inclined lingually when viewed from side. Its tip is slightly more than 1 mm above the horizontal plane. It follows labial contour of the rim **(Figs. 24.26 and 24.27)**.

> Mandibular teeth when viewed occlusally should not cross land area of the cast.

Arrange all six mandibular anterior teeth accordingly. Remove wax from lingual surface of teeth **(Figs. 24.28A and B)**.

Check for overjet and overbite once the maxillary and mandibular anterior teeth are arranged.

The vertical overlap between mandibular teeth and the maxillary teeth is called as over bite. It should be 0.5–1.0 mm. The horizontal overlap between the maxillary and mandibular teeth is called as overjet. It should be 1–2 mm **(Figs. 24.29A and B)**.

The overjet should be uniform from left canine to right canine **(Fig. 24.30)**.



Fig. 24.26: Mandibular canine—occlusal view.



Figs. 24.27A to C: Arrangement of mandibular anterior. *Note:* Overbite, overjet and canine key of occlusion.

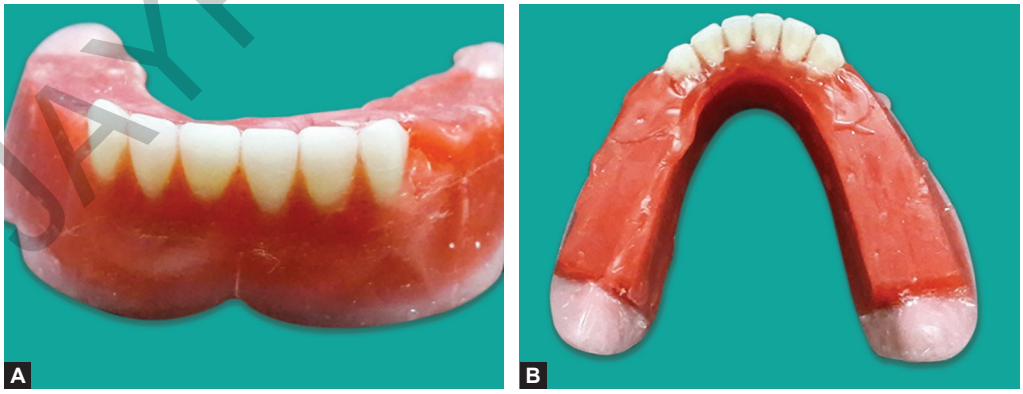

Figs. 24.28A and B: Removal of excess wax from lingual surface.

JAYPEE BROTHERS

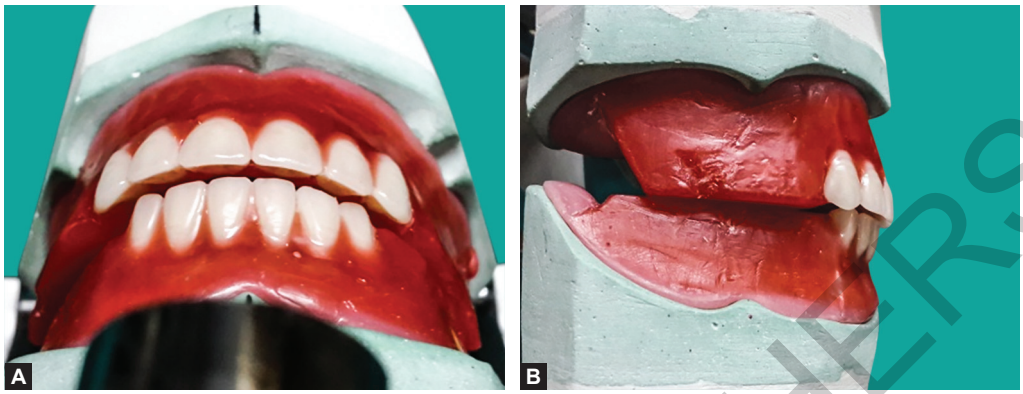

Figs. 24.29A and B: Horizontal overlap is 1–2 mm and vertical overlap is 0.5–1 mm.

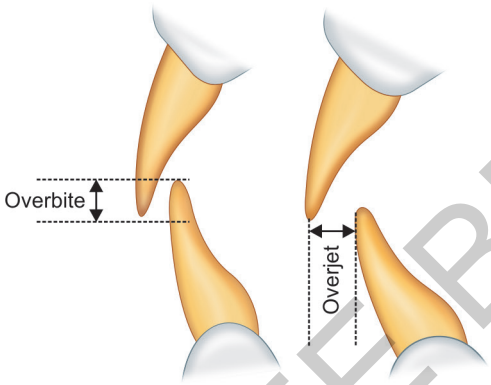

Fig. 24.30: Line diagram representing overbite and overjet.



Fig. 24.31: Canine key of occlusion.

In properly arranged artificial teeth, the mesial slop of maxillary canine should overlap the distal slop of mandibular canine **(Fig. 24.30)**. This is called as "canine key of occlusion" **(Fig. 24.31)**.

In some cases, the long axis of the mandibular canine may be slightly inclined distally to achieve the class-I canine relation.

ARRANGEMENT OF MAXILLARY POSTERIOR TEETH

Maxillary posterior teeth are shown on tooth card in **Figure 24.32**.



Fig. 24.32: Maxillary posterior teeth.

ARRANGEMENT OF MAXILLARY FIRST PREMOLAR

Step 1

Take out first premolar from tooth card and clean carding wax from ridge lap area

JAYPEE BROTHERS

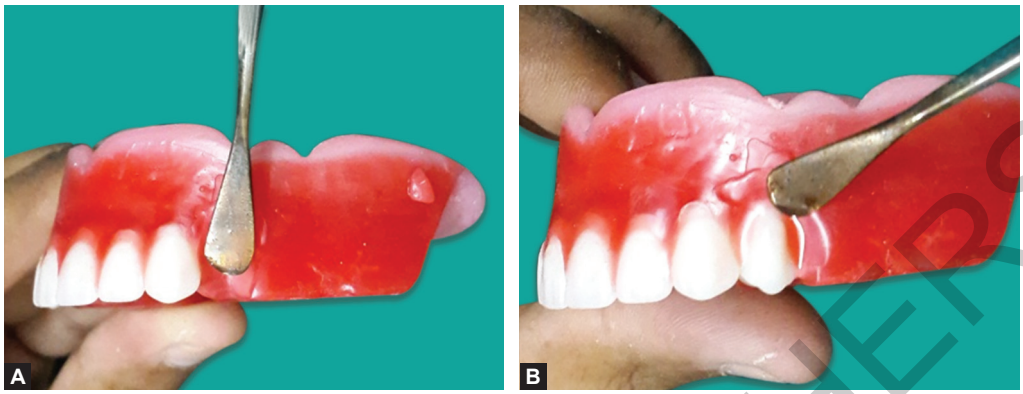

Figs. 24.33A and B: Scooping out the wax and placement of maxillary first premolar.

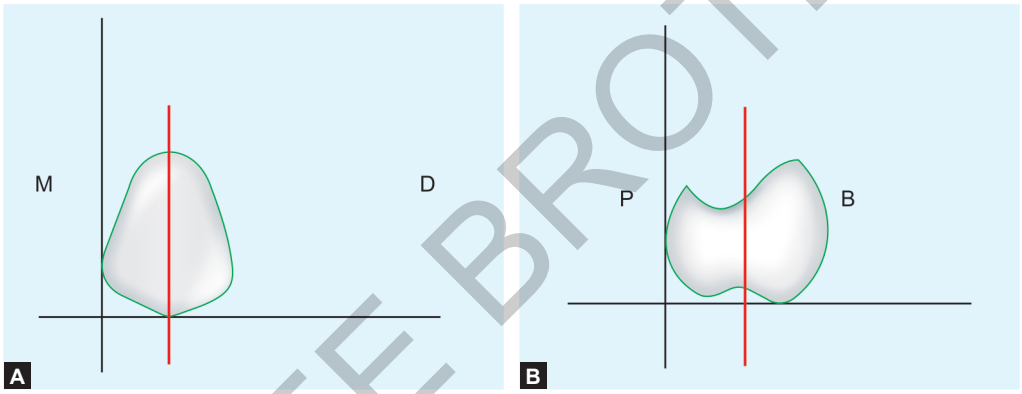

Figs. 24.34A and B: Diagrammatic representation of arrangement of maxillary first premolar.

Table 24.5: Maxillary first premolar arrangement guidelines.	
Mesiodistal inclination	Placed straight. No mesial or distal inclination
Buccopalatal inclination	Vertical. No inclination
Relation of incisal edge to horizontal plane	Buccal cusp touches the plane. The palatal cusp is 1 mm above the horizontal plane

(Figs. 24.33A and B). Heat wax spatula and remove wax from labial surface of maxillary occlusion rim in area corresponding to first premolar space. Soften the area with hot wax spatula and arrange premolar accordingly set up reference given in **Table 24.5 and Figs. 24.34A and B**.

Step 2

Seal the first premolar in finally determined position with hot wax spatula. Put the wax rim in cold water to set the wax and tooth **(Figs. 24.35A and B)**.

> When viewed occlusally, the buccal ridges of the canine and the first premolar should be flushed in one plane.

ARRANGEMENT OF MAXILLARY SECOND PREMOLAR

Step 1

Take out second premolar from tooth card and clean carding wax from ridge lap area. Heat wax

JAYPEE BROTHERS

for detailed information on dental books, visit our website www.jaypeebrothers.com, for detailed information on dental books, visit our websit

Essential Manual of
Preclinical Prosthodontics

The *Essential Manual of Preclinical Prosthodontics* is a complete reference manual with illustrations of preclinical prosthodontics with the following features:

- Confirms to the syllabus of Dental Council of India (DCI) for BDS students.
- Includes step-by-step illustrations/demonstrations of preclinical exercises to be learned and performed by 1st- and 2nd-year BDS students.
- Provides a concise review of the instruments, dental materials, and techniques used during various preclinical exercises.
- Contains a dedicated section on common viva voce question with answer for ready reference and exam-oriented preparation.
- Includes OSCE/OSPE types of question answer useful for exam preparation and exam viva voce and spotters.
- Provides key points and tables for easy learning and quick recapitulation.
- Step-by-step approach to illustrate/demonstrate any exercise.
- Contains more than 1,100 high-quality color illustrations on important preclinical exercises.
- Includes flowcharts, schematic diagrams, and tables to improve understanding and easy reproducibility.
- Provides brief information about fixed partial denture, maxillofacial prosthesis, post and core, and implant prosthesis.

Paranjay Prajapati BDS MDS is Professor, Department of Prosthodontics and Crown and Bridge, KM Shah Dental College and Hospital, Sumandeep Vidyapeeth Deemed to be University, Vadodara, Gujarat, India. He completed his graduation from AME'S Dental College and Research Center, Raichur, Karnataka, and postgraduation in Prosthodontics from KM Shah Dental College and Hospital. He has a number of national and international scientific publications and patents to his credit.

Sneha Kulkarni BDS completed her graduation from AME'S Dental College and Research Center, Raichur, Karnataka, India. She has more than 12 years of teaching experience as a tutor in the Department of Prosthodontics and Crown and Bridge, KM Shah Dental College and Hospital, Sumandeep Vidyapeeth, Deemed to be University. Currently, she is managing her private dental practice.

Printed in India

Available at all medical bookstores or buy online at www.ejaypee.com

JAYPEE BROTHERS
Medical Publishers (P) Ltd.
EMCA House, 23/23-B, Ansari Road,
Daryaganj, New Delhi - 110 002, INDIA
www.jaypeebrothers.com

Join us on facebook.com/JaypeeMedicalPublishers
Follow us on instagram.com/JaypeeMedicalPublishers

Shelving Recommendation
DENTISTRY

ISBN 978-93-6616-100-6