website www.ejaypee.com, for detailed information on surgery books, visit our website www.ejaypee.com, for detailed information on surgery books, visit our website www.ejaypee.com



MCQs in
SURGERY

An Ultimate Solution for the Super Speciality Exam in Surgery

Includes:

- Detailed strategies and methods for Effective Exam Preparation including mnemonics to boost exam performance
- Basic Surgical Principles vital for both practical exams and clinical practice
- Specialized Surgical Sections covering critical areas in surgical disciplines offering detailed insights essential for both theoretical exams and real-world application

Vinod Kumar Nigam
Siddharth Nigam

JAYPEE

Contents

SECTION 1: Preparation for Entrance Examinations

1. How to Increase your Retention while Preparing for Examinations? 3
2. How to Prepare for these Entrance Examinations? 9
3. How to Attempt the Entrance Examination Paper? 10
4. How to Keep Healthy and Avoid Anxiety and Stress during Exam Preparations? 11
5. How to be Motivated and have a Positive Attitude? 13
6. What should be the Daily Routine during Preparations for these Entrance Exams? 14

SECTION 2: Basic Principles of Surgery

7. Wounds and Healing 17
8. Shock and Blood Transfusion 26
9. Metabolic Response to Injury 35
10. Tissue Repair and Regeneration 41
11. Surgical Infections 46
12. Basic Surgical Skills 56
13. Surgical Instruments and Machines 64
14. Laparoscopic Surgery 70
15. Robotic Surgery 75
16. Trauma 77
17. Fluid and Electrolyte Balance 94

SECTION 3: Surgical Diseases of Skin and Subcutaneous Tissue

18. Skin and Subcutaneous Tissue 103
19. Burns 112
20. Plastic Surgery 120

SECTION 4: Head and Neck

21. Brain and Central Nervous System Tumors 129
22. Cerebrovascular Diseases 144
23. Oral Cavity 153
24. Salivary Glands 160
25. Neck 172
26. Face 180

SECTION 5: Breast

27. Breast 189

SECTION 6: Endocrine

28. Thyroid 229
29. Parathyroid 249
30. Adrenal Glands 257

SECTION 7: Gastrointestinal Diseases

31. Hernia 271
32. Esophagus 296
33. Stomach and Duodenum 318
34. Bariatric and Metabolic Surgery 339
35. Liver 343
36. Spleen 357
37. Gallbladder and Bile Ducts 364
38. Pancreas 388
39. Small Intestine 402
40. Large Intestine 419
41. Vermiform Appendix 430
42. Rectum 495
43. Anus and Anal Canal 504
44. Peritoneum 516

SECTION 8: Genitourinary

45. Kidneys and Ureters 527
46. Urinary Bladder 541
47. Prostate and Seminal Vesicles 553
48. Urethra and Penis 563
49. Testes and Scrotum 572

SECTION 9: Vascular System

50. Arterial Disorders 583
51. Venous Disorders 593
52. Lymphatic Disorders 603
53. Thorax and Lungs 610

SECTION 10: Oncology

54. Tumors 625

SECTION 11: Transplantation

55. Kidney 635
56. Liver 641

SECTION 12: Pediatric Surgery

57. Pediatric Surgery 647

SECTION 13: Miscellaneous

58. Miscellaneous Subjects Multiple Choice Questions 653
Index *657*

CHAPTER 41

Vermiform Appendix

"To study the phenomenon of disease without books is to sail an uncharted sea, while to study books without patients is not to go to sea at all."

– Sir William Osler

JAYPEE BROTHERS

INTRODUCTION

The word "vermiform appendix" is derived from the Latin words "vermis," meaning "worm," and "forma," meaning "shape," so shaped like a worm, and "appendere" means to "hang upon." The vermiform appendix is a worm-like tubular structure that hangs from the cecum in the abdominal cavity.

Morphologically, the appendix is an undeveloped distal end of the large cecum found in many animals. The appendix was considered a vestigial organ, an organ that becomes rudimentary and functionless in the course of evolution. The vermiform appendix is now considered a specialized part of the gastrointestinal tract and not a vestigial organ. It may be a reservoir for beneficial gut bacteria.

Important milestones:

- In 1736, Claudius Amyand performed the first appendicectomy.
- In 1880, Lawson Tait performed the first appendicectomy, but it was reported in 1890.
- In 1886, Reginald Heber Fitz coined the term "appendicitis."
- In 1886, Krönlein reported the first appendicectomy.
- In 1889, McBurney described McBurney's point **(Fig. 1)**.
- In 1889, McBurney also described Gridiron incision.
- In 1902 Ochsner–Sherren Regimen was given by Ochsner and Sherren.
- In 1982, Kurt Semm performed the first laparoscopic appendicectomy.
- In 2009, the first transvaginal removal of the appendix by Santiago Horgan and Mark A Talamini—a procedure called Natural Orifice Transluminal Endoscopic Surgery (NOTES).



Fig. 1: McBurney's point.

DEVELOPMENT OF APPENDIX (FIG. 2)

The appendix develops as a diverticulum from the wall of the cecum. The appendix appears first as a prominence in the

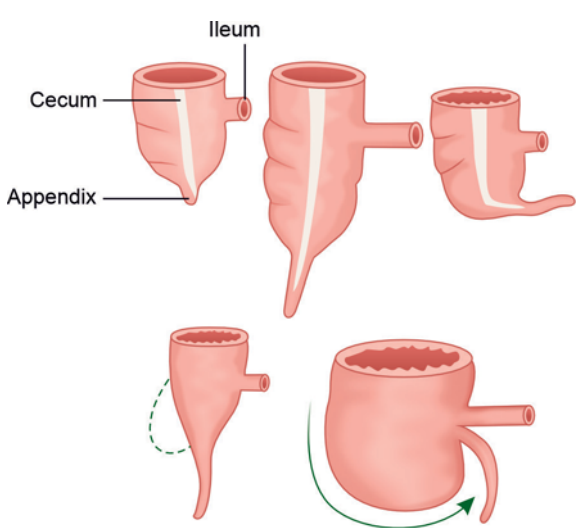

Fig. 2: Development of the appendix.

terminal part of the cecum in the eighth week of intrauterine life, it attains the shape of a tubular structure by about the age of 2 years. In an early embryonic age appendix has the same diameter as the cecum, and it lies in the line of the cecum. The excessive growth of the right and anterior walls of the cecum pushes the appendix to the medial side and posteriorly. In later stages of development, the lumen disparity between the cecum and appendix develops. The lumen of the cecum enlarges and develops fast, but the lumen of the appendix enlarges much more slowly, and the disparity develops. By the fifth month of intrauterine life, the appendix elongates and becomes vermiform in shape. At birth, the appendix is broad and short, then gradually, around 2 years of age, it acquires a tubular shape. *The position of the appendix in relation to the cecum varies greatly, but the relation between the attachment of the base of the appendix and the cecum is always constant.* The base of the appendix is always attached at the same spot as the cecum in relation to the ileocecal valve. The location of the appendix is determined by the location of the cecum. The appendix is devoid of lymphoid tissue before birth, and it appears only after 2 weeks of birth. *The lymphoid tissue increases in amount continuously from birth to puberty, then its amount becomes stationary for 10–12 years, then it starts regressing with age, and by the age of 60 years, again appendix becomes almost devoid of lymphoid tissue. The excessive growth of the right and anterior walls of the cecum pushes the appendix to the medial side and posteriorly.*

SURFACE MARKING OF APPENDIX (FIGS. 3A AND B)

The base of the appendix can be marked on the anterior abdominal wall at a point 2 cm below the point where the transtubercular plane crosses the vertical right lateral plane. McBurney's point is the site of maximum tenderness in acute appendicitis. McBurney's point is situated at the junction of the medial two-thirds and lateral one-third of the imaginary line joining the umbilicus and anterior superior iliac spine (ASIS). The position of the appendix can be marked in relation to the face of a clock (for example, the pelvic position of the appendix is mentioned as a 4 o'clock position). The base of the appendix is fixed as it is attached to the cecum, so it is marked as the center of a clock where the hands of the clock meet. The appendix is marked as the hand of a clock.

POSITION OF APPENDIX

The appendix is situated in the right iliac fossa (RIF). The anatomical position of the appendix in the peritoneal cavity is inconstant. The position of the base of the appendix is always constant in relation to the cecum. However, true but, Howard Atwood Kelly, mentioned in his book, "Appendicitis and Other Diseases of the Vermiform Appendix," that the location of the point of origin depends, entirely upon the topography of the cecum. According to whether the cecal pouch is directed upward or downward, outward, or inward, forward or backward, or whether the colon and cecum have rotated insufficiently or too much around their long axis, the point of origin of the appendix varies in position. It may be found at almost any point of the cecal pouch. The base of the appendix during operation is traced by identifying and following the three taenia coli, especially the anterior taenia coli. The position of the appendix is extremely variable, more so than that of any other organ. As the appendix is attached to the cecum so its position depends upon the position of the cecum. Usually, it is in the RIF, but due to incomplete descent of the cecum, it may be subhepatic. *The cecum may be in the pelvis or even on the left side due to malrotation of the gut*

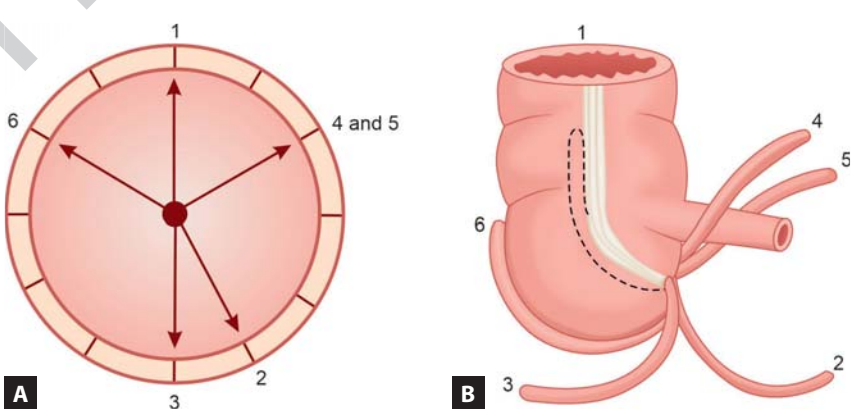

Figs. 3A and B: Positions of the appendix.

JAYPEE BROTHERS

or arrest in rotation of the gut. Appendix usually hangs and floats free in the peritoneal cavity and is fixed only in the retrocecal position or when it is inflamed. Appendix can take any of the following positions:

- *Retrocecal (12 o'clock) position (in 70% of persons):* The normal location of the appendix is retrocecal. The appendix lies behind the cecum. It may be embedded in the cecal wall. It is intraperitoneal, but sometimes also extraperitoneal. It may be sometimes difficult to elicit tenderness in RIF, as an inflamed appendix is lying behind the cecum, which is distended with gas. A long retrocecal appendix can mimic cholecystitis if only the tip is inflamed, or it can mimic ureteric colic if it touches the ureter.
- *Pelvic (4 o'clock) position (in 25% of persons):* The appendix hangs down in the pelvis. There may be no tenderness in RIF as the inflamed appendix lies in the pelvis, but deep tenderness may be elicited on digital rectal examination (DRE). The tip of the appendix, if it touches the ureter or bladder patient will have urinary symptoms. When the tip of the appendix touches the rectum patient will have rectal symptoms.
- *Subcecal (6 o'clock) position (in 2% of persons):* The appendix lies just below the cecum.
- *Preileal (2 o'clock) position (in 1% of persons):* The appendix lies in front of the terminal part of the ileum.
- *Postileal (2 o'clock) position (in 1% of persons):* The appendix lies behind the terminal part of the ileum.
- *Paracolic position (in 1% of persons):* It lies just along the lateral wall of the cecum.

Though the retrocecal position of the appendix is the most common, but in some countries, it is different, as in Iran and Bosnia, the pelvic position is most common, with 55.8 and 57.7% occurrence, respectively.

The appendix, ileum, and cecum are depicted in **Figure 4**.

SUBHEPATIC APPENDIX

Malrotation of the gut puts the cecum with the appendix below the liver. It is a very rare incident. It gives a great challenge to diagnosis. It can mimic cholecystitis and liver abscess, may lead to delayed diagnosis, and increase the chances of appendicular rupture. Dissection for subserous appendix can cause damage to the wall of the cecum, which can be dangerous if deep and can lead to fecal fistula, so all precautions must be taken while dealing with appendicectomy for subserous appendix.

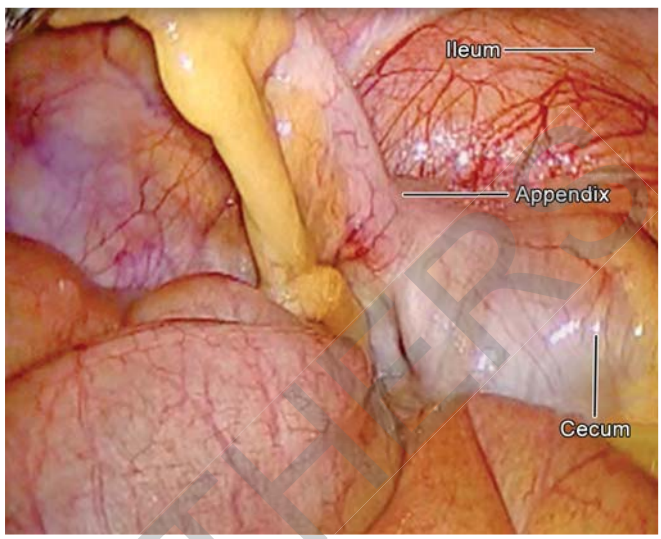

Fig. 4: Appendix, ileum, and cecum.

SIZE OF THE APPENDIX

The size of the appendix varies from person to person. Some studies have indicated a relation between the length of the appendix and with height of a person, but it is not confirmed. The usual length of the appendix is approximately 7.5 cm, but it may vary from 2 to 20 cm. It is longer in children and may atrophy after midadult life. The longest appendix ever removed was 26 cm long. The average length of the appendix is about 8.3 cm or between 3 and 3.5".

APPENDICULAR ORIFICE

It is situated 2 cm below and lateral to the ileocecal orifice at the posteromedial aspect of the cecum. It approximately corresponds to McBurney's point. Often it lies to a point below it. The appendicular orifice is sometimes, but not always, has a semilunar fold of mucus membrane, which acts as a valve and is called the "valve of Gerlach" **(Fig. 5)**.

LUMEN OF THE APPENDIX

The lumen of the appendix is approximately 2 mm wide, just sufficient to introduce a matchstick. The capacity of the lumen of the appendix is 0.1–0.2 mL. The mucus secretion beyond the obstruction site in the lumen can raise the intraluminal pressure of the appendix considerably, even by 0.5 mL of mucus. The capability of appendicular mucosa to secrete mucus even in the presence of raised in intraluminal pressure causes acute appendicitis, which is an important factor **(Fig. 6)**.

JAYPEE BROTHERS

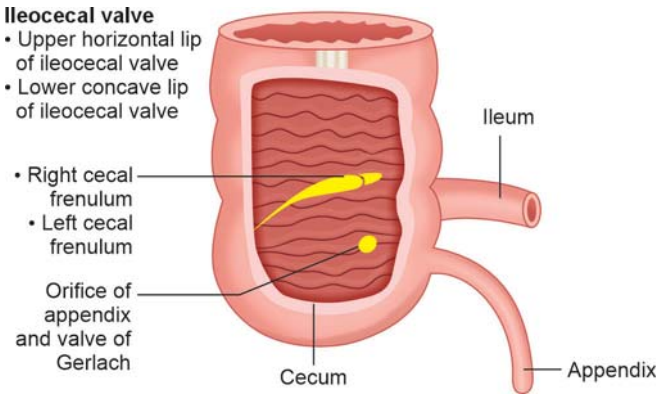

Fig. 5: Appendicular orifice and ileocecal valve.

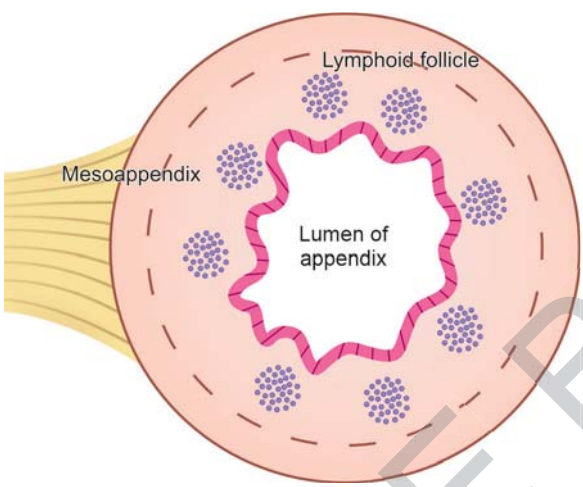

Fig. 6: Lumen and wall of the appendix.

WHY APPENDIX IS PRONE TO INFECTION?

It is due to the following facts:

- It is a long, narrow, blind-ended tube that encourages stasis of contents, which leads to the proliferation of bacteria.
- Lymphoid follicles are present in the wall of the appendix, which catches bacteria.
- The lumen of the appendix has a tendency to be blocked by hard stool (enterolith), which results in stasis.

MESOAPPENDIX OR MESENTERY OF APPENDIX

An appendix has a well-developed mesentery called "mesoappendix." It is continuous with the mesentery of the terminal ileum. It is a triangular fold of the peritoneum. The appendix is suspended in the peritoneal cavity by the mesoappendix. It fuses with the posterior layer of the mesentery of the ileum behind the terminal part of the ileum. The tip of the appendix is not covered by mesoappendix, which is one of the reasons for the early perforation of the tip of the appendix due to the lack of protective covering. The thrombosis of the appendicular artery develops due to inflammation of the appendix as the artery is directly over it. The mesoappendix contains appendicular vessels and nerves. *The mesoappendix in newborns is transparent without any fat deposit, but as we grow, it gradually becomes laden with fat. We identify the vessels in the mesoappendix by seeing them against the light. The fat-laden mesoappendix does not show vessels clearly.*

Appendicular Artery

The appendicular artery is a branch of the lower division of the ileocolic artery. It passes behind the terminal ileum to enter the mesoappendix, a short distance from the base of the appendix from the medial side, and then it runs along the free border of the mesoappendix, but at the tip of the appendix, it lies directly over the wall of the appendix. The appendicular artery gives three to four branches in its course to the appendix in the mesoappendix. The appendicular artery is an end artery, which is why acute appendicitis results in gangrene and perforation once this artery is thrombosed and blocked, causing necrosis of the appendix, which is also known as gangrenous appendicitis. A recurrent branch is given by an appendicular artery near the base of the appendix, which anastomoses with a branch of the posterior cecal artery. While putting a purse-string suture, this artery can be damaged and may cause a big hematoma. The branches of the appendicular artery form two main systems—the superficial in the serous coat, and the deep in the submucosa. From this submucous system, branches run toward the mucosa **(Fig. 7)**.

Accessory Appendicular Artery (Artery of Seshachalam)

It is a branch of the posterior cecal artery. It is quite commonly found. It supplies the base of the appendix. It sometimes bleeds a lot, if not properly ligated during appendicectomy. The tip and antimesenteric border of the appendix have the least blood supply, and therefore, these sites are prone to get gangrene and perforation. T Seshachalam, an Indian surgeon, described this artery in the 1930s **(Fig. 8)**.

JAYPEE BROTHERS

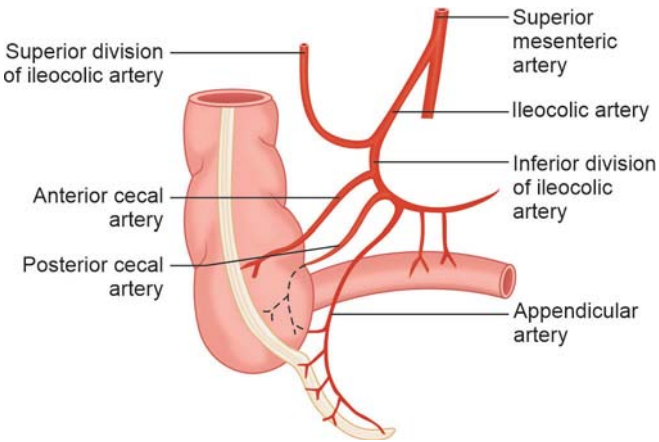

Fig. 7: Appendicular artery.

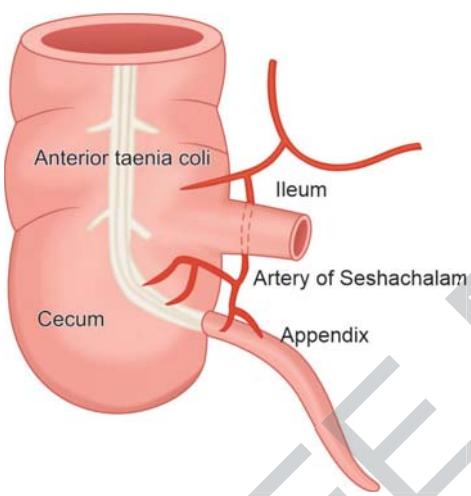

Fig. 8: Accessory appendicular artery of Seshachalam.

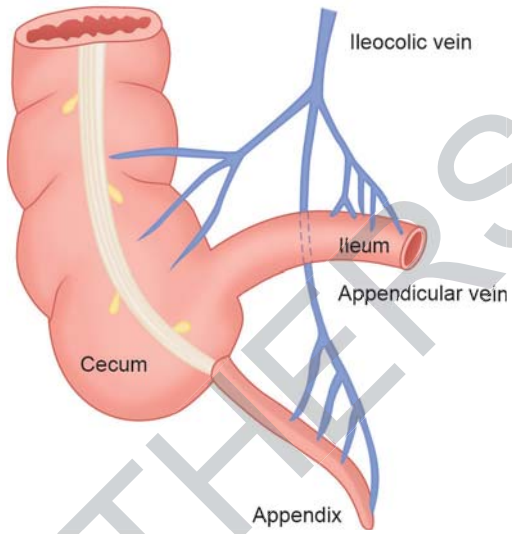

Fig. 9: Venous drainage of the appendix.

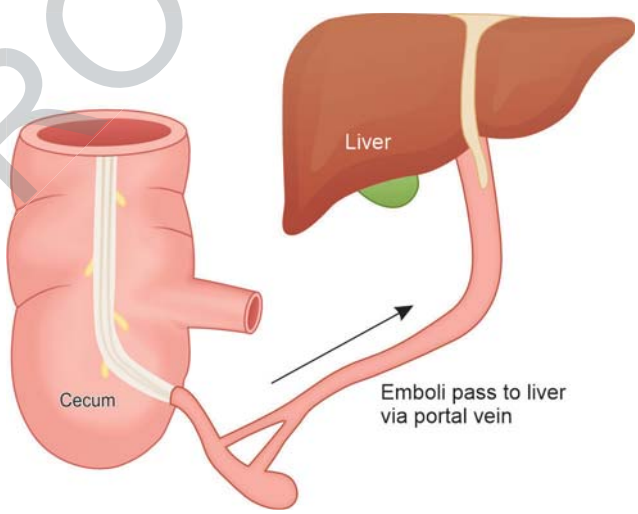

Fig. 10: Emboli passes to the liver via the portal vein.

Venous Drainage of Appendix

The veins draining the blood from the appendix follow the arteries of the appendix ***(Fig. 9)***. The tributaries from the appendix drain into an ileocolic vein, which drains into the superior mesenteric vein, which opens in the portal vein. This is part of the portal circulation. The blood reaches the liver via the portal vein due for this reason, suppurative appendicitis or appendicular abscess can lead to multiple pyemic abscesses in the liver. The veins of the appendix are generally central to the arteries. When we do appendicectomy, we crush the base of the appendix with artery forceps, which blocks the lumen of the veins, and also this avoids sending infected emboli to the portal vein and liver **(Fig. 10)**.

Lymphatic Drainage of Appendix

Lymph is drained from the appendix to the regional lymph nodes by four to six lymphatic channels ***(Fig. 11)***. *These channels carry lymph:*

- *Directly to the ileocolic lymph nodes.*
- *Some lymph passes first to the appendicular lymph nodes in the mesoappendix, and then to the ileocecal lymph nodes near the base of the appendix, and then to the ileocolic lymph nodes.* Lymph from the anterior surface of the appendix and cecum reaches via anterior cecal vessels to anterior ileocolic lymph nodes, and lymph

JAYPEE BROTHERS

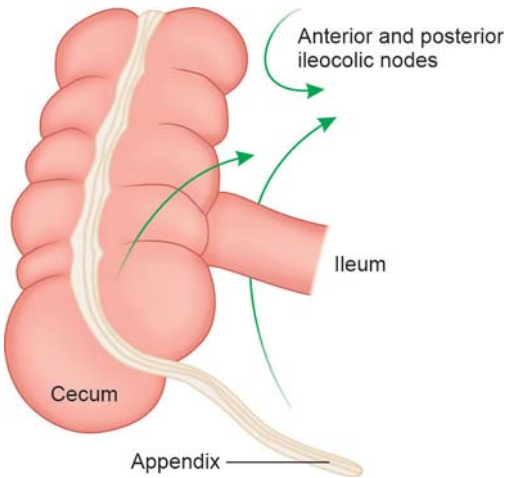

Fig. 11: Lymphatic drainage of the appendix.

from the posterior surface of the cecum and appendix reaches via posterior cecal vessels to posterior ileocolic lymph nodes. Ultimately, the lymph reaches from the ileocolic lymph nodes to the superior mesenteric lymph nodes. The lymphatics of the appendix run into superficial, middle, and deep groups. Superficial groups lie in the serosa, the middle group is between the muscle coats and submucosa, and the deep group is in the mucosa.

The lowest lymph gland is situated over the posterior cecal pouch and is called the Clades gland or the appendiceal gland. It receives lymph from the cecum and not from the appendix. In a very few instances, it received a small tributary from the cecoappendical angle.

NERVE SUPPLY OF APPENDIX

- Sympathetic nerves come from the thoracic nine (T9) and thoracic ten (T10) segments of the spinal cord through the celiac plexus.
- Parasympathetic nerves come from the vagus nerve. The pain in the initial stage of acute appendicitis is felt at the umbilicus, it is "referred to as pain" as the same segment of the spinal cord (T10), supplies the umbilicus also. It is visceral pain. Later on, the pain shifts to RIF due to irritation and inflammation of the local peritoneum. This pain is due to stimulation of nerve endings of the local peritoneum and is called "somatic pain."

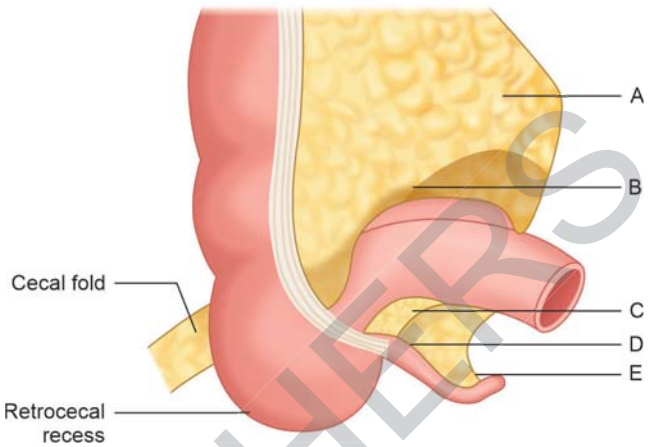

Fig. 12: Folds and recesses in relation to the appendix. (A: vascular fold of cecum; B: superior ileocecal recess; C: inferior ileocecal fold; D: inferior ileocecal recess; E: mesoappendix)

FOLDS AND RECESSES IN RELATION TO THE APPENDIX (FIG. 12)

- Superior ileocecal fold
- Superior ileocecal recess
- Inferior ileocecal fold
- Inferior ileocecal recess

Superior Ileocecal Fold and Recess

It is a commonly seen pair of folds and recesses. The superior ileocecal recess is formed by the superior ileocecal fold, which is a vascular fold present between the terminal ileum and ascending colon. The opening of the recess is directed down and medially.

Inferior Ileocecal Fold and Recess

This fold is a bloodless fold and is also called the "bloodless fold of Treves." It is between the terminal ileum and the base of the appendix. The opening of this recess is downward.

JACKSON'S MEMBRANE

It is a peritoneal fold, attached from the posterior abdominal wall to the anterior surface of the cecum on the lateral side. Sometimes it is required to cut to find out the retrocecal appendix. It is vascular and has blood vessels that run parallel **(Fig. 13)**.

JAYPEE BROTHERS

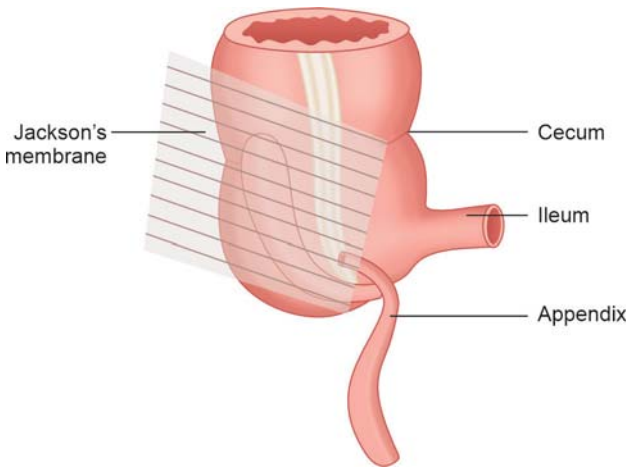

Fig. 13: Jackson's membrane.

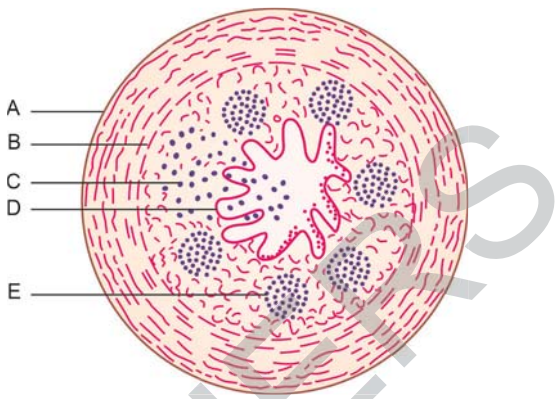

Fig. 14: Cut section of appendix. (A: serosa; B: muscle coat; C: submucosa; D: mucosa; and E: lymph follicle).

Histology of Appendix

Histology, also known as microscopic anatomy or microanatomy, is the branch of biology that studies the microscopic anatomy of biological tissues; whereas, in medicine, histopathology is the branch of histology that includes the microscopic identification and study of diseased tissue. Accurate diagnosis of a sickness sometimes requires histopathological examination of biopsied or resected tissue. Histopathology of the appendix sample after appendicectomy details the correct diagnosis, such as chronic appendicitis, subacute appendicitis, acute appendicitis, gangrene of the appendix, perforation of the appendix, and tumor of the appendix (benign or malignant). Negative appendicectomy is also confirmed by histopathological examination of the appendix sample.

The appendix has the following layers, which are similar to the intestine. These are from outside to inside **(Figs. 14 and 15)**:

- Serosa
- *Muscle coat:*
  - Outer longitudinal muscular coat
  - Inner circular coat
- Submucosa
- Mucosa

It is a complete investment of the appendix, except for a narrow strip along with the mesenteric attachment. There is a subserous layer of connective tissue. The serous layer surrounds the outer surface of the appendix. The *mesoappendix* is the continuation of the mesentery of the ileum, and it wraps the appendix and mixes with the serosa of the appendix.

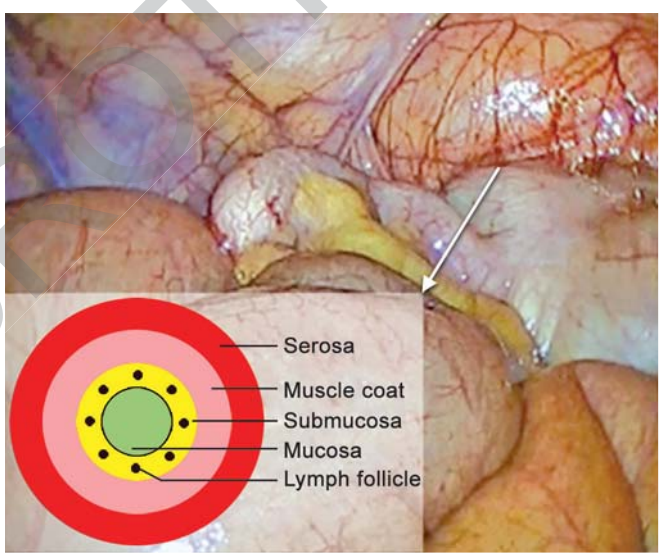

Fig. 15: Structure of the wall of the appendix.

MUSCLE COAT

It has outer longitudinal and inner circular muscle fibers, as in the small intestine, but the muscle fibers in the appendix are weakly developed in comparison to the intestine. They are deficient in some areas where the serosa and submucosa are in contact. These gaps in muscle layers are called "hiatus muscularis." Through these gaps, the infection from the mucosa reaches fast to the serosa and peritoneum quickly. These gaps sometimes act as weak spots, and perforation occurs here due to raised intraluminal pressure. Acquired diverticulum of the appendix occurs through these gaps. The longitudinal muscle layer is thicker near the base of the appendix

JAYPEE BROTHERS

to form a rudimentary *Taenia*, which is continuous with those of the cecum and colon. The circular muscle layer is separated from the longitudinal muscle layer by connective tissue. The muscularis mucosa is very thin in the appendix.

SUBMUCOSA

It has 20–40 lymphoid follicles in adults. These lymphatic tissues decrease in size as age advances. Follicular and parafollicular zones in the submucosa contain B and T lymphocytes. The lymphoid masses are a local defense against infection. Lymphoid tissues in the appendix are not present at birth but develop at 2 weeks after birth. The number of lymphoid follicles is maximum during 12–20 years of age, 200, then the number of lymphoid follicles reduces with age and almost they disappears by the age of 60 years. This is one of the reasons why acute appendicitis is rare after 60 years of age. Appendicectomy does not cause any change in a person's immune response or cause any cancer. The appendix is also called "abdominal tonsil" due to its rich lymphatic tissue presence.

MUCOSA

The mucosa of the appendix resembles that of the colon. It has several longitudinal folds. The number of crypts in Lieberkühn is less as compared to the colon. *Crypts of Lieberkühn contain Kulchitsky cells or Argentaffin cells.*

The openings of the crypts of Lieberkühn are arranged around certain centers marked by a depression on the surface of the apices of lymph follicles. Nikolai Kulchitsky, first time, described argentaffin cells, which are responsible for tumors. As with the rest of the colon, there are mucus-secreting goblet cells.

The thickness of the longitudinal muscular coat of the appendix varies in different individuals and also in the same specimen from 0.2 to 0.3 mm. The circular muscular coat measures from 0.2 to 0.5 mm in width. The thickness of the submucosa varies greatly in different individuals (0.2 to 0.8 mm or more). It is this layer that gains the most in thickness during the process of obliteration. The submucosa consists of loose, wavy strands of fibrous and elastic tissue that form a framework for the blood, lymph vessels, and nerves. In the interspaces are fat globules. The mucosa is bound to the submucosa by the vestiges of muscularis mucosa. The mucosa presents an irregularly folded appearance, the folds running parallel with the longitudinal axis of the appendix.

Functions of Appendix

The vermiform appendix is a small tubular structure attached to the cecum. Earlier appendix was considered a vestigial organ, serving no function, but now the view has changed. An appendix is found to store and develop body-friendly flora of the intestine that can redevelop after its loss in sicknesses of the digestive tract. An appendix also plays a role in immune function as it contains lymphoid tissue. The appendix has been shown to have an important interaction with the intestinal flora. Though the appendix was considered a vestigial organ but it is found that it is well developed in some animals, which casts doubt on it being as a vestigial organ. In view of its rich vascularity and histological differentiation, the appendix is probably a specialized rather than a degenerate or vestigial organ.

So, it is not considered a vestigial organ and it does not take an active part in the immunity of the body, but:

- *Lymphoid follicles help in the maturation of B-lymphocytes.*
- *Appendix is a part of gut-associated lymphoid tissue (GALT) and forms globulin, which is required for an immune mechanism of the body.* It is proved now proven that appendicectomy does not increase the incidence of carcinoma of the colon, which was doubtful in studies in 1960. The removal of the appendix does not cause a defect in the immunoglobulin system's functioning. So, we can take the following functions of the appendix into consideration.

TO MAINTAIN GUT FLORA

William Parker, Randy Bollinger, and colleagues at Duke University proposed in 2007 that the appendix serves as a haven for useful bacteria when illness flushes the bacteria from the rest of the intestines. This reservoir of bacteria could then serve to repopulate the gut flora in the digestive system following a bout of dysentery or cholera or to boost it following a milder gastrointestinal illness.

IMMUNE FUNCTION

An appendix is an important part of mucosal immune functions through B and T cells to fight off pathogens. Innate lymphoid cells of the gut help the appendix to maintain digestive health.

VESTIGIALITY

Earlier, it was proposed that the human appendix was a vestigial organ, as during evolution, the cecum was thought to have shrunk in size and its remnant was the appendix.

JAYPEE BROTHERS

After millions of years, the once necessary cecum degraded to become the appendix of modern humans. Humans have a diet rich in foliates (cellulose-rich plants), but now take easily digestible foods, so a long cecum is not required to host bacteria digesting cellulose.

Though there is no clear role of the appendix in the causation of human disease but studies have shown a correlation between appendicectomy and the development of inflammatory bowel disease (IBD), especially ulcerative colitis. The appendix delays the onset of ulcerative colitis. Association of inflammatory bowel disease is not so clear as in ulcerative colitis.

Diseases of the Appendix

Schnitzler was of the opinion that the so-called chronic appendicitis did not exist. Deaver, on the other hand, believed chronic appendicitis to be a clinical entity and divided it into two distinct types—that which occurs after acute appendicitis and that which has always taken the form of chronic inflammation without acute exacerbation. He felt that there could be a differential diagnosis in these two types of chronic appendicitis. He stated his belief that in cases of chronic peptic ulcer, chronic cholecystitis, ureteric colic, Dietl's crisis, and chronic pelvic inflammatory disease, the appendix is commonly unjustifiably removed.

Congenital Anomalies of the Appendix

According to the World Health Organization (WHO), congenital disorders can be defined as structural or functional anomalies that occur during intrauterine life. Congenital anomalies of the appendix are quite rare—the absence of an appendix, duplication of the appendix, and its diverticulum have been mentioned in the literatures.

AGENESIS OF APPENDIX

Absence of Appendix

It is a very rare occurrence, one in 100,000 cases. Sometimes it is not congenital, but the appendix is autodigested after an attack of acute of appendicitis or appendicular abscess.

DUPLICATION OF APPENDIX

It is also an extremely rare occurrence. A total of 10 cases have been reported in the literature so far. One case reported having one normal appendix, and the other one was inflamed. Maizels G has reported that failure to identify the presence of appendiceal duplicates has resulted in appendectomy being performed twice.

Wallbridge Classification of Duplication of Appendix

- *Type A*: Partial duplication in a single cecum.
- *Type B*: Two separate appendices in a single cecum.
- *Type C*: Double cecum with each one having one appendix.

Appendix in Left Iliac Fossa

It is found in situs inversus viscerum. It occurs in one in 35,000 cases. It also occurs due to malrotation of the gut.

Subhepatic Appendix

It is the most common type of all congenital anomalies of the appendix. It is due to the arrest of the downward migration of the cecum. In this position, it may be close to the gallbladder, so in such a situation, the acute appendicitis mimics acute cholecystitis.

Diverticulum of Appendix

Diverticula of the appendix are rare. They are either congenital or acquired. The wall of the congenital appendicular diverticulum contains all layers. Congenital diverticulum is a rare entity; acquired diverticula occur more frequently. The mucosa of the appendix balloons out from the weak spots in the walls, "Hiatus muscularis." If the appendix with a diverticulum develops appendicitis, then perforation of the appendix occurs early due to a weak wall. The inflammation of the vermiform appendix is called "appendicitis."

TYPES OF APPENDICITIS

Appendicitis can present in the following forms:

- Acute appendicitis
- Subacute appendicitis
- Recurrent appendicitis
- Chronic appendicitis
- Grumbling appendix
- Pseudoappendicitis
- Residual appendicitis
- Appendicitis granulosa
- Appendicitis larvata

Acute Appendicitis

Acute appendicitis is the most common and dangerous type of appendicitis, others are milder versions of acute appendicitis.

JAYPEE BROTHERS

Subacute Appendicitis

Subacute appendicitis is actually a milder form of acute appendicitis. If the acute appendicitis subsides before reaching to full-blown appendicitis, it is called subacute appendicitis. The symptoms subside, and the pain disappears. It may recur again. It is treated with appendicectomy, which relieves the pain and prevents future complications.

Recurrent Appendicitis

It is a milder variety of appendicitis that occurs recurrently, there is a symptomatic interval between attacks. It is a common variety of appendicitis. The appendix shows the obliteration of its lumen by fibrosis due to recurrent inflammation. Appendicectomy is the treatment of choice. Recurrent appendicitis occurs with an incidence of 8–14% following the resolution of the acute episode. Out of 142 cases, 92% of the removed appendix showed abnormality, and 95% of these patients were cured.

Chronic Appendicitis

Some researchers say that there is no entity called chronic appendicitis; it is actually recurrent appendicitis. However, recent clinical data document the existence of this uncommon disease. In this type of appendicitis, there is persistent RIF pain. The appendicectomy relieves the pain and other symptoms. Pain lasts longer and is less intense than acute appendicitis. Pain, nausea, anorexia, malaise, and pain with motion are frequent features. The white blood cell (WBC) count and computed tomography (CT) scan are normal. The color of the appendix is reddish with white island areas. The appendix is rigid and bent over itself and is often spiral. The mesoappendix is thickened, shortened, and indurated. The histopathology of the removed appendix shows chronic inflammatory cell infiltration in the wall of the appendix. It may show an old, healed scar of previous inflammation. Appendix may show adhesions, kinks, and nodularity. Appendicectomy is the treatment of choice for chronic appendicitis.

Chronic appendicitis develops either after an acute appendicitis episode or erupts in chronic form. Chronic appendicitis may occur in recurrent form, relapsing form, or in residual form. Recurrent form of chronic appendicitis has repeated attacks of subacute or mild-acute attacks, followed by a disease-free interval. Relapsing form is a continuous form where the patient is never free from symptoms. Residual form of chronic appendicitis is due to residual effects of previous attacks of acute appendicitis, such as adhesions and angulations.

Grumbling Appendix

Recurrent bouts of pain in RIF are sometimes called "grumbling appendix." It is usually a milder recurrent appendicitis. It is common in children. They have been admitted several times in the hospital with pain in the RIF. The grumbling of the appendix is relieved by appendicectomy. It is associated with recurrent pain in RIF, general malaise, tenderness over the appendix, and anorexia.

Pseudoappendicitis

This appendicitis is due to acute ileitis.
It is caused by the following factors:

- Yersinia
- Crohn's ileitis

Residual Appendicitis

Residual deformities of the appendix develop after active inflammation subsides. After the attack of acute or chronic appendicitis, it may be hypertrophy or atrophy, stricture, closure of the lumen, cyst formation, dilation, kink, diverticula, adhesions, or fibrosis. This can cause recurrent pain in RIF. Stump appendicitis is also considered as residual appendicitis, which occurs in the stump of the appendix left after appendicectomy. It is a rare entity. It is difficult to differentiate clinically from acute appendicitis, which delays the diagnosis and treatment. This reminds us to avoid leaving a big stump during appendicectomy.

Appendicitis Granulosa

Riedel believes that acute appendicitis has always had an insidious onset, one of the most important predisposing causes being a chronic primary disease, "appendicitis granulosa". Chronic inflammation of the appendix is essentially a hypertrophic process and produces a characteristic thickening and rigidity of its wall. In rare instances the inflammatory reaction seems to be confined to the mucous membrane, but, as a rule, all the coats are more or less affected.

Note: Alexandre Émile Jean Yersin, 1863–1943, Bacteriologist, Paris, France, discovered the bacillus causing bubonic plague, which was later named after him, "*Yersinia pestis*."

Appendicitis Larvata

The clinical condition described by Lenzmann and by Ewald as appendicitis larvata, acute or chronic appendicitis,

JAYPEE BROTHERS

exceedingly rarely results in a "restitutio ad integrum" (restoration to original condition). In the mildest cases, there is more or less connective—tissue hyperplasia, and as a consequence, a certain amount of rigidity and enfeebled muscular power persisted. This is also called latent *appendicitis*.

ACUTE APPENDICITIS

Acute appendicitis may be divided into the following groups clinically:
- Catarrhal
- Purulent
- Gangrenous
- Perforative

HISTORICAL BACKGROUND

The acute appendicitis has been reported since 1500 AD, it used to be called "perityphlitis," which they used to meant severe and fatal inflammation of the cecal region of the large intestine. Jean François Fernel, a French physician and astronomer, was the first who reported a case of appendicitis in 1554 when he noted at autopsy the luminal obstruction, necrosis, and perforation of the appendix and cecum. He was the first to describe this disease as "perityphlitis."

Reginald Heber Fitz, Professor of Medicine, Harvard University, Boston, USA, was credited for describing acute appendicitis as a proper clinical entity for the first time. He presented a scientific research paper in the first meeting of the Association of Physicians of America in 1886 entitled. "Perforating inflammation of the vermiform appendix." This paper helped doctors to diagnose more and more cases of acute appendicitis at an early stage of acute appendicitis. He studied 25 patients and found that the appendix was the primary site and source of inflammation in perityphlitis.

French Surgeon Claudius Amyand performed the world's first successful appendicectomy at St George's Hospital, London, on an 11-year-old boy who swallowed a pin. It was a perforated appendix.

In 1889, Charles McBurney, Professor of Surgery, Columbia University College of Physicians and Surgeons, New York, NY, USA, described the clinical manifestation of acute appendicitis, including the point of maximum tenderness in the RIF, which later on was called "McBurney's point." Appendectomy for appendicitis is one of the advancements of surgery. Surgical treatment of appendicitis saves 8 million lives per year in the USA alone.

ACUTE CATARRHAL APPENDICITIS

Catarrhal appendicitis is an inflammatory process affecting only the mucous lining of the appendix throughout the attack, and not involving the deeper layers. In all cases of acute appendicitis, there is probably an early stage in which the reaction is limited to the mucous membrane, but in the majority of cases, this is only momentary, and so speedily gives way to a general involvement of all the coats.

Macroscopically, in acute endoappendicitis, the appendix appears slightly thicker than normal, and owing to more or less general edema, it may be somewhat rigid. The superficial blood vessels, both those immediately beneath the peritoneum and those between the subperitoneal fibrous layer and the muscle, are prominent and tortuous, presenting a characteristic arborescent appearance. There is not, however, the diffuse redness of inflammatory tissue; on sectioning the appendix, its canal is found to be patent, and, as a rule, is of uniform caliber. The mucosa is swollen, edematous, diffusely injected, and granular in appearance.

In the gross specimen, the difference between an inflammation limited to the mucosa and the diffuse process is at once evident. In diffuse inflammation, the appendix shows a notable increase in all of its dimensions, and instead of the normal, pale, flaccid organ, of about the thickness of a goose quill, it may be twice the usual length and is often as thick as the index finger, the tip being frequently slightly clubbed. The appendix is usually tense and rigid, and exceedingly hyperemic, the blood vessels standing out in high relief. Its color is a diffuse bright red or dark mahogany, mottled with subperitoneal extravasations of blood, and often presenting light yellowish or greenish-yellow areas due to localized foci of suppuration or necrosis. Simple catarrhal appendicitis may undergo complete repair, and in cases that presented clinical evidence of repeated attacks, the appendix, when removed in the interval, may appear quite normal.

PURULENT APPENDICITIS

There is no sharp dividing line between purulent and nonpurulent appendicitis, and at any moment, a nonpurulent process may become purulent. The nature of the inflammatory reaction is chiefly due to the virulence of the infection. A mild infection is commonly not suppurative, while a severe infection induces suppuration unless the virulence of the infective material is so great that no migration of leukocytes occurs. In suppuration, there is, first, necrosis of the tissue invaded, and second,

JAYPEE BROTHERS

the reaction of the tissue, producing cells which form the purulent exudates. Suppuration is evidence of the ability of the tissue to offer resistance to the invasion of the infective agent.

GANGRENOUS APPENDICITIS

This condition is essentially characterized by the death and putrefaction of the tissues and is due to the action of microbes upon tissue. The most important factors, including gangrene are of which act by obstructing circulation, and so producing local ischemia. Interruption to the blood current may occur in one of the small arteries that supply only a limited portion of the appendix, or the main artery may be involved; or, in some instances, both the vein and artery, in which case the entire appendix becomes gangrenous. The obstruction to the circulation may be caused by thromboangiitis, twists, angulations, and compressions by adhesions or by hernial rings. Localized areas of gangrene may also be produced by the pressure of concretions. The pressure of concretion, added to the acute edema that accompanies the early inflammatory changes, compresses the tissue and produces local ischemia with subsequent gangrene. Most frequently, the tip of the appendix is affected, but it is not unusual to find several distinct areas of gangrene both in the proximal and the distal portions of the appendix. The role of bacteria in the production of tissue necrosis is an important one, and in cases where the gangrene of the appendix is partly due to mechanical influences, the heightened virulence of the contained bacteria, in the presence of the lessened vitality of the tissues, undoubtedly promotes the destructive process. The mesoappendix in acute inflammation becomes greatly thickened, due to the dilatation of the blood vessels, and the infiltration of the lax areolar tissue with the serous and cellular exudates. The tissue also becomes exceedingly friable, so that the ligature, although placed with the utmost care, often tears directly through it.

In the appendix, gangrene sometimes occurs only at the proximal part, and it may be due to the presence of a concretion. In this form of gangrene, the appendix remains healthy except for the proximal part connecting with the cecum. In such a form of gangrene, the appendix may lose the attachment to the cecum and fall off into the peritoneal cavity.

PERFORATED APPENDICITIS

Perforation may take place in any variety of acute appendicitis and in any stage of the attack. The rupture may be of pin-hole size, or there may be a wide, ragged aperture through which a large concretion can escape. The factors concerned in the production of a rupture are various; it may follow the eruption of an erosion to the peritoneal surface, the degeneration of the tissue due to purulent infiltration, or it may be the result of thrombosis or embolism. If perforation occurs in the appendix near its base, then it may become completely detached from the cecum and float free in the abscess cavity, as can also occur in gangrene of the appendix. It may get attached to any neighboring organs through adhesions. A tensely distended empyema often terminates in the rupture of the appendix walls, and it is particularly in such cases, where a large amount of highly virulent material empties into the abdominal cavity, that the most fatal forms of peritonitis result. One of the most important causes of rupture is the necrosis of the tissue, induced by the presence of concretions. The favorite location of the perforation is at or near the tip of the appendix, but it is not uncommon to find the perforation directly at the base or at some intermediate point. A perforation at the base may involve the neighboring portion of the cecum and produce a wide opening through which the intestinal contents escape.

Risk factors for perforation of the appendix:

- Extreme of age
- Immunosuppression
- Diabetes mellitus
- Fecolith obstruction
- Pelvic appendix
- Previous abdominal surgery

ETIOLOGY OF ACUTE APPENDICITIS

Common etiological factors of appendicitis:

- Diet
- Familial tendency
- Hereditary factor
- Nationality
- Viral infection
- Lumen of the appendix
- Socioeconomic status
- Obstruction of the lumen of the appendix
- Nonobstructive theory
- Purgatives
- Racial factor
- Epidemic of acute appendicitis
- Seasonal variation of acute appendicitis
- Trauma
- Menstruation

JAYPEE BROTHERS

Appendicitis is one of the most common acute problems in medicine, yet we do not know much about its etiology. The real cause of acute appendicitis is still not known. We now understand the process of acute appendicitis well. The important contributing factors are discussed further.

Diet

Burkitt found a higher incidence of appendicitis in the West, and he attributed this to the low-fiber and high-sugar diet. It is found that the incidence of appendicitis is higher in the low-fiber, meat-rich, westernized diet-consuming population than in the high-fiber, vegetarian (cellulose) Indian diet-consuming population. There is an increasing incidence of appendicitis when the diet changes to a low-fiber Western-type diet. However, the role of diet in the etiology of acute appendicitis has not been clarified and the role of dietary fiber is less convincing than was originally thought. The reasons for and against it are:

- *The low-fiber diet-consuming persons have small stools, which take more time to pass through the intestine, and this changes the bacterial flora of the gut.*
- The high-fiber diet increases the bulk of stool, which takes less time to pass through the intestine, and bacterial flora change does not happen.
- *Some people feel that the role of a high-fiber diet in the prevention of acute appendicitis is highly exaggerated.*
- The low-fiber diet reduces the mobility of the intestine, which predisposes for obstruction of the appendix with a fecalith.
- *The incidence of appendicitis is going down in the countries in the West where the intake of dietary fiber is gradually increasing.*
- Appendicitis occurs in newborns and pure vegetarians also, which raises the doubt about the role of fiber-rich vegetarian diet in keeping the incidence of appendicitis low.
- *There is an increase in the incidence of acute appendicitis if high-fiber diet people change to a low-fiber diet.*
- There is also epidemiological evidence indicating that the consumption of green vegetables and tomatoes may be protective against appendicitis, whereas potato consumption appears to be related to the disease. In elderly patients, there is some evidence that chronic intake of nonsteroidal anti-inflammatory drugs (NSAIDs) may increase the risk.

Familial Tendency

Sometimes several members of the same family suffer from appendicitis, which may be a familial tendency (30%), or they are consuming the same diet. It is seen in a long retrocecal appendix (which many members of the same family may have) where the blood supply of the distal part of the appendix tip is diminished which precipitates appendicitis. Genetic factors theory can be explained by the following factors:

- Shared dietary habits
- Genetic resistance to bacterial flora
- Inheritance of fibrous band anomalies in the appendix.

Hereditary Factor

Sometimes, a particular anatomical position of the appendix is found in many members of the same family, which is inherited. The familial anomaly may be the cause of acute appendicitis. A family predisposition is explicable upon the grounds of anatomic peculiarities and constitutional predisposition. It is well known that in some families there is a marked tendency toward affections of the lymphoid tissues. As a rule, the affection appears in the various members of the family at different periods, but there are a considerable number of observations referring to its development in two or more at the same time.

Nationality

Though this factor seems to be of not much importance, but some researchers have found that appendicitis is much less common in colored people (Africans) than white people. Some found it rare to see appendicitis in Africans. Various nations have different incidences of acute appendicitis. Incidence is taken as a number of cases per 100,000 people.

Viral Infection

The relationship of viral infection and acute appendicitis is based on the following factors:

- Appendicitis seems to have seasonal variations, as a viral infection does.
- Raised viral antibodies have also been found during appendicitis.
- Lymphoid hyperplasia in the submucosa of the appendix is commonly seen in histopathology in appendicitis. Viral infection may enlarge the lymphoid

JAYPEE BROTHERS

tissue, causing blockage of the lumen of the appendix, leading to appendicitis. Viral infection causes mucosal inflammation, which gets secondarily infected, leading to acute appendicitis. Most commonly, appendicitis is found in association with influenza, leading to catarrhal appendicitis.

Lumen of Appendix

The lumen of the appendix is quite narrow, and so it is prone to getting obstructed. Approximately 60% of inflamed appendix removed during appendicectomy for acute appendicitis show blockage of the lumen. The blockage is most commonly found due to a fecalith, but rarely a neoplasm of the cecum (<1% is also responsible).

Socioeconomic Status

- *Appendicitis is more common in rich and uppermiddle-class people.* The reason for this is known as probably they tend to take more protein as the main dish and try to ignore vegetables thereby taking a low-fiber diet or high-caloric diet.
- *The role of personal hygiene and domestic overcrowding is considered as one of the reasons for infection.*

OBSTRUCTION OF THE LUMEN OF THE APPENDIX

Obstruction of the lumen of the appendix is the most common factor in causing acute appendicitis. Wangensteen studied the anatomy of the appendix and postulated that mucosal folds and sphincter-like orientation of muscle fibers at the appendiceal orifice make the appendix susceptible for obstruction. The cause of obstruction of the lumen may be in the lumen, in the wall, or outside the wall of the appendix. Lymphoid hyperplasia and fecalith are the most common factors in appendicular lumen obstruction; 60% of obstruction in teens is due to submucous lymphoid hyperplasia, and 35% in older adults and children.

Causes of Obstruction

- *In lumen:*
  - Fecalith
  - Worm
  - Foreign body, i.e., seeds of fruits
- *In the wall:*
  - Hyperplasia of lymphoid follicles
  - Fibrosis and stricture due to previous appendicitis—if a normal appendix get adherent to a neighboring organ or a previous operation scar, it becomes prone to inflammation.
  - Neoplasm
  - Crohn's disease
  - Distal colonic obstruction
- *Outside the wall:*
  - Adhesions
  - Kinks
  - Bands
- *Fecalith: It is a mass of inspissated fecal material, and it is made up of:*
  - Fecal material
  - Calcium phosphate
  - Bacteria
  - Epithelial debris
  - *Foreign body:* Foreign bodies causing appendicitis are rare, but Fitz, in 1886, found foreign bodies in 12% of cases of perforative appendicitis. Gallstones are also found as enterolith inside the appendix. The clinical evidence in some of these cases so strongly supports the gallstone theory as to leave no doubt in the mind of the observer. Global distribution of appendicitis varies according to various factors, such as geographic site, eating habits, and environmental factors. Fecaliths are the most common cause of appendicitis. They are found in 40% of cases of acute appendicitis, 65% of cases of purulent appendicitis with rupture, and nearly 90% of cases of gangrenous appendicitis with rupture. It is also found that a histologically normal appendix having fecalith and appendicitis may show no fecalith obstruction. A fecalith in combination of localized right lower quadrant (RLQ) pain is highly diagnostic of appendicitis. The fecalith is also called an enterolith.

Worms: Usual parasites found in the appendix are the following:
- Pin worm (Oxyuris vermicularis)
- *Ascaris lumbricoides*
- *Enterobius vermicularis*
- *Strongyloides stercoralis*
- *Echinococcus* granulosus
- *Entamoeba histolytica*

The most common intestinal parasite causing obstruction of the appendix lumen is pinworm (Oxyuris vermicularis). Careful examination of stools for worms and ova is important. The presence of parasites in the lumen of the appendix sometimes produces difficulty in ligation or stapling of the base of the appendix. All such cases must be given deworming treatment post appendicectomy, and cases of amebiasis with antiamoebic therapy.

JAYPEE BROTHERS

Nonobstructive Theory

This is due to bacterial infection in the wall of the appendix without obstruction of its lumen. It is due to the following factors:

- Hematogenous spread of generalized infection.
- Vascular occlusion
- Diet with low roughage
- *Disorders of digestion:* Many persons suffering with appendicitis have a history of indigestion or constipation or diarrhea.

Purgatives

Acute appendicitis sometimes is precipitated by the administration of purgatives, and it can cause perforation of the appendix in a patient suffering from acute appendicitis. That is why purgative is contraindicated in RIF pain as generally it is said "purgation means perforation."

Racial Factor

It is seen that appendicitis is most common in white Westerners than in dark-colored Asians and Africans.

Epidemic of Acute Appendicitis

The epidemic of acute appendicitis is also reported. It usually occurs in institutionalized children.

Seasonal Variation of Acute Appendicitis

In Europe, it has been observed that between May and August, more cases of acute appendicitis are reported in hospitals. In some Western countries, a link between viral infection and appendicitis is found which also explains the seasonal variation.

Menstruation

The intimate relationship existing between menstrual periods and appendicitis has been frequently noted, not only when the appendix is situated in the pelvis, but also when it is retrocecal. The probable explanation lies in the fact that the congestion of the whole splanchnic area which accompanies the lowered blood pressure (BP) of the peripheral circulation during menstruation creates a favorable soil for the activities of the microorganisms contained in the appendix. I have observed this association in several instances, in some of which the recurrent appendiceal attacks invariably occurred during the menstrual period.

PATHOLOGY OF ACUTE APPENDICITIS

Acute appendicitis starts as inflammation and then converts to infection of the appendix. The infection in the appendix develops from the bacteria contained in the contents of the appendix. No single organism is found responsible for acute appendicitis. Usually, it is a mixed infection with aerobic and anaerobic bacteria. The obstruction of the lumen accelerates the process of infection as the contents become stagnant and bacteria multiply fast. The bacteria gain access to the wall of the appendix through a breach in the continuity of the mucosa of the appendix.

The infection and inflammation spread in the wall of the appendix from inside to outside (from mucus membrane to the serosa) which is why sometimes at an early stage of appendicitis appendix looks normal from the outside but on exploration it is found inflamed from the inside, it is called "macroscopic normal appendix" but microscopically it is diseased.

Bacteriology

The infection in an appendix is a mixed infection by anaerobic and aerobic organisms. In 85% of cases, the organism responsible is Escherichia coli.

The appendiceal flora remains constant throughout life except *Porphyromonas gingivalis* which is seen only in adults. *Porphyromonas* is a gram-negative, rod-shaped, anaerobic, pathogenic bacterium. It is found in periodontal disease, the gastrointestinal tract, and the respiratory tract.

- Peritoneal fluid cultures show bacteria in <50% of cases of nonperforated appendicitis and in >85% of cases of perforated or gangrenous appendicitis.
- It is usually caused by organisms normally residing in an appendix.
- *Enterococcus* is also responsible for appendicitis infection in a large number of cases.
- In 1938, Altemeier demonstrated the polymicrobial nature of perforated appendicitis. Now due to this, the routine peritoneal culture in perforated appendicitis is questioned.
- The bacteria commonly contained in an appendix in acute appendicitis are given below.

COMMON ORGANISMS SEEN IN PATIENTS WITH ACUTE APPENDICITIS

Foul-smelling odor in a perforated appendix is not due to *E. coli* or anaerobic bacilli, as it is commonly and wrongly believed, but is due to anaerobic streptococci.

JAYPEE BROTHERS

TABLE 1: Common organisms seen in acute appendicitis.

Aerobic and facultative	*Anaerobic*
Gram-negative bacilli	Gram-negative bacilli
Escherichia coli	*Bacteroides fragilis*
Pseudomonas aeruginosa	*Bacteroides* species
Klebsiella species	*Fusobacterium* species
Gram-positive cocci	Gram-positive cocci
Streptococcus species	*Peptostreptococcus* species
Streptococcus species	Gram-positive bacilli
Enterococcus species	*Clostridium* species

Routine culture of intraperitoneal samples in patients with either perforated or nonperforated appendicitis is questionable, the peritoneal fluid culture should be reserved for immunosuppressed patients and those who developed abscess after appendicitis **(Table 1)**.

Obstructive Acute Appendicitis

In most of cases of acute appendicitis, the obstruction of its lumen is the main and essential reason. Obstruction is found in 50–80% of cases of acute appendicitis. Gangrene and perforation of the appendix usually do not occur if the appendix is not obstructed. When obstruction happens due to lymphoid hyperplasia or other obstructing agents, the intraluminal pressure in the appendix increases due to continuous mucus secretion and inflammatory exudate formation, and a closed-loop obstruction is produced. Secretion of even 0.5 mL of fluid distal to obstruction raises intraluminal pressure to quite a high level. Rapid distension of the appendix ensues because of its small luminal capacity, and intraluminal pressure can reach 50–65 mm Hg. The distension of the appendix stimulates nerve endings of visceral afferent nerve fibers, producing dull, vague, diffuse pain in midabdomen or lower epigastrium, it also causes reflex nausea and vomiting. The raised intraluminal pressure does not decrease or stop further mucus secretion. The raised intraluminal pressure obstructs the lymphatic drainage from the wall of the appendix, which leads to the edema of the wall. The high intraluminal pressure and edema cause superficial ulcerations in the wall, which become a port of entry for the bacteria to the wall of the appendix from the luminal contents. The further increase in intraluminal pressure causes venous obstruction, which further increases the edema of the wall. Now, the increased intraluminal pressure, venous obstruction, and increasing edema of the wall cause compromise of arterial blood flow, which leads to ischemia of the wall. Further bacterial invasion causes full-blown acute appendicitis.

TYPES OF ACUTE APPENDICITIS

Acute appendicitis is of two types:

1. Obstructive acute appendicitis
2. Nonobstructive acute appendicitis

The further development leads to acute gangrenous appendicitis and then the further increase in intraluminal pressure causes perforation of the wall of the appendix, leading to local or general peritonitis. The body tries to limit the damage and tries to prevent the spread of infection to other parts of peritoneal cavity. So, loops of the small intestine, greater omentum, and cecum come close and become adherent to wall-off the appendicular lesion to avoid peritoneal contamination. This leads to the formation of an appendicular mass or lump. The omentum is therefore called "abdominal policeman," as it helps to contain the problem. Rarely, the obstructed appendix become a mucus-filled sac called "mucocele of appendix" when infection subsides and sometimes it becomes "empyema of the appendix," when the obstructed appendix becomes filled with frank pus. The most dreaded complication of appendicitis is perforation of a gangrenous appendix leading to generalized peritonitis. *Sir David Wilkie, Professor of Surgery, Edinburgh, Scotland (1882–1938) stated that close examination of gangrenous appendicitis directly after their removal shows conclusively that they usually belong to the obstructive group.* Usually, the perforation occurs at the tip of the appendix due to poor vascularity or at the site of obstruction due to pressure necrosis, or at the antimesenteric border. The fate of appendicitis can lead to resolution, operation, perforation, peritonitis, fecal fistula, appendicular mass, abscess. This appendicular condition leads to enlargement of cecum due to cecal localized ileus, caused by the inflammatory process. The cecal content is stored and is not conducted to the right colon. The presence of fecal loading inside a large cecum is identified in the plain abdominal radiography as a specific sign of acute appendicitis.

Nonobstructive Appendicitis (Catarrhal Appendicitis)

The infection occurs in the wall of the appendix from the mucosa and the process of inflammation is slow. Nonobstructive appendicitis is usually a catarrhal type of appendicitis. Generalized peritonitis is not a common finding with nonobstructive appendicitis but it can occur. It occurs due to:

- Transmigration of bacteria to the peritoneal cavity through the wall of the appendix.
- Rarely due to perforation of the appendix.

JAYPEE BROTHERS

Macroscopic Changes

In a normal-looking appendix, only the mucosa is inflamed, so every normal-looking appendix must be opened to see the mucosa.

- Early stage of acute inflammation—the appendix is swollen with hyperemic serosa.
- Late stage of acute inflammation—the surface is coated with fibrinopurulent exudates with prominent vessels. In later stages, edema, necrosis, and gangrene develop.

Microscopic Changes

- Neutrophilic infiltration of the muscularis mucosa is characteristic of acute appendicitis.
- Congestion, edema, microabscesses, immobilized blood vessels, necrosis, and gangrene may be seen.
- The cause of obstruction is also confirmed. Many patients, who are forced to undergo an operation with acute appendicitis, give a history of previous similar, but less severe, attacks of RLQ pain.
- Pathologic examination of the appendices removed from these patients often reveals thickening and scarring, suggesting old, healed, and acute inflammation.

CLINICAL FEATURES OF ACUTE APPENDICITIS

Incidence

The lifetime incidence of acute appendicitis is 6.7–20%, with a lifetime risk of appendectomy of 12% for men and 23% for women. Acute appendicitis represents about 17% of all cases of acute abdominal pain presented to the hospital. Acute appendicitis is the most common emergency in surgery, where a general surgeon is called. It is the most common cause of acute abdomen in young adults. It is more common in Western countries than in India, probably due to diet, which is more vegetarian and with high roughage content. By adulthood, one in six people will have undergone the removal of this appendix. Nowadays, the disease is increasing in the developing areas of the world, but decreasing in Western countries, probably due to changing food habits. The incidence of acute appendicitis in the population is most frequently seen from the second to fourth decades, with a mean age of 31.3 years and a median age of 22 years.

- Appendicectomy is one of the most common operations performed in general surgery.
- The lifetime rate of appendicectomy is 7% for the Population, it is 12% for men, and 25% for women.
- The rate of appendicectomy for appendicitis is 10 per 10,000 patients per year and is constant.
- The rate of misdiagnosis of appendicitis is 15.3%, higher in women (22.2%) than in men (9.3%).
- Negative appendicectomy rate for females, if fertile age is 23.1%, and is highest in females above 80 years.

Age

The maximum incidence occurs in the second and third decades, the mean age is 31.3 years.

Acute appendicitis is rare in infancy; it is uncommon before the age of 2 years, but no age is exempted from it. The incidence of acute appendicitis gradually decreases after middle age. *The peak incidence occurs between 20 and 30 years, and the median age is 22 years.* This is also the age of peak increase in size and number of lymphoid follicles. This indicates the relation between the incidence of acute appendicitis and amount and number of lymphoid follicles. The incidence of acute appendicitis becomes very low after 60 years of age, almost a rarity; 70% of appendicitis occurs <30 years of age.

The mortality rate of acute appendicitis is 0.8%; such patients are either very young or very old.

The incidence of acute appendicitis in males and females is age-related. Before puberty, it is equal among both sexes. In the second and third decades, the male and female ratio is 3:2. After the third decade, the incidence among males declines and becomes equal gradually. Acute appendicitis is more common in teenage girls. The highest incidence of appendicitis in males is at early years, whereas in females it is later years. The association between menstruation and appendicitis is frequently noted. Some researchers indicate that the probable explanation lies in the fact that the condition of the whole splanchnic area, which accompanies the lowered BP of the peripheral circulation during menstruation, creates a favorable soil for the activities of the microorganisms contained in the appendix *(Howard A Kelly)*.

Symptoms

Important symptoms of acute appendicitis **(Fig. 16):**

- Pain
- Nausea
- Vomiting
- Anorexia
- Fever
- Murphy's syndrome
- Constipation or diarrhea

JAYPEE BROTHERS

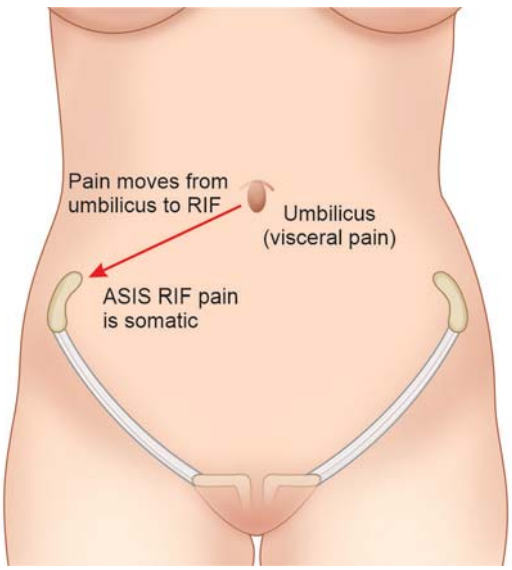

Fig. 16: Migratory pain in acute appendicitis.

Pain

Pain in acute appendicitis usually starts in the early morning. The patient sleeps well in night, and the pain wakes him up in the early morning. The pain in appendicitis is produced by distension of its lumen or spasm of the muscle due to stimulation of visceral nerve endings responsible for pain. First, the pain is felt at the umbilicus. It is referred to as pain, as both the umbilicus and the appendix receive their nerve supply from the thoracic tenth (T10) segment of the spinal cord. Appendix receives its sympathetic nerve supply from T10 via the celiac plexus and the umbilicus by somatic nerves via the vagus nerve. This is referred to as pain and is vague pain. The explanation of referred pain is that the nerve fibers from the diseased organ and the area where the referred pain is felt (here the umbilicus) ascend to the cerebral cortex and the cerebral cortex sometimes becomes incapable of differentiating between the causative site and referred site, which is why some patients complain of umbilical pain. This umbilical pain is seen in appendicitis irrespective of the position of the appendix. One can explain this visceral pain by midline radiation of delta nonmyelinated fibers that have very poor localization. The pain increases gradually as the inflammation increases. The pain later migrates to the RIF. This shift of pain is due to the involvement of the parietal peritoneum by inflammation over the appendix. As the inflammation increases, pain spreads. The visceral layer of the peritoneum is insensitive to pain, but the parietal peritoneum is sensitive to pain, which is why in the early stage of inflammation, when the parietal peritoneum is not involved, the pain is not felt in RIF and is only felt at the umbilicus. When the parietal peritoneum is involved, the pain is conveyed by alpha fibers at the RIF.

Initial pain is visceral pain, which is felt at the umbilicus, and later on, pain is somatic pain, which is in the RIF. It is called the "shifting pain" of acute appendicitis. The history of shifting pain from the umbilicus to RIF, if present, is a very important symptom to diagnose acute appendicitis. The visceral pain in acute appendicitis is dull, diffuse, and vague in the umbilical, paraumbilical, and lower epigastrium region. 25% of patients have no visceral pain and present with localized pain. Sudden movement or coughing increases the pain, and even walking increases the pain. The diminution of pain is not always good news. In acute appendicitis sudden disappearance of pain may be due to perforation of a gangrenous appendix or obstructive appendicitis. In pelvic appendicitis, the pain is aggravated when the right obturator internus muscle is stretched by flexion and medial rotation of the right thigh. It is due to the fact that the inflamed appendix is touching the obturator internus muscle. Pain severity and associated nausea and vomiting depend upon the degree of distension of the appendix.

In retrocecal appendicitis pain is aggravated or even caused when the psoas major muscle of right side is stretched by extension of right hip joint. This is not often seen in obese patients. The distension of lumen of appendix also stimulates the peristalsis in appendix which produces cramp-like pain as in acute gastroenteritis or in ureteric colic so the visceral pain may be cramp-like pain super imposed on dull pain.

Anorexia

It is a constant feature in every patient with acute appendicitis. It is more marked in infants and children than adults. It is difficult to find a case of acute appendicitis without anorexia. If anorexia is absent, the diagnosis of acute appendicitis is reconsidered. Hiccoughs are rare but are present in generalized peritonitis due to irritation of the peritoneal surface of the diaphragm.

Anorexia is a reliable and permanent feature of acute appendicitis, usually, it is the first sign. If anorexia is not present, then the diagnosis of acute appendicitis may be deferred.

Nausea

It is a common symptom in both types of obstructive and nonobstructive appendicitis. Nausea and vomiting occur in 70% patients of with appendicitis.

JAYPEE BROTHERS

Vomiting

It occurs due to reflex pylorospasm which is protective as the body does not want food to reach the site of inflammation, i.e., the appendix. It is more marked in obstructive appendicitis than nonobstructive appendicitis. It follows abdominal pain. It is more marked in children than adults. Vomiting is not persistent; it subsides when the stomach becomes empty. If vomiting precedes the pain, the diagnosis of acute appendicitis should be questioned.

Fever

It is due to bacterial infection and is of low grade (<100°F). Fever is the last symptom after pain and vomiting. So, it is not present in the initial sickness. In 20% of patients, there is no fever. A higher fever indicates that a complication has occurred or that another diagnosis should be considered. High and persistent temperature relates to the severity of infection and local or metastatic collection of pus.

Murphy's Syndrome

Pain first, followed by vomiting and then by fever, is called "Murphy's triad of acute appendicitis" or "Murphy's syndrome" after John Benjamin Murphy. He used to say that "If vomiting precedes the pain, probably you are not dealing with acute appendicitis." It is not a must to find Murphy's triad in every case of acute appendicitis.

Constipation or Diarrhea

Constipation is a common feature in acute appendicitis except in pre- and postileal appendicitis where diarrhea occurs due to irritation of the ileum. In pelvic appendicitis patient may have "tenesmus" (ineffectual straining at defecation with passage of mucus and blood only). Due to irritation of the rectum diarrhea occurs in 10% patients of with acute appendicitis, causing doubt about acute gastroenteritis and delay in diagnosis of acute appendicitis and appendicectomy.

Hematuria

It is not a common finding and when occurs it is due to irritation of the right ureter, especially in retrocecal appendicitis. Patients may feel strangury (painful and frequent attempts at micturition passing only a small quantity of urine) if the appendix is touching the urinary bladder or ureter in pelvic appendicitis or retrocecal appendicitis.

Examination

Examination of the patient of acute abdomen attracts attention of the posture of the patient—the dorsal decubitus with the right leg slightly flexed and avoiding any movement.

- *Inspection:* Abdomen appears normal or slightly distended. Respiratory movements of the abdominal wall are slow and mild.
- *Palpation:* Knees and thighs to be flexed and relaxed. Gradually speaking clearly ask the patient questions about features of the disease while your right hand is passed over the whole abdomen except RIF and slightly press here and there. This way gain the confidence of the patient and then fingertips press at McBurney's point, the patient may wince or cry with pain, feeling tenderness, rigidity, and muscle guarding.

Note: John Benjamin Murphy (1857–1916), Professor of Surgery, Northwestern University, Chicago II, USA. He described this syndrome in 1903.

- *Percussion:* It shows normal tympany but dullness if an appendicular mass or abscess is present.
- *Auscultation:* It shows a reduction or absence of bowel sounds if ileus is present. In the olden days an instrument called "piezometer" was used to measure the amount of pressure required to produce pain. It has become obsolete now.

Signs

Important signs of acute appendicitis:

- Cough sign (Dunphy's sign)
- Rovsing sign
- Hyperesthesia in Sherren's triangle
- Cope's psoas test
- Cope's obturator test
- Bed shaking test of Bapat
- Baldwin's test
- Tenderness on DRE
- Bastedo's sign
- Markle sign or jar tenderness

Pyrexia

Usually, the patient looks unwell with low-grade pyrexia. The temperature is not very high, but in children, the temperature may be high. It is between 90 and 100°F. The temperature may be normal in uncomplicated and early appendicitis. When generalized peritonitis occurs temperature goes up to 102–103°F. It must be remembered

JAYPEE BROTHERS

that pyrexia is not an early sign of acute appendicitis. In acute appendicitis, pyrexia comes after pain and vomiting, so it is the last sign of the three, i.e., pain, vomiting, and fever (Murphy's syndrome).

Tachycardia

It is a good diagnostic guide for acute appendicitis. Sometimes, when the pain is not severe and the patient cannot locate the abdominal pain properly, the pulse plays an important role in suspecting acute appendicitis. The pulse rate is usually slightly elevated between 80 and 90 beats/min. Temperature and pulse rate are usually not elevated in the first 4–6 hours, the pulse increases in proportion to the temperature rise. *Osborne Joby Dunphy (1898–1989), a British American physician, observed this sign for the first time.*

A high tachycardia or very rapid pulse is not a good sign, it may be a grave sign. Tachycardia out of proportion to fever is also a grave sign.

Coated and Dry Tongue

Rough, brownish-coated, and dry tongue-it indicates toxemia. Even in early acute appendicitis tongue may be thickly coated and dry, as the patient might have vomited several times and is dehydrated.

Limited Respiratory Movements

Movement of the abdominal wall during respiration may be limited in RIF in acute appendicitis due to localized irritation of the peritoneum from the inflammation. The vigorous respiratory movements will shake the inflamed parietal peritoneum and will cause pain, so the movement of the abdominal wall is limited. It is also a protective phenomenon.

Pointing Test

This test confirms RIF inflammatory pathology, the patient is asked to indicate the site of pain by the tip of a finger, and indicates toward RIF. If the pain is diffuse, then the patient will use his whole hand instead of one finger to point toward the site of pain.

Method of test:

- Ask the patient to lie down.
- Ask to indicate the site of maximum pain.

If it is also the point of maximum tenderness, this is the site of the inflamed organ.

Tenderness

In acute appendicitis, the RIF is tender. The maximum tenderness is elicited at McBurney's point. The tenderness can be best elicited in the left lateral position when coils of a small intestine shift to the left, exposing the appendix directly to palpation. The abdominal wall also becomes relaxed in this position. Tenderness persists even after cessation of pain till the inflammatory process is present.

Tenderness on pressing RIF is one of the most important signs of acute appendicitis. It is very significant that if it is absent surgeon is doubtful of the diagnosis of acute appendicitis.

In acute appendicitis, the site of muscle guarding varies according to the position of the appendix.

- In paracecal appendicitis, guarding is in RIF.
- In retrocecal appendicitis, it may be present over the flank and even on the back muscle and may be RIF totally free. In pelvic appendicitis, there may not be any rigidity in the anterior abdominal wall. In preileal and postileal appendicitis, guarding may be near the umbilicus.
- Muscle guarding is an indication of irritation of the parietal peritoneum. It is a protective mechanism for inflamed organs not to get hurt. It is important to differentiate the involuntary muscle rigidity of acute appendicitis from voluntary muscle guarding. Involuntary muscle rigidity indicates local parietal peritonitis due to an underlying inflamed appendix. Voluntary muscle guarding is brought by the patient himself due to fear of being hurt. In every case of acute appendicitis, there is some degree of voluntary muscle guarding. It is more so in children. To elicit muscle guarding, the patient's confidence must be gained by your polite manners and behavior.

Rebound Tenderness (Blumberg's Sign)

The RIF is palpated with flat of the right hand. With each expiration hand on the abdomen is gradually pressed down the abdomen. Then the hand is suddenly withdrawn completely, so the abdominal musculature springs back suddenly to its original position, and the patient will cry or will wince due to pain. This pain is due to the sudden movement of the inflamed parietal peritoneum.

Muscle Guarding

Spasm or rigidity is the involuntary tightening of the abdominal musculature that occurs in response to underlying inflammation. This stiffness can be felt when

JAYPEE BROTHERS

touched or pressed. Guarding in contrast is a voluntary contraction of the abdominal wall musculature to avoid pain.

Next to pain, rigidity is the most important and dependable sign of acute appendicitis. Richardson expressed about rigidity that "rigidity with distinctly localized pain strongly suggests appendicitis, with fever it almost proves it, and with tumor, it fully establishes the diagnosis."

Note: Jacob Moritz Blumberg (1873–1955), Surgeon and Gynecologist in Berlin and later in London reported this sign for the first time.

The patient opens the mouth and do deep breathing. This will make voluntary muscle guarding to disappear. The muscle guarding usually corresponds to the area of tenderness. It is directly proportional to the severity of inflammation. A patient will complain of pain or will wince with pain when asked to extend the right thigh as the inflamed retrocecal appendix remains in contact with psoas major muscle, which becomes contracted during flexion of hip joint. Tenderness, muscle guarding, rebound tenderness, and perforation usually develop after 24–36 hours of onset of symptoms.

Method of eliciting muscle guarding:

- Make the patient comfortably lie on a bed.
- Sit on right side of patient bed on a stool.
- Gently keep the flat of right hand on his abdomen on *left upper quadrant (LUQ)* abdomen, palpate it then move hand toward RIF you will feel firmness of muscles.

"The surgeon is constantly reminded that in practice, the classic presentation of acute appendicitis is not present in all patients. Because appendicitis is so common, a high index of suspicion for appendicitis is warranted in all patients with abdominal pain."

—Douglas S Smink and David (Maingot's Abdominal Operations)

Pain in Right Iliac Fossa on Coughing (Dunphy's Sign)*

***Ask the patient** to cough and he will indicate to RIF for pain. It is due to the movement of inflamed parietal peritoneum.* It differentiates acute appendicitis from right-side ureteric colic, where pressing the loin with the hand gives relief but not in appendicitis. This sign is named after Osborne Joby Dunphy (1898–1989, a British–American physician).

*Rovsing Sign***

The palpation of the left iliac fossa (LIF) produces pain in RIF. It is due to the displacement of colonic gases and small bowel coils, causing movement of the inflamed appendix. It is named after Niels Thorkild Rovsing, who observed and explained it initially.

Method of eliciting sign:

- Ask the patient to lie down comfortably on the bed.
- Sit on the right side of a bed on a stool.
- *Put the whole flat palm and finger of the right hand on LIF and gradually press. Slowly increase the pressure he will wince with pain, ask him where is the pain, and he will point toward RIF.*

Hyperesthesia in Sherren's Triangle

It is due to irritation of the lower abdominal nerves. The 'Sherren's triangle' is formed by the line joining ASIS, the umbilicus, and pubic symphysis. It can sometimes be the first sign of early appendicitis.

Cutaneous hyperesthesia is regarded as a symptom of great importance. Where cutaneous hyperesthesia, muscular rigidity, and localized or general pain are present, peritonitis always be found. It is sometimes exceedingly vivid, making further palpation impossible.

Method of eliciting sign:

- *This can be elicited by gently picking up a fold of skin and lifting it off the abdomen* or by gently scratching the abdominal wall by fingernails.
- If this hyperesthesia disappears during illness, it indicates the bursting of gangrenous appendix.

Cope's Psoas Test

It is seen in retrocecal appendicitis. The retrocecal appendicitis causes irritation of the psoas major muscle. The psoas major muscle causes flexion of the hip, so the attempts to extend the hip cause pain as it stretches the psoas muscle and moves the inflamed appendix lying over it. It is named after Sir Vincent Zachary Cope (1881–1975), a surgeon at St Mary's Hospital, London, England. He described "Acute Abdomen in Rhyme" as:

Distension, rigidity, vomiting, and pain are actors abdominal which often deign To act on behalf of the chest, spine, or brain, or general ills of which typhoid is the main.

RD Bapat, Professor Emeritus of the Seth GS Medical College and King Edward Memorial Hospital, Mumbai.

*Osborne Joby Dunphy (1898–1989), a British–American Physician, observed this sign for the first time.
**Niels Thorkild Rovsing (1862–1937), Professor of Surgery, Copenhagen, Denmark.

JAYPEE BROTHERS

Method of eliciting test:

- Ask the patient to lie down on the left side, right side up laterally.
- By left hand hold right ileum area.
- Ask to extend the thigh voluntary by a patient or do it yourself with your right hand. It will cause pain.

Cope's Obturator Test

It is seen in pelvic appendicitis, which causes irritation of the internal obturator muscle so flexion and medial rotation of thigh produces pain in hypogastrium due contraction of internal obturator muscle which moves the inflamed appendix.

Method of doing test:

- Ask the patient to lie down supine.
- Hold the knee by your left hand and foot by right hand. Flex the hip joint 90° and then move the foot away from the patient's body, it will rotate the thigh medially and will make the obturator internus muscle tense and the patient will wince with pain.

Bed Shaking Test of Bapat

The foot end of the bed is moved slightly, and this will evoke pain in RIF by shaking the inflamed appendix suddenly.

Baldwin's Test

In retrocecal and pelvic appendicitis, there may not be any tenderness or muscle rigidity at the McBurney's point.

Method of doing the test:

- Patient lies supine.
- The left hand is placed and pressed at the right flank of a patient. Now the patient is asked to raise the right lower limb off the bed, keeping the right knee extended. He will feel pain in the RIF. The tenderness and rigidity may not be present or may not be so prominent in RIF. History of diarrhea, fever, strangury, and tenesmus makes the clinical picture very confusing. Surgeons must give importance to history, which, with proper examination, will make up to reach a diagnosis of pelvic appendicitis. History of periumbilical pain, Rovsing sign, Cope's obturator test, and DRE will diagnose pelvic appendicitis. DRE is very helpful as tenderness on the right side of a rectouterine pouch in females and the rectovesical pouch in males is present in pelvic appendicitis. A tender boggy lump or a cystic swelling in DRE is diagnostic of appendicitis with pelvic abscess.

Tenderness on Digital Rectal Examination

No examination is complete in the acute abdomen without DRE. Tenderness in the right rectal wall is present in pelvic appendicitis. It is found in 25% of cases. It also excludes pelvic lesions in females. "If you do not put your finger in the rectum, you will put your foot." Rectal examination is of little value in establishing the diagnosis of acute appendicitis, but can be useful to determine the presence or absence of a mass.

Bastedo's Sign

Pain and tenderness elicited on RIF by pushing air through rectal tube. This test is not done now due to risk of perforation.

Markle Sign or Jar Tenderness

It is a sign of acute appendicitis. Pain in the RLQ of the abdomen is elicited by dropping from standing on toes to the heels with a jarring landing. It is found in patients with localized peritonitis due to acute appendicitis. It is named after George *Bushar Markle IV (1921–1999), who was an American surgeon. This article was published in the American Journal of Surgery in 1973.*

OTHER IMPORTANT POINTS IN CLINICAL FEATURES OF APPENDICITIS

Appendicular Dyspepsia

Appendicular dyspepsia is a common presentation of recurrent appendicitis. It is the gastric symptom that predominates in it. Dyspepsia resembles the symptoms of diseases of the stomach, duodenum, and gallbladder. Usually, the symptoms of milder appendicitis are anorexia, nausea, epigastric discomfort, flatulence, and dyspepsia. It does not improve with *antacid or H2 receptor antagonists or proton pump inhibitors (PPI).*

Cause of Appendicular Dyspepsia

The infected lymph from the appendix is drained to subpyloric lymph nodes which irritates the pylorus and causes symptoms of dyspepsia. Treatment is appendicectomy.

JAYPEE BROTHERS

CLINICAL FEATURES ACCORDING TO THE TYPE OF APPENDICITIS

Not to forget:
- Appendicitis is common in 20–30-year-olds of age.
- Gangrene and perforation of the appendix are common in obstructive appendicitis and rare in nonobstructive or catarrhal appendicitis.
- Pneumoperitoneum is uncommon in appendicular perforation, but common in duodenal perforation.
- Appendicitis in a child <2 years is uncommon, but if it happens, then perforation, peritonitis, and poor prognosis are common.
- Appendicitis is found in LIF in a case of situs inversus and mimics acute diverticulitis.
- The mortality rate in appendicitis is <1%.
- If a normal appendix is found on the operation is called "Lilly White Appendix." If the appendix is found directly on the introduction of the laparoscope in the abdomen, it is called "handshake appendix."

OBSTRUCTIVE APPENDICITIS

- The onset of symptoms is abrupt, and then symptoms progress fast.
- Pain is severe.
- Pain is of a colicky nature.
- Vomiting is common.
- Temperature may be normal.
- The patient immediately goes to bed as they cannot perform their usual day-to-day duty due to tiredness and pain.
- Tenderness is more.
- It is a more dangerous variety.
- The obstruction makes the appendix a closed loop, so the contents stagnate and the walls get infected fast, and it rapidly progresses to perforation and gangrene.
- It may mimic acute intestinal obstruction.

NONOBSTRUCTIVE APPENDICITIS

It is also called "acute catarrhal appendicitis."

- The onset and progress are slow and not so abrupt as in acute obstructive appendicitis.
- Pain is less and of a dull type or constant burning pain rather than colic.
- Vomiting is not much and may be absent.
- Fever is usually present, which may be normal in obstructive appendicitis.
- Patient carries out his usually day-to-day duties but with discomfort in the abdomen, nausea, vomiting, and anorexia. He is not very sick.
- Tenderness is not much.
- It is not so dangerous a variety as acute obstructive appendicitis.
- Usually does not lead to gangrene and perforation.
- Does not mimic acute intestinal obstruction.
- Inflammation spreads from the mucosa to the serosa slowly, and the appendix becomes congested.
- The inflammation ends in:
  - Resolution
  - Fibrosis
  - Suppurate
  - Gangrene
- Nonobstructive appendicitis can be acute, subacute, chronic, or recurrent.

CLINICAL FEATURES ACCORDING TO THE POSITION OF THE APPENDIX

Characteristic features in different anatomical positions of the appendix in acute appendicitis:
- Retrocecal appendicitis—silent
- Pelvic appendicitis—diarrhea
- Preileal and postileal—diarrhea
- Subhepatic—pain above RIF, as in cholecystitis, and RIF is pain-free.

RETROCECAL APPENDICITIS

This may be silent without any tenderness and rigidity in the RIF, which is why called a "silent appendix." It is due to a distended cecum with gas lying anterior to the appendix, so the pressure exerted cannot pass up to the appendix. In such cases, deep tenderness may be present in the loin, and muscles of the loin (i.e., quadratus lumborum) may be found in spasm. Here, the inflamed appendix lies over the psoas major muscle, so it may be in spasm, causing flexion of the hip joint, and the extension of the hip joint causes pain. If the irritation of the psoas major muscle is not much, then instead of extension, hyperextension of the hip may cause pain, as extension may not cause sufficient stretching of the psoas muscle.

In retrocecal appendicitis, if the appendix is totally and completely retroperitoneal, then there is no rigidity and tenderness in the anterior abdominal wall. There may be tenderness and rigidity in the right flank and more posteriorly. To elicit such tenderness patient has to be rolled to the left side. If the appendix is in direct contact with the right ureter, a patient may feel pain radiating from the loin to the groin and may have hematuria.

JAYPEE BROTHERS

This may confuse the surgeon with ureteric colic, but an initial history of pain around the umbilicus, Rovsing sign, psoas test, and examination in the left lateral position will diagnose the appendicitis. One has to be very careful in history taking and examination to not to miss appendicitis.

Pouch of Douglas is named after James Douglas (1675–1742), an anatomist and male midwife who practiced in London, England.

PELVIC APPENDICITIS

It can produce diarrhea instead of constipation if the inflamed appendix is in contact with the rectum. If the inflamed appendix is in contact with the urinary bladder, then it may cause frequency of micturition, leading to the doubt of urinary tract infection.

Per-rectal examination in males and bimanual examination in females by putting one hand over the lower abdomen and a finger in the vagina is necessary to not to miss pelvic appendicitis.

Tenderness and abdominal muscle rigidity may be altogether absent, and DRE may reveal tenderness in a pouch of Douglas (Rectovesical pouch). The inflamed pelvic appendix may touch the psoas muscle or internal obturator muscle and cause spasms of these muscles, causing flexion of the hip joint or flexion and internal rotation of the thigh.

- *Postileal and preileal appendicitis:* It causes diarrhea, and one may miss appendicitis and be diagnosed as acute gastroenteritis. So, it is called a "missed appendix." Tenderness may be present just on the right side of the umbilicus.
- *Subhepatic appendicitis:* The pain is present above the RIF. It may mimic acute cholecystitis.

INVESTIGATIONS FOR APPENDICITIS

The acute appendicitis is diagnosed clinically only, but investigations are done to avoid the removal of a normal appendix. Approximately 20% of appendices removed on appendicectomy are found normal on histopathological examination. The most important criteria in the diagnosis of acute appendicitis are given here.

Important preoperative investigations in acute appendicitis:
- Complete blood count
- Urine analysis
- Pregnancy test
- Urea, creatinine, and electrolytes
- C-reactive protein
- Radiography
- Barium meal or enema
- Ultrasound
- Contrast-enhanced computerized tomography (CECT) scan of the abdomen
- Diagnostic laparoscopy
- Alvarado scoring system
- Nigam's Scoring System (NSS)

COMPLETE BLOOD COUNT

More than 90% of patients suffering from acute appendicitis have some leukocytosis. The total leukocyte count (TLC) is usually above 10,000/mm^3 (12,000–18,000/mm^3). There is a shift toward the left means polymorph nuclear cells predominance. In perforated appendicitis, the count may be >18,000 mm^3. Serial WBC measurement improves diagnostic accuracy, with a rising value over time commonly seen in patients with appendicitis.

As a matter of fact, the total number of leukocytes is subject to fairly wide variations even under normal conditions, so the conclusion drawn from an absolute count alone may prove entirely erroneous. While on the one hand in the majority of individuals, an absolute count from 5,000 to 7,500 is the rule, on the other hand in a lower state of nutrition than an average, lower values are also normally present (3,000–5,000), while higher figures (up to 10,000) may be found in unusually vigorous and well-nourished persons. It, thus, becomes clear that an absolute count of 8,000–10,000 in a poorly developed and ill-nourished individual might really indicate a decided hyperleukocytosis. reliance upon the absolute count alone may here give rise to disastrous consequences.

High value, it is true, indicates in a general way that the disease is active, and increasing values—where repeated examinations are made—that the decrease is progressive. Low count or falling values, on the other hand, may indicate either that the disease is abating, or that the infection is unusually severe, or that the perforation with general peritonitis has developed. In these cases, again, the differential leukocyte count will tell the true story. Eosinophil count is a "septic factor" in infective states, such as appendicitis.

URINE EXAMINATION

Dehydration is caused due to repeated vomiting. So, the urine shows high specific gravity. Urine may also show RBCs and WBCs if the appendix touches the urinary bladder or ureter in pelvic or retrocecal appendicitis. If urine shows >20 WBC per high power field or shows >30 WBC per high power field, it indicates urinary tract infection (UTI).

JAYPEE BROTHERS

Bacteriuria in a catheterized patient is not generally seen with acute appendicitis. Failure to find blood or pus cells in the urine is not a certainty of exclusion of right renal or ureteric problem but the diagnosis of a renal problem is less likely, especially in the presence of peritoneal signs.

PREGNANCY TEST

The negative pregnancy test will rule out RIF pain due to ectopic gestation.

BLOOD UREA, CREATININE, AND ELECTROLYTES (SODIUM, POTASSIUM, AND CALCIUM)

Vomiting can cause raised blood urea and abnormal serum electrolytes. The estimation of urea, creatinine, and electrolytes also helps to assess the renal function of the patient, which also helps the anesthetist with anesthesia for the operation.

C-REACTIVE PROTEIN

C-reactive protein (CRP) estimation is found helpful in the diagnosis of acute appendicitis, CRP is produced by the liver when infection occurs in any part of the body, it increases rapidly within the first 12 hours and then within the next 12 hours comes to a normal level.

C-reactive protein levels above 1 mg/dL are found in acute appendicitis, and very high level of CRP with leukocytosis indicates advanced or gangrenous appendicitis. The high level of CRP in blood shows inflammation. The CRP value comes to normal once the infection is controlled. It is not very useful. Clinically as it is nonspecific and cannot distinguish between sites of infection.

RADIOGRAPHY

X-ray neither confirms acute appendicitis nor excludes it. It can be of benefit to exclude other pathologies, such as calculus in the ureter. There is no classical sign of acute appendicitis on plain X-ray. Plain X-ray of the abdomen is not a very important investigation in acute appendicitis, except in perforation of the appendix. Avoid doing radiographs if a patient is pregnant. Acute appendicitis is quite common in young females, so keep in mind the pregnancy when X-ray is advised.

The following findings may help to support the diagnosis of acute appendicitis in association with clinical signs:

- *Sentinel loops of bowel:* These are seen as gas shadows due to localized ileus due to inflammation.
- *Calcified fecaliths:* Approximately 15% of cases of acute appendicitis show calcified fecaliths on X-ray. A fecalith shows a laminated shadow. The presence of fecaliths in X-ray in RIF pain is suggestive of appendicitis.
- *Mass effect around the appendix:* The bowel loops are displaced away from an appendicular lump.
- The presence of free gas under the diaphragm is a sure sign of perforation of the appendix, but it is not always seen, so the absence of this sign does not rule out the diagnosis of appendicitis or perforation of the appendix.
- Scoliosis of the spine with concavity toward the right side due to spasm of the psoas muscle due to irritation by an inflamed appendix is rarely seen on X-ray.
- The psoas muscle margin of the right side is lost due to the superimposed inflamed appendix.
- Retained barium from previous studies is to be noted. It is noted that inspissated barium from earlier barium enema or meal can rarely cause acute obstructive appendicitis.
- Blurring of preperitoneal fat on the flank is also an important sign on plain X-ray of abdomen. Gas in the appendix is not a sign specific for appendicitis and should not mandate laparotomy for appendicitis.

ULTRASOUND OF ABDOMEN

Ultrasound cannot visualize a healthy normal appendix. It may not be very helpful in early acute appendicitis. It is more useful in excluding gynecological causes of RIF pain. Ultrasound is highly operator-dependent which is the main limitation of ultrasound in the diagnosis of acute appendicitis, frequently unable to visualize the normal appendix.

A blind-ended tubular structure, easily compared possible and <6 mm in diameter is the feature of a normal appendix and if it is found then appendicitis is excluded from the diagnosis.

Ultrasound findings in acute appendicitis are:

- Probe tenderness at McBurney's point.

JAYPEE BROTHERS

- A blind-ending, tubular structure with a thick wall, without peristalsis and noncompressible originating from the cecum, is detected in RIF. It is seen, especially when the lumen is >6 mm in diameter.
- Appendicolith may be present.
- Intussusception
- Periappendicular fluid collection.

If an ultrasound of the abdomen shows an abscess cavity in an appendicular mass, then drain the abscess.

Nowadays with better ultrasound machines and advanced probes, the full fledged acute appendicitis can be diagnosed in >90% of cases. In most of hospitals, now ultrasound is used as a routine investigation of RIF pain. It is helpful in diagnosing appendicular lumps and abscess.

Ultrasound can diagnose approximately 86% of appendicitis cases. However, the ultrasound is usually not used as a tool to diagnose acute appendicitis than to rule out other causes of such pain or when the diagnosis is uncertain or in females of childbearing age. Tzanakis et al. proposed the use of ultrasound as it is more readily available than a CT scan.

Graded Compression Sonography

It is recommended as an accurate way to establish the diagnosis of appendicitis. The diameter of the appendix is measured in anteroposterior dimension with maximal compression. The presence of appendicolith establishes the diagnosis. Thickening of the appendicular wall and periappendicular fluid are highly suggestive signs on ultrasound. The sonographic diagnosis of acute appendicitis has a specificity of 85–98%.

Normal appendix demonstration on sonography is as easily compressible as a blind-ending tubular structure 6 mm or less in diameter, which excludes the diagnosis of acute appendicitis. Transvaginal ultrasound alone or a combination of transabdominal scans is a must in a female of reproductive age with RIF pain to diagnose acute appendicitis. It reveals pelvic pathology and fluid in a pouch of Douglas.

Advantages of Graded Compression Ultrasonography

- Reduced negative appendicectomies from 37 to 13%.
- Reduces preoperative time.
- Improves the diagnosis of acute appendicitis diagnosed on physical examination.

COMPUTED TOMOGRAPHY SCAN OF ABDOMEN

It is not used as a routine investigation. Selective use of CT is required as a standard approach. CT scans used in acute appendicitis can be focused and nonfocused or enhanced and nonenhanced. CECT of the abdomen is a better option than NCCT (noncontrast CT).

Computed tomography scans with oral contrast medium or rectal Gastrografin enema may help in the diagnosis of appendicitis.

- When patient scores 6 or <6 in Alvarado Scoring System.
- *Particularly useful in elderly patients as it rules out intestinal obstruction, neoplasm, and diverticulitis, and diagnoses acute appendicitis in the absence of signs.*

Contrast-enhanced computed tomography reduces the chances of removal of a normal appendix.

Computed tomography scans can diagnose acute appendicitis in approximately 98% of cases, i.e., 92–97% sensitivity, 85–94% specificity, 90–98% accuracy, and 75–95% positive and 95–99% negative predictive values. A CT scan is good for patients who come late, after 48 hours, with appendicitis as a mass or abscess.

Indications of Computed Tomography Scan in Acute Appendicitis

- *Suspected case of acute appendicitis where the diagnosis is not confirmed by ultrasound and other investigations.*
- Appendicular abscess
- Pelvic abscess

Disadvantages of Computed Tomography Scan

- Expensive
- Radiation
- Cannot be used during pregnancy.
- Some patients may develop an allergy to the dye used in CECT.
- Some patients cannot take oral dye due to nausea and vomiting.
- Optimal CT technique requires complete small bowel opacification (CECT).

Advantages of Computed Tomography Scan

- A study by Rao and colleagues showed that CT scans have reduced the incidence of negative appendectomies from 20 to 7%, it is confirmed by others too.

JAYPEE BROTHERS

- Decreased perforation rate from 22 to 14%.
- Established an alternative diagnosis in 50% of cases
- Saved unnecessary appendicectomies
- Saved inpatient hospital stay days
- Lowered per-patient costs by $ 447.

Improved image resolution to a 0.5–1.0 cm range which has improved the accuracy of CT scanning.

DIAGNOSTIC LAPAROSCOPY

Diagnostic laparoscopy is particularly helpful in obese patients and females of childbearing age to exclude acute gynecological pathology. It can help in 30–40% of negative appendicectomies, some surgeons routinely do diagnostic laparoscopy in all ovulating women with suspected acute appendicitis to avoid delay and negative appendicectomies.

It is useful in the following cases: Infants, elderly, and female patients.

SCORING SYSTEMS

Alvarado (MANTRELS) Scoring System

It is a system developed to diagnose acute appendicitis more precisely to avoid negative appendicectomies **(Table 2)**.

Alfredo Alvarado, Contemporary Surgeon, Plantation, FL, USA, gave this scoring system, which is most widely used globally. A score of 7 or more is strongly indicative of acute appendicitis. Score <5: Not sure of diagnosis of acute appendicitis, *score 5–6:* Compatible with acute appendicitis, *score 7–9:* Probably acute appendicitis, *score 10:* Confirmed acute appendicitis, if score is 7 or more, admit the patient for urgent appendicectomy, if score is 5–6, further investigations are required to reach to a diagnosis. Any patient with a score of <6 cannot have a perforated appendix.

TABLE 2: Alvarado (MANTRELS) scoring system.

Features	*Score*	
Symptoms	*M*igrating RIF pain	1
*A*norexia	1	
*N*ausea, vomiting	1	
Signs	*T*enderness RIF	2
*R*ebound tenderness	1	
*E*levated temperature	1	
Laboratory	*L*eukocytosis (>10 ×1,000 cells/mm^3)	2
Shift to the left (segmental neutrophils) (>75%)	1	
Total	10	

Raja Isteri Pengiran Anak Saleha Appendicitis Scoring System

It is similar to the Alvarado scoring system. It typically provides a quantitative value for a clinician's clinical score for appendicitis.

Nigam's Scoring System

It is invented to deal with the drawbacks of the Alvarado scoring system and improve accuracy. Nigam's scoring system (NSS) has 17 scoring points. This scoring system can be divided into three parts, 6 and below 6, 7–10, and 11 and above. If NSS comes to 6 or below, probably we are not dealing with acute appendicitis. If the score is between 7 and 10 probably diagnosis of appendicitis cannot be ruled out. If the score is 11 or more, we are dealing with a case of appendicitis. The higher the score after 11, severe is the inflammation, from acute appendicitis to impending perforation or gangrene. The scoring by NSS decides about the management of the case also. Patients with scores <6 are advised outpatient department (OPD) treatment. Patients with scores 7–10 are admitted to the hospital for observation and scores 11 or above are operated. The diagnosis of acute appendicitis by NSS was compared with the ultrasonography findings, operation findings, and histopathological results.

We have to confirm the diagnosis of acute appendicitis before doing an appendectomy otherwise there is a chance of a negative appendectomy. NSS confirmed the diagnosis of acute appendicitis in all cases before appendectomy. The diagnosis was based on NSS which was compatible to the operative and histopathological findings in all cases. There was not a single case of negative appendectomy among 34 operated cases. The negative appendectomy rate was zero. Out of 34 patients diagnosed as appendicitis by NSS all patients underwent appendectomy, and appendicitis was confirmed in all cases by operative and histopathological findings. Four patients had perforation and these all patients had leukocytosis above 15,000 and tenderness in RIF was severe. Nigam's scoring system has better accuracy than Alvarado's scoring system

JAYPEE BROTHERS

in diagnosing acute appendicitis [*Source*: Nigam VK, Nigam S. Nigam's scoring system for acute appendicitis with high accuracy surpassing Alvarado scoring system. Int Surg J. 2022;9(4):835-40]. NSS is an easy, economical, simple, accurate, fast, and dependable scoring system. NSS is best suited for small hospitals that lack advanced investigative techniques such as ultrasound, CT scan, and magnetic resonance imaging (MRI).

NUCLEAR MEDICINE INVESTIGATIONS

Two types of nuclear imaging are done for appendicitis diagnosis:

1. Radiolabeled WBCs (Tc-99m WBC)
2. Immunoglobulin G (Tc-99m Igl)

The localization of Tc-99 labeled WBCs, and Igl is done with the use of scintigraphy. Their value lies only in cases with negative ultrasound and CT scans.

These are highly sensitive and highly specific, but the procedure is time-consuming and not widely available, and not useful in emergency conditions.

VAGINAL EXAMINATION

Look for tenderness in the movement of the cervix if present then appendicitis is less likely, young women about the age of 20 years have the highest incidence of a normal appendix on operation and persistence of symptoms thereafter.

URINARY 5-HYDROXYINDOLEACETIC ACID

Few studies have shown the estimation of *urinary 5-hydroxyindoleacetic acid (U5-HIAA)* can be of help in the diagnosis of acute appendicitis due to the presence of a large amount of serotonin-secreting cells in an appendix. The level of U5-HIAA increases with the development of acute appendicitis and reduces with the development of gangrene or necrosis.

DIAGNOSIS OF ACUTE APPENDICITIS

One has to diagnose acute appendicitis in case of acute abdomen by excluding other causes.

Common causes of RIF pain:
- Acute gastroenteritis
- Mesenteric lymphadenitis
- Right ureteric colic
- Ruptured ovarian follicle (Mittelschmerz)
- Acute salpingitis
- Ruptured ectopic pregnancy
- Torsion of an ovarian cyst
- Meckel's diverticulitis
- Regional ileitis (Crohn's disease)
- Acute pyelonephritis
- Perforated duodenal ulcer (DU)
- Acute cholecystitis
- Acute pancreatitis
- Acute intestinal obstruction

PROBLEMS OF ACUTE APPENDICITIS AT DIFFERENT AGES AND STAGES

In Infancy and Childhood

Acute appendicitis is usually underdiagnosed. Tere are some special problems with younger age.

- *Appendicitis is seen in neonates associated with aganglionosis and neonatal necrotizing enterocolitis.*
- Infants and children are more sensitive to examination, so it is not easy to do a proper examination. Children <5 years of age have a negative appendicectomy rate of 25% and a perforation rate of 45%, whereas children >5 years of age have rates of negative appendectomy and perforation of 10 and 20%, respectively.
- *Most infants and children are uncooperative due to apprehension.*
- Infants, especially, cannot complain correctly.
- *The clinician has to win the confidence of the infant and child before proceeding for the examination.*

Differences between the appendix of the child and adult:
- Size of the appendix.
- Thickness of appendicular walls.
- Cecoappendicular junction Appendix in children is larger than in adults as compared to the size of the body and the gastrointestinal tract (GIT). The coats of the walls of the appendix are more delicate than in adults. Cecoappendicular junction is often funnel-shaped when the cecum and appendix are in the same line. Valves at the cecal junction of the appendix do not close as in adults; this makes fecal contents easier to enter into the lumen of the appendix and renders its expulsion also easy.

- The omentum is not well developed in infants and children. Omentum is like a "Bib" in children but an "Apron" in adults. So appendicular lump does not develop and perforation occurs earlier.
- Eliciting tenderness in infants and children is not an easy task, and you cannot do without it also. So, palpate the abdomen of a child with your own hand. The child will try not to touch the tender area, or he will pull his hand.
- Constitutional disturbances are more common in children.

JAYPEE BROTHERS

- Temperature and pulse are high.
- Tere is a complete dislike for the food.
- There is diarrhea and vomiting instead of constipation, so it mimics acute gastroenteritis, and this is the main confusing factor in the diagnosis of acute appendicitis at this age.
- "Hunger Sign" if the child is being hungry, then for sure he is not suffering from acute appendicitis (AA).
- In the early stage, the bowel sounds may be absent.
- Appendicular lump is rarely seen due to short omentum and poor inflammatory response.
- Early perforation is quite common in children, so diagnosis at a very early stage is essential to avoid perforation. Diagnosis is often delayed in children and infants.
- Vomiting is a common feature of appendicitis in children. It is rare to find acute appendicitis in children without vomiting.
- Approximately, there are 80% chances of perforation with 50% mortality in infancy when acute appendicitis develops.
- The child should be asked to stand on their right leg and hip. If he can probably, he does not have acute appendicitis.

Perforation of the appendix occurs so frequently in children that one has to follow the rule that "Every child having RIF pain with diarrhea and vomiting should be suspected as suffering with acute appendicitis unless proven otherwise."

In children, worms such as pinworms and roundworms have been considered one of the etiological factors. Sometimes deworming relieves from mild appendicitis symptoms.

The mortality in infants and children due to acute appendicitis is higher than in adults. It is due to:

- The omentum is underdeveloped, so it cannot reach RIF and so cannot seal and limit or wall off the infection.
  - Difficulty in diagnosis due to its resemblance to enteritis.
  - Diagnostic laparoscopy is of great help for children as laparoscopy is an effective form of treatment in children.

Trauma

Blows, falls, and exertions in children occur due to running and playing and can also be considered as one of the etiological factors of appendicitis. Rectal examination in children must not be omitted. The adult finger is longer for a child's rectum, and this can reach high in the pelvis, avoiding not finding pelvic appendicitis.

Acute Appendicitis in Old Age

There are some special situations in old age due to acute appendicitis in old age has become a serious problem.

- A total of 5–10% of cases of acute appendicitis occur in old age, lower than in younger patients, but the morbidity and mortality are higher due to more rapid progression to perforation. In patients older than 80 years of age, perforation rates of 49% and mortality rates of 21% have been reported, and some workers have reported perforation as high as 50%.
- The clinical signs are not well marked at this age.
- The abdomen is lax due to muscle wasting or weakness, so the muscle guard or rigidity is not prominent.
- Tere is atherosclerosis in an appendicular artery at this age and is responsible for the rapid development of gangrene and perforation.
- The distension of the abdomen, lack of rigidity, vomiting, and constipation make the picture mimic acute intestinal obstruction. Sometimes this may lead to the introduction of an enema, which can perforate the appendix in acute appendicitis.
- Recently, it has been observed that the incidence of acute appendicitis is decreasing in young adults and increasing in older age in spite of recent advances in imaging and laparoscopy.
- Mortality rate in old age >65 years of age is 4.6%.
- Gangrene and perforation occur more frequently in old age due to poor vascularity.
- *Mortality is high due to:*
  - Early gangrene and perforation.
  - Delayed diagnosis
  - Associated old age medical diseases

Acute Appendicitis in Pregnancy

- Acute appendicitis is the most common extra-uterine disease requiring operation during pregnancy; the incidence is one in 2,000 pregnancies.
- Acute appendicitis occurs most commonly in the first and second trimesters.
- In normal pregnancy, TLC may be between 15,000 and 20,000, and in acute appendicitis, it can go higher; in 10% of cases, it may be normal.
- There is a chance of abortion if appendicectomy is done, but one has to weigh the risk.
- Mortality increases considerably by appendicectomy in the third trimester.
- In the first trimester, the nausea and vomiting of appendicitis is taken wrongly as morning sickness,

JAYPEE BROTHERS

which delays the diagnosis and treatment, but nausea and vomiting after the first trimester must raise doubt of acute appendicitis.
- Rebound tenderness and muscle guarding are less marked due to a lax abdomen.
- Marked leukocytosis and ultrasonography may help to reach the diagnosis.
- Mortality in both mother and fetus increases with trimester and delay in diagnosis. In third-trimester fetuses, the mortality rate is 20%, whereas the maternal mortality rate is 9%. RB Parker was of the view that after 6 months, the mortality is 20%—10 times greater than in the first 3 months.
- Laparoscopic surgery becomes technically difficult after 26 weeks of pregnancy.
- Appendicectomy is the treatment of choice in all trimesters of pregnancy as soon as it is diagnosed.
- The enlarged uterus causes upward displacement of the cecum and appendix during the second and third trimesters of pregnancy, which may cause confusion in diagnosing appendicitis with acute cholecystitis.
- Visceral and parietal peritoneum are separated due to an enlarged uterus, so the somatic component of pain decreases.
- Sometimes necrobiosis of uterine fibroids or concealed accidental hemorrhage may cause similar pain as that of acute appendicitis.
- Careful history and positive Rovsing sign help to diagnose acute appendicitis.
- Put the patient in a supine position and mark the most tender spot with a marker, and then put the patient in the left lateral position. In acute appendicitis, the maximum tender spot will not shift, but in a uterine pathology, it will shift.
- Pyelitis, pyelonephritis, and cystitis are common during pregnancy. Pyelitis or pyelonephritis may mimic acute appendicitis. So, one should keep in mind these conditions during pregnancy.
- Appendicectomy during pregnancy carries a 10–15% risk of premature labor, and it increases to 30% in the presence of perforation.
- Intrauterine fetal death occurs in 3–5% of cases of acute appendicitis and 35% in perforation of the gangrenous appendix.
- Acute appendicitis is evenly distributed among all trimesters, but the maximum incidence of perforation occurs during the third trimester.

Appendicitis in Young Females

A lot of gynecological problems mimic acute appendicitis, so every young female going for appendicectomy must undergo gynecological examination by a gynecologist and lower abdominal, pelvic, and endovaginal ultrasound to avoid negative appendicectomies.

STUMP APPENDICITIS

It is defined as "appendicitis in the remaining appendicular stump after appendectomy." Surgeons must also remember that a previous appendectomy does not definitely exclude the diagnosis of appendicitis, as 'stump appendicitis,' although rare but has been described. RLQ tenderness is always present.

DIFFERENTIAL DIAGNOSIS OF ACUTE APPENDICITIS

Different diagnosis is a process of differentiating between the conditions that show similar signs and symptoms, so mimic the real disease. The process is based on symptoms, science, laboratory results, history, and physical examination. The aim of *differential diagnosis (DDX)* is to arrive at the correct diagnosis by excluding other provisional diagnoses. Similarly, acute appendicitis is diagnosed in a suspected case.

Meckel's Diverticulitis

- Johann Friedrich Meckel* described the diverticulum in 1809.
- Clinically it cannot be differentiated from acute appendicitis.
- Sometimes pain in Meckel's diverticulitis is more central or to the left than in acute appendicitis.
- *Tere may be intermittent lower gastrointestinal bleeding.*

Johann Friedrich Meckel (1781–1833), Professor of Anatomy and Surgery, Halle, Germany* **(Fig. 17).

Rule of 2 of Meckel's diverticulum
Meckel's diverticulum occurs in 2% children at the age of 2 years, it usually measures 2 inches in size, it arises at about 2 feet distance from ileocecal junction, can have two types of tissues, i.e., gastric and pancreatic, and it has a gender ratio of 1:2 in females and males.

JAYPEE BROTHERS

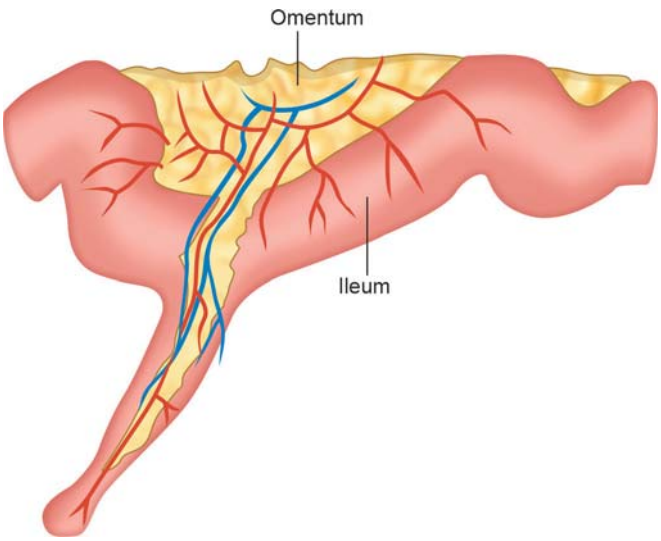

Fig. 17: Meckel's diverticulitis.

IN CHILDREN

Acute Mesenteric Lymphadenitis

- It is the most commonly confused disease with acute appendicitis in children.
- Recent history of upper respiratory tract infection is present.
- The pain is colicky in nature, and lasts for a few minutes.
- Vomiting is less marked than in acute appendicitis.
- Cervical lymph nodes may be enlarged.
- Shifting tenderness may be present if the child is placed in a left lateral position.
- True muscle rigidity is rare.
- Relative lymphocytosis may be present.
- It is a self-limiting disease.
- If the diagnosis is in doubt, then urgent exploration is the safest action.

Acute Gastroenteritis

- It usually presents as intestinal colic with vomiting and diarrhea.
- Tenderness is less localized and even may be no tenderness at all.
- Other members of the family are also affected at the same time.
- Laboratory values may be normal.
- In viral gastroenteritis stool is watery and profuse.
- In typhoid fever diagnosis is made by prostration, maculopapular rash, leukopenia, and culture of *Salmonella typhi* from stool and blood, 1% of patients develop terminal ileum perforation requiring urgent surgical interference.

Intussusception

Intussusception is most common at the age of 18 months, whereas acute appendicitis is rare before the age of 2 years.

A sausage-shaped lump is palpable in the lower abdomen, usually in the right side, and the RLQ feels empty.

- It occurs in well-nourished children.
- Colicky pain occurs, and the child doubles up, but in between colics, the child appears well.
- After several hours of pain, stool mixed with mucus and blood is passed.

If the intussusceptions is large as the bowel enters the distal bowel, it can be seen or felt at the anus. Rectal examination may find a polyp-like mass in the rectum. So, the rectal examination in acute abdomen in children must not be omitted. In intussusceptions, the invagination may be partial or complete or the appendix with cecum can invaginate into the colon.

Henoch–Schönlein Purpura

- Henoch described this form of purpura in 1886. Johann Lukas Schönlein described this form of purpura in 1837.
- Preceded by sore throat or respiratory infection.
- Abdominal pain can be very severe.
- Ecchymotic rash on external surfaces of limbs and buttocks.
- Microscopic hematuria is common.
- Platelet count and bleeding time are normal.
- Joint pain and nephritis may be present.

Lobar Pneumonia

- Pain of pleurisy and lobar pneumonia at the right base may mimic acute appendicitis pain.
- There is minimal or absent abdominal tenderness and muscle guarding.
- Pleural friction—rub or altered breath sounds are present.
- Tere is marked pyrexia.
- X-ray of the chest is diagnostic.

*Eduard Heinrich Henoch (1820–1910), Professor of Diseases of Children, Berlin, Germany.
**Johann Lucas Schönlein (1793–1864), Physician, Charity Hospital, Berlin, Germany.

JAYPEE BROTHERS

IN ADULT MALE

Ureteric Colic

- If a stone is lodged in the ureter near the site of the appendix it mimics acute appendicitis.
- Pain radiates from the loin to the groin.
- Cough test is negative but positive in acute appendicitis.
- Urine examination will reveal red blood cells (RBCs).
- Ultrasound, CT scan, and intravenous urography (IVU) are diagnostic.

Regional Enteritis (Regional Ileitis or Crohn's Disease)

- History of abdominal cramps, diarrhea, and weight loss.
- Doughy, vague, tender lump in RIF with fever, RLQ pain, and leukocytosis is present.
- The mesenteric lymph node may be palpable.
- Small bowel enema will show the "string sign of Kantor."
- Pain is very severe, much more than what happens in acute appendicitis.

Torsion of Testis

- Torsion of the undescended testis causes similar pain, but the scrotum is found empty.
- Usually occurs in a young adult male.
- Scrotal examination is diagnostic.
- Color Doppler or an ultrasound of the scrotum will confirm the diagnosis.

Acute Pancreatitis

- Epigastric pain that radiates to the back by penetrating directly to the back.
- Referred pain of acute appendicitis in the epigastrium is of much less severity.
- A high level of serum amylase, >1,000 IU, is diagnostic of acute pancreatitis.
- History of alcohol intake or gallbladder disease is present.

Rectus Sheath Hematoma

- It is due to rupture of the inferior epigastric artery, usually after a violent attack of cough or strenuous exercise.
- It is a rare entity.
- Acute pain and tenderness in RIF after an episode of strenuous physical exercise.
- Localized pain without gastrointestinal upset is the rule.
- Elderly patients on anticoagulant therapy may get it after minor and trivial trauma.

Right-sided Acute Pyelonephritis

- There is an increased frequency of micturition
- The tenderness in the loin is accompanied by fever, rigors, bacteriuria, and pyuria.

It is difficult to differentiate between acute pyelonephritis and acute appendicitis during pregnancy as the appendix is lifted up by the uterus and comes at the level of the kidney.

Amebic Typhlitis

- It is characterized by diarrhea and blood-mixed mucus.
- There is tenderness at the "Manson–Bahr amebic point" in LIF, Sir Philip Manson Bahr gave this point corresponding to McBurney's point in LIF. In amebiasis, there are two tender spots, one over the cecum at McBurney's point in RIF and the other over the sigmoid colon over Manson Bahr* point in LIF.

Valentino Appendix

It is also called Valentino syndrome or Valentino appendicitis. In a perforated duodenal ulcer, the contents and bile from the ulcer hole pass down through the right paracolic gutter in RIF, causing local peritonitis and hyperemia of the appendix, resembling appendicitis. Clinical features resemble acute appendicitis, as happened in this case. It is named after a famous film director, Rudolph Valentino, who suffered like this. In 1926, Valentino collapsed in a New York City hotel and underwent surgery for presumed appendicitis at New York Polytechnic Hospital. At the time, he was found to have a perforated ulcer. Postoperatively, he developed peritonitis, multiple organ system dysfunctions, and died several days later (Valentino loses battle with death: Greatest of screen lovers fought valiantly for life.

Yersinia Ileitis (Pseudoappendicitis)

- About 6% of cases of acute mesenteric lymphadenitis and 5% of cases of acute appendicitis are caused by *Yersinia* infection.

*Sir Philip Henry Manson-Bahr (1881-1966), English Zoologist and Physician.

JAYPEE BROTHERS

- It is a condition that mimics acute appendicitis. It is caused by the *Yersinia pseudotuberculosis* organism. The terminal ileum looks red, edematous, and inflamed.
- It subsides by itself.
- It does not require any treatment.

IN ADULT FEMALE

Inflammatory diseases of the right uterine adnexa more frequently mimic appendicitis than other parts. Some genital tract ailments in a female of childbearing age mimic acute appendicitis. A careful history of menstrual cycle, vaginal discharge, and pregnancy may help to reach to diagnosis.

After the expulsion of the fetus uterus suddenly contracts, and it can cause the rupture of appendicular or periappendicular abscess, leading to a grave situation.

Mittelschmerz

The typical midcycle lower abdominal or pelvic pain is indicative of Mittelschmerz. It is the rupture of a midcycle follicular cyst with bleeding. Mittelschmerz's name is given to this condition as pain occurs at the midpoint of the menstrual cycle.

- Usually, no GIT symptoms.
- Patient is not looking sick or toxic.
- Pregnancy test is negative.
- Usually not many signs are present.
- Leukocytosis and fever are absent or minimal.
- Diagnostic laparoscopy may be required.

Pelvic Inflammatory Disease

It is a common condition and includes the following conditions:

- Salpingitis
- Endometriosis
- Tubo-ovarian sepsis
- Every young female should be suspected of pelvic inflammatory disease (PID) in lower abdominal pain. It is very common.
- History of purulent vaginal discharge, dysmenorrhea, and burning pain during micturition are important features.
- Anorexia, nausea, and vomiting are absent.
- Pain is felt on both sides and lower than in appendicitis.
- The pain is typically bilateral.
- Pain starts within 7 days of menstruation and stays for >2 days.
- On vaginal examination the cervical and bilateral adnexa are found tender.
- Transvaginal ultrasound is of help in reaching to diagnosis.
- Diagnostic laparoscopy may be of help to diagnose it in difficult situations.
- Thorough examination and keeping in mind PID can 15% reduce negative appendectomies.

Pyelonephritis

- Patients of pyelonephritis have a dull pain in the lumbar region.
- Patients usually have high fever associated with rigors.

Ectopic Pregnancy

When a fertilized egg implants outside the uterus, most commonly it happens in fallopian tube.

Torsion of an Ovarian Cyst

- Torsion or hemorrhage in ovarian cysts may cause sudden severe pain in the abdomen.
- May be low-grade fever with vomiting present.
- A mass is felt on RIF if the cyst is big.
- Pelvic ultrasound and CT scan are diagnostic.

Endometriosis

Endometriosis in RQL can mimic AA as the endometrial tissue can get deposited over the right ovary, right fallopian tube, and the appendix.

Gallstone Colic

Gallstone colic can mimic acute appendicitis, but the pain will be located in or near the right hypochondrium and may radiate to the back, whereas the acute appendicitis pain is in the RIF.

IN ELDERLY

Appendix in old age progressively atrophies.

Diverticulitis

Diverticulitis develops due to inflammation of a colonic diverticulum. A CT scan is a diagnostic investigation for diverticulitis.

Acute Intestinal Obstruction

- Acute appendicitis is uncommon in the elderly, and intestinal obstruction is common.

JAYPEE BROTHERS

- The diagnosis of intestinal obstruction is easy, as an X-ray abdomen and an ultrasound are diagnostic.
- Early decision for surgery is important.

Carcinoma of Colon

Acute appendicitis can be a sign of cancer of the colon, as the growth may obstruct the lumen of the appendix.

Torsion of Appendix Epiploica or Epiploic Appendicitis

It is an infarction of the appendix epiploica due to its torsion. Appendices epiploicae are small peritoneal sacs filled with fat and are attached to the colon. Pain may be mild or severe and last for a few days.

- The site of pain is the colon area.
- There is no anorexia, sequence of symptoms, and shifting pain of appendicitis.
- The patient does not look ill.
- Nausea and vomiting are uncommon.
- Recurrence of pain occurs.
- Local signs of tenderness and rebound tenderness are present.

Mesenteric Infraction

It causes interruption of the blood supply to varying portions of the small intestine. Mortality is approximately 50%. Early diagnosis and surgical treatment are of utmost importance. In a case where *acute mesenteric ischemia (AMI) is suspected, urgent computed tomography angiography (CTA)* should be performed.

Leaking Aortic Aneurysm

It causes sudden and severe pain in the abdomen, and 80% of patients die before reaching hospital.

RARE DIFFERENTIAL DIAGNOSIS

Amebic Typhlitis

Amebic typhlitis can present as appendicitis, as it is the inflammation of the cecum, which harbors the appendix.

Spinal Conditions

- Tuberculosis of the spine or Pott's spine is a common condition. It causes nerve root compression, which may appear as appendicitis pain if T10 or T11 are affected.
- Lumbar spine rigidity may be present.
- Movement aggravates pain.
- No intestinal symptoms

Preherpetic Pain

- Preherpetic pain especially of 10th and 11th dorsal nerves, which occurs over the same area of appendicitis.
- Tere is marked hyperesthesia.
- Pain is not shifting.
- Tere is no muscle rigidity or guarding.
- A herpetic eruption will develop after a few hours.

Tabetic Crisis

It is rare nowadays.

Abdominal Crisis of Diabetes Mellitus

- History of diabetes mellitus
- No abdominal rigidity
- Abdominal crisis of porphyria
- Severe attacks of intestinal colic occur.
- Urine is of an orange color, which changes to a high color when exposed to sunlight.
- It is precipitated by barbiturates.

Leukemic Ileocecal Syndrome

- It is rare.
- It occurs in immunosuppressed patients.
- Gram-negative septicemia (*Clostridium septicum*) occurs.

Primary Peritonitis

It occurs in the following conditions:

- Nephrotic syndrome
- Cirrhosis
- Immunosuppression

It is diagnosed by peritoneal aspiration showing only gram-positive cocci.

Sigmoid Diverticulitis

- It has almost identical findings such as appendicitis on the left side, but if the sigmoid colon loop is big and lies right to the midline, then it becomes clinically impossible to differentiate acute sigmoid diverticulitis from acute appendicitis.
- A CT scan of the abdomen is of value to differentiate acute sigmoid diverticulitis from acute appendicitis.
- Ultrasound is not of much value.

JAYPEE BROTHERS

Carcinoma of the Cecum

- Sometimes carcinoma of the cecum may mimic acute appendicitis, especially when it is perforated.
- History of change of bowel habits and anemia with a palpable mass is diagnostic of carcinoma of the cecum.
- Contrast CT scan is an important diagnostic tool.

COMPLICATIONS OF APPENDICITIS

In 1886, Fitz reported the associated mortality rate of appendicitis to be 67% without surgical therapy. Currently, the mortality rate of acute appendicitis is reported to be <1%. Elderly patients have a higher rate of complications.

Complications of Appendicitis

- Perforation of the appendix
- General peritonitis
- Appendicular abscess
- Appendicular lump or mass
- Septicemia
- Portal pyemia
- Infertility
- Recurrent appendicitis
- Obliteration of the appendix
- Intestinal obstruction
- Appendicular cysts
- Vascular infections as complications of appendicitis

PERFORATION OF APPENDIX

Urgent appendicectomy is the treatment of choice for acute appendicitis, which prevents the risk of perforation. The average rate of perforation of the appendix in acute appendicitis is 25.8%. Children younger than 5 years and patients older than 65 years have the highest rate of perforation (45% and 51%, respectively). Nonoperative treatment exposes the patient to perforation.

Perforation usually occurs due to increased intraluminal pressure, which occurs in obstructive appendicitis. Patients having nonobstructive appendicitis rarely get perforation, if at all, and it is usually late. Perforation is uncommon within the first 12 hours.

The accuracy in diagnosing acute appendicitis does not change the rate of perforation. Surprisingly, the diagnosis accuracy diminishes, but the appendicectomy rate increases. Usually, a perforated appendix is brought from home, it is rare to happen in admitted hospital patients. Hospital-admitted patients can be diagnosed after some time if he/she is not diagnosed early.

Overall, about 20% of all patients with acute appendicitis have perforation at the time of operation. At the extremes of age (<5 years and >60 years) the rate of perforation is in the region of 60%.

Promoting factors of general peritonitis due to perforation of the appendix are:

- Extremes of age—too young or too aged.
- Diabetes mellitus
- Poor nutritional state of the patient
- Other debilitating conditions
- Immunosuppression
- Previous abdominal surgery—which reduces the ability of the greater omentum to wall off the infection.
- Pelvic appendix—it hangs freely in the pelvis without protection.
- Obstruction of the appendix lumen, e.g., finding a fecalith in the lumen of an appendix on exploratory laparotomy for any other reason, is an indication of appendicectomy to prevent future acute appendicitis and generalized peritonitis.

When to Suspect Perforation?

Perforation of the appendix in a case of acute appendicitis should be suspected in the following conditions:

- Fever higher than 102°F
- WBC count >18,000/mm^3
- Sudden increase of pain in RIF with localized rebound tenderness
- Generalized peritonitis

When to Suspect General Peritonitis?

When perforation of the appendix leads to general peritonitis, you will find:

- Patient looks toxic
- Tenderness all over the abdomen
- Initial board-like rigidity of the abdomen, later distension of the abdomen
- Vomiting
- Absolute constipation
- High fever
- No bowel sounds, silent abdomen

Treatment

- *If it presents as a small abscess:* Incision and drainage is done extraperitoneally, and after a 6-week interval, appendicectomy is advised.

JAYPEE BROTHERS

- *If generalized peritonitis is present:* Laparotomy is done. Appendicectomy is done if the appendix is easily accessible.
- *If the appendix is inaccessible:* If the appendix is found inaccessible and cannot be removed, then interval appendicectomy is recommended after 6 weeks.

GENERAL PERITONITIS

It develops after perforation of the appendix when the protective phenomenon of the body tries to seal it off from other parts of the peritoneal cavity by omentum and loops of the small bowel, but fails. The pain, fever, tenderness, and rigidity increase. At this stage or later, the abdomen should be opened, a midline or right paramedian incision. Peritoneal lavage with normal saline should be performed.

Some researchers believe that, as per exudate in the peritoneal cavity after perforation of the appendix following types of peritonitis can happen:

- Acute fibrinous peritonitis
- Acute serofibrinous peritonitis
- Acute fibrinopurulent peritonitis
- Acute purulent peritonitis
- Acute dry or septic peritonitis

APPENDICULAR ABSCESS

The first reported case of the appendicular abscess was reported in 1848 and operated by Henry Hancock, Surgeon, Charring Cross Hospital, London. There is a tender mass in RIF with high fever, which may be associated with chills. Ultrasound and CT scans are diagnostic.

Causes of Appendicular Abscess Open Surgical Repair

- Appendicular mass does not resolve with *open surgical repair (OSR)* and converts to an abscess.
- Acute appendicitis leads to abscess formation.

The appendicular abscess should be drained. If appendicectomy can easily be performed, do it; otherwise, do not do blind dissection. Interval appendicectomy is done after 6–8 weeks. Usually, the appendicular abscess develops from the appendicular mass, which fails to resolve.

Important features of appendicular abscess are:

- Hot and tender mass in RIF.
- High pyrexia with chills and rigors
- High TLC (>14,000)
- Increase the size of the appendicular mass
- Shift to the left, polymorphs increase
- Tachycardia

Subphrenic Abscess

It may occur between the diaphragm and liver which is the most common site for a subphrenic abscess. It may occur in one of the three following ways:

1. As a part of general systemic infection
2. As a localized abscess from general purulent appendicitis
3. Direct extension from infected appendix by lymphatics.

Subphrenic abscess may occur even after recovery from acute appendicitis.

Rupture of Appendicular Abscess

Appendicular abscess can rupture and can cause:

- *Fistulae between*:
  - Appendix and urinary bladder
  - Appendix and small bowel
  - Appendix and sigmoid colon
  - Appendix and rectum
- *Intraperitoneal residual abscesses*:
  - Pelvic abscess
  - In between coil of small bowel
  - Paracolic abscess
  - Subdiaphragmatic abscess
  - Subhepatic abscess

Resolution of Appendicular Abscess

Appendicular abscess can be resolute in the following ways:

- Resolution by rupture of an abscess—it produces tissue necrosis due to pressure and abscess walls give way at a point of least resistance.
- Resolution by absorption of its contents—it may be partial or complete. Sometimes only the liquid part of the abscess gets absorbed and the solid part forms a mass.

Role of Interval Appendicectomy after Appendicular Abscess

In most of cases of appendicular abscess, the appendix is destroyed by necrosis and gangrene so appendicectomy should be performed only if symptoms recur, otherwise you may not be able to find the appendix.

JAYPEE BROTHERS

APPENDICULAR LUMP OR MASS (PHLEGMON)

Appendicular mass can develop in any case of acute appendicitis if appendectomy is not done. A total of 2–5% of patients with appendicitis present with a palpable mass in RLQ. Usually, appendicular mass develops on the third day from the start of the attack of acute appendicitis. When the infection goes beyond the wall of the appendix, or the appendix becomes gangrenous then small bowel loops and omentum come near the appendix and try to limit the spread of infection. The omentum that is why called the "policeman of the abdomen." It is nature's attempt to limit and prevent the spreading of infection causing generalized peritonitis. If an appendicular mass develops in a patient whose age is 50 years or above must go to CECT abdomen or barium enema and meal study after the resolution of the appendicular mass to rule out malignancy.

Constituents of Appendicular Lump

An appendicular lump consists of:

- Inflamed appendix in the center of the lump
- Cecum
- Loops of small bowel
- Omentum
- Maybe some pus, usually there is no pus. There is a tender lump in RIF. Usually, the appendicular mass resolves after conservative treatment. Appendicular mass is a tender, from well-circumscribed, localized mass, and smooth lump. It is nonmobile, does not move with respiration, and is resonant on percussion.

Mortality from Appendicitis

- Mortality from appendicitis is reducing. It was 9.9 deaths per 100,000 in 1939 and 0.2 per 100,000 in 1986.
- In ruptured appendix mortality increases up to 3%—a 50-fold increase, in the elderly it goes up to 15%.

Postappendicectomy Pyrexia (Fig. 18)

What to look in postappendicectomy pyrexia?

- Wound for infection. Look for hyperemia, cellulitis, or pus discharge.
- Examine lungs for atelectasis or pneumonia.
- Examine legs to rule out deep vein thrombosis (DVT).
- DRE to rule out pelvic abscess.
- Keep in mind intraperitoneal abscess, i.e., "when pus is somewhere, pus is nowhere, and pus is under the diaphragm." Remember this saying so you will not forget to examine the extra RIF sites of pus collection: Extra RIF sites of pus are:
  - Subdiaphragmatic abscess
  - Subhepatic abscess
  - Paracolic abscess
  - Interloop small bowel abscess
  - Pelvic abscess
  - Abscess at an operative site
- See the IV cannula site for thrombophlebitis; change it every third day.
- Catheter for UTI. UTI is one of the main causes of postappendicectomy pyrexia as the organism colonizes here and causes inflammation.
- Examine eyes—for jaundice—as pyrexia may be due to hepatitis.
- Examine urine for pyelonephritis.
- In children, look for tonsils for tonsillitis and the ear for otitis media.

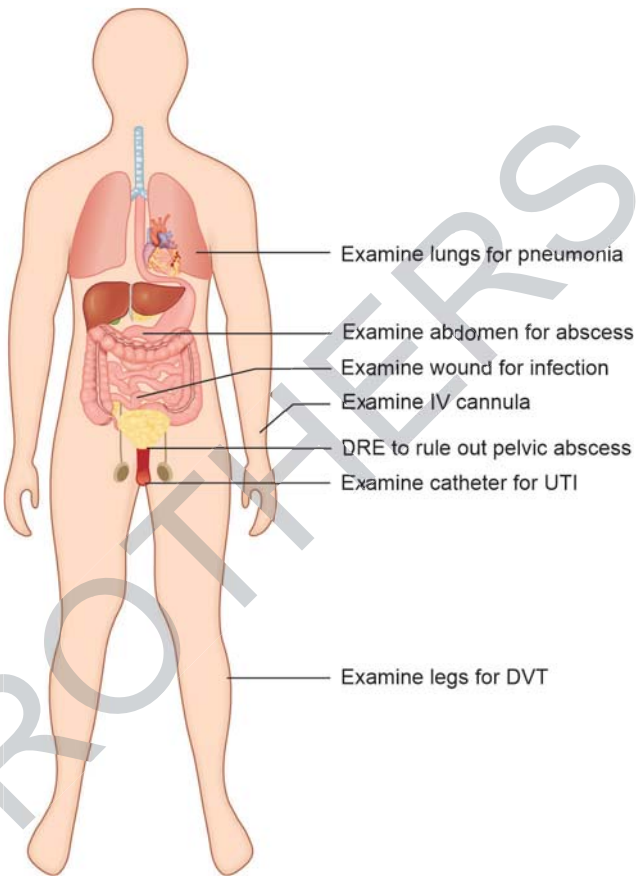

Fig. 18: Postappendectomy pyrexia. (DVT: deep vein thrombosis; IV: intravenous; UTI: urinary tract infection)

JAYPEE BROTHERS

Causes of Mortality

- Uncontrolled sepsis, i.e., septicemia, peritonitis, and intraperitoneal abscess.
- Pulmonary embolism

Differential Diagnosis of Appendicular Mass

- Carcinoma of the cecum
- Ileocecal hyperplastic tuberculosis
- Crohn's disease
- Actinomycosis
- Ovarian carcinoma
- Ilial lymphadenitis
- Parametritis
- Amebic typhlitis
- Twisted ovarian cyst

Treatment

The regimen of treatment is called the "**Ochsner–Sherren regimen**."*

Principle of Ochsner–Sherren Regimen

The inflammatory process of acute appendicitis is localized. Appendicular mass formation is nature's protective phenomenon. The operative search for the appendix may prove difficult and dangerous due to edema of the cecum and surrounding tissue, a fecal fistula can develop. Ochsner–Sherren regimen is a preparation for operation and not a postponement of appendicectomy.

Ochsner–Sherren regimen:

- Bed rest
- Nil orally
- Nasogastric aspiration
- Observation chart for pulse/temperature/size of mass
  - Intravenous (IV) fluids
  - IV antibiotic

The OSR consists of:

- Bed rest
- The head end of the bed is kept 30° up.
- Patient is kept nil orally. Gradually, orally water started at 30 mL hourly, then 60 mL.
- First oral fluids are given, then gradually semisolids, and then solids are started in 3–4 days.
- Observation chart is maintained. Pulse and temperature recorded 4 hourly.
- Daily abdomen examined and reexamined.
  - The limits of the lump is marked with a skin marker to see whether the lump increases or decreases.
- Intake and output chart is maintained.
- Hourly nasogastric aspiration by Ryle's tube** is done. Aspirate is collected, measured, color noted, and shown to a surgeon.
- IV fluid intake record is kept.
- IV antibiotics—a third-generation cephalosporin and metronidazole are given, targeting aerobic, gram-negative, and anaerobic organisms.
- After 48 hours, clinical improvement should be seen.
- Oral hygiene is maintained by 8 hourly mouthwashes.
- Deterioration in condition after 48 hours indicates the development of peritonitis.
- If a patient has not passed stool for 4–5 days, then a glycerin suppository is given.
- Desire for food occurs on the fourth to fifth day, which is a good sign.
- Usually an appendicular mass takes 2–6 weeks to resolve.

Contraindications of Ochsner–Sherren Regimen

- When one cannot make a definite diagnosis between acute appendicitis and any other cause of acute abdomen which needs urgent operation, e.g., rupture of ectopic gestation.
- Infection is still limited to the appendix and appendicectomy can be done.
- When the patient is an infant or child, perforation occurs early.
- If a patient is >60 years of age when perforation and peritonitis occur without much sign.

Fate of Appendicular Lump

- Resolution
- Appendicular abscess

In 9–15% of cases of appendicular lump, OSR fails, requiring operative intervention. Percutaneous or operative drainage of the abscess is not considered a failure. 40% of patients require appendicectomy before the planned time of interval appendicectomy, 6–10 weeks.

*Albert John Ochsner, Surgeon (1896-1981), and James Sherren, Physician.

** John Alfred Ryle (1889–1950), Professor of Physics at the University of Cambridge and Professor of Social Medicine at the University of Oxford, England; developed Ryle's tube in 1921.

JAYPEE BROTHERS

Future Plan

Interval appendicectomy is advised after complete resolution of the appendicular mass. The full resolution of appendicular mass takes 6–8 weeks. So, interval appendicectomy should be done after 6–8 weeks.

How do You Assess Improvement by the Ochsner–Sherren Regimen?

- Pain is diminishing and localizing.
- The size of the lump is reducing.
- Temperature is becoming normal
- Pulse rate returning to normal
- No vomiting and nasogastric aspiration is reducing in quantity. The patient is discharged only when he/she is taking a normal diet and passing normal stools.

When to Stop Ochsner–Sherren Regimen?

- Rising pulse rate
- Increasing and spreading abdominal pain
- Increase in size of the appendicular mass
- Increase in nasogastric aspiration amount or vomiting
- Diarrhea with infection, mucus in stool: This shows that the patient is not getting controlled by nature and treatment anymore, and peritonitis is setting in, so urgent operation is required.

SEPTICEMIA

It can occur at any stage of acute appendicitis but is commonly seen in perforation and peritonitis.

PORTAL PYEMIA OR SUPPURATIVE PYLEPHLEBITIS AND PYEMIC ABSCESSES

Pus emboli from suppurative appendicitis enter tributaries of the mesenteric vein and reach the liver, causing multiple abscesses. These are caused by *E. coli* present with high fever and jaundice. Now it is not commonly seen due to good antibiotics.

- Portal pyemia is a rare entity now. It is a form of septic portal system thrombosis and causes septicemia, which is a dangerous entity, and that is why it carries a poor prognosis. It is common in immunosuppressed patients.
- Portal pyemia causes a tender and enlarged liver with jaundice.
- It is treated by IV fluids and antibiotics.

Abscess can also develop due to portal pyemia in the kidneys, lungs, brain, spleen, etc. Pyrexia is accompanied with chills, rigors, fever, and excessive sweating. Fever is intermittent with periods of pyrexia. It may even run for months.

INFERTILITY

In a young girl perforated appendix can cause a frozen pelvis, due to extensive chronic inflammation in the pelvis, leading to infertility.

OBLITERATION OF THE APPENDIX

An obliterated appendix appears as thick and rigid, or it may become a thin fibrous strand or band. The whole appendix may be obliterated or only the tip gets affected, resulting in a clubbed appearance. If the middle of the appendix is affected and atrophies, then the appendix appears as a dumbbell. The color of the appendix becomes pale in the obliteration of the appendix, but if only the tip is involved, then the rest of the appendix is pink as a normal appendix. On cross-section, the appendicular wall consists only of two layers, the outer muscular layer and the inner or central layer of fibrous tissue.

INTESTINAL OBSTRUCTION

Usually, intestinal obstruction develops as a late complication of acute appendicitis. It develops when a patient recovers fully from an attack of acute appendicitis, it may also develop in the course of chronic appendicitis. The cause of intestinal obstruction is usually bands, or sharp flexures and adhesions developed due to an earlier attack.

APPENDICULAR CYSTS

Retention cysts of the appendix are produced in appendicitis if a portion of the lumen of the appendix distal to the obstruction remains patent, the normal secretion is accumulated, and a retention cyst develops. Sometimes the appendicular luminal tube is occluded at more than one site, and then multiple cysts develop. Usually, the contents of the retention cysts are clear.

VASCULAR INFECTIONS AS A COMPLICATION OF APPENDICITIS

Infection can spread far by circulation from the infected appendix and can cause the following complications:

- Thrombotic and embolic processes
- Erosion hemorrhage can occur in the stomach and intestine in acute appendicitis.

JAYPEE BROTHERS

- Gangrene by embolus blocking an artery.
- Lymphatic spread can lead to subphrenic abscess or lymphadenitis.

TREATMENT OF ACUTE APPENDICITIS

General Principles

The goal of the treatment of acute appendicitis is threefold:

- Early diagnosis
- Urgent appendicectomy
- Prevention of complications

Urgent appendicectomy is the golden rule—it is done by open, conventional, or by laparoscopic method.

The aim of doing an appendicectomy is to prevent the complications of appendicitis, so there should not be a delay in removing the inflamed appendix.

On the other hand, the normal appendix should not be removed unnecessarily. Early diagnosis and early appendicectomy reduce the incidence of complications, morbidity, and mortality.

The discomfort and risk associated with the operation of appendicitis cannot be compared with the discomfort and risk (morbidity and mortality) associated with perforation of the appendix and peritonitis.

Appendicectomy is the treatment of choice for acute appendicitis.

Appendicectomy can be performed by two methods.

1. Open or conventional appendicectomy
2. Laparoscopic appendicectomy

PROGNOSIS OF ACUTE APPENDICITIS

- If appendicectomy is done properly and early, then recovery is fast, and the patient goes home without any long-term effects.
- The mortality in uncomplicated cases of acute appendicitis is <0.1%.
- The mortality in a perforated appendix with peritonitis is <1%.
- The mortality in perforated appendix in elderly patients is up to 15–20%.
- *The mortality rate of the acute appendix is nowadays falling due to:*
  - Early diagnosis
  - Early appendicectomy when the infection is limited to the appendix.
  - Increasing awareness of the public.

SOME GOLDEN RULES IN ACUTE APPENDICITIS

- Rectal examination must be done in every patient with RIF pain.
- Gynecological examination is necessary for every child-bearing age female, especially 13–25 years suffering with RIF pain.
- There is no harm in removing a normal appendix, but there is big harm in not removing an inflamed appendix.
- Always examine external genitals in a young male with RIF pain.
- Take a decision immediately and not to postpone it for the next morning as hours matter in acute appendicitis, not days.
- When you go for a ward round, always examine the pulse of the patient yourself.

SOME IMPORTANT AND PRACTICAL HINTS TO THE BEGINNERS

- Do not rely solely on laboratory investigations, e.g., TLC and urine examination, which can be normal.
- If you cannot diagnose for sure and have doubts, then do not commit but reexamine the patient.
- The laparoscopy may be helpful in both diagnosis and treatment.
- Ultrasound of the abdomen cannot diagnose 100% in an early stage of acute appendicitis and it may be deceptive. So, depends more upon signs and symptoms than on ultrasound. A normal ultrasound is not a contraindication for appendicectomy.
- Localized abscess can be aspirated by CT-guided process under local anesthesia, which reduces the morbidity.
- Do not try medical therapy, e.g., antibiotics, once you have made the diagnosis of appendicitis; always advise urgent appendicectomy.
- With laparoscopy, several time-honored rituals have been proven unnecessary.
- Josef E Fischer, Editor of Master of Surgery, says, "We currently do not oversee the appendiceal stump or cauterize the mucosa after using a stapler."
- If you cannot decide, call some more experienced surgeon; remember your timely decision can prevent your patient's morbidity and mortality.
- Various studies have shown that during pregnancy, laparoscopic appendectomy can be done with a low

JAYPEE BROTHERS

incidence of fetal loss. But it should be done with caution. An open approach should be used after the first trimester.

SOLUTION

- Incision should not be >3 cm medial to ASIS.
- Give more importance to the situation of the appendix than cosmetic reasons.
- Do not hesitate to enlarge the incision if you require more space.
- Do not hesitate to open the rectus sheath medially if you feel the space is less and a lot of retraction is required. The junction of the internal oblique muscle and rectus sheath is the thinnest part, so incise here.
- The best way to gain more space is to enlarge the incision by cutting deep muscles in the line of skin incision and converting a muscle splitting to muscle cutting, incision, and catching the bleeders.

OTHER CONDITIONS OF APPENDIX

- Mucocele of the appendix.
- Pyocele of the appendix or empyema of the appendix.
- Intussusception of appendix.
- Diverticulum of the appendix.
- Cyst of the appendix.

MUCOCELE OF APPENDIX

Mucocele of the appendix is a retention cyst of the appendix. It is of four types:

1. Retention cyst
2. Mucosal hyperplasia
3. Cystadenoma
4. Cystadenocarcinoma

Sometimes obstruction of the lumen of the appendix happens without the development of infection, it leads to mucocele of the appendix as mucus secretion continues in spite of obstruction of the lumen of the appendix. The mucus gets collected in the appendix. It should be differentiated from cystadenocarcinoma of the appendix.

The symptoms of mucocele of the appendix are like mild recurrent appendicitis. If infection occurs, then it turns to empyema of the appendix. It is diagnosed by ultrasound and CT scan.

Treatment of mucocele of the appendix is appendicectomy.

Malignant Mucocele

It is a mucous papillary adenocarcinoma grade I of the appendix.

PYOCELE OF APPENDIX OR EMPYEMA OF APPENDIX

- Distention of the appendix with pus is called "empyema or pyocele" of the appendix.
- Mucocele of the appendix may convert to empyema due to infection and pus formation.
- Rupture of empyema of the appendix causes generalized peritonitis.
- Treatment of empyema of the appendix is appendicectomy.

INTUSSUSCEPTION OF APPENDIX

It is a rare condition and usually occurs in children. It is diagnosed only when an operation is done for acute appendicitis.

Clinical Features

Its symptoms are of subacute appendicitis.

Complications

- Appendicocecal or appendiculocecocolic intussusception.
- Appendix may slough out and be treated as agenesis of the appendix later on.

Treatment: Appendicectomy

Diverticulum of Appendix

It is a rare entity.

The diverticulum of the appendix is of two types:

1. Congenital or true diverticulum. It has all the layers of the wall of the appendix.
2. Acquired or false diverticulum.

It has only a mucus membrane and no muscle layer. It occurs due to the rise of pressure inside the lumen of the appendix as in mucocele. The mucosa is pushed out of weak spots in the muscle layer, "Hiatus muscularis."

The diverticula of the appendix can also occur by external traction by adhesions. When the lumen of the appendix gets blocked at a place cystic distension of the appendix occurs which follows the development of the diverticulum. It is more common when the muscular walls of the appendix are weakened. Appendicular diverticula may be single or multiple. Most of the diverticula

JAYPEE BROTHERS

in an appendix developed between the folds of the mesoappendix.

Diverticula of the appendix can occur at any site in the appendix but are commonly found at the tip of the appendix.

TUMORS OF APPENDIX

Tumors of the appendix:
- *Benign tumors:* Lymphoma, fibroma, myxoma, angioma, myoma, and endometriosis.
- *Malignant tumors:* Carcinoid tumor, adenocarcinoma, and pseudomyxoma peritonei.

These are extremely rare tumors. Mostly the tumors of the appendix are malignant, benign tumors are rarer than malignant tumors.

Benign Tumors of the Appendix

Following benign tumors of the appendix are reported but are extremely rare:
- Lymphoma
- Fibroma
- Myxoma
- Angioma
- Myoma
- Endometriosis

Endometriosis

The endometrium of the appendix is not an extremely rare entity. It causes pain in RIF which becomes monthly and is associated with melena.

Treatment: Appendicectomy

MALIGNANT TUMORS OF THE APPENDIX

- Carcinoid tumor or argentaffinoma of appendix
- Adenocarcinoma of appendix
- Pseudomyxoma peritonei

Carcinoid Tumor or Argentaffinoma of Appendix

It is found in one case in 400 appendix specimens subjected to histopathology after appendicectomy in acute appendicitis. One study has shown mean age of carcinoid of the appendix is 42.2 years and predominance in females.

Origin

- Kulchitsky cells of crypts of Lieberkühn (Johann Nathanael Lieberkühn, 1711–1756, physician and anatomist, Berlin, Germany).
- It is the most common tumor of the appendix.
- The most common site of carcinoid tumors is the appendix.

Site

- It can be found at the tip, base, or body of the appendix.
- Most commonly it is found near the tip of the appendix, (70% of cases).

Pathology

- It is yellow, from and small tumor.
- It is situated between the mucosa and peritoneal coat of the appendix.
- Tumor cells are typically arranged in small nests.
- Carcinoid tumor of the appendix very rarely gives metastasis, only in 2% of cases. One unique carcinoid tumor is the "Goblet cell carcinoid" (adenocarcinoid). The histological behavior of the tumor is between the carcinoid tumor and the adenocarcinoma of the appendix.
- This tumor arises from argentaffin or enterochromaffin cells. Argentaffin cells are present among the cells lining the wall appendix. The cytoplasmic granules of these cells strain black with silver salts so-called "Argentaffin" and brown with chromium salts so-called "Enterochromaffin" cells. *They are classified as a type of Amine Precursor Uptake and Decarboxylation (APUD) cells.*

Treatment

The malignant potential of the tumor is related to its size.
- Appendicectomy is the treatment of choice if the tumor is <2 cm in size.
- *Right hemicolectomy is done if:*
  - Tumor is >2 cm in size.
  - Cecal wall is involved.
  - Regional lymph nodes are enlarged.

Carcinoid Syndrome

It is due to chemicals in carcinoid tumors. These chemicals are:
- 5-HT (5-hydroxytryptamine or serotonin)
- 5-hydroxytryptophan
- 5-HIAA
- Histamine
- Kallikrein
- Bradykinin

JAYPEE BROTHERS

Clinical Features of Carcinoid Syndrome

Carcinoid tumors that metastasize to the liver are sometimes associated with a symptom complex called carcinoid syndrome which is characterized by mnemonic (Mn)—DABAR.

D: Diarrhea
A: Attack of bronchial asthma due to histamine.
B: Increased borborygmi
A: Attack of flushing of the face is induced by alcohol.
R: Reddish blue hue (cyanosis) due to histamine.

Carcinoid syndrome is rarely associated with appendix carcinoid unless widespread metastases are present, which occur in 2.9% of cases. Symptoms due to carcinoid are rare, although tumors can obstruct the appendix lumen and result in acute appendicitis.

Adenocarcinoma of Appendix

The most common presentation of carcinoma of the appendix is acute appendicitis.

- It is a very rare tumor.
- Usually, the tumors are diagnosed late.
- Neoplasm occurs in three major histologic subtypes.
  - Mucinous adenocarcinoma
  - Colonic adenocarcinoma
  - Adenocarcinoid
- Mucus-secreting adenocarcinoma of the appendix can rupture and disseminate malignant cells in the peritoneal cavity and cause pseudomyxoma peritonei.
- *10% of patients have dissemination at the time of operation.*

Malignant mucocele: It is a mucus-secreting papillary adenocarcinoma where the appendix gets distended with mucoid secretion.

Treatment

- Right hemicolectomy.
- If pseudomyxoma peritonei, then resection of the involved peritoneum is also done, and then chemotherapy is given.

Pseudomyxoma Peritonei

Recent studies suggest that the appendix is the site of origin for most of the cases of pseudomyxoma and not the ovary. Mucin-secreting adenoma (mucinous cyst adenoma) and adenocarcinoma (mucinous cyst adenocarcinoma) invade through the wall of the appendix and produce intraperitoneal seedlings and spread to the whole peritoneal cavity. The abdomen is filled with yellow-colored jelly. It is a locally malignant condition. It does not give extraperitoneal metastasis. Diagnosis is made by ultrasound and CT scan. It is three times more common in females than males.

Treatment

Debulking surgery is done with appendicectomy. The jelly is scoped out. Recurrence is common but takes years to develop.

Resection of the peritoneum and intraperitoneal chemotherapy helps some patients.

OPERATIVE SURGERY OF APPENDIX

Introduction

Since the first appendicectomy was done by Claudius Amyand in 1735 on a boy, it is the treatment of choice for appendicitis. Appendicitis is a common problem, and the gold standard treatment of appendicitis is appendicectomy. There is a possibility of developing complications in the inflamed appendix if there is a delay in appendicectomy. Complications can be serious like perforation of the appendix and general peritonitis and therefore, the appendicectomy for inflamed appendicectomy is considered a medical emergency.

ANATOMY OF RIGHT ILIAC FOSSA IN RELATION TO APPENDIX SURGERY

The anterior abdominal wall has the following features:

Skin

The skin of the anterior abdominal wall has an enormous capacity for stretching as during pregnancy.

Superficial Fascia

It has two layers below the level of the umbilicus and one layer above the umbilicus.

The two layers of superficial fascia are:

1. Camper's fascia superficial fatty layer.
2. Scarpa's fascia, deep membranous layer.

Cutaneous Nerves

Cutaneous nerves are derived from the lower five intercostal nerves, subcostal nerves, and iliohypogastric nerves.

JAYPEE BROTHERS

Cutaneous Arteries

These are branches of arteries that accompany nerves:

- Superior epigastric artery
- Inferior epigastric artery
- Lower intercostal arteries

Cutaneous Veins

- Accompany arteries
- Veins radiate from the umbilicus, veins above the umbilicus drain to the superior vena cava, and veins from below the umbilicus drain to the inferior vein cava.

MUSCLES OF ANTERIOR ABDOMINAL WALL

There are four muscles on either side of midline:

1. External oblique muscle
2. Internal oblique muscle
3. Transversus abdominis muscle
4. Rectus abdominis muscle

External Oblique Muscle

- It originates from lower eight ribs.
- It inserts in xiphoid process, linea alba, pubic symphysis, pubic crest, and pectineal line.

Direction of Fibers

- Medially
- Downward
- *Forward:* Fleshy fibers of muscle are laterally present and tough and whitish aponeurosis is situated medially.

The junction of fleshy fibers and aponeurosis of the external oblique muscle is approximately medial to a line drawn down from the tip of the ninth costal cartilage; medial to this line is aponeurosis, and lateral are fleshy muscle fibers.

Internal Oblique Muscle

- It originates from the inguinal ligament, iliac crest, and thoracolumbar fascia.
- It inserts as an aponeurosis to the lower four costal cartilages, xiphoid process, linea alba, pubic crest, and pectineal line.

Direction of Fibers

- Medially
- Upward
- Forward
- The aponeurosis of the internal oblique muscle is in the medial part. Internal oblique aponeurosis takes part in the formation of the rectus sheath. It forms two layers, anterior and posterior, above the point midway between the umbilicus and the pubic symphysis; below this point, it forms only an anterior layer. The posterior layer of internal oblique aponeurosis ends at a point midway between the umbilicus and pubic symphysis and is called "arcuate line" or "fold of Douglas" or "linea semilunaris."

Transversus Abdominis Muscle

- Originates from the inguinal ligament, iliac crest, thoracolumbar fascia, and lower six costal cartilages.
- Inserts at the xiphoid process, linea alba, pubic crest, and pectineal line.

Direction of Fibers

- Medially
- Horizontally
- Forward
- The neurovascular plane of an anterior abdominal wall lies between the internal oblique and transversus abdominis muscle. Various nerves and vessels run in this plane so while splitting or cutting this muscle taking care of nerves and blood vessels sometimes bleeding from here can be annoying.

Rectus Abdominis Muscle

- Rectus abdominis muscle runs vertically, originating as two heads from pubic crest and anterior pubic ligament.
- Inserts at xiphoid process and seventh, sixth, and fifth costal cartilages.
- Tere are three tendinous intersections in rectus abdominis muscle which divide the muscle in smaller parts at three levels:
  1. Xiphoid process
  2. Umbilicus
  3. Between xiphoid process and umbilicus
- Fascia transversalis lines the transversus abdominis muscle and is separated from peritoneum by connective tissue.

JAYPEE BROTHERS

INFERIOR EPIGASTRIC ARTERY

It arises from external iliac artery, it runs upward and medially in extraperitoneal connective tissue, reaches rectus sheath, and divides in upper and lower branch.

> Important point to remember is that neurovascular bundle runs between the internal oblique and transversus abdominis muscle. Iliohypogastric nerve pierces the internal oblique muscle about 2.5 cm in front of ASIS and then runs medially and forwards and pierces external oblique fascia 2.5 cm above inguinal ligament. This nerve can be damaged in big incision for appendicectomy and can cause right inguinal hernia.

- The ilioinguinal nerve pierces the internal oblique muscle and runs below the iliohypogastric nerve and external oblique muscle, and runs with the spermatic cord in the inguinal canal and emerges from the superficial inguinal ring.

PREOPERATIVE PREPARATION FOR APPENDICECTOMY

Shaving of the part is done in a ward before surgery. It is done from the nipples to the midthigh level. Nowadays, shaving one night before an operation is avoided if possible, to reduce the chance of postoperative infection, as skin abrasions will act as ports of entry for bacteria and will give them time to multiply.

- Patient is told to pass urine before going to the operating theater (OT).
- *Nil per os (NPO = Nil Per Oral, nothing by mouth)—6-hour fasting is required, but in an emergency, appendicectomy can be done in a shorter essential period for preoperative preparation.*
- IV fluid is to be given to avoid dehydration and to maintain normal urinary output.
- Antibiotics and IV antibiotics have been shown to significantly reduce the incidence of postoperative wound infection and intra-abdominal abscess formation. Antibiotics should be administered 30 minutes prior to incision to achieve the required tissue level of antibiotics. Antibiotics alone have been used in rare situations, such as with sailors on long submarine tours and long-distance travelers. IV antibiotics are given to cover gram-negative and anaerobic organisms. *The commonly used such antibiotics are:*
  - Cephalosporin
  - Metronidazole
  - Amikacin or another aminoglycoside
- Some doctors prefer a 1 g metronidazole suppository before the operation.
- A nasogastric tube should be introduced if you suspect perforation or peritonitis, or if the patient is profusely vomiting.
- If a patient has a fever, then cold sponging is done to reduce the temperature.
- Preanesthetic medicines are given according to the anesthetist's advice.
- Patient's anxiety and apprehension are reduced by properly explaining about the anesthesia and operative procedure.
- An indwelling Foley catheter is passed in patients with generalized peritonitis.

APPENDICECTOMY OR APPENDECTOMY

Appendicectomy

- In 1736, Claudius Amyand (1685–1740, Surgeon, St George's Hospital, London, England) successfully removed an acutely inflamed appendix from the hernial sac of a boy.

Appendicitis is the most common indication of appendicectomy, including its complicated entities.

- Lawson Tait (1845–1899, Surgeon, Hospital for Diseases of Women, Birmingham, England) was the first surgeon to perform the first planned appendicectomy in May 1880, but he did not report it till 1890.
- Thomas Morton (1835–1903, Surgeon, Philadelphia, PA, USA) was the first to diagnose appendicitis, drain the abscess, remove the appendix, and publish in 1887.

Definition

Removal of the appendix is called appendicectomy or appendectomy (in British English, it is called *appendicectomy* and in American English, appendectomy).

Types of appendicectomy:
- *Appendicectomy:*
  - Open or conventional appendicectomy
  - Laparoscopic appendicectomy
- Interval appendicectomy
- Incidental appendicectomy
- Retrograde appendicectomy
- Inversion appendicectomy

Indications of Appendicectomy

- Acute appendicitis
- *Appendicular tumor:*

JAYPEE BROTHERS

- Carcinoma of the appendix involving only the mucosa but not the base of the appendix
- Small carcinoid tumor <2 cm in size and at the body or tip of the appendix

- Subacute appendicitis
- Chronic appendicitis
- Recurrent appendicitis
- Interval appendicectomy after appendicular mass
- Mucocele of appendix.
- Empyema of the appendix
- *Endometriosis of the appendix*
- Diverticulum of the appendix—the acquired diverticulum of the appendix perforates early if appendicitis develops.

Open or Conventional Appendicectomy

Anesthesia

- Usually, the anesthetist decides during the preanesthesia checkup (PAC) about the kind of anesthesia is required.
- General anesthesia is preferred.
- Spinal anesthesia is also used.
- Local anesthesia with sedation and IV analgesics can be tried in very sick patients with other serious systemic ailments, and or where other forms of anesthesia are contraindicated.

Steps of Appendicectomy

Steps of Open Appendicectomy

- Incision
- Identification and isolation of the appendix
- Cutting of mesoappendix
- Removal of the appendix
- Inspection of the operative site, cecum, terminal ileum, and pelvic organs
- Closure of the wound

INCISIONS

Common incisions for appendicectomy ***(Fig. 19)****:*
- Gridiron incision (McBurney's incision)
- Lanz or crease incision
- Rutherford Morison's muscle cutting incision
- Lower right paramedical incision
- Lower midline incision
- Medial muscle cutting incision (Fowler–Weir approach)
- Battle's pararectus incision
- Rockey–Davis incision

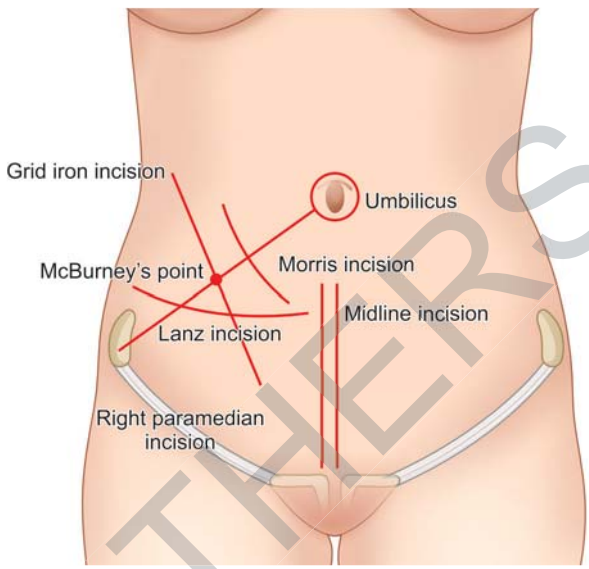

Fig. 19: Incisions for appendectomy.

Antibiotics should be administered 30 minutes prior to incision to achieve adequate tissue levels. IV antibiotics have been shown to significantly reduce the incidents of postoperative wound infection and intra-abdominal abscess.

Source: Andersen BR, Kallehave FL, Andersen HK. Antibiotics versus placebo for prevention of postoperative infection after appendicectomy. Cochrane Database Syst Rev. 2003;(2): CD001439.

The most commonly used incision in appendicectomy is the gridiron incision. A gridiron is a frame of crossbeams. It is used to support a ship during repairs.

Gridiron Incision

Gridiron incision was first described by Lewis Linn McArthur (1858–1934, Surgeon, St Luke's Hospital, Chicago, IL, USA). It is also called McBurney's gridiron incision.

Principle: It is a muscle-splitting incision. It is used to cause rapid healing and the least damage to the anatomy of the anterior abdominal wall. The incision was made in the abdominal wall in cases of appendicitis, with a description of a new method of operating.

Advantages of Gridiron Incision

- No nerve injury
- It heals fast
- Lowest mortality rate
- No muscle damage
- Less time-consuming compared to muscle-cutting incisions.

JAYPEE BROTHERS

Disadvantages of Gridiron Incision

- Cosmetically not very good
- Medial extension of the incision can damage the inferior epigastric vessels.

Steps of Gridiron Incision

- The center of the gridiron incision lies at McBurney's point and is perpendicular to the line joining ASIS and the umbilicus.
- It is a 5–7 cm-long incision.
- It can also be adjusted by moving up or down as the surgeon feels, according to the position of the cecum and appendix.
- Skin, superficial fascia, Camper's fascia, and Scarpa's fascia are divided along the line of incision.
- In the subcutaneous layer, a branch of the superficial circumflex artery is caught and cauterized or ligated.
- The external oblique aponeurosis is divided into the line of its fibers, which is in the same line as the incision. The external oblique fibers are kept separated by retraction with Czerney's retractors.
- Mayo's scissors or artery forceps are inserted and opened between the fibers of the internal oblique muscle and the transversus abdominis muscle, which splits the fibers of the muscles. Now, two index fingers are introduced and pulled apart to enlarge the space.
- Now the peritoneum is visible.
- Peritoneum is exposed by retraction.
- Two Langenbeck's retractors are inserted deep into the muscles, and the peritoneum is exposed. The peritoneum is incised between two artery forceps. First, the peritoneum is picked up by the surgeon by artery forceps. The peritoneum is now picked up by the assistant by artery forceps in front of the surgeon's artery forceps. Now surgeon leaves the peritoneum and again catches the fold of the peritoneum to avoid injury to the underlying bowel. Now the surgeon feels the fold of the peritoneum between his thumb and index finger to confirm that the bowel is not caught between artery forceps. Now he cuts the peritoneum fold with a knife. Do not cut by scissors as scissors can cut the bowel within the peritoneum fold.
- *As soon as the peritoneum is opened air sucks in, and intestinal loops fall back then the small cut is extended with scissors.*
- Gridiron incision can be converted to Rutherford Morison incision and can be extended up or down by cutting the muscle fibers if the exposure is not sufficient.

Closure of Incision

- The closure is done in layers.
- First the peritoneum and fascia transversalis are sutured with 2/0 Vicryl.
- Secondly, the fibers of the internal oblique and transversus abdominis are sutured together.
- Thirdly aponeurotic layer of the external oblique is sutured.
- Fourthly, the subcutaneous tissue and skin are approximated by staples or 3/0 Prolene, or subcuticular sutures. Even in advanced appendicitis or perforation, primary closure is cost-effective and without a high risk of wound infection, with proper use of antibiotics.

Lanz or Crease Incision

Otto Lanz (1865–1935, Surgeon, Amsterdam, the Netherlands) started this incision.

Principle: It is a cosmetic incision as it is a transverse incision in the skin crease, i.e., Langer's lines, which heals well and gives the scar in the skin crease.

Rutherford Morison's Muscle-Cutting Incision

James Rutherford Morison (1853–1939, Professor of Surgery, Durham, England) describes it for the first time.

Principle: It is an oblique muscle-cutting incision.

Details of incision: It starts at McBurney's point and goes up laterally.

- It cuts external oblique aponeurosis, internal oblique and transverses abdominis muscle in same line.
- Further steps are like gridiron incision.

Indications of Rutherford Morison's Incision

- Appendicectomy
- To expose ureter
- To expose external iliac vessels

Disadvantages of Rutherford Morison's Incision

- The chances of postoperative hernia are more due to nerve injury and local muscle cutting.
- Incisional hernia is also seen if the wound is not well-repaired.
- More chances of wound infection than other incisions due to more bleeding.
- The chances of postoperative hematoma are higher.

JAYPEE BROTHERS

Lower Midline or Right Paramedian Incision

- A lower midline incision is preferred over a lower right paramedian incision.
- *Indication:* It is used when in doubt about the diagnosis of perforation and peritonitis.

Advantages of Lower Midline Incision

- Midline incision is easy to extend upward if there is a perforated duodenal ulcer.
- It gives good access to the pelvic cavity as well as the abdominal cavity.
- Easy to close.
- Less damaging to the tissues, so it heals early.

Advantages of Right Paramedian Incision

- It gives good access to pelvic organs.
- It can be extended up if a perforated duodenal ulcer is present.

Disadvantages of Lower Midline or Right Paramedian Incision

- A lot of retraction is required to expose the appendix and cecum. It gives poor access in retrocecal appendicitis.
- The chances of postoperative hematoma and infection are higher with this incision as it behaves as a trapdoor for infection.
- It can contaminate the peritoneal cavity.

Fowler–Weir Approach

Similar to Battle's incisions, but the muscles are cut medially over the rectus muscle.

- Not used nowadays.

Battle's Pararectal Incision

William Henry Battle, 1855–1936, started this incision. Battle WH modified the incision for the removal of the vermiform appendix. (Br Med J. 1895;2:1360)

It is not used nowadays.

Indications of Battle's pararectal incision:

- Appendicectomy
- Gynecologic operations

Rockey–Davis Incision

It is similar to the Lanz incision. It is a transverse muscle-splitting incision. It is extended up to the rectus sheath for better exposure.

Identification of Cecum

- One retractor is placed on the medial side of the wound.
- If pus is present, take a swab for culture and sensitivity before removing it by suction.
- *Identify the cecum by:*
  - Anterior taenia coli
  - It is whitish-pale in color, whereas ileal loops are pinkish
  - Absence of appendices epiploicae

Delivering the Cecum and the Appendix

Hold the cecum with a swab by thumb and index finger and bring it out in wound by pulling it down and medially.

Identification and Isolation of Appendix

- *Appendix is caught with Babcock forceps near its tip encircling it and not crushing. Now it is pulled so as to see the mesentery and base of the appendix clearly.*
- The loops of the ileum are returned back to the peritoneal cavity.
- The abdominal pack is put around to wall of the peritoneal cavity from the wound.
- One can easily reach the cecum by following the peritoneal reflection from the abdomen wall.
- Sometimes, even the sigmoid colon and transverse colon could be present in RIF. The transverse colon has an omentum attached to it, and the sigmoid colon is identified by its mesocolon, whereas the cecum has no mesocolon or omentum.
- A word of caution—do not use cautery near the bowel as thermal injury may cause necrosis later on, which can form a fecal fistula.
- The right index finger is introduced into the wound to help in the gentle delivery of the appendix by hooking, but must be done under vision. Now the cecum is given to the assistant to hold.

Cutting of Mesoappendix

Mesoappendix is made tense by holding and pulling the appendix with Babcock forceps, or the mesoappendix is caught with curved artery forceps.

- One-pointed and curved mosquito artery forceps is introduced in the mesoappendix near its base near the appendicular artery. The 4–0 Vicryl ligature passes in this hole, and the appendicular artery is

JAYPEE BROTHERS

ligated. Gradually, in the same manner, the whole mesoappendix is ligated close to the appendix.
- Accessory appendicular artery is also ligated.

In most of cases, vessels are clearly divided at the base of the appendix and in such cases, ligature can be applied high enough to have perfect control of all vessels. In some cases, the cecal artery also supplies the base of the appendix.

Here, one has to be cautious against bleeding after amputation of the appendix.

Removal of Appendix

Crush the base of the appendix with straight artery forceps, which crushes only the mucus membrane and muscle coat but does not crush the serosa. The crushed mucosa and muscle coat block the lumen. Ligate the appendix base at the crush site with 3/0 Vicryl.

When the Base of the Appendix is Not Crushed?
- If the appendix is gangrenous.
- If there is a perforation at the base of the appendix.
- If the base of the appendix and cecum are edematous.

Occasionally, in certain cases, the appendiceal inflammation extends to the base of the appendix or beyond to the cecum. The division of the appendix through inflamed, infected tissue leaves the potential for leakage of cecal contents with a residual abscess or fistula—Poole GV (Am Surg. 1993;59:624-5)

A purse string suture or 'N' shape suture with 3/0 Vicryl is applied ***(Fig. 20)****. It is applied on the wall of the cecum around the base of the appendix. Take care of not injuring any blood vessels while taking a purse-string suture, as it may become a big hematoma in the wall of the cecum. It is a seromucosal suture. Take taenia coli in it to give strength to this ligature.*

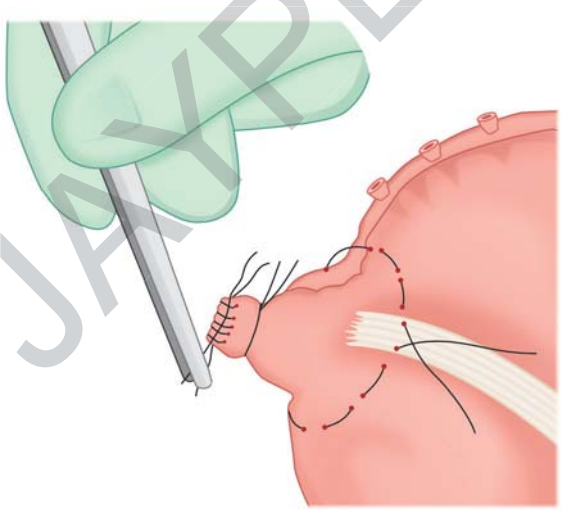

Fig. 20: Purse string suture.

Clamp the base of the appendix with an artery forceps 5 mm away from the ligature.

Before putting the clamp on the appendix milk, the intervening portion of the appendix between the ligature and the artery forceps by sliding with the artery forceps, to avoid soiling of the operation site when the appendix is cut.
- Now the appendix is cut flushed with artery forceps by a knife.
- Place a swab behind the appendix base to avoid spillage.
- Cut the ligature of the appendix stump.
- The cut stump of the appendix is touched with phenol or betadine solution or spirit or cauterized by diathermy to avoid contamination.

Burying the Base of the Appendix

Recent prospective studies show no advantages to appendiceal stump inversion.

Inversion may also have the deleterious effect of deforming the cecal wall, which could be misinterpreted as a cecal mass on future contrast radiographs. Furthermore, the long-standing notion that stump inversion reduces postoperative adhesion was discredited by Strut and colleagues. Now, the general opinion is to avoid the burying of the base of the appendix.

Invaginate the stump with pursue string suture or "figure of Z or N" suture by holding the stump base near the knot of a purse-string suture with a straight toothless dissecting forceps while pushing the stump of appendix in cecum the purse string suture is tied then cut this ligature 5 mm from the knot.

COMPLICATED SITUATIONS DURING APPENDECTOMY

The main purpose here is how to avoid injury to the intestine and other organs while doing an appendectomy in complicated situations.
- When the tip of the appendix is densely adherent then first do amputation of the appendix at the base and then free the tip by careful dissection. It is easier than when both ends are fixed.

JAYPEE BROTHERS

- If the whole appendix is fixed by dense adhesions, then there is a risk of bleeding and injuring other structures by dissecting deep in adhesions. First, free the base of the appendix then give traction by applying artery forceps at this end of the appendix, cut the peritoneal covering over the appendix on its direction, and the appendix can be stripped.
- When omentum is adherent strongly with the appendix then it is better to tie and excise the omentum with the appendix.
- When the appendix is totally concealed and cannot be identified then utilize various landmarks, especially the cecum. Examine minutely cecum to find the base of the appendix. If you directly attempt to enucleate the mass, you may land up with disaster.

LAPAROSCOPIC APPENDICECTOMY

Historical Background

In 1982, Kurt Semm, a German Gynecologist, performed the first successful laparoscopic appendicectomy, several years before laparoscopic cholecystectomy **(Fig. 21)**.

Two meta-analyses have confirmed the benefits of the laparoscopic approach—this is at the expense of slightly longer operating time and a trend to higher incidence of intra-abdominal abscesses [*Source:* Sauerland et al. Kargar, Basil, 1998:109-14. Golub R, Siddiqui F, Pohl D. Laparoscopic versus open appendectomy: a metaanalysis. J Am Coll Surg. 1998;186(5):545-53].

Chronic or Subacute or Recurrent Appendicitis and Grumbling Appendix

Advantages of laparoscopic appendicectomy over open or conventional appendicectomy:

- A large meta-analysis comparing open to laparoscopic approach showed that the duration of surgery and operation costs are higher with laparoscopic appendicectomy.
- Faster convalescence, early mobility, shorter hospital stays, and early return to work.
- Less pain
- Better scar, so cosmetic
- Access to pelvic organs is better.
- Postoperative wound infection is less than open procedure.
- Exploration of the peritoneal cavity is possible.

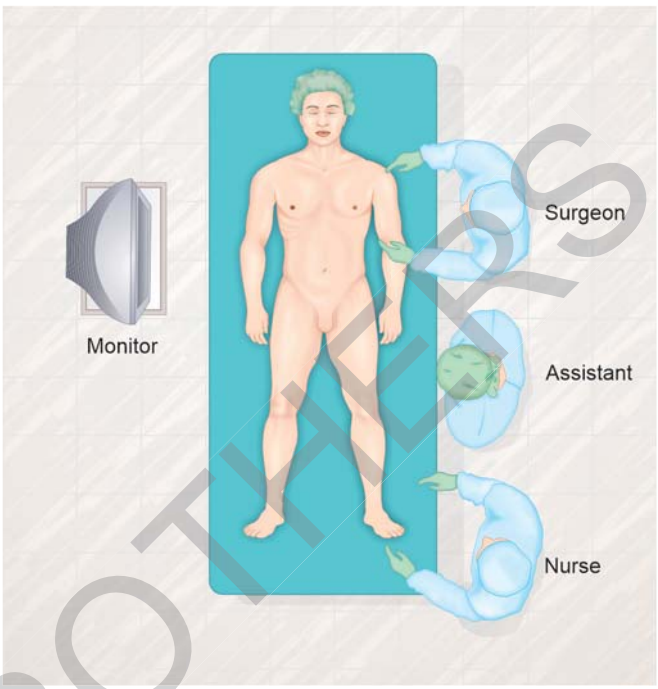

Fig. 21: Laparoscopic setup for appendicectomy.

- Treatment of other causes of RIF pain is possible.
- Unnecessary laparotomy is avoided.
- Better in obese patients as there is less risk of wound infection in fat patients. Wound infections were about as likely (Peto or Position: Supine in 15° Trendelenburg position with rotation of the table to the left side. 15–20°, right side up.

Indications

Acute Appendicitis

- In suspected cases where the diagnosis is not clear.
- In females of childbearing age.
- In obese appendicitis patients, the laparoscopic technique proved to be superior to an open technique in criteria such as perioperative-postoperative complications, operation time, etc. In open appendectomy in obese patients, sometimes incisions are required to be enlarged, extra time is required, and the risk of wound complications is higher.

In the first trimester of pregnancy.

- Incidental appendicectomy when the appendix is found inflamed during laparoscopy for other ailments.

JAYPEE BROTHERS

Position of Surgical Team

- The surgeon stands on the left side of the patient.
- The first assistant also stands on the left side of the patient next to the surgeon.
- The second assistant stands between the patient's legs or on the right side of the patient, but sometimes it obstructs the vision of surgeon to monitor.
- The monitor is kept on the right side of the patient.
- An anesthetist stands near the head of the patient.

Set Up in Operation Theater

- The right arm of the patient is extended with an IV cannula in it for drugs and IV fluids.
- Left arm is tucked under patient's side.
- Pulse oximeter is attached with the thumb of the right hand.
- Video monitor is at the eye level opposite the surgeon.
- Cables and CO_2 tubing are kept near the head end of the patient.
- The instrument tray is kept near the foot end of the patient.

Relative Contraindications

- Inexperienced surgeon
- Suspicion of malignancy
- Pregnancy
- Previous lower abdominal surgery
- PID
- Severe systemic medical disease as congestive heart failure (CHF)

Preoperative Preparation

A Foley's catheter is passed to evacuate the urinary bladder and monitor urinary output before sending the patient to OT, which can be removed after the operation in the OT itself. A nasogastric tube should be passed to decompress the stomach.

Anesthesia: General anesthesia.

Steps of laparoscopic appendicectomy:
- Introduction of instruments by three ports
- Division of mesoappendix
- Extraction of the appendix

Procedure

It is usually done with their ports. The fourth port is sometimes used in the retrocecal appendix to mobilize it.

Pneumoperitoneum

- A stab wound is made at the umbilicus with a No. 11 blade, and the Veress needle is passed through it to produce pneumoperitoneum.
- Nowadays, some surgeons use the open technique by using Hasson's cannula rather than the Veress needle to produce pneumoperitoneum.

Trocar Placement

- A 5 mm or 10 mm telescope is passed through the umbilical A port and the peritoneal cavity is surveyed in all four quadrants.
- Safe access to the peritoneal cavity is by Hasson's trocar, a 3 cm incision is given infraumbilically in midline up to linea alba, and Hasson trocar is bound to the abdominal wall. It is fixed with 2–0 Vicryl with fascia.
- Under the vision of the telescope the abdominal wall is transilluminated between the umbilicus and pubic symphysis then another 1-cm incision is made in the skin just above the pubic symphysis without damaging any vessel which is visible in transillumination, and a 10 mm port is introduced. Some surgeons prefer the port at McBurney's point in LIF to avoid the swording of instruments (collision of instruments).
- Another 10 mm post is introduced in LIF lateral to the inferior epigastric artery.
- Intraperitoneal pressure is kept at 12 mm Hg and a maximum to 14. In children, the pressure equals the age.
- Trocars should be inserted in a slightly oblique direction to prevent incisional hernia.
- Placement of trocars through the rectus muscle is avoided to avoid injury to inferior epigastric vessels.
- The table is tilted in the Trendelenburg position with the right side up by 25°. By this maneuver, the omentum and the coil of the small bowel fall away from the cecum and appendix.

Exploration

Sometimes, as you introduce a laparoscope in the peritoneal cavity, you find an appendix lying in front. It is called "handshake appendix" or "how do you do the appendix." When the appendix is found shining and normal, it is called the Lilly white appendix."

- First, the abdomen is thoroughly explored to exclude any other pathology.

JAYPEE BROTHERS

- Now the search for the appendix is started first identifying the cecum by the taenia coli. Follow the anterior taenia coli to find the appendix.
- If the appendix is found normal, then search for other causes of RIF pain, e.g., Meckel's diverticulitis, Crohn's ileitis, Port placement in laparoscopic appendices-salpingitis, and tuboovarian pathology.
- If the appendix cannot be found or cannot be exposed well then do not hesitate to convert the laparoscopy operation to an open operation.
- The appendix is caught near the tip with Babcock's forceps, and the mesoappendix is then visualized.
- A window is created in the mesoappendix near the base of the appendix, mesoappendix and base of the appendix are dealt with separately between clamps or staples.
- The mesoappendix is divided between two staples.

Removal of Appendix

- Two staples are applied at base of the appendix then the appendix is divided between two staples. Some surgeons prefer using endoloop at stump of the appendix.
- If the appendix appears gangrenous, then catch it with Babcock's forceps to avoid perforation.
- The base of the appendix is not inverted or buried.
- The appendix is put into the endobag, and the endobag is retrieved from the 10 mm port.
- The area of the appendix and cecum can be irrigated with saline if the site is soiled with pus or seropurulent fluid.
- Inspect the stump of the appendix and mesentery for any hemorrhage.
- RLQ may be irrigated if there is spillage.

Closure

- Remove all ports under vision so any bleeding from the abdominal wall can be seen and stopped.
- Skin staples are used at a 10 mm port site.
- At the 5 mm post site adhesive band-aid is applied.
- Drain is put in if there was generalized peritonitis.
- It is advised to locally infiltrate long-acting local anesthetic at three port sites for relief of postoperative pain.
- Some surgeons feel that in the case of a perforated appendix, the CO_2 pneumoperitoneum enhances the bacteremia and toxemia, though it is not confirmed.

Various inflammatory stages of the appendix in appendicitis and how to deal:

- *If the appendix is normal*: Look for other sources of abdominal pain; if it is not found, then proceed for appendicectomy.
- *If the appendix is mildly inflamed without the involvement of mesoappendix:* The appendix can be held with a grasper gently and without fear of perforation; it can be removed by putting it in a 10 mm trocar and removing the trocar and appendix together, protecting the abdominal wall from contamination.
- *Highly inflamed appendix with thickened mesoappendix:* Be gentle and do not move the appendix too much unnecessarily. A fourth port, if required, should be introduced to facilitate the dissection. The appendix must be removed on a retrieval bag to avoid spillage in the peritoneal cavity. Adhesions can be relieved by gentle traction on the appendix. A pretied ligature may be used to elevate the grossly inflamed appendix with minimal trauma.

Needlescopic Approach

- In laparoscopic approach two 10 mm ports and one 5 mm port are used.
- In needlescopic approach one 10 mm and two 2 mm ports are used.

Postoperative Care

- Foley's catheter is removed in the postoperative period.
- The rest of the care is the same as in the open procedure.
- Patient is discharged on the second postoperative day.
- Two recent meta-analyses have confirmed the benefit of the laparoscopic approach in relation to less pain, faster recovery, and a lower incidence of wound infection. But a Cochrane database systematic review of over 4,000 patients suggested that there was a threefold increase in intra-abdominal abscesses and a longer operating time (16 minutes) in those patients undergoing laparoscopic procedures.

Interval Appendicectomy

Interval appendicectomy is defined as "an elective appendicectomy in the interval" between attacks of appendicitis. It is the easiest appendicectomy. It is usually done 6–10 weeks after the resolution of the appendicular mass.

Incidental Appendicectomy

Incidental appendicectomy is an appendicectomy for a normal appendix during laparotomy or laparoscopy for another condition.

JAYPEE BROTHERS

Inversion Appendicectomy

Indication

It is done when an incidental appendicectomy is performed.

Aim

- To avoid the risk of sepsis in otherwise clean laparotomy.
- In appendicectomy the bowel is opened, and bacterial soiling of peritoneum may happen.

Postoperative Complications of Open Appendicectomy

Age and perforation of the appendix significantly increase the complications; one study showed the rate of complications 3% in nonperforated appendicitis and 47% in perforate cases.

Complications of Appendicectomy

- Wound infection
- Hemorrhage
- Intraperitoneal abscesses
- Paralytic ileus
- Fecal fistula
- Portal pyemia (pylephlebitis)
- Postoperative adhesions
- Acute intestinal obstruction
- Right inguinal hernia
- Pelvic abscess

Wound Infection

It is the most common postoperative complication. It occurs in <10% of cases; it increases with perforated appendicitis to 15–20% and is highest with diffuse peritonitis (35%). It is usually seen at home on the fourth or fifth postoperative day. Infection is most commonly found in subcutaneous tissue.

- Wound infection is almost always confined to subcutaneous tissue and responds to simple drainage.
- Wound infection can cause dehiscence or burst abdomen in laparotomy wounds but not in gridiron incisions.

Postoperative sequelae after appendectomy are early, intermediate, and late. Early sequelae are due to anesthesia or operations, such as hemorrhage, infection, and peritonitis continues. Intermediate sequelae develop within a few days to a few weeks, such as abscess, ileus, phlebitis, and embolus lodgment. Late sequelae arise after months or years, such as hernia and intestinal obstruction.

Hemorrhage

Slipping of the ligature of the appendicular artery or the accessory appendicular artery is usually the cause of reactionary hemorrhage. Take the patient to OT and open the wound and ligate the bleeding vessel.

Intraperitoneal Abscesses

The incidence of intraperitoneal abscesses has gone down due to preoperative and perioperative antibiotics. Locally increased pain, tenderness, and high fever suggest an intraabdominal abscess. A CT scan of the abdomen is diagnostic. The abscess can be in the following forms:

- Appendix fossa abscess
- Right paracolic gutter abscess
- Pelvic abscess
- Pouch of Douglas abscess
- Subphrenic abscess
- Subhepatic abscess
- Inter small bowel loop abscess, usually multiple

Paralytic Ileus

It happens after every appendicectomy but usually stays longer in the gangrenous, perforated appendix and generalized peritonitis.

Fecal Fistula

Nowadays, fecal fistula is rare due to the regular use of pre-, peri-, and postoperative antibiotics. It is an annoying but not a dangerous complication. The causes of the development of fecal fistula after appendicectomy are:

- Cecal wall edema with inflammation and sloughing of part of the cecum inside the purse string suture.
- Attempted appendicectomy in appendicular mass.
- Leakage from the appendicular stump due to slipping of the ligature in a noninvaginated stump.
- Appendicectomy in Crohn's disease, tuberculosis, actinomycosis, and carcinoma of the cecum.
- Tight and deep purse-string suture sometimes causes necrosis and leakage.
- Erosion of the cecum by a drain.
- When carcinoma of the appendix is the cause of appendicitis.
- By necrosis of the cecum from an abscess. All fecal fistulae close spontaneously in a few days unless there is distal obstruction.

Fecal fistula formation is most common when the appendectomy is performed for gangrene or perforation of the appendix.

JAYPEE BROTHERS

- *Clinical features:*
  - Features of infection are present as fever, erythema over the drain site or operation incision.
  - Foul-smelling, feculent discharge from the operation wound site or the drain site.
  - The skin around the fistula becomes excoriated.
- *Investigations*:
  - CT scan abdomen to look for other pathology.
  - CT fistulogram.
- *Treatment:* Conservative treatments are—antibiotics, IV fluids, dressing, and protective cream on the skin around the fistula, such as Lacto Calamine or zinc oxide cream. If the fistula does not close within 6 weeks, then consider resection and anastomosis of the ileocecal region.

Portal Pyemia (Pylephlebitis)

- It is rare nowadays due to the use of antibiotics.
- *It is characterized by:*
  - High fever
  - Chills and rigors
  - Jaundice
- It is due to the spread of suppuration to the portal vein via the superior mesentery vein. It may lead to multiple liver abscesses.

Postoperative Adhesions

It is a late complication of appendicectomy. Diagnostic laparoscopy is required to diagnose. It causes:

- Persistent pain in RIF
- Intestinal obstruction

Acute Intestinal Obstruction

It can occur after appendicectomy due to adhesions. Initially may be paralytic, but later on may become mechanical. Obstruction may occur due to band development, but it is much less common than adhesions. It is seen in some studies occurring within 6 months and in 1% of cases.

Right Inguinal Hernia

It is a direct inguinal hernia. The incidence of hernia is three times greater than in a normal person. It occurs more in a lower right paramedian incision. It can be caused by injury to an iliohypogastric nerve or an ilioinguinal nerve, especially in the Rutherford Morison incision.

Pelvic Abscess

Nowadays it is reducing due to antibiotic coverage. It is characterized by:

- High spiking pyrexia.
- Tenesmus or discomfort at defecation
- Loose stools
- Tender mass on DRE
- Ultrasound and CT scans are diagnostic

Prophylaxis is, which is the best safeguard against hernia the small incision whenever it can be employed with equal safety and in the separation of the muscular layers without cutting them (McBurney).

Treatment

- If left untreated leads to generalized peritonitis.
- Transrectal drainage of pelvic abscess—DRE is done, and then push the closed sinus forceps in the pelvic abscess and the abscess is drained.

Mortality

In a survey of 8,651 appendectomies done in England and Wales in 1992, the mortality rate was 0.24%, and morbidity was 8%.

Postoperative Complications After Laparoscopic Appendicectomy

Inferior Epigastric Artery

It begins as a branch of the external iliac artery and ascends medially along the medial margin of the deep inguinal ring, pierces the fascia transversalis, and crosses the arcuate line, entering the rectus sheath and running upward between the rectus abdominis muscle and the posterior rectus sheath. To avoid injuring to these vessels, the trocars should be either in midline or lateral to the left rectus muscle.

Ascending Branch of Deep Circumflex Iliac Artery

The deep circumflex iliac artery arises as a branch of the external iliac artery opposite the origin of an inferior epigastric artery. It runs up and laterally near ASIS, it gives an ascending branch that runs upward between the internal oblique and transversus muscles, to avoid its injury to the tracer should be one finger breadth above ASIS.

JAYPEE BROTHERS

Bleeding

Aggressive dissection of the mesoappendix is usually responsible for bleeding. Careful and minimal dissection prevents bleeding. An additional trocar may be required to identify and grasp the bleeding vessel.

Leakage of Pus or Fecolith

It occurs when the appendix is distended with pus and inflamed; careful dissection and removal in an endobag prevents it. Remove the fecolith or pus immediately and irrigate and suck the field after removal of the appendix.

Big Stump is Left or Appendix is Incompletely Removed

It can cause recurrent appendicitis, so remove it.

Postoperative Abdominal Abscesses

Intra-abdominal abscess formation is three times more common after laparoscopic appendicectomy than after open appendicectomy.

POSTOPERATIVE CARE

The person in charge of the case should give instructions, and these should be followed. Not many people of the unit treat the patient. The postoperative care instructions should be written clearly. Any change in treatment should also be written and not be verbal. A surgeon must explain nurse on duty everything in detail.

- Nil orally for 24 hours, but sips of water can be given from the same evening.
- IV fluids for 24 hours.
- Oral fluid intake allowed by the next morning if no complication develops.
- Patient is allowed to be out of bed the same evening so as not to get deep vein thrombosis.
- Gastric suction is not advised in uncomplicated cases of acute appendicitis after smooth appendicectomy.
- A soft diet is started from the second postoperative day.
- In case of perforated appendicitis with generalized peritonitis, oral intake takes more time, so nasogastric suction is done till bowel sounds appear.
- *Antibiotic:*
  - In case of nonperforated acute appendicitis, antibiotic coverage is given for 36–48 hours after appendicectomy
  - In perforated appendicitis with or without generalized peritonitis, antibiotic coverage is given for 7–10 days. IV antibiotics are given until:
    - Patient becomes afebrile for 24 hours
    - While the blood count becomes normal
  - Peritoneal culture is not of much use, as by the time the culture reports come, the patient has recovered. Peritoneal culture is of use in the following conditions:
    - In an immunosuppressed patient
    - A patient who develops an abscess.

Postappendectomy checklist if the patient is unwell:
- Examine the wound for infection or abscess
- Per-rectal examination to rule out pelvic abscess
- Examine lungs to rule out lobar pneumonia
- Rule out pylephlebitis, liver abscess, subphrenic abscess, and pyelonephritis.

MNEMONICS

Introduction

The word "Mnemonic' is derived from the ancient Greek word, "Mnemonikos," meaning "of memory" or "relating to memory." It is also related to the Greek goddess of memory, "Mnemosyne." The mnemonic word was discovered by a Greek poet, Simonides, in 447 BC. According to the Oxford Dictionary mnemonic can be defined as a word, sentence, or poem used to help remember a rule, name, etc. Mnemonics help our memory to retain information and make it easy to remember. Mnemonics are used in medicine as instruments to remember medical knowledge for the long term. Various medical terms and facts that are difficult to remember can be remembered for a long time with the help of mnemonics. A mnemonic couplet to help students learn the names of cranial nerves has been in use in the United States since the mid-19th century.

- *Murphy's triad:*
  - *Mnemonic (Mn)*: PVP
    - P = Pain in abdomen
    - V = Vomiting
    - P = Pyrexia
- *Etiology of appendicitis (common causes)*:
  - *Mn:* DR SODA
    - D = Diet
    - R = Racial, familial, and geographical factors
    - S = Socioeconomical level
    - O = Obstruction of the appendix by fecalith and worms
    - D = Diseases of the cecum: Cancer, Crohn's disease, and tuberculosis
    - A = Abuse of purgative

JAYPEE BROTHERS

- *Alvarado scoring*:
  - M = Migrating RIF pain
  - A = Anorexia
  - N = Nausea, vomiting
  - T = Tenderness RIF
  - R = Rebound tenderness
  - E = Elevated temperature (>37.3°C)
  - L = Leukocytosis (>10 × 1,037.3 cells)
  - S = Shift to left (segmental neutrophils) (>75%)
- *Ochsner–Sherren regimen*:
  - *A* = Aspiration—Ryle's tube
  - *B* = Bowel care—no purgatives
  - *C* = Charts for pulse/temperature/BP/size of mass
  - *D* = Drugs, antibiotics
  - *E* = Exploration is avoided in the appendicular mass
  - *F* = Fluids, IV
- *Common differential diagnosis of acute appendicitis*:
  - *Mn*: PUNAM TRIPS MRCP
    - P = Perforated peptic ulcer
    - U = Ureteric colic
    - N = Nonspecific mesenteric lymphadenitis
    - A = Acute gastroenteritis
    - M = Mittelschmerz
    - T = Torsion of ovarian cyst
    - R = Regional ileitis
    - I = Intestinal obstruction
    - P = Pancreatitis
    - S = Salpingitis
    - M = Meckel's diverticulitis
    - R = Ruptured ectopic gestation
    - C = Cholecystitis, acute
    - P = Pyelonephritis, acute
- *Clinical features of carcinoid syndrome*:
  - *Mn:* DABAR
    - D = Diarrhea
    - A = Attack of bronchial asthma due to histamine
    - B = Increased borborygmi
    - A = Attack of flushing of the face, induced by alcohol
    - R = Reddish blue hue (cyanosis) due to histamine
- *Differential diagnosis of appendicular mass:*
  - *Mn:* TIC-T-TAC
    - T = TB (Ileocecal TB)
    - I = Ilial lymphadenitis
    - C = Crohn's disease
    - T = Tumor, carcinoma of cecum
    - T = Tumor, carcinoma of the ovary
    - A = Amoebic typhlitis, actinomycosis
    - C = Twisted ovarian cyst
- *Complications of appendicectomy:*
  - *Mn:* 2 PACIF
    - P = Portal pyemia
    - P = Paralytic ileus
    - A = Abscess, pelvic and intraperitoneal
    - A = Adhesions, postoperative
    - C = Complication of any operation, wound infection
    - C = Complication of any operation, hemorrhage
    - I = Intestinal obstruction, acute
    - I = Inguinal hernia, right
    - F = Fecal fistula
- Important signs of acute appendicitis:
  - *Mn:* Remember Best Teachers Certify MCH 2 2 2 2
    - R = Rebound tenderness
    - R = Rovsing sign
    - B = Bed shaking test of Bapat
    - B = Baldwin's test
    - T = Tenderness in RIF
    - T = Tenderness in DRE
    - C = Cope's psoas test
    - C = Cope's obturator test
    - M = Muscle guarding
    - C = Cough sign
    - H = Hyperesthesia in Sherren's triangle
- *Complications of acute appendicitis*:
  - *Mn:* GAPSAP
    - G = Generalized peritonitis
    - A = Appendicular abscess
    - P = Perforated appendix
    - S = Septicemia
    - A = Appendicular lump
    - P = Portal pyemia
- *Important tumors of the appendix*:
  - *Mn:* CAP
    - C = Carcinoid tumor
    - A = Adenocarcinoma
    - P = Pseudomyxoma peritonei (PMP)
- *Two layers of subcutaneous tissue in RIF*:
  - *c Mn:* CS (C comes before S as an alphabet)
    - C = Camper's superficial fatty layer
    - S = Scarpa's deep membranous layer
- *Names of three taenia coli*:
  - *Mn:* MOL
    - M = Taenia mesocolica
    - O = Taenia omentalis
    - L = Taenia libera

JAYPEE BROTHERS

Key points

Remember MAO Mnemonics, Murphy's triad, Alvarado scoring, and Ochsner–Sherren regimen.

SOME IMPORTANT QUESTIONS

Q1. All are true about the appendicular artery, *except*:
a. Supplies only appendix
b. Supplies the terminal ileum also
c. Is an end artery
d. Branch of the lower division of the ileocolic artery

Ans. b

Q2. The fold of Treves is:
a. The fold of mucous membrane projecting into the lumen to the rectum
b. The ilio-appendicular fold of the peritoneum
c. The fold of the mucous membrane around the papilla of water
d. The fold of the peritoneum over the inferior mesenteric vein

Ans. b

Q3. Diffuse peritonitis following appendicitis is usually seen:
a. When appendicular perforation occurs early (within 24 hours)
b. When perforation occurs late (after 24 hours)
c. Particularly in nonobstructive appendicitis
d. When antibiotics are withheld

Ans. a

Q4. "Ten horn" sign is a feature of:
a. Rectus muscle hematoma
b. Acute pancreatitis
c. Choledocholithiasis
d. Acute appendicitis

Ans. d

Q5. Which one of the following is a muscle-splitting incision?
a. Kocher's
b. Rutherford–Morrison
c. Pfannenstiel
d. Lanz

Ans. d

Q6. The most dangerous position of the appendix is:
a. Retrocecal
b. Paracolic
c. Pelvic
d. Retroperitoneal

Ans. c

Q7. Diffuse peritonitis following appendicitis is usually seen:
a. When appendicular perforation occurs early (within 24 hours)
b. When perforation occurs late (after 24 hours)
c. Particularly in nonobstructive appendicitis
d. When antibiotics are withheld

Ans. a

Q8. A 26-year-old male presented with a 4-day history of pain in the right-sided lower abdomen with frequent vomiting. The patient's general condition is fair, and clinically, a tender lump was felt in the right iliac fossa (RIF). The most appropriate management for this case would be:
a. Exploratory laparotomy
b. Immediate appendectomy
c. Ochsner–Sherren regimen
d. External drainage

Ans. c

Q9. The most common tumor occurring in the appendix:
a. Melanoma
b. Carcinoid tumor
c. Adenocarcinoma
d. Mucinous carcinoma

Ans. b

Q10. Grid-iron incision was first described by:
a. McArthur
b. Rutherford Morrison
c. Hamilton Bailey
d. Lanz

Ans. a

Q11. During appendectomy, if it is noticed that the base of the appendix is inflamed, then a further line of treatment is:
a. No appendectomy
b. No burying of stump
c. Hemicolectomy
d. Cecal resection

Ans. b

Q12. The recurrent appendicular artery is a branch of:
a. Ileocolic artery
b. Right colic artery
c. Middle colic artery
d. Posterior cecal artery

Ans. d

Q13. The appendicular artery is a branch of:
a. Ileocolic artery
b. Right colic artery
c. Middle colic artery
d. Posterior cecal artery

Ans. a

Q14. The most common site of the appendix:
a. Retrocecal
b. Preileal
c. Paracecal
d. Postileal

Ans. a

JAYPEE BROTHERS

Q15. The earliest symptom in acute appendicitis is:
a. Pain
b. Fever
c. Vomiting
d. Rise in pulse rate

Ans. a

Q16. McBurney's point:
a. Lies in the middle of the right spine umbilical line
b. At the junction of the lateral two-thirds and medial one-third of line
c. At the junction of the lateral one-third and the medial two-thirds of line
d. Lies at the umbilicus-liver junction

Ans. c

Q17. The following signs are not seen in acute appendicitis, *except*:
a. Rovsing's sign
b. Murphy's sign
c. Boa's sign
d. Macewen's sign

Ans. a

Q18. Rovsing's sign is seen in:
a. Acute appendicitis
b. Acute cholecystitis
c. Pancreatitis
d. None of the above

Ans. a

Q19. The pointing index sign is seen in:
a. Acute appendicitis
b. Acute pancreatitis
c. Perforated duodenal ulcer
d. Acute cholecystitis

Ans. a

Q20. A gridiron incision becomes a Rutherford–Morrison incision when the incision is extended by:
a. Splitting the muscle laterally
b. Cutting the muscles laterally
c. Cutting the muscles medially into the rectus sheath
d. Incising vertically along the rectus muscle

Ans. b

Q21. The most common initiating factor in acute appendicitis is: (JIPMER GIS 2011)
a. Luminal obstruction
b. Bacterial infection
c. Lymphoid hyperplasia
d. Perforation

Ans. a

Q22. All of the following signs are not seen in acute appendicitis, *except*:
a. Rovsing's
b. Murphy's
c. Boa's sign
d. Macewen's sign

Ans. a

Q23. False about appendicitis in children:
a. Localized pain is the single most important symptom
b. Vomiting precedes abdominal pain
c. Perforation occurs in 80% of cases <5 years
d. 60% of perforation occurs within 48 hours

Ans. b

Q24. Which of the following statements is not true of McBurney's incision?
a. Most suitable if the diagnosis of appendicitis is definite
b. It is it converted into a muscle-cutting incision, it is called Rutherford Morrison's incision
c. Inguinal hernia is a sequelae of the incision
d. The incision can be extended upwards and downwards

Ans. d

Q25. Treatment of choice for mucinous adenocarcinoma of the appendix:
a. Right hemicolectomy
b. Appendicectomy
c. Percutaneous aspiration
d. Total colectomy

Ans. a

Q26. When the rectum is inflated with air through a rectal tube, pain, and tenderness occur in the RIF in case of appendicitis. This is known as:
a. Aaron's sign
b. Battle's sign
c. Bastedo sign
d. McBurney's sign

Ans. c

Q27. The frequent mechanism in perforation of the appendix is:
a. Impacted fecolith
b. Tension gangrene due to the accumulating secretions
c. Necrosis of the lymphoid patch
d. Retrocecal infection

Ans. b

JAYPEE BROTHERS

Q28. Aaron's sign is seen in:
a. Achalasia cardia
b. Hiatus hernia
c. Mediastinum emphysema
d. Acute appendicitis

Ans. d

Q29. Regarding appendicitis in pregnancy, false is:
a. Most common cause of acute abdomen in the first trimester
b. Pregnancy does not increase the risk
c. Conservative management by antibiotics should be tried
d. After rupture, fetal mortality is around 30–40%

Ans. c

Q30. Treatment of choice for mucinous adenocarcinoma of the appendix:
a. Right hemicolectomy
b. Appendectomy
c. Percutaneous aspiration
d. Total colectomy

Ans. a

Q31. Mark the correct statement about inflammatory bowel disease (IBD):
1. Crohn's disease has skip lesions
2. Childhood IBD is genetic
3. Crohn is mucosal and ulcerative colitis (UC) is transmural
4. Crohn is curable fully

a. 2, 3 are correct
b. 1 and 2 are correct
c. 1, 2, 3 are correct
d. All are correct

Ans. b

Q32. Which of the following statements is not true of McBurney's incision?
a. Most suitable if the diagnosis of appendicitis is definite.
b. If it is converted into a muscle-cutting incision, it is called Rutherford–Morrison incision.
c. Inguinal hernia is a sequelae of the incision.
d. The incision can be extended upward or downward.

Ans. c

Q33. All are true about appendicular rupture, *except*:
a. Common in low socioeconomic status people
b. Common in extremes of age
c. Early antibiotics prevent perforation
d. Appendicectomy done even in the presence of rupture

Ans. d

Q34. All of the following are early complications arising after appendicectomy for acute appendicitis, *except*:
a. Ileus
b. Sterility
c. Intestinal obstruction
d. Pulmonary complications

Ans. b

Q35. Ochsner–Sherren regimen is used in the management of:
a. Appendicular abscess
b. Chronic appendicitis
c. Appendicular mass
d. Acute appendicitis

Ans. c

Q36. Mucocele of the appendix is:
a. Benign tumor
b. Low-grade malignancy
c. Retention cyst
d. Infective process

Ans. c

Q37. The most common site of carcinoids is:
a. Ileum
b. Liver
c. Rectum
d. Appendix

Ans. d

Q38. Carcinoid of which site is least likely to be malignant?
a. Appendix
b. Stomach
c. Small intestine
d. Lung

Ans. a

Q39. The most common tumor of the appendix is:
a. Argentaffinoma
b. Lymphoma
c. Leiomyosarcoma
d. Adenocarcinoma

Ans. a

Q40. Surgery for carcinoid tumor of the appendix:
a. Right hemicolectomy
b. Appendicectomy
c. Limited resection of the right colon
d. Right hemicolectomy with removal of inches of the ileum also

Ans. b

JAYPEE BROTHERS

Q41. What is "peritoneal mice"?
a. Pseudomyxoma peritonei
b. Appendices epiploicae
c. Peritoneal seedings of the tumor
d. Endometriosis

Ans. b

Q42. Epidemic appendicitis is due to:
a. Fecalith
b. Worms of the ileocecal region
c. Streptococcal infections
d. Abuse of purgatives
e. None of the above

Ans. c

Q43. The frequent mechanism in the perforation of the appendix is:
a. Impacted fecalith
b. Tension gangrene due to accumulated secretions
c. Necrosis of lymphoid tissue
d. Carcinoid tumor

Ans. b

MULTIPLE CHOICE QUESTIONS

Grade I	*Simple*

Q1. Most common organism isolated from perforated appendicitis: (AIIMS GIS May 2008)
a. *E. coli* b. *Pseudomonas*
c. *Klebsiella* d. *Enterococcus*

Q2. When acute appendicitis is suspected, it can be confirmed by: (PGI JUNE 2002)
a. Clinical examination
b. Ultrasound (USG)
c. Computed tomography (CT) scan
d. Blood counts
e. Upper gastrointestinal (GI) endoscopy

Q3. A patient with Crohn's disease was opened for and an inflamed appendix was found. The treatment of choice is: (PGI 1988)
a. Appendicectomy
b. Ileocolic resection and anastomosis
c. Close the abdomen and start medical treatment
d. None of the above

Q4. The most common neoplasm of the appendix is: (AIIMS NOV 1993)
a. Lymphoma b. Adenocarcinoma
c. Leiomyosarcoma d. Argentaffinoma

Q5. Mucocele of the appendix is: (All India 1989)
a. Benign tumor b. Low-grade malignancy
c. Retention cyst d. Infective process

Q6. In the case of retrocecal appendicitis, which movement aggravates pain? (AIIMS Nov 2007)
a. Flexion b. Fever
c. Medical rotation d. Lateral rotation

Q7. Acute appendicitis is due to: (AIIMS 1990)
a. Fecolith
b. Worms of the ileocecal region
c. Streptococcal infections
d. Abuse of purgative
e. None of the above

Q8. Which of the following is a muscle-splitting incision? (AIIMS Nov 2016)
a. Kocker's incision
b. Lanz incision
c. Rutherford–Morrison incision
d. Pfannenstiel incision

Q9. The commonest anatomical position of the appendix is: (Karnataka 2013)
a. Retrocecal b. Pelvic
c. Paracecal d. Prelieal

Q10. Rovsing sign is seen in: (PGI 1995)
a. Acute appendicitis b. Acute cholecystitis
c. Pancreatitis d. None

Grade II	*Difficult*

Q1. True statement about appendix: (PGI June 2006)
a. Does not have mesentery
b. Has taenia coli
c. Develops from midgut
d. Supplied by an appendicular branch of the ileocolic artery

Q2. Appendicitis is diagnosed by: (PGI JUNE 2003)
a. Total leukocyte count (TLC) and differential leukocyte count (DLC)
b. X-ray abdomen
c. USG
d. Color Doppler
e. Ba enema

Q3. True about appendicular rupture is A/E: (PGI DEC 1999)
a. Common in extremes of age
b. Common in people with fecalith obstruction

JAYPEE BROTHERS

c. Early antibiotics prevent rupture
d. Appendicectomy is done always in the presence of a rupture

Q4. In a case of retrocecal appendicitis, which movement aggravates pain: (AIIMS NOV 2007)
a. Flexion
b. Extension
c. Medial rotation
d. Lateral rotation

Q5. A 26-year-old male presented with a 4-day history of pain in the right-sided lower abdomen with frequent vomiting. Patient's general condition is fare and clinically a tender lump was felt in the RIF. Most appropriate management for this case would be: (MCI March 2010)
a. Exploratory laparotomy
b. Immediate appendectomy
c. Ochsner–Sherren regimen
d. External drainage

Q6. The most common tumor occurring in the appendix: (JIPMER 2010)
a. Melanoma
b. Carcinoid tumor
c. Adenocarcinoma
d. Mucinous carcinoma

Q7. A pregnant female presents with pain in the abdomen on examination, tenderness is found in the right lumbar region. TLC is 12,000/mm^3, and urine examination is normal, for diagnosis further tests done is: (AIIMS June 1999)
a. Chest X-ray with abdominal shield
b. Ultrasound abdomen
c. Noncontract CT abdomen
d. Laparoscopy

Q8. Investigation of choice for acute appendicitis in children: (AIIMS May 2015)
a. CT scan
b. MRI
c. USG
d. X-ray

Q9. What is the treatment of a patient with a carcinoid tumor of the appendix of size >2 cm? (AIIMS June 1999)
a. Right hemicolectomy
b. Appendectomy
c. Appendectomy + Abdominal CT scan
d. Appendectomy + 24-hour urinary 5-hydroxyindoleacetic acid (HIAA)

Q10. The nerve commonly damaged during McBurney's incision is: (All India 2003)
a. Subcostal
b. Iliohypogastric
c. 11th thoracic
d. 10th thoracic

Grade III	*Most difficult*

Q1. During appendectomy, if it is noticed that the base of the appendix is inflamed, then a further line of treatment is: (PGI 1996)
a. No appendicectomy
b. No burying of stump
c. Hemicolectomy
d. Cecal resection

Q2. What is the T/t of patient with a carcinoid tumor of the appendix of size >2 cm? (AIIMS JUNE 1999)
a. Right hemicolectomy
b. Appendicectomy
c. Appendicectomy + abdominal CT scan
d. Appendicectomy + 24 hours urinary HIAA

Q3. Treatment of an incidentally detected appendicular carcinoid measuring 2.5 cm is: (MCI March 2009)
a. Right hemicolectomy
b. Limits the resection of the right colon
c. Total colectomy
d. Appendectomy

Q4. A young boy presented to the casualty with a history of fever, abdominal pain, and vomiting. On examination, he was febrile with a pulse rate of 104/min. The resident was eliciting the sign shown below. Identify the sign. (AIIMS May 2017)
a. Rovsing's sign
b. Balance sign
c. McBurney's point tenderness
d. Psoas sign

Q5. All are useful in acute appendicitis, *except*: (Kerala 1994)
a. Antibiotics
b. Analgesics
c. Intravenous (IV) fluids
d. Purgation

Q6. All are to be done in case of a 20-year-old female coming to casualty with right iliac fossa pain, with local guarding and tenderness, *except*: (AIIMS Nov 1999)
a. IV glucose
b. Pethidine 100 mg intramuscular (IM)
c. Nil orally
d. X-ray abdomen

Q7. False about appendicitis in children: (JIPMER 2011)
a. Localized pain is the single most important symptom

JAYPEE BROTHERS

b. Vomiting precedes abdominal pain
c. Perforation occurs in 80% of cases <5 years
d. 60% perforation occurs within 48 hours

Q8. Most common occurrence before appendicitis: (PGI Nov 2011)

a. Blockage of the lumen
b. Ileitis
c. Gastroenteritis
d. Perforation

Q9. A pregnant female presents with pain in the abdomen on examination, tenderness is found in the right lumbar region. TLC is 12,000/mm^3, and urine examination is normal. For diagnosis, further tests are done is: (AIIMS June 1999)

a. Chest X-ray with abdominal shield
b. Ultrasound abdomen
c. Noncontrast CT abdomen
d. Laparoscopy

Q10. A 25-year-old patient presented with a mass in the right iliac fossa, which, after laparotomy, was found to be a carcinoid of 2.5 cm in diameter. What will be the next step in management? (AIIMS Nov 2000)

a. Segmental resection
b. Appendectomy
c. Right hemicolectomy
d. Do a yearly 5-HIAA assay

ANSWERS

Grade I: 1. a; 2. a, b, c, d (Bailey 27/e p1307); 3. a (Bailey 27/e p1308); 4. b (Bailey 26/e p1213); 5. a, b, c (Sabiston 20/e p1308); 6. b (Bailey 27/e p1304); 7. a; 8 b; 9. a; 10. a

Grade II: 1. c (Sabiston 20/e p1296); 2. a, c (Bailey 27/e p1307); 3. c (Schwartz 10/e p1250-51); 4. b (Bailey 27/e p1304); 5. c; 6. d; 7. b; 8. c; 9. a; 10. b (Bailey 25/e p1213)

Grade III: 1. b (Sabiston 20/e p1300); 2. a; 3. a; 4. c (Schwartz 10/e p1244); 5. d (Bailey 27/e p1308); 6. None (Harrison 16/e p84); 7. b (Bailey 27/e p1303); 8. a; 9. b; 10. c (Bailey 27/e p1315)

MODEL QUESTIONS

Q1. The earliest symptoms in acute appendicitis are:

a. Pain
b. Fever
c. Vomiting
d. Rise of pulse rate

Ans. a

Q2. A patient with Crohn's disease was opened, and an inflamed appendix was found. The treatment of choice is:

a. Appendectomy
b. Ileocolic resection and anastomosis
c. Close the abdomen and start medical treatment
d. None of the above

Ans. a

Q3. The most common organism isolated from perforated appendicitis:

a. *Escherichia coli*
b. *Pseudomonas*
c. *Klebsiella*
d. *Enterococcus*

Ans. a

Q4. A 15-year-old boy is admitted with a history and physical finding consistent with appendicitis. Which of the following findings is most likely to be positive?

a. Pelvic crepts
b. Iliopsoas sign
c. Murphy's Sign
d. Flank ecchymosis

Ans. b

Q5. In appendicitis, the initial periumbilical pain is eventually localized to the right iliac fossa because of:

a. Peritoneum
b. Iliopsoas
c. Colon
d. Cecum

Ans. a

Q6. Which of the following organisms produces signs and symptoms that mimic acute appendicitis?

a. Enteropathic *Escherichia coli*
b. *Enterobius vermicularis*
c. *Trichomonas hominis*
d. *Yersinia enterocolitica*

Ans. d (Sabiston 20/e p1105)

Q7. The Alvarado score consists of:

a. Leucopenia
b. Anorexia
c. Diarrhea
d. Periumbilical pain

Ans. b

JAYPEE BROTHERS

Q8. The most common differential diagnosis for appendicitis:
a. Gastroenteritis
b. Mesenteric lymphadenopathy
c. Intussusception
d. Meckel's diverticulitis

Ans. b

Q9. Which is the best test for the diagnosis of acute appendicitis in a pregnant female?
a. Alder's test
b. Aaron's test
c. Angell's test
d. McBurney's test

Ans. a

Q10. Which of the following is true about the appendicular mass is all, *except*?
a. Ochsner-Sherren regimen followed
b. Develops after 72 hours
c. Fever is present
d. Operation is to be done immediately

Ans. d

Q11. Grid-iron incision was first described by:
a. McArthur
b. Rutherford Morrison
c. Hamilton Bailey
d. Lanz

Ans. a (Bailey 27/e p1309)

Q12. Which of the following statements is now true of McBurney's incision?
a. Most suitable if the diagnosis of appendicitis is definite
b. If it is converted into a muscle-cutting incision, it is called Rutherford's Morison's incision
c. Inguinal hernia is a sequele of the incision
d. The incision can be extended upwards or downwards

Ans. d (Bailey 27/e p1309)

Q13. A Gridiron incision becomes a Rutherford Morison's incision is extended by:
a. Splitting the muscles laterally
b. Cutting the muscles laterally
c. Cutting the muscles medially into the rectus sheath
d. Incising vertically along the rectus muscle

Ans. b

Q14. Which one of the following is a muscle-splitting incision?
a. Kocher's
b. Rutherford-Morrison
c. Pfannenstiel
d. Lanz

Ans. d

Q15. An appendicular fistula is least likely to heal if:
a. The stump was sutured with Vicryl
b. There is stenosis/narrowing of the sigmoid colon
c. Superadded infection
d. None

Ans. b (Sabiston 20/e p1287)

Q16. Fecal fistula after appendectomy may occur due to:
a. Adhesions
b. Gangrenous appendicitis
c. Undiagnosed ileocecal disease
d. Postoperative infection

Ans. c (Bailey 27/e p1314)

Q17. Incision at McBurney's point corresponds to:
a. Tip of the appendix
b. Base of appendix
c. Midpoint of the appendix
d. Base of the cecum

Ans. b

Q18. All are true about the appendicular artery, *except*:
a. Supplies only appendix
b. Supplies the terminal ileum also
c. Is an end artery
d. Branch of the lower division of the ileocolic artery

Ans. b (Sabiston 20/e p1296)

Q19. The fold of Treves is:
a. The fold of the mucous membrane projecting into the lumen of the rectum.
b. The ilio-appendicular fold of the peritoneum.
c. The fold of the mucus membrane around the papilla of water.
d. The fold of peritoneum over the inferior mesenteric vein.

Ans. b (Sabiston 20/e p1296)

Q20. The Malone procedure is used in:
a. Anorectal incontinence
b. Urinary incontinence

JAYPEE BROTHERS

c. Neurogenic bladder
d. Gastroesophageal reflux disease (GERD)

Ans. a (Bailey 27/e p137)

Q21. The most common anatomical position of the appendix is:
a. Retrocecal
b. Pelvic
c. Paracecal
d. Preileal

Ans. a

Q22. The frequent mechanism in perforation of the appendix is:
a. Impacted fecolith
b. Tension gangrene due to the accumulating secretions
c. Necrosis of the lymphoid patch
d. Retrocecal infection

Ans. b

Q23. Acute appendicitis is characterized by all of the following, *except*:
a. Anorexia
b. Rovsing's sign
c. Fever >42°C
d. Periumbilical colic

Ans. c

Q24. A 15-year-old boy is admitted with a history and physical finding consistent with appendicitis. Which of the following findings is most likely to be positive?
a. Pelvic crepts
b. Iliopsoas sign
c. Murphy's sign
d. Flank ecchymosis

Ans. b

Q25. True about the appendicular mass is all, *except*:
a. Ochsner–Sherren regime followed
b. Develops after 72 hours
c. Fever is present
d. Operation is to be done immediately

Ans. d

Q26. A Gridiron incision becomes a Rutherford Morison's incision is extended by: **(Karnataka 1994)**
a. Splitting the muscle laterally
b. Cutting the muscle laterally
c. Cutting the muscle medially into the rectus sheath
d. Incising vertically along the rectus muscle

Ans. b

Q27. A 25-year-old patient presented with a mass in the RIF. Which, after laparotomy, was found to be a carcinoid of 2.5 cm in diameter. What will be the next step in management?
a. Segmental resection
b. Appendectomy
c. Right hemicolectomy
d. Do a yearly 5-HIAA assay

Ans. c

Q28. A 25-year-old man presents with a 3-day history of pain in the right lower abdomen and vomiting. The patient's general condition is satisfactory, and clinical examination reveals a tender lump in the RIF. The most appropriate management in this case would be:
a. Immediate appendectomy
b. Exploratory laparotomy
c. Ochsner–Sherren regimen
d. External drainage

Ans. c

Q29. Best treatment option for appendicular lymphoma:
a. Right hemicolectomy
b. Chemotherapy
c. Right hemicolectomy + chemotherapy
d. None

Ans. c

Q30. ALVARADO score 2 defines:
a. Temperature
b. Leukocytosis
c. Tenderness in LIF
d. Migratory pain

Ans. b

Q31. A 25-year-old female who had pain in the RIF with vomiting was managed conservatively. He was stable for 2 days, after which he had worsening of symptoms, for which extraperitoneal drainage was done by USG guidance. What is the diagnosis?
a. Perinephric abscess
b. Appendicular abscess
c. Ruptured ectopic
d. Acute cholecystitis

Ans. b

Q32. The lady is in the first trimester of pregnancy and presents to the ER with acute abdominal pain. She is diagnosed with acute appendicitis. The next step in the management will be:

JAYPEE BROTHERS

a. Terminate the pregnancy
b. Give antibiotics and wait till the second trimester
c. Do appendectomy
d. Wait and watch

Ans. c

Q33. What do you do for a 2.5 cm carcinoid in the appendix?

a. Right hemicolectomy
b. Appendicectomy with yearly CT scan
c. Total colectomy with ileoanal pouch anastomosis
d. Limited colonic resection with adjuvant chemotherapy

Ans. a

Q34. In an incidental diagnosis of carcinoid of the appendix covering an area of 2.5 cm, the line of action will be:

a. Appendicectomy
b. Appendicectomy with yearly follow-up of 24 hours, estimation of HIAA
c. Appendicectomy along with right hemicolectomy
d. Appendicectomy and annual CT scan

Ans. c

Q35. When the rectum is inflated with air through a rectal tube, pain, and tenderness occur in RIF in case of appendicitis. This is known as:

a. Aaron's sign
b. Battle sign
c. Bastede's sign
d. McBurney's sign

Ans. c

Q36. All of the following are parts of prolonged antibiotic therapy in intra-abdominal sepsis, *except*:

a. Masking of general signs
b. Subacute intestinal obstruction
c. Malignant change
d. Frozen pelvis

Ans. c

Q37. Odorless peritoneal fluid is noticed in:

a. Perforated peptic ulcer
b. Perforated ileum
c. Perforated appendix
d. Tuberculosis (TB) peritonitis

Ans. a

Q38. All are useful in acute appendicitis, *except*:

a. Antibiotics
b. Analgesics
c. IV fluids
d. Purgative

Ans. d

SUGGESTED READING

1. A handbook of Appendix, Vinod Kumar Nigam, Siddharth Nigam, 1st edition.
2. Bailey & Love's - Short Practice of Surgery, 27th edition.
3. Schwartz's Principles of Surgery, 18th edition.

JAYPEE BROTHERS

for detailed information on surgery books, visit our website www.ejaypee.com, for detailed information on surgery books, visit our website www.ejaypee.com, for detailed information on s

MCQs in SURGERY

An Ultimate Solution for the Super Speciality Exam in Surgery

This book provides knowledge in understandable and required details to prepare the candidate well without wasting time. It has updated knowledge based on the latest examination of NEET and superspeciality entrance for surgery. It has the required lined diagrams, colored images, tables, and flowcharts which are essential for these exams. It is a complete MCQs book for surgery and its main purpose is to give success to the candidates after studying it.

The special features of the book which are unique

- How to increase your retention while preparing for exams?
- Mnemonics
- Pomodoro method of studying
- How to prepare for these entrance exams?
- How to attempt the entrance exam paper?
- How to keep healthy and avoid anxiety and stress during exam preparations?
- How to be motivated and have a positive attitude?
- What should be the daily routine during preparations for these entrance exams?

Vinod Kumar Nigam MBBS MS FICS FIAGES is an Associate Director, Department of General and Minimal Access Surgery, Max Hospital, Gurugram, Haryana, India. He is the Author of three books, *Essentials of Abdominal Wall Hernias*, a surgical textbook, a bestseller *40 Minutes with God*, which deals with the scientific basis of healing through prayers, faith and meditation, and *An Introduction to History of Medicine*, which gives a detailed account of the history of medicine. He received his training in Gastrointestinal Endoscopy at AIIMS, New Delhi, India. He received his training in Laparoscopic Surgery at Ninewells Hospital, Dundee, Scotland, UK, under Professor Alfred Cuschieri, one of the Pioneers of Laparoscopic Surgery. He is also the Inventor of two operative techniques in general surgery: "Window Operation" for hydrocele and "NICH—Nigam's Inverted Curtain Hernioplasty" for inguinal hernia repair. He has published a number of papers in various national and international journals of repute. He has presented papers at various national and international conferences and has also been invited as Faculty. He also writes a Blog "40 Minutes with God" on www.speakingtree.in.

Siddharth Nigam MBBS MS FIAGES FALS (Robotic) is a Senior Consultant, Department of General and Minimal Access Surgery, Max Hospital, Gurugram, Haryana, India. He is also the Co-Author of three books, *Essentials of Abdominal Wall Hernias*, *40 Minutes with God* and *An Introduction to History of Medicine*. He is the inventor of a surgical technique for Inguinal Hernia, "NICH". He has presented various papers at national and international conferences in the field of general surgery.

Buy from ejaypee

JAYPEE BROTHERS

Shelving Recommendation
SURGERY

ISBN 978-93-6616-115-0