rothers.com, for detailed information on ophthalmology books, visit our website www.jaypeebrothers.com, for detailed information on ophthalmology books

OPHTHALMOLOGY CLINICS-2

for Postgraduates

Basic Sciences
Instruments
Investigations
Imaging
Interpretation & Viva Voice

Prafulla Kumar Maharana
Namrata Sharma
Atul Kumar

2nd Edition

JAYPEE

Contents

SECTION 1 Appliances and Instruments

1. Oculoplasty and Orbital Imaging 3

1.1 **Exophthalmometry** 3
Pallavi Singh, Siddhi Goel

1.2 **Orbital Imaging Techniques** 7
Sanjay Sharma, Savinay Kapur

1.3 **A Pattern-based Approach to Radiologic Diagnosis in Ophthalmology: Part I** 15
Sanjay Sharma, Savinay Kapur

1.4 **A Pattern-based Approach to Radiologic Diagnosis in Ophthalmology: Part II** 23
Sanjay Sharma, Savinay Kapur

1.5 **Ultrasonography** 31
Asha Samdani, Aditi Dubey

1.6 **Appliances and Instruments in Oculoplasty** 44
Saloni Gupta, Sahil Agrawal, Pranita Sahay

2. Cornea 56

2.1 **Slit-Lamp Biomicroscopy** 56
Rinky Agarwal, Sitesh Kumar Bergaal, Ritu Nagpal, Namrata Sharma

2.2 **Keratometer** 68
Ritu Nagpal, Siddhi Goel, Shipra Singhi, Prafulla Kumar Maharana

2.3 **Pentacam** 72
Prafulla Kumar Maharana, Siddhi Goel, Abhipsa Sharma, Pranita Sahay, Anin Sethi, Jeewan Singh Titiyal

2.4 **Aberrometers** 88
Prafulla Kumar Maharana, Deepali Singhal, Aafreen Bari, Siddhi Goel

2.5 **Anterior Segment Optical Coherence Tomography** 99
Sourabh Verma, Talvir Sidhu, Deepali Singhal, Manasi Tripathi, Namrata Sharma

2.6 **Specular Microscope** 112
Manasi Tripathi, Pranita Sahay, Mohamed Ibrahime Asif, Divya Agarwal, Prafulla Kumar Maharana

2.7 **Ultrasonic Pachymeter** 122
Pranita Sahay, Mohamed Ibrahime Asif, Manasi Tripathi, Namrata Sharma

2.8 **Orbscan** 127
Alisha Kishore, Pranita Sahay, Ritu Nagpal

2.9 **Corneal Biomechanics** 135
Ritu Nagpal, Chandradevi Shanmugam

2.10 **Appliances and Instruments in Cornea** 142
Pranita Sahay, Mohamed Ibrahime Asif, Devesh Kumawat, Namrata Sharma

3. Cataract 153

3.1 Intraocular Lens Master 153
Deepali Singhal, Alisha Kishore, Arpit Sharma, Prafulla Kumar Maharana

3.2 LenStar 159
Yogita Gupta, Deepali Singhal, Prafulla Kumar Maharana

3.3 A-Scan 162
(Surg Capt) Srujana D, Mohamed Ibrahime Asif, Pranita Sahay, Ritu Nagpal

3.4 Appliances and Instruments in Cataract Surgery 166
Pranita Sahay, Prafulla Kumar Maharana

4. Retina and Uvea 176

4.1 Ophthalmoscope 176
Alisha Kishore, Hannah Shiny R, Suman Meena, Pranita Sahay

4.2 Fundus Fluorescein Angiography 182
Nasiq Hasan, Priyanka, Brijesh Takkar, Rohan Chawla, Atul Kumar

4.3 Optical Coherence Tomography 192
Priyanka Ramesh, Nawazish Shaikh, Nasiq Hasan, Aayush Majumdar, Atul Kumar

4.4 Indocyanine Green Angiography 202
Anusha Sachan, Nasiq Hasan, Atul Kumar

4.5 Electroretinogram 204
Sourabh Verma, Lohith Rambarki, Divya Agarwal

4.6 Multispot Laser System 212
Anusha Sachan, Brijesh Takkar, Amber Bhayana

4.7 Adaptive Optics 215
Anusha Sachan, Divya Agarwal, Rohan Chawla

4.8 Amsler Grid 218
Ankit Singh Tomar, Saurabh Verma, Atul Kumar

4.9 Vitreoretinal Instruments 221
Devesh Kumawat, Pranita Sahay, Anusha Sachan, Atul Kumar

4.10 Optical Coherence Tomography Angiography 227
Aayush Majumdar, Nawazish Shaikh, Saurabh Verma

4.11 Ultra-Widefield Imaging 237
Aayush Majumdar, Nawazish Shaikh, Saurabh Verma

5. Glaucoma 245

5.1 Gonioscopy 245
Talvir Sidhu, Tanuj Dada

5.2 Tonometry 256
Jyoti Shakrawal, Talvir Sidhu, Shahnaz Anjum

5.3 Optic Nerve Head Evaluation 264
Talvir Sidhu, Mohit Goyal, Tanuj Dada

5.4 Perimetry Part 1: Kinetic Perimetry—Goldmann Visual Field 274
Jyoti Shakrawal, Talvir Sidhu, Nikita Gupta

5.5 Perimetry Part 2: Static Perimetry—Humphrey Visual Field 280
Talvir Sidhu, Jyoti Shakrawal, Harika Regani, Tanuj Dada

5.6 Ultrasound Biomicroscopy and Anterior Segment Optical Coherence Tomography in Glaucoma 296
Talvir Sidhu, Saurabh Verma, Tanuj Dada

5.7 Optical Coherence Tomography In Glaucoma— Interpretation 302
Talvir Sidhu, Jyoti Shakrawal, Ritu Nagpal, Tanuj Dada

5.8 Heidelberg Retina Tomograph 318
Gaurav Garg, Jyoti Shakrawal

5.9 Instruments Used in Glaucoma Surgeries 326
Vatsalya Venkatraman, Pranita Sahay, Jyoti Shakrawal

6. Squint and Neuro-Ophthalmology 330

6.1 Hess Chart/Lees Screen 330
Ritu Nagpal, Mousumi Bannerjee, Anin Sethi, Pallavi Singh

6.2 Synoptophore 337
Pallavi Singh, Vatika Jain, Pranita Sahay

6.3 Tests for Binocular Vision and Stereopsis 342
Pallavi Singh, Shreya Nayak, Pranita Sahay

6.4 Instruments for Squint Surgery 351
Pranita Sahay, Devesh Kumawat, Divya Agarwal, Karthika Bhaskaran

SECTION 2 Basic Sciences

7. Pathology Basics 359
Seema Kashyap, Siddhi Goel, Suman Lata, Prafulla Kumar Maharana

8. Ocular Microbiology 375
Siddhi Goel, Nishat Hussain Ahmed, Geeta Satpathy

9. Community Ophthalmology 384

9.1 Blindness: Definition, Burden, Prevention, and Rehabilitation 384
Vivek Gupta, Pallavi Shukla, Suraj S Senjam, Meenakshi Wadhwani, Praveen Vashist

9.2 Survey Methods in Ophthalmology 395
Vivek Gupta, Meenakshi Wadhwani, Praveen Vashist, Suraj S Senjam

SECTION 3 Interpretation of Images and Reports

10. Interpretation of Images 405
Pranita Sahay, Jyoti Shakrawal, Gunjan Saluja, Siddhi Goel

Index 429

SECTION 2

Basic Sciences

7. Pathology Basics
8. Ocular Microbiology
9. Community Ophthalmology

JAYPEE BROTHERS

CHAPTER 7

Pathology Basics

Seema Kashyap, Siddhi Goel, Suman Lata, Prafulla Kumar Maharana

JAYPEE BROTHERS

INTRODUCTION

Histopathological examination of the tissue specimen is vital to know the disease process affecting the different ocular structures. It is essential to be aware of the basic histopathology of the essential structures of the eye. It is often an essential component of postgraduate and fellowship examinations.

This chapter deals with a few fundamental aspects of ocular histopathology and examples of common clinical conditions where histopathology plays a vital role in diagnosis, management, and prognostication of cases.

COMMON FINDINGS IN PATHOLOGY

The following components are typically seen in the presence of any disease process:[1]

Polymorphonuclear Leukocytes

Polymorphonuclear leukocytes are characterized by:

- A typical multilobulated nucleus
- Abundant eosinophilic cytoplasm
- Occasionally, intracytoplasmic granules which are nothing but proteolytic enzymes

Mast Cells

Mast cells are characterized by:

- Single nucleus
- Bigger than the polymorphonuclear leukocytes
- Intracytoplasmic pink and red granules (characteristic)
- These granules contain heparin, histamine, and prostaglandins.
- Important mediators of allergic conjunctivitis reactions

Lymphocytes

Lymphocytes are characterized by:

- A very large dark staining nucleus with scanty cytoplasm
- Condensed coarse chromatin
- Play an important role in chronic inflammation and autoimmune disorders

Plasma Cells

Plasma cells are characterized by:

- These are modified altered B lymphocytes
- These are oval in shape
- The nucleus is eccentric with a cartwheel or "clockface arrangement" (nucleus is at one pole of the cell)
- Abundant amphophilic cytoplasm
- A paranuclear pale area is characteristic
- Produce antibodies

GRANULOMATOUS REACTION

A granulomatous reaction usually occurs in response to some chronic low-grade infections (such as tuberculosis or aspergillosis) or a foreign body or chronic uveitis (sarcoidosis).

The inflammatory cells primarily consist of macrophages, lymphocytes, and plasma cells. One of the characteristic features is the formation of epithelioid cell granulomas along with multinucleated giant cells.[1]

PYOGENIC GRANULOMA

- Clinically a pyogenic granuloma is characterized by a fleshy, granular, red mass primarily in the conjunctiva. Unlike the name suggests, it does not contain any pus, hence a misnomer.
- Histopathologically, it is a lobulated lesion with a rich, vascular network within a loose fibrous connective tissue along with inflammatory cells. Surface is often ulcerated.[1]

NEOPLASIA

The different types of changes seen are:[1]

- *Hypertrophy:* Increase in size of cells
- *Hyperplasia:* Increase in the number of cells
- *Hyperkeratosis:* Hyperkeratosis, generally, refers to a thickening of the keratin-containing outer layer of the skin. In the eye, there is thickening of the conjunctiva.
- *Parakeratosis:* Retention of the nucleus in superficial layers of skin or conjunctiva.
- *Metaplasia:* It is the transformation of one cell type to another cell type.
- *Examples:*
  - *Keratinization of ocular surface:* In Stevens–Johnson syndrome (SJS), ocular cicatricial pemphigoid (OCP), and severe dry eye, the columnar epithelium of conjunctiva is transformed into the stratified squamous keratinized epithelium.
  - Metaplasia of retinal pigment epithelium (RPE) in proliferative vitreoretinopathy (PVR)
  - Metaplasia of lens epithelium after cataract or posterior capsular opacification (PCO)
- *Dysplasia:* It is an abnormal proliferation of atypical squamous epithelial cells of the conjunctiva. They are classified as mild, moderate, or severe dysplasia depending on the thickness involved. When it involves the entire thickness of the epithelium without any breach in the underlying basement membrane, it is called as carcinoma in situ.
- *Mitotic figures:* Instead of a nucleus, the chromosomes are visible as tangled, dark-staining threads called mitotic figures, which are generally present in malignant tumors.
- *Atrophy:* It means a decrease in the size of a body part, tissue or an individual cell. It can occur following any disease or loss of trophic support due to another disease. It can be physiological (e.g., atrophy of lacrimal gland with increasing age) or it can be pathological [RPE atrophy in age-related macular degeneration (ARMD)].
- *Apoptosis:* Apoptosis is programed cell death that occurs in healthy tissue. Examples include loss of tissue/organs during embryogenesis.
- *Necrosis:* It is the death of cells in an organ or tissue due to disease, injury, or failure of blood supply. Inflammation is always there. Examples include aseptic necrosis in retinoblastoma (RB) when tumor growth exceeds the blood supply.

SPECIMENS RECEIVED IN OCULAR PATHOLOGY

- *Eyeball:* Evisceration, enucleation, exenteration
- *Eyelid:* Biopsy
- *Lacrimal gland:* Biopsy
- *Conjunctiva:* Biopsy, excised lesion, impression cytology

JAYPEE BROTHERS

- *Cornea:* Lamellar keratoplasty (LK), full thickness (penetrating keratoplasty), impression cytology, and corneal biopsy in keratitis
  - *Optic nerve:* Enucleation
  - *Temporal artery biopsy:* Giant cell arteritis
  - *Aqueous tap:* In non-Hodgkins lymphoma (NHL), retinoblastoma (RB), and malignant melanoma (MM) cases
  - *Vitreous tap:* Vitrectomy in endophthalmitis
  - *Retinal:* Rare as in retinal tumors, or retinitis

TISSUE PREPARATION

Fixatives Used

- *Formalin:* 10% buffered formalin is the most commonly used fixative. The advantage of formalin is that it has prolonged chemical stability.[1]

  Time for fixation:
  - Minimum period for a 4-mm thick specimen—8 hours, 6 mm thick specimen—24 hours
  - Large specimen to be cut into thin slices for fixation
  - Eyeball to be cut after 24–48 hours
- *Glutaraldehyde:* It is used for scanning electron microscopy (SEM) and transmission electron microscopy (TEM).

Preparation of Tissue

- *Paraffin embedding:* It is the most commonly used method. The tissue is embedded in paraffin wax. The wax serves two purposes; firstly, it allows the sample to adhere to the slide and secondly, it stabilizes the tissue during sectioning. Paraffin-prepared blocks can be stored indefinitely.[1]
- *Fresh/frozen sections:* In frozen section, fresh tissue is immediately transported in saline to the laboratory, frozen and embedded in a special medium, and multiple sections are taken using a cryostat. Sections are stained and report is given within 20–30 minutes while the patient is still under anesthesia. It is extremely useful in cases when immediate histopathology report is required as in Mohs' micrographic surgery, to know whether the margins are involved in eyelid tumor surgery in the evaluation of intracellular fat as seen in sebaceous carcinoma, and for immunohistochemical studies.[1]
- *Plastic embedding:* The tissue is embedded in an epoxy resin such as araldite. It is used in TEM.[1]

GROSS EXAMINATION (MACROSCOPIC EXAMINATION)

Dimensions: It is the first step. The specimen is measured and its description regarding its shape, size, texture, external and cut surface characteristics are noted.

Usually, the following things are recorded (e.g., in case of an enucleated globe) **(Fig. 7.1)**:[1]

- The maximum dimensions are measured:
  - Anteroposterior (normal 22–24 mm)

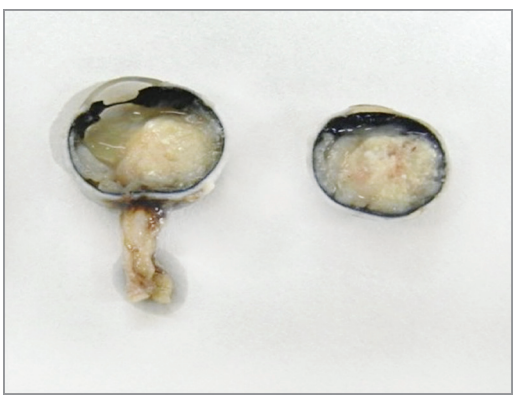

Fig. 7.1: Retinoblastoma—enucleation specimen showing an intraocular retinoblastoma with optic nerve infiltration.

JAYPEE BROTHERS

- Horizontal (normal 23.5 mm)
- Vertical (normal 23 mm)

Transillumination: For this, light is projected from behind the globe to look for the location of mass lesions within the globe.

The eye is then cut in a way revealing the most prominent tumor areas that include the pupil as well as the optic nerve. This half of the globe along with optic nerve is submitted for the routine examination and is termed as the pupillary-optic disc portion (PO). The remaining cut portions of the globe are called calottes, as they resemble the shape of caps. Each calotte is cut serially to maximize the tissue examined.

Special Stains

Commonly used special stains and their uses are depicted in **Table 7.1**.

TABLE 7.1: Special stains in ocular histopathology.

Stain	*Target*	*Color*	*Diagnostic use*
Alcian blue	Mucopolysaccharides	Blue	Macular corneal dystrophy **(Fig. 7.2)**
Colloidal iron	Mucopolysaccharides	Blue	Macular corneal dystrophy **(Fig. 7.3)**
Alizarin red	Chelates calcium	Red	Detects calcification like in band-shaped keratopathy
Von Kossa	Calcium	Black or brown black	Calcific band keratopathy
Bodian	Axons	Black	Optic atrophy
Loyez	Myelin	Black	Demyelinating diseases (multiple sclerosis), optic atrophy
Masson trichrome	Connective tissue hyaline material	• Red—muscle • Green—connective tissue • Nuclei—blue	• Granular corneal dystrophy **(Fig. 7.4)** • Thyroid eye disease (muscle)
Periodic acid–Schiff (PAS)	Basement membranes Fungus	Bright pink	• *Cornea:* Epithelial basement membrane, Descemet's membrane • *Lens:* Capsule • *Retina*: Internal limiting membrane (ILM) • Fungal elements
Silver methenamine (SM)	Fungus	Black	Fungal hyphae in a light-green background
Congo red with polarized light	Amyloid	Apple-green birefringence	Lattice corneal dystrophy **(Fig. 7.5)**
Perl's Prussian blue	Iron	Dark blue	• Intraocular foreign body • Fleischer ring

Contd...

JAYPEE BROTHERS

Contd...

Stain	Target	Color	Diagnostic use
Van Gieson	Elastic fibers	Gray	Elastic tissue like in giant cell arteritis
Ziehl–Neelsen	Acid-fast bacilli	Pink-beaded rods	Detects *Mycobacterium, Nocardia* species in inflammatory tissue and in granulomatous lesions
Oil Red O	Lipid	Red	Fat within cells, sebaceous carcinoma
Fontana–Masson	Melanin and argentaffin cells	Black	Melanin pigments in malignant melanoma and carcinoid tumor

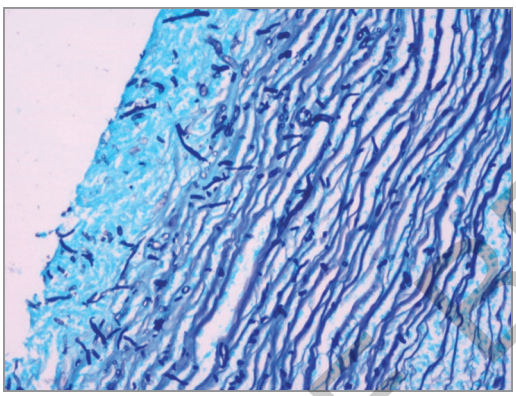

Fig. 7.2: Silver methenamine stain reveals black-colored septate fungal hyphae with acute angle branching in mycotic keratitis.

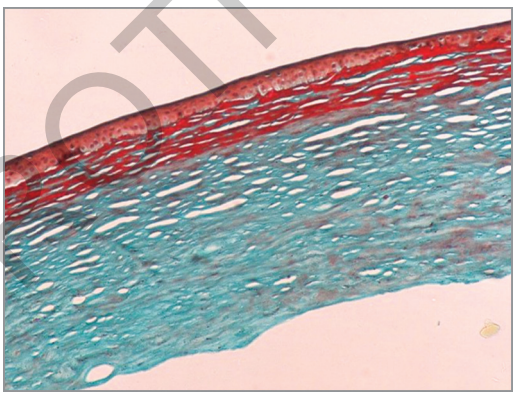

Fig. 7.4: Granular dystrophy—stromal deposits take up a brilliant red color on Masson's trichrome stain.

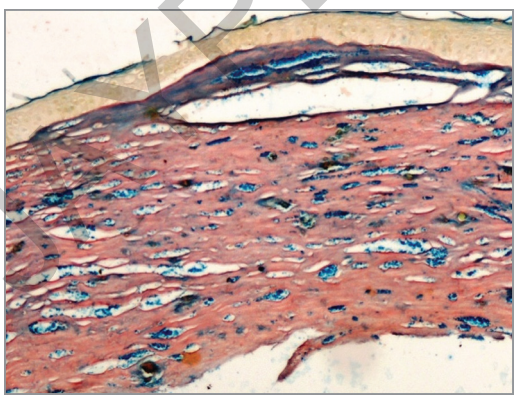

Fig. 7.3: Macular dystrophy—acid mucopolysaccharides are seen in the keratocytes, which take up a Prussian blue color by colloidal iron stain.

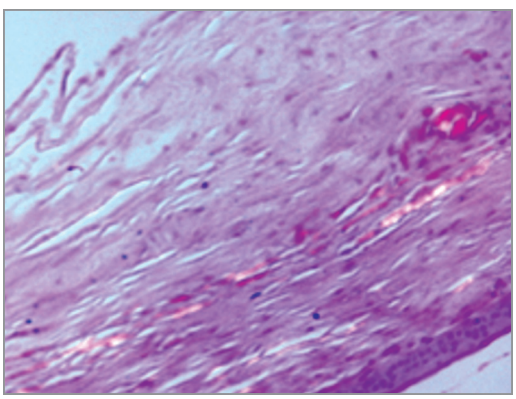

Fig. 7.5: Lattice dystrophy—apple-green birefringence is demonstrated on Congo red stain in polarized light in the corneal stroma.

JAYPEE BROTHERS

Example: Macular corneal dystrophy (MCD) is characterized by deposit of mucopolysaccharides in the stroma, in the keratocytes, beneath the epithelium and endothelium in advanced cases. The stains commonly used are colloidal iron or Alcian blue, both of which stain the mucopolysaccharides blue.[1]

Silver methenamine stains fungal hyphae black in color against a green background **(Fig. 7.1)**.

IMMUNOHISTOCHEMISTRY

Immunohistochemistry involves accurate identification of cells by using an antigen-specific antibody against the antigens present within/on the cells. Specific stains are used to label the antibody and visualize under a light microscope or a fluorescence microscope. The commonly used antibodies are summarized in **Table 7.2**.[1]

TABLE 7.2: Summary of immunohistochemistry antibodies.

Antibody	*Antigen*	*Diagnostic use*	*Ocular example*
Muscle-specific actin, desmin	Contractile filaments in smooth and striated muscle	Smooth muscle-derived tumors	Leiomyosarcoma
Desmin, myogenin, MYOD1	Intermediate filaments in smooth and striated muscle	Muscle-derived tumors	Rhabdomyosarcoma
Cytokeratin (CK 7)	High-molecular-weight glycoprotein epithelial cells	Metastatic adenocarcinomas, adnexal skin tumors	Metastatic carcinoma to orbit
LCA, B cell (CD20), CD3 (T cell), MPO, macrophage (CD68)	Components of T and B cells, macrophages	Hematological malignancies	Lymphomas, leukemias
Cytokeratin/CAM 5.2/ AE1/AE3	Intermediate filaments in epithelial cells	Epithelial-derived carcinomas	Squamous cell carcinoma, sebaceous cell carcinoma
Epithelial membrane antigen (EMA)	Epithelial cells and carcinomas	Epithelial derived carcinomas	Sebaceous cell carcinoma, meningioma
Factor VIII-related antigen	Endothelial cell	Vascular tumors	Ocular angiosarcoma
Glial fibrillar acidic protein (GFAP)	Glial cell constituents	Glial cells and astrocytes origin tumors	Glioma of optic nerve
HMB45/Melan-A	Intracytoplasmic antigen in melanocytes	Tumors of melanocytic origin	Malignant melanomas
S-100	Neural crest cells	Peripheral nerve tumors	Schwannomas, melanoma
Vimentin, smooth muscle antigen (SMA)	• Intermediate filaments • Cells of mesenchymal origin	Spindle cell tumors	Fibrous histiocytoma
Glucose transporter 1 (GLUT 1)	Microvascular endothelium	Tumors of vascular origin	Infantile hemangioma

JAYPEE BROTHERS

Electron Microscopy

Transmission electron microscopy is useful in identifying cell organelles and viral particles at a very high magnification of up to 100,000×. SEM is useful for the evaluation of structures like corneal endothelium.[1]

Molecular Methods

Polymerase Chain Reaction

Polymerase chain reaction (PCR) identifies DNA or RNA sequences specific to particular pathogenic organisms or cellular components. The most significant advantage of PCR is that it requires a tiny amount of sample. The nuclear chromatin is lyzed into individual sequences, and the desired sequence is amplified followed by its rapid detection using various electrophoresis methods.[1]

In Situ Hybridization

Similar to PCR the nuclear chromatin is segregated into fragments, which are detected by immunohistochemical techniques in routine light microscopy. Using this, the exact location of the protein fragments can be visualized within the tissue.[1]

Flow Cytometry[1]

Flow cytometry is useful in identification of various cell types such as B and T cells. Fluorescent antibodies specific to the antigens of different cell types are used for identification.[1]

COMMON PATHOLOGICAL LESIONS IN OPHTHALMOLOGY

Dermoid Cyst (Fig. 7.6)

- These are benign teratomas present since birth.
- Clinically they are most commonly seen in superotemporal quadrant of the eye, followed by superonasal quadrant.
- *Histologically:* It is lined by the stratified squamous epithelium and contains adnexal structures such as sebaceous glands and hair follicles in its wall. The lumen may contain pultaceous material, hair shafts and thyroid, bone, tooth, and other epidermal-derived structures in case of benign teratoma.
- Appendages are a rule for a fully matured cyst and differentiate it from the epidermoid cyst and sebaceous cyst.
- Rupture of cyst during removal provokes a foreign body giant cell reaction and thus removal of cyst should be done.

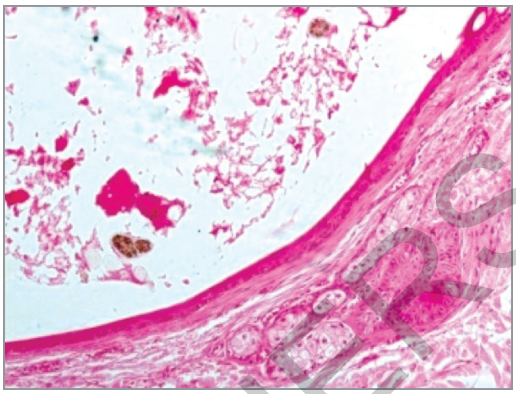

Fig. 7.6: Dermoid cyst—the cyst wall is lined by stratified squamous epithelium with hair follicle and epidermal appendages in its wall with desquamated keratin in its lumen.

Pigmented Tumors

Benign tumors of nevus cells are called melanocytic nevi. These can be of the following types:

- *Intradermal nevus:*
  - It is the most common type of nevus.
  - Presents as an elevated mass, brown to black **(Fig. 7.7)**
  - Histologically, nevus cells are arranged in the form of nests and cords and

JAYPEE BROTHERS

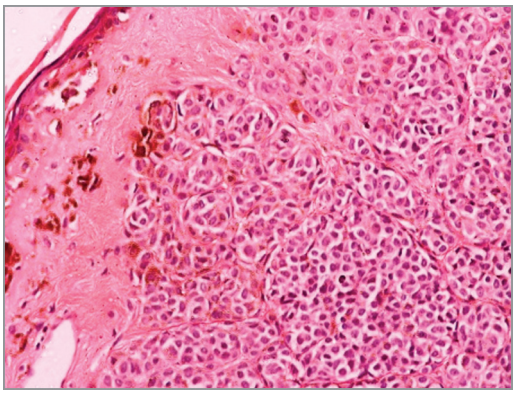

Fig. 7.7: Intradermal nevus showing benign nests of nevus cells with melanin in its superficial cells.

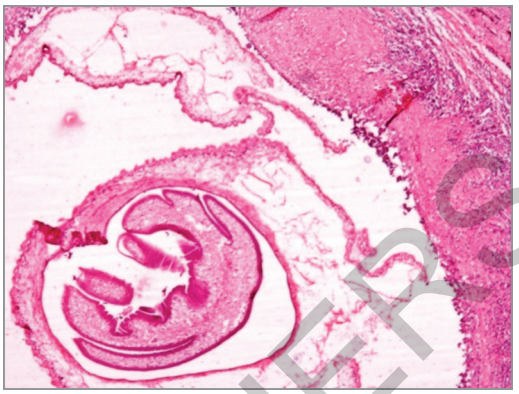

Fig. 7.8: Cysticercosis—body of a cysticercus larva with multiple papillary infoldings.

are located entirely in the dermis. Cells contain a moderate amount of cytoplasm and melanin. The nuclei mature as they go deeper in the dermis and cells become smaller, with less cytoplasm and less melanin and lie in a well-defined mass. Still lower down the nevus cells appear spindle-shaped. Maturation is regarded as an evidence of benignity. There is no malignant potential.

- *Congenital nevus:*
  - Larger in size than acquired nevus
  - Differentiated from acquired nevus on the basis of histology
  - Presence of nevus cells in lower reticular dermis/subcutaneous fat
- *Compound nevus:*
  - Both intradermal and junctional component
  - Malignant potential is related to the junctional component.
- *Nevus of Ota:*
  - Bluish-gray discoloration of periorbital skin with the sclera
  - Heterochromia or choroidal nevi may be present.
  - Fusiform, bipolar, heavily pigmented melanocyte in the dermis.
- *Junctional nevus:*
  - Nevus cells are at the junction of epithelium and dermis.
  - Low malignant potential

Cysticercosis (Fig. 7.8)

Cysticercosis is caused by the larvae of the pork tapeworm, *Taenia solium, Cysticercus cellulosae*. The preferred tissues by the larvae are subcutaneous tissue, skeletal muscles, brain, and eye. Microscopically the scolex consists of a sucker and multiple papillary infoldings of tegument. The larvae contain a perioral double row of hooklets.[1]

The wall of the cyst shows characteristic histologic appearance, with three distinct layers:

1. *Outer layer/cuticular layer*: Corrugated containing multiple microtrichia, which are nothing but hair-like protrusions. This layer remains in contact with the host surface.
2. Middle layer, which is very thin and cellular.
3. Inner layer, which is thick and contains a network of multiple small canaliculi.

Chalazion (Fig. 7.9)

A chalazion is a chronic lipogranulomatous inflammation of the sebaceous glands (Zeis

JAYPEE BROTHERS

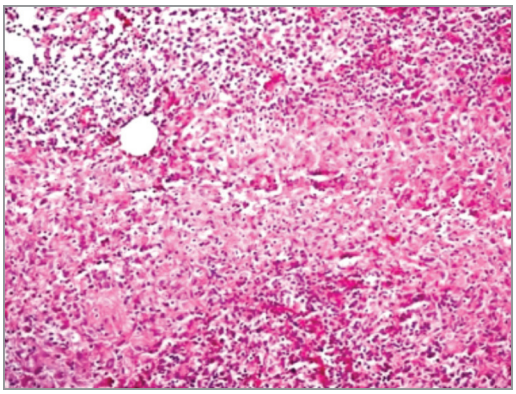

Fig. 7.9: Chalazion—microscopic examination reveals lipogranulomatous inflammation comprising plasma cells, lymphocytes, histiocytes, giant cells, and ill-defined epithelioid cell granuloma. Lipid dissolved during processing is seen as a large vacuolated area.

and Meibomian glands), resulting in a hard painless eyelid nodule. Microscopically, the essential lesion is the formation of focal granuloma centered around clear spaces (lipid vacuoles) discharged from sebaceous glands.

The lipid deposits can be stained using Oil Red O stain on frozen section. The granuloma contains giant cells, epithelioid cells, plasma cells, and lymphocytes.[1]

Differential diagnosis:

- Tuberculosis
- Sarcoidosis
- Fungal infections
- Parasitic infections

Intraocular Tumors

Retinoblastoma

Retinoblastoma is the most common intraocular tumor seen in the pediatric age-group. It arises from the nucleated retinal layers. The average age of presentation is 13 months. Six percent may be familial and 50% of these may be bilateral. Around 94% of the RBs are sporadic.

- *Endophytic RB:* This form grows from the inner surface of the retina, and can be easily seen with ophthalmoscopy.
- *Exophytic RB:* This form grows from the outer surface of retina toward the choroid.
- *Mixed, endo-exophytic:* Most common type
- *Diffuse infiltrating RB:* It is a rare (1–2%) histologic form of RB characterized by diffuse infiltration of the retina without a tumor mass.

Histology reveals cells with a large basophilic nucleus of variable size and shape and scanty cytoplasm. Mitotic figures are numerous **(Figs. 7.10A to D)**. Rosettes are highly characteristic of RBs seen in well-differentiated RBs. Flexner–Wintersteiner rosette is formed by cuboidal cells, which are lined up around an empty central lumen. Special stains reveal acid mucopolysaccharides in the lumen. Homer-Wright rosettes are less common, and cells are not arranged around a lumen. The cells send out cytoplasmic processes and are lined up around cobweb-like eosinophilic material. Well-differentiated RB has a better prognosis.[1]

Endophytic RBs tend to spread anteriorly by seeding into vitreous and aqueous. Aqueous seeding may stimulate a hypopyon. Deposits may appear on iris and in anterior chamber angle and produce secondary angle-closure glaucoma. Anterior uveal invasion leads to hematogenous disease or regional lymphatic spread.

Poorly differentiated RB is composed of cells with a large basophilic nucleus of variable size and shape and scanty cytoplasm. No rosettes are identified. Mitotic figures are numerous. Necrotic RBs result in liberation of DNA from tumor nuclei. This DNA is preferentially absorbed by blood vessels.

JAYPEE BROTHERS

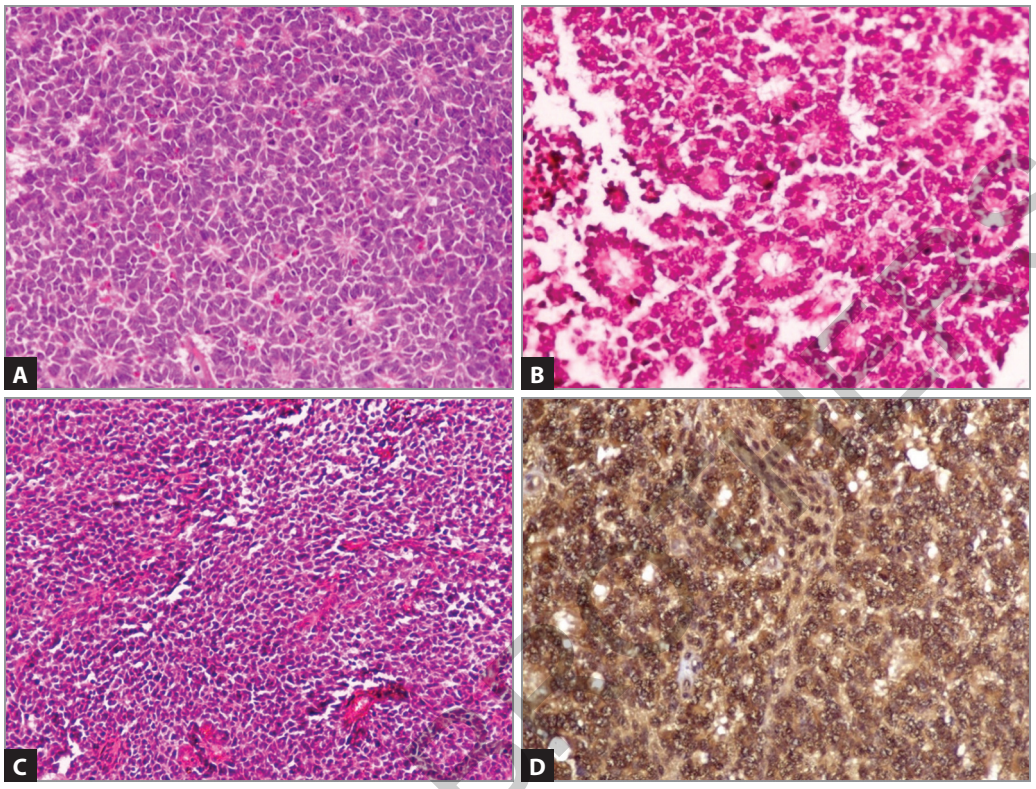

Figs. 7.10A to D: (A) Retinoblastoma—hematoxylin and eosin section from a well-differentiated retinoblastoma showing numerous Homer-Wright rosettes. In these rosettes, the pink material in the center represents tangle of processes of tumor cells; (B) Retinoblastoma—section shows Flexner–Wintersteiner rosettes with a central lumen; (C) Poorly differentiated retinoblastoma; (D) Immunohistochemical stain synaptophysin shows cytoplasmic positivity in the tumor cells.

Retinoblastoma, extraocular spread: Extraocular spread may occur to orbit and brain. All RBs show a striking tendency to invade the optic disc. Optic nerve involvement increases the mortality to 15% when the invasion is up to lamina cribrosa. This increases up to 65% when the resected margin is involved. Once in the nerve, the tumor can reach chiasma through nerve bundles or subarachnoid space through the pia. The access to subarachnoid space can occur via central retinal vessels. Histopathological high-risk factors like massive choroidal invasion, optic nerve retrolaminar region and cut end involvement, iris and ciliary body involvement, and scleral and extrascleral invasion should be looked for in the histopathology sections for adjuvant chemotherapy **(Figs. 7.11A and B)**.[1]

Uveal Malignant Melanoma

Malignant melanoma of the uveal tract is rare. It originates most commonly from choroid, followed by ciliary body and iris. The prognosis is poor with hematogenous spread mainly to the liver, lung, and bone. Microscopically based on the cell type they

JAYPEE BROTHERS

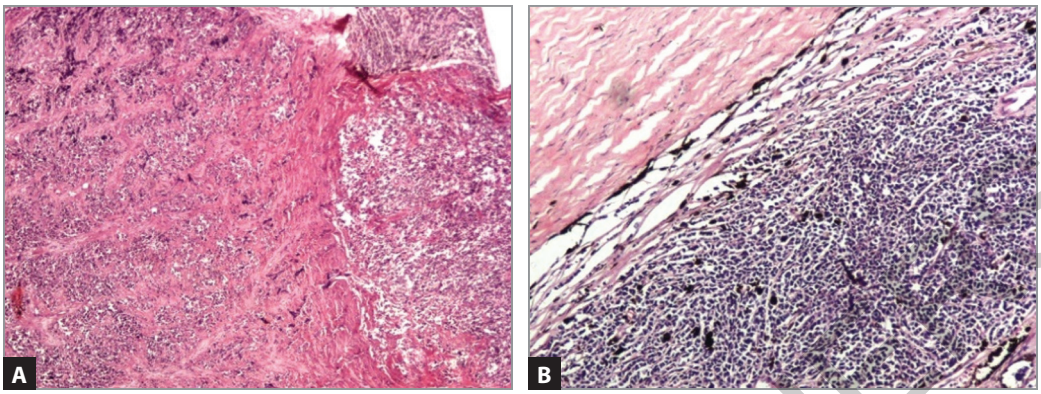

Figs. 7.11A and B: (A) Optic nerve head and retrolaminar invasion; (B) Massive choroidal invasion.

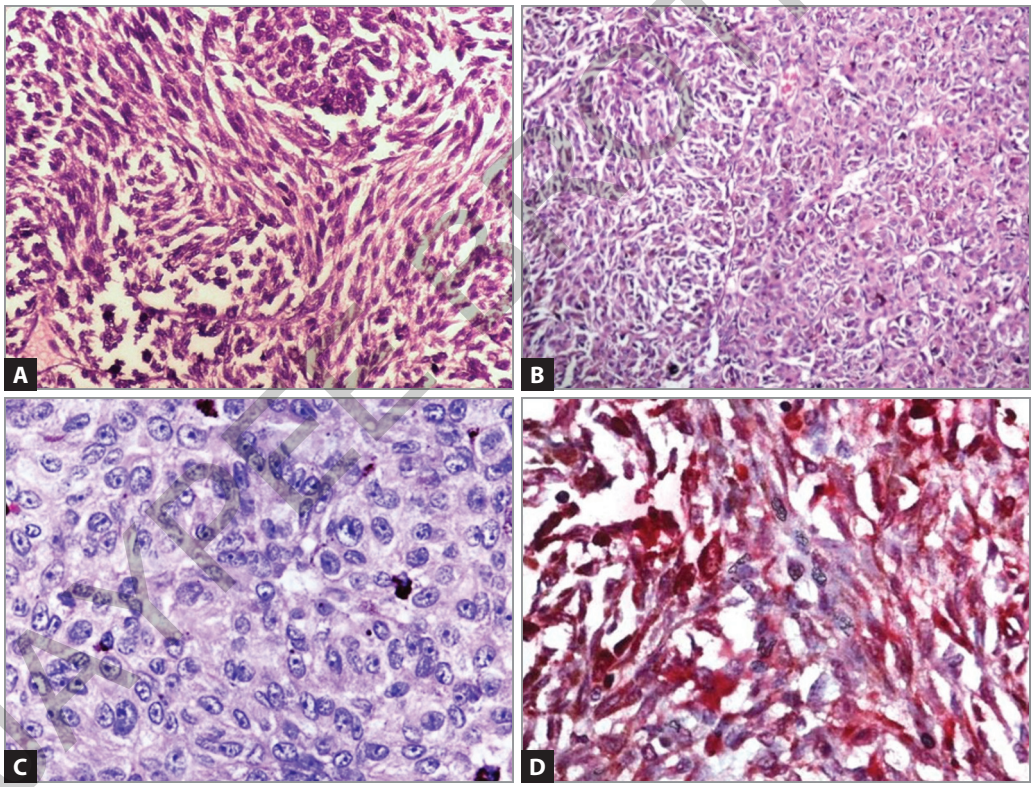

Figs. 7.12A to D: (A) Spindle-cell melanoma; (B) Mixed-cell melanoma; (C) Epithelioid cell melanoma; (D) Cytoplasmic HMB45 positivity in melanoma cells.

are classified into spindle cell type, mixed cell type, and epithelioid cell type **(Figs. 7.12A to D)**. Immunohistochemical stain HMB45, Melan A, and S-100 are positive in the tumor cells. Spindle cell type has the best prognosis while epithelioid has the worst prognosis.[1]

for detailed information on ophthalmology books, visit our website www.jaypeebrothers.com, for detailed information on ophthalmology books, visit our we

OPHTHALMOLOGY CLINICS-2
for Postgraduates

This book describes the different investigative tools in ophthalmology, their output, and how to interpret those findings with maximum possible images. It will help the students appearing in examination as well as the general practitioners to interpret the various investigative tools in ophthalmology and arrive at a diagnosis. The section on Appliances and Instruments will help in appearing for viva-voce examination. The section on Basic Sciences such as ocular microbiology, pathology basics, and community ophthalmology will help students appearing in various postgraduate examinations.

Prafulla Kumar Maharana MD DNB is an Additional Professor, Dr Rajendra Prasad Centre for Ophthalmic Sciences, All India Institute of Medical Sciences (AIIMS), New Delhi, India. He has over 100 publications in various national and international peer-reviewed journals to his credit. He has written over 40 chapters in several books and edited a book. He has the experience of working at several institutes such as LV Prasad Eye Institute (LVPEI), Hyderabad, Telangana; AIIMS, Bhubaneswar, Odisha; and AIIMS, Bhopal, Madhya Pradesh, India and teaching of MD/MS/DNB/Diploma/MBBS and optometry students.



Namrata Sharma MD is a Professor, Dr Rajendra Prasad Centre for Ophthalmic Sciences, All India Institute of Medical Sciences (AIIMS), New Delhi, India. She has over 500 publications to her credit with more than 350 publications in international peer-reviewed journals. She has co-authored nine books based on various aspects of ophthalmology and has filed two patents. She has won over 20 national and international awards for her achievements and excellence in the field of Ophthalmology and has been actively involved in undergraduate, postgraduate, and post-doctoral teaching for the last 20 years.



Atul Kumar MD FAMS FRCS (Ed) is a Medical Director, Department of Ophthalmology, AK Institute of Ophthalmology, New Delhi, India. He has been awarded the prestigious 'Padma Shri' in 2007 for his significant contributions to health care in the field of vitreoretinal diseases and BC Roy Award for excellence in medical education in 2016. He has been awarded fellowship of the FRCS Edinburgh (ad hominem) by the Royal College of Surgeons of Edinburgh, Scotland, UK, recently. He has been appointed Honorary Advisor (Ophthalmology) to the Government of India in 2016. He has over 300 publications in indexed and nonindexed journals and has co-authored 10 books. He has been an active collaborator in 84 basic science and clinical research projects and actively involved in undergraduate and postgraduate teaching for the last 30 years.



Printed in India

Available at all medical bookstores or buy online at www.ejaypee.com

JAYPEE BROTHERS
Medical Publishers (P) Ltd.
EMCA House, 23/23-B, Ansari Road,
Daryaganj, New Delhi - 110 002, INDIA
www.jaypeebrothers.com

Join us on facebook.com/JaypeeMedicalPublishers
Follow us on instagram.com/JaypeeMedicalPublishers

Shelving Recommendation
OPHTHALMOLOGY

ISBN 978-93-6616-127-3
9 789366 161273