books, visit our website www.jaypeebrothers.com, for detailed information on allied health books, visit our website www.jaypeebrothers.com, for detailed information on allied health books

Complimentary Online Student Resource
MCQs, Flash Cards & Videos

Essentials of ANATOMY & PHYSIOLOGY for Allied Health Sciences

PR Ashalatha
G Deepa

JAYPEE

Contents

Quick Scan ..... *xv*

SECTION 1: Body and its Constituents



Chapter 1. Introduction to Anatomy and Physiology 3

Anatomy 3; Physiology 4

Basic Anatomical Terminology 4

Anatomical Position 4; Anatomical Planes 5; Terminology 6

Levels of Organization and Organ Systems of Body 10

Level of Organization 10

Organ Systems of Body 11

Integumentary System 12; Skeletal System 12; Muscular System 13; Nervous System 13; Endocrine System 14; Urinary System 14; Cardiovascular System 15; Lymphatic System 15; Respiratory System 16; Digestive System 16; Female Reproductive System 17

Skeleton 17

Male Reproductive System 17; Axial Skeleton 18; Appendicular Skeleton 19

Cavities of the Body 20

Cranial Cavity 20; Thoracic Cavity 20; Abdominopelvic Cavity 21

Composition of Body 24

Homeostasis 24

Components of Homeostatic System 24

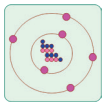

Chapter 2. Introduction to Chemistry of Life 28

Introduction to Chemical Basis of Life 28

Water 28; Carbohydrates 28; Proteins 29; Fats and Fatty Acids 30; Vitamins 32; Minerals 32; Source of Energy 33; Isotopes 34

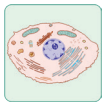

Chapter 3A. Organization of Human Body: Cell Level 36

Cell 36

Structure of a Cell 36

Transport Across Cell Membrane 45

Basic Mechanism of Transport 46



Chapter 3B. Organization of Human Body: Tissue Level 50

Primary Tissues 50

Classification 50; Epithelial Tissue (Epithelium) 50; Classification of Epithelia 51; Glands 58; Connective Tissue 62; Special Connective Tissue 67; Muscular Tissue 69; Nervous Tissue 69; Supporting Tissues 69

SECTION 2: Organ Systems



Chapter 4. Respiratory System 75

Exchange of Gases 75; Air Passages 75; Nose and Paranasal Sinuses 76; Pharynx 80; Larynx 80; Trachea 85; Tracheobronchial Tree 87; Lungs 88; Pleura and Pleural Cavity 95; Physiology of Respiration 96; Ventilation 99; Gaseous Exchange in Lungs 99; Transport of Gases between Lungs and Tissues 100; Regulation of Respiration 102; Nervous Control of Respiration 102

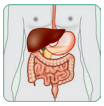

Chapter 5. Digestive System 108

Process of Digestion 109; Innervation of Gastrointestinal Tract 109; Parts of Digestive System 110; Pharynx 117; Salivary Glands 119; Saliva 124; Gut 126; Esophagus 126; Stomach 128; Small Intestine 135; Duodenum 135; Large Intestine 141

Accessory Organs of Digestion 145

Liver 145; The Peritoneum 152; Gastrointestinal Hormones 159

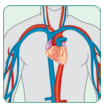

Chapter 6A. Circulatory System: Heart 164

Heart 166; Electrocardiogram (ECG) 177; Cardiac Output 179; Arterial Blood Pressure 182

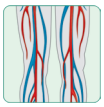

Chapter 6B. Circulatory System: Blood Vessels 189

Blood Vessels 189

Arteries 189; Veins 191; Aorta 191

Blood Circulation of Head and Neck 196

Arterial Supply 196; Venous Drainage 198

Blood Circulation of Upper Limb 201

Arterial Supply 201; Venous Drainage 203

Blood Circulation of Thorax 204

Arterial Supply 204; Venous Drainage 204

Blood Circulation of Abdomen 205

Arterial Supply 205; Celiac Trunk 205; Venous Drainage 206

Portal Circulation 207

Portal Vein 207

Blood Circulation of Pelvis and Lower Limb 207

Arterial Supply 207; Venous Drainage 210



Chapter 7. Blood 214

Erythrocytes (Red Blood Cells) 219; Leukocytes (White Blood Cells) 229; Thrombocytes (Platelets) 233; Blood Groups 236; Blood Transfusion 238



Chapter 8. Lymphatic System 240

Lymph 240; Lymphatic Tissue and Organs 241; Major Lymphatics of Body 243; Spleen 245; Tonsil 247; Thymus 248



Chapter 9. Resistance and Immunity 251

Immunity 251; Classification of Immunity 252; Nonspecific Defense Mechanisms/Innate Immunity 252; Humoral Immunity 253; Cell-Mediated Immunity 253



Chapter 10. Endocrine System 257

Hormone 258; Hypothalamus 259; Hypophysis Cerebri or Pituitary Gland 260; Thyroid Gland (Thyroid = Shield-Like) 265; Hormones Regulating Calcium Metabolism 270; Parathyroid Glands 271; Suprarenal or Adrenal Glands 272; Pancreas 277; Glossary 279

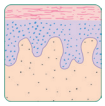

Chapter 11. Skin and Temperature Regulation 281

Skin 280

Structure of Skin 282; Types of Skin 282; Nerve Supply 283; Functions of Skin 283

Appendages of Skin 284

Hair 284; Sebaceous Glands 285; Sweat Glands 285; Nails 285; Receptors of Skin 286

Temperature Regulation 286

Channels of Heat Loss 286; Mechanisms Activated by Heat 286; Mechanisms Activated by Cold 287



Chapter 12. Sensory Organs 289

Sense of Smell or Olfaction 289

Mechanism 289

Sense of Taste 289

Sense of Hearing 290

External Ear 290; Middle Ear 292; Internal Ear 294; Physiology of Hearing 297; Balance and Ear 298

Sense of Vision 299

Living Eye 299; Eyebrows 299; Eyelids or Palpebrae 299; Lacrimal Apparatus 300; Muscles of the Eyeball 300; Eye 301; Lens 306; Visual Processes 306; Field of Vision 308; Visual Pathway 309; Color Vision or Chromatic Vision 310



Chapter 13A. Musculoskeletal System: Muscular System 313

Classification of Muscles 313

Skeletal Muscle 314; Cardiac Muscle 321; Smooth Muscle 322; Distribution 322

Muscles of the Body 323

Muscles of the Head 323; Muscles of the Neck 324; Muscle of the Trunk 326; Muscles of Shoulder Girdle and Upper Limb 331; Muscles of the Lower Limb 340



Chapter 13B. Musculoskeletal System: Skeletal System 349

Bone 349; Osteology 349; Number of Bones 349; Classification 349; Gross Structure 350; Skeleton 360

Axial Skeleton 362

Skull 362; Individual Skull Bones 368; Skeleton of Thorax (Thoracic Cage) 375; Appendicular Skeleton 384; Upper Arm (Arm or Brachium) 386; Pelvic Girdle and Lower Limb 392



Chapter 13C. Musculoskeletal System: Joints 403

Joints 403; Major Joints of Upper Limb 407; Joints of Lower Limb 412; Retinacula Related to Joints 421



Chapter 14. Renal System 426

Parts of Renal (Urinary) System 426; Functions of Urinary System 426; Kidneys (Renes; Nephros) 426; Physiology of Urine Formation 435; Glomerular Filtration 435; Tubular Reabsorption 437; Urine 439; Water Balance 440; Ureters 442; Urinary Bladder 443; Urethra 444; Radiological Anatomy of Urinary System 445; Micturition 446



Chapter 15. Reproductive System 448

Female Reproductive System 448

External Genital Organs (Vulva) 449; Internal Genital Organs 450

Physiology of Female Reproductive System 461

Puberty 461; Mammary Gland or Breast 466

Male Reproductive System 468
Penis (L. Tail) 468; Scrotum 470; Testes (Singular—Testis) 470; Epididymis 473; Spermatic Cord 473; Vas Deferens or Ductus Deferens 473; Seminal Vesicles 474; Ejaculatory Ducts 474; Prostate Gland 474

Physiology of Male Reproductive System 475
Control of Testicular Function 475; Spermatogenesis 475; Structure of Spermatozoon (Sperm) 476; Semen or Seminal Fluid 476; Puberty in Males 477; Pregnancy 477; Functions of Placenta 477; Diagnostic Tests for Pregnancy 478; Physiological Changes During Pregnancy 478; Lactation 479; Contraception 479



Chapter 16. Nervous System 482

Divisions of Nervous System 482

Tissues Constituting the Nervous System 483
Neurons 484; Nerves 485

Synapse 490
Classification of Synapse 490; Structure of a Typical Chemical Axodendritic Synapse 491

Neurotransmitters 492
Classification of Neurotransmitters 492

Central Nervous System 493
Meninges 493

Ventricles of the Brain and Cerebrospinal Fluid 496
Lateral Ventricles 496; Third Ventricle 497; Fourth Ventricle 497; Choroid Plexuses 497; Cerebrospinal Fluid (CSF) 497

Brain 499
Internal Capsule 503; Basal Nuclei (Ganglia) 504; Functional Areas of Cerebral Cortex 505; Functions of Cerebrum 508

Diencephalon 508
Subdivisions 508; Thalamus 509; Hypothalamus 511

Brainstem 512
Midbrain 512; Pons (Bridge) 514; Medulla Oblongata 514; Cerebellum (Little Brain) 515

Blood Supply of Brain 517
Arteries Supplying the Brain 517; Vertebrobasilar Arteries 518; Internal Carotid Artery 519; Venous Drainage 519

Spinal Cord 519
External Features 519; Internal Structure of Spinal Cord 520; Blood Supply 522

Reflexes 524
Classification of Reflexes 524

Tracts of Spinal Cord and Brainstem 526
Ascending Tracts 526; Dorsal (Posterior) Column Tract or Fibers 527; Anterior (Ventral) Spinothalamic Tract 527; Lateral Spinothalamic Tract 528; Descending Tracts of Spinal Cord 531; Extrapyramidal Spinal Tracts 532

Cranial Nerves 533
Olfactory Nerve—CN I 535; Optic Nerve—CN II 535; Oculomotor Nerve—CN III 535; Trochlear Nerve—CN IV 536; Trigeminal Nerve—CN V 536; Abducent Nerve—CN VI or Abducens 538; Facial Nerve—CN VII 538; Vestibulocochlear—CN VIII 539; Glossopharyngeal Nerve—CN IX 540; Vagus Nerve—CN X 540; Accessory Nerve—CN XI 541; Hypoglossal Nerve—CN XII 541; Summary of Cranial Nerves 542; Spinal Nerves 542; Nerve Plexuses 544; Brachial Plexus 545; Musculocutaneous Nerve (C5–7) 546;

Median Nerve or "Laborer's Nerve" 546; Ulnar Nerve 547; Radial Nerve 548;
Axillary Nerve 548; Lumbar Plexus 548; Femoral Nerve 549;
Obturator Nerve (A) 549; Sacral Plexus 549; Sciatic Nerve 550

Autonomic Nervous System 551
Subdivisions of Autonomic Nervous System 551

SECTION 3: Genetics



Chapter 17. Introduction to Genetics 561

Chromosomes 561; Basic Structure of DNA 563; Cell Division 565

Genetic Basis of Inheritance 568
Dominant Inheritance 569; Recessive Inheritance 569; Sex-Linked Inheritance 569

SECTION 4: Nutrition

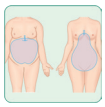

Chapter 18. Introduction to Nutrition 581

Importance of Food in Health and Disease 582; Classification of Food 582;
Basal Metabolic Rate 583; Specific Dynamic Action 583; Energy Requirement by Adults 583;
Energy Balance 583; Balanced Diet 583; Nutritional Disorders 584; Lifestyle Diseases 588

Appendices 589

Appendix 1: Memory Joggers!! 589
Appendix 2: Normal Values 591
Appendix 3: Common Prefix, Suffix, and Root 599
Appendix 4: Important Terms Used for Bones 600
Appendix 5: Largest and Smallest 601
Appendix 6: Alternative Names of Organs 602
Appendix 7: Different Types of Cells in Human Body 603
Appendix 8: Different Plexuses 605
Appendix 9: Neurotransmitters 605
Appendix 10: Regions of Brain and their Functions 605
Appendix 11: Dissection 606
Photos of Specimens Obtained during Autopsy 611

Glossary 613

Index 621

Digestive System

5

CHAPTER

Chapter at a Glance

- Introduction
- Process of Digestion
- Innervation of Gut
- Oral Cavity
- Pharynx
- Salivary Glands
- Esophagus
- Stomach
- Small Intestine
- Large Intestine
- Accessory Organs of Digestion
- Liver
- Gallbladder
- Pancreas
- Secretions Helping in Digestion of Food in the Small Intestine
- Gastrointestinal Hormones
- Development of Digestive System

Learning Objectives

- Describe the parts and structure of digestive system
- Describe the functions of digestive system

INTRODUCTION

The purpose of digestion is to change the food stuffs by mechanical and chemical action to simple forms, which can be easily absorbed into blood and utilized by various tissues in the body. It is also involved in maintaining the water and electrolyte balance of the body. The gastrointestinal tract consists of an alimentary canal of 8–10 meters length, extending from the mouth to the anus, salivary glands, liver and exocrine part of pancreas.

The process of digestion involves breaking up of large particles of foodstuff like polysaccharides, fats and proteins (which cannot be easily absorbed) into smaller particles like monosaccharides, fatty acids and amino acids, which can be easily absorbed. These absorbed products are metabolized for the production of energy for various activities of the body system.

Gastrointestinal (GI) tract is formed by two types of organs:

1. Primary digestive organs
2. Accessory digestive organs

Primary digestive organs	*Accessory digestive organs*
Primary digestive organs are the organs where actual digestion takes place. These organs are: • Mouth • Pharynx • Esophagus • Stomach • Small intestine • Large intestine	Accessory digestive organs are the organs which help the primary digestive organs in the process of digestion. These organs are: • Teeth • Tongue • Salivary glands • Exocrine part of pancreas • Liver • Gallbladder

JAYPEE BROTHERS

PROCESS OF DIGESTION (FLOWCHART 5.1)

The process of digestion takes place in the alimentary canal and it is assisted by some accessory organs like salivary glands, liver and pancreas.
Food is processed within the body in four steps:
1. Ingestion
2. Digestion
3. Absorption
4. Excretion

Ingestion

Ingestion or taking in of food and mastication (chewing) are functions performed by mouth and teeth, aided by tongue. Pharynx and esophagus are concerned with swallowing.

Flowchart 5.1: Process of digestion.

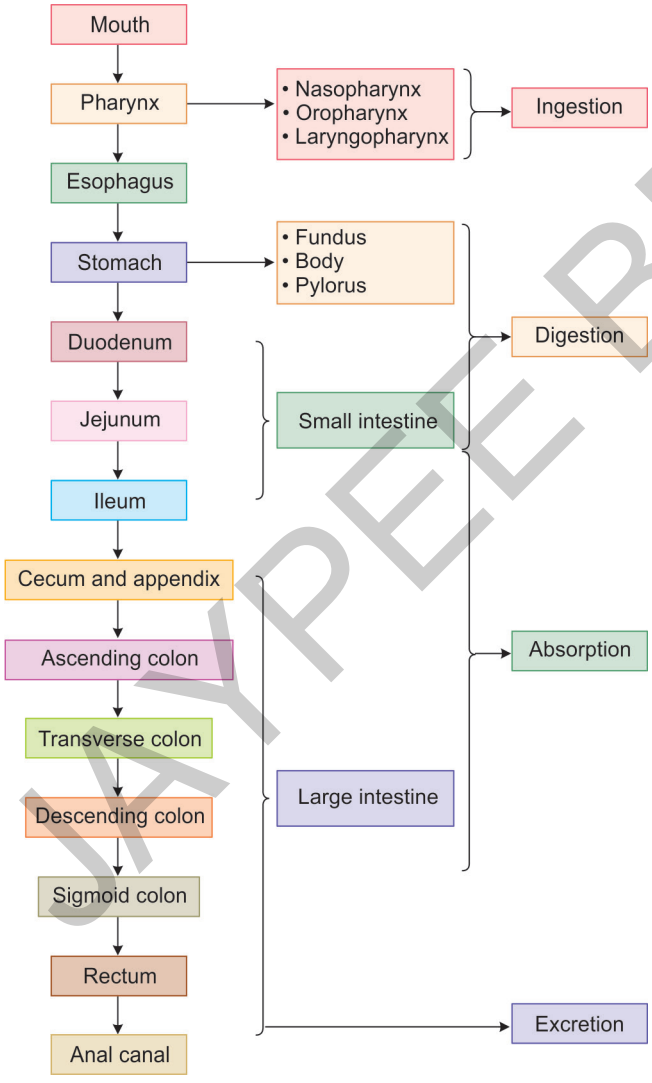

Digestion

Digestion occurs in the stomach and upper part of small intestine.

Absorption

Absorption can occur from any part of alimentary canal (mainly by small intestine).

Excretion

Large intestine absorbs major quantity of water and the residue is excreted in the form of feces.

INNERVATION OF GASTROINTESTINAL TRACT

The special network of nerve fibers innervating the gastrointestinal tract (GIT) consists of two groups of fibers.
1. Enteric nervous system or intrinsic nervous system **(Fig. 5.1).**
2. Extrinsic nervous system or autonomic nervous system **(Fig. 5.2).**

Enteric Nervous System (ENS) or Intrinsic Nervous System (INS)

It is formed by two different networks of nerve fibers **(Fig. 5.1):**
1. *Myenteric (Auerbach's) plexus*: It lies between the longitudinal and circular muscle layers. They are responsible for the tone of the gut wall and the rhythmic contractions of gut. Thus, they control the peristalsis of the gut.
2. *Meissner's (submucous) plexus*: It lies between the submucous layer and the inner layer of muscular

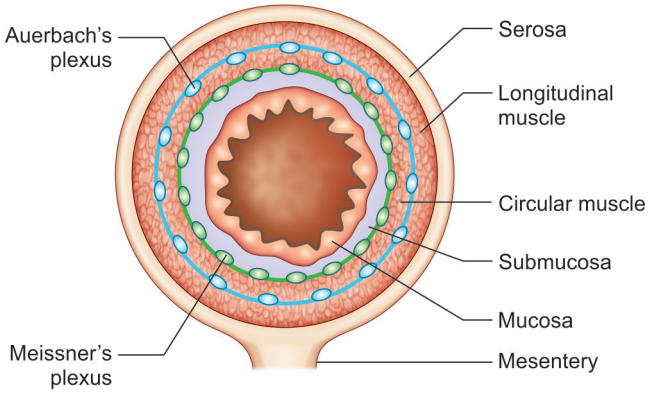

Fig. 5.1: Structure of intestinal wall with intrinsic nerve plexus (schematic representation).

JAYPEE BROTHERS

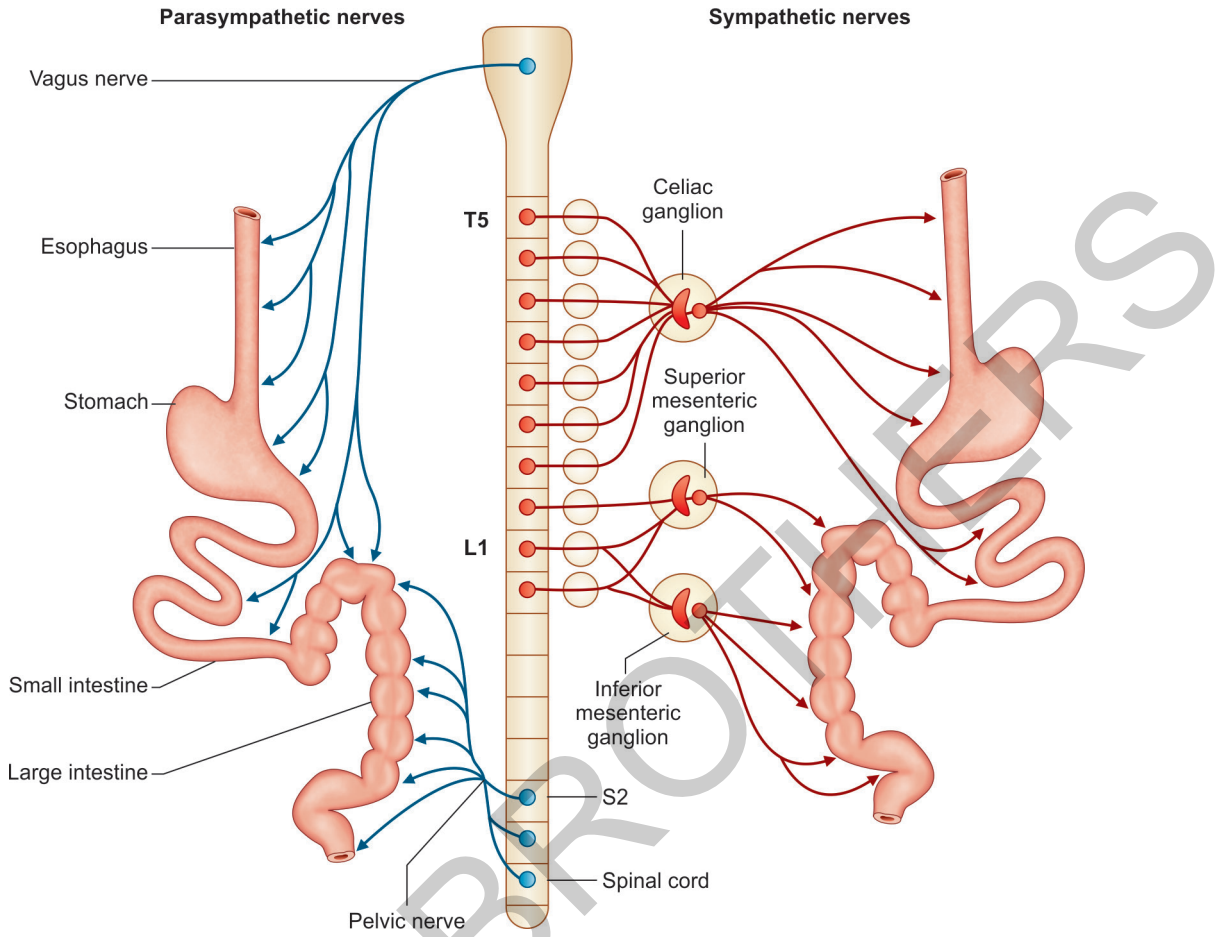

Fig. 5.2: Extrinsic nerve supply to GI tract (T5 = 5th thoracic segment of spinal cord; L1 = 1st lumbar segment of spinal cord; S2 = 2nd sacral segment of spinal cord) (schematic representation).

layer. It is mainly sensory in function and is responsible for the control of exocrine and endocrine secretions from GIT.

Extrinsic Nervous System

This is under the control of the parasympathetic and sympathetic nerves **(Fig. 5.2)**.

Parasympathetic innervation to the gut arises from the vagus. The vagus nerve supplies the GIT up to the right two-third of transverse colon. The rest of the gut tube receives parasympathetic supply from the pelvic splanchnic nerves. Stimulation of parasympathetic system results in an increase in the gastrointestinal secretions as well as the gastrointestinal motility.

Sympathetic fibers to GIT arise from T8 to L2 segments of the spinal cord. Most of these fibers terminate on the ENS, but a few go along with the blood vessels of the gut. Their stimulation causes inhibition of peristalsis and vasoconstriction of the blood vessels supplying GIT.

PARTS OF DIGESTIVE SYSTEM (FIG. 5.3)

Oral Cavity

The mouth or oral cavity is the first part of the digestive tube. It is divided into mouth proper and a vestibule. The vestibule is a slit-like space between the lips and cheek externally, and the gums and teeth internally. It communicates externally through the oral fissure. The parotid duct opens into the vestibule, on the inner surface of the cheek opposite the crown of the upper second molar tooth. Numerous mucous glands (buccal and labial) of lips and cheek open into the vestibule. The vestibule is lined by mucous membrane, the lining epithelium of which is stratified squamous nonkeratinizing.

Lips

Lips (labia) are fleshy folds lined externally by skin and internally by mucous membrane. Each lip is composed

JAYPEE BROTHERS

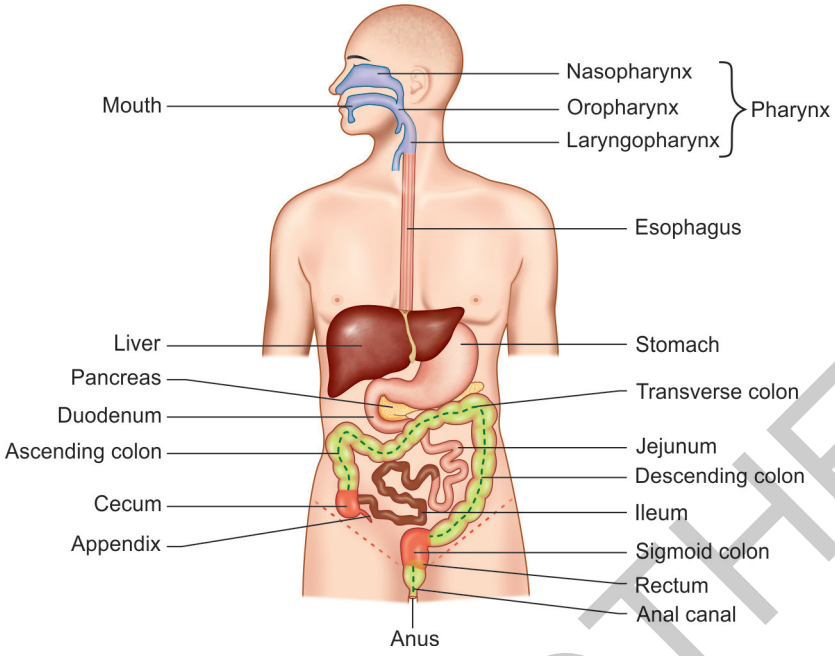

Fig. 5.3: Parts of digestive system (schematic representation).

of skin, superficial fascia and orbicularis oris muscle, submucosal and mucous membrane.

Cheeks

Cheeks (buccae) are fleshy flaps, forming a large part of each side of the face. The cheeks are composed of skin, buccinator muscle, parotid duct, vessels and nerves, mucous glands and mucosa. In infants, a well-developed buccal pad of fat lies on the buccinator.

Oral Cavity Proper (Fig. 5.4)

Boundaries

- *Anterolaterally* by teeth, gums and alveolar arches of jaws.
- *Roof* is formed by hard and soft palates.
- *Floor* is formed by the tongue and sublingual region.
- *Posteriorly* the oral cavity communicates with the pharynx through the oropharyngeal isthmus which

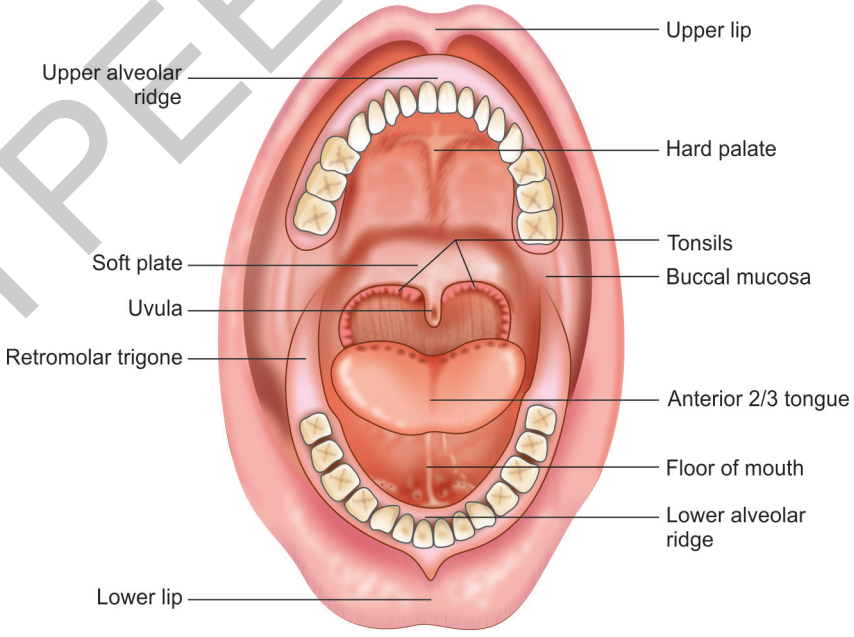

Fig. 5.4: Oral cavity (schematic representation).

JAYPEE BROTHERS

is bounded superiorly by soft palate, inferiorly by tongue and on each side by palatoglossal arches.

Gums

Gums are the soft tissues which cover the alveolar processes of the upper and lower jaws and surround the necks of the teeth. The gums are made up of dense fibrous tissue, covered by stratified squamous epithelium.

Teeth

Oral and paraoral tissues comprise of oral mucous membrane, three pairs of major and innumerable minor salivary glands, jaw bones bearing deciduous and permanent sets of dentitions, maxillary sinus and temporomandibular joint. Teeth constitute approximately 20% of the surface area of mouth, the upper teeth significantly more than the lower teeth. A tooth consists of a crown which is exposed to oral cavity and single or multiple roots, lying in socket of jaw bones. The teeth are composed of the following tissues **(Fig. 5.5)**:

- ***Enamel:*** It is the hardest tissue in a human body, covering the crown of the tooth. It is inert, acellular and formed from ectoderm. It is supported by the underlying dentin.
- ***Dentin:*** It is less calcified, more resilient, vital, hard tissue forming the main bulk of the tooth. It is formed from and supported by the dental pulp. In crown portion, it is covered by the enamel and in the root portion, it is covered by the cementum. The junction between enamel and dentin is known as ***dentinoenamel junction***.
- ***Cementum:*** It is less mineralized tissue, covering the radicular portion of the tooth. The junction between enamel and cementum is known as ***cervical line*** or ***cementoenamel junction***.

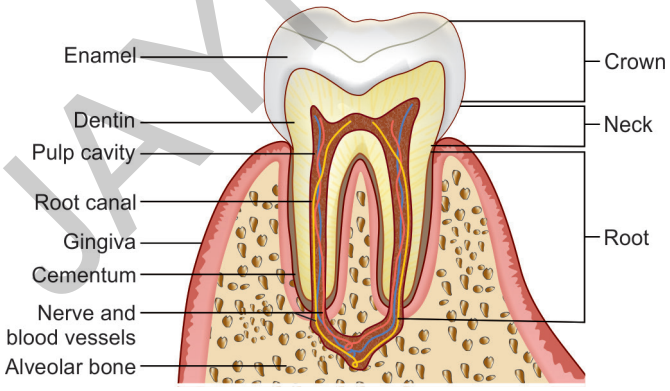

Fig. 5.5: Vertical section through a tooth (schematic representation).

- ***Pulp:*** It is the soft, connective tissue in the central part of tooth enclosed by dentin. The pulp cavity in the crown part is known as ***pulp chamber*** and in the root portion, it is known as ***pulp canal*** or ***root canal***.
- ***Periodontium:*** The tissues (periodontal ligament, cementum, alveolar bone), which support the teeth in jaws are collectively termed as periodontium. The tooth is anchored to the socket of bone by periodontal ligament. The part of jaw bone which supports the tooth is known as ***alveolar bone***.

At birth, normally, no teeth are visible in the oral cavity. In postnatal period, teeth of various sizes and shapes are found in the jaws. The human beings are known as diphyodont as human dentition or consists of two sets of teeth primary and secondary, the details of which are given below:

Key Points

- Primary, deciduous or milk dentition:
  - Total 20 in number
  - 10 in each jaw
  - 5 in each quadrant
  - Start erupting in oral cavity at the age of 6 months
  - Continue to erupt up to two-and-a-half to 3 years
- Secondary, permanent or succedaneous dentition:
  - Total 32 in number
  - 16 in each jaw
  - 8 in each quadrant
  - Start erupting in oral cavity at the age of 6 years.

The teeth are arranged into two dental arches:

1. Maxillary or upper arch
2. Mandibular or lower arch

The arrangement of teeth is symmetrical in the right and left halves in each arch.

Functions of Teeth

- Help in mastication (cutting of food by the incisors, tearing by the canines, chopping by the premolars and grinding by the molars).
- Help in articulation and speech.
- Give a definite shape and beauty to the face. Vertical height of face is maintained by molars. Help to maintain the personality of an individual.
- May be used for self-protection.
- Growth and development of jaws are dependent on tooth.

Vessels of Teeth

The branches of maxillary artery supply the upper and lower set of teeth. The veins join the pterygoid

JAYPEE BROTHERS

venous plexus. Lymph vessels drain mainly into the submandibular nodes.

Nerves of Teeth

- The teeth of upper jaw are supplied by maxillary nerve.
- The lower (mandibular) set of teeth are supplied by inferior alveolar nerve, which is a branch of mandibular nerve.

Palate (Fig. 5.6)

Palate forms the arched roof of the oral cavity and the floor of the nasal cavities. It separates the nasal cavities and nasopharynx from the oral cavity.

Parts

The palate consists of two regions:

1. The anterior 2/3rd or bony part, called the hard palate.
2. The mobile, posterior 1/3rd or fibromuscular part, known as the soft palate.

Hard palate

- The hard palate is formed by the palatine processes of maxillae and the horizontal processes of palatine bones.
- Anteriorly and laterally, the hard palate is bounded by alveolar processes and gums.
- Posterior to the central incisor teeth, there is an incisive foramen, which leads into incisive canal. This canal transmits nasopalatine nerve and sphenopalatine artery.

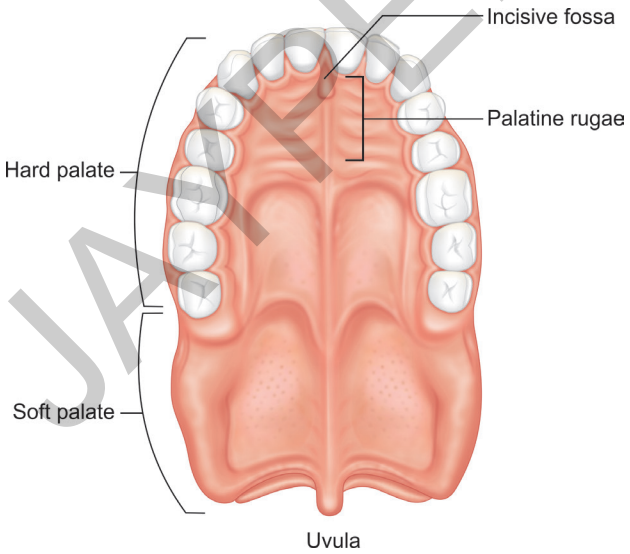

Fig. 5.6: Palate (schematic representation).

- Medial to 3rd molar tooth is the greater palatine foramen through which greater palatine nerve and vessels emerge from the greater palatine canal.
- The hard palate is covered by mucous membrane that is firmly attached to the bone.
- There are numerous mucus-secreting palatine glands deep to the mucosa.

Soft palate

- The soft palate is a movable, fibromuscular fold, that is attached to the posterior edge of the hard palate.
- The soft palate shows a conical process called uvula (L. uva = grape) which hangs from its posterior, curved, free margin.
- Laterally, the soft palate is continuous with the wall of the pharynx and is joined to the tongue and pharynx by the palatoglossal and palatopharyngeal arches respectively.
- The palatine tonsil is located in the triangular interval between the palatoglossal and palatopharyngeal arches.

Muscles of Soft Palate—Five Pairs

1. Levator palati
2. Tensor palati
3. Palatoglossus
4. Palatopharyngeus
5. Musculus uvulae

The expanded tendon of tensor palati muscle forms the palatine aponeurosis which strengthens the soft palate.

Nerves of the Palate

- ***Sensory***: Greater and lesser palatine nerves.
- ***Motor***: All the muscles of the palate are innervated by pharyngeal plexus formed by cranial part of accessory and vagus nerves; the tensor palati is an exception, which is supplied by mandibular nerve.

APPLIED ANATOMY

Cleft Lip and Cleft Palate (Figs. 5.7A and B)

- Cleft lip and cleft palate are congenital facial and oral malformations that occur early in pregnancy. A cleft is a fissure or opening or a gap.
- A cleft lip is a physical split or separation of the two sides of the upper lip that appears as a gap in the skin of upper lip. This gap can be on one side or both sides and often extends beyond the base of the nose.

Contd...

JAYPEE BROTHERS

Contd...

- Palate develops from three palatal processes which unite along a Y-shaped line. Non-union of these processes results in cleft palate.
- A cleft palate is a split or gap in the roof of the mouth. It can involve the hard palate and/or the soft palate.
- Cleft lip and cleft palate can occur together or separately and can be successfully corrected with surgery, if conducted soon after birth or in early childhood.
- ***Paralysis*** of muscles of the palate leads to **nasal regurgitation** and gives a "**nasal sound**" to the voice.
- **Poliomyelitis** affecting the medulla oblongata—**bulbar poliomyelitis**—often leads to paralysis of palate.

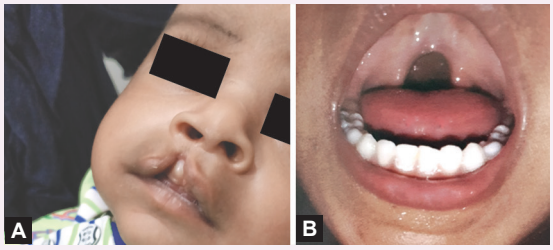

Figs. 5.7A and B: A. Cleft lip; B. Cleft palate.
Courtesy: Dr Prathap Somnath, Professor and HOD, Paediatric Surgery, Government Medical College, Kozhikode.

Tongue

The tongue (lingua, glossa) is a highly mobile muscular organ that can vary greatly in shape. It is situated partly in the mouth and partly in the oropharynx.

Parts

It has a root, body, tip, a dorsal surface, a ventral surface and two lateral borders.

Functions

Tongue is concerned with:
- Mastication (chewing)
- Taste
- Deglutition (swallowing)
- Articulation/speech
- Oral cleansing

Dorsal surface (Fig. 5.8)

- The dorsal surface of tongue is covered by mucous membrane.
- A V-shaped groove, the sulcus terminalis, divides this surface into anterior two-third or palatine part and posterior one-third or pharyngeal part **(Fig. 5.8).**
- At the apex of the V is a small ***foramen cecum***.
- A shallow median groove extends from the tip to the foramen cecum, dividing the anterior two-third into right and left halves.

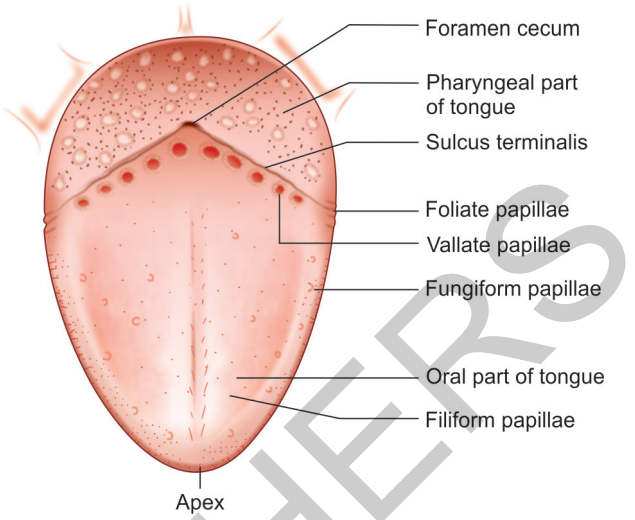

Fig. 5.8: Dorsal surface of tongue (schematic representation).

- The mucous membrane of anterior two-third of dorsum of tongue is rough due to the presence of microscopic projections called ***papillae***.
- Mucous membrane of posterior one-third of tongue shows collections of lymphoid tissue called ***lingual tonsil***.

Ventral surface (Fig. 5.9)

- The ventral surface of the tongue is covered by smooth mucous membrane, devoid of papillae.
- There is a median mucous fold, the frenulum linguae, stretching from this surface to the floor of the mouth.
- On either side of the frenulum, the deep lingual vein can be seen **(Fig. 5.9)**.

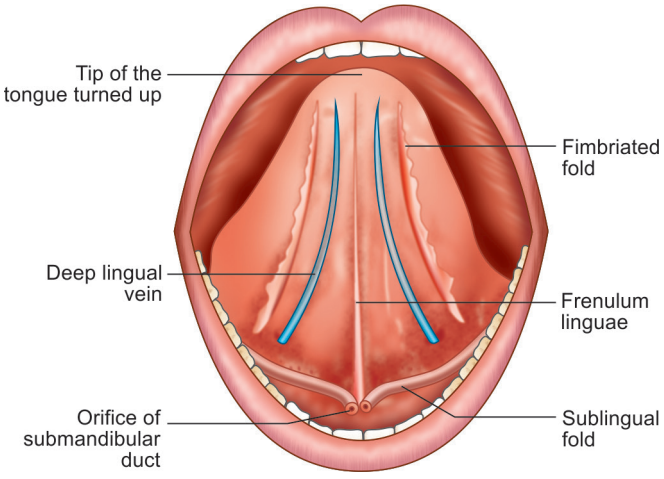

Fig. 5.9: Ventral or inferior surface of tongue and floor of mouth (schematic representation).

JAYPEE BROTHERS

APPLIED ANATOMY

- While measuring oral temperature, the patient is asked to hold the thermometer in the mouth specifically below the lingua (tongue), which measures the core temperature and is highly vascular.
- Nitroglycerine is a drug of choice administered sublingually (that is it is placed below the tongue) to treat angina.

Muscles of the Tongue (Figs. 5.10 and 5.11)

Muscles of the tongue are grouped into two parts: Intrinsic muscles and extrinsic muscles.

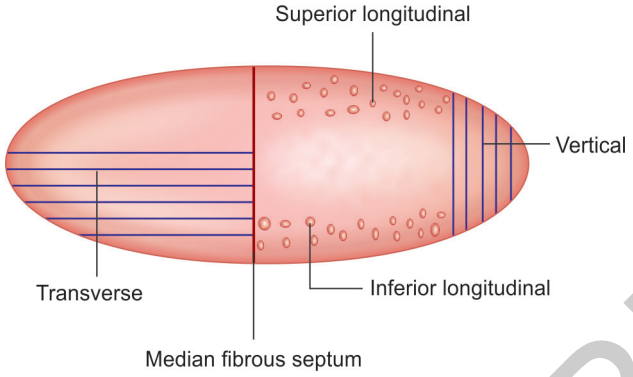

Fig. 5.10: Intrinsic muscles of tongue (schematic representation).

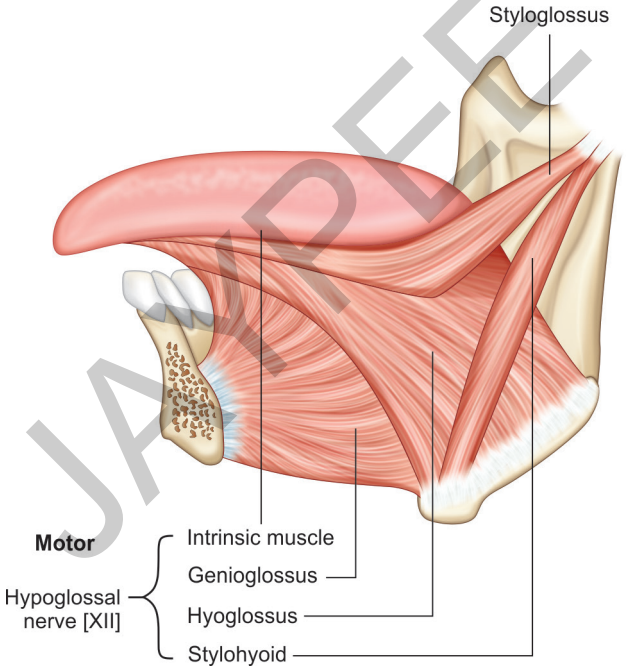

Fig. 5.11: Extrinsic muscles of the tongue (schematic representation).

The intrinsic muscles

A median fibrous septum divides the tongue into right and left halves. Each half has four intrinsic muscles **(Fig. 5.10):**

Classification of muscles of tongue	
Intrinsic	***Extrinsic***
• Superior longitudinal muscle • Inferior longitudinal muscle • Transverse muscle • Vertical muscle	• Genioglossus • Hyoglossus • Styloglossus • Palatoglossus
Note: All muscles except palatoglossus are supplied by hypoglossal nerve. Palatoglossus is supplied by cranial accessory through vagus.	

Nerve Supply

Motor nerve supply (Fig. 5.12)

- All the intrinsic and extrinsic **muscles** of tongue, except palatoglossus are supplied by the **hypoglossal nerve**.
- The palatoglossus is supplied by cranial accessory through vagus.

Sensory nerve supply (Fig. 5.12)

- Tongue is divided into anterior two-third and posterior one-third.
- In the anterior two-third of tongue, **general sensory** (pain, temperature, touch, pressure, etc.) supply is by the **lingual nerve**, a branch of mandibular nerve (which is a branch of trigeminal, the V cranial nerve).
- **Special sensory** (gustatory or taste) supply is by the **chorda tympani** branch of facial nerve (VII cranial nerve).

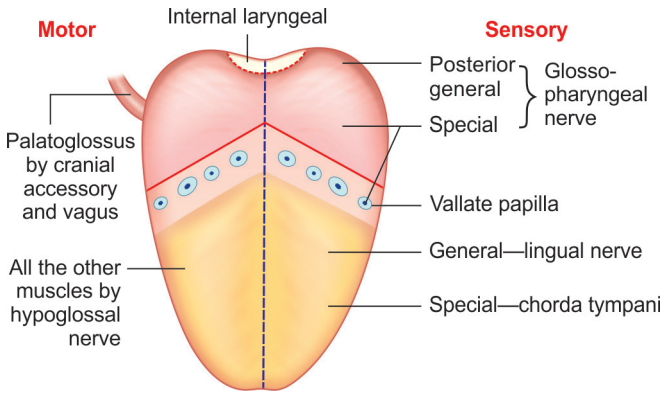

Fig. 5.12: Nerve supply of the tongue (schematic representation).

JAYPEE BROTHERS

- Both the **general and special** sensations **from the posterior one-third** of the tongue are carried by the **glossopharyngeal nerve** (IX cranial).
- The **posterior most part** is supplied by **internal laryngeal nerve**, a branch of vagus.
- **The circumvallate papillae**, even though situated anterior to sulcus terminalis, are supplied by **glosso-pharyngeal nerve** (due to developmental reasons).

Blood Supply

- The lingual arteries (branch of external carotid artery) supply blood to the tongue.
- The corresponding veins drain into the internal jugular veins.

Lymphatic Drainage

Lymph from the tongue drains into the superior and inferior **deep cervical lymph nodes** (mainly into the **jugulo-omohyoid**).

Papillae

Each papilla consists of a lining of epithelium and a core of connective tissue. The epithelium over the papillae is partially keratinized.

The papillae are of various types **(Figs. 5.13A to D)**:

- ***Filiform papillae:*** They are the most numerous papillae. They are small and conical in shape. The epithelium at the tips of these papillae is keratinized. It may project in the form of threads.
- ***Fungiform papillae:*** At the apex of the tongue and along its lateral margins, there are larger fungiform papillae with rounded summits and narrower bases. Fungiform papillae bear taste buds (described below). In contrast to the filiform papillae, the epithelium on fungiform papillae is not keratinized.
- ***Circumvallate papillae:*** These are the largest papillae of the tongue. They are arranged in a row just anterior to the sulcus terminalis.
- When viewed from the surface, each papilla is seen to have a circular top demarcated from the rest of the mucosa by a groove. In sections through the papilla, it is seen that the papilla has a circumferential' lateral wall' that lies in the depth of the groove **(Fig. 5.14)**. Taste buds are present on this wall, and also on the 'outer wall' of the groove.
- ***Foliate papillae:*** These are rudimentary in a human being. They can be seen along the posterior part of lateral margin of the tongue.

Taste Buds (Fig. 5.14)

- They are small, barrel-shaped structures, arranged along the sides of the grooves that surround the vallate or fungiform papillae.
- A taste bud has a layered appearance like an onion under the microscope.
- There is a pit, called inner taste pore, near the surface of the bud.
- Any substance to be tasted gets dissolved in saliva and passes through the taste pore into the pit of the taste bud, where it stimulates the neuroepithelial cells.
- These cells are richly innervated. So, a nerve impulse is set up.

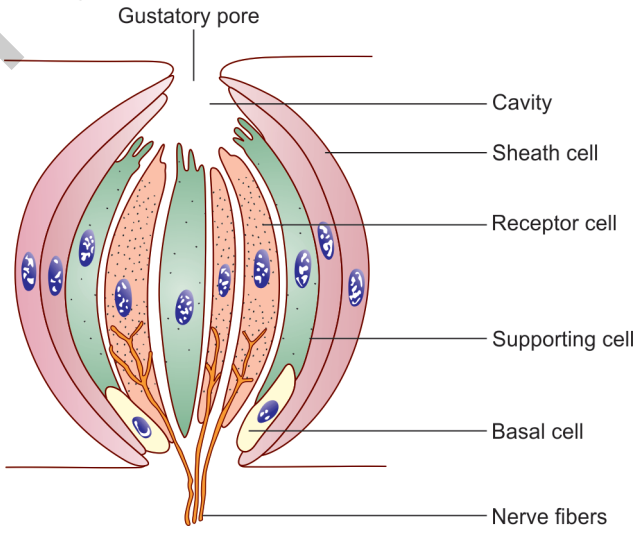

Fig. 5.14: Structure of a taste bud (schematic representation).

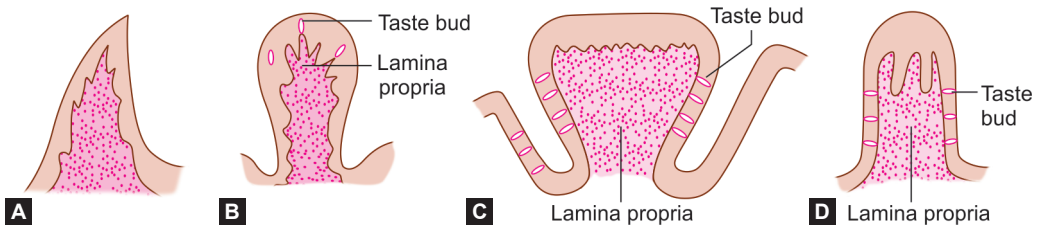

Figs. 5.13A to D: Papillae: A. Filliform; B. Fungiform; C. Circumvallate; D. Foliate (schematic representation).

JAYPEE BROTHERS

APPLIED ANATOMY

- Carcinoma of the tongue is common. Surgical removal of affected side is known as hemiglossectomy **(Fig. 5.15)**.



Fig. 5.15: Carcinoma of tongue.

Contd...

- When quick absorption of a drug is required, e.g., nitroglycerin, a vasodilator used in angina pectoris, they are placed under the tongue where they dissolve and enter the deep lingual veins in less than a minute.
- In unconscious patients, the tongue may fall back and obstruct the air passage. So, the patient can be made to lie on one side with head down.

PHARYNX (FIG. 5.16)

The pharynx is a wide muscular tube, situated behind the nose, mouth and larynx. It is about 13 cm long. Its upper part is the widest (3.5 cm) and lower part is the narrowest part of gastrointestinal tract (except the appendix). Inferiorly it continues with the esophagus through oropharyngeal junction.

Contd...

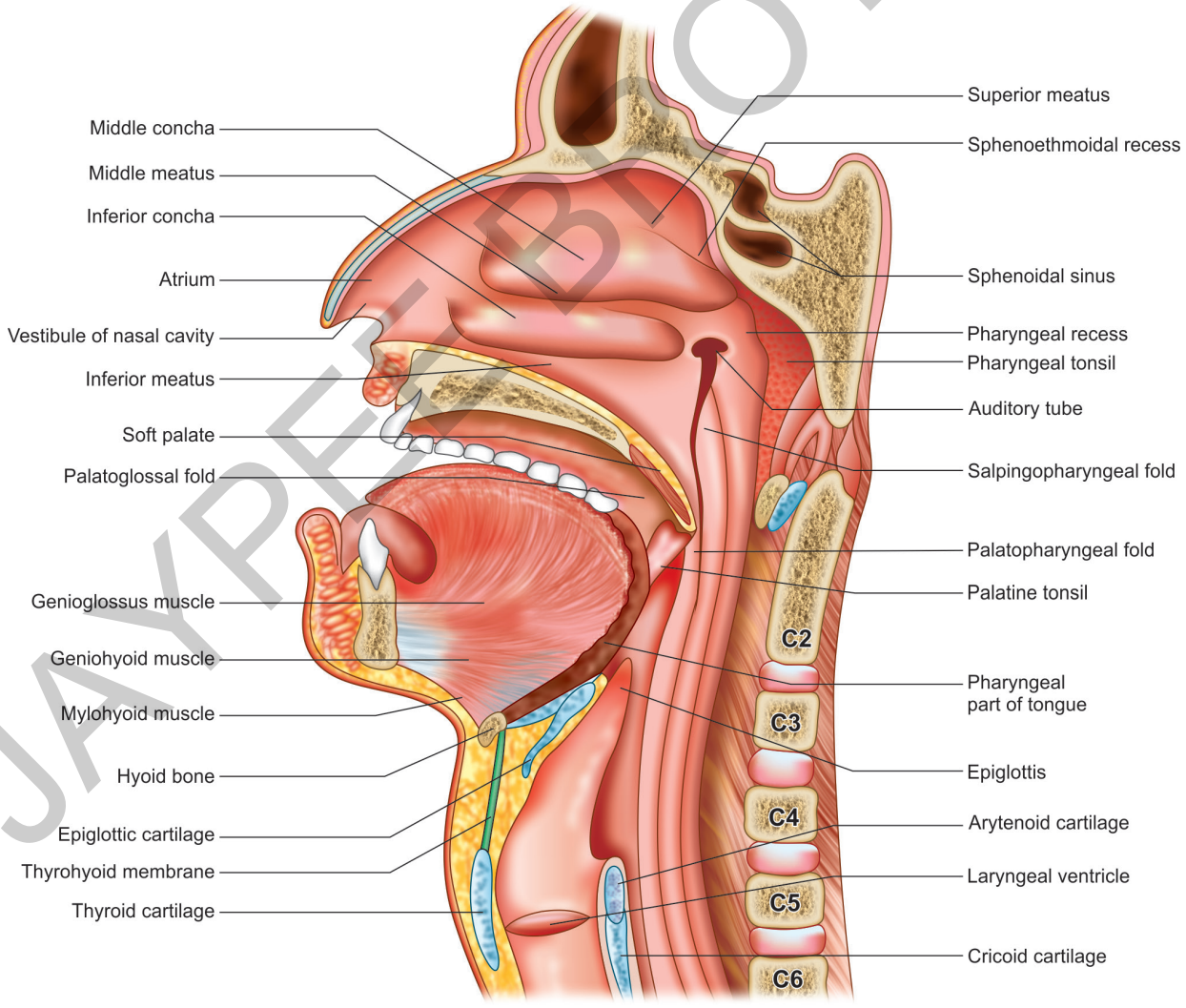

Fig. 5.16: Paramedian section of the pharynx (schematic representation).

JAYPEE BROTHERS

Parts of Pharynx

The cavity of pharynx is divided into:

- *The nasal part*: Nasopharynx
- *The oral part*: Oropharynx
- *The laryngeal part*: Laryngopharynx

Nasopharynx

- This part is situated behind the nose.
- It resembles the nose structurally and functionally. It is respiratory in function.
- It is lined by ciliated columnar epithelium.
- Anteriorly, it communicates with the nasal cavities, through the posterior nasal apertures.
- Inferiorly, it becomes continuous with the oropharynx.
- The lateral wall of the nasopharynx shows the pharyngeal opening of the auditory tube or Eustachian tube.
- Near the junction of the roof and posterior wall of the nasopharynx, there is a collection of lymphoid tissue called the ***pharyngeal*** or ***nasopharyngeal tonsil***.
- It is better developed in children. A pathologically enlarged pharyngeal tonsil is called ***adenoid***.
- Another collection of lymphoid tissue is present in the nasopharynx, behind the opening of the auditory tube—it is called ***tubal tonsil***.

Functions

- *Airway:* A conduit for air to its way to the larynx and trachea.
- *Middle ear ventilation:* Eustachian tube ventilates the middle ear and equalizes air pressure on both sides of the tympanic membrane. Dysfunctions of Eustachian tube can affect the middle ear.
- *Resonance:* It is a part of resonating chamber for voice production. Nasopharyngeal obstruction produce changes in voice.
- *Drainage:* It is a drainage channel for nasal and nasopharyngeal mucus secretions.
- *Nasopharyngeal isthmus*: It cuts off the nasopharynx from the oropharynx during swallowing, vomiting, gagging and delivering of speech.

Oropharynx

- It is the middle part of the pharynx situated behind the oral cavity.
- Superiorly it communicates with oral cavity through the oropharyngeal isthmus (isthmus of fauces).
- Inferiorly, it opens into the laryngopharynx.
- The lateral wall of oropharynx presents the palatine tonsil, lying between the palatoglossal and palatopharyngeal arches.
- Palatine tonsils are discussed in detail in **Chapter 8**.

Functions

- A common conduit for the passage of both air and food.
- Oropharyngeal phase of deglutition.
- Taste: The base of tongue, soft palate, anterior pillars and posterior pharyngeal wall contain taste buds.

Laryngopharynx (Fig. 5.17)

- Laryngopharynx is situated behind the larynx.
- It extends from the upper border of epiglottis to the lower border of cricoid cartilage.
- The lateral wall of laryngopharynx shows a depression called the ***piriform fossa or sinus***, one on each side of the inlet of larynx.
- This shallow depression is bounded by the aryepiglottic fold medially; by thyroid cartilage and thyrohyoid membrane laterally.
- The internal laryngeal nerve lies deep to the mucosa lining this fossa.
- Piriform fossa is a common site where foreign bodies can get arrested.

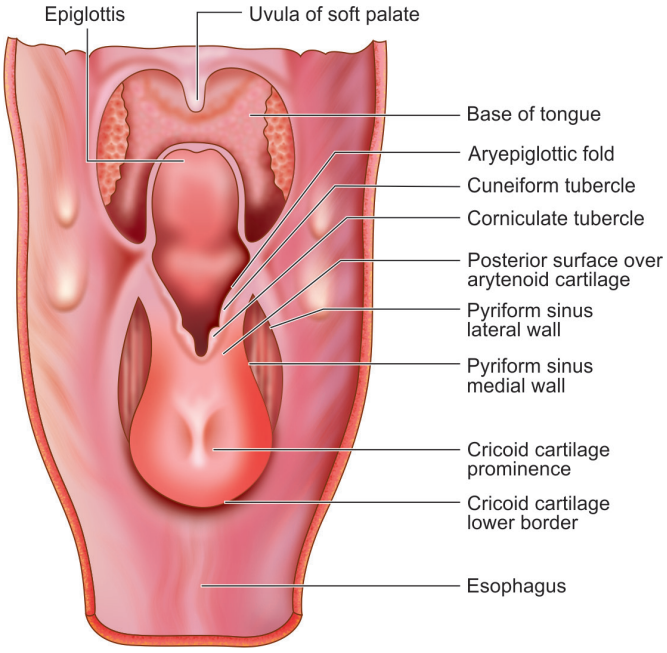

Fig. 5.17: Posterior view of laryngopharynx (schematic representation).

JAYPEE BROTHERS

Added Information

ADENOIDS

These nasopharyngeal tonsils, which are covered with ciliated columnar epithelium, are situated at the junction of the roof and posterior wall of the nasopharynx. Adenoids are composed of lymphoid tissue. Adenoid tissue shows physiological enlargement during the first 6 years of life and then tends to regress and almost completely disappears by 20 years of age.

Inflammation of adenoids is called adenoiditis, which is common in children.

Waldeyer's Ring (Fig. 5.18)

Mucosa-associated lymphoid tissue (MALT) in subepithelial layer of pharynx is aggregated at the entrance of aerodigestive tract and are collectively called Waldeyer's ring.

Waldeyer's Ring

Waldeyer's ring consists of:

- Adenoids or nasopharyngeal tonsil
- Tubal tonsils (fossa of Rosenmuller)
- Lateral pharyngeal bands
- Palatine tonsils
- Nodules (posterior pharyngeal wall)
- Lingual tonsils

Functions of Tonsils and Adenoids

- ***Immunology and host defenses***
- ***Sentinels at the portal of aerodigestive tract***: Oropharyngeal subepithelial masses of lymphoid tissues, which form the part of Waldeyer's ring, act as protective sentinels against harmful intruders into the air and food passages.

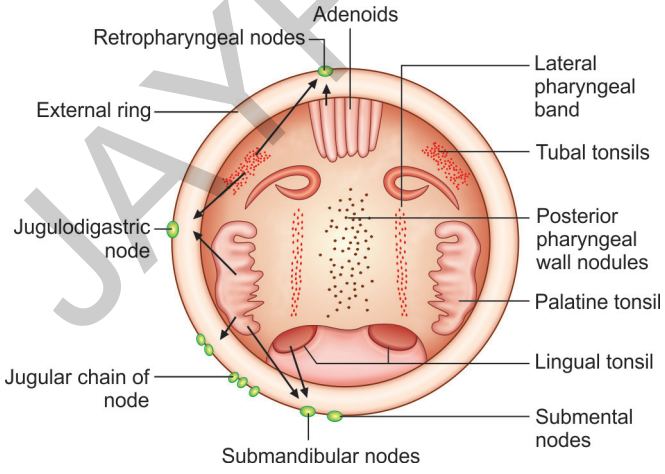

Fig. 5.18: Waldeyer's ring (schematic representation).

- ***Antibody production, especially secretory IgA***: B-lymphocytes in the germinal centers of these lymphoid follicles produce an IgA.

Muscles of Pharynx

- There are three pairs of constrictors—superior, middle and inferior.
- Other muscles of the pharynx are stylopharyngeus, salpingopharyngeus and palatopharyngeus.

Nerve Supply of Pharynx

- The pharynx is supplied by the pharyngeal plexus of nerves, formed by motor fibers of cranial accessory nerve, sensory fibers from glossopharyngeal nerve and branches from sympathetic chain.
- All the muscles of pharynx are supplied by the pharyngeal plexus except stylopharyngeus which is supplied by glossopharyngeal nerve.

SALIVARY GLANDS (FIG. 5.19)

The secretions of these glands help to keep the mouth moist and provide a protective and lubricant coat of mucus.

Classification of salivary glands		
Based on the presence of duct	***Based on the absence of duct***	***Based on the type of secretion***
Major salivary glands—3 pairs	Minor salivary glands	
1. Parotid	1. Labial	1. Serous
2. Submandibular	2. Buccal	2. Mucus
3. Sublingual	3. Lingual	3. Mixed
	4. Palatine	
Note: Tumors arising from minor salivary glands are mostly malignant.		

Classification of Salivary Glands

- ***Based on the presence or absence of duct***
  - ***Major salivary glands:*** These are those glands which discharge their secretions into the oral cavity through a duct. Major salivary glands are: (1) parotid, (2) submandibular, and (3) sublingual **(Table 5.1)**.

Table 5.1: Ducts of major salivary glands.

Gland	Duct
Parotid gland	Stensen's duct
Submandibular gland	Wharton's duct
Sublingual gland	Ducts of Rivinus

JAYPEE BROTHERS

for detailed information on allied health books, visit our website www.jaypeebrothers.com, for detailed information on allied health books, visit our website www.jaypeebrothers.com, for deta

Essentials of ANATOMY & PHYSIOLOGY for Allied Health Sciences

Salient Features

- Helpful textbook for students of Allied Health Sciences as it covers all major body systems, organs, tissues, and their functions in detail.
- Rich visual aids, more than 800 diagrams and photographs, about 100 tables and 100 flowcharts are used to help in understanding the anatomy.
- Clear, concise, and easy-to-understand explanations of complex anatomical and physiological concepts without overwhelming jargon.
- Pedagogical tools like tables, boxes, mnemonics, charts, appendices, clinical correlations to facilitate and retention of information.
- Use of lucid language for better understanding.
- Prenatal diagnosis of genetic disorders is gaining more importance in the prevention of birth of children with serious congenital anomalies.
- Review questions are added at the end of each chapter, which will enable the students to face the examination with confidence.

PR Ashalatha MBBS MS (Anatomy) is currently working as Professor and Head, Department of Anatomy, Malabar Medical College and Research Center, Ulliyeri, Kozhikode, Kerala, India. *Former* Professor and Head, Government Medical College, Kozhikode, Kerala, India. She graduated from Government Medical College, Kozhikode in the year 1988 and did her postgraduation in Anatomy from the same institution. Students of this institution have selected her as the "Best Teacher in Anatomy". She is the author of *Textbook of Anatomy for Nurses* and *Textbook of Anatomy and Physiology for GNM Students*. She has keen interest in Medical Genetics and has undergone training in Genetics from AIIMS, New Delhi; CCMB, Hyderabad, Telangana, India and CMC, Vellore, Tamil Nadu, India. She has published several research papers in national and international journals. Students of GMC Kozhikode and MMC Ulliyeri have selected her the "Best Teacher in Anatomy".

G Deepa MBBS MD (Physiology) is Associate Professor, Department of Physiology, Government Medical College, Thiruvananthapuram, Kerala, India. She graduated in Medicine from Government TD Medical College, Alappuzha, Kerala and Masters in Physiology from Government Medical College, Kozhikode, Kerala, India. She is interested in research in medical physiology and has published research articles.

Printed in India

Available at all medical bookstores or buy online at www.ejaypee.com

JAYPEE BROTHERS
Medical Publishers (P) Ltd.
EMCA House, 23/23-B, Ansari Road,
Daryaganj, New Delhi - 110 002, INDIA
www.jaypeebrothers.com

Join us on facebook.com/JaypeeMedicalPublishers
Follow us on instagram.com/JaypeeMedicalPublishers

Shelving Recommendation
ALLIED HEALTH

ISBN 978-93-6616-149-5