it our website www.ejaypee.com, for detailed information on radiology books, visit our website www.ejaypee.com, for detailed information on radiology books, visit our website www.ejaypee.com,

Textbook of RADIOLOGY

For X-ray, CT, MRI, BSc, BRIT and MSc Technicians

With Review Questions & MCQs

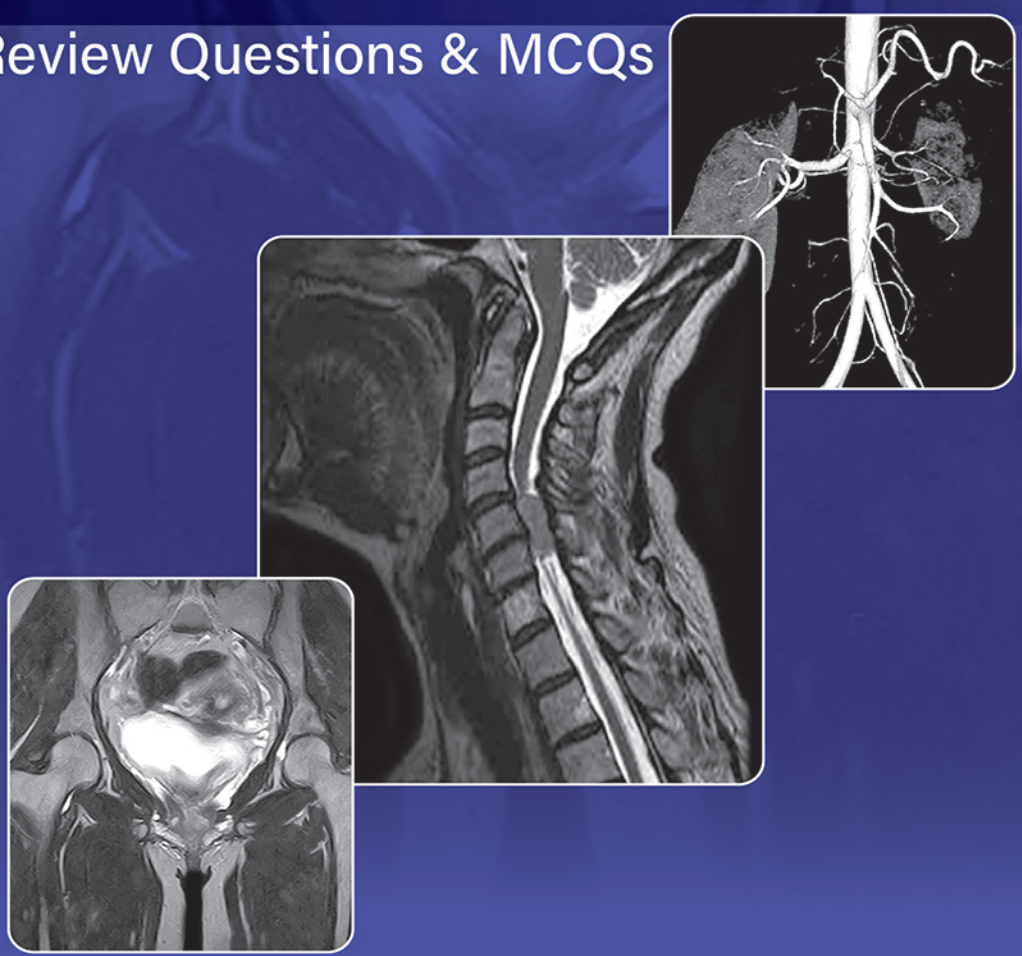

Sachin Khanduri

3rd Edition

JAYPEE

Contents

SECTION 1: INTRODUCTION TO RADIOLOGY

Chapter 1: Basics of Radiology 3
- Radiology Modalities *3*
- Ionizing Radiation *3*
- Nonionizing Radiation *4*
- X-rays *4*
- Ultrasound *6*
- Ultrasonography in Emergency *8*
- Transducer *9*
- Obstetric Ultrasound *10*
- Computed Tomography Scan *16*
- Magnetic Resonance Imaging *17*

Chapter 2: Role of Contrast Media 20
- Types of Contrast *20*
- Inherent Image Contrast in X-ray and CT Images *20*
- Properties of an Ideal Contrast Medium *20*
- Side Effects and Reactions *21*
- Prevention of Reactions *21*
- Management of Acute Reactions to Contrast Media *21*
- MRI Contrast Media *21*
- CT Contrast Media *23*

Chapter 3: Radiation Hazards and Protection 25
- Regulatory Body *25*
- Sources of Radiation *25*
- Radiation Hazards *25*
- Biological Effects of Radiation *27*
- Principles of Radiation Protection *28*

SECTION 2: X-RAYS

Chapter 4: Production and Properties of X-rays 35
- Basic Physics of X-ray Production *35*
- Overview: How X-rays are Produced *35*
- Equipment for X-ray Production *35*
- Producing an X-ray Beam *36*
- X-ray Spectrum *38*
- Quality and Quantity of X-rays *39*
- Properties of X-rays *39*

Chapter 5: Special Contrast Procedures in X-rays 41
- Urinary System *41*
- Female Genital Tract *45*
- Male Genital Tract *47*
- Digestive System *47*
- Biliary Tract *52*
- Dacryocystography *53*
- Orbital Venography *54*
- Sialography *54*
- Nasopharyngography *54*
- Laryngography *54*
- Bronchography *54*
- Arthrography *54*
- Central Nervous System *54*
- Diagnostic Visceral and Peripheral Angiography *55*

Chapter 6: Synopsis of X-ray Positioning 57
- Summary of X-ray Positioning *57*

Chapter 7: X-Ray Films, Screens and Radiography 73
- Radiographic Cassettes *73*
- Intensifying Screen *73*
- X-ray Film *74*
- Grid *76*
- Darkroom *77*

Chapter 8: Recent Advances in X-rays 79
- Digital Radiography *79*
- Working of Digital Radiography *80*
- Picture Archiving and Communication System *81*
- Computed Radiography *82*
- Tomosynthesis *82*
- Dexa Scan—Dual-energy X-ray Absorptiometry *83*
- Fluoroscopy *85*
- Digital Fluoroscopy and Radiography *87*

Chapter 9: Common X-ray Pathologies 90
- Normal Radiographic Shadows on a Standard Postero-anterior Chest X-ray *90*
- Occupational Lung Diseases *91*
- Miliary Tuberculosis *91*
- Fungal Ball *92*
- Lung Abscess *92*
- Aspiration Pneumonitis *93*

- Common Pathologies on Abdominal X-rays *93*
- Common Bone Tumors *94*

SECTION 3: MAMMOGRAPHY

Chapter 10: Basics of Mammography 99
- Breast Anatomy *99*
- Radiological Requirements for Mammography *99*
- Standard Mammographic Views *100*
- Screen-film System *101*
- Mammography X-ray Equipment *102*
- Magnification Mammography *103*
- Digital Mammography *103*
- Digital Breast Tomosynthesis *104*

SECTION 4: COMPUTED TOMOGRAPHY

Chapter 11: Computed Tomography Physics 109
- Scanning Principle *109*
- Computed Tomography Methodology *109*
- Generations *110*
- Advantages and Disadvantages of Computed Tomography over Conventional Radiography *115*
- Advantages and Disadvantages of Computed Tomography over Multi Detector Computed Tomography *116*
- Advantages and Disadvantages of Computed Tomography over Magnetic Resonance Imaging *116*

Chapter 12: Indications and Contraindications 119
- Advantages of CT *119*
- Indications for Use of Computed Tomography *119*
- Contraindications for Use of Computed Tomography *121*
- Contrast Medium *122*
- Pressure Injectors *122*

Chapter 13: Patient Preparation, Positioning and Contrast Administration 127
- Patient Positioning for Computed Tomography Scan *127*
- CT Contrast Agents *128*
- Classification of Iodinated CT Contrast Media *128*
- Guidelines for Intravenous Administration of Iodinated Contrast Media *130*
- Injection Techniques and Safety Measures *130*
- Renal Function Considerations Before ICM Injection3 *130*
- Risk Factors for Acute Adverse Reaction *130*
- Types of Adverse Reaction *130*
- Contrast-induced Nephropathy *131*
- CT Imaging Protocols *132*

Chapter 14: Computed Tomography Anatomy 138
- CT Head *138*
- CT Neck *140*
- CT Thorax *140*
- CT Larynx *141*
- CT Cardiac *142*
- CT Spine *142*
- CT Abdomen *143*

Chapter 15: Basic Computed Tomography Pathologies 149

Head 149.
- Brain Hematomas *149*
- Ischemic Stroke *151*
- Neurocysticercosis *151*
- Brain Tumors *151*
- Cerebral Arteriovenous Malformation *151*
- Brain Abscess *153*
- Metastasis to Brain *153*

Thorax 154
- Tuberculosis *154*
- Occupational Lung Diseases *155*
- Bronchogenic Carcinoma *156*
- Mediastinal Masses *156*

Hepatobiliary System 158
- Gallbladder Carcinoma *158*
- Cholelithiasis *158*
- Cholangiocarcinoma *159*
- Hepatic Hemangioma *160*

Pancreas 162
- Acute Pancreatitis *162*
- Pancreatic Pseudocyst *162*
- Computed Tomography Findings *162*

Genitourinary Tract: Renal 163
- Urolithiasis (Urinary Tract Calculus) *163*
- Dual-energy CT (Dect) in Renal Stone Analysis *163*
- Renal Cell Carcinoma *163*
- Autosomal Dominant Polycystic Kidney Disease *164*

Urinary Bladder 164
- Transitional Cell Carcinoma of the Bladder *164*

Bowel 165
- Bowel Obstruction *165*
- Abdominal Tuberculosis *166*
- Ulcerative Colitis *166*
- Carcinoma of the Esophagus *167*
- Carcinoma Colon (Colorectal Cancer—CRC) *167*
- CA Rectum *167*

Bones 168
- Fractures *168*
- Osteosarcoma *169*
- Ewing's Sarcoma (Ewing's Tumor) *170*
- Giant Cell Tumor *170*
- Bone (Spine) Metastasis *171*

Chapter 16: Recent Advances in Computed Tomography 174
- Advances in Hardware *174*
- Cone-beam Computed Tomography Scanner *174*
- Helical and Multislice Computed Tomography Helical Computed Tomography *175*
- Multidetector Computed Tomography *176*
- Dual Energy Computed Tomography *177*
- Positron Emission Tomography Scan *178*
- CT Fluoroscopy *181*
- Electron Beam Tomography *182*
- Photon-counting Computed Tomography *182*
- Ultra High-resolution CT (UHR-CT) *183*
- Low Dose and Dose Optimization Technologies in Medical Imaging *183*
- Advances in Cardiac CT *184*
- AI-powered Image Reconstruction and Analysis *184*
- Portable CT Scanners *185*

Chapter 17: Computed Tomography Guided Interventions 187
- Materials and Methods *187*
- Computed Tomography-guided Procedure *188*
- CT Dosimetry *191*
- Main Risks and Complications of Computed Tomography-guided Interventions *192*
- Pitfalls *193*

Chapter 18: Computed Tomography Angiography 195
- Procedure of CT Angiography *195*
- Contraindications *196*
- Relative Contraindications *196*
- Benefits of CT Angiography over Digital Subtraction Angiography *196*
- Specialized CT Angiography Applications *197*
- Lower Limb Angiography *200*
- Brain Angiography *200*
- Digital Subtraction Angiography *201*

Chapter 19: Computed Tomography Artifacts 204
- Classification of Artifacts *204*
- Advances in Artifact Reduction Technologies *209*

SECTION 5: MAGNETIC RESONANCE IMAGING

Chapter 20: Magnetic Resonance Imaging Physics and Sequences 213
- MRI System *213*
- MRI Physics and Principles *216*
- Proton Precession *216*
- MRI Sequences *218*
- Advanced Sequences *222*

Chapter 21: Magnetic Resonance Imaging Contrast Agents 227
- MRI Contrast Agents: Importance and Applications *227*
- Contrast Agents *227*
- MRI Contrast Agent Safety *228*
- Conclusion *228*
- Pressure Injector *228*
- Ultrahigh Field Magnetic Resonance Imaging *229*

Chapter 22: Indications, Contraindications, Patient Preparation and Positioning 231
- Indications and Contraindications for MRI *231*
- MRI-Patient Preparation and Positioning *231*
- Magnetic Resonance Cholangiopancreatography *235*
- Enterography *237*
- MR Enteroclysis *238*
- Defecography *238*

Chapter 23: Magnetic Resonance Imaging Anatomy 241
- MRI Brain *241*
- MRI Neck *243*
- MRI Spine *244*
- MRCP *244*
- MRI Abdomen *245*
- MRI Male Pelvis *246*
- MRI Anatomy of Female Pelvis *246*
- MRI Hip Joint *247*
- MRI Shoulder *247*
- MRI Knee *248*
- MRI Thorax *248*

Chapter 24: Magnetic Resonance Imaging Pathologies 257

Bone Tumors 257
- Classification *257*
- Introduction *257*
- Basic View *258*
- Benign Bone Tumors *258*
- Malignant Bone Tumors *261*

Central Nervous System 262
- Dandy-walker Malformation *262*
- Arnold-chiari Malformation *262*
- Intracranial Infections *263*
- White Matter Disease *263*
- Intracranial Hemorrhage *266*
- Hypoxic-ischemic Encephalopathies *266*
- Intracranial Neoplasm *268*

Hepatobiliary System 270
- Liver *270*
- Pancreas *276*
- Spleen *278*
- Gallbladder *279*
- Common Bile Duct *279*
- Portal Vein *281*

Thorax 282
- Introduction *282*
- Mediastinum *282*
- Neurogenic Tumors *282*
- Thymoma *282*

- Cystic Masses 282
- Aorta 282
- Heart and Pericardium 284

Shoulder Joint 284
- Magnetic Resonance Imaging Standard Views 284
- Full Thickness Tear 285
- Partial Thickness Tears 285
- Impingement 286
- Types of Acromion 286

Knee Joint 287
- Indications of Knee Joint Magnetic Resonance Imaging 287
- Cruciate Ligaments Injury 288

Wrist Joint 289
- Carpal Tunnel Syndrome 289

Degenerative Diseases of Spine 290
- Introduction 290
- Spondylosis 290
- Disc Bulge 292
- Disc Herniation 292
- Trauma 294
- Spinal Tumors 294
- Metastatic Disease 295

Infection of Bones 296
- Tuberculosis 296
- Pyogenic Infections 298

Infections of Spine 300
- Tuberculosis 300
- Pyogenic Infections 301

Chapter 25: Recent Advances in Magnetic Resonance Imaging 311
- Functional Magnetic Resonance Imaging 311
- Magnetic Resonance Spectroscopy 313
- Magnetic Resonance Elastography 314
- Positron Emission Tomography—Magnetic Resonance Imaging 315
- Real-time Magnetic Resonance Imaging 316
- Cardiovascular Magnetic Resonance Imaging 317

Chapter 26: Magnetic Resonance Imaging Artifacts 322
- Artifacts 322
- Zipper Artifact 322
- Herringbone Artifact 323
- Zebra Stripes/Artifacts 323
- Moire Fringes Artifact 323
- Central Point Artifact 323
- Starry Star Artifact 324
- Radiofrequency Overflow Artifact 324
- Shading Artifact 324
- Slice-overlap Artifact 325
- Cross-excitation Artifact 325
- Motion Artifact 325
- Entry Slice Phenomenon 326
- Black Boundary Artifact 326
- Magic Angle Artifact 327
- Magnetic Susceptibility Artifacts (Susceptibility Artifact) 327
- Chemical Shift Artifact or Misregistration 328
- Dielectric Effect Artifact 328
- Gibbs Artifact/Truncation Artifact 328
- Zero-fill Artifact 328
- Aliasing in Magnetic Resonance Imaging 329

SECTION 6: MISCELLANEOUS

Chapter 27: Radiotherapy 335
- Quantity of Radioactivity 335
- Radiation Source 335
- Linear Acceleration [Linac] 336
- Radiosurgery 336
- Principles of Treatment 338
- Role of Radiotherapy in Cervical Cancer 339
- Role of Radiotherapy in Breast Cancer 339
- Radiotherapy in Ewing Sarcoma 340
- Common Side Effects of Radiation 341
- Newer Advances in Radiotherapy 341

Chapter 28: Imaging in COVID-19 343
- Clinical Features of COVID-19 343
- Assessment and Diagnosis 343
- Approaches to Imaging 343
- Imaging 344
- Post-COVID-19 Sequelae 346
- Follow-up Imaging Protocols 346

Index 349

CHAPTER

17

Computed Tomography Guided Interventions

INTRODUCTION[1]

In general, computed tomography (CT) guided interventions may be divided into:

- Diagnostic intervention
- Therapeutic intervention

Diagnostic Intervention

Typical diagnostic interventions are biopsies, which can be done as aspiration or fine-needle biopsies, punch biopsies, or drill biopsies, depending on the area, accessibility, or the material that has to be biopsied. Aspiration or fine-needle biopsies are generally used to acquire liquid material (most commonly abscess) for a microbiological analysis **(Fig. 17.1)**. Punch biopsies are usually done for lymph nodes before treatment of tumors. It can also be done in parenchymal organs or large pulmonary or pleural masses. Drill biopsies are usually done in bones to classify bone tumors or soft- tissue tumors within bones. Biopsy of mediastinal masses can be performed using fine-needle aspiration or core biopsy, typically under computed tomography guidance to obtain tissue for histopathological analysis. **(Fig. 17.3A to E)** Further diagnostic interventions that can be done under CT guidance include discographies or localization techniques, for example, coil or wire placement prior to video-assisted thoracoscopy surgery of lung mass **(Fig. 17.2)**. Most drainages are done to evacuate abscesses as an established alternative method to surgical intervention. Also, other liquid-filled structures can be drained, such as bilioma, hematoma, seroma, urinoma, cysts, pseudocysts, pleural effusion or empyema, the renal pelvis, and the urinary bladder.

Therapeutic Intervention

A large field of therapeutic intervention is pain management by the use of neurolysis or injection therapy of local anesthesia with or without corticoids.

For example, CT-guided thermal ablation of osteoid osteoma could even be established as a curative treatment of choice.

MATERIALS AND METHODS

General Equipment

Generally, every type of CT scanner (single-slice or multi-slice) can be used for CT-guided interventions. There should be enough space in the scanner room for the radiologist, one or two assistants, the sterile table with the required instruments, and possible further equipment (for example, for anesthesia or even general anesthesia, radiofrequency generators, etc.)

Before every intervention, the scanner room must be carefully cleaned and disinfected with antibacterial, antifungal, and/or antiviral agents, especially the CT table and the gantry. A movable instrument table must be covered with sterile sheets and equipped with syringes of different size (5 mL, 10 mL, and 20 mL) with and without Luer-Lock, hypodermic, and 20 G syringe needles for local anesthesia, anesthetics, saline solution, sterile pads, sterile clear tape to cover the CT gantry's control panel, and sterile sheets for interventional purposes. Furthermore, the procedure-specific materials such as puncture needles, drainages, sample tubes, and specific drugs need to be placed on the table.

The radiologist must perform medical hand washing and wear a surgical cap and mask, sterile gloves, as well as a lead apron.

Desirable Equipment

A monitor within the scanner room is almost mandatory for the radiologist to monitor the procedure.

- A foot pedal to start sequential scans or fluoroscopy makes the radiologist more independent during the procedure and helps to speed up the intervention.
- The patient table can be either moved after covering the control panel with sterile clear tape or pushed directly after manually releasing the table. Newer CT systems also offer a complete control panel fixed at the side of the patient table, where all scanner actions can be carried out by the radiologist under sterile conditions.

JAYPEE BROTHERS

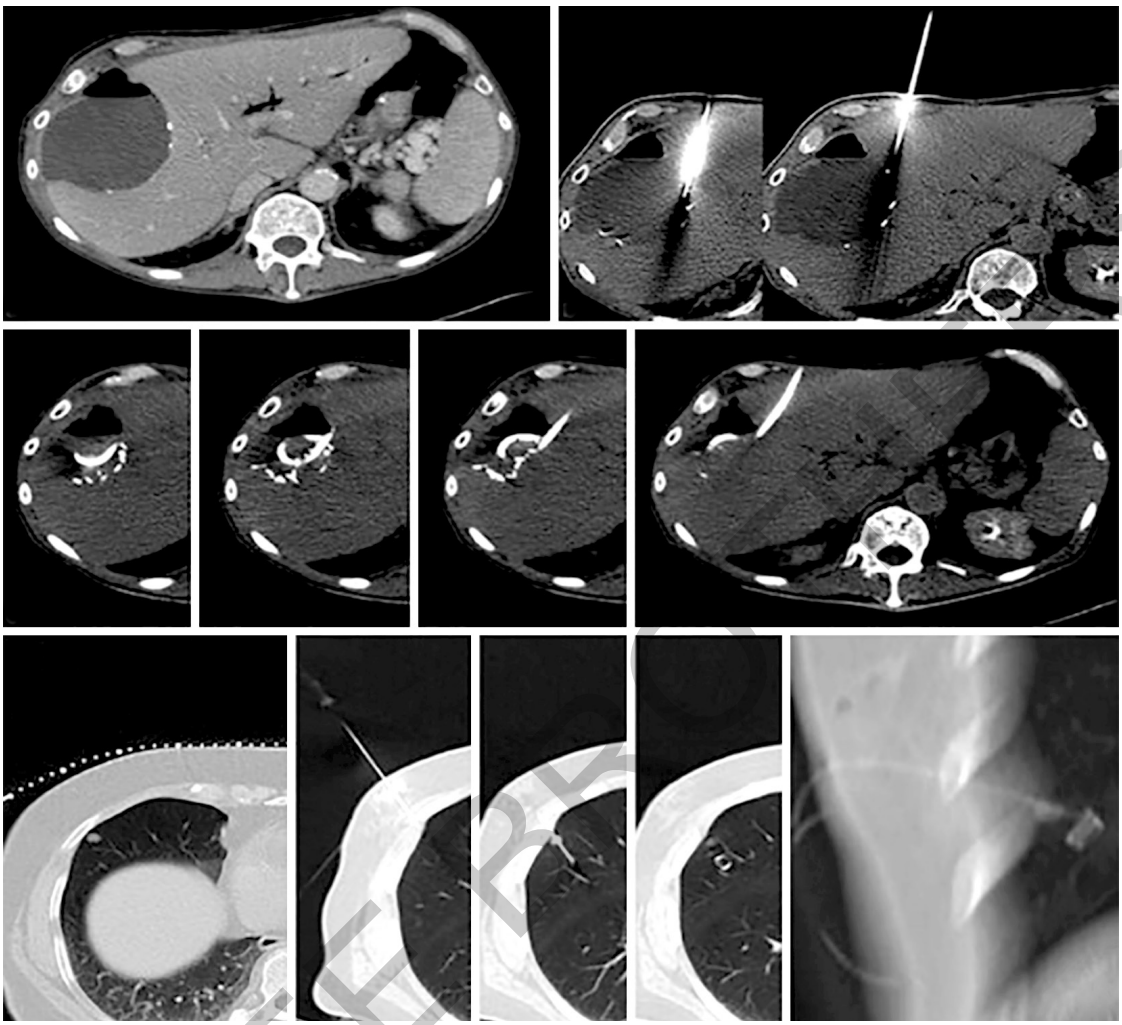

Fig. 17.1: Computed tomography images showing liver abscess drainage.



Fig. 17.2: Computed tomography image showing biopsy of a lung mass.

- Computed tomography scanners with a larger bore, for example, 85 cm, are very practical for CT-guided interventions since they at least partly overcome the narrowness of normal-size CT scanner.

COMPUTED TOMOGRAPHY-GUIDED PROCEDURE

Steps (Table 17.1)

The general course of a CT-guided intervention is as follows:

- The first mandatory step is the review of the radiological examinations that have been done to the patient so far. It is the decision of the radiologist whether he/she will perform the puncture or if alternative approaches (i.e., surgery) have to be considered. If the puncture is determined, the patient needs to be informed about



Figs. 17.3A to E: Computed tomography-guided biopsy of a mediastinal mass.

TABLE 17.1: Step-by-step approach for CT—Guided intervention.

Step no.	*Procedure step*	*Description*
1. Patient preparation	Explain procedure and obtain consent	Ensure patient understanding and proper positioning on the CT table
2. Initial CT scan	Perform a preliminary CT scan	Locate the target area and assess the safest approach
3. Needle path planning	Determine the best entry point and trajectory	Adjust patient positioning if necessary
4. Skin marking and sterilization	Mark the entry site and sterilize the area	Use antiseptic preparation and sterile draping
5. Needle insertion under CT guidance	Advance needle incrementally with CT imaging	Adjust trajectory as needed for precision
6. Position confirmation	Perform a CT scan to verify correct placement	Make fine adjustments if necessary
7. Procedure execution	Perform biopsy, drainage, or ablation	Inject contrast if needed for verification
8. Needle removal and final scan	Withdraw the needle carefully	Conduct post-procedure CT scan for complications
9. Postprocedural care	Monitor patient for adverse reactions	Provide postprocedure care and discharge instructions

the course, the risks, and the possible complications of the procedure, optimally the day before the procedure. Depending on local laws, written consent may be required **(Fig. 17.4)**.

- The knowledge of the patient's blood clotting capabilities [international normalized ratio (INR), platelet count, previous taking of platelet inhibitors, i.e., aspirin] is mandatory before starting the procedure. Generally, the INR should be below 1.7 and the platelet count above 50,000/mm^3.
- Before the procedure, the CT room should be cleaned, and the sterile table should be prepared.
- The patient is placed on the CT table in a position that facilitates the preinterventionally determined access

JAYPEE BROTHERS

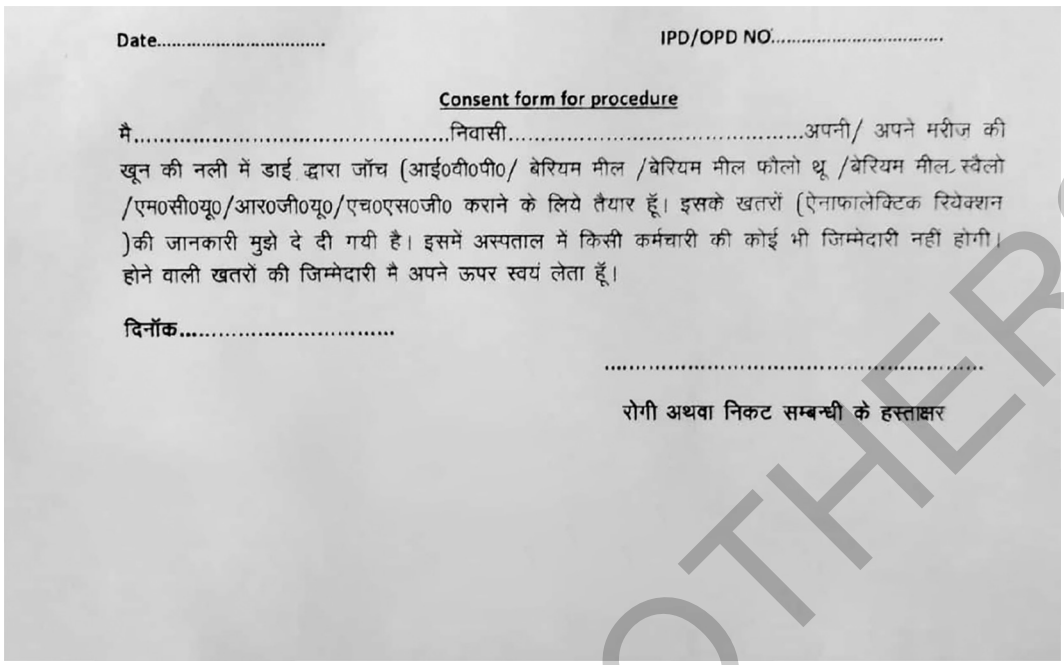

Date..... IPD/OPD NO.....

Consent form for procedure

मै.....निवासी.....अपनी/ अपने मरीज की खून की नली में डाई द्वारा जॉच (आई0वी0पी0/ बेरियम मील /बेरियम मील फौलो थू /बेरियम मील स्वैलो /एम0सी0यू0/आर0जी0यू0/एच0एस0जी0 कराने के लिये तैयार हूँ। इसके खतरों (ऐनाफालेक्टिक रियेक्शन)की जानकारी मुझे दे दी गयी है। इसमें अस्पताल में किसी कर्मचारी की कोई भी जिम्मेदारी नहीं होगी। होने वाली खतरों की जिम्मेदारी मै अपने ऊपर स्वयं लेता हूँ।

दिनॉक.....

.....

रोगी अथवा निकट सम्बन्धी के हस्ताक्षर

Fig. 17.4: Format of consent form.

route. For most interventions a spiral scan of the region of the intended procedure is done for further planning. The scan can be done with or without the use of contrast material to identify vascular structures and/or areas of abnormal or pathologic contrast enhancement behavior. Furthermore, it must be decided whether the procedure has to be done in inspiration, expiration, or free breathing, depending on the area and the compliance of the patient. The access path of the intervention can be assessed either on the axial images or on multiplanar reformations if procedures are needed to be angulated to the z-direction. Preferably, the intervention is planned in a plane perpendicular to the z-axis, which makes the procedure much easier to perform and to monitor. If double-angulated punctures are necessary, a tilted gantry can be used for surveillance to provide images parallel to the direction of the intervention.

- The radiologist performs medical hand washing and dresses with a surgical cap and mask and sterile gloves. A sterile coat is used in complex as well as in all skeletal interventions. The skin area of the procedure is disinfected and the patient covered with sterile sheets.
- After another disinfection of the skin, local anesthesia is performed. Using the syringe needle for the local anesthesia, one approaches the intended target for the first time. This step can already be done with CT guidance using the techniques described below. Careful local anesthesia is mandatory for the patient, especially in bone punctures.
- After the target has been reached with the anesthesia needle, the procedure is repeated with the interventional device [i.e., drainage, puncture device, radiofrequency (RF) ablation device, etc.]. If a thicker device is used, a small incision of the skin using a scalpel is necessary.
- After the procedure has finished, the skin lesion is bandaged. A CT scan of the target region is performed to exclude complications and, if necessary, to control the position of drainage catheters, coils, or localization needles.
- Depending on the procedure, the patient should typically maintain bed rest for 3–6 hours, ideally lying on the punctured site. During that time, he or she should be regularly monitored. After pulmonary punctures at least one chest X-ray should be performed to exclude pneumothorax. After punctures in the upper abdomen a chest X-ray can be considered depending on the course of the intervention. In difficult interventions, a further CT scan may be required in the short follow-up. In patients with reduced blood clotting capabilities or after punctures with a bleeding risk, further controls of the blood hemoglobin are needed.

Indications of Various Computed Tomography Guided Procedures

See **Table 17.2**.

JAYPEE BROTHERS

TABLE 17.2: Depicting the indications of various procedures.

Type of intervention	*Indications*	*Examples*
Fine-needle biopsy	Cytology Microbiology	➢ Small lymph nodes (<1 cm) ➢ Pulmonary nodules ➢ Difficult access (i.e. trans gastral) ➢ Suspected malignant effusion ➢ Suspected superinfection
Punch biopsy	Histology	➢ Lymph nodes ➢ Solid masses
Drill biopsy	Histology	➢ Bones ➢ Bone tumors ➢ Soft tissue tumors within bones
Drainages	Microbiology therapy	➢ Every type of superinfected fluid collection ➢ Abscess ➢ Necrosis ➢ Fluid collections (bilioma, seroma, etc.) ➢ (Gastrostomy)
Localization techniques	Surgery preparation	➢ Large nodules before video-assisted thoracoscopy surgery ➢ Intraparenchymal kidney tumors
Tumor/ablation therapy	Palliative or curative tumor therapy	➢ Primary cancers (hepatocellular carcinoma, renal cell carcinoma, lung cancer, etc.) ➢ Metastasis (liver, kidney, adrenal, lung, etc.)
Neurolysis	Pain therapy	➢ Tumor-induced pain (sympathetic chain, ganglion celiacum, etc.) ➢ Neuralgia [Gasserian (trigeminal) ganglion, etc.]
Anesthesia injection	Pain therapy	➢ Periradicular therapy (disc herniation, etc.)
Skeletal interventions	Trauma therapy	➢ Vertebroplasty, sacroplasty, percutaneous screw insertions, etc.

CT DOSIMETRY

For interventional CT-guided procedures, the entire ionization effect is concentrated in a few slices (e.g., a small segment of the thorax for the lung biopsy). Therefore, it is important to consider both the stochastic and deterministic effects of this mode of dose delivery. Historical data suggests that the stochastic risk associated with radiation exposure (e.g., tumor induction and hereditary effects) has no threshold for cancer occurrence: the risk increases linearly with patient dose. However, deterministic effects (direct damage to organs or tissue) have a threshold below which no direct radiation-induced damage to the body will occur; for skin 2 Gy or higher is required for local skin damage (acute skin reactions like erythema and epilation) to occur.

The effective dose (E) is typically used to quantify the stochastic dose because it takes into account the doses received by all radiosensitive organs weighed according to their individual radiosensitivity. The entrance skin dose (ESD) is the metric chosen to represent the deterministic dose to the skin of the patient.

Multiple tools for patient dose calculations are available. The ImPACT CT Patient Dosimetry Calculator is a commonly used tool. This program contains the CTDI values normalized per 100 mAs for air (nCTDIair) and for the center (nCTDIc) and periphery (nCTDIp) of both body and head phantoms for a variety of scanners. To obtain the effective dose (E), the corresponding anatomic region scanned on a patient is noted from the CT images and prescribed on the mathematic phantom included in the program. The entrance skin dose can then be estimated using the CTDI value that refers to the dose at 1 cm below the surface of a standard 32 cm body phantom. The anatomic location of the maximum entrance skin dose (ESDM) can be calculated by determining the overlap of all scans and their respective entrance skin dose.

There have been a number of recent studies that quantify the contributions of the CT scanning to the entrance skin dose and effective dose received by the patient. During interventional CT-guided procedures, the amount of acquired CT scan series is directly correlated with the maximum entrance skin dose. However, the effective dose is most largely influenced by the first planning scan since it covers such a large area of the body, and the subsequent more localized scans have less of an effect. For each procedure, it is essential that the above calculations are

JAYPEE BROTHERS

performed for typical parameter settings and scan lengths. One can also perform the dose calculations for any prior CT-guided procedure as all parameters needed for the calculation are readily available from the archived image data (provided all scans acquired during the procedure are saved and pushed to the PACS). This exercise is essential to ensure that the dose is below the required level for induction of erythema, epilation, and other deterministic and stochastic effects of radiation.

MAIN RISKS AND COMPLICATIONS OF COMPUTED TOMOGRAPHY-GUIDED INTERVENTIONS (TABLE. 17.3)

General Complications

Drug reaction due to local anesthesia, nerve lesion with numbness or paralysis infection, abscess, sepsis, bleeding, hematoma, surgery and death.

Procedure-specific Complications

Thoracic Procedures

Pneumothorax, air embolism (arterial and venous) with arterial infarction (i.e., myocardial infarction, stroke).

Abdominal Procedures

Pneumothorax (upper abdomen), injury of parenchymal organs of the abdomen (i.e. liver, spleen, kidneys), arteriovenous fistula in parenchymal organs, injury of the intestine and peritonitis.

Osseous Procedures

Fracture and osteomyelitis.

Tumor Ablation

Large necrosis with resulting sepsis, injury of adjacent organs or structures, bleeding.

TABLE 17.3: Complications of CT-Guided interventions with risk factors and preventive measures.

Category	*Complication*	*Risk factors*	*Preventive measures*
Bleeding	Hematoma	Coagulopathy, anticoagulant use, large vessel puncture	Preprocedure INR/PTT check, discontinue anticoagulants if safe
	Hemorrhage	Vascular lesion, deep organ biopsy, hypertension	Use smaller gauge needle, postprocedure monitoring
Infection	Abscess formation	Poor aseptic technique, immunosuppression	Strict aseptic precautions, prophylactic antibiotics if needed
	Sepsis	Prolonged procedure, infected biopsy site	Early detection and treatment with antibiotics
Organ Injury	Pneumothorax	Lung biopsy, COPD, emphysema	Use of expiratory breath-hold technique, postprocedure CXR
	Bowel perforation	Abdominal interventions, difficult access route	CT-fluoroscopy guidance, avoiding unnecessary deep needle passes
	Solid organ damage	Liver/kidney/spleen biopsy, large lesion	Real-time needle tracking, avoid excessive needle repositioning
Neurological	Nerve injury	Close proximity to major nerves, deep needle penetration	Use of contrast guidance, avoiding high-risk approaches
	Spinal cord injury	Epidural injections, vertebral biopsies	Precise needle placement, ultrasound guidance if applicable
Vascular	Arterial puncture	Poor visualization, deep vascular structures	Doppler or contrast-enhanced CT guidance
	Air embolism	Pulmonary procedures, improper syringe handling	Avoid excessive suction, ensure proper syringe handling
Procedure-specific	Contrast reaction	Prior allergies, renal impairment	Premedication in high-risk patients, use nonionic contrast
	Needle fracture	Poor-quality needles, excessive force	Use high-quality needles, avoid excessive angulation
Others	Pain	Large needle size, deep tissue penetration	Local anesthesia, sedation in sensitive cases
	Radiation exposure	Repeated procedures, prolonged fluoroscopy	Minimize exposure time, use lowest effective dose

JAYPEE BROTHERS

PITFALLS

To avoid unwanted incidents such as bleeding, infection, pneumothorax, or nerve injury, the following precautions must be taken:

- The whole procedure must be performed under sterile conditions to prevent intervention-related iatrogenic infections, especially in skeletal interventions.
- The patient's blood clotting capabilities must be known to prevent bleeding.
- Before the intervention starts, the initially acquired CT images must be analyzed carefully to identify the safest path to the target. Extensive knowledge of the anatomy of the region of intervention is mandatory to avoid injury to neural structures or blood vessels, especially arteries.
- The direction of the puncture should not head toward organs sensitive to damage, i.e., aorta, coronary arteries, etc., especially when performing punch biopsies.
- To avoid contact of the puncture device with the gantry, especially when long devices are used, the procedure should be done with the patient table in the lowest position in order to gain more space in the gantry bore. This is even more important if the patient is positioned on his/her side, for example, on the left side, if the liver is punctured.
- Biopsies or drainages of parenchymal organs should be done with parenchymal bridging of the access path to prevent bleeding or spreading of infection into peritoneum or retroperitoneum.
- Liver punctures in patients with ascites should be avoided, if possible, owing to a higher bleeding risk, especially in patients with liver cirrhosis. Pre-interventional drainage directly prior to the intervention may be used to provide safe access to the target without interposition of fluid.

KEY POINTS

- Computed tomography is a widely available tool to monitor interventions.
- The patients must be informed about the complications and the patient's blood clotting capabilities must be known.
- The procedures have to be done under sterile conditions.
- Knowledge of the anatomy and accurate planning of the procedure are mandatory to avoid complications.
- After the procedure the patients have to be carefully monitored.

REFERENCE

1. Haaga JR. Interventional CT: 30 years' experience. Eur Radiol. 2005;15(Suppl 4):D116-20.

MULTIPLE CHOICE QUESTIONS

1. Which of the following are CT-guided interventions?
a. Diagnostic b. Therapeutic
c. Both a & b d. None

2. Which of the following is therapeutic intervention?
a. Punch biopsy
b. FNAC
c. Thermal ablation of tumor
d. None

3. Generally, the INR of the patient should be:
a. Below 1.7 b. Above 1.7
c. Both a & b d. None

4. What is/are the general complications of an intervention?
a. Abscess b. Sepsis
c. Bleeding d. All of the above

5. What is/are the complications of thoracic procedures?
a. Pneumothorax b. Headache
c. Both a & b d. None

6. What is/are the complications of abdominal procedures?
a. Pneumothorax b. AV fistula
c. Both a & b d. None

7. What is/are the complications of osseous procedures?
a. Fractures b. Osteomyelitis
c. Both a & b d. None

8. What type of CT scanner is most practical for CT-guided interventions due to its wider bore?
a. Single-slice CT b. Dual-slice CT
c. 85 cm bore CT d. Multislice CT

9. What is the first mandatory step before performing a CT-guided intervention?
a. Anesthesia administration
b. Review of previous radiological exams
c. Positioning the patient on the CT table
d. Disinfecting the CT scanner

JAYPEE BROTHERS

10. What is a common complication after a thoracic CT-guided procedure?
a. Pneumothorax
b. Osteomyelitis
c. Peritonitis
d. Aortic rupture

11. What should be done after a pulmonary puncture in a CT-guided procedure to rule out complications?
a. Chest X-ray
b. MRI of the chest
c. Follow-up CT scan of the abdomen
d. Blood test for clotting factors

Answers Key

1. c 2. c 3. a 4. d 5. a 6. c 7. c 8. c 9. b 10. a 11. a

JAYPEE BROTHERS

for detailed information on radiology books, visit our website www.ejaypee.com, for detailed information on radiology books, visit our website www.ejaypee.com, for detailed information on radio

Textbook of
RADIOLOGY
For X-ray, CT, MRI, BSc, BRIT and MSc Technicians
With Review Questions & MCQs

Salient Features

- A comprehensive yet concise guide designed to help radiology technicians master the fundamentals of CT, MRI, and X-ray imaging.
- Perfect for examination preparation, enabling students to confidently clear final and competitive examinations.
- Includes chapter-wise MCQs for thorough self-assessment, quick revision, and concept reinforcement.
- Presents essential anatomy, pathology, and image interpretation in a clear, easy-to-understand, point-based format.
- Equally useful for radiology technicians, MD/DNB residents, and radiology trainees seeking conceptual clarity.
- Structured for success—exam-oriented, comprehensive, and easy to learn within limited time.
- At the end of this edition, an appendix has been included with chapter-wise review questions for student's practice.

Learn, revise, and excel—your complete guide for success in radiology!



Sachin Khanduri MBBS MD (Radiodiagnosis) is a distinguished academician and eminent radiologist, currently serving as Professor and Head, Department of Radiodiagnosis, Era's Lucknow Medical College, Lucknow, Uttar Pradesh, India.

He completed his MD in Radiodiagnosis from GR Medical College, Gwalior, Madhya Pradesh, and has over 25 years of experience in medical education, research, and clinical radiology. A passionate teacher and examiner, he has guided more than 170 MD postgraduate research theses and trained numerous undergraduate, postgraduate, and technician students.

He has published over 150 scientific papers in reputed and indexed national and international journals and has presented and lectured at leading global forums including RSNA, ECR, and IRIA.

He is the proud recipient of several honors, notably the Pannalal Oration Award, the Cureus Laureate Award, and recognition by IRIA as one of the "Most Ethical Radiologist" in India.

He has authored five acclaimed textbooks in radiology that are widely appreciated for their clarity, clinical relevance, and practical approach. Renowned for his ethical values, teaching excellence, and academic leadership, he continues to inspire radiologists, clinicians, and students across India and beyond.

Shelving Recommendation
RADIOLOGY

ISBN 978-93-6616-154-9
9 789366 161549

Buy from ejaypee

JAYPEE BROTHERS