thers.com, for detailed information on radiology books, visit our website www.jaypeebrothers.com, for detailed information on radiology books



Essentials of
RADIODIAGNOSIS

As per the Revised Competency-based Medical Education Curriculum 2024 (NMC)

Rachna Chaurasia

diginerve®
A Jaypee Initiative
• Video Lectures • Dr. Wise AI Chatbot
• Question Bank • Notes
Download App

JAYPEE

Contents

UNIT 1: Fundamentals and Techniques in Radiodiagnosis

Chapter 1: Introduction 3
- Role of the Radiologist *3*
- Imaging Modalities and their Applications *4*
- Practical Aspects of Radiodiagnosis *5*
- Future Directions in Radiodiagnosis *6*

Chapter 2: Evolution of Radiodiagnosis 9
- Radiological Divisions in the Current Era *10*
- Advances and Innovations in Radiodiagnosis *17*

Chapter 3: Radiation and its Effects 19
- Fundamentals of Radiation *19*
- Mechanisms of Radiation Interaction *21*
- Biological Effects of Radiation *22*
- Radiation-Induced Diseases *24*

Chapter 4: Radiation Safety and Protection 28
- Fundamental Principles of Radiation Protection *28*
- Damaging Effect of Radiation *28*
- Protection Techniques and Strategies *29*
- Radiation and Pregnancy *32*

Chapter 5: Basic Imaging Techniques 36
- Ionizing Rays Based Imaging *36*
- Magnetic Resonance Based Imaging (MRI) *39*
- Sound Based Imaging *39*
- Nuclear Medicine Imaging *40*
- Optical Imaging *40*
- Hybrid Imaging Techniques *40*
- Contrast Medias and Common Contrast Procedures *40*
- Common Imaging Procedures *43*
- Contrast Reactions *46*

Chapter 6: Advanced Imaging Techniques 52
- Advanced X-ray Techniques *52*
- Advanced Ultrasound Techniques *54*
- Advanced Computed Tomography Techniques *56*
- Advanced Magnetic Resonance Imaging (MRI) Techniques *58*
- Advanced Nuclear Medicine and Molecular Imaging *59*

Chapter 7: Interventional Radiology 63
- Prerequisites to any Interventional Radiological Procedure *63*
- Materials *64*
- Classification of Interventional Procedures *65*
- Risk Management *70*
- Interventional Radiology-Indian Scenario *71*

Chapter 8: Career Opportunities in Radiodiagnosis 74
- Eligibility to Pursue a Course in Radiodiagnosis *74*
- Job Opportunities in Radiodiagnosis *75*
- Work-Life Integration in Radiodiagnosis *75*
- Challenges and Considerations in Radiodiagnosis *76*

UNIT 2: Core Radiological Anatomy and Specialized System Imaging

Chapter 9: Radiological Anatomy 81

Chapter 10: ENT and Face Imaging 88
- Imaging Modalities *88*
- Radiological Evaluation *89*
- Common Pathology *96*

Chapter 11: Neurological Imaging 104
- Indications of Brain Imaging *104*

Chapter 12: Chest Imaging 119
- Modalities Used in Chest Imaging *119*
- Radiological Compartments of Chest *123*
- Common Chest Pathology *128*

Chapter 13: Spine Imaging 134
- Common Indications *134*
- Imaging Modalities *134*
- Application of Imaging Modalities in Common Pathology *135*
- Radiological Anatomy *136*
- Common Pathologies *137*

Chapter 14: Musculoskeletal Imaging 148
- Imaging Modalities *148*
- Common Indications of Musculoskeletal Imaging *154*

UNIT 3: Obstetric and Gynecological Imaging

Chapter 15: Basics of Obstetric Imaging 161
- Early First-Trimester Scan or Viability Scan *161*
- NT/NB Scan or Level 1 Scan *165*
- Anomaly Scan or Level 2 Scan or Targeted Imaging for Fetal Anomalies (TIFFA Scan) *168*
- Third-Trimester USG or Growth Scan *173*

Chapter 16: Fetal Imaging: Developmental Anomalies 177
- Techniques *177*
- Indications of TIFFA *177*
- ISUOG 20+2 Planes Approach to Midtrimester Scan *178*
- Ultrasound Features of Common Abnormalities *179*
- Limitations of the Anomaly Scan *183*

Chapter 17: Fetal Imaging: Advanced Techniques 186
- Noninvasive Techniques *186*
- Invasive Techniques *189*

Chapter 18: Obstetric Emergencies.....193
- Indication of Ultrasound in Obstetric Emergencies *193*
- Common Obstetric Emergencies *195*

Chapter 19: Gynecological Imaging.....202
- Modalities *203*
- Common Pathologic Conditions *204*

UNIT 4: Pediatric Radiology

Chapter 20: Basics of Pediatric and Neonatal Imaging 215
- Challenges in Pediatric Imaging *215*
- Technical Consideration *217*
- Clinical Applications *218*

Chapter 21: Pediatric Neuroimaging 220
- Imaging Techniques *220*
- Common Pathology *222*

Chapter 22: Pediatric Musculoskeletal Imaging 234
- Common Pathologies *235*

Chapter 23: Cardiovascular Imaging in Pediatric.....247
- Modalities *247*
- Common Congenital Heart Diseases *252*

Chapter 24: Interventional Radiology in Pediatrics 261
- Risks and Safety Concerns *263*
- Post-Procedure Care and Monitoring *264*

UNIT 5: Comprehensive Radiological Review

Chapter 25: Breast Imaging 269
- Imaging Techniques *269*
- Normal Breast Anatomy *271*
- Imaging Approach to Breast Lesions *271*
- Imaging Features of Common Breast Pathologies *279*

Chapter 26: Imaging in Joint Disease 283
- Imaging Modality *284*
- Common Pathology *286*

Chapter 27: Gastrointestinal Tract Imaging 294
- Imaging Modalities *294*
- Common Diseases of GIT *299*

Chapter 28: Hepatobiliary and Pancreatic Imaging 305

***Liver* 305**
- Embryology *305*
- Anatomy *305*

***Biliary Apparatus* 306**

***Pancreas* 307**
- Embryology *307*
- Anatomy *307*
- Imaging Techniques *307*
- Common Anatomical Variants and Congenital Anomalies *311*
- Benign Hepatobiliary Diseases *313*
- Tumors *317*

Chapter 29: Imaging in Urinary Tract and Male Reproductive System.....321
- Embryology and Anatomy *321*
- Imaging Modalities *322*
- Common Pathologies *326*

***Imaging in Male Reproductive System* 332**

Chapter 30: Radiology in Geriatric Patients 336
- Indication of Geriatric Imaging *336*
- Imaging of Geriatric Brain *337*
- Imaging Heart Diseases in Geriatric Patients *338*
- Imaging Vascular Diseases in Geriatrics *340*
- Imaging Respiratory Diseases in Geriatrics *340*
- Imaging of Gastrointestinal Tract Diseases in Geriatrics *341*
- Imaging of Urologic Diseases in Geriatrics *343*
- Osteoarthritis/Degenerative in Geriatric Patients *343*
- Imaging in Myeloid and Lymphoid Diseases *344*

Chapter 31: Oncological Imaging 347
- Brain Neoplasms *347*
- Head and Neck Cancer *348*
- Breast Cancer *350*
- Lung Cancer *351*
- Hepatocellular Carcinoma *351*
- Renal-Cell-Carcinoma *352*
- Prostate Cancer *352*
- Bowel Cancer *353*
- Endometrial and Cervical Cancer *353*
- Imaging of Common Extracranial Solid Tumors in Children *354*
- Bone Tumors *354*
- Pancreatic Cancer *354*
- Nuclear Medicine for Diagnosis and Treatment *355*

Chapter 32: Cardiovascular Imaging in Adult 357
- Radiographic Features of Common Diseases *359*
- Radiographs in Specific Cardiac Disease *362*
- Echo *364*
- Coronary CT Angiogram *366*
- Cardiac MRI *367*
- Common Diseases *368*

UNIT 6: Emergency Radiology

Chapter 33: Imaging in Trauma.....377
- Principles of Imaging in Trauma *377*
- Targeted Imaging Approaches for Specific Trauma Scenarios *381*
- Operational and Clinical Considerations *384*

Chapter 34: Radiology in Intensive Care Unit 386
- Portable Chest Radiography *386*
- PACS in the ICU *387*
- Common Radiographic Appearances of Support Devices *388*
- Common Pulmonary Complications in the ICU *390*
- Computed Tomography (CT) in the ICU *391*

UNIT 7: Advanced Techniques and Professional Practice

Chapter 35: Nuclear Medicine in Radiology 397
- Types of Radiation *397*

Chapter 36: Imaging in Transplantation 402
- Renal Transplantation *402*
- Liver Transplantation *407*

Chapter 37: Medicolegal Aspects in Radiology.....411
- The Preconception and Prenatal Diagnostic Techniques (PCPNDT) Act and Rules *413*

Form F (To Be Filled in Two Copies One Given to Patient and Other Kept at Centres as Record) *418*
- Form for Maintenance of Records in case of Prenatal Diagnostic Test/Procedure by Genetic Clinic/Ultrasound Clinic/Imaging Centre *418*

Annexure 427

Glossary.....445

Index *463*

CHAPTER

21 Pediatric Neuroimaging

"Pediatric neuroimaging explores the growing mind—each scan a chance to guide a child's path before words are even spoken."

INTRODUCTION

During the neonatal period, encompassing the first month of life, a substantial proportion of infant mortalities and persistent neurological issues originate from adverse incidents. Premature infants are particularly susceptible to brain damage during this critical time. Imaging is pivotal for diagnosing and comprehending such injuries and for predicting neurodevelopmental outcomes. Cranial ultrasound is typically the initial imaging modality employed due to its portability. It is effective in monitoring conditions, such as germinal matrix hemorrhage, hydrocephalus, and significant brain malformations. However, ultrasound may not be as effective as computed tomography (CT) or magnetic resonance imaging (MRI) in detecting small calcifications or subtle brain malformations. CT is generally reserved for cases requiring confirmation of specific conditions, such as intracranial calcifications. MRI, on the other hand, is the most advanced technique for evaluating the neonatal brain. Advanced MRI techniques, such as diffusion-weighted imaging (DWI) and functional magnetic resonance imaging (fMRI) offer valuable insights into brain physiology and function. Furthermore, arterial spin labelling allows for noninvasive assessment of neonatal brain perfusion.

IMAGING TECHNIQUES

When assessing the pediatric brain, different imaging modalities provide unique insights into the developing neural structures. This overview outlines the key characteristics and considerations of ultrasound, CT, and MRI for pediatric brain imaging.

Ultrasound

- **Advantages:** Ultrasound is a noninvasive imaging modality that offers high-resolution images for evaluating superficial brain structures, particularly in neonates.
- **Limitations:** Ultrasound may struggle to visualize deeper brain structures, such as the cerebellum and posterior fossa, due to limited penetration depth and reduced visibility of more intricate details.
- **Applications:** Primarily used for neonatal brain screening, such as evaluating for intraventricular hemorrhage and periventricular leukomalacia. Accessible and quick, it is suitable for bedside use.

JAYPEE BROTHERS

Computed Tomography (CT)

- **Advantages:** CT provides increased tissue contrast and can visualize deep brain structures, making it useful for assessing hemorrhage, fractures, and acute injuries.
- **Limitations:** Concerns about radiation exposure limit its use in pediatric patients. It is generally reserved for specific cases where rapid imaging is needed or when MRI is contraindicated.
- **Applications:** Commonly used for evaluating acute brain injuries, cranial trauma, and potential abnormalities requiring immediate assessment.

Magnetic Resonance Imaging (MRI) (Figs. 21.1 and 21.2)

- **Advantages:** MRI is the most sensitive modality for detecting abnormalities in the pediatric brain. It offers superior soft tissue contrast and can utilize various imaging sequences to optimize visualization.
- **Limitations:** MRI can be time-consuming and may require sedation in younger children to minimize movement. It is also more expensive and less readily available in emergency situations.
- **Sequences:**
  - *T1-weighted:* Provides detailed anatomical images, particularly useful for assessing myelination and brain maturation.

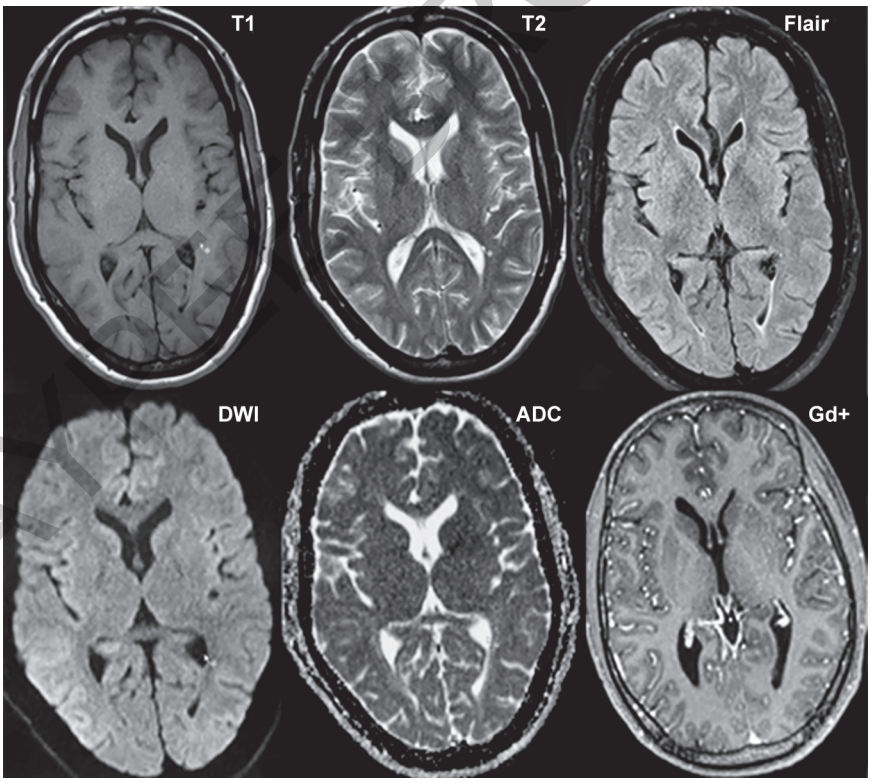

Fig. 21.1: MRI images of a patient showing T1-weighted, T2-weighted, fluid-attenuated inversion recovery (FLAIR), diffusion-weighted image (DWI), apparent diffusion coefficient (ADC) map and Gd+ (post-gadolinium) contrast-enhanced images.

JAYPEE BROTHERS

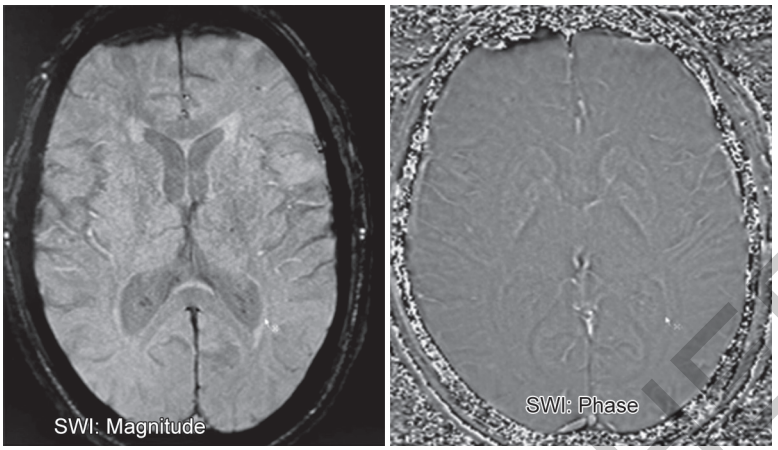

Fig. 21.2: Susceptibility-weighted images of a patient (magnitude and phase images).

  - *T2-weighted:* Excellent for detecting water content and fluid changes, such as edema and inflammation.
  - *Diffusion-weighted imaging (DWI):* Useful for evaluating brain ischemia, infarction, and white matter tract integrity.
  - **Gradient-Echo:** Helpful for detecting microbleeds and vascular malformations.
- **Optimization:** Adjustments in scan parameters, such as longer echo times and inversion times for T1-weighted scans, enhance the quality of neonatal imaging. Dedicated neonatal MR head coils improve image quality, contrast, and resolution for smaller field of view imaging, aiding in better visualization of critical structures like the brainstem and posterior fossa.

Overall, each imaging modality has its strengths and weaknesses in pediatric brain assessment. A careful choice based on the clinical scenario and correct selection of modality as per patient needs can provide the most accurate and safe diagnosis.

COMMON PATHOLOGY

Hypoxic Ischemic Encephalopathy

Brain injury in term neonates can vary significantly and is affected by the severity and duration of the insult. Imaging results may vary based on when they are conducted, with studies before 72 hours potentially underestimating injury severity due to delayed cell death, such as apoptosis, peaking around the 72-hour post-insult. Therapeutic hypothermia, typically initiated within 6 hours of birth and maintained for 72 hours, can prolong this process.

Hypoxic-ischemic encephalopathy (HIE) typically arises from severe asphyxia, causing sudden blood supply disruption and resulting in oxygen and glucose deprivation in the neonatal brain. Structures with high metabolic demands, including the thalami, basal ganglia, and brainstem, are particularly susceptible to hypoxia and ischemia. The ventral lateral thalami, posterolateral lentiform nuclei, posterior midbrain, hippocampi, lateral geniculate nuclei, and perirolandic cerebral cortex are notably vulnerable regions. Profound asphyxia is associated with conditions, such as quadriparesis, choreoathetosis, seizures, mental retardation, and cerebral palsy.

JAYPEE BROTHERS

- Ultrasound and CT often show transient or persistent hyperechogenicity in deep brain structures, potentially progressing to cavitation, especially in basal ganglia and thalami.
- MRI is the preferred imaging for neonatal encephalopathy; MRS at 24 hours post-insult is sensitive to hypoxic-ischemic injury, indicating elevated lactate and reduced N-acetyl-aspartate (NAA), with lactate peaking 3–5 days post-event.
- DWI is highly sensitive for acute brain injury, detecting lesions in deep gray and perirolandic gray matter earlier than conventional MRI.
- Conventional MRI progresses from unremarkable to increased T1-weighted signal and decreased T2-weighted signal in the subacute phase, followed by increased T2-weighted signal in the chronic phase.

Prematurity

Premature birth, especially very preterm birth (before 32 weeks of gestation), can lead to various neurological features and imaging findings due to the immature development of the central nervous system. Some common neurological features of prematurity along with associated imaging findings are as follows:

Intraventricular Hemorrhage (IVH)

- IVH can lead to intracranial hemorrhage, presenting with symptoms, such as lethargy, apnea, seizures, or a sudden change in mental status.
- **Imaging findings:** Cranial ultrasound (CUS) typically reveals echoic or echo lucent areas within the ventricles, depending on the stage of hemorrhage. Severe IVH may progress to hydrocephalus or periventricular hemorrhagic infarction.

Periventricular Leukomalacia (PVL)

- PVL is characterized by white matter injury and can lead to developmental delays, spasticity, motor deficits, and cognitive impairment later in life.
- **Imaging findings:** CUS initially shows echoic periventricular areas, later progressing to cystic lesions or gliosis. MRI is more sensitive and can demonstrate diffuse or focal areas of signal abnormality in the periventricular white matter.

Cerebral White Matter Injury

- White matter injury is associated with motor and cognitive deficits, including cerebral palsy and learning disabilities.
- **Imaging findings:** MRI reveals abnormal signal intensity in the cerebral white matter, typically involving periventricular regions. Diffusion-weighted imaging (DWI) may show restricted diffusion in acute injury, while T2-weighted or FLAIR sequences demonstrate hyperintense signal changes in chronic injury.

Intracranial Hemorrhage

- Intracranial hemorrhage can lead to symptoms, such as seizures, irritability, poor feeding, or altered consciousness.
- **Imaging findings:** CUS or MRI can reveal hemorrhage within the parenchyma, subarachnoid space, or ventricles. Hemorrhages may resolve or evolve into complications, such as hydrocephalus or porencephaly.

JAYPEE BROTHERS

Congenital Brain Malformations

Chiari Malformations

Chiari malformations are a group of defects associated with congenital caudal 'displacement' of the cerebellum and brainstem.

- **Chiari I malformation** is the most common form, characterized by the displacement of peg-like cerebellar tonsils (>5 mm) into the upper cervical canal through the foramen magnum.
- **Chiari 1.5 malformation** is described both as a separate condition and a variant of Chiari I malformation, involving caudal descent of cerebellar tonsils and brainstem.
- **Chiari II malformation** involves the displacement of the medulla, fourth ventricle, and cerebellar vermis through the foramen magnum, often associated with a lumbosacral spinal myelomeningocele.
- **Chiari III malformation** shares similarities with Chiari II, but includes an occipital and/or high cervical encephalocele.
- **Chiari IV malformation** presents with severe cerebellar hypoplasia without displacement of the cerebellum through the foramen magnum, possibly a variation of cerebellar hypoplasia.
- **Chiari V malformation** is characterized by the absence of the cerebellum and herniation of the occipital lobe through the foramen magnum.
- **Chiari 0 malformation** refers to the presence of a syrinx without cerebellar tonsillar or brainstem descent, is infrequently used and considered confusing, and it is advised to avoid it, particularly in light of reports indicating syrinx improvement after posterior fossa decompression.

Dandy-Walker Continuum

The Dandy-Walker continuum encompasses two main conditions: the Dandy-Walker malformation and the Dandy-Walker variant.

Dandy-Walker Malformation

- This condition involves either complete or partial absence (agenesis) of the vermis, along with cystic enlargement of the fourth ventricle.
- It leads to an enlarged posterior fossa with displacement of the torcula (a structure at the back of the head where dural sinuses converge).
- Often, supratentorial hydrocephalus (build-up of cerebrospinal fluid within the brain's ventricles) accompanies this malformation.
- Roughly 70% of patients also exhibit associated anomalies, such as abnormal or absent corpus callosum (a structure connecting the brain's hemispheres), callosal lipoma (fatty tissue in the corpus callosum), and neuronal migration anomalies.

Dandy-Walker Variant

In this variant, there is underdevelopment (hypoplasia) of the inferior portion of the vermis, coupled with non-obstructive cystic enlargement of the fourth ventricle.

- Unlike the malformation, the posterior fossa appears normal or slightly enlarged.
- In contrast to the Dandy-Walker continuum, two other conditions should be kept in mind:

Posterior Fossa Arachnoid Cyst

- This condition involves a cystic space filled with cerebrospinal fluid (CSF) in the posterior fossa.
- It does not affect the formation of the cerebellum and typically causes anterior displacement of the fourth ventricle and cerebellum.

JAYPEE BROTHERS

Mega Cisterna Magna

- In this condition, there is enlargement of the CSF spaces (>10 mm) behind the cerebellum.
- It does not exert pressure on surrounding structures and does not affect the development of the cerebellum.

Inborn Errors of Metabolism

Metachromatic Leukodystrophy

- Metachromatic leukodystrophy (MLD) is characterized by a deficiency in arylsulfatase A enzyme, leading to cerebroside sulfate accumulation in lysosomes.
- **MLD has four subtypes:** Congenital, late infantile, juvenile, and adult. The late infantile subtype is most common, typically appearing between 14 months to 4 years of age.
- Symptoms include initial unsteady gait progressing to severe ataxia, flaccid paralysis, dysarthria, mental retardation, and decerebrate posturing.
- Imaging shows marked T2 hyperintensity of white matter fiber tracts with diffuse involvement, sparing subcortical white matter initially.

Infections

Neonatal brain infections pose a significant risk for long-term neurological issues, being caused by viruses, bacteria, and parasites transmitted during different stages of development—in utero, during labor and delivery, or after birth.

Bacterial and fungal infections commonly transmit during labor or postnatally, while infections, such as toxoplasmosis, syphilis, rubella, and cytomegalovirus (CMV) are often transmitted in utero. Herpes simplex virus (HSV) and human immunodeficiency virus (HIV) can be transmitted during any stage.

Bacterial Infections

- Common bacteria causing neonatal brain infections include group B streptococcus, *Escherichia coli, Streptococcus pneumoniae, Haemophilus influenzae* type B, and *Listeria monocytogenes*.
- Ventricular enlargement, due to impaired CSF absorption from inflammatory exudate, is common in meningitis but does not necessarily indicate ventriculitis.
- **Ventriculitis** is characterized by ependymal enhancement and sometimes pus-fluid levels, often accompanied by hydrocephalus and intraventricular abscesses.
- **Sterile subdural effusions** are common in neonatal meningitis, but about 2% of cases progress to **empyemas**, identified by distinct signal intensity from CSF and peripheral enhancement.
- **Cerebritis,** evidenced by vasogenic edema with/without patchy enhancement, may appear on autopsy despite normal in vivo imaging findings.
- As the disease progresses, enhancing areas may merge, forming a **cerebral abscess** with restricted water diffusivity and an enhancing capsule.

CNS Tuberculosis

It may present as focal lesions, such as tuberculomas or tuberculous abscesses, or more widespread conditions, such as meningitis and arachnoiditis.

Tuberculomas and Tuberculous Abscesses

- Tuberculomas constitute the majority of focal TB lesions and are usually devoid of tuberculous meningitis (TBM).

JAYPEE BROTHERS

- On CT, tuberculomas appear iso- or hyperdense to cortex before contrast administration, often exhibiting ring or nodular enhancement with surrounding edema.
- They typically show low signal on T2-weighted images and isointense signal on T1-weighted images, with rim enhancement post-contrast administration.
- TB abscesses are larger lesions, also rim-enhancing, but with low density centrally, similar to pyogenic abscesses.

Tuberculous Meningitis (TBM)

- TBM is the most severe form of TB in children, presenting with diffuse involvement of the CNS, which can be asymmetrical, unilateral, or focal.
- MRI is excellent for detecting basal enhancement and infarctions but may have limited impact due to availability constraints, especially in resource-limited areas.

Complications of TBM

Includes vasculitis (can lead to infarcts), hydrocephalus, spinal arachnoiditis.

Viral Encephalitis

Herpes Simplex Virus Type 2 (HSV-2) Infection

- Outbreaks during pregnancy increase the risk of miscarriage or delivering a low birth weight baby.
- Neonatal transmission commonly occurs during birth but in utero transmission is possible.
- HSV-2 encephalitis poses a serious risk to the newborn.
- Diagnosis is typically made through viral culture or PCR of CSF.
- Imaging may reveal cortical hemorrhagic foci, leptomeningeal enhancement, and cystic white matter changes.
- Findings are typically normal in neonates.
- Late findings include atrophy, delayed myelination, and CNS lymphoma.

Japanese Encephalitis (JE)

- It is a viral infection transmitted by arthropods, belonging to the flavivirus family, and is associated with significant mortality and morbidity.
- Recurrent outbreak of JE are reported annually, between the month of July and October from the districts of upper Assam of Northeast India.
- Abnormal T2 and FLAIR hyperintensities indicative of Japanese encephalitis (JE) are commonly observed in the thalami, substantia nigra, basal ganglia, hippocampus, pons, and occasionally in cortical and subcortical regions, as well as cerebellar hemispheres.
- DWI's sensitivity to cytotoxic edema, an early indicator of encephalitis, makes it superior in detecting early-stage JE cases but less effective in later stages.
- During the acute stage of JE, DWI typically shows diffusion restriction with low apparent diffusion coefficient (ADC) values, which gradually increase during the late acute and chronic stages.

Neurocysticercosis (NCC)

- It is a parasitic infection affecting the nervous system, resulting from the presence of cystic larvae of *Taenia solium*.
- It represents the most prevalent helminthic infection of the nervous system in humans and is a primary contributor to epilepsy incidence in tropical regions, particularly noted as the leading cause of focal seizures in children from North India.

JAYPEE BROTHERS

Table 21.1: Difference between neurocysticercosis and CNS tuberculosis.

Neurocysticercosis	*CNS tuberculosis*
Lesions are generally smaller than 2 cm and often multiple	Lesions are often multiple, >2 cm because of conglomeration
Meningitis is not a prominent feature	Meningitis with basal exudates and hydrocephalus is usually associated
Generally present at gray white matter junction and can also involve eyes, muscles and subcutaneous tissue	Generally posterior fossa is involved
T2W image shows hyperintensity with hypointense scolex	T2W image shows can show hypo- or hyperintense lesion without any mural nodules
Lesions show less edema and less midline shift	Lesions show more edema and more midline shift
MRS shows multiple amino acid peak	MRS shows lipid peak
Raised ICP is transient	Raised ICP is present
Constitutional symptoms usually absent	Constitutional symptoms usually present

- **Location of cysts:**
  - Cysts can be found anywhere within the neuroaxis and may be intra-axial or extra-axial
  - Most commonly, cysts are located in the parenchyma.
  - In the subarachnoid space over the cerebral hemispheres, cysts can attain significant size.
  - Ventricular involvement is also observed.
- Difference between neurocysticercosis and CNS tuberculosis shown in **Table 21.1**.
- **Stages of infection:** Each stage exhibits distinctive imaging features, although there is no clear demarcation between them.
  a. *Vesicular stage:*
     - Characterized by cysts with dot sign, CSF density/intensity, and occasionally an eccentric hyperintense scolex on T1.
     - Typically, no enhancement is observed, although faint enhancement of the wall and scolex may occur.
     - Absence of surrounding vasogenic edema.

  b. *Colloidal vesicular stage:*
     - Marked by turbid cyst fluid, appearing hyperattenuating to CSF on CT and hyperintense on T1 MRI.
     - Surrounding edema is evident, and the cyst and wall become thickened and enhance brightly.
     - The scolex may initially be visible but gradually diminishes.

  c. *Granular nodular stage:*
     - Edema diminishes, and the cyst retracts, eventually becoming a small enhancing nodule.
     - Persistent but less marked enhancement is observed.

  d. *Nodular calcified stage:*
     - Represents the end-stage with quiescent calcified nodules.
     - No edema is present, and there is no enhancement on CT.
     - Signal drop-out on T2 and T2* sequences, with some intrinsic high T1 signal.
     - Long-term enhancement on MRI may predict ongoing seizures.

JAYPEE BROTHERS

Epilepsy

It is very common presenting complaints in childrens. Causes are innumerable (e.g., infections, congenital causes, prematurity, tumors, etc.). Few common causes are described below:

Focal Cortical Dysplasia

The exact mechanism of epilepsy in FCD is not fully understood, but possible factors include abnormal firing from dysplastic neurons, dysfunctional synaptic circuits, and disorganized inhibitory interneurons.

- FCD can occur in any cerebral cortex and vary in size, ranging from one gyrus to multiple lobes.
- MRI features of FCD include increased cortical thickness, blurring of cortical–white matter junction, and abnormal signal intensities in T2 or FLAIR sequences in cortex and subcortical white matter, along with abnormal sulcation and gyration pattern.

Lissencephaly

In lissencephaly, MRI typically shows a smooth brain surface with a lack of normal convolutions or gyri. The cortex appears thickened and lacks the usual sulci and gyri, resulting in a characteristic "smooth brain" appearance.

Pachygyria

Pachygyria is characterized by broad and abnormally thick gyri. On MRI, the cortex appears thicker than normal, with fewer and larger gyri than expected. This can result in a "pebbled" or "cobblestone" appearance of the brain surface.

Polymicrogyria

Polymicrogyria is characterized by an excessive number of small, irregular gyri. On MRI, the cortex appears densely folded with numerous small gyri, giving a "bumpy" or "spongy" appearance to the brain surface.

Heterotopia

Heterotopia refers to clusters of neurons that have migrated abnormally and are located in the wrong brain regions. On MRI, heterotopias appear as focal areas of abnormal signal intensity within the white matter or along the ventricular walls (Iso-intense to grey matter on all sequences).

Schizencephaly

Schizencephaly is characterized by clefts or cleft-like openings in the cerebral cortex that extend from the surface of the brain to the ventricular system, always lined by grey matter. On MRI, these clefts are visualized as linear clefts of CSF signal intensity extending from the brain surface to the lateral ventricles, often associated with abnormal cortical development around the clefts.

Phakomatosis

Tuberous Sclerosis

- Tuberous sclerosis complex (TSC) is an autosomal-dominant neurocutaneous syndrome affecting multiple systems including the brain, eyes, heart, kidney, skin, and lung.
- Seizures are prevalent in 80–90% of TSC patients, with 25–30% experiencing intractable seizures.

JAYPEE BROTHERS

- Medically refractory epilepsy in children with TSC often involves multiple cortical/subcortical tubers characterized by broad gyri, thick cortex, and abnormal signal in cortex and subcortical white matter.
- Cortical/subcortical tubers in TSC may occasionally exhibit calcification and cystic degeneration.
- Subependymal nodules, common in TSC, often calcify.
- Subependymal giant cell astrocytomas, another manifestation of TSC, frequently occur near the foramen of Monro.

Neurofibromatosis Type 1

Neurofibromatosis Type 1 (NF1) patients face an elevated risk of developing primarily benign tumors affecting the nervous system:

- Optic pathway gliomas (OPGs) represent the most common central nervous system tumors in NF1 children under seven years old, with an incidence of 15–20%.

Epilepsy-associated Tumors

Epilepsy-associated tumors constitute a significant portion, potentially up to two-thirds, of the pathological substrate for epilepsy surgery. These tumors arise within the cortex and are clinically characterized by seizures, typically displaying benign behavior with low proliferation rates, although malignant transformation can occur in rare instances.

Ganglioglioma (Fig. 21.3)

- Gangliogliomas commonly present with seizures, particularly complex partial seizures that are often medically refractory.
- They tend to be larger in children than in adults and are predominantly located in the temporomesial or temporolateral regions.
- Comprised of both glial and neuronal elements, gangliogliomas can manifest as solid masses, cysts, or mixed lesions, often causing remodeling of adjacent bone due to their cortical location.

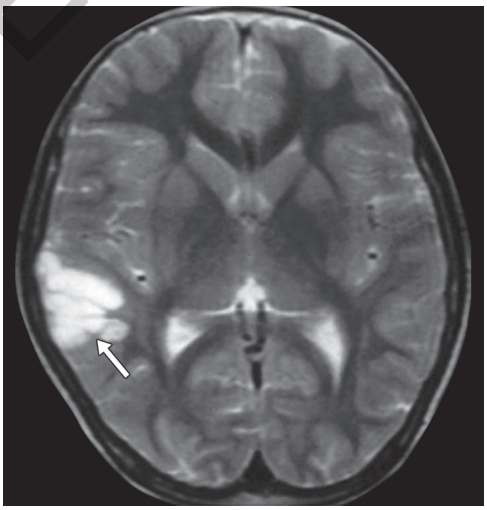

Fig. 21.3: T2 hyperintense mass involving cortex of right temporal lobe suggestive of ganglioneuronal tumor.

JAYPEE BROTHERS

- Imaging characteristics include hypodensity on CT in a majority of cases, with varying degrees of density and frequent calcification. On MRI, the solid portion typically appears hypointense or isointense on T1-weighted images and hyperintense on T2-weighted images, often with enhancement.

Dysembryoplastic Neuroepithelial Tumor (DNET)

- DNET is a benign cortical tumor typically found in the supratentorial region, showing a predilection for the temporal lobes
- It may present with a well-demarcated margin or slightly blurred margins, along with associated gyral broadening, sulcal effacement, ventricular distortion, and skull remodeling.
- On imaging, DNET tends to appear hypodense with a cystic appearance on CT, with reported calcifications in a portion of cases. MRI typically shows a low T1 and high T2 signal, often with multicystic features and possible enhancement, extending into the ventricle in some instances (soap bubble/bubbly appearance).

Brain Neoplasm

Medulloblastoma

- It is the most prevalent childhood posterior fossa tumors, account for approximately 38% of all such tumors and 15–20% of pediatric brain tumors.
- Medulloblastomas typically originate midline within the vermis, causing obstructive hydrocephalus as they grow into the fourth ventricle, though they may localize to the cerebellar hemispheres in older patients or those with the desmoplastic subtype.
- Imaging features include hyperdensity on CT while T1 and T2 hypointensity relative to gray matter with homogeneous enhancement on MRI. Elevated taurine content on MRS may also be observed.

Craniopharyngiomas

- Craniopharyngiomas are slow-growing, benign tumors located in the sellar and parasellar regions, comprising 3–10% of all pediatric brain tumors.
- They are WHO grade I tumors, originating from ectodermal remnants of the Rathke's pouch, with a bimodal incidence in the first and fifth decades of life. The adamantinous type is more common in children, while the squamous-papillary variant is predominant in adults
- Imaging typically reveals mixed cystic and solid components, with high signal intensity on both T1- and T2-weighted MRI images in areas with high protein content or subacute hemorrhage. Hypointensity on T1-weighted images may indicate the presence of keratin within cysts. Calcifications are commonly demonstrated on CT scans, aiding diagnosis and surgical planning.

Astrocytomas

The modified WHO classification categorizes astrocytomas into low grade (grades I and II) and high grade (grades III and IV), with grading predictive of patient survival.

- Pilocytic astrocytomas, classified as grade I WHO tumors, represent 20–30% of childhood brain tumors and typically manifest within the first two decades of life.
- These tumors commonly arise in various locations, such as the optic pathways, hypothalamus, thalamus, basal ganglia, cerebral hemispheres, cerebellum, and brainstem, with patients with NF1 having an elevated risk, especially for optic pathway tumors.
- On imaging, grade I astrocytomas usually exhibit well-defined lesions with contrast enhancement of the solid component, possibly accompanied by cystic components. Increased ADC values within these lesions aid in differentiation from higher grade astrocytomas.

JAYPEE BROTHERS

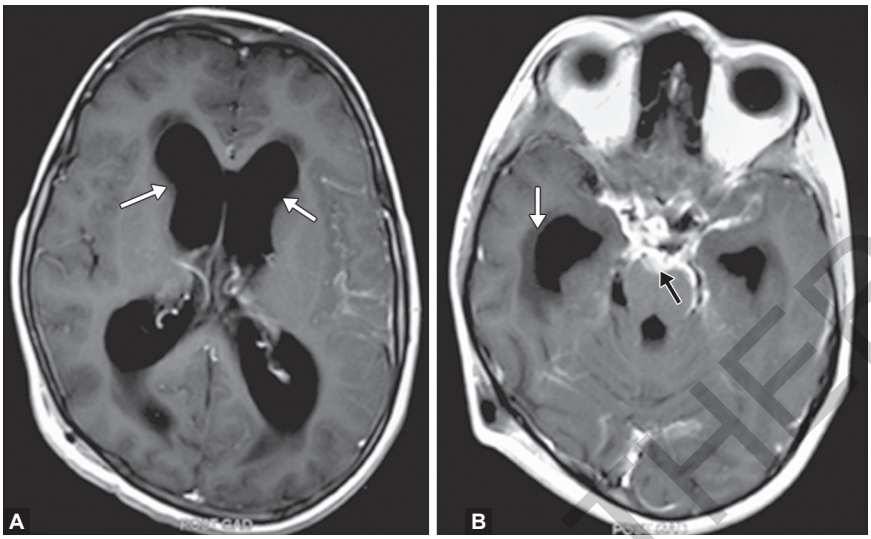

Figs. 21.4A and B: Hydrocephalus: (A) Contrast-enhanced axial T1 images showing dilated bilateral lateral ventricles; (B) Dilated temporal horns *(white arrow)* along with enhancing basal exudates *(black arrow)* suggestive of tubercular meningitis causing hydrocephalus.

Hydrocephalus (Figs. 21.4A and B)

- Hydrocephalus, which translates to "fluid accumulation within the brain," occurs when various factors culminate in the expansion of ventricles, causing compression of brain tissue and surrounding spaces, thereby resulting in elevated intracranial pressure (ICP).
- This imaging findings also having long list of causes (e.g., TBM, brain tumors, Dandy Walker continuum, etc.)
- CT and MRI serve as primary modalities for assessing ventricular size, while ultrasound is preferred in infants with macrocephaly.
- **Enlargement of the anterior and posterior recesses of the third ventricle** is a reliable sign of hydrocephalus due to less resistance from surrounding structures.
- **Commensurate dilation of the temporal horns** with the lateral ventricles is indicative of hydrocephalus and can be observed on coronal T2-weighted images.
- **Reduction of the mamillopontine distance** and **diminution of the ventricular angle** suggest hydrocephalus, as seen on MRI images.
- Hydrocephalus may lead **to periventricular interstitial edema**, which is appreciable on MRI with fluid-attenuated inversion recovery and proton density sequences.
- These imaging findings aid in distinguishing hydrocephalus from other conditions, guiding treatment decisions, and monitoring disease progression.

Child Abuse

- Skeletal surveys are conducted in suspected abuse cases to evaluate and record skeletal injuries. The "babygram" technique, capturing the entire infant in one view, is deemed inadequate due to its lower image quality and the need for varied exposures for different anatomical regions.
- Bone scans are utilized in certain institutions for their capability to identify fractures not visible on radiographs.

JAYPEE BROTHERS

- Specific fractures, such as **metaphyseal fractures** (such as **bucket handle** or **corner fractures**) and rib fractures, are highly indicative of non-accidental injuries, particularly in abused infants under 18 months.
- Suspicious features of skull fractures include non-parietal locations, involvement of multiple bones, diastatic sutures, cross-suture patterns, and depressed fractures resembling a signature. Other moderately specific fractures for non-accidental injury include bilateral fractures with differing ages, digital fractures in non-ambulant children, vertebral fractures, spiral humeral fractures, and complex skull fractures.
- **Subdural hemorrhage** is the most common, often located interhemispherically.
- Subarachnoid hemorrhage is also observed.
- Cerebral edema may manifest as focal, multifocal, or diffuse swelling.
- Acute cerebral contusion appears as an ovoid collection of intraparenchymal blood with surrounding edema.
- MR imaging is more sensitive in identifying hematomas of varying ages.
- White matter shearing injuries present as areas of prolonged T1 and T2 signals at the corticomedullary junction, centrum semiovale, and corpus callosum.
- Visceral injuries—trauma to abdominal viscera, accounting for 3% of cases, is the second leading cause of death in child abuse. Causes include crushing blows to the abdomen (e.g., punches, kicks), with victims often older than two years.

LAST MINUTE REVISION



- **MRI is superior** for detailed brain structure, e.g., to see tumor extension, for etiology and stage of infection etc.
- **Ultrasound** is quick and effective for initial screenings and safe for frequent use.
- **CT scans** are reserved for urgent assessments due to quick imaging capabilities but carry radiation risk.
- Medulloblastoma is most prevalent childhood posterior fossa tumors

REVIEW QUESTIONS

Multiple Choice Questions (MCQs)

1. **What is the initial imaging modality typically employed for assessing neonatal brain injuries due to its portability?**
   a. MRI
   b. CT
   c. Ultrasound
   d. X-ray
2. **Which MRI sequence is particularly useful for evaluating brain ischemia and white matter tract integrity in neonates?**
   a. T1-weighted
   b. T2-weighted
   c. Diffusion-weighted imaging (DWI)
   d. Gradient-Echo
3. **What is a major limitation of using CT scans in pediatric patients?**
   a. Time-consuming procedures
   b. High cost of the scans
   c. Radiation exposure
   d. Need for sedation

JAYPEE BROTHERS

4. **Which condition is MRI particularly sensitive to at 24 hours post-insult due to its ability to detect elevated lactate and reduced N-acetyl-aspartate (NAA)?**
   a. Prematurity
   b. Hypoxic-ischemic encephalopathy (HIE)
   c. Intraventricular hemorrhage
   d. Periventricular leukomalacia
5. **Chiari malformation type II often involves the displacement of which of the following through the foramen magnum?**
   a. Medulla, fourth ventricle, and cerebellar vermis
   b. Only cerebellar tonsils
   c. Cerebellum without displacement
   d. None of the above

Answer Key

1. c 2. c 3. c 4. b 5. a

SUGGESTED READING

1. Aldinger KA, Lehmann OJ, Hudgins L, et al. FOXC1 is required for normal cerebellar development and is a major contributor to chromosome 6p25.3 Dandy-Walker malformation. Nat Genet. 2009;41(9): 1037-42.
2. Kimura-Hayama ET, Higuera JA, Corona-Cedillo R et al. Neurocysticercosis: radiologic-pathologic correlation. Radiographics. 2010;30(6):1705-19. doi:10.1148/rg.306105522 - Pubmed citation
3. Martinez-Biarge M, Diez-Sebastian J, Kapellou O, et al. Predicting motor outcome and death in term hypoxic-ischemic encephalopathy. Neurology. 2011;76(24):2055-61.
4. Shofty B, Ben-Sira L, Constantini S. Neurofibromatosis 1-associated optic pathway gliomas. Childs Nerv Syst. 2020;36:2351-61. doi: 10.1007/s00381-020-04697-1. [PubMed] [CrossRef] [Google Scholar]
5. Verma R. MRI features of Japanese encephalitis. BMJ Case Rep. 2012;2012:bcr0320126088. [PMC free article] [PubMed] [Google Scholar]

JAYPEE BROTHERS

for detailed information on radiology books, visit our website www.jaypeebrothers.com, for detailed information on radiology books, visit our we

Essentials of Radiodiagnosis

"**Essentials of Radiodiagnosis**" debuts as a comprehensive guide meticulously aligned with the National Medical Commission's competency-based curriculum. Tailored for both MBBS students and postgraduates, this resource is indispensable for excelling in various professional exams, including PGME, USMLE, and PLAB. With its clear language and accessible format, enhanced by significant contributions from leading radiology experts across India, this book stands as an essential resource for mastering the complexities of radiodiagnosis.

- **Compliance with the Latest Curriculum:** Thoroughly covering the competency-based curriculum as mandated by the National Medical Commission.
- **New Chapters and Content Areas:** Includes emerging topics and recent advancements in radiodiagnosis, such as modern imaging techniques and interventional procedures.
- **Essential for Exam Preparation:** Ideal for both comprehensive studying and last-minute reviews, ensuring readiness for a wide range of exams.
- **Enhanced Learning Tools:** Features updated diagrams, tables, flowcharts, and mnemonics to facilitate understanding and retention.
- **Contributions from Eminent Institutions:** Chapters and sections within this book have been contributed by senior faculty from prestigious institutions such as AIIMS, RML, SGPGI, BHU, and KGMC, ensuring that the content is both authoritative and reflects the latest in medical knowledge.
- **Inclusion of Image Glossary:** A unique glossary containing common X-rays, CTs, MRIs, and imaging procedures frequently examined in tests, providing a practical study tool.
- **Integration of Practice Questions:** Questions formatted in the style of NEET and USMLE exams included to aid self-assessment and exam preparation.
- **Key Points and Facts:** Highlighted in dedicated boxes throughout the book for quick reference, offering deeper insights and focused learning.
- **Last-Minute Essentials:** Key points crucial for examination success are succinctly summarized at the end of each chapter to enhance last-minute study.
- **Annexures includes commonly used approaches in flowchart form for useful clinical tests and presentation.**

Rachna Chaurasia MD (Radiodiagnosis), holds the distinguished position of Professor and Academic Head in Radiodiagnosis, recognized as the youngest to achieve this rank in the field across India. She is a well-known author with extensive research experience, contributing significantly to the academic and clinical understanding of radiodiagnosis. She also holds examinerships in various states of India and at AIIMS, marking her as a key influencer and respected authority in medical imaging.

Printed in India

Available at all medical bookstores or buy online at www.ejaypee.com

JAYPEE BROTHERS
Medical Publishers (P) Ltd.
EMCA House, 23/23-B, Ansari Road,
Daryaganj, New Delhi - 110 002, INDIA
www.jaypeebrothers.com

Join us on facebook.com/JaypeeMedicalPublishers
Follow us on instagram.com/JaypeeMedicalPublishers

Shelving Recommendation
RADIOLOGY

ISBN 978-93-6616-175-4