ion on cardiology books, visit our website www.jaypeebrothers.com, for detailed information on cardiology books, visit our website www.jaypeebrothers.com

Volume 2

on on cardiology books, visit our website www.jaypeebrothers.com, for detailed information on cardiology books, visit our website www.jaypeebrothers.com

Volume 1

Complimentary e-book accompanied by
1852 Movie Clips with Duration of 5.5 hours

Comprehensive Textbook of Echocardiography


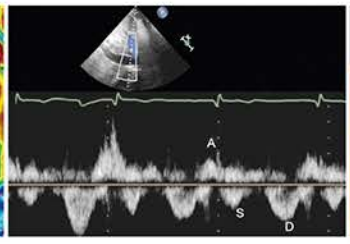

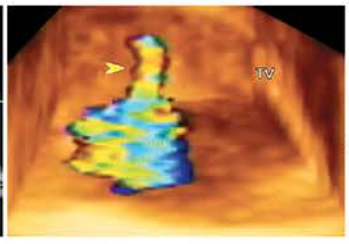

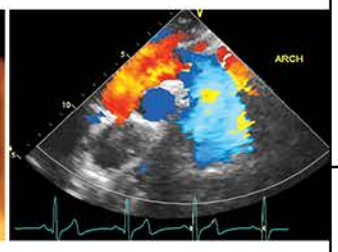

Navin C Nanda

3rd Edition

JAYPEE

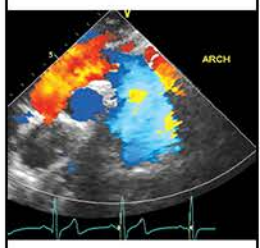

JAYPEE



Contents

VOLUME 1

SECTION 1 HISTORY AND BASICS

Chapter 1. History of Echocardiography 3
Fadi G Hage, Anant Kharod, David Daly, Navin C Nanda
- History of Ultrasound *4*
- Development of Clinical Cardiac Ultrasound: A-mode and M-mode Echocardiography *4*
- Two-dimensional Echocardiography *8*
- Conventional Doppler Ultrasound *9*
- Color Doppler Ultrasound *10*
- Contrast Echocardiography *12*
- Transesophageal Echocardiography *13*
- Tissue Doppler and Speckle Tracking Imaging *16*
- Three-dimensional Echocardiography *16*
- Perspective *18*

Chapter 2. Early Cardiac Flow Doppler Era: A Key for a New Clinical Understanding of Cardiology 25
Colette Veyrat
- Preflow Doppler Era: Paucity of Existing Noninvasive Tools *25*
- Explosive Emergence of the Flow Concept, an Indispensable Mutation from Pressure Measurements, which Prepared the Doppler Flow Era *28*
- Return to the Doppler Technique in Search of a Noninvasive Tool Documenting The "Flow Concept" *29*

Chapter 3. Basics of Ultrasound 55
Caroline Morbach, Kamran Haleem, Lissa Sugeng
- General Physics 55
- Imaging by Ultrasound 57
- Image Optimization and Equipment 60
- Artifacts 61
- Doppler Ultrasound 62

Chapter 4. Doppler Echocardiography: Methodology, Application, and Pitfalls 65
George Thomas
- Doppler in Cardiology *65*
- Doppler Instrumentation *66*
- Continuous-Wave Doppler *68*
- Pulsed-Wave Doppler *68*
- Color Doppler *70*
- Power Doppler *71*
- Tissue Doppler *72*
- Doppler Methodology *72*
- Information Derived from Doppler *73*

Chapter 5. Basics of Three-dimensional Ultrasound 75
Ivan S Salgo, Wendy Tsang, Nicole Bhave, Roberto M Lang
- Evolution of Three-dimensional Echocardiography *75*
- Transducer Technology *76*
- Beamforming *79*
- Rendering *79*
- Limitations in Three-dimensional Image Quality *80*
- Three-dimensional Echocardiography Quantification *82*

Chapter 6. Speckle Tracking Acquisition: Basics and Practical Tips 89
Willem Gorissen, Navin C Nanda
- M-mode (One-dimensional Speckle Tracking) *89*
- Two-dimensional Speckle Tracking *90*
- R–R Interval *92*
- Standard Views *93*
- Standardization *93*
- Two-dimensional Speckle Tracking Limitation *94*
- Speckle Tracking versus Tissue Doppler Imaging *94*
- Tissue Doppler Imaging versus Speckle Tracking *94*
- Three-dimensional Acquisition *94*
- Multiview Monitoring during Live Acquisition *98*
- Multiview Orientation *98*
- Gain Setting *100*
- Patient Breath-Hold *100*
- Arrhythmias *100*

Chapter 7. Instrumentation for Transesophageal Echocardiography Including New Technology 101
(Late) Ryozo Omoto, Kiyoshi Tamura
- Kinds of Transesophageal Echo *101*
- What Makes Image Quality? *106*
- Artifacts *108*
- Safety Considerations *111*
- Current and Future Technologies *113*
- In the Future *117*

SECTION 2 ECHOCARDIOGRAPHY/ULTRASOUND EXAMINATION AND TRAINING

Chapter 8. M-mode Examination 121
Kamran Haleem, Caroline Morbach, Lissa Sugeng
- Underlying Concept *122*
- Color M-mode *122*
- Advantages and Disadvantages of M-mode *122*
- Use of M-mode *123*

Chapter 9. The Complete Transthoracic Echocardiography 134
Rachel Hughes-Doichev, Osama Okasha, Anantha S Madgula
- Getting Started *134*
- Echocardiographic Imaging Windows and Planes *136*
- Imaging Modalities *136*

- Parasternal Window *139*
- Apical Window *148*
- Subcostal Window *156*
- Suprasternal Notch Window *160*
- Three-dimensional Echocardiography *160*
- Left Ventricle Chamber Quantification and Regional Wall Motion Determination *162*
- Contrast Echocardiography (Ultrasound Enhancing Agent) *164*
- Strain Assessment *164*

Chapter 10. The Standard Transthoracic Examination 168
Atif N Qasim, Nelson B Schiller
- Set-up and Patient Positioning *168*
- Imaged Planes *170*
- Apical Views *179*
- Cardiac Point-of-Care Ultrasound *189*

Chapter 11. Nonstandard Echocardiographic Examination 194
Navin C Nanda, Aylin Sungur, Kunal Bhagatwala, Nidhi M Karia, Tuğba Kemaloğlu Öz
- Right Parasternal Examination Planes *194*
- Right and Left Supraclavicular Examination *196*
- Left Parasternal and Apical Planes for Examination of Coronary Arteries *216*
- Examination of Left Atrial Appendage *220*
- Examination from the Back *223*
- Abdominal Examination *224*

Chapter 12. Technique and Applications of Continuous Transthoracic Cardiac Imaging..... 230
(Late) Premindra PAN Chandraratna, Dilbahar S Mohar, Peter Sidarous
- Feasibility of Continuous Cardiac Imaging *230*
- Limitations *242*

Chapter 13. The Basics of Performing Three-dimensional Echocardiography 245
Steven Bleich, Rahul Gandotra, Garima Arora, Navin C Nanda, Satish K Parashar, HK Chopra, Rakesh Gupta
- Three-dimensional Technology *245*
- Three-dimensional Examination Protocol *246*
- Left Parasternal Approach *249*
- Apical Approach *252*
- Subcostal Approach *260*
- Suprasternal Approach *260*
- Supraclavicular Approach *261*
- Right Parasternal Approach *261*
- Color Doppler Imaging *271*
- Advantages/Disadvantages of Three-dimensional Echocardiography *272*

Chapter 14. How to do Three-dimensional Transthoracic Echocardiography Examination?..... 274
Fabrice Larrazet, Colette Veyrat
- History *274*
- Methods for Data Acquisition *274*
- Left Ventricular Assessment *276*
- Reproducibility *278*
- Aortic Regurgitation *286*

- Aortic Annulus *286*
- Mitral Stenosis *286*
- Mitral Regurgitation *288*
- Tricuspid Valve Disease *289*
- Pulmonic Valve Disease *290*
- Advances in Pediatric and Fetal Cardiac Pathologies *291*

Chapter 15. Critical Care Ultrasound 298
Alice NW Leung, Timothy C Tan, Hatem Soliman-Aboumarie
- Role of POCUS in Shock States *298*
- Cardiogenic Shock *298*
- Assessment of Left Ventricular Systolic Function and Cardiac Output *300*
- Estimation of Left Ventricular Diastolic Function and Filling Pressures *300*
- Distributive Shock *301*
- Hypovolemic Shock *302*
- Echocardiographic Findings In Hypovolemic Shock *304*
- Obstructive Shock *304*

Chapter 16. Spectral Doppler of the Hepatic Veins 315
Bahaa M Fadel, Bader Almahdi, Mohammad Al-Admawi, Giovanni Di Salvo
- Imaging of the Hepatic Veins *315*
- Physiological and Other Factors that Affect Hepatic Venous Flow *318*
- Doppler Pattern of the Hepatic Veins Versus the Superior Vena Cava *320*
- Transthoracic Echocardiography *320*
- Transesophageal Echocardiography *321*
- Technical Considerations *321*
- Hepatic Venous Flow in Disease States *322*
- Limitations, Technical Pitfalls, and Artifacts *335*

Chapter 17. Spectral Doppler of the Pulmonary Veins 341
Bahaa M Fadel, Bader Almahdi, Mohammad Al-Admawi, Giovanni Di Salvo
- Historical Perspective *341*
- Imaging of the Pulmonary Veins *341*
- Physiological Factors that Affect Pulmonary Venous Flow *345*
- Pulmonary Venous Flow in Disease States *346*
- Limitations and Technical Pitfalls *358*
- Artifacts *359*

Chapter 18. Tissue Doppler Imaging 365
Hisham Dokainish, Michael Trump, Garima Arora
- Technical Considerations *365*
- Development of Tissue Doppler Imaging *366*
- Current Clinical Uses of Tissue Doppler Imaging *366*

Chapter 19. Speckle Tracking Echocardiography: Clinical Usefulness 377
Alex M D'Amico, Anurag Tripathy, Shrikar Iragavarapu, Pranav Bhargava, Shyam Padmanabhan, Siddharth Singh, Efstathia Andrikopoulou, Navin C Nanda
- Cardiac Muscular Anatomy and Cardiac Mechanics *378*
- What is Strain? *378*
- Two-dimensional Speckle Tracking Echocardiography *382*

- Image Acquisition and Processing *383*
- Two-Dimensional Speckle Tracking Echocardiography: Clinical Applications *384*
- Coronary Artery Disease *384*
- Cardiac Resynchronization Therapy for Heart Failure *387*
- Cardiomyopathies *388*
- Cardiac Transplantation *389*
- Valvular Heart Disease *390*
- Chemotherapy Cardiotoxicity *390*
- Congenital Heart Disease and Right Ventricular Dysfunction *390*
- Role of Rotational Dynamics *391*
- Three-dimensional Speckle Tracking Echocardiography *391*
- Clinical Applications of Three-dimensional Speckle Tracking Echocardiography *392*
- Limitations of Speckle Tracking Echocardiography *395*

Chapter 20. Echocardiographic Assessment of Global and Segmental Function using Velocity Vector Imaging™ 401

Michael J Campbell, David A Parra, Daniel Forsha, Piers Barker, Jonathan H Soslow

- Cardiac Anatomy *401*
- Application of Velocity Vector Imaging by Age and Disease Group *411*
- Reproducibility and Correlation between Vendors *424*
- Future Directions *427*

Chapter 21. Contrast Echocardiography 444

Jatinder S Pabla, Leigh-Ann Wakefield, Roxy Senior

- What is Ultrasound Contrast? *444*
- How does Ultrasound Contrast Work? *445*
- Indications for the Use of Ultrasound Contrast *454*
- Evidence for the Use of Ultrasound Contrast Agents *457*
- Practical Tips *460*
- Safety of Ultrasound Contrast Agents *463*
- Saline Contrast Echocardiography *463*

Chapter 22. Myocardial Perfusion Echocardiography 468

Angele AA Mattoso, Jeane M Tsutsui, Wilson Mathias Jr

- Imaging Generation for Myocardial Perfusion Analysis *468*
- Techniques for Ultrasound-enhancing Agents' Administration in Everyday Clinical Practice *469*
- Acute Coronary Syndromes *471*
- Assessment of Myocardial Viability *473*
- Chronic Coronary Artery Disease *473*
- Other Clinical Applications *475*
- Final Remarks *479*

Chapter 23. Endothelial Dysfunction 482

Naveen Garg, Kanwal K Kapur

- History *483*
- Endothelial Functions *483*
- Endothelial Dysfunction *484*
- Role of Acetylcholine *484*
- Shear Stress and Flow-mediated Dilatation *485*

- Vasoactive Molecules Involved in Vasoregulation *486*
- Nitric Oxide Release *487*
- Methodology for Assessing Endothelial Function *488*
- Analysis of Shear Stress and Flow-mediated Dilation Response *490*
- Limitations *490*
- Factors Affecting the Flow-Mediated Dilation *495*
- Clinical Utility *497*
- Other Noninvasive Methods to Assess Endothelial Function *498*
- Clinical Impact of Endothelial Dysfunction and Treatment Strategies to Improve Flow-Mediated Dilation *503*
- Automated Machines, Semiautomated, and Dedicated Systems *508*
- Assessment of Endothelial Function and Future Directions *508*

Chapter 24. How to do a Two-dimensional Transesophageal Examination? 517
Andrew P Miller, Navin C Nanda
- Patient Selection and Consent *517*
- Preparation, Conscious Sedation, and Esophageal Intubation *517*
- Transesophageal Echocardiographic Examination *518*

Chapter 25. Upper Transesophageal and Transpharyngeal Examination 524
Stephanie El-Hajj, Navin C Nanda, Kunal Bhagatwala, Nidhi M Karia, Fadi G Hage
- Technique and Recognition of Vessels *524*
- Applications *528*

Chapter 26. How to Perform a Three-dimensional Transesophageal Echocardiogram? 544
Elisa Zaragoza-Macias, Michael A Chen, Edward A Gill
- Three-Dimensional Transesophageal Technology *544*
- Performing Three-dimensional Transesophageal Echocardiography Evaluation *545*
- Specific Uses of Three-dimensional Transesophageal Echocardiography *548*
- Guidelines and Final Recommendations *554*

Chapter 27. Three-dimensional Examination to Evaluate Valvular Heart Disease: The Value of an Added Dimension 556
Patrycja Galazka, Maninder Randhawa, Santhosh KG Koshy, Nina Ghosh, Judy R Mangion
- Data Acquisition *557*
- Three-dimensional Echocardiography Image Optimization *558*
- Three-dimensional Echocardiography of the Mitral Valve *558*
- Three-dimensional Echocardiography of the Aortic Valve *561*
- Three-dimensional Echocardiography of the Pulmonic Valve *564*
- Three-dimensional Echocardiography of the Tricuspid Valve *566*

Chapter 28. Three-dimensional Echocardiographic Guidance of Percutaneous Procedures 572
Muhamed Saric, Leila Alizadeh, Alan Vainrib, Ricardo J Benenstein
- Mitral Valve Interventions *575*
- Aortic Valve Interventions *583*
- Device Closure of Cardiac Shunts *589*
- Electrophysiology Related Procedures *602*
- Miscellaneous Procedures *610*
- Tricuspid Valve Percutaneous Procedures *613*
- Pulmonary Valve Percutaneous Procedures *616*

Chapter 29. Three-dimensional Echocardiography in the Operating Room 624
Ahmad S Omran
- Mitral Valve Disease *624*
- Aortic Valve Disease *629*
- Tricuspid Valve Disease *644*
- Native Valve Endocarditis *656*
- Prosthetic Valve Dysfunction *658*
- Cardiac Masses *673*
- Limitations of Three-dimensional Transesophageal Echocardiography and Future Directions *683*

Chapter 30. Epiaortic Ultrasonography 688
Prajeesh M Nambiar, Yatin Mehta
- Advantages of Epiaortic Ultrasonography over Transesophageal Echocardiography *688*
- Importance of Aortic Pathology Assessment *688*
- Indications for Epiaortic Echocardiography *689*
- Equipment and Setup *689*
- Technique and Imaging Views for Epiaortic Ultrasonography *690*
- Clinical Application of Epiaortic Ultrasonography in Aortic Pathologies *691*
- Other Aortic Pathologies *692*

Chapter 31. Intracardiac Echocardiography 694
Krishnaswamy Chandrasekaran, T Sean Dunn, Donald Hagler, James Seward
- Equipment and the Catheters *694*
- Intracardiac Echocardiography: Clinical Applications *695*
- Intracardiac Echocardiography during Electrophysiology Interventions *697*
- Intracardiac Echocardiography during Structural Interventions *702*

Chapter 32. Intravascular Ultrasound Imaging 709
Siyuan Sheng, Smadar Kort
- Image Acquisition *709*
- Intravascular Ultrasound Examination *710*
- Image Interpretation *711*
- Utility of Intravascular Ultrasound in Clinical Practice *713*
- Safety Considerations *714*
- Future Perspectives *714*

Chapter 33. Peripheral Vascular Ultrasound 718
Ricardo J Benenstein, Muhamed Saric
- Ultrasound Diagnosis of Carotid Artery Diseases *718*
- Ultrasound Diagnosis of Femoral Access Complications *754*
- Screening and Surveillance of Abdominal Aorta Aneurysm *760*

Chapter 34. Advanced Noninvasive Quantification Techniques in Echocardiography 771
Bernhard Mumm, Navin C Nanda
- Technological Background of Advanced Quantification Tools *772*
- Clinical Applications of Advanced Two- and Three-dimensional Echo Quantification Tools *786*
- Left Atrial Quantification *788*
- Right Ventricular Quantification *789*
- Mitral Valve Assessment *792*
- Aortic Valve Assessment *794*

- Structural Heart Disease Interventions *794*
- Conclusion and Future Outlook *794*

Chapter 35. Artifacts in Echocardiography 800
Shyam Padmanabhan, Navin C Nanda, Aylin Sungur, Tuğba Kemaloğlu Öz, Kunal Bhagatwala, Nidhi M Karia, Kruti Jayesh Mehta, Rohit Tandon
- Acoustic Shadowing and Acoustic Enhancement *802*
- Reverberation Artifacts *803*
- Mirror Image Artifacts *804*
- Double Image Artifacts *804*
- Side Lobe Artifacts *804*
- Artifacts Secondary to the Use of Electronic Equipment *805*
- Artifacts in Three-dimensional Echocardiography *805*
- Techniques to Identify and Eliminate Artifacts *806*

Chapter 36. Echocardiography Training 820
Monodeep Biswas, Steven Bleich, Navin C Nanda
- Fellowship Training *821*
- Training of Noncardiologists *822*
- Training for Cardiac Sonographers *823*
- Training in CT and MRI *824*
- Certification and Maintenance of Proficiency *827*
- Appropriate Use Criteria *830*

SECTION 3 VALVULAR HEART DISEASE

Chapter 37. Echocardiography in Acute Rheumatic Fever 835
IB Vijayalakshmi
- Echocardiography in the Diagnosis of Carditis in Acute Rheumatic Fever *835*
- Mitral Regurgitation *842*
- Aortic Regurgitation *847*
- Tricuspid Valve Diseases *852*
- Tricuspid Regurgitation *852*

Chapter 38. Echocardiographic Assessment of Mitral Valve Diseases 861
CN Manjunath, Nagaraja Moorthy, Luis Bowen, Navin C Nanda
- *Part 1:* Echocardiographic Assessment of Mitral Stenosis *861*
- *Part 2:* Echocardiographic Assessment of Mitral Regurgitation *882*
- Assessment of the Severity of Mitral Regurgitation *899*

Chapter 39. Mitral Regurgitation 915
Luc A Pierard, Christine Henri, Julien Magne, Rahul Gandotra, Garima Arora
- Etiology *915*
- Mechanisms *919*
- Severity of Mitral Regurgitation *920*
- Pulmonary Venous Flow *921*
- Mitral Regurgitation Consequences *924*
- Sequential Evaluation of Chronic Asymptomatic Mitral Regurgitation *925*
- Feasibility of Mitral Valve Repair *927*
- Role of Exercise Echocardiography *928*

Chapter 40. Aortic Stenosis 932
Timothy D Woods, Aqeeb Ur Rehman, Navin C Nanda
- Normal Aortic Valve Anatomy *932*
- Etiology of Aortic Stenosis *933*
- Echocardiography in Aortic Stenosis *934*
- Aortic Valve Doppler Examination *940*
- Use of Exercise Echo and Strain in Evaluation of Asymptomatic Severe Aortic Stenosis *954*
- Indications and Appropriateness for Echocardiography in Aortic Valve Stenosis *957*
- Two-dimensional Echocardiographic Calcium Quantification *959*
- Multimodality Imaging in Aortic Stenosis *960*
- Chronic Kidney Disease and Aortic Stenosis *962*
- Role of Artificial Intelligence in Aortic Stenosis Diagnosis and Management *963*
- Management of Aortic Stenosis *965*

Chapter 41. Low-gradient, Severe Aortic Stenosis with Depressed and Preserved Ejection Fraction 974
Priti Mehla
- Myocardial Response to Chronic Aortic Stenosis *975*
- Role of Aortic Valve Replacement in Aortic Stenosis *980*

Chapter 42. Aortic Regurgitation 986
Arzu Ilercil, Arthur J Labovitz
- Aortic Regurgitation Etiologies *986*
- Quantification of Aortic Regurgitation Severity *992*
- Timing of Aortic Valve Surgery *1000*

Chapter 43. Echocardiography Assessment of the Aorta 1003
Matthew Bocchese, Martin G Keane
- Anatomy *1003*
- Transthoracic Echocardiographic Assessment *1004*
- Transesophageal Echocardiographic Assessment *1008*
- Measurements *1010*
- Aortic Aneurysms *1013*
- Heritable Thoracic Aortic Diseases *1015*
- Acute Aortic Syndromes *1016*
- Atherosclerosis *1020*
- Coarctation *1020*
- Operating Room Transesophageal Echocardiography *1023*

Chapter 44. Transesophageal Echocardiography in the Diagnosis of Aortic Disease 1025
Leon J Frazin
- Anatomical Relationship of the Aorta and Esophagus *1025*
- Imaging the Aorta with Transesophageal Echocardiography *1026*

Chapter 45. Echocardiographic Examination of the Tricuspid Valve 1042
Poonam Malhotra Kapoor, Aqeeb Ur Rehman, Kunal Bhagatwala, Nidhi M Karia, Navin C Nanda
- Anatomy of Tricuspid Valve *1042*
- Physiology of Normal Tricuspid Apparatus *1042*
- M-mode Echocardiography *1043*
- Two-dimensional Transthoracic Examination *1043*
- Two-dimensional Transesophageal Examination *1044*

- Three-dimensional Examination *1046*
- Intracardiac Echocardiography *1047*
- Tricuspid Regurgitation *1048*
- Tricuspid Stenosis *1053*
- Tricuspid Valve Prolapse: Flail Tricuspid Valve *1056*
- Management of Tricuspid Regurgitation: The Role of Echocardiography *1075*
- Atrial Functional Tricuspid Regurgitation *1095*
- Role of Echocardiography in Transvenous Lead Extraction *1096*

Chapter 46. Echocardiographic Assessment of Pulmonary Valve 1102
Hoda Mojazi-Amiri, Padmini Varadarajan, Ramdas G Pai
- Epidemiology *1102*
- Pulmonary Stenosis *1103*
- Pulmonary Regurgitation *1106*
- Echocardiographic Evaluation *1107*
- Ross Procedure *1110*
- Postpulmonary Valve Surgery: Monitoring Sequelae *1110*
- Other Complementary Techniques for the Evaluation of Pulmonary Valves *1111*

Chapter 47. Echocardiography in Infective Endocarditis 1114
Javier López, Vijayadithyan Jaganathan, Teresa Sevilla, José Alberto San Román, Isidre Vilacosta, Maximiliano German Amado Escañuela, Kunal Bhagatwala, Nidhi M Karia, Navin C Nanda
- Echocardiographic Findings in Infective Endocarditis *1115*
- Special Considerations in Patients with Infective Endocarditis *1119*
- Role of Echocardiography in the Prognostic Stratification of Infective Endocarditis *1122*
- Indications of Echocardiography in Infective Endocarditis *1131*

Chapter 48. Role of Echocardiography in Pulmonary Hypertension 1137
Francesco Ferrara, Alessandra Maria Esposito, Graziella Lacava, Salvatore Rega, Andreina Carbone, Eduardo Bossone
- Conventional Echocardiography *1138*
- Nonconventional Echocardiography *1145*
- Diagnostic Algorithm in Pulmonary Hypertension *1147*

Chapter 49. Echocardiographic Assessment of Prosthetic Valves 1158
Aditya Bharadwaj, Pooja Swamy, Gary P Foster, Padmini Varadarajan, Ramdas G Pai
- Types of Prosthetic Valves *1158*
- Assessment of Prosthetic Valves *1160*
- Prosthetic Valve Dysfunction *1164*
- Other Complementary Imaging Modalities *1169*

Chapter 50. Three-dimensional Transthoracic and Transesophageal Echocardiographic Evaluation of Prosthetic Valves 1172
Steven Bleich, Olivia Hudson, Garima Arora, Navin C Nanda
- Three-dimensional Visualization of Prosthetic Valves *1172*
- Three-dimensional Transthoracic Echocardiographic Assessment of Prosthetic Valves *1173*
- Three-dimensional Transesophageal Echocardiographic Assessment of Prosthetic Valves *1178*

VOLUME 2

SECTION 4 LEFT AND RIGHT VENTRICLES, LEFT ATRIUM, AND HEMODYNAMICS

Chapter 51. M-mode and Two-dimensional Echocardiographic Assessment of Left Ventricular Systolic Function 1195

Anjlee M Mehta, Vijayadithyan Jaganathan, Navin C Nanda

- Visual Estimation of Left Ventricular Systolic Function *1195*
- M-mode and Two-dimensional Transthoracic Echocardiographic Methods for Assessment of Left Ventricular Systolic Function *1196*
- Doppler Echocardiographic Methods of Assessment of Left Ventricular Function *1199*
- Two-dimensional Speckle Tracking Echocardiography and Velocity Vector Imaging *1199*
- Myocardial Performance Index *1200*
- Contrast Echocardiography in the Assessment of Left Ventricular Systolic Function *1200*
- Arterial–Ventricular Coupling *1202*
- Three-dimensional Transthoracic Echocardiography *1203*
- Role of Artificial Intelligence in Echocardiographic Analysis of Left Ventricular Function *1203*

Chapter 52. How to Assess Diastolic Function? 1206

Hisham Dokainish, Olivia Hudson, Garima Arora

- Integrating Echocardiographic Variables for Accurate Diagnosis of Diastolic Function *1214*
- Novel Imaging Techniques and Future Directions *1215*

Chapter 53. Evaluation of the Right Ventricle 1219

Nouran A Sorour, Vincent L Sorrell

- General Overview *1219*
- Right Ventricle Morphology *1220*
- Echocardiography *1221*
- M-mode Echocardiography *1222*
- Two-dimensional Echocardiography *1224*
- Doppler Echocardiography *1225*
- Two-dimensional Strain (Speckle Tracking) *1227*
- Three-dimensional Echocardiography *1228*
- Transesophageal Echocardiography *1230*
- Hemodynamics *1230*
- Other Imaging Modalities *1230*

Chapter 54. Three-dimensional Echocardiographic Assessment of Left Ventricular and Right Ventricular Function 1235

Keya Shah, Aasha S Gopal

- Three-dimensional Quantitation of the Left Ventricle 1235
- Three-dimensional Quantitation of the Right Ventricle 1253

Chapter 55. Newer Aspects of Structure/Function to Assess Cardiac Motion 1266

Gerald Buckberg, Navin C Nanda, Julien IE Hoffman, Cecil Coghlan

- Basic Heart Function *1270*
- State-of-the-Art *1271*

- Composite of State-of-the-Art Reports *1273*
- Definitions *1276*
- Novel Mechanical and Timing Interdependence between Torsion and Untwisting *1276*
- The Normal Heart *1276*
- The Septum *1284*
- The Right Ventricle *1288*
- Other Considerations *1290*

Chapter 56. Echocardiography in Assessment of Complications Related to Permanent Pacemakers and Intracardiac Defibrillators.....1301

Ahmed Almomani, Mohammed Faluk, Khadija Siddiqui, Masood Ahmad

- Normal Echocardiographic Findings In Permanent Pacemakers/Implantable Cardioverter-Defibrillators *1301*
- Pacemaker and Implantable Cardioverter-Defibrillator-Related Complications *1303*
- Tricuspid Regurgitation *1303*
- Masses: Lead Infection and Thrombus *1307*
- Myocardial Perforation *1309*
- Deleterious Effects of Right Ventricular Apical Pacing on Left Ventricular Function *1310*

Chapter 57. Echocardiographic Evaluation of Ventricular Assist Devices 1317

Peter S Rahko

- Clinical Uses of Ventricular Assist Devices *1319*
- Reverse Remodeling *1321*
- Types of Devices *1322*
- Complications of Left Ventricular Assist Devices *1339*

Chapter 58. Echocardiographic Assessment of Left Atrial Function 1350

Simrat Kaur, Bo Xu, Allan L Klein

- Anatomy and Physiology *1350*
- Physiology *1350*
- Functional Assessment *1351*
- Left Atrial Size and Volume Measurements *1351*
- Spectral Doppler Imaging *1352*
- Strain Parameters *1352*
- Left Atrial Function with Age and Gender *1353*
- Left Atrium with Hypertension and Diabetes Mellitus *1353*
- Left Atrium and Atrial Fibrillation *1353*
- Left Atrium and Diastolic Dysfunction *1354*
- Left Atrium and Cardiomyopathies *1354*
- Future Directions *1357*

Chapter 59. Use of Echocardiography to Assess Cardiac Hemodynamics and Guide Therapy 1363

Roy Beigel, Fernando Chernomordik, Robert J Siegel

- Right Atrial Pressure or Central Venous Pressure *1363*
- Pulmonary Artery Hemodynamics *1367*
- Left-sided Filling Pressures *1372*
- Additional Parameters for Estimation of Left Atrial Pressure *1379*
- Stroke Volume, Stroke Distance, Cardiac Output, and Systemic Pulmonary Shunts (QP/QS) *1379*

SECTION 5 ISCHEMIC HEART DISEASE, CARDIOMYOPATHIES, PERICARDIAL DISORDERS, TUMORS, AND MASSES

Chapter 60. Echocardiography in Ischemic Heart Disease 1389
Chetan Shenoy, Natesa G Pandian
- Detection of Ischemia *1389*
- Role in Acute Coronary Syndromes *1392*
- Mechanical Complications of Myocardial Infarction *1394*
- Role of Echocardiography in Chronic Ischemic Cardiomyopathy *1398*
- Novel Echocardiography Techniques in Ischemic Heart Disease *1401*
- Future *1403*

Chapter 61. Stress Echocardiography 1406
Azhar Supariwala, Siu-Sun Yao, (Late) Farooq A Chaudhry
- Fundamentals of Stress Echocardiography *1406*
- Types of Stress Echocardiography *1407*
- Interpretation of Stress Echocardiography *1408*
- Stress Echocardiography: Future Directions *1417*

Chapter 62. Squatting Stress Echocardiography 1422
(Late) Premindra PAN Chandraratna, Dilbahar S Mohar, Peter Sidarous
- Squatting Echocardiography *1422*

Chapter 63. Three-dimensional Stress Echocardiography 1427
Geru Wu, Mohammed Faluk, Masood Ahmad
- Two-dimensional Stress Echocardiography *1427*
- Three-dimensional Transducers *1428*
- Advantages of Three-dimensional Stress Imaging *1428*
- Three-dimensional Image Acquisition *1429*
- Three-dimensional Stress Protocol *1429*
- Postacquisition Analysis *1430*
- Review of Studies Comparing 3D Stress Echocardiography to Current Standards *1430*
- Differences between 2DSE and 3DSE in Wall Visualization *1433*
- Parametric Imaging In 3DSE *1433*
- Role of Contraction Front Mapping in Real-time 3DSE *1433*
- Contrast in Three-dimensional Stress Testing *1434*
- Prognostic Value of 3DSE *1434*
- Future Directions *1434*

Chapter 64. Echocardiographic Assessment of Coronary Arteries: Morphology and Coronary Flow Reserve 1438
Karina Wierzbowska-Drabik, Jarosław D Kasprzak
- Assessment of Coronary Morphology and Flow in Transthoracic and Transesophageal Studies *1438*
- Visualization of Coronary Arteries *1438*
- Distal Coronary Flow and Coronary Flow Reserve *1441*
- Congenital Abnormalities of the Coronary Arteries *1445*

Chapter 65. Echocardiography in Hypertrophic Cardiomyopathy 1450
Mark V Sherrid, Dan G Halpern, Daniele Massera
- Definitions and Types of Hypertrophy *1451*
- Left Ventricular Outflow Obstruction and Systolic Anterior Motion of the Mitral Valve *1452*
- Mitral Apparatus and Regurgitation *1458*
- Diastolic Dysfunction *1458*
- Apical Hypertrophic Cardiomyopathy *1459*
- Mid-Left Ventricular Hypertrophic Cardiomyopathy *1459*
- Chronic Systolic Dysfunction in Hypertrophic Cardiomyopathy *1460*
- Paradoxical Reversible Systolic Dysfunction in Obstructive Hypertrophic Cardiomyopathy *1461*
- Differential Diagnosis *1464*
- Athlete's Heart *1465*
- Monitoring Treatment Strategies in Hypertrophic Cardiomyopathy *1465*

Chapter 66. Echocardiographic Assessment of Nonobstructive Cardiomyopathies 1475
Dany F Debs, Sai Krishna C Korada, Wenxin Liu, John Beshoy Boutros, Rohit Gokhale, Manreet Basra, Victor Vacanti, Steven J Horn, Aylin Sungur, Robert P Gatewood Jr, Navin C Nanda
- Dilated Cardiomyopathy *1476*
- Secondary Findings in Dilated Cardiomyopathy *1477*
- Role of Echocardiography in Optimizing Heart Failure *1484*
- Echocardiography in Assessing Ventricular Remodeling *1487*
- Findings in Dilated Cardiomyopathy Based on Etiology *1488*
- Restrictive Cardiomyopathy *1499*
- Other Infiltrative Cardiomyopathies *1507*
- Metabolic Cardiomyopathies *1521*
- Carcinoid Heart Disease *1521*

Chapter 67. Echocardiographic Differentiation of Ischemic and Nonischemic Cardiomyopathy: Comparison with Other Noninvasive Modalities 1534
Nisha Hosadurg, Arshad Kamel, Navin C Nanda, Maximiliano German Amado Escañuela, Kunal Bhagatwala, Nidhi M Karia, Sula Mazimba
- Echocardiographic Assessment of Ischemic and Nonischemic Cardiomyopathy *1534*
- M-mode Echocardiography *1535*
- Two-dimensional/Three-dimensional/Doppler Echocardiography *1537*
- Echocardiographic Distinction between Ischemic Cardiomyopathy and Nonischemic Dilated Cardiomyopathy *1541*
- Other Noninvasive Imaging Modalities *1543*

Chapter 68. Pericardial Disease 1556
Trevor L Jenkins, Brian D Hoit
- Acute Pericarditis *1557*
- Pericardial Effusion *1558*
- Pericardial Tamponade *1559*
- Constrictive Pericarditis *1565*
- Effusive–Constrictive Pericarditis *1568*
- Congenital Anomalies *1570*
- Multimodality Imaging of the Pericardium *1571*

Chapter 69. Three-dimensional Echocardiographic Assessment in Pericardial Disorders 1575
O Julian Booker, Navin C Nanda
- Two-dimensional Transthoracic Echocardiography versus Three-dimensional Transthoracic Echocardiography in Pericardial Effusion *1576*
- Two-dimensional Transthoracic Echocardiography versus Three-dimensional Transthoracic Echocardiography in Constriction *1579*
- Two-dimensional Transthoracic Echocardiography versus Three-dimensional Transthoracic Echocardiography in Pericardial Masses *1580*

Chapter 70. Echocardiographic Assessment of Cardiac Tumors and Masses 1585
Johnny Y Wu, Dany F Debs, Leon Varjabedian, Jennifer K Lang, Abdallah Kamouh, Steven J Horn, Tuğba Kemaloğlu Öz, Aylin Sungur, Kruti Jayesh Mehta, Kunal Bhagatwala, Nidhi M Karia, Maximiliano German Amado Escañuela, Robert P Gatewood Jr, Navin C Nanda
- Primary Benign Cardiac Tumors *1587*
- Malignant Primary Cardiac Tumors *1607*
- Secondary Cardiac Tumors *1614*
- Normal Variants and Other Masses *1625*
- Mesothelial/Macrophage Incidental Cardiac Excrescences *1635*
- Extracardiac Masses *1635*
- Artificial Intelligence in the Assessment of Cardiac Tumors and Masses *1637*

SECTION 6 CONGENITAL HEART DISEASE

Chapter 71. Fetal Cardiac Imaging 1651
Aarti H Bhat
- Scope of Fetal Cardiology *1651*
- Fetal Physiology *1653*
- Indications for Fetal Echocardiography *1653*
- Fundamentals of Fetal Cardiac Imaging *1655*
- Fetal Cardiac Function *1667*
- Three-dimensional Imaging *1682*
- Case Studies *1682*

Chapter 72. M-mode and Two-dimensional Echocardiography in Congenital Heart Disease 1688
Neeraj Awasthy, (Late) Savitri Shrivastava

Basics of Imaging and Sequential Segmental Analysis *1689*
- Patient Preparation *1689*
- Imaging *1690*
- Dextrocardia *1697*
- Principles of Sequential Chamber Analysis *1701*

Left-to-Right Shunts: Atrial Septal Defect, Ventricular Septal Defect, Patent Ductus Arteriosus, and Aortopulmonary Window *1708*
- General Features: Shunt Lesions *1708*
- Atrial Septal Defects *1711*
- Ventricular Septal Defect *1717*
- Patent Ductus Arteriosus *1724*
- Aortopulmonary Window *1728*
- Gerbode Defect *1729*

Atrioventricular Septal Defects ***1729***
- Types of Atrioventricular Septal Defect *1730*
- Hemodynamic Assessment of Atrioventricular Septal Defect *1735*
- Mechanism of Atrioventricular Valve Regurgitation *1735*

Congenital Left Ventricular and Right Ventricular Inflow Anomalies ***1735***
- Congenital Anomalies of Mitral Valve *1735*
- Congenital Abnormalities of Tricuspid Valve *1740*

Left Ventricular Outflow Tract Obstruction ***1743***
- Valvular Aortic Stenosis *1743*
- Subvalvular Aortic Stenosis *1748*
- Supravalvular Aortic Stenosis *1751*
- Aortic Regurgitation *1753*
- Sinus of Valsalva Aneurysm *1755*
- Aortocameral Communications *1757*

Echocardiographic Anatomy of Tetralogy of Fallot with Pulmonary Stenosis ***1758***
- Aortic Override *1759*
- Double-Outlet Right Ventricle *1769*
- Truncus Arteriosus *1775*

Complete Transposition of Great Arteries ***1778***
- Transposition of Great Vessels *1778*

Atrioventricular and Ventriculoarterial Discordance ***1788***
- Associated Defects *1789*
- Coronary Artery Anatomy *1789*
- Associated Malformations *1792*
- Left Ventricular Outflow Tract Obstruction *1794*
- Abnormalities of Right Ventricular Outflow *1794*

Pulmonary Veins ***1795***
- Normal Flow Pattern of Pulmonary Veins *1796*
- Anomalies of Pulmonary Veins *1797*
- Total Anomalous Pulmonary Venous Connection *1797*
- Anomalies of Systemic Veins *1802*

Imaging of Coronary and Pulmonary Arteries ***1809***
- Coronary Artery Anomalies *1809*
- Coronary Arteriovenous Fistula *1812*
- Coronary Aneurysms *1814*

Echocardiographic Evaluation of Aortic Arch and its Anomalies ***1814***
- Abnormal Formation of Arch *1815*
- Coarctation of Aorta *1816*
- Interruption of Aortic Arch *1819*
- Aortic Aneurysm *1819*

Univentricular Heart and Heterotaxy Syndrome ***1821***
- Univentricular Atrioventricular Connections *1821*
- Tricuspid Atresia *1825*
- Mitral Atresia and Hypoplastic Left Heart Syndrome *1825*

Heterotaxy Syndrome ***1828***
- Anatomical Background: Characterization of Two Distinct Heterotaxy Syndromes *1828*
- Initial Echocardiogram *1828*

Chapter 73. Real-time Three-dimensional Echocardiography for Quantification of Ventricular Volumes, Mass, and Function in Children with Congenital and Acquired Heart Diseases 1846
Shuping Ge, Rula Balluz, Jie Sun
- Left Ventricular Volumes, Ejection Fraction, and Mass *1847*
- Right Ventricular Volumes, Ejection Fraction, and Mass *1849*
- Single Ventricular Volumes, Ejection Fraction, and Mass *1851*
- Three-dimensional Analysis of Regional Wall Motion, Synchrony, and Strain *1851*
- Summary and Recommendations *1854*
- Future Perspectives *1854*

Chapter 74. Three-dimensional Echocardiography in Congenital Heart Disease 1861
Steven Bleich, Gerald R Marx, Navin C Nanda, Fadi G Hage
- Shunt Lesions/Septal Defects *1861*
- Common Atrium *1880*
- Aortopulmonary Window *1880*
- Patent Ductus Arteriosus *1883*
- Conotruncal Anomalies *1884*
- Outflow Tract Obstruction *1895*
- Aortic Arch Anomalies *1902*
- Atrial and Atrioventricular Valve Abnormalities *1903*
- Other Abnormalities *1906*
- Double Outlet Right Ventricle *1906*
- Sinus of Valsalva Aneurysm *1913*

Chapter 75. Echocardiography in the Evaluation of Adults with Congenital Heart Disease 1921
Reema Chugh
- Key Concepts of Echocardiography in Adults with Congenital Heart Disease *1923*
- Simple Congenital Heart Defects in Adults *1928*
- Valvular Disease *1941*
- Complex Congenital Heart Defects *1953*

Chapter 76. Echocardiographic Evaluation for Acquired Heart Diseases in Childhood 1982
Jie Sun, Shuping Ge
- Infective Endocarditis *1982*
- Echocardiographic Findings *1984*
- Complications of Infective Endocarditis *1985*
- Rheumatic Heart Disease *1986*
- Jones Criteria—Updated 1992 *1986*
- Chronic Rheumatic Heart Disease *1988*
- Kawasaki Disease *1988*
- Coronary Ectasia and Aneurysms by Echocardiography *1989*

SECTION 7 MISCELLANEOUS AND OTHER NONINVASIVE TECHNIQUES

Chapter 77. Echocardiography in Systemic Diseases 1995
Mark Hellerman, Mahdi Veillet-Chowdhury, Smadar Kort
- Systemic Lupus Erythematosus *1995*
- Rheumatoid Arthritis *1996*

- Hypereosinophilic Syndrome *1997*
- Systemic Sclerosis *1999*
- Renal Disease *1999*
- Amyloidosis *2000*
- Carcinoid *2002*
- Chagas Disease *2006*
- Sarcoidosis *2007*
- Thyroid Disorders *2009*
- Nutritional Deficiency *2010*

Chapter 78. Echocardiography in Women 2016
Jennifer Kiessling, Navin C Nanda, Tuğba Kemaloğlu Öz, Aylin Sungur, Kunal Bhagatwala, Nidhi M Karia
- Differences in Echocardiographic Measurements and Technical Considerations *2016*
- Structural Heart Disease: Mitral Valve Prolapse, Mitral Stenosis, and Mitral Annular Calcification *2017*
- Ischemic Heart Disease/Stress Echocardiography/Polycystic Ovarian Syndrome *2019*
- Takotsubo Cardiomyopathy *2030*
- Congenital Heart Disease *2031*
- Echocardiography in Pregnancy, Peripartum Cardiomyopathy, Fetal Echocardiography *2035*

Chapter 79. Echocardiography in the Elderly 2053
Gopal Ghimire, Navin C Nanda, Kunal Bhagatwala, Nidhi M Karia
- Aortic Atherosclerosis and Penetrating Aortic Ulcer *2053*
- Aortic Valve Sclerosis *2055*
- Aortic Stenosis *2056*
- Aortic Aneurysm *2068*
- Aortic Dissection *2069*
- Left Ventricular Mass, Dimensions, and Function *2076*
- Echocardiography in Stroke Patients: Assessment of Coronary Stenosis *2076*
- Mitral Annular Calcification *2081*
- Prosthetic Valves *2082*

Chapter 80. How to do Echo for the Electrophysiologist? 2091
Chittur A Sivaram, Daniel Sohinki
- Echocardiography In Supraventricular Tachycardia *2091*
- Left Atrium *2094*
- Atrial Septum *2095*
- Pulmonary Veins *2097*
- Inferior Vena Cava *2098*
- Echocardiography in Ventricular Tachycardia *2099*
- Echocardiography in Cardiac Implantable Electronic Devices *2100*
- Echocardiography for Percutaneous Left Atrial Appendage Exclusion *2101*

Chapter 81. Echocardiography in Life-threatening Conditions 2107
Rachel Harris, Aqeeb Ur Rehman, Elizabeth Ofili, Navin C Nanda
- Chest Trauma *2107*
- Acute Mitral Regurgitation *2111*
- Acute Severe Aortic Regurgitation *2112*

- Aortic Dissection *2113*
- Pulmonary Thromboembolic Disease *2115*
- Air Embolism *2116*
- Hypovolemia *2116*
- Large Intracardiac Thrombus *2117*

Chapter 82. Lung Ultrasound in Cardiology 2121
Eugenio Picano, Elisa Merli
- Physical and Physiological Basis of Lung Ultrasound *2121*
- Methodology *2123*
- Pulmonary Interstitial Edema *2123*
- Pleural Effusion *2124*
- Pulmonary Embolism *2125*
- Acute Respiratory Distress Syndrome *2125*
- Pneumothorax *2125*
- Cardiopulmonary Ultrasound: An Integrated Approach *2126*
- Limitations and Perspectives *2126*

Chapter 83. Use of Artificial Intelligence in Echocardiography 2130
Subash Dulal, Raj Wasan, George Wuni, Vinay Wasan, Gültekin Karakuş, Alecs Değirmencioğlu, Navin C Nanda
- Introduction and Basics *2130*
- Artificial Intelligence in Echocardiography *2130*
- Limitations *2138*

Chapter 84. A Primer on Cardiac Magnetic Resonance Imaging for the Echocardiographer 2143
Madhavi Kadiyala, Esosa Odigie-Okon, Aasha S Gopal
- Quantitative Chamber Assessment *2143*
- Strain Assessment *2145*
- Left Ventricular Structure *2145*
- Cardiac Hypertrophy *2153*
- Cardiomyopathies *2154*
- Velocity Mapping, Flow, and Shunt Assessment *2157*
- Valvular Heart Disease and Prosthetic Valves *2158*
- Pulmonic Valve *2160*
- Pericardial Disease *2163*
- Normal Variants and Masses *2165*
- Limitations of Cardiac Magnetic Resonance Imaging *2166*
- Glossary of Cardiac Magnetic Resonance Imaging Sequences *2168*

Chapter 85. Cardiac Computed Tomography Imaging 2172
Satinder P Singh, Sushilkumar K Sonavane
- Challenges for Cardiac Computed Tomography *2173*
- Radiation Dose *2174*
- Patient Selection *2176*
- Technique *2176*
- Image Postprocessing *2177*
- Pitfalls and Artifacts *2184*
- Diagnostic Accuracy of Coronary Computed Tomography Angiogram *2187*

- Prognostic Information from Coronary Computed Tomography Angiogram *2190*
- Cardiac Function *2191*
- Myocardial Perfusion *2191*
- How to Improve the Accuracy of Computed Tomography Angiogram In Determining Flow-limiting Disease? *2192*
- Clinical Indications *2193*

SECTION 8 NEW CHAPTERS

Chapter 86. Where do Echocardiography and Ultrasound Stand in the Assessment and Management of Pulmonary Embolism?.....2223
Vijayadithyan Jaganathan, Vaidehi Mendpara, Debashish Roychoudhury, Harvinder S Dod, Ravindra Bhardwaj, Navin C Nanda
- Ultrasound Diagnosis of Thrombi in Peripheral Veins *2223*
- Echocardiographic Diagnosis and Management of Thrombi in the Right Heart and Vena Cavae *2224*
- Risk Stratification and Prognosis *2224*
- Ultrasound-accelerated Thrombolysis *2231*
- Limitations *2231*

Chapter 87. Using Echocardiography to Assess for Cardiac Amyloidosis.....2235
Hamid AK Shirwany, Nilda Espinola-Zavaleta, Navin C Nanda
- Echocardiographic Diagnosis *2236*
- Additional Considerations *2242*

Chapter 88. Role of Echocardiography in Cardio-oncology.....2245
Sibel Catirli Enar, Santhosh KG Koshy, Navin C Nanda
- Utility of Echocardiography in Assessing Cardiovascular Risk Prior to Institution of Treatment for Cancer *2245*
- Echocardiography during Chemotherapy *2246*
- Anthracyclines *2246*
- Vascular Endothelial Growth Factor Inhibitors and Tyrosine Kinase Inhibitors *2246*
- Proteasome Inhibitors *2247*
- Echocardiography after Chemotherapy *2247*
- Utility of Echocardiography in the Assessment of Cardiotoxicity *2247*
- Global Longitudinal Strain *2247*
- Changes in Left Ventricular Diastolic Function with Cancer Therapy *2248*
- Right Ventricular Function Changes after Chemotherapy and/or Radiotherapy *2249*
- Left Atrial Function Associated with Cancer Therapy *2249*
- Ischemic Heart Disease Associated with Cancer Therapy *2250*
- Cancer Therapy Affecting Cardiac Valves *2250*
- Pericardial Disease with Treatment of Cancer *2251*

Chapter 89. Echocardiography in Heart Failure with Reduced Ejection Fraction 2256
Donovon Allen, Ahmed E Ali, Simranpreet Singh Daid, Navin C Nanda
- Preheart Failure *2256*
- Workup for Acute Heart Failure with Reduced Ejection Fraction *2257*
- Interventional Devices *2262*
- Cardiac Transplantation *2262*

Chapter 90. Evaluation of Heart Failure with Preserved Ejection Fraction with Echocardiography.... 2266
Donovon Allen, Ahmed E Ali, Simranpreet Singh Daid, Vijayadithyan Jaganathan, Navin C Nanda
- Initial Diagnosis of HFpEF using 2D Transthoracic Echocardiography *2266*
- Dyspnea Clinics *2270*
- Supplemental Multimodality Imaging *2270*
- Three-dimensional Echocardiography *2271*

Chapter 91. Critical Care Echocardiography: Role of Echocardiography in the Modern Cardiac Intensive Care Unit 2274
Martin Miguel I Amor
- Echocardiography as a Noninvasive Pulmonary Artery Catheter *2274*
- Identification of Mechanical Complications of Myocardial Infarction *2275*
- Assessment of Pericardial Effusion and Cardiac Tamponade *2275*
- Evaluation of Right Ventricular Function and Pulmonary Embolism *2275*
- Detection of Cardiac Sources of Embolism *2277*
- Diagnosis of Aortic Dissection *2278*
- Assessment of Mechanical Circulatory Support Devices *2280*
- Optimization of Cardiopulmonary Resuscitation *2285*
- Evaluation of Pleural Effusions *2287*
- Focused Assessment with Sonography in Trauma Exam for Free Fluid *2287*
- Procedural Guidance *2288*

Index 2291

CHAPTER

88

Role of Echocardiography in Cardio-oncology

Sibel Catirli Enar, Santhosh KG Koshy, Navin C Nanda

Snapshot

- Utility of Echocardiography in Assessing Cardiovascular Risk Prior to Institution of Treatment for Cancer
- Echocardiography during Chemotherapy
- Anthracyclines
- Vascular Endothelial Growth Factor Inhibitors and Tyrosine Kinase Inhibitors
- Proteasome Inhibitors
- Echocardiography after Chemotherapy
- Utility of Echocardiography in the Assessment of Cardiotoxicity
- Global Longitudinal Strain
- Changes in Left Ventricular Diastolic Function with Cancer Therapy
- Right Ventricular Function Changes after Chemotherapy and/or Radiotherapy
- Left Atrial Function Associated with Cancer Therapy
- Ischemic Heart Disease Associated with Cancer Therapy
- Cancer Therapy Affecting Cardiac Valves
- Pericardial Disease with Treatment of Cancer

INTRODUCTION

New therapeutic modalities have resulted in a considerable decrease in the mortality of cancer patients. However, chemotherapy agents and radiotherapy have cardiovascular side effects. Morbidity and mortality in cancer patients increase with the presence of concomitant cardiovascular diseases.[1] As stated in 2016 European Society of Cardiology (ESC) guidelines, cardiac and vascular complications of cancer treatment are left ventricular (LV) systolic and/or diastolic dysfunction (DD), subclinical heart failure, diseases affecting cardiac valves, pericardial involvement, ischemic heart disease, hypertension, arrhythmias, and arterial and venous diseases.[2]

Various cardiac imaging techniques may be used to diagnose cancer therapy-related cardiac dysfunction (CTRCD). Echocardiography is the most used and mostly available technique. Other techniques that are valuable are cardiac magnetic resonance imaging (CMR), cardiac computerized tomography (CCT), and nuclear imaging techniques like single photon emission computerized tomography and positron emission tomography.[3]

UTILITY OF ECHOCARDIOGRAPHY IN ASSESSING CARDIOVASCULAR RISK PRIOR TO INSTITUTION OF TREATMENT FOR CANCER

The American Society of Clinical Oncology (ASCO) 2017 guidelines categorized adult cancer patients who are at risk of developing LV dysfunction secondary to cancer-related treatment, and they are high-dose anthracycline (>250 mg/m^2), high-dose radiation therapy (>30 Gy), or low-dose anthracycline (<250 mg/m^2) in combination with low-dose radiation therapy (<30 Gy).[4] In addition, the presence of more than two cardiovascular risk factors, age >60 years, reduced or low normal LV ejection fraction (EF), previous myocardial infarction, or moderate valvular disease are also considered as a high risk for the development of CTRCD.[5]

According to the most recent guidelines published by the ESC, all patients planned to have cancer therapy should undergo a risk assessment and echocardiography should be performed to determine LV EF. These patients are divided into three categories: Low, medium, and high risk.

JAYPEE BROTHERS

Low-risk Group

This group includes patients who will be treated with a low dose of anthracycline trastuzumab therapy only and patients between 18 and 50 years of age.

Medium-risk Group

Medium-risk group includes patients who will be treated with a moderate dose of anthracyclines, anthracycline + trastuzumab therapy, vascular endothelial growth factor (VEGF) inhibitor, proteasome inhibitor, or immune checkpoint inhibitors, and patients with borderline LV EF between 50% and 54%, age 50–64 years, or having one to two cardiovascular risk factors.

High-risk Group

This group includes patients who will be treated with high-dose anthracyclines, anthracyclines + trastuzumab simultaneously, anthracyclines + radiation therapy, or high-dose chest radiation, and with a history of heart failure, LV EF <50%, age >65 years, more than two coronary artery disease (CAD) risk factors, or the presence of CAD. Those who have low-normal EF (50–54%) could be at high risk and should be followed during the therapy.[6]

The American Society of Echocardiography/European Association of Cardiovascular Imaging (ASE/EACVI) document published in 2014 recommends measuring baseline LV EF and global longitudinal strain (GLS) in those patients who are diagnosed with heart failure before undergoing cancer treatment.[7]

Recommendations for cardiac imaging in patients with cancer are as follows:

- Regular two-dimensional (2D) echocardiography is advocated as the initial procedure for the assessment of cardiac function in cancer patients (class IC recommendation).
- Three-dimensional (3D) echocardiography is advocated as the preferred procedure to calculate LV EF (class IB recommendation).
- LV GLS by speckle tracking echocardiography, if available, is recommended in all patients with cancer having echocardiography (class IC recommendation).

ECHOCARDIOGRAPHY DURING CHEMOTHERAPY

Chemotherapy-induced cardiotoxicity varies depending on the agent used. Chemotherapy could result in reversible or irreversible cardiotoxicity, and it is important to have knowledge of the intensity of damage as well as its reversibility while serially monitoring patients undergoing chemotherapy with agents that could cause cardiotoxicity.

ANTHRACYCLINES

These agents may cause irreversible cardiac dysfunction. Therefore, it is recommended to monitor these patients during the therapy. Factors that impact high risk for the development of anthracycline toxicity include a history of previous heart failure or, cardiomyopathy or chemotherapy-related cardiovascular disease, history of severe valvular heart disease, presence of CAD, LV EF <50%, age >80 years, and concomitant left chest radiotherapy.

Baseline echocardiography is advocated in all patients with cancer before anthracycline chemotherapy (Class I recommendation), and echocardiography is recommended after every two cycles and within 3 months after completing the therapy for high and very high-risk patients (Class 1 recommendation). Additional echocardiography may be considered after a >250 mg/m^2 or equivalent doxorubicin dose in moderate- or low-risk patients (Class 2 recommendation).[8]

Heart failure therapy may be started if necessary, depending on the clinical status of the patient in combination with echocardiographic indices. Cardiotoxicity mostly occurs within the first year after completion of therapy.[9] Late cardiotoxicity is mostly seen in pediatric cancer survivors.[10]

HER2-Targeted Treatment

Trastuzumab, Pertuzumab, and Lapatinib are most used in HER+ breast cancer therapy, and heart failure secondary to these agents is considered as reversible. Recommended echocardiographic evaluation for HER2-targeted therapy includes baseline echocardiography in all patients (Class 1 recommendation), and echocardiography every 4 months in low-risk patients who are asymptomatic and have normal echo after 3 months. More frequent echocardiographic monitoring should be considered in high and very high-risk patients (Class 2 recommendation). In metastatic HER2+ disease, echocardiography is recommended every 3 months during the first year (Class 1).[11,12]

VASCULAR ENDOTHELIAL GROWTH FACTOR INHIBITORS AND TYROSINE KINASE INHIBITORS

These drugs are used in solid tumor therapy such as renal cell cancer. Besides causing hypertension, they

JAYPEE BROTHERS

cause abnormalities in cardiac function in 3–15% of patients. Currently, echocardiography is recommended every 4 months during the therapy after initial baseline imaging.[11,13,14]

PROTEASOME INHIBITORS

Proteosome inhibitors like Carfilzomib, Ixazomib, and Bortezomib are therapeutic agents used in the management of multiple myeloma and mantle cell lymphoma. The risk of developing LV dysfunction is higher with Carfilzomib. According to the studies, cardiovascular events can occur as early as the first month of the therapy.[15] Multiple myeloma patients are also at risk of developing cardiac amyloidosis. Therefore, these patients also should be screened for amyloidosis.[6]

ECHOCARDIOGRAPHY AFTER CHEMOTHERAPY

Depending on the risk category, patients should be evaluated by echocardiography 6–12 months after chemotherapy. However, the ESC also recommends echocardiographic evaluation of patients at 1 and 5 years after high-dose anthracycline therapy or those who demonstrated LV dysfunction during therapy.

Cardiotoxicity may develop late in childhood cancer survivors with high total cumulative anthracycline doses (>400 mg/m^2 doxorubicin). It is recommended to screen these patients 2 years post therapy and then repeat every 5 years. Females treated with cardiotoxic agents and/or radiotherapy should be evaluated and counseled before planned pregnancy and during the first trimester of pregnancy.[4]

UTILITY OF ECHOCARDIOGRAPHY IN THE ASSESSMENT OF CARDIOTOXICITY

Various echocardiographic parameters, acting as surrogate markers, are affected by cardiotoxicity related to therapeutic interventions for cancer. Structural and functional assessment of cardiac structures can provide evidence for cardiac toxicity. Early detection of cardiac toxicity is important to institute therapeutic strategies that can prevent or retard worsening of cardiac function with continued treatment of cancer.

LV Systolic Function

The ASE/EACVI 2014 consensus statement defined CTRCD as a decline of LV EF >10% to an absolute value of <53%. As per the definition of CTRCD as outlined in the ESC/International Cardio-Oncology Society (ICOS) 2022 guidelines, patients are divided into two groups: Symptomatic and asymptomatic. Characteristics of cancer therapy-related cardiovascular toxicity are defined in each group. Severe CTRCD in symptomatic patients is defined as those who need heart failure hospitalization whereas in asymptomatic patients, severe CTRCD is defined as LV EF reduction to <40%.[7]

To account for the inter- and intraobserver variability, repeat echocardiographic examination is recommended within 2–3 weeks after the first echocardiogram demonstrating LV EF decline. LV EF is highly dependent on volume changes. A clinically significant deterioration is an increase of 15 mL for end-systolic LV volume or 30–35 mL in end-diastolic LV volume.[12]

The superiority of 3D volumes over 2D volumes is described in several studies. However, the feasibility of the 3D technique can be reduced with concomitant radiotherapy (breast cancer, lymphoma), surgery (left-sided mastectomy), or breast implants[16,17] because of a decrease in the size of acoustic windows.

GLOBAL LONGITUDINAL STRAIN

Left ventricular GLS is a new parameter to detect subclinical systolic dysfunction. A relative decrease of GLS >15% below the lower limit of normal or early reduction of GLS by 10–15% is considered as a marker of cardiotoxicity.[12,18] Changes in GLS could result in earlier detection of cardiotoxicity even before there is a change in LV EF. Detection of preclinical cardiotoxicity could result in better outcomes and overall cost of medical care and could complement LV EF as a surrogate marker for cardiotoxicity. Currently, surveillance strategies and therapeutic management strategies are based on changes in LV EF.[8,19]

There would be value in the assessment of LV EF and GLS serially since both parameters could be affected by various other factors, especially when the patient is acutely ill. This potential variability of these surrogate markers based on other clinical variables should be understood by the interpreting physician who directs therapeutic decisions.[20–22] Hence, there is an additional value for combining GLS measurement with LV EF assessment during serial monitoring of patients. However, the value of therapeutic decisions based on very early detection of cardiotoxicity with serial GLS measurement is not known. Therefore, therapeutic decisions solely based on the reduction of GLS are not the standard of care.[21]

JAYPEE BROTHERS

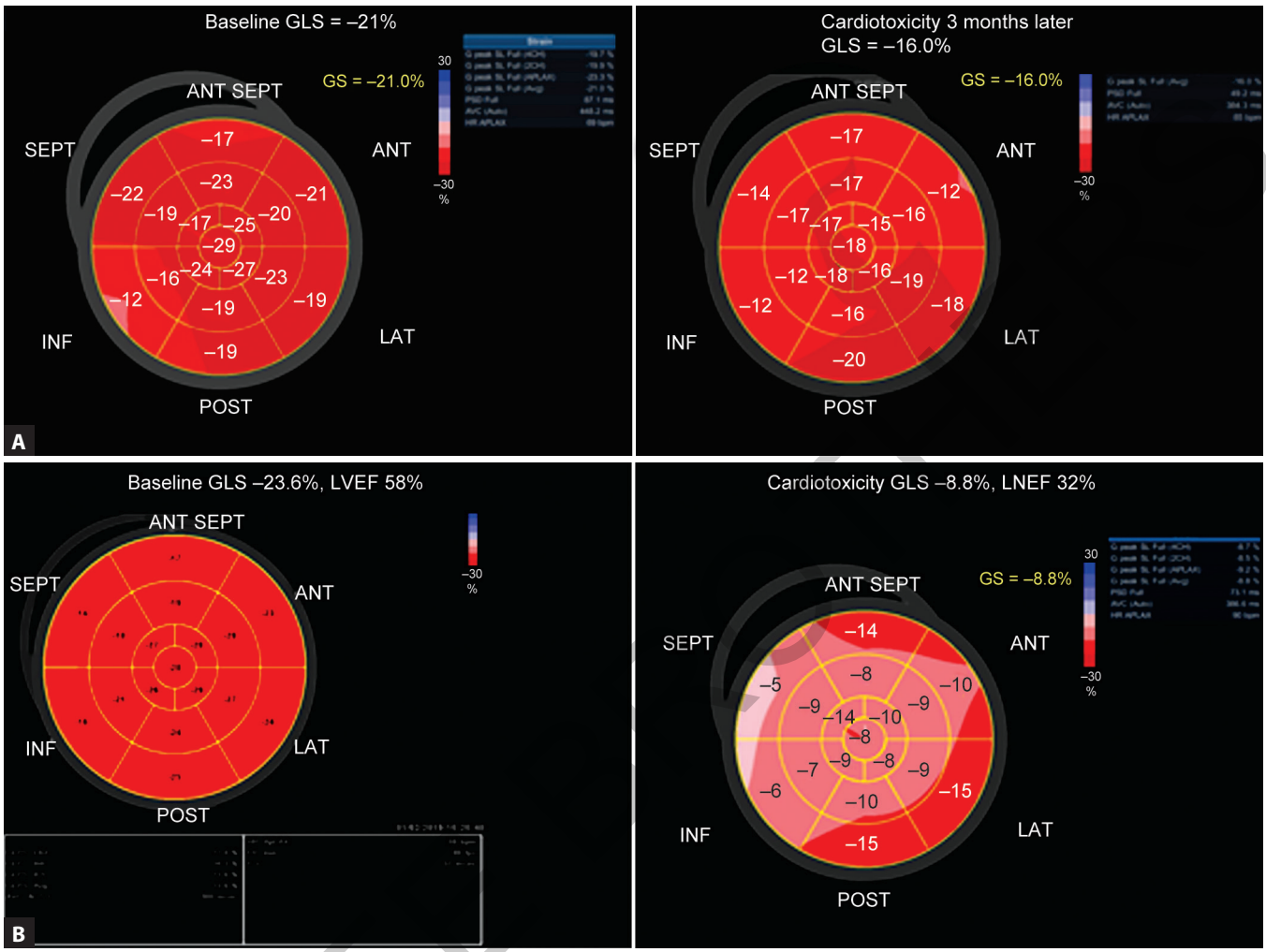

Figs. 1A and B: (A) Change in left ventricular global longitudinal strain (GLS) with mitogen/extracellular signal-regulated kinase inhibitor therapy. Pre (left panel) and post (right panel)-treatment strain assessment. Note a mild decrease in GLS from –21 to –16% following therapy; (B) Change in left ventricular GLS due to cardiotoxicity with vascular endothelial growth factor receptor kinase inhibitor (Lenvatinib) therapy for thyroid cancer. Pre (left panel and post (right panel)-treatment strain assessment. Note a marked decrease in GLS from –23.6 to –8.8% and left ventricular ejection fraction (LVEF) from 58 to 32% following treatment.

The standard recommendation is to average the GLS values from three apical (four-, two-, and three chamber) views. [19] Strain surveillance for improving cardiovascular outcomes during chemotherapy (SUCCOUR) study used and suggested that the GLS based on three apical views should remain as the preferred technique for the detection of cardiotoxicity.[23] The 3-year results of the SUCCOUR study with serial measurement in patients taking potentially cardiotoxic chemotherapy for cancer showed LV function improvement at 3 years compared to 1 year, however without a difference in change in LV EF between GLS- and LV EF-guided cardioprotection strategies[24] **(Figs. 1A and B)**.

In addition to GLS, LV global circumferential strain (GCS) has been studied in a few studies.[25,26] A study comparing strain-guided and 3D LV EF-guided therapy in patients treated with anthracyclines showed that both 3D LV EF and GCS predicted subsequent 2D LV EF in long-term follow-up.[27]

CHANGES IN LEFT VENTRICULAR DIASTOLIC FUNCTION WITH CANCER THERAPY

The mechanism of LV DD related to cancer treatment is not clearly known. Such LV DD is often seen in patients with normal weight and who are nondiabetic unlike in patients not receiving chemotherapy. Proposed causes

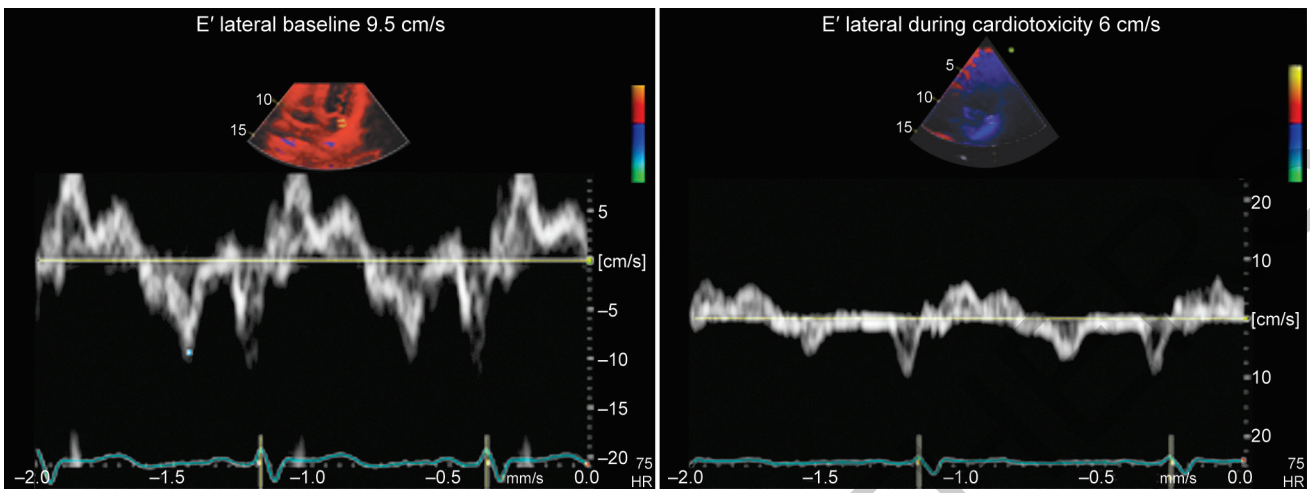

Fig. 2: Change in left ventricular diastolic function with cardiotoxicity: Pre (left panel) and post (right panel) chemotherapy with anthracyclines. Mitral lateral annulus E′ velocity measured by tissue Doppler echocardiography has reduced from 9.5 cm/s at baseline to 6 cm/s following therapy.

of LV DD associated with anthracycline therapy include microvascular dysfunction and altered interactions of Ca^{2+} with myofilaments during diastole. [28,29]

Left chest irradiation after anthracycline therapy is another risk factor for DD.[30] Imaging studies were able to show early changes in microvascular function in areas exposed to radiation.[31] Currently, LV diastolic function parameters for diagnosis and to guide therapy for cardiotoxicity are not well established. Changes in diastolic parameters such as mitral E/e′ velocity ratio and LV diastolic strain have been observed even as early as around the first week of chemotherapy in patients treated with anthracycline[32] **(Fig. 2)**.

A recent study evaluated the differential effect of breast cancer patients' treatment with Doxorubicin, Doxorubicin and Trastuzumab, or Trastuzumab alone for changes in LV diastolic function. Patients with Doxorubicin monotherapy or when combined with Trastuzumab showed worsening of LV DD over a 2-year follow-up.[33]

RIGHT VENTRICULAR FUNCTION CHANGES AFTER CHEMOTHERAPY AND/OR RADIOTHERAPY

The effect of chemotherapy and radiotherapy on right ventricular (RV) function has been studied in breast cancer and childhood cancer survivors. RV function was found to be impaired in survivors of acute lymphoblastic leukemia and lymphoma who underwent treatment with mediastinal radiation, anthracyclines, or both.[34,35] Radiation may cause a decrease in RV function in addition to LV function, especially when high doses (>15 Gy) of radiation therapy are used.[2]

In breast cancer patients, RV GLS impairment may be seen in addition to LV strain, and the lowest values are seen 6 months after therapy initiation.[36] Recommended echocardiographic parameters that are to be measured are tricuspid annular plane systolic excursion, RV free wall strain, and pulmonary artery systolic pressure at baseline and during therapy. The general cut-off point for cardiotoxicity is 15% change for RV strain.[6,37]

LEFT ATRIAL FUNCTION ASSOCIATED WITH CANCER THERAPY

There are a few studies that looked into left atrial (LA) function with cancer treatment. One study looked at LA function in children and adolescents who were treated with anthracycline. Prepubertal children with preserved LV EF treated with anthracyclines showed significant change in LA EF and LA GLS after chemotherapy. However, after adjustment for radiation dose, age, gender, body surface area, or cumulative anthracycline dose, there was no significant relationship with the absolute difference between pre- and post-LA EF or LA GLS.[38] Another study looked at the association between baseline LA size and future cardiotoxicity in patients with breast cancer who were treated with Trastuzumab. A larger LA size at baseline correlated with more cardiotoxicity after therapy.[39] In a more recent study by Emerson et al.,[40]

JAYPEE PROOF

anthracycline therapy for breast cancer treatment resulted in significantly lower LA reservoir strain and LA conduit strain without significant change in LA volumes. They also correlated these parameters with LV diastolic parameters; therefore, these LA strain parameters may be an early marker of LV DD in these patients. Recommended parameters for left atrium evaluation are: LA volume index, LA EF, and LA strain. Similar to >15% reduction in LV GLS, >15% reduction in LA strain compared to baseline is considered as significant.

ISCHEMIC HEART DISEASE ASSOCIATED WITH CANCER THERAPY

Several of the chemotherapeutic agents cause endothelial dysfunction, functional microvascular changes, and coronary artery injury and disease. Few of these agents are 5-FU and Capecitabine causing endothelial injury and vasospasm, Cisplatin causing arterial thrombosis, VEGF inhibitor causing arterial thrombosis, endothelial injury, and hypertension, tyrosine kinase inhibitors causing arterial thrombosis and hypertension, and radiotherapy causing endothelial injury, plaque rupture, and thrombosis.[41]

Utility of Stress Echocardiography

Stress echocardiography is an important technique to evaluate global as well as regional LV function during bicycle or treadmill exercise or using pharmacologic agents such as dobutamine or dipyridamole. This technique has the advantage of low cost, lack of ionizing radiation exposure, and relative safety.[42-44] Stress echocardiography is also of value in the evaluation of patients with intermediate to high pretest probability of CAD, evaluation of subclinical LV dysfunction and contractile reserve, and evaluation of abnormalities of cardiac valves that are associated with chemo- or radiotherapy but commonly after radiotherapy.[41,45,46]

Type of Stress Echocardiography

Exercise is the preferred technique. In patients who cannot perform the exercise (due to fatigue, muscle pain, etc.), pharmacological stress echo may be performed. However, in patients who receive anticancer treatment, dobutamine is not preferred due to its propensity to cause arrhythmias.[47] The advantages of physical stress test are that it is more physiologic, safe, and less expensive when compared with pharmacological stress tests. The disadvantages are that this test is not feasible in patients who have a disability, and it is contraindicated in patients with bone metastases, sarcopenia, or cachexia.

Dobutamine stress echocardiography is the best test to evaluate myocardial viability, and it is feasible in patients with asthma; however, the presence of severe hypertension or severe arrhythmias are contraindications for dobutamine stress echocardiography. On the other hand, dipyridamole stress echocardiography is safer since it has no arrhythmogenic or hypertensive effect. However, it is contraindicated in patients who have severe electrophysiological conduction abnormalities or advanced asthma.[41]

Future Directions

Strain measures during low-dose dobutamine stress echocardiography have been studied in children who have survived cancer. They were found to have impaired myocardial contractile reserve and suboptimal strain values. Therefore, it is suggested that dobutamine stress echocardiography may help to identify subclinical heart failure in this patient group.[48] 3D stress echocardiography may better identify myocardial dysfunction, and contrast echocardiography can improve the assessment of myocardial wall segments.[49] However, currently, there are no large studies to prove the utility of these techniques.

CANCER THERAPY AFFECTING CARDIAC VALVES

Secondary abnormalities of cardiac valves are most seen in patients who have received radiation in the past. Structural and functional abnormalities of cardiac valves have been described in patients who had radiation for Hodgkin lymphoma, non-Hodgkin lymphoma, breast cancer, lung cancer, or esophageal carcinoma.[50,51]

Mitral and aortic valves are more commonly affected than tricuspid and pulmonary valves. Valvular pathology may present as regurgitation or stenosis. Radiation may cause damage to leaflets and cause fibrotic thickening, retraction, and calcification. In addition, annulus, subvalvular apparatus, and aortomitral curtain are also affected. Calcification of the aortomitral curtain is considered as the hallmark of radiation-associated valvular disease (RAVD)[52] **(Fig. 3)**.

Radiation causes a degenerative process that begins with valve retraction resulting in regurgitation, followed by thickening and calcification of the valves ultimately

JAYPEE BROTHERS

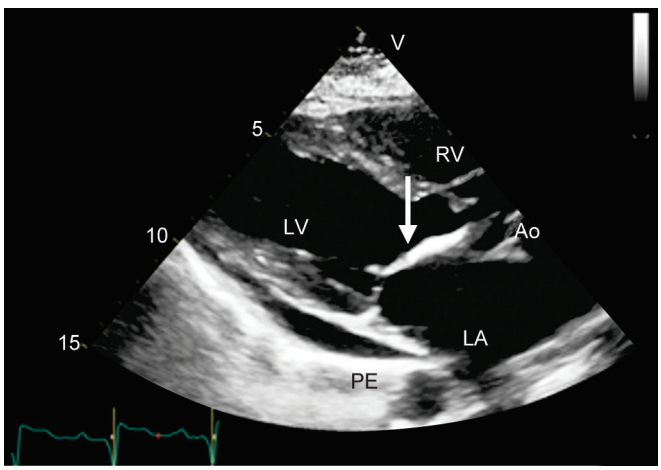

Fig. 3: Systolic frame in parasternal long-axis view showing calcified aortomitral curtain (white arrow) from remote (20 years before) radiation treatment for Hodgkin lymphoma. (Ao: aorta; LA: left atrium; LV: left ventricle; PE: pericardial effusion; RV: right ventricle)

leading to stenosis.[53] Development of clinically significant RAVD occurs after a latent period (one to two decades), and the most common forms are aortic regurgitation, mitral regurgitation, and aortic stenosis in that order.

As per the 2013 EACVI/ASE guidelines, it is recommended to perform echocardiography after 5 years of radiotherapy in asymptomatic patients who have high risk. Anterior or left-sided chest radiotherapy and the presence of risk factors for developing heart disease such as hypertension, diabetes mellitus, hyperlipidemia, obesity, or smoking are associated with a higher risk for RAVD. In patients who are asymptomatic, but have low risk, it is recommended to screen 10 years after radiotherapy and then every 5 years afterward.

The main tool to diagnose valvular pathology is 2D transthoracic echocardiography (TTE). A typical finding in echocardiography is commissural fusion after radiotherapy.[1] Although TTE is the most common technique to screen these patients, 2D transesophageal echocardiography (TEE) and multidetector computed tomography (MDCT) may provide additional information.[54] TTE carries advantages that it is easily accessible, has low risk, and can assess cardiac function, valves, and pericardium as well. Disadvantages are that the presence of severe calcification or low stroke volume can limit accurate assessment.

Transesophageal echocardiography is useful when TTE cannot provide accurate assessment and has superior temporal and spatial resolution. Like TTE, severe calcification of the valves and low stroke volume can limit accurate assessment.

Cardiac magnetic resonance imaging is of value in patients with poor transthoracic acoustic windows, and it is considered the standard imaging technique for the assessment of cardiac chambers and has superior temporal resolution than CCT. However, it can be difficult to tolerate for patients when serial imaging is required and in the presence of arrhythmias. With CCT, it is possible to assess coronary pathology. It can be used to assess coronary artery stenosis severity and it has superior spatial resolution than CMR. Disadvantages of CCT include radiation exposure and the need to administer intravenous contrast agents with the potential for nephrotoxicity.[55]

PERICARDIAL DISEASE WITH TREATMENT OF CANCER

The pericardium can be affected by the cancer itself or as an adverse effect of chemotherapy or radiation therapy. Primary malignancies like mesothelioma, metastatic disease from the lung, breast, lymphoma, and melanoma can involve pericardium.[56]

Chemotherapy

The pericardium can be affected by various chemotherapeutic agents. Therapeutic regimens that include anthracyclines, protein kinase inhibitors, agents like Dasatinib used in leukemia, immunotherapy agents like immune checkpoint inhibitors, cytotoxic T-lymphocyte-associated protein 4 antibodies like Ipilimumab, program cell death protein 1 antibodies like Nivolumab, and program cell death ligand 1 antibodies like Avelumab used in renal cell cancer and nonsmall cell lung cancer can affect pericardium.[57,58] These agents can cause pericarditis, pericardial effusion, or tamponade with or without concomitant myocarditis. It occurs often after one or two administrations of therapy and within a median of 30 days.[59,60]

Radiation Therapy

Radiation therapy is commonly used in the treatment of Hodgkin lymphoma, lung, and breast cancer. Radiation therapy-induced pericardial disease can manifest as acute or chronic clinical presentation. Acute pericarditis is currently rare with the current technical modification of the delivery of radiation. It can develop as soon as hours to several weeks after the last dose.[7,61-63] Late

JAYPEE BROTHERS

radiotherapy-induced pericarditis is related to the development of fibrosis and primarily affects the parietal pericardium. This leads to thickening and results in the formation of constrictive pericarditis. It occurs years or decades after radiotherapy and therefore most commonly occurs in childhood cancer survivors. In elderly patients, concomitant chemotherapy, pre-existing cardiovascular disease, and presence of additional risk factors can result in the development of pericardial disease. Restrictive cardiomyopathy could also be seen in patients who had been treated with radiotherapy. Therefore, it is important to distinguish it from constrictive pericarditis.[61-65]

The pericardium can be affected during the treatment of cancer by either radiation or chemotherapy alone or during combination therapy with both. Common presentations are acute pericarditis, pericardial effusion, cardiac tamponade, chronic pericarditis, pericardial fibrosis or calcifications, and constrictive pericarditis.[66]

Imaging Techniques

According to ASE recommendations, echocardiography is considered as the imaging modality of choice for the diagnosis of radiation-induced pericardial disease. It is possible to detect pericardial effusion and its quantification. Pericardial thickness, diastolic collapse of right heart chambers in tamponade, diastolic ventricular septal bounce, and respiratory variation of mitral and tricuspid flow velocities as a sign of constriction could be identified with echocardiography.[67] It is a noninvasive and easily available imaging modality. Addition addition of multimodality imaging with CCT and magnetic resonance imaging (MRI) in addition to TTE can provide better tissue characterization and help in distinguishing patients with constriction from restrictive cardiomyopathy.[8,51]

CONCLUSION

Echocardiography remains the primary imaging modality and the gold standard for the diagnosis of cancer therapy-related cardiotoxicity. It is widely used in the initial assessment as well as during serial follow-up to evaluate the progression of cardiotoxicity. Early detection of these cardiac complications during the treatment of cancer may decrease heart disease-related mortality in these patients.

ACKNOWLEDGMENT

The authors thank Anita Deswal, MD, FACC, Professor and Chairman of Department of Medicine, MD Anderson Cancer Center, Houston, Texas, USA for contributing pictures that are included as figures in this chapter.

REFERENCES

1. Ntoskas. Advanced Concepts in Endocarditis. Cardio-oncology: The Role of Echocardiography in Cancer Patients. Chapter 4. 2021. Intech Open.
2. Zamorano JL, Lancellotti P, Rodriguez Muñoz D, Aboyans V, Asteggiano R, Galderisi M, et al. 2016 ESC Position Paper on cancer treatments and cardiovascular toxicity developed under the auspices of the ESC Committee for practice guidelines: the Task Force for cancer treatments and cardiovascular toxicity of the European Society of Cardiology (ESC) ESC Scientific Document Group. Eur Heart J. 2016;37(36):2768-801.
3. Addison D, Neilan TG, Barac A, Scherrer-Crosbie M, Okwuosa TM, Plana JC, et al. Cardiovascular imaging in contemporary cardio-oncology: a scientific statement from the American Heart Association. American Heart Association Council on Cardiovascular Radiology and Intervention; Cardio-Oncology Committee of the Council on Clinical Cardiology and Council on Genomic and Precision Medicine; and Council on Cardiovascular and Stroke Nursing. Circulation. 2023;148(16):1271-86.
4. Armenian SH, Hudson MM, Mulder RL, Chen MH, Constine LS, Dwyer M, et al. Recommendations for cardiomyopathy surveillance for survivors of childhood cancer: a report from the International Late Effects of Childhood Cancer Guideline Harmonization Group. International Late Effects of Childhood Cancer Guideline Harmonization Group. Lancet Oncol. 2015;16(3):e123-36.
5. Liu J, Banchs J, Mousavi N, Plana JC, Scherrer-Crosbie M, Thavendiranathan P, et al. Contemporary role of echocardiography for clinical decision making in patients during and after cancer therapy. Am Coll Cardiol Cardiovasc Imaging. 2018;11(8):1122-31.
6. Frey MK, Bergler-Klein J. Echocardiographic evaluation of patients undergoing cancer therapy. J Eur Heart J Cardiovasc Imaging. 2021;22(4):375-82.
7. Plana JC, Galderisi M, Barac A, Ewer MS, Ky B, Scherrer-Crosbie M, et al. Expert consensus for multimodality imaging evaluation of adult patients during and after cancer therapy: a report from the American Society of Echocardiography and the European Association of Cardiovascular Imaging. Am Soc Echocardiogr. 2014;27(9):911-39.
8. Lyon AR, López-Fernández T, Couch LS, Asteggiano R, Aznar MC, Bergler-Klein J, et al. 2022 ESC Guidelines on cardio-oncology developed in collaboration with the European Hematology Association (EHA), the European Society for Therapeutic Radiology and Oncology (ESTRO) and the International Cardio-Oncology Society (IC-OS); ESC Scientific Document Group. Eur Heart J. 2022;43(41):4229-361.

JAYPEE BROTHERS

9. Cardinale D, Colombo A, Bacchiani G, Tedeschi I, Meroni CA, Veglia F, et al. Circulation. Early detection of anthracycline cardiotoxicity and improvement with heart failure therapy. Circulation. 2015;131(22):1981-8.
10. Mulrooney DA, Armstrong GT, Huang S, Ness KK, Ehrhardt MJ, Joshi VM, et al. Cardiac outcomes in adult survivors of childhood cancer exposed to cardiotoxic therapy: a cross-sectional study. Ann Intern Med. 2016;164(2):93-101.
11. Lyon AR, Dent S, Stanway S, Earl H, Brezden-Masley C, Cohen-Solal A, et al. Baseline cardiovascular risk assessment in cancer patients scheduled to receive cardiotoxic cancer therapies: a position statement and new risk assessment tools from the Cardio-Oncology Study Group of the Heart Failure Association of the European Society of Cardiology in collaboration with the International Cardio-Oncology Society. Eur J Heart Fail. 2020;22(11):1945-60.
12. Zamorano JL, Rosano G, Coats AJS, Asteggiano R, Seferovic P, Edvardsen T, et al. Role of cardiovascular imaging in cancer patients receiving cardiotoxic therapies: a position statement on behalf of the Heart Failure Association (HFA), the European Association of Cardiovascular Imaging (EACVI) and the Cardio-Oncology Council of the European Society of Cardiology (ESC). Eur Heart Fail. 2020;22(9):1504-24.
13. Steingart RM Chandrashekhar Y, Marwick TH. Imaging in cardio-oncology: where are we and where should we be going? J Am Coll Cardiol Cardiovasc Imaging. 2018;11(8): 1209-11.
14. Qi WX, Shen Z, Tang LN, Yao Y. Congestive heart failure risk in cancer patients treated with vascular endothelial growth factor tyrosine kinase inhibitors: a systematic review and meta-analysis of 36 clinical trials. Br J Clin Pharmacol. 2014; 78(4):748-62.
15. Cornell RF, Ky B, Weiss BM, Dahm CN, Gupta DK, Du L, et al. Prospective study of cardiac events during proteasome inhibitor therapy for relapsed multiple myeloma. J Clin Oncol. 2019;37(22):1946-55.
16. Thavendiranathan P, Amir E. Left ventricular dysfunction with trastuzumab therapy: is primary prevention the best. J Clin Oncol. 2017;35(8):820-5.
17. Santoro C, Arpino G, Esposito R, Lembo M, Paciolla I, Cardalesi C, et al. 2D and 3D strain for detection of subclinical anthracycline cardiotoxicity in breast cancer patients: a balance with feasibility. Eur Heart J Cardiovasc Imaging. 2017;18(8):930-6.
18. Potter E, Marwick TH. Assessment of left ventricular function by echocardiography: the case for routinely adding global longitudinal strain to ejection fraction. J Am Coll Cardiol Cardiovasc Imaging. 2018;11(2 Pt 1): 260-74.
19. Nolan MT, Plana JC, Thavendiranathan P, Shaw L, Si L, Marwick TH, et al. Cost-effectiveness of strain-targeted cardioprotection for prevention of chemotherapy-induced cardiotoxicity. Int J Cardiol. 2016; 212:336-45.
20. Thavendiranathan P, Poulin F, Lim KD, Plana JC, Woo A, Marwick TH. Use of myocardial strain imaging by echocardiography for the early detection of cardiotoxicity in patients during and after cancer chemotherapy: a systematic review. J Am Coll Cardiol. 2014;63(25 Pt A): 2751-68.
21. Yeh ETH, Vejpongsa P. Subclinical cardiotoxicity associated with cancer therapy: early detection and future directions. J Am Coll Cardiol. 2015;65(23):2523-5.
22. Koneru S, Collier P, Goldberg A, Sanghi V, Grimm DO, Rodriguez L, et al. Temporal variability of global longitudinal strain in stable patients undergoing chemotherapy with trastuzumab. Am J Cardiol. 2016;118(6):930-5.
23. Thavendiranathan P, Negishi T, Coté MA, Penicka M, Massey R, Cho GY, et al.; SUCCOUR Investigators. Single versus standard multiview assessment of global longitudinal strain for the diagnosis of cardiotoxicity during cancer therapy. Am Coll Cardiol Cardiovasc Imaging. 2018;11(8):1109-18.
24. Negishi T, Thavendiranathan P, Penicka M, Lemieux J, Murbraech K, Miyazaki S, et al. Cardio protection using strain-guided management of potentially cardiotoxic cancer therapy: 3-year results of the SUCCOUR trial. J Am Coll Cardiol Cardiovasc Imaging. 2023;16(3):269-78.
25. Mavinkurve-Groothuis AM, Marcus KA, Pourier M, Loonen J, Feuth T, Hoogerbrugge PM, et al. Myocardial 2D strain echocardiography and cardiac biomarkers in children during and shortly after anthracycline therapy for acute lymphoblastic leukemia (ALL): a prospective study. Eur Heart J Cardiovasc Imaging. 2013;14(6):562-9.
26. Moudgil R, Hassan S, Palaskas N, Lopez-Mattei J, Banchs J, Yusuf SW, et al. Evolution of echocardiography in subclinical detection of cancer therapy-related cardiac dysfunction. Echocardiography. 2018;35(6):860-8.
27. Zhang KW, Finkelman BS, Gulati G, Narayan HK, Upshaw J, Narayan V, et al. Abnormalities in 3-dimensional left ventricular mechanics with anthracycline chemotherapy are associated with systolic and diastolic dysfunction. J Am Coll Cardiol Imaging. 2018;11:1059-68.
28. Minotti G, Menna P, Camilli M, Salvatorelli E, Levi R. Beyond hypertension: diastolic dysfunction associated with cancer treatment in the era of cardio-oncology. Adv Pharmacol. 2022;94:365-409.
29. Mohammed SF, Hussain S, Mirzoyev SA, Edwards WD, Maleszewski JJ, Redfield MM, Coronary microvascular rarefaction and myocardial fibrosis in heart failure with preserved ejection fraction. Circulation. 2015;131(6):550-9.
30. Cao L, Cai G, Chang C, Miao AY, Yu XL, Yang ZZ, et al. Diastolic dysfunction occurs early in HER2-positive breast cancer patients treated concurrently with radiation therapy and trastuzumab. Oncologist. 2015;20(6):605-14.
31. Song J, Yan R, Wu Z, Li J, Yan M, Hao X, et al. 13N-Ammonia PET/CT detection of myocardial perfusion abnormalities in beagle dogs after local heart irradiation. Nucl Med. 2017;58(4):605-10.

JAYPEE BROTHERS

32. Stoodley PW, Richards DA, Boyd A, Hui R, Harnett PR, Meikle SR, et al. Altered left ventricular longitudinal diastolic function correlates with reduced systolic function immediately after anthracycline chemotherapy. Eur Heart J Cardiovasc Imaging. 2013;14(3):228-34.
33. Upshaw JN, Finkelman B, Hubbard RA, Smith AM, Narayan HK, Arndt L, et al. Comprehensive assessment of changes in left ventricular diastolic function with contemporary breast cancer therapy. JACC Cardiovasc Imaging. 2020;13(1 Pt 2):198-210.
34. Christiansen JR, Massey R, Dalen H, Kanellopoulos A, Hamre H, Ruud E, et al. Right ventricular function in long-term adult survivors of childhood lymphoma and acute lymphoblastic leukemia. Eur Heart J Cardiovasc Imaging. 2016;17(7):735-41.
35. Bergler-Klein J. Right from the heart: survivors of childhood cancer and the right ventricle (editorial). Eur Heart J Cardiovasc Imaging. 2016;17(7):742-3.
36. Keramida K, Farmakis D. Right ventricular involvement in cancer therapy-related cardiotoxicity: the emerging role of strain echocardiography. Heart Fail Rev. 2020;26(5): 1189-93.
37. Tadic M, Cuspidi C, Hering D, Marwick TH. The influence of chemotherapy on the right ventricle: did we forget something? Clin Cardiol. 2017;40(7):437-43.
38. Patel NR, Chyu CK, Satou GM, Halnon NJ, Nguyen KL. Left atrial function in children and young adult cancer survivors treated with anthracyclines. Echocardiography. 2018;35(10):1649-56.
39. Bergamini C, Dolci G, Rossi A, Torelli F, Ghiselli L, Trevisani L, et al. Left atrial volume in patients with HER2-positive breast cancer: one step further to predict trastuzumab-related cardiotoxicity. Clin Cardiol. 2018;41(3):349-53.
40. Emerson P, Stefani L, Boyd A, Richards D, Hui R, Altman M, et al. Alterations in left atrial strain in breast cancer patients immediately post anthracycline exposure. Heart Lung Circ. 2023;33:S1443-9506(23)04291-9.
41. Novo G, Santoro C, Manno G, Di Lisi D, Esposito R, Mandoli GE, et al. Usefulness of stress echocardiography in the management of patients treated with anticancer drugs J Am Soc Echocardiogr. 2021;34(2):107-16.
42. Lancellotti P, Pellikka PA, Budts W, Chaudhry FA, Donal E, Dulgheru R, et al. The clinical use of stress echocardiography in non-Ischemic heart disease: recommendations from the European Association of Cardiovascular Imaging and the American Society of Echocardiography. J Am Soc Echocardiogr. 2017;30(2):101-38.
43. Picano E, Ciampi Q, Citro R, D'Andrea A, Scali MC, Cortigiani L, et al. Stress echo 2020: the international stress echo study in ischemic and non-ischemic heart disease. Cardiovasc Ultrasound. 2017;15(1):3.
44. Picano E, Scali MC. Stress echocardiography, carotid arteries, and more: its versatility for our imaging time. Am Coll Cardiol Cardiovasc Imaging. 2018;11(2 Pt 1):181-3.
45. Carpeggiani C, Landi P, Michelassi C, Andreassi MG, Sicari R, Picano E. Stress echocardiography positivity predicts cancer death. J Am Heart Assoc. 2017;6(12):e007104.
46. Yeh ETH, Bickford CI. Cardiovascular complications of cancer therapy: incidence, pathogenesis, diagnosis, and management. Am Coll Cardiol. 2009;53:2231-47.
47. Tamargo J, Caballero R, Delpón E. Cancer chemotherapy and cardiac arrhythmias: a review. Drug Saf. 2015;38(2): 129-52.
48. Broberg O, Ora I, Weismann CG, Wiebe T, Liuba P. Childhood cancer survivors have impaired strain-derived myocardial contractile reserve by dobutamine stress echocardiography. J Clin Med. 2023;12(8):2782.
49. Wang S, Wang Y, Wang S. The role of stress echocardiography in identifying cardiotoxicity: an in-depth exploration. Front Cardiovasc Med. 2024;11:1236966.
50. Stewart ME, Jahangir E, Polin MP. Valvular heart disease in cancer patients: etiology, diagnosis, and management. Curr Treat Options Cardiovasc Med. 2017;19:53.
51. Bergom C, Bradley JA, Ng AK, Samson P, Robinson C, Lopez-Mattei J, et al. Past, present, and future of radiation-induced cardiotoxicity: refinements in targeting, surveillance, and risk stratification. J Am Coll Cardiol CardioOncol. 2021; 3(3):343-59.
52. Desai MY, Wu W, Masri A, Popovic ZB, Agarwal S, Smedira NG, et al. Increased aorto-mitral curtain thickness independently predicts mortality in patients with radiation-associated cardiac disease undergoing cardiac surgery. Ann Thorac Surg. 2014;97(4):1348-55.
53. Rutkovskiy A, Malashicheva A, Sullivan G et al. J Valve interstitial cells: the key to understanding the pathophysiology of heart valve calcification. Am Heart Assoc. 2017;6(9):e006339.
54. Xu S, Donnellan E, Desai MY. Radiation-associated valvular disease. Curr Cardiol Rep. 2020;22(12):167.
55. Lee C, Hahn RT. Valvular heart disease associated with radiation therapy: a contemporary review. Struct Heart. 2022;7(2):100104.
56. Burazor I, Aviel-Ronen S, Imazio M, Markel G, Grossman Y, Yosepovich A, et al. Primary malignancies of the heart and pericardium. Clin Cardiol. 2014;37(9):582-8.
57. Chahine J, Shekhar S, Mahalwar G, Imazio M, Collier P, Klein A. Pericardial involvement in cancer. Am J Cardiol. 2021;145;151-9.
58. Wattal S, Rao MS, Chandra GN, Razak UK, Shetty KR. Dasatinib induced cardiac tamponade—a rare association. J Clin Diagn Res. 2017;11(2):FD03-4.
59. Ribas A, Wolchok JD. Cancer immunotherapy using checkpoint blockade. Science. 2018;359(6382):1350-5.
60. Salem JE, Manouchehri A, Moey M, Lebrun-Vignes B, Bastarache L, Pariente A, et al. Cardiovascular toxicities associated with immune checkpoint inhibitors: an observational, retrospective, pharmacovigilance study. Lancet Oncol. 2018;19(12):1579-89.

JAYPEE BROTHERS

61. Szpakowski N, Desai MY. Radiation-associated pericardial disease. Curr Cardiol Rep. 2019;21(9):97.
62. Ala CK, Klein AL, Moslehi JJ. Cancer treatment-associated pericardial disease: epidemiology, clinical presentation, diagnosis, and management. Curr Cardiol Rep. 2019;21(12): 156.
63. Desai MY, Jellis CL, Kotecha R, Johnston DR, Griffin BP. Radiation-associated cardiac disease: a practical approach to diagnosis and management. J Am Coll Cardiol Cardiovasc Imaging. 2018;11(8):1132-49.
64. Gevaert SA, Halvorsen S, Sinnaeve PR, Sambola A, Gulati G, Lancellotti P, et al. Evaluation and management of cancer patients presenting with acute cardiovascular disease: a Clinical Consensus Statement of the Acute Cardiovascular Care Association (ACVC) and the ESC council of Cardio-Oncology-part 2: acute heart failure, acute myocardial diseases, acute venous thromboembolic diseases, and acute arrhythmias. Eur Heart J Acute Cardiovasc Care. 2022;11(11):865-74.
65. Marinko T. Pericardial disease after breast cancer radiotherapy. Radiol Oncol. 2018;53(1):1-5.
66. von Kemp BA, Cosyns B. Radiation-induced pericardial disease: mechanisms, diagnosis, and treatment. Curr Cardiol Rep. 2023;25(10):1113-21.
67. Klein AL, Abbara S, Agler DA, Appleton CP, Asher CR, Hoit B, et al. American Society of Echocardiography clinical recommendations for multimodality cardiovascular imaging of patients with pericardial disease: endorsed by the Society for Cardiovascular Magnetic Resonance and Society of Cardiovascular Computed Tomography. J Am Soc Echocardiogr. 2013;26(9):965-1012. e15.

JAYPEE BROTHERS

for detailed information on cardiology books, visit our website www.jaypeebrothers.com, for detailed information on cardiology books, visit our website www.j

Comprehensive Textbook of Echocardiography

Salient Features

- This book is probably the largest book on Echocardiography till date
- Covers all aspects of echocardiography and cardiovascular ultrasound in a comprehensive manner
- Written by over 150 internationally renowned experts in the field of echocardiography from all over the world
- Supplemented by a huge number of illustrations (5,637) and 1852 Movie Clips
- Written in a clear, coherent, and easy-to-grasp language
- This edition has been updated to cover all recent advances in Echocardiography.

Navin C Nanda MD DSc (Hon) DSc (Med) (Hon) FACC FAHA FASE FISCU (D) is Distinguished Professor of Medicine and Cardiovascular Disease, University of Alabama at Birmingham, AL, USA. He is a nationally and internationally renowned Cardiologist and Echocardiographer and a Pioneer in Echocardiography and Cardiovascular Ultrasound. His pioneering contributions, which have "significantly altered the way cardiology is practiced in the world today", include the following: He with his group is the first to discover the pulmonary valve by echo, which spurred development of pediatric echocardiography. He is the first to diagnose a bicuspid aortic valve by echo and invented treadmill exercise echocardiography. He introduced color Doppler to the USA. He invented the technique of transpharyngeal and transgastric ultrasound and developed the clinical technique of real-time three-dimensional transesophageal echocardiography. He pioneered the use of echocardiography in cardiac pacing and electrophysiology. He with his group also introduced pulse Doppler, color Doppler, and real-time three-dimensional echocardiography in the cardiac evaluation of the fetus. He is the first to study and show a high incidence of myocardial infarction in young adults in India and relationship of diabetes mellitus to myocardial infarction. He has been recognized as the *Father of Echocardiography/Father of Modern Echocardiography* by many institutions and medical societies throughout the world for his pioneering work in adult, pediatric, and fetal echocardiography. In 2018, he was awarded the "Life-time Achievement Award" by the American Society of Echocardiography. In 2023, the Cardiology Society of India honored him for "his pioneering contributions to the development of Echocardiography/Cardiology in India over the past several decades, way more than any other foreign physician". In 2024, the Indian Academy of Echocardiography honored him "for pioneering the development of echocardiography". This year, the American College of Cardiology decided to rename its distinguished annual award as the "Navin C Nanda International Service Award", in perpetuity, in recognition of his "unparalleled contributions" which have "profoundly shaped the field of cardiology" and his tireless commitment to advancing cardiovascular care on an international scale. Three institutions and two prominent echocardiography laboratories are named after him in India. In addition, "Dr Navin Nanda Echocardiographic and Vascular Training Academy" has been established in his honor in the country of Philippines. He has over 1,000 scientific publications (over 540 original, full length, and peer-reviewed) to his credit including 18 books on echocardiography and cardiology, 4 of which have been translated into Italian, French, German, and Turkish languages. Besides, he has also authored six video textbooks/CDs. He has given over 2,000 scientific presentations including many as a Visiting Professor.

Printed in India

Available at all medical bookstores or buy online at www.ejaypee.com

JAYPEE BROTHERS
Medical Publishers (P) Ltd.
EMCA House, 23/23-B, Ansari Road,
Daryaganj, New Delhi - 110 002, INDIA
www.jaypeebrothers.com

Join us on facebook.com/JaypeeMedicalPublishers
Follow us on instagram.com/JaypeeMedicalPublishers

Shelving Recommendation
CARDIOLOGY

ISBN 978-93-6616-211-9