ooks, visit our website www.ejaypee.com, for detailed information on surgery books, visit our website www.ejaypee.com, for detailed information on surgery books,

Fully Revised & Updated

S Das



18th Edition Revised Reprint

A Manual on CLINICAL SURGERY

With New Diagnostic Algorithms, Special Investigations & Differential Diagnosis

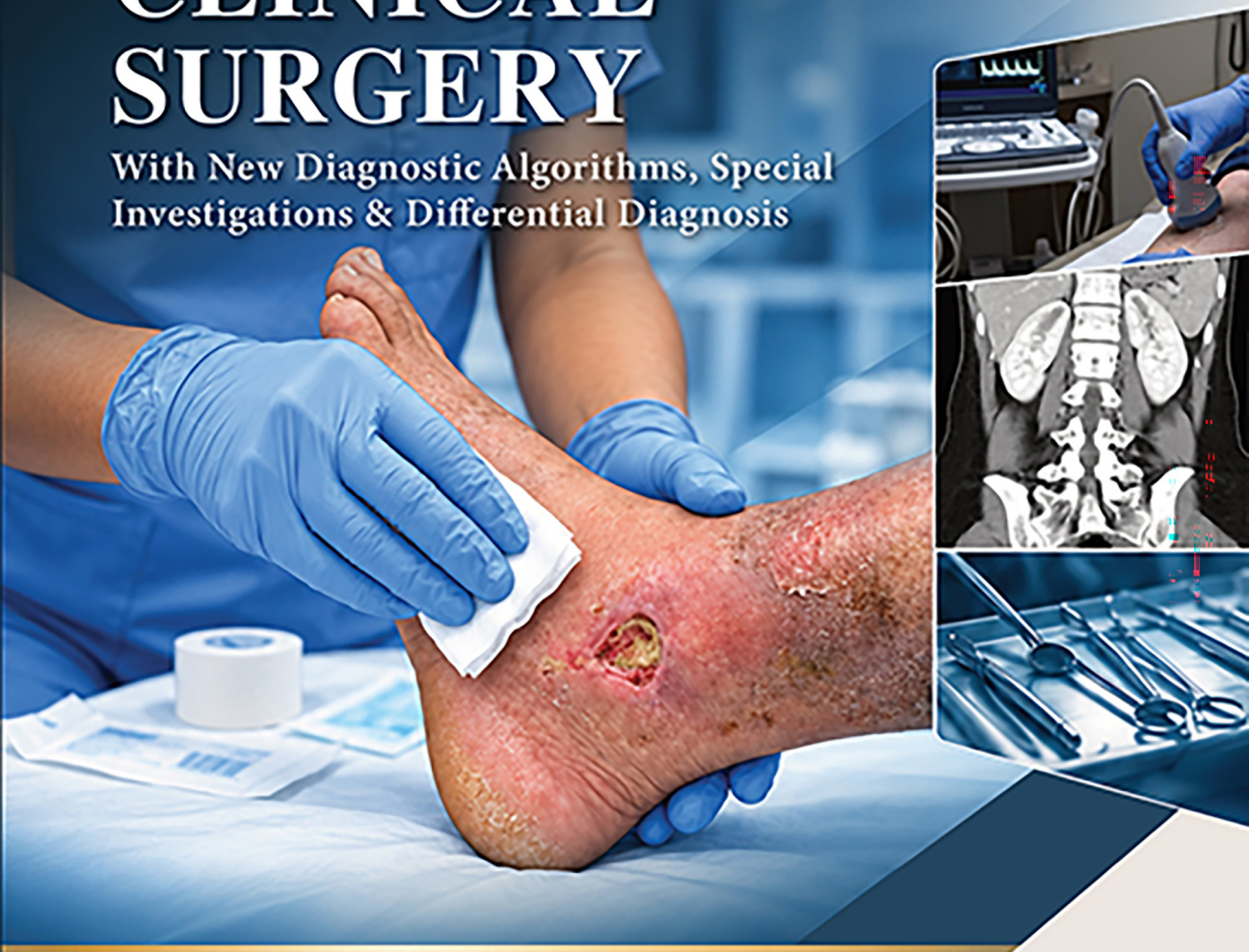

New! Introducing Clinical Masterclass

Your Online Clinical Learning Companion with Genuine Book

- 40 Examination Videos to sharpen clinical examination skills
- 40 Audio Case Files to strengthen case-based understanding

Genuine?
Scratch, Scan & Validate

JAYPEE

CONTENTS

Chapter 1: General Scheme of Case Taking 1
Chapter 2: A Few Special Symptoms and Signs 14
Chapter 3: Examination of a Lump or a Swelling 26
Chapter 4: Examination of an Ulcer 68
Chapter 5: Examination of a Sinus or a Fistula 85
Chapter 6: Examination of Peripheral Vascular Disease and Gangrene 92
Chapter 7: Examination of Varicose Veins 114
Chapter 8: Examination of the Lymphatic System 126
Chapter 9: Examination of Peripheral Nerve Lesions 142
Chapter 10: Diseases of Muscles, Tendons and Fasciae 164
Chapter 11: Examination of Diseases of Bone 171
Chapter 12: Examination of Bone and Joint Injuries 195
Chapter 13: Examination of Injuries about Individual Joints 207
Chapter 14: Examination of Pathological Joints 246
Chapter 15: Examination of Individual Joint Pathologies 259
Chapter 16: Examination of Head Injuries 299
Chapter 17: Investigation of Intracranial Space-occupying Lesions 314
Chapter 18: Examination of Spinal Injuries 327
Chapter 19: Examination of Spinal Abnormalities 335
Chapter 20: Examination of the Hand 360
Chapter 21: Examination of the Foot 374
Chapter 22: Examination of the Head and Face 383
Chapter 23: Examination of the Jaws and Temporomandibular Joint 390
Chapter 24: Examination of the Palate, Cheek, Tongue and Floor of the Mouth 400
Chapter 25: Examination of the Salivary Glands 415
Chapter 26: Examination of the Neck (Excluding the Thyroid Gland) 427
Chapter 27: Examination of the Thyroid Gland 438
Chapter 28: Examination of Injuries of the Chest 462
Chapter 29: Examination of Diseases of the Chest 469
Chapter 30: Examination of the Breast 479

Chapter 31: Examination of a Case of Dysphagia 504
Chapter 32: Examination of Abdominal Injuries 516
Chapter 33: Examination of an Acute Abdomen 527
Chapter 34: Examination of Chronic Abdominal Conditions 559
Chapter 35: Examination of an Abdominal Lump 596
Chapter 36: Examination of a Rectal Case 617
Chapter 37: Examination of a Urinary Case 635
Chapter 38: Examination of a Case of Hernia 673
Chapter 39: Examination of a Swelling in the Inguinoscrotal Region or Groin 692
Chapter 40: Examination of Male External Genitalia 701
Index *727*

Online Examination Videos

1.	Examination of pain
2.	Examination of a swelling
3.	Examination of an ulcer
4.	Examination of a sinus or a fistula
5.	Examination of edema
6.	Examination of varicose veins
7.	Examination of peripheral nerve lesions
8.	Examination of muscles and tendons
9.	Examination of the shoulder joint
10.	Examination of the knee joint
11.	Examination of the wrist joint
12.	Examination of the elbow joint
13.	Examination of the hip joint
14.	Examination of the ankle and foot
15.	Examination of the spine
16.	Examination of head injuries
17.	Examination of the face

18.	Examination of the oral cavity
19.	Examination of the jaws and temporomandibular joint
20.	Examination of the salivary glands
21.	Examination of the neck
22.	Examination of the thyroid gland
23.	Examination of lymph nodes
24.	Examination of the chest
25.	Examination of the breast
26.	Examination of the abdomen
27.	Examination of the scrotum
28.	Examination of a ventral hernia
29.	Examination of an inguinal hernia
30.	Examination of the anorectal region
31.	Examination in a case of appendicitis
32.	Examination in a case of pancreatitis
33.	Examination in a case of cholelithiasis
34.	Examination in a case of peripheral vascular disease
35.	Examination in a case of acute abdomen
36.	Examination in a case of pneumothorax
37.	Examination in a case of ascites
38.	Examination in a case of thyroglossal cyst
39.	Examination in a case of nephrolithiasis
40.	Examination in a case of chest discomfort

Online Audio Case Files

1.	Right iliac fossa pain
2.	Right iliac fossa lump
3.	Right hypochondriac pain
4.	Epigastric pain

5.	Left hypochondriac pain
6.	Obstructive jaundice
7.	A case of painless hematuria
8.	A case of painless progressive jaundice
9.	Acute urinary retention
10.	Dysphagia
11.	A neck swelling
12.	A thyroid swelling
13.	A case of cervical lymphadenopathy
14.	A midline neck swelling
15.	A case of scrotal swelling
16.	Inguinal swelling
17.	A case of breast lump
18.	A case of nipple discharge
19.	A case of upper gi bleed
20.	A case of lowe gi bleed
21.	A case of acute abdomen
22.	A case of chronic abdominal pain
23.	A case of a nonhealing ulcer
24.	A case of a nonhealing wound
25.	A case of sudden-onset unilateral leg swelling
26.	A case of sudden-onset scrotal pain
27.	A case of back pain
28.	A case of chronic hip pain
29.	A case of shoulder pain
30.	A case of knee pain in a young athlete
31.	A case of hand deformity
32.	A case of foot ulcer
33.	A case of unilateral facial swelling
34.	A case of blunt abdominal trauma
35.	A case of chest trauma

36.	A case of burn injury
37.	A case of atraumatic limb swelling
38.	A case of postoperative fever
39.	A case of sudden onset chest pain
40.	A case of acute limb ischemia

CHAPTER

3

Examination of a Lump or a Swelling

A **'Lump'** is a vague mass of body tissue.

A **'Swelling'** is a vague term which denotes any enlargement or protuberance in the body due to any cause. According to cause, a swelling may be *congenital, traumatic, inflammatory, neoplastic* or *miscellaneous*.

A **'Tumor'** or **'Neoplasm'** is a growth of new cells which proliferate independent of the need of the body. While *benign tumor* proliferates slowly with little evidence of mitosis and invasiveness to the surrounding tissues, *malignant tumor* proliferates fast with invasiveness and mitosis.



Fig. 3.1: Sacrococcygeal teratoma usually presents since birth. Rudimentary hand is seen in the tumor which develops from the totipotent cells.

HISTORY: It is recorded as described in Chapter 1 with particular reference to the following points:

1. **Duration**: 'How long is the lump present there?' That means, you should ask the patient, 'When was the lump first noticed?' In case of congenital swellings, e.g., cystic hygroma, meningocele, sacrococcygeal teratoma **(Fig. 3.1)** they are likely to be present since birth. One thing must be remembered that there is heaven and hell difference between 'The lump was first noticed two months ago' and 'The lump first appeared two months ago'. The former is the patient's finding and very often they feel its existence later than it actually appeared. A painless lump may be present for a long time without the patient's knowledge.

Lumps with shorter duration and pain are mostly inflammatory (acute), whereas those with longer duration and without pain are possibly neoplastic (benign). But the swellings with longer duration and with slight pain may be chronic inflammatory swellings whereas swellings with shorter duration may be neoplastic, mostly malignant.

2. **Mode of onset:** 'How did the swelling start'? It may have appeared just after a trauma (e.g., fractured displacement of the bone, dislocation of the joint or hematoma) or may have developed spontaneously and grown rapidly with severe pain (inflammation) or was noticed casually and the swelling was gradually increasing in size (neoplasm). Sometimes swelling may occur from pre-existing conditions, e.g., keloid may start from a scar of burn or otherwise **(Figs. 3.2A and 3.3)** or even from a pinprick in the ear **(Fig. 3.2B)**. Malignant melanoma generally develops from a benign naevus or a birthmark.

The neoplasms are mostly noticed casually and the patient says, 'I felt it during washing'. Or 'Someone else noticed it first and drew my attention.' These swellings are more dangerous and

JAYPEE BROTHERS



Figs. 3.2A and B: Keloids have developed in the scars of vaccination and ear pricks.

should invite more careful examination than those which are painful and mostly inflammatory or traumatic.

3. **Other symptoms associated with the lump:** PAIN is by far the most important symptom, which brings the patient to the doctor. Sometimes there may be other symptoms associated with the lump, such as difficulty in respiration, difficulty in swallowing, interfering with any movement, disfiguring, etc. The patient will definitely give the history of pain, but he may not give the history of other symptoms. So he must be asked relevant questions to find out if any symptom is associated with the lump.



Fig. 3.3: Keloids have developed from scars of healed boils.

4. **Pain:** Pain is an important and frequent complaint of traumatic and inflammatory swellings, whereas pain is conspicuously absent in neoplastic swellings particularly in early stage. If the patient complains of pain associated with the lump, the surgeon should know precisely its nature, site and time of onset—whether appeared before the swelling or after it.

Nature of the pain: Whether the pain is throbbing which suggests inflammation leading to suppuration; or burning; or stabbing, i.e., the pain is sudden, sharp, severe and of short duration; or distending; or aching type.

Site: Sometimes the pain is referred to some other site than the affected one. As for example, in case of affection of the hip joint, the pain may be referred to the corresponding knee joint. But most often the pain is localized to the site of the swelling.

Time of onset: It is very important to know whether the pain preceded the swelling or the swelling preceded the pain. In the case of inflammation pain always appears before the swelling, but in case of tumors (both benign and malignant) swelling appears long before the patient will complain of pain. It cannot be impressed too strongly that *most malignant tumors be it in the*

JAYPEE BROTHERS

stomach, kidney, rectum or breast, are painless to start with. Pain only appears due to involvement of the nerves, deep infiltration, ulceration, fungation or associated inflammation and often indicates inoperability. The only exception is osteosarcoma in which mild pain is usually the first symptom and precedes the appearance of swelling.

5. **Progress of the swelling:** 'Has the lump changed its size since it was first noticed'? Benign growths grow in size very slowly and sometimes may remain static for a long time. Malignant tumors grow very quickly. Sometimes the swelling suddenly increases in size after remaining stationery for a long period—this suggests malignant transformation of a benign growth. If the swelling decreases in size—this suggests inflammatory lesion. The patient should also be asked whether he has noticed any change in the surface or in consistency of the swelling.

6. **Exact site:** Mostly the site of the swelling is obvious on inspection. In case of a huge swelling, the surgeon may be confused from which structure the swelling appeared. In these instances the patient may help the surgeon by telling him the exact site from which the swelling originated.

7. **Fever:** Enquiry must be made whether the patient ran temperature alongwith the swelling or not. This suggests inflammatory swelling. Abscess anywhere in the body may be associated with rise of body temperature—typical examples being axillary abscess, gluteal abscess, ischiorectal abscess, etc. Pyogenic lymphadenitis is often associated with fever. Sometimes Hodgkin's disease, renal carcinoma, etc., are also associated with peculiar fever.

8. **Presence of other lumps:** 'Whether the patient ever had or has any other lump'? Neurofibromatosis, diaphyseal aclasis, etc., will always have multiple swellings. Similarly, Hodgkin's disease generally shows multiple lymphoglandular enlargements **(Fig. 3.4)**. Abscesses may occur one after the other.



Fig. 3.4: Multiple swellings of neurofibromatosis (Von Recklinghausen's disease).

9. **Secondary changes:** Some swellings present secondary changes such as softening, ulceration, fungation, inflammatory changes, etc. The patients should be asked for the secondary changes specifically.

10. **Impairment of function**—particularly of the limb or spine may be associated with a swelling near about. Enquire about the nature of loss of movement and intensity of it and how much of it is due to the swelling. An osteosarcoma near knee joint may cause partial or total loss of knee movement. Similarly, a cold abscess from caries spine will cause limitation of movement of the spine.

11. **Recurrence of the swelling:** If the swelling recurs after removal, this often indicates malignant change in a benign growth or the primary tumor was a malignant one. Certain other swellings are notoriously known to recur, e.g., Paget's recurrent fibroid. Cystic swelling may recur if the cyst wall is *not completely* removed.

12. **Loss of body weight:** Appearance of swelling may be associated with loss of body weight. This indicates that the swelling may be either a malignant growth or a cold abscess with generalized tuberculosis.

13. **Past history:** This may reveal presence of similar swelling or recurrence of swelling. Past history of syphilis or tuberculosis may offer clue to the present swelling.

14. **Personal history:** Habit of eating betel leaf, betel nut, slaked lime or tobacco, may be the etiological factor for growth in the mouth, tongue, cheek or lip. 'Chutta Cancer' of hard palate

JAYPEE BROTHERS

is seen in women who smoke cigars with the burning ends in their mouths. 'Khaini Cancer' occurs due to mixture of lime and tobacco kept in the gingivolabial sulcus.

15. **Family history:** This is quite important, as many diseases have familial incidence. Tuberculosis, Von Recklinghausen's disease, many malignant tumors often recur among family members.

History in cases of lump or swelling

Aspect	*Clinical significance*	*Key history taking questions*
Duration	Short-duration lumps are often **inflammatory**, while long-duration lumps are **neoplastic**.	"When did you first notice the lump?" "Has it changed in size over time?"
Mode of onset	Sudden-onset lumps suggest **trauma or inflammation**; gradual-onset lumps suggest **neoplasia**.	"Did the lump appear suddenly or gradually?" "Was there any injury before it appeared?"
Pain	Painful lumps are **often inflammatory**; painless lumps may be benign or **malignant**.	"Is the lump painful?" "If yes, what is the nature of the pain?"
Growth pattern	Rapid growth suggests **malignancy or inflammatory processes**.	"Has the lump grown in size recently?"
Secondary changes	Ulceration, fungation, and discharge indicate **possible malignancy**.	"Have you noticed any changes in the lump, such as redness, ulceration, or pus?"
Family history	Some conditions, like **neurofibromatosis or malignancies, run in families**.	"Has anyone in your family had similar lumps or cancers?"

PHYSICAL EXAMINATION

GENERAL SURVEY: When a patient presents with a swelling, the patient should be looked at as a whole. Cachexia or malnutrition may be obvious in first look. The attitude of the patient is also very important. Abnormal attitude may be either due to a swelling like osteosarcoma pressing on the nerve leading to paresis or paralysis of the distal limb or the swelling may be a displaced fracture or dislocation and the limb assumes abnormal attitude due to that. Raised temperature and pulse rate are always associated with inflammatory swelling.

Examination of lump or swelling

Exam step	*Findings and interpretation*	*Clinical example*
Inspection	Look for **size, shape, color, pulsation, movement**.	Black color → **melanoma**; pulsatile → **aneurysm**.
Palpation	Assess **temperature, tenderness, consistency, mobility, fluctuation, transillumination**.	Hard, irregular, fixed lump → **malignancy**; fluctuant lump → **abscess/cyst**.
Percussion	Identify resonance or dullness over the swelling.	Resonant swelling → **hernia**; dull swelling → **solid tumor**.
Auscultation	Listen for bruits over vascular swellings.	Bruit heard → **arteriovenous malformation or aneurysm**.

JAYPEE BROTHERS

LOCAL EXAMINATION

A. **INSPECTION:** It must be remembered that a good clinician always spends some time in observation. The students should make it a practice and should not hasten to touch the swelling as soon as he sees it.

In *inspection* the following points should be precisely noticed:

1. **Situation:** A few swellings are peculiar in their positions such as dermoid cysts are mostly seen in the midline of the body or on the line of fusion of embryonic processes, e.g., at the outer canthus of the eye—that means on the line of fusion between the frontonasal process and the maxillary process **(Fig. 3.5)** or behind the ear **(Fig. 3.6)** (post-auricular dermoid)—on the line of fusion of the mesodermal hillocks which form the pinna. Extragonal germ cell tumors like sacrococcygeal teratoma **(Fig. 3.7)** are also typically seen in midline (tail bone). It can also be anywhere on body like keloid formation due to abscess **(Fig. 3.8)**.

One must always note the extent of the swelling in vertical and horizontal directions on the case note.

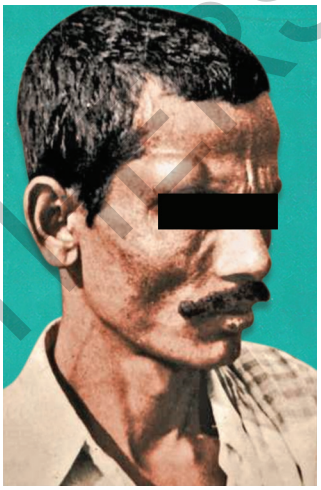

Fig. 3.5: Shows the typical site of the dermoid cyst at the outer canthus of the eye.

2. **Color:** Color of the swelling sometimes gives a definite hint to the diagnosis. Black color of benign nevus and melanoma, red or purple color of hemangioma **(Fig. 3.47)** (according to whether it is an arterial or venous hemangioma), bluish color of ranula are obvious and diagnostic.

3. **Shape:** The shape of the swelling must be noted—whether it is ovoid, pear-shaped, kidney-shaped, spherical or irregular. Sometimes the students, by mistake, utter the term 'circular' to describe the shape of the swelling. A swelling cannot be circular as we do not know about the deeper dimension of the swelling. So, it is wiser to say 'spherical' to describe this swelling.



Fig. 3.6: Postauricular dermoid.

4. **Size:** To have firsthand knowledge about the swelling, one must know the size of the swelling. On inspection, we shall miss the deeper dimension, but shall have the other two dimensions. These must be mentioned clearly in your history sheet the vertical and horizontal dimensions.

5. **Surface:** On inspection, it may be difficult to have a clear idea about the surface of the swelling. But in certain swellings, the surface may be very much obvious and diagnostic, e.g., irregular numerous branched surface of a papilloma **(Fig. 3.9)**, cauliflower surface of squamous cell carcinoma **(Fig. 3.10)**, etc.

6. **Edge:** The edge of the swelling may be clearly defined or indistinct. The swelling may be pedunculated or sessile.

JAYPEE BROTHERS

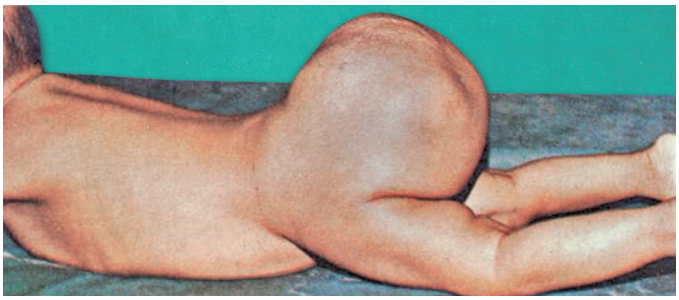

Fig. 3.7: A case of sacrococcygeal teratoma.

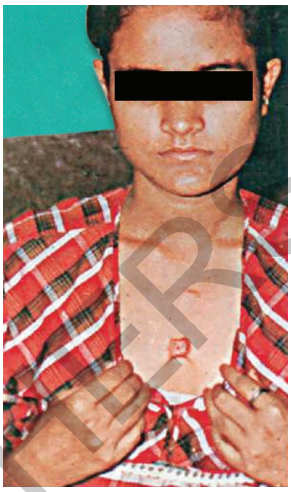

Fig. 3.8: A case of keloid in its typical position over the chest wall following a small abscess.

7. **Number:** This is important as this may give a clue to the diagnosis. Some swellings are always multiple, such as diaphyseal aclasis, neurofibromatosis, multiple glandular swellings, etc. Some swellings are more known to be solitary, e.g., lipoma, dermoid cyst, etc.

8. **Pulsation:** The swellings, arising from the arteries, are pulsatile, e.g., aneurysms and vascular growths, such as carotid body tumor. The swellings, which lie just superficial to the artery in close relation with it, will be pulsatile. This pulsation is called *transmitted pulsation*, whereas those which originate from the arterial walls give rise to *expansile pulsation*.

9. **Peristalsis:** Certain swellings are associated with visible peristalsis, e.g., congenital hypertrophic pyloric stenosis. A few swellings cause intestinal obstruction and thus show visible peristalsis.

10. **Movement with respiration:** Certain swellings arising from the upper abdominal viscera move with respiration, e.g., those arising from liver, spleen, stomach, gallbladder, hepatic and splenic flexures of the transverse colon.

11. **Impulse on coughing:** The swellings, which are in continuity with the abdominal cavity, the pleural cavity, the spinal canal or the cranial cavity, will give rise to impulse on coughing.



Fig. 3.9: Papilloma.



Fig. 3.10: Cauliflower surface of squamous cell carcinoma.

JAYPEE BROTHERS

The patient is asked to cough and the swelling will be seen giving rise to an impulse while the patient is coughing. In case of children, crying will work as coughing.

12. **Movement on deglutition:** A few swellings which are fixed to the larynx or trachea move during deglutition, e.g., thyroid swellings, thyroglossal cysts, subhyoid bursitis and pre-or paratracheal lymph node enlargement.

13. **Movement with protrusion of the tongue:** A thyroglossal cyst moves up along with protrusion of the tongue showing its intimate relation with the thyroglossal tract.

14. **Skin over the swelling:** This will be *red and edematous*, where the swelling is an inflammatory one. The skin becomes *tense, glossy with venous prominence*, where the swelling is a sarcoma with rapid growth. Presence of a *black punctum* over a cutaneous swelling indicates sebaceous cyst. *Pigmentation* of the skin is seen in moles, nevi or after repeated exposures to deep X-rays. *Presence of scar* indicates either previous operation (when the scar is a linear one with suture marks), injury (a regular scar) or previous suppuration (when the scar is puckered, broad and irregular). Sometimes the skin over a growth looks like the peel of an orange—*Peau d' orange* **(Fig. 30.9)** which is due to edematous swelling from blockage of small lymphatics draining the skin. This is most peculiarly seen in breast carcinoma. Presence of *ulcer* on the skin over the swelling is examined as discussed in the next Chapter.

15. **Any pressure effect:** It is always essential to conclude the inspection by examining the limb distal to the swelling. In many cases this will give suggestion as to what may be the diagnosis. An axillary swelling with edema of the upper limb means the swelling is probably arising from the lymph nodes. Wasting of the distal limb indicates the swelling to be a traumatic one and the wasting is due to either nonuse of the limb or due to injury to the nerves **(Fig. 3.11)**. Sometimes a swelling may be seen in the neck with venous engorgement. This should immediately give rise to suspicion of possibility of retrosternal prolongation of the swelling, giving rise to venous obstruction.



Fig. 3.11: Sarcoma of the left humerus interfering with venous return of the upper limb leading to excessive edema and wrist drop from nerve involvement.

B. PALPATION: This is the most important part of local examination which will not only corroborate the findings of inspection, but also will explore some other findings, which will give a definite clue to the diagnosis. The students must be very methodical in this examination and follow a definite order, which is given below, so that they would not miss any important examination. The students should also be very gentle in palpation not to hurt the patients and a few swellings may be malignant and may well spread into the system due to reckless handling.

1. **Temperature:** Local temperature is raised due to excessive vascularity of the swelling. It may be due to infection or due to well-vascularized tumor (e.g., sarcoma).

This examination should be done first in palpation, as manipulation of the swelling during subsequent examinations may increase the temperature without any definite reason. *Temperature of the swelling is best felt by the back of the fingers* **(Fig. 3.12)**.

2. **Tenderness:** It must be remembered that this is a sign, which is elicited by the clinician. When the patient complains of pain due to the pressure exerted by the clinician, the swelling

JAYPEE BROTHERS

is said to be 'tender'. To elicit tenderness, one should be very gentle and should not give too much pain to the patient. It is a good practice to keep an eye on the patient's facial expression while palpating the swelling to note whether this is giving rise to pain or not. Inflammatory swellings are mostly tender, whereas neoplastic swellings are not tender.



Fig. 3.12: Showing how to feel for local temperature with the back of the fingers which is more sensitive than the palmar surface.

3. **Size, shape and extent:** By palpation, one can have an idea about the deeper dimension of the swelling, which remains unknown in inspection. The vertical and horizontal dimensions of the swelling are also better clarified by palpation. It is a good practice to mention in cm the vertical and horizontal diameters and should be sketched on the history sheet clearly indicating the *position* of the swelling as well.

The clinician should always try to find out the whole extent of the swelling. If a portion of the swelling disappears behind a bone, it should be clearly mentioned and its importance cannot be too impressed to the students.

4. **Surface:** With the palmar surfaces of the fingers, the clinician should palpate the surface of the swelling to its entirety. The surface of a swelling may be smooth (cyst), lobular with smooth bumps (lipoma), nodular (a mass of matted lymph nodes) or irregular and rough (carcinoma). Sometimes the surface of the lump may be varied according to variable consistency.

5. **Edge:** Very carefully, the edge or margin of the swelling is palpated **(Fig. 3.13)**. It may be well-defined or indistinct—merging imperceptibly into the surrounding structures. Broadly speaking, neoplastic swellings and chronic inflammatory swellings have well-defined margins. Benign growths generally have smooth margins whereas malignant growths have irregular margins. Acute inflammatory swellings have ill-defined or indistinct margins.



Fig. 3.13: Shows how to feel the margin of a swelling. The margin of a cyst yields to the palpating finger and does not slip away (cf. lipoma).

The margins are palpated by the tips of the fingers. Swellings with well-defined margins tend to slip away from the finger. Benign tumor such as lipoma is often confusing with a cyst. The benign tumor has a smooth margin, so has a cyst. The most important finding, which differentiates benign tumor like lipoma from the cyst is that the margin of the former slips away from the palpating finger, but does not yield to it, whereas the margin of the latter yields to the palpating fingers and cannot slip away from the examining finger (Slip sign in **Figs. 3.14A and B**).

JAYPEE BROTHERS

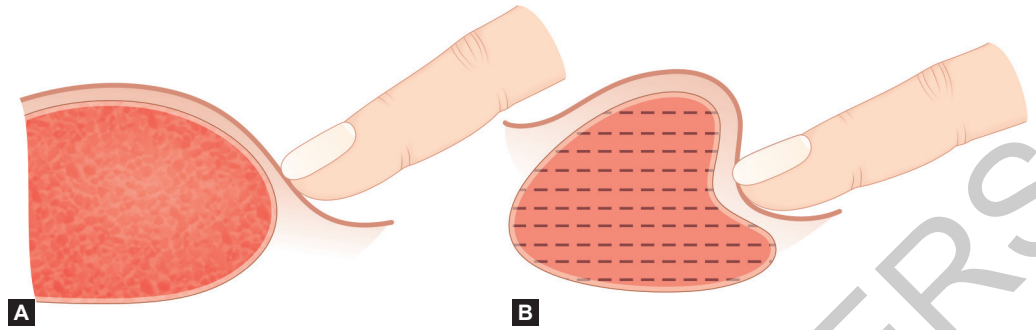

Figs. 3.14A and B: Slip sign: When the edge of a swelling is palpated, the margin of the solid swelling does not yield to the palpating finger but slips away from it; but in case of a cystic swelling the edge yields to the pressure of the palpating finger and does not slip away.

6. **Consistency:** The consistency of a lump may vary from very soft to very hard. It depends on what it is made up of **(Fig. 3.15)**. When the swelling is of *UNIFORM consistency*, it gives a clue as to which anatomical structure it is derived from. It may be *soft,* e.g., lipoma; *cystic,* e.g., cysts and chronic abscesses; *firm,* e.g., fibroma; *hard* but yielding, e.g., chondroma, *bony hard,* e.g., osteoma or *stony hard,* e.g., carcinoma. The consistencies, just described, are all solid except the cystic one, which contains liquid within it. It should be borne in mind that consistency of a solid swelling may also be soft as seen in case of a lipoma. In case of gaseous swellings, e.g., gas gangrene, surgical emphysema, a *crepitus* may be heard. Sometimes the swelling may be of *VARIABLE consistency*. This variability often indicates malignancy—either carcinoma or sarcoma.



Fig. 3.15: Implantation dermoid at the dorsum of the left hand near the web between the index and the middle fingers.

While palpating for consistency, one must look for whether the swelling is getting molded or not to pressure. It indicates that the content is a pultaceous or putty-like material. So, the swelling must be a sebaceous cyst or a dermoid cyst or even an abdominal (colonic) swelling containing fecal mass. Sometimes the swelling *pits on pressure*. This means that there is edematous tissue and most often the swelling is an inflammatory one.

7. **Fluctuation:** A swelling fluctuates, when it contains liquid or gas. This test should be carried out by one finger of each hand **(Fig. 3.16)**. Sudden pressure is applied on one pole of the swelling.



Fig. 3.16: Correct method of eliciting fluctuation. The fingers of the hand 'P' will remain passive and perceive the movement of the fluid displaced by the finger of the hand 'D'.

JAYPEE BROTHERS

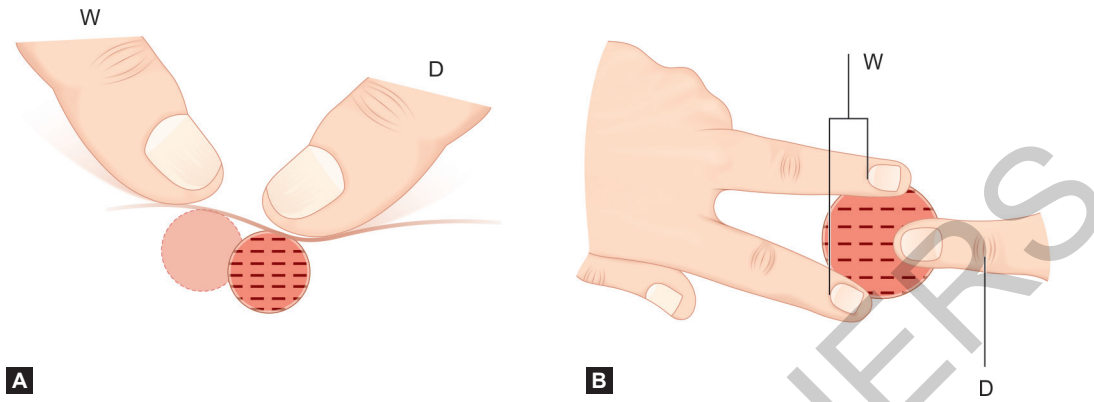

Figs. 3.17A and B: Shows the method of eliciting fluctuation in case of a small swelling. (A) shows how a small swelling may be displaced as a whole by the displacing finger (D) and it shifts towards the watching finger (W) to elicit a false sense of fluctuation even when the swelling is a solid one. (B) the correct method of eliciting fluctuation in case of a small swelling. Two fingers of the left hand (watching fingers 'W') are placed on two sides of the swelling and the index finger of the right hand (displacing finger 'D') is pressed on the swelling to displace the fluid within the swelling.

This will increase pressure within the cavity of the swelling and will be transmitted equally at right angles to all parts of its wall. If another finger of the other hand is placed on the opposite pole of the swelling, the finger will be raised passively due to increased pressure within the swelling. This means that the swelling is fluctuating **(Fig. 3.17A)**.

(i) *This test should always be performed in two planes at right angles to each other*. A fleshy muscle (e.g., quadriceps femoris) sometimes shows fluctuation at right angle to its fibers, but not along the line of its fibers. (ii) *The two fingers should be kept as far apart as the size of the swelling will allow*. (iii) In case of the *swelling, which is freely movable*, it should be held fixed with the thumb and forefinger of one hand, while the swelling is compressed on the other pole by the thumb and fingers of the other hand. The thumb and fore-finger, which have been used to fix the swelling, will feel increase of pressure within the swelling passively. Very often fluctuation is elicited in this manner in case of hydrocele. (iv) In case of *very small swelling*, which cannot accommodate two fingers, this test can be performed by simply pressing the swelling at its center. The swelling containing fluid, will be softer at the center than its periphery, while a solid swelling will be firmer at the center than its periphery. This test is known as ***Paget's test (Fig. 3.17B)***. Another method is to keep two fingers of the left hand on the swelling so as to fix it and are called 'watching fingers.' Right index finger is used ('displacing finger') to press on the swelling to displace fluid inside the swelling which is felt by the 'watching fingers.' This test should be done in two planes at right angles to one another as the conventional method. The students should not try to perform traditional fluctuation test on a small swelling, as pressure exerted by one finger, will simply displace the swelling and fluctuation test cannot be performed. (v) *For very large swelling* more than one finger of each hand are used. Two or even three fingers may be used for providing pressure (displacing fingers) and palmar aspect of four fingers of the other hand may be used to perceive the movement of displaced fluid (watching fingers). (vi) *Very soft swellings sometimes yield false positive sense in fluctuation test.* The swellings which can be included in this list are: lipoma, myxoma, soft fibroma, vascular sarcoma, etc. But if the students become careful while performing the fluctuation test, they will easily realize that these swellings yield to pressure, but fail to expand in other parts of the swelling like a true fluctuant swelling.

JAYPEE BROTHERS

8. **Fluid thrill:** In case of a swelling containing fluid, a percussion wave is seen to be conducted to its other poles when one pole of it is tapped as done in percussion. In case of a big swelling, this can be demonstrated by tapping the swelling on one side with two fingers while the percussion wave is felt on the other side of the swelling with palmar aspect of the hand. In case of a small swelling, three fingers are placed on the swelling and the middle finger is tapped with a finger of the other hand (as done in percussion), the percussion wave is felt by other two fingers on each side.



Fig. 3.18: Testing for translucency.

9. **Translucency:** This means that the swelling can transmit light through it **(Fig. 3.18)**. For this, it must contain clear fluid, e.g., water, serum, lymph, plasma or highly refractile fat. A swelling may be fluctuant as it contains fluid, but may not be translucent when it contains opaque fluid, such as blood or pultaceous material (dermoid or sebaceous cyst). To carry out this test, darkness is essential. In day time, this can be achieved by a roll of paper, which is held on one side of the swelling, while a torch light is held on the other side of the swelling. The swelling will be seen to transmit the light, if it is a translucent swelling. The torch light should not be kept on the surface of the swelling, but on one side of the swelling, while the roll of paper on the other side so that the whole swelling intervenes between the light and the roll of paper. This will eliminate the possibility of false positive results.

10. **Impulse on coughing:** In palpation, this test corroborates the finding detected in inspection. The swellings, which are likely to give rise to impulse on coughing, are: (i) those, which are in continuity with the abdominal cavity (e.g., herniae, iliopsoas and lumbar abscesses), (ii) those, which are in continuity with the pleural cavity (e.g., empyema necessitatis) and (iii) those, which are in continuity with the spinal canal or cranial cavity (spinal or cranial meningocele).

The swelling is grasped and the patient is asked to cough. An impulse is felt by the grasping hand. Due to coughing, pressure is increased within the abdominal, pleural, spinal and cranial cavities. This increase in pressure is transmitted to the swelling, where the impulse is felt. *In case of children, this examination is performed when they cry* **(Figs. 3.19A and B)**.

11. **Reducibility:** This means that the swelling reduces and ultimately disappears when it is pressed upon. This is a feature of hernia. Lymph, varix, varicocele, saphena varix, meningocele, etc., are also reducible partly or completely.

12. **Compressibility:** In contradistinction to reducibility, compressibility means the swelling can be compressed, *but would not be disappeared completely*. The compressible swellings may not have connections with the abdominal, pleural, spinal or cranial cavity. These swellings are liquid-filled and are mostly vascular malformations, e.g., arterial, capillary or venous hemangiomas **(Fig. 3.20)**. Lymphangiomas are also compressible. The most important differentiating feature between a compressible swelling and a reducible swelling is that in case of the latter, the swelling completely disappears as the contents are displaced into the cavities from where they have come out and may not come back until and unless an opposite force, such as coughing or gravity

JAYPEE BROTHERS



Figs. 3.19A and B: Note how to examine for impulse on coughing in case of an adult and a child.

is applied. But in case of the former, the contents are not actually displaced, *so the swelling immediately reappears* as soon as the pressure is taken off.

13. **Pulsatility:** A swelling may be pulsatile (i) if it arises from an artery (expansile pulsation), (ii) if it lies very close to an artery (transmitted pulsation) or (iii) if the swelling is a very vascular one (telangiectatic sarcoma). It is very easy to detect whether a swelling is pulsatile or not, yet the students miss this test and land up with great disaster (an aneurysm is sometimes incised by mistake considering it to be an abscess).

Two fingers, one from each hand, are placed on the swelling as far apart as possible **(Fig. 3.21)**. If the two fingers are raised with each throb of the artery, the swelling is a pulsatile one. When the two fingers are *not only raised, but also separated* with each beat of the artery, the pulsation is said to be an '**expansile**' one. When the two fingers are only raised, but *not separated*, the pulsation is said to be '**transmitted**'. In case of pulsatile swelling of the abdomen, the patient is placed in the knee-elbow position to determine whether it is an aneurysm of the abdominal aorta or a tumor lying in front of the abdominal aorta (transmitted pulsation). In case of the latter in this position pulsation ceases **(Figs. 3.22A and B)**.

14. **Fixity to the overlying skin:** The swellings, which originate from the skin (e.g., papilloma, epithelioma, sebaceous cyst, etc.) will be obviously fixed to the skin.



Fig. 3.20: Testing for compressibility in case of hemangioma of the upper eyelid.



Fig. 3.21: Demonstration whether the pulsation is expansile or transmitted in nature.

JAYPEE BROTHERS

for detailed information on surgery books, visit our website www.jaypeebrothers.com, for detailed information on surgery books, visit our website www.jaypeebrothers.com, for

A Manual on CLINICAL SURGERY

With New Diagnostic Algorithms, Special Investigations & Differential Diagnosis

Salient Features

- New edition features updated diagnostic algorithms for key conditions.
- Tables are included for better understanding and revision.
- Covers history-taking and physical examination in detail.
- Each chapter concludes with a structured differential diagnosis.
- Includes special investigations to enhance diagnostic accuracy.
- Highly recommended by universities and medical colleges.
- An essential resource for surgical ward entrants.
- Widely acclaimed by leading national and international surgical journals.

S Das MBBS (Cal.) FRCS (Eng. and Edin.) is Senior Consultant Surgeon, possesses a distinguished academic career. He graduated from Calcutta Medical College and Calcutta University. During his undergraduate career in Calcutta Medical College (CMC), he was good-eve Scholar. He was offered certificate of merit in Anatomy, Surgery, and Obstetrics and Gynecology. He received medals in Operative Surgery and Surgical Anatomy. He scored highest mark in Anatomy in first MBBS examination and highest mark in Surgery among CMC students in final MBBS examination.

He was honours in Anatomy, Calcutta University. After his internship and housestaffship in Calcutta Medical College, he went to UK and received extensive training in both General Surgery and Orthopedics & Traumatology. He became fellow of Royal Colleges of Surgeons of Edinburgh and London in first attempts before his 28th birthday. Thus, he is probably the youngest fellow in India. After that he held responsible posts in the departments of General Surgery and Orthopedic & Fractures in different hospitals in United Kingdom including a few posts in teaching institutions. His biodata has been included in international 'Who's Who' for his contribution in the field of teaching Surgery.

Review of the Book:

"This book, written and published by one of Calcutta's senior surgeons, bears the stamp of a master teacher. It is illustrated by a set of remarkable photographs of clinical conditions and these monochrome and color prints, along with reproductions of radiographs and line drawings, amount to nearly 600 illustrations. These will probably be the main source of interest to the Western medical student who is unlikely to see such advanced pathology in the clinics where he is taught. All in all, the author is to be congratulated for this book; it is one which will undoubtedly be highly regarded in India and a subject of interest elsewhere."

—The British Journal of Surgery

"It is directed at medical students beginning their surgical tuition and goes through the history-taking and examination of each part of the body in turn. It is copiously illustrated with photographs whose range in fascinating and stand up well in illustrating the text written in lively manner. Packed with information it should continue to sell well."

—The Annals of The Royal College of Surgeons of England

Printed in India

Available at all medical bookstores or buy online at www.ejaypee.com

JAYPEE BROTHERS
Medical Publishers (P) Ltd.
EMCA House, 23/23-B, Ansari Road,
Daryaganj, New Delhi - 110 002, INDIA
www.jaypeebrothers.com

Join us on facebook.com/JaypeeMedicalPublishers
Follow us on instagram.com/JaypeeMedicalPublishers

Shelving Recommendation
SURGERY

ISBN 978-93-6616-236-2