radiology books, visit our website www.jaypeebrothers.com, for detailed information on radiology book

Karthikeyan's Chest X-ray Made Easy®

Made Easy®

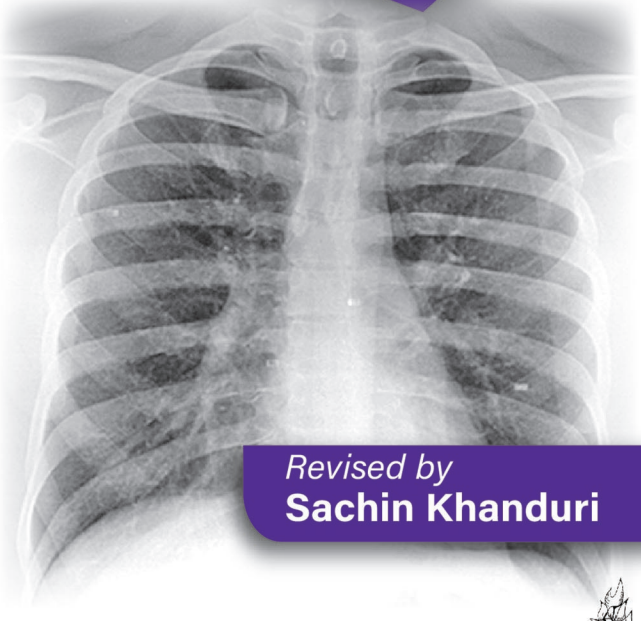

Revised by
Sachin Khanduri

3rd Edition

JAYPEE

Contents

1. Production and Properties of X-rays and Positioning 1

- Basic Physics of X-ray Production *1*
- Overview: How X-rays are Produced *1*
- Equipment for X-ray Production *2*
- Producing an X-ray Beam *5*
- Collimation and Filtration *10*
- X-ray Spectrum *10*
- Important Factors Affecting X-ray Exposure *10*
- Altering the X-ray Spectrum *12*
- Quality and Quantity of X-rays *12*
- Properties of X-rays *13*
- Chest X-ray Positioning *14*

2. Chest X-ray 20

- Objectives of Chest X-ray *20*
- Standard Views *20*
- Special Views *21*
- Techniques *22*
- Technical Considerations *24*
- Lung Zones *29*
- Fissures *32*
- Mediastinum and Heart *36*
- Hila *41*
- Diaphragm *44*
- Comparison with Previous X-rays *47*
- Silhouette Sign *52*
- Air Bronchogram *54*
- Consolidation *54*
- Collapse (Atelectasis) *55*
- Pleural Disease *63*
- Pneumothorax *69*
- Diaphragm *80*

- Pneumomediastinum *85*
- Basics of Cardiac Diagnosis from Chest X-ray *86*
- Plain Film Approach to Critical Care Patient with CXR Findings of Pulmonary Congestion/Edema *100*

3. Disease Pattern **109**

- Opacity *109*
- Generalized Pulmonary Translucency *117*
- Localized Pleural Based/Chest Wall Opacity *126*
- Pleural Effusion with Large Cardiac Silhouette *128*
- Localized Opacity with Segmental Distribution *131*
- Cystic and Cavitary Disease *133*
- Fibrocavitary Disease *142*
- Common Tubes and Lines in ICU *144*
- Tracheostomy *145*
- Central Venous Line *146*
- Endotracheal Tube *146*
- Pacemaker *147*
- Thoracostomy Tube *147*
- Nasogastric Tube *148*

4. Differential Diagnosis **153**

- Normal Chest X-ray—Landmarks *153*
- Coin Lesion on CXR *154*
- CXR: Cardiac *178*

5. Chest X-ray Correlations with HRCT **187**

- Case 1 *187*
- Case 2 *189*
- Case 3 *190*
- Case 4 *191*
- Case 5 *192*
- Case 6 *193*
- Case 7 *194*
- Case 8 *195*
- Case 9 *196*
- Case 10 *197*
- Case 11 *198*

- Case 12 *199*
- Case 13 *200*
- Case 14 *201*
- Case 15 *202*
- Case 16 *203*
- Case 17 *204*
- Case 18 *205*
- Case 19 *206*
- Case 20 *207*
- Case 21 *208*
- Case 22 *209*
- Case 23 *210*
- Case 24 *211*
- Case 25 *212*
- Case 26 *213*
- Case 27 *214*
- Case 28 *215*
- Case 29 *216*
- Case 30 *217*

6. Imaging in COVID-19 220

- Post-COVID-19 Sequelae *224*

Appendices 229

Appendix 1: Chest X-ray—Basics *229*
- Review of Normal Chest *229*
- Initial Survey *230*
- Soft Tissues and Skeletal Structure *230*
- Chest Wall *231*
- Breast Tissue *232*
- Abdomen *232*
- Neck Soft Tissues and Spine *233*
- Thoracic Spine *234*
- Ribs *234*
- Superior Mediastinum—Posteroanterior *235*
- Margin of Superior Vena Cava *235*
- Right Paratracheal Stripe *235*
- Left Subclavian Stripe *236*

- Aorta *237*
- Pulmonary Artery *237*
- Azygoesophageal Line or Paraesophageal Line *237*
- Right and Left Pulmonary Arteries *237*
- Pulmonary Arteries, Lateral View *238*
- Aorticopulmonary Window (AP Window) *238*
- Paraspinal Edges (Stripes) *238*

Appendix 2: Hila *239*
- Frontal View of the Hila *239*
- Parenchyma *239*
- Lateral View of the Lung *239*
- Pleura *240*

Index *243*

CHAPTER 6

Imaging in COVID-19

JAYPEE BROTHERS

INTRODUCTION

Coronavirus or novel coronavirus termed as SARS-CoV-2 and named by the World Health Organization (WHO) as COVID-19 emerged from Wuhan city, Hubei Province of China by the end of 2019 and has caused pandemic. SARS-CoV-2 is primarily transmitted between people through respiratory (droplet and aerosol) and contact routes. Risk of transmission is highest where people are in close proximity (within 2 meters). In healthcare settings where procedures or support treatments that generate aerosols are performed, airborne transmission can occur. Poorly ventilated indoor spaces increase the chances of transmission by air, particularly if individuals are in the same room together for an extended period.

Clinical Features

COVID-19 presents with a range of symptoms of varying severity. Asymptomatic infection also occurs often although frequency is not defined.

More common symptoms are: Fever, new and continuous cough, shortness of breath, fatigue, loss of appetite, anosmia (loss of smell), ageusia (loss of taste).

Non-specific symptoms include: Shortness of breath, fatigue, loss of appetite, myalgia, sore throat, headache, nasal congestion, diarrhea, nausea, vomiting.

Atypical symptoms, such as delirium and reduced mobility, can present in older and immunocompromised people, often in the absence of a fever.

Assessment and Diagnosis (Table 6.1)

Reverse transcription polymerase chain reaction-based SARS-CoV-2 RNA detection from respiratory samples (e.g. nasopharynx) is the standard for diagnosis.

HRCT thorax is highly sensitive but has low specificity.

TABLE 6.1: CO-RADS: Level of suspicion of COVID-19 infection.

	Suspicion	*CT findings*
CO-RADS 1	No	Normal or noninfectious abnormalities
CO-RADS 2	Low	Abnormalities consistent with infections other than COVID-19
CO-RADS 3	Indeterminate	Unclear whether COVID-19 is present
CO-RADS 4	High	Abnormalities suspicious for COVID-19
CO-RADS 5	Very high	Typical COVID-19
CO-RADS 6	PCR+	

Approaches to Imaging

A dedicated route for radiological investigations is established. If imaging is to be done with portable equipment (chest or abdominal radiography), the technologist dons PPE and performs portable radiography in the isolation room. PPE consists of a gown, gloves, eye protection, and a mask. Once radiographic scan is complete, the technologist doffs PPE gear, preferably with a trained observer monitoring removal, ensures that the patient continues to wear a mask and will

JAYPEE BROTHERS

direct the patient out of the department. Air disinfection is done before starting the scan and after its completion.

Imaging (Figs. 6.1 to 6.3)

Typical chest X-ray findings of COVID-19 are multifocal, bilateral (>unilateral) radiopacities with lower lung and peripheral predominance.

Atypical chest X-ray findings of COVID-19 are pleural effusion, pneumothorax, cavitation, solitary/diffuse lung nodule.

Chest computed tomographic imaging abnormalities for COVID-19 are multifocal, bilateral (>unilateral), basal and peripheral distribution of ground-glass opacities with or without consolidation. Ground-glass opacities may have

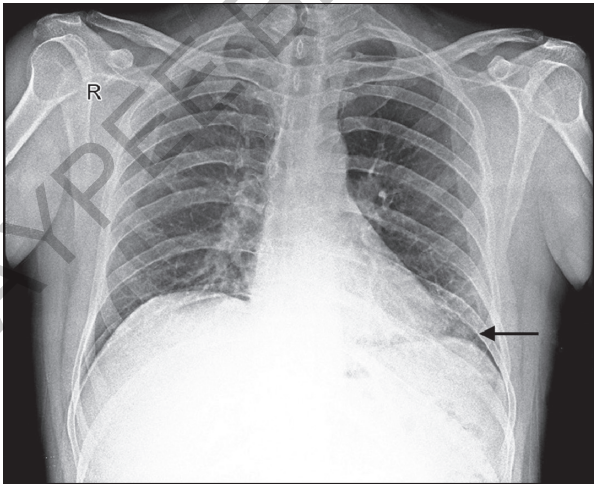

Fig. 6.1: CXR AP view shows subtle haze (arrow) in left lower lung field. Findings are likely suggestive of mild pulmonary involvement.

JAYPEE BROTHERS

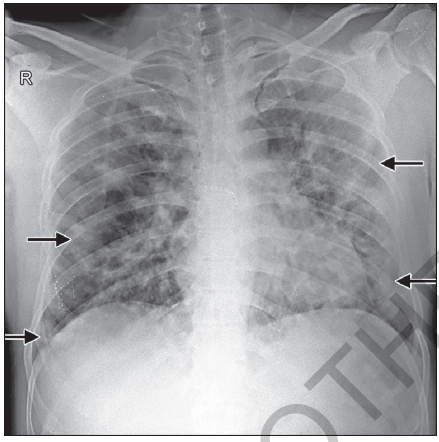

Fig. 6.2: CXR AP view shows multiple ground glass opacities (arrows) noted in bilateral lung fields with peripheral predominance. Findings are likely suggestive of moderate to severe pulmonary involvement.

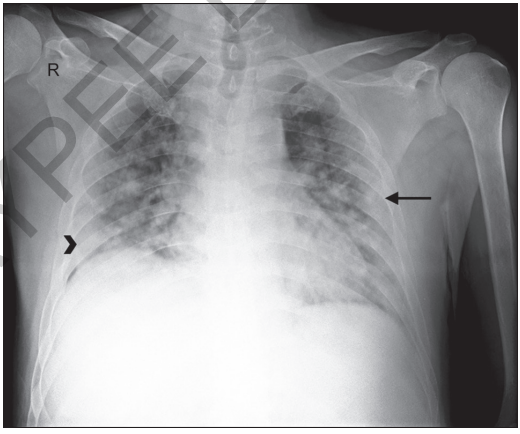

Fig. 6.3: CXR AP view shows multiple ground glass opacities (arrow) in bilateral lung fields with area of consolidation in right lower lung field (arrowhead). Findings are likely suggestive of severe pulmonary involvement.

JAYPEE BROTHERS

ill-defined margins, air bronchograms, smooth or irregular interlobular thickening or intralobular lines giving crazy paving pattern, traction bronchiectasis, vascular dilatation, subpleural bands and architectural distortion.

CT involvement score is given by scoring the percentage of involvement of each of five (maximum score 25) lobes as follows **(Tables 6.2 and 6.3)**:

TABLE 6.2: Score with respect to lung involvement.

Score	*Lung involvement*
0	Absent
1	<5%
2	5–25%
3	25–50%
4	50–75%
5	>75%

TABLE 6.3: Interpretation of the pulmonary involvement.

Score	*Pulmonary involvement*
<8	Mild
9–15	Moderate
>15	Severe

POST-COVID-19 SEQUELAE

1. Fibrosis
2. Mucormycosis

CASE: Characteristic chest radiograph finding in a 44-year-old male presenting with cough, fever and breathlessness for 4 days **(Fig. 6.4)**.

Chest radiographic finding includes bilateral patchy and confluent, band-like ground-glass and consolidative opacities showing peripheral distribution involving middle to lower lung zones.

JAYPEE BROTHERS

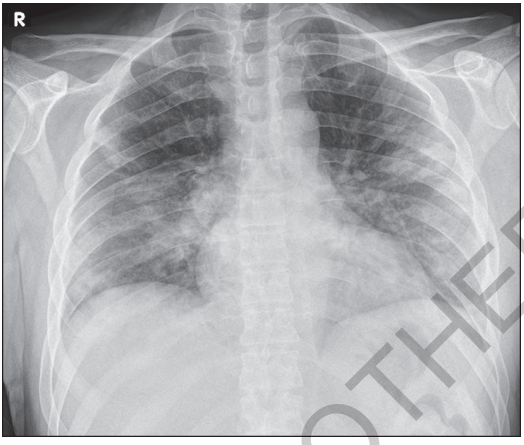

Fig. 6.4: Chest X-ray PA view in a COVID-19 patient.

MULTIPLE CHOICE QUESTIONS

1. **What is the severity score of a mild case of COVID-19 infection on HRCT thorax?**
   a. 0 b. 1–8
   c. 9–15 d. 16–25

2. **What is the severity score of a moderate case of COVID-19 infection on HRCT thorax?**
   a. 0 b. 1–8
   c. 9–15 d. 16–25

3. **What is the severity score of a severe case of COVID-19 infection on HRCT thorax?**
   a. >25 b. 1–8
   c. 9–15 d. 16–25

4. **What is the typical pattern on chest X-ray of a COVID-19 pneumonia patient?**
   a. Bilateral and peripheral
   b. Unilateral

JAYPEE BROTHERS

c. Bilateral and asymmetrical
d. Any of the above

5. Which of the following CT features is frequently observed in COVID-19 pneumonia?
a. Multifocal ground glass opacities (GGO) with peripheral distribution
b. Consolidations
c. Pericardial effusion
d. Pleural effusions

6. According to US Multicenter which of the following is not a typical pattern on chest X-ray of a COVID-19 infected patient?
a. Multifocal bilateral and peripheral predominance
b. Bilateral and lower zones predominant
c. Bilateral and upper zones predominant
d. None

7. Which of the following is a post-COVID-19 sequelae?
a. Fibrotic changes in lungs
b. Mucormycosis
c. Traction bronchiectasis changes in lung
d. All of the above

8. Who are at risk for death with COVID-19 pneumonia?
a. Cardiac diseases
b. Age >60 years
c. Diabetes, TB, HIV and chronic diseases
d. All of the above

9. What precautions will you take while managing a confirmed COVID-19 case?
a. Use PPE (medical mask, eye protection, gloves and gown) when entering room and remove PPE when leaving
b. Avoid contaminating environmental surfaces (e.g., door handles and light switches)
c. Ensure adequate room ventilation
d. All of the above

JAYPEE BROTHERS

10. What are the elements of standard precautions while handling COVID-19 case?

a. Hand hygiene and respiratory hygiene
b. PPE (personal protective equipment) according to the risk
c. Safe injection practices, sharps management and injury prevention, safe handling, cleaning and disinfection of patient care equipment
d. All of the above

ANSWERS

1. b	2. c	3. d	4. a
5. a	6. d	7. d	8. d
9. d.	10. d		

JAYPEE BROTHERS

for detailed information on radiology books, visit our website www.jaypeebrothers.com, for detailed info

Karthikeyan's
Chest X-ray Made Easy®

Chest X-ray Made Easy (Third Edition) is designed to serve as a concise yet comprehensive guide for medical students, postgraduate residents, and clinicians who require a quick and reliable reference for chest X-ray interpretation. This updated edition covers the essential knowledge and practical skills needed to navigate chest X-ray findings and diagnose a wide range of pulmonary conditions.

Key features that make this book a valuable resource:

- *Concise and Easy to Understand:* The text is structured to present complex information in a simplified and straightforward manner. Whether you are just beginning your radiology training or are a busy clinician, this book delivers high-yield content that is both easy to grasp and quick to reference.
- *Coverage of Major Chest Disease Patterns:* The book provides a comprehensive overview of the major disease patterns visible on chest X-rays, covering everything from infections to malignancies. It offers clear explanations and diagnostic tips to help readers differentiate between various pathologies.
- *High-Quality Images:* Equipped with a large number of high-resolution chest X-ray images, this book enhances the learning experience by offering visual clarity. These images are crucial for understanding subtle radiographic findings and recognizing different disease processes.
- *Differential Diagnosis for X-ray Chest Pathology:* For each chest pathology presented, the book includes a detailed discussion of possible differential diagnoses. This helps clinicians and trainees think critically when interpreting X-rays and improves diagnostic accuracy.
- *Multiple-Choice Questions (MCQs) for Interactive Learning:* To make learning more engaging, every chapter concludes with a set of MCQs that reinforce key concepts. These questions challenge the reader to apply what they have learned, helping to solidify knowledge in a practical, hands-on manner.
- *X-ray Case Discussions with CT Correlation:* A unique feature of this edition is the dedicated chapter discussing chest X-ray cases in tandem with CT correlations. By comparing findings from both imaging modalities, readers gain a deeper understanding of the pathology and how different imaging techniques complement each other in clinical practice.
- *New Content on COVID-19:* The addition of a chapter on Basic Chest X-ray Findings in COVID-19 addresses the urgent need to recognize and interpret the radiological manifestations of this viral disease, making it a timely and relevant addition to the text.

Overall, *Chest X-ray Made Easy* offers a concise, practical, and interactive approach to mastering chest X-ray interpretation. This book is an essential tool for medical professionals at all levels who want to develop a solid foundation in chest imaging.

Sachin Khanduri MD is a distinguished Professor and Head, Department of Radiodiagnosis at Era's Lucknow Medical College, Lucknow, Uttar Pradesh, India. With over 24 years of teaching experience, he has mentored MD postgraduates, MBBS students, and technicians. A postgraduate from Gajra Raja Medical College (GRMC), Gwalior, Madhya Pradesh, he has guided more than 100 theses and has published over 120 research articles, including 45 in PubMed-indexed journals. He is a lifetime member of the Indian Radiological and Imaging Association (IRIA) and serves as a member of the Ethics Committee of UPMCI. He is also a respected reviewer for prestigious journals with publishers such as Elsevier, Cureus (USA), AIUM (USA), and Wiley (USA). In addition to his academic contributions, he has authored two editions of the Textbook of Radiology. He has delivered lectures and presented papers at over 30 national and state-level conferences (like RSNA, ECR, IRIA, etc.)

Printed in India

Available at all medical bookstores or buy online at www.ejaypee.com

JAYPEE BROTHERS
Medical Publishers (P) Ltd.
EMCA House, 23/23-B, Ansari Road,
Daryaganj, New Delhi - 110 002, INDIA
www.jaypeebrothers.com

Join us on facebook.com/JaypeeMedicalPublishers
Follow us on instagram.com/JaypeeMedicalPublishers

Shelving Recommendation
RADIOLOGY

ISBN 978-93-6616-273-7