isit our website www.ejaypee.com, for detailed information on Orthopedics books, visit our website www.ejaypee.com, for detailed information on Orthopedics books



Solved Papers
Orthopedics
for PG Students

A must for MS and DNB

Editor
Abdul Ghani

JAYPEE

Contents

1. Basic Applied Orthopedic Sciences **1**
Samarth Mittal, Nusrat Jabeen, Saroj Sharma

2. Investigations and Diagnosis in Orthopedics **20**
Vineet Aggarwal, Barkat Anwar Shah, Varun Gupta

3. Infections in Orthopedics **40**
Jujhar Singh, Vedant Bajaj, Abhimanu Kaith

3.1 Musculoskeletal Tuberculosis *82*
Qazi Manaan Masood, Rohit Rambani

4. Musculoskeletal Tumors **132**
Ashish Gulia, Aman Koul, Vipin Sharma

5. Metabolic Bone Diseases and Endocrine Disorders **173**
Bhat Jameel Mohd Jabbar, Sparsh Dagoria, Rifaaqat Ghani

6. Inflammatory Disorders, Crystal Arthropathy, and Degenerative Disorders **193**
Anoop Kumar, Sachin Kudyar, Ankita Khajuria

7. Regional Orthopedic Pathologies **208**

7.1. Shoulder Disorders ***208***
Priti Ranjan Sinha, Khalid Muzzafar, Omeshwar Singh

7.2. Elbow Disorders ***244***
Vipin Sharma, Azhar Ud Din, Nitin Choudhary

7.3. Wrist and Hand Disorders ***273***
Rajesh Kapila, Meganath Pawar, Suraydev Aman Singh

7.4. Spine ***306***
Younis Kamal, Farid Hussain, Agnivesh Tikoo

7.5. Hip ***365***
Ashish Jaiman, Abhishek Mahajan

7.6. Knee Joint ***388***
Sumit Banerjee, Mohamad Waseem Dar, Manish Singh

7.7. Foot and Ankle ***417***
Biswajit Sahu, Zubair Ahmad Lone, Saransh Bahl

8. Nerve Injury **442**
Arun K Sharma, Subqat Farooq, Akash Narangyal

9. Neuromuscular and Neurological Disorders **479**
Tarkik Thami, Sachin Kudyar, Shubham Pandoh

10. Pediatric Orthopedics **505**

10.1. Congenital and Developmental Disorders ***505***
Rashid Anjum, Kamal Ji Pandit, Kanav Mahajan

10.2. Genetic Disorders in Orthopedics ***541***
Sajal Maingi, Aditya Chaubey, Iram Mir

11. Trauma and Fracture Management **558**

11.1. General Principles of Trauma ***558***
Mozam Hamid Wani, Vineet Aggarwal, Asim Maqbool

11.2. Upper Limb Trauma ***587***
Sakib Arfee, Abhai Singh Bhadwal, Shyam Singh

11.3. Lower Limb Trauma ***661***
Vipin Sharma, Sajad Ahmad Wani

11.4. Spinal Trauma ***699***
Tahir Afzal, Pankaj Vir Singh

11.5. Pediatric Trauma ***731***
Ashish Nehru, Kushagra Pathak, Irfan Ahmed Poswal

11.6. Trauma in Special Populations ***763***
Sumeet Singh Charak, Sajad Ahmad Wani

12. Sports Injuries and Soft Tissue Disorders **781**
Sanjeev Gupta, Mozam Hamid Wani, Deepali Gupta

13. Amputation and Disarticulation **801**
Shamim Ahmad Bhat, Simranpreet Singh, Tejpal Singh

14. Tractions, Orthosis, Prosthesis, and Braces/Splints **813**
MD Maaz, Pankaj Spolia, Abhishek Bral

15. Gait Analysis and Disorders **836**
Sajal Maingi, Varun Gupta, Naresh V

16. Common Surgical Approaches and Procedures **848**
Mohammed Farooq Butt, Amit Kumar

16.1 Arthroplasty, Arthroscopy, Arthrodesis, and Minimally Invasive Surgery ***869***
Vijay Kumar, Heemanshu Bhat, Pardeep Singh

17. Complications in Orthopedics **893**
Dev Kant Meena, Niaz Ahmed, Bhaarath KS, Shubam Surmal

18. Rehabilitation in Trauma and Orthopedics **909**
Amandeep Singh Bakshi, Tejpal Singh, Deepali Gupta

19. Biomaterials and Bone Healing in Orthopedics **933**
Irfan Andleeb Gul, Aakash Deep, Kanav Mahajan

20. Recent Advances in Orthopedics **945**
Ashish Jaiman, Harsh Chauhan, Sukhil Raina

21. Basic Research and Publication Methodology **959**
Asif Nazir Baba, Waseem Ahmad Sheikh, Nikhil Gupta

22. General and Non-specific Orthopedic **977**
Shubhranshu Choudhary, Abdul Maajid Bhat, Shubham Pandoh

Index **1005**

CHAPTER 3

Infections in Orthopedics

Jujhar Singh, Vedant Bajaj, Abhimanu Kaith

JAYPEE BROTHERS

Acute and Chronic Osteomyelitis

Q1. Describe acute osteomyelitis with its clinical features, diagnosis, and management.

(Asked in AIIMS Delhi 2022, PGI Chandigarh 2022)

Definition

Acute osteomyelitis is an **acute infection of bone and bone marrow**, usually caused by **hematogenous spread** of bacteria, commonly seen in children.

Common Pathogens

- *Staphylococcus aureus* (most common).
- *Streptococcus* species
- Kingella kingae (young children).
- *Salmonella* (especially in sickle cell disease).

Clinical Features

Symptoms	***Signs***
Sudden onset bone pain	Localized swelling, redness, warmth
Fever, malaise	Tenderness over bone
Refusal to bear weight or move the limb (in children)	Pseudoparalysis in infants

Diagnosis

- *Blood investigations*:
  - ↑ESR, ↑ CRP, leukocytosis.
  - Positive blood cultures (~50% cases).
- *Radiology*:
  - Early X-ray may be normal; changes (periosteal reaction, lytic areas) appear after 10–14 days.
  - MRI is investigation of choice—shows early marrow edema.
- *Bone aspiration/biopsy*: For culture and sensitivity.

Management

Stage	***Treatment***
Early (no abscess)	IV antibiotics (empirical, later adjusted based on culture)
Abscess formation	Surgical drainage + IV antibiotics
Supportive	Analgesics, splinting for comfort and IV fluid

Important Tip
Empirical antibiotics: Cover ***Staphylococcus aureus*** + **Gram-negatives** initially (e.g., Cefazolin + Gentamicin).

Duration of Antibiotics
4–6 weeks (initial IV followed by oral course).

Q2. Write answers on chronic osteomyelitis, including sequestrum, involucrum, management principles.

(Asked in MUHS Maharashtra 2022, RGUHS Karnataka 2022)

Definition
Chronic osteomyelitis is a **persistent bone infection** lasting beyond 6 weeks, characterized by **necrotic bone (sequestrum)**, **new bone formation (involucrum)**, and often sinus formation.

Key Pathological Terms

Term	*Definition*
Sequestrum	Dead piece of bone separated from living bone, harboring infection
Involucrum	New bone formed around sequestrum by periosteal reaction
Cloaca	Opening in involucrum through which pus drains
Sinus tract	External opening of infection on the skin

Clinical Features
- Chronic discharging sinus.
- Intermittent swelling, redness.
- Persistent dull bone pain.
- History of prior acute osteomyelitis, open fractures, or surgeries.

Cause of chronicity of infection
1. Presence of unabsorbed and retained sequestra serving as a constant source of infection
2. Unobliterated cavities (dead spaces alive with bacteria)
3. 'Microbiological shift' (change of aerobic cocci to gram negative or anaerobes)
4. Multiple types of bacteria "mixed infection" and anti microbial resistance.

Diagnosis
- *Blood tests*: ESR and CRP elevated chronically.
- *X-ray*: Sequestrum appears as dense devascularized bone; involucrum seen as thickened periosteal new bone.
- *MRI*: Defines soft tissue extent.
- *Sinogram*: If sinus tract present.
- *Bone biopsy*: For definitive microbiological diagnosis.

Management Principles

Step	*Details*
Surgical debridement	Removal of sequestrum and infected tissue (sequestrectomy)
Antibiotic therapy	Culture-directed antibiotics (6–8 weeks)
Stabilization	External fixation if necessary (if bone instability)
Dead space management	Bone grafting, antibiotic-loaded beads, muscle flaps
Reconstruction	If major bone loss—e.g., Ilizarov techniques, vascularized bone grafts

Important Surgical Options
- Sequestrectomy (removal of dead bone).
- Saucerization (widening of cavity for drainage).
- Antibiotic cement beads/spacers.
- Ilizarov external fixator for infected non-union.

JAYPEE BROTHERS

Mnemonic for Management: "DASSR"
- *D*ebridement
- *A*ntibiotics
- *S*tabilization
- *S*pace management
- *R*econstruction

Q3. What are the prerequisites of surgery (sequestrectomy and saucerization) for chronic osteomyelitis?

Absolute
- *Radiological*: Well-formed involucrum surrounding the discretely visible sequestrum adequately at least 2/3rd diameter of bone (3 intact walls on two views ensure 3/4th intact walls!).
- *Clinically*: Symptomatic patient with pus discharge or chronic unrelieved disabling pain due to osteomyelitis per se and type A/B host.
- *Ethical*: Salvageable limb and patient willing for prolonged and multiple treatments.

Relative: Stopping antibiotic treatment at least one week prior to surgery (otherwise cultures will be misleading).

Quick Tips for Theory and Viva
- In acute osteomyelitis, **early diagnosis + early IV antibiotics** are key.
- In chronic osteomyelitis, **surgery is essential**—antibiotics alone are not enough!
- Always clearly define **sequestrum and involucrum**—highly scoring if drawn neatly in exam diagrams.

Short answer and Viva Question

Q4. Define musculoskeletal infections. Classify with examples.

Definition
Musculoskeletal infections are **infective conditions affecting bones, joints, muscles, tendons, or surrounding soft tissue** caused by microbial organisms.

Classification
1. *Based on site*:
   - Osteomyelitis
   - Septic arthritis
   - Pyomyositis
   - Tenosynovitis
2. *Based on etiology:*
   - Pyogenic (*Staphylococcus aureus*)
   - Tubercular (*Mycobacterium tuberculosis*)
   - Fungal (e.g., *Candida*, *Aspergillus*)
3. *Based on duration*:
   - Acute (<2 weeks)
   - Subacute (2–6 weeks)
   - Chronic (>6 weeks)
4. *Based on mode of acquisition*:
   - Hematogenous
   - Direct inoculation
   - Contiguous spread

JAYPEE BROTHERS

Q5. Classification of osteomyelitis based on duration, pathology, and etiology.

Duration
- *Acute*: <2 weeks
- *Subacute*: 2–6 weeks
- *Chronic*: >6 weeks

Pathology
- Suppurative (e.g., *Staphylococcus aureus*)
- Non-suppurative (e.g., TB)
- Granulomatous (fungal, TB)

Etiology
- Pyogenic
- Tubercular
- Fungal
- Viral
- Parasitic

Classification of osteomyelitis

A. *Based on the mode of infection*:
   - Hematogenous—via bloodstream (common in children)
   - Contiguous spread—from nearby soft tissue or wound
   - Direct inoculation—trauma, surgery, implants

B. *Based on duration*:
   - Acute (<2 weeks)
   - Subacute (2–6 weeks)
   - Chronic (>6 weeks)

Q6. Cierny–Mader classification (most widely used).

Based on two factors:
1. Anatomic type (bone involvement)
2. Host physiology (patient's immune status)

Anatomic Types

Type	*Description*
I	Medullary osteomyelitis (confined to the medullary canal)
II	Superficial osteomyelitis (involves cortical bone)
III	Localized osteomyelitis (full-thickness bone involvement but stable)
IV	Diffuse osteomyelitis (circumferential bone involvement, instability)

Host Types

Host	*Description*
A	Normal healthy host
B	Systemically or locally compromised host
C	Treatment worse than disease (very poor host; treatment may be avoided)

Example

Patient could be classified as **type III, Host B** osteomyelitis.

JAYPEE BROTHERS

Q7. What is the common site of osteomyelitis and why?

(Grant Government Medical College 2014)

Metaphysis

- Hair pin bend arrangement of arterioles
- Relatively less phagocytosis (↓ reticuloendothelial system activity)
- Sluggish flow
- Tortuous blood vessels and skimming of bacteria
- Dead (apoptotic) and degenerating cartilage cells from physeal plate serving as medium for bacterial growth
- Microfractures and local hematoma common in young active children

Q8. What are the causes for diaphyseal osteomyelitis?

- Long standing osteomyelitis in children (grows out to diaphysis)
- Post-traumatic osteomyelitis
- Implant related osteomyelitis
- Tubercular osteomyelitis
- Drug abusers (heroin addicts—pseudomonas)
- Immunocompromised (fungal)
- Salmonella osteomyelitis (often bilateral and may be symmetrical).

Q9. Routes of infection spread in musculoskeletal infections.

(Christian Medical College Vellore 2014)

1. *Hematogenous spread*:
   - Common in children
   - From distant foci like skin or respiratory tract
   - E.g., Acute hematogenous osteomyelitis
2. *Direct inoculation*:
   - Post-trauma or surgery
   - Implant-associated infections
   - E.g., Infection after ORIF
3. *Contiguous spread*:
   - From adjacent soft tissue infections or ulcers
   - Common in diabetics
   - E.g., Diabetic foot osteomyelitis

Q10. Pathophysiology of musculoskeletal infections.

1. **Bacterial colonization** of tissue
2. Activation of **innate immune response**
3. Influx of **neutrophils → pus formation**
4. **Inflammatory cytokines** → tissue destruction
5. **Increased intramedullary pressure** → ischemia → necrosis
6. Formation of **sequestrum**, especially in osteomyelitis
7. *Chronic phase*: Biofilm formation, sinus tract, immune evasion

Q11. Biofilms in orthopedic infections (short note).

Definition

Biofilm is a **structured bacterial colony** embedded in self-produced matrix (EPS) that adheres to surfaces like implants.

JAYPEE BROTHERS

Characteristics
- Highly **antibiotic-resistant**
- Shields bacteria from **immune clearance**
- Requires **implant removal** for eradication of infection
- Delays healing and causes **chronicity**

Examples
- Prosthetic joint infections
- Infected intramedullary nails or plates

Q12. Role of imaging in diagnosing musculoskeletal infections.

(Jammu University 2013)

- *X-ray*: Detects **periosteal elevation, osteolysis, sequestrum** (late findings)
- *Ultrasound:* Useful in detecting **effusions**, **abscesses**
- *MRI:*
  - **Most sensitive** modality
  - Shows **bone marrow edema**, **soft tissue involvement**, sinus tracts
- *CT*:
  - Useful for **bone detail**, sequestrum visualization
  - Assists in **guided biopsy**
- *Nuclear imaging*: Bone scan (Tc-99m), PET-CT for **early detection** and **infection mapping**

Q13. Role of laboratory investigations.

Blood Tests
- *CBC*: Leukocytosis
- *ESR, CRP*: Elevated in acute/chronic infection
- *Procalcitonin*: Specific for bacterial infections

Microbiological Tests
- Blood cultures (hematogenous cases)
- Aspirate culture and sensitivity
- Gram stain, AFB stain, fungal cultures

Histopathology
Helps in **tubercular or fungal** cases.

Q14. Role of CRP and procalcitonin.

(Kashmir University)

C-reactive Protein (CRP)
- Acute-phase protein
- **Rapid rise and fall** with infection/inflammation
- Useful for **monitoring treatment response**

Procalcitonin
- More **specific to bacterial infections**
- Rises **faster than CRP** (within 6–12 hours)
- Not elevated in **viral or autoimmune inflammation**

Q15. Pathophysiology of acute osteomyelitis.

1. Bacterial entry via bloodstream or direct trauma
2. Neutrophil influx → pus formation in medullary cavity

JAYPEE BROTHERS

3. Increased intramedullary pressure → vascular compromise
4. Ischemia and bone necrosis → formation of sequestrum
5. Reactive new bone formation (involucrum) may follow if not treated early

In Children
- Infection starts in the **metaphysis** due to the rich, slow-flowing blood supply and end-artery configuration

Q16. Etiological factors for acute osteomyelitis.

(Rajendra Institute of Medical Sciences 2016)

1. *Microbial*:
   - *Staphylococcus aureus* (most common)
   - MRSA, *Streptococcus* species, Gram-negative bacilli
   - *Salmonella* in sickle cell disease
   - *Mycobacterium tuberculosis* in endemic areas
2. *Host factors*:
   - Immunocompromised states
   - Diabetes, malnutrition
   - Recent trauma or surgery
   - IV drug use

Q17. Clinical features, diagnosis, and management.

Clinical Features
- Acute onset of **localized bone pain**, **fever**, swelling
- Limitation of movement
- *In children*: **Refusal to bear weight**, pseudoparalysis

Diagnosis
- *Blood tests*: ↑ ESR, CRP, WBC count
- **Blood culture**
- *Imaging*: MRI is most sensitive
- **Bone biopsy/aspiration** for culture and sensitivity

Management
- Empirical IV antibiotics → culture-based antibiotics
- **Surgical drainage** if abscess or no improvement
- Limb support (splint/cast)
- Monitor CRP for response

Q18. Radiological features of acute osteomyelitis.

(AIIMS Bhubaneswar 2014)

X-ray (after 10–14 days)
- Soft tissue swelling
- Periosteal reaction
- Lucent areas indicating lysis

MRI (most sensitive)
- Early **bone marrow edema**
- Soft tissue involvement
- Abscess or sequestrum detection

JAYPEE BROTHERS

Ultrasound
Useful in detecting **subperiosteal abscess** in children

Bone Scan/PET-CT
Sensitive but less specific; useful in multifocal cases

Q19. Differential diagnosis of acute osteomyelitis.

Condition	*Differentiating feature*
Septic arthritis	Joint tenderness, effusion, rapid destruction
Ewing sarcoma	Systemic symptoms, diaphyseal involvement
Osteoid osteoma	Night pain, nidus on CT
Cellulitis	No bony tenderness, normal imaging early
Bone infarction	Sickle cell disease, lacks inflammatory markers

Q20. Acute hematogenous osteomyelitis (short note).

(Baba Farid University of Health Sciences 2013)

- Common in **children**
- Affects **metaphysis** of long bones (femur, tibia)
- *Route*: **Hematogenous spread** from minor infections (URTI, skin)
- Presents with **fever, localized pain, pseudoparalysis**
- Treated with **early antibiotics**, sometimes surgical drainage
- *Staphylococcus aureus* is the most common pathogen

Q21. Complications of acute osteomyelitis.

Early
- Septicemia
- Septic arthritis (especially in infants)
- Subperiosteal abscess

Late
- Chronic osteomyelitis
- Growth disturbances (physeal damage)
- Pathological fractures
- Joint stiffness
- Deformity or limb length discrepancy

Q22. Principles of antibiotic therapy in acute osteomyelitis.

Initial Therapy
- **Empirical IV antibiotics** targeting *Staphylococcus aureus, Streptococcus*, and Gram-negatives
- Choice guided by **local sensitivity patterns** and patient factors

Duration
- Typically **4–6 weeks**
- **IV → oral switch** after clinical response (fever, CRP decline)

Monitoring
- Serial **CRP/ESR**, clinical improvement
- Modify based on **culture and sensitivity**

JAYPEE BROTHERS

Q23. Role of surgical management in acute osteomyelitis.

(All India Institute of Medical Sciences New Delhi 2013)

Indications
- Failure of medical treatment
- Presence of **abscess**, sequestrum, or sinus
- Diagnostic uncertainty
- **Compartment syndrome**

Procedures
- **Aspiration or incision & drainage**
- **Cortical window** for decompression
- Removal of **necrotic bone or sequestrum** if present
- Drain placement and lavage

Q24. Define chronic osteomyelitis. Classify it.

Definition
Chronic osteomyelitis is a **long-standing infection of bone**, typically lasting >6 weeks, characterized by **necrotic bone (sequestrum), sinus tracts**, and persistent inflammation.

Classification
A. *Based on source:*
- Hematogenous
- Post-traumatic/post-surgical
- Contiguous spread

B. *Based on duration:*
- Chronic >6 weeks
- *Subacute*: 2–6 weeks

C. *Cierny-Mader classification:*
- *Anatomic type (1–4)*:
  - 1: Medullary
  - 2: Superficial
  - 3: Localized
  - 4: Diffuse
- *Host type (A/B/C)*:
  - A: Healthy
  - B: Compromised
  - C: Surgery not justified due to risks

Q25. Pathophysiology of chronic osteomyelitis.

(Atal Medical and Research University 2012)

1. Persistence of infection after acute phase
2. Sequestrum formation (dead bone harboring bacteria)
3. Involucrum formation (reactive new bone)
4. Development of sinus tracts
5. Biofilm formation on necrotic bone or implants
6. Chronic inflammatory response → bone sclerosis, poor vascularity

Q26. Risk factors for chronic osteomyelitis.

- **Previous acute osteomyelitis**
- Open fractures

JAYPEE BROTHERS

- **Surgical implants** (internal fixation, prosthesis)
- Diabetes mellitus
- Immunosuppression
- Peripheral vascular disease
- **Inadequate treatment** of acute infection

Q27. Clinical presentation of chronic osteomyelitis.

(Grant Medical College Mumbai 2009)

- **Chronic discharging sinus**
- Pain and swelling
- Non-healing wound or ulcer
- Sinus fixed to bone or healed puckered scar
- Exposed necrotic bone
- Soft tissue contractures
- **Local tenderness**, limb deformity
- *Occasionally*: Fever, malaise
- History of trauma or surgery

Q28. Radiological features of chronic osteomyelitis.

- *X-ray*:
  - *Sequestrum*: **Dense, necrotic bone fragment**
  - *Involucrum*: **New bone formation around sequestrum**
  - *Cloaca*: **Opening in involucrum** for sinus drainage
  - Sclerosis, periosteal thickening
- *MRI*: Best for soft tissue, sinus tracts, marrow involvement
- *CT scan*: Defines **bone architecture, cloacae, and sequestrum**
- *Bone scan/PET-CT*: Detects **active infection**, especially in multifocal disease

Q29. Treatment options for chronic osteomyelitis.

(Dr DY Patil Vidyapeeth Pune 2011)

Non-surgical
- **Long-term antibiotics** based on culture (4–6 weeks or more)
- Best for **low-grade or inoperable cases**

Surgical
- Debridement of necrotic tissue and sequestrum
- Sinus tract excision
- Dead space management (antibiotic beads, muscle flap)
- Stabilization if bone defect present
- Reconstruction using bone grafts or vascularized flaps

Q30. Surgical principles in chronic osteomyelitis management.

1. Adequate debridement of infected and necrotic tissue
2. Sequestrectomy and curettage
3. Identify and excise sinus tracts
4. *Dead space management*:
   - Antibiotic beads (PMMA)

JAYPEE BROTHERS

- Vascularized muscle flap
- Bone transport (ilizarov)

5. *Reconstruction*:
   - Bone grafting
   - Free flaps for coverage
   - External or internal stabilization

Q31. Role of antibiotics in chronic osteomyelitis.

Principles
- **Culture-guided therapy** is essential
- Antibiotics alone are **insufficient** without debridement
- Usually given for **4–6 weeks** post-surgery

Delivery Methods
- **IV or oral** antibiotics
- *Local delivery*: PMMA antibiotic beads, biodegradable carriers
- Monitor using **CRP/ESR** for treatment response

Q32. Short notes on sequestrum and involucrum.

(Goa Medical College Bambolim Goa 2012)

Sequestrum
- A fragment of **necrotic bone** separated from viable bone
- Radiodense, may harbor bacteria
- Requires **surgical removal**

Types of Sequestrum
- *Sequestrum*: Dead bone fragment in osteomyelitis.
  - *Ring sequestrum*: Circumferential, in amputation stump infections.
  - *Button sequestrum*: Small round (seen in eosinophilic granuloma).
  - *Floating sequestrum*: In sinus or cavity.
  - *Coralliform sequestrum*: Perthes
  - *Coke like sequestrum*: Tuberculosis
  - *Feathery sequestrum*: Syphilis
  - *Sand like sequestrum*: Tubercular osteomyelitis in metaphysis
  - *Black*: Amputation stump and long exposure of necrotic bone to air while also attached to parent bone (formation of ferrous sulphide), fungal infection
  - *Green*: Pseudomonal osteomyelitis
- *Involucrum*: Reactive new bone around sequestrum.
- *Cloaca*: Opening in involucrum for pus drainage.

Involucrum
- **Reactive new bone** formed around the sequestrum
- May have **cloacae (openings)** for sinus drainage
- Seen on **X-ray/CT** in chronic osteomyelitis
- Only if three walls of involucrum are seen fully on two perpendicular views should sequestrectomy be undertaken otherwise a pathological fracture will result and it will get converted into infected nonunion.

Q33. Complications of chronic osteomyelitis.

- **Sinus tract formation**
- **Pathological fractures**
- Skeletal **deformity or limb shortening**

JAYPEE BROTHERS

- Septic arthritis
- Septicemia
- Soft tissue contractures
- Squamous cell carcinoma in long-standing sinus
- **Amyloidosis** (rare)
- Chronic pain, disability
- Recurrence despite treatment

Q34. Define subacute osteomyelitis. Classify it.

(AIIMS Jodhpur Rajasthan 2011)

Definition

Subacute osteomyelitis is a **low-grade bone infection** that presents between **2 to 6 weeks** after onset. It is **less severe than acute osteomyelitis**, often with **milder symptoms** and a **localized abscess or lytic lesion**.

Clinical Features

- Mild to moderate localized pain
- Low-grade or absent fever
- Minimal systemic symptoms
- Often missed in early stages

Classification

1. *Based on radiological appearance*:
   - *Brodie's abscess*: Localized, intracortical or metaphyseal abscess
   - Metaphyseal lucency with sclerotic rim
   - Subperiosteal lesion
   - Diaphyseal type
   - Epiphyseal type (rare)
2. *Based on anatomic location*:
   - Metaphysis (most common)
   - Diaphysis
   - Epiphysis
   - Vertebrae (rare)

Q35. What is brodie's abscess? Discuss its diagnosis and management.

Definition

Brodie's abscess is a **localized form of subacute osteomyelitis**, characterized by a **walled-off abscess cavity** within the **metaphysis** of long bones.

Common Sites

- Tibia (proximal metaphysis)
- Femur, radius, or calcaneus

Diagnosis

Clinical:

- Chronic dull pain
- No or low-grade fever
- Often in children/adolescents

Radiological

- *X-ray*: Oval/round lytic lesion with **sclerotic margin** in metaphysis
- *MRI*: Confirms abscess, rim enhancement
- *CT*: Defines bony margins and sinus if present

JAYPEE BROTHERS

Labs
- Mildly raised or normal ESR/CRP
- Blood cultures usually negative

Management
1. *Conservative (early or small lesions)*: Empirical antibiotics → guided by biopsy/culture
2. *Surgical (larger or symptomatic abscess)*:
   - **Curettage** and **debridement**
   - **Antibiotic bead placement** if needed
   - Post-operative IV antibiotics for 2–4 weeks

Q36. Differential diagnosis of subacute osteomyelitis (short note).

Condition	*Differentiating features*
Bone tumor (e.g., Ewing's sarcoma)	Systemic symptoms, periosteal reaction, diaphyseal location
Osteoid osteoma	No fever, night pain relieved by NSAIDs, nidus seen on CT
Chronic osteomyelitis	Sinus tract, sequestrum, involucrum on imaging
Langerhans cell histiocytosis	Solitary lytic lesion, eosinophilic granuloma
Tubercular osteomyelitis	Constitutional symptoms, caseation, positive GeneXpert

Osteomyelitis after Open Fracture
- *Definition*: Infection of bone secondary to contamination during open fracture.
- *Etiology*: Polymicrobial; common organisms include *Staphylococcus aureus*, *Pseudomonas*.
- *Management*:
  - Early aggressive debridement.
  - IV antibiotics.
  - Fracture stabilization (external or internal fixation).
  - Sometimes staged reconstruction (Masquelet technique).

Q37. Pyogenic vertebral osteomyelitis.

(Jammu University 2010)

Definition
Bacterial infection of vertebral bodies and intervertebral discs.

Etiology
Hematogenous spread; *Staphylococcus aureus* is most common.

Clinical Features
Back pain, fever, localized tenderness.

Diagnosis
MRI (most sensitive), blood cultures.

Treatment
- IV antibiotics (6–12 weeks).
- Immobilization.
- Surgical decompression if neurological deficit or abscess.

Q38. Chronic recurrent multifocal osteomyelitis (CRMO).

Definition
Non-infectious autoinflammatory bone disorder.

JAYPEE BROTHERS

Features
Recurrent episodes of bone pain, swelling, multiple sites.

Diagnosis
Clinical + MRI; cultures negative.

Treatment
- NSAIDs first-line.
- Immunomodulators (e.g., TNF inhibitors) in refractory cases.

Q39. *Salmonella* osteomyelitis.

Common in
Sickle cell disease

Site
Diaphysis of long bones

Diagnosis
Blood cultures, MRI, bone biopsy

Treatment
IV ceftriaxone or fluoroquinolones for 4–6 weeks ± surgical debridement

Summary Flowcharts: Acute Osteomyelitis, Chronic Osteomyelitis

Acute Osteomyelitis: Early Diagnosis and Treatment
Acute osteomyelitis is a bacterial infection of bone, most commonly hematogenous in children and postoperative in adults. Timely diagnosis and antibiotics can prevent chronicity and surgical intervention.

FLOWCHART: Management of acute osteomyelitis.

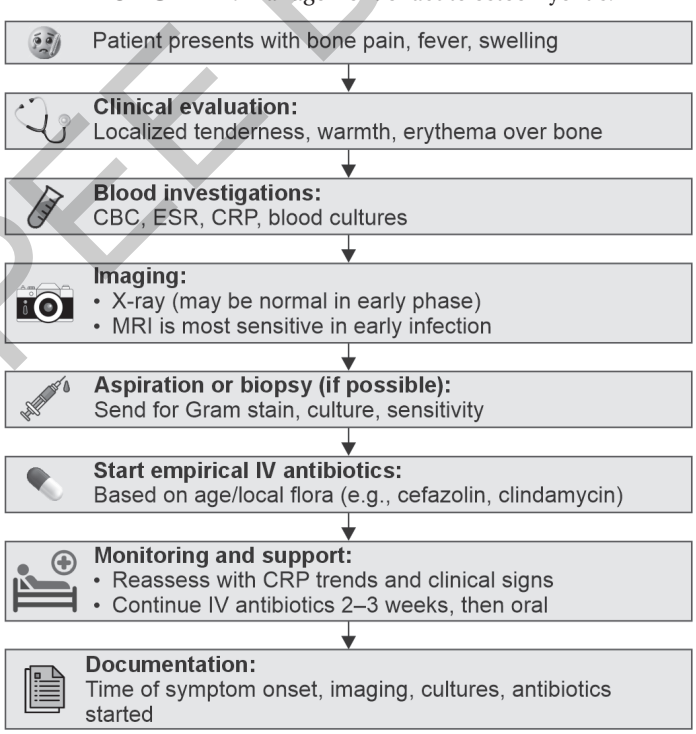

Key Points
- MRI is the best early diagnostic tool for osteomyelitis.
- Blood cultures and local aspiration help guide antibiotic therapy.

JAYPEE BROTHERS

- Empirical antibiotics must cover *Staphylococcus aureus* and Streptococci.
- Monitor CRP for response and consider surgical drainage if no improvement.

Chronic Osteomyelitis

Progression from untreated or inadequately treated acute osteomyelitis → Chronic osteomyelitis
↓
Persistent infection + Dead bone (sequestrum)
↓
Sinus tract formation
↓

Clinical features:

- Chronic pain
- Sinus tract discharge
- Bone deformity

Key Mnemonics:

- *Acute*: "Red hot bone" (pain, fever, swelling)
- *Chronic*: "Dead bone and drainage" (sequestrum and sinus)

Septic Arthritis

Q40. Describe septic arthritis with reference to clinical diagnosis, joint aspiration findings, and management.

(Asked in PGI Chandigarh 2022, AIIMS Delhi 2021)

Definition

Septic arthritis is an **acute infection of a joint** caused by the invasion of bacteria, leading to **rapid joint destruction** if not treated urgently.

Common Pathogens

Age Group	*Organisms commonly Involved*
Neonates	*Staphylococcus aureus,* Group B *Streptococcus*, Gram-negative bacilli
Children	*Staphylococcus aureus*, *Streptococcus pyogenes, Kingella kingae*
Adults	*Staphylococcus aureus* (most common), *Neisseria gonorrhoeae* (sexually active adults)

Clinical Diagnosis

- Acute onset **severe joint pain**, **swelling**, **redness**, and **warmth**.
- Marked **restriction of joint movement**.
- **Fever**, chills, malaise
- Joint held in position of maximal **comfort** (e.g., hip flexion, abduction, external rotation).
- Inability to bear weight (especially in children with hip involvement).
- **Pseudoparalysis** in infants.

Joint Aspiration Findings

Parameter	*Typical finding in septic arthritis*
Appearance	Turbid, purulent fluid
WBC count	Very high (>50,000–100,000 cells/mm^3; mostly neutrophils)
Gram stain	Positive in 50–75%
Culture	Definitive diagnosis
Glucose	Low compared to serum
Protein	Elevated

JAYPEE BROTHERS

Management

Stage	*Action*
Immediate	Joint aspiration for diagnosis
Antibiotic therapy	Empirical IV antibiotics (targeting *Staphylococcus aureus*) immediately after cultures
Surgical intervention	Arthrotomy + lavage (especially for hip, shoulder) if severe infection or delayed diagnosis
Joint immobilization	Initial phase (short term)
Physiotherapy	To prevent stiffness post infection control

Empirical Antibiotic Choices

- IV cefazolin or clindamycin (children).
- Vancomycin if MRSA suspected.
- Later tailored based on culture results.

Important Point

Early treatment within **first 24–48 hours** prevents irreversible cartilage destruction!

Q41. Write a note on kocher's criteria for differentiating septic arthritis from transient synovitis.

(Asked in MUHS Maharashtra 2022)

Background

- Designed primarily for differentiating **septic arthritis** from **transient synovitis** in **pediatric hips**.
- Helpful in **early clinical decision-making** before full laboratory results are available.

Kocher's Four Criteria

Criterion	*Significance*
Non-weight bearing on affected side	Strong predictor
ESR > 40 mm/h	Indicates inflammation
Fever > 38.5°C (101.3°F)	Suggests systemic infection
WBC count > 12,000 cells/mm^3	Leukocytosis

Interpretation of Kocher's Criteria

Number of criteria positive	*Probability of septic arthritis*
1/4	~3%
2/4	~40%
3/4	~93%
4/4	~99%

Mnemonic for Kocher's Criteria: "FEWS"

- *F*ever,
- *E*SR raised,
- *W*BC raised,
- *S*tanding not possible (non-weight bearing).

Clinical Tip

- If ≥2 criteria positive → Strong suspicion → Proceed with aspiration and IV antibiotics.
- Always correlate with joint aspiration and imaging findings (e.g., ultrasound showing hip effusion).

Quick Tips for Theory and Viva

- Always emphasize that **joint aspiration** is both diagnostic and therapeutic.
- State clearly that **hip septic arthritis is a true orthopedic emergency**—needs immediate surgical drainage if suspected.

Short answer and viva questions about septic arthritis

JAYPEE BROTHERS

Q42. Define septic arthritis. Classify it.

Definition

Septic arthritis is an **acute infection of the joint** caused by pyogenic organisms, leading to **joint inflammation, cartilage destruction**, and potential loss of function.

Classification

A. *Based on source*:
- Hematogenous spread (most common)
- Direct inoculation (e.g. post-surgery, trauma)
- Contiguous spread (e.g. from adjacent osteomyelitis)

B. *Based on organism*:
- *Pyogenic*: *Staphylococcus aureus, Streptococcus,* Gram-negatives
- Tubercular
- Fungal or viral

C. *Based on duration*:
- *Acute*: <2 weeks
- *Subacute*: 2–6 weeks
- *Chronic*: >6 weeks (e.g., TB)

Q43. Etiopathogenesis of septic arthritis.

Etiology

- **Bacteria** (e.g., *Staphylococcus aureus*, MRSA, *Streptococcus, Haemophilus influenzae*)
- *Mycobacterium tuberculosis* in chronic cases

Pathogenesis

1. *Bacterial entry into joint via*:
   - Hematogenous spread
   - Direct inoculation
   - Spread from adjacent tissues
2. Bacteria **adhere to synovium**
3. **Inflammatory response** → cytokine release (IL-1, TNF-α)
4. *Rapid cartilage degradation via*:
   - Enzymes from neutrophils
   - Pressure effects from effusion
5. Can lead to **joint destruction** in 48–72 hours if untreated

Q44. Clinical features and diagnosis.

(Madras Medical College Chennai Tamil Nadu 2010)

Clinical Features

- Sudden onset of **painful, swollen joint**
- **Fever, malaise**
- Joint is **warm, tender, erythematous**
- **Decreased ROM** (guarding due to pain)
- *Most commonly affected*: **Knee, hip, shoulder**

Diagnosis

- **CBC, ESR, CRP**—raised
- **Blood cultures** (positive in 50%)
- *Joint aspiration*: Purulent fluid, ↑ WBC count (>50,000/mm³), ↓ glucose
- Gram stain and culture
- *Imaging*: X-ray, MRI, Ultrasound

JAYPEE BROTHERS

Q45. Radiological findings of septic arthritis.

- *X-ray (late signs)*:
  - Joint space **narrowing**
  - Periarticular **osteopenia**
  - **Bone erosions** at articular margins
- *Ultrasound*:
  - Detects **joint effusion**
  - Useful in **hip joint** (especially in children)
- *MRI*: Early detection of **synovial inflammation**, **effusion**, **bone edema**
- *CT*: Helps in **guiding aspiration**, defining joint anatomy

Q46. Differential diagnosis of septic arthritis.

Condition	*Differentiating features*
Reactive arthritis	Recent infection, sterile joint fluid
Gout/Pseudogout	Crystals in fluid, often monoarticular
Rheumatoid arthritis	Symmetrical, multiple joints, RF/anti-CCP positive
Hemarthrosis (bleeding disorders)	No infection signs, history of trauma or hemophilia
Tubercular arthritis	Chronic, insidious onset, caseous tissue

Q47. Synovial fluid analysis in septic arthritis (short note).

[Christian Medical College (CMC) Vellore Tamil Nadu 2008]

Gross Appearance
Turbid or purulent, yellowish

Microscopy
- WBC count > 50,000/mm^3 (mostly neutrophils)
- *Gram stain*: It may show organisms
- *Crystals*: To rule out gout/pseudogout

Culture
- Essential for identifying causative organism
- **Positive in 60–80%**

Glucose
Low (<50 mg/dL) compared to serum glucose

Q48. Principles of management of septic arthritis.

1. *Antibiotics*:
   - Empirical IV antibiotics → switched to targeted therapy after culture
   - Duration: **3–4 weeks IV**, followed by **oral antibiotics**
2. *Joint drainage*: Aspiration, arthroscopic lavage, or open arthrotomy, depending on the joint and response
3. *Immobilization*: Initial rest, followed by **early mobilization** to prevent stiffness
4. *Supportive care*: Analgesia, nutritional support

Q49. Role of arthroscopic lavage.

Indications
- Large joint involvement (e.g., **knee**, shoulder)
- Persistent or **recurrent effusion**
- To **avoid open arthrotomy**

JAYPEE BROTHERS

or detailed information on Orthopedics books, visit our website www.ejaypee.com, for detailed information on Orthopedics books, visit our website www.ejaypee.com,

Solved Papers
Orthopedics
for PG Students

This book is a comprehensive collection of the **most commonly asked theory/viva questions with their answers in the MS and DNB Orthopedics postgraduate examinations**. It will also be extremely helpful for MCH/FNB entrance examination and for any interview or MCQ, as well. Designed with clarity and precision, it presents answers in a crisp, concise, and structured format, making it a highly practical resource for exam preparation. While it is not intended to replace standard textbooks, it serves as a quick-reference companion, covering every major section and topic in orthopedics and trauma.

Whether you are revising before the exams or strengthening your conceptual understanding, this book offers an easy-to-read, exam-oriented approach to help postgraduate students succeed with confidence.



Abdul Ghani MBBS MS(Orthopedics, AIIMS New Delhi) MRCS(Edinburgh) is a distinguished Orthopedic Surgeon and Academician with 30 years of clinical and teaching experience. Currently, he is serving as a Professor and Head of Unit in a Tertiary Care Teaching Hospital.

Dr Ghani is a passionate teacher and dedicated mentor, internal and external examiner, national faculty, and conference speaker, with numerous national and international presentations and publications to his credit.

Dr Ghani has already authored six books:

1. Secrets of Scoring More Marks and Passing Any Exam Easily
2. How to Unleash Your Potential and Achieve Success
3. Competency Based Orthopaedics Manual for MBBS Students
4. Musculoskeletal Pain Management
5. Handbook of Fractures: The Current Concepts
6. Clinical Orthopaedics: Common Problems & Solutions

His vast experience, structured thinking, and student-focused approach make him a highly impactful author for this book.

Shelving Recommendation
ORTHOPEDICS

ISBN 978-93-6616-292-8
9 789366 162928

Buy from ejaypee

JAYPEE BROTHERS