our website www.jaypeebrothers.com, for detailed information on orthopedics books, visit our website www.jaypeebrothers.com

3rd Edition

Complimentary Online
Video (Duration 28 Min. 36 Sec.)

KNEE REPLACEMENT



SKS Marya
Rajiv Thukral

Foreword
Sam Oussedik

JAYPEE

Contents

Chapter 1	History and Basics	1
Chapter 2	Relevant Surgical Anatomy	5
Chapter 3	Biomechanics and Alignment	11
Chapter 4	Getting Started: Implant Systems and Designs	17
Chapter 5	Surgical Approaches	19
Chapter 6	Indications and Contraindications	27
Chapter 7	Preoperative Preparation	31
Chapter 8	Preoperative Clinical Assessment	35
Chapter 9	Radiology and Templating	41
Chapter 10	Scoring	44
Chapter 11	Surgical Technique: Standard Knee	49
Chapter 12	Surgical Technique: Varus Deformity	74
Chapter 13	Surgical Technique: Valgus Deformity	78
Chapter 14	Surgical Technique: Flexion Deformity	85
Chapter 15	Surgical Technique: Bone Defect Management	90
Chapter 16	Surgical Technique: Recurvatum Deformity	95
Chapter 17	Surgical Technique: Fused Knee Takedown	100
Chapter 18	Postoperative Period	105
Chapter 19	Accelerated Physiotherapy Protocol	110
Chapter 20	Follow-up	112
Chapter 21	Thromboprophylaxis Update	114
Chapter 22	Complications	121

Chapter 23 Issues 127

Chapter 24 Current Day Economics of Total Knee Arthroplasty 133

Chapter 25 Compartmental Knee Arthroplasty 138

Chapter 26 Technology Today 154

Index 171

Chapter 11

Surgical Technique: Standard Knee

JAYPEE BROTHERS

PATIENT POSITIONING, INCISION, AND APPROACH

Position: Supine with rolled towel/sandbag under ipsilateral hip **(Fig. 1)**.

Skin incision: Midline or slightly lateral paramidline (lower mid-thigh to tibial tubercle).

Deep incision and approach: Medial parapatellar approach **(Fig. 2)**.

Placement of Hohman's retractors: Lateral tibial, medial tibial, and posterior tibial **(Fig. 3)**.

Structures cut and removed: Menisci (medial and lateral), ligaments [anterior cruciate ligament (ACL) posterior cruciate ligament



FIG. 1: Supine position with side support with tourniquet.



FIG. 2: Superficial and deep dissection using medial parapatellar approach.



FIG. 3: Placement of bony spikes: Medial, lateral, and posterior to tibial surface.



FIG. 4: Excision of menisci and fat pad.



FIG. 5: Posteromedial release (depicted by complete exposure of posteromedial tibial corner).

(PCL)], *where PCL sacrificing designs are used* retropatellar fat pad obstructing surgical view, osteophytes, and inflamed synovial tissue **(Fig. 4)**.

Soft tissue release: Posteromedial tibial soft tissue release is essential **(Fig. 5)** *[except in severe valgus knees with lax medial*

JAYPEE BROTHERS

collateral ligaments (MCLs)], and lateral patellofemoral ligament is incised.

PATELLAR EVERSION/SUBLUXATION

Proximal Tibial Bone Cut

- Extramedullary jig is placed aligning the medial one-third of the tibial tuberosity to the center of the ankle joint (this line also passes along the tibial shin and through the axis of the second metatarsal, with the ankle in neutral position) **(Fig. 6)**.
- Alignment rod confirms mechanical axis placement of this jig.
- Stylus is affixed to jig with two pins (at 0 mark), aimed to cut either 9 mm (from normal unaffected lateral tibial plateau), or 2 mm (from the affected medial tibial plateau); using slotted or nonslotted guides **(Fig. 7)** (*these steps are no longer needed in computer- and robotic-assisted surgery)*.
- The first tibial cut is taken with saw and completed with an osteotome; surface is smoothened **(Figs. 8 and 9)**.
- Tibial sizing is now achieved with tibial sizing tray **(Fig. 10)**.

Distal Femoral Bone Cut

- The femoral canal is entered with drill (5 mm anterior to insertion of anterior cruciate ligament on the femoral intercondylar area)



FIG. 6: Placement of extramedullary tibial alignment jig.

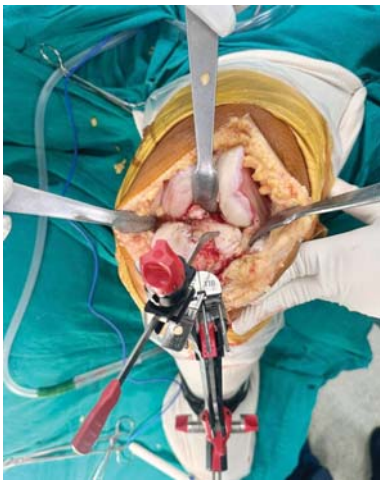

FIG. 7: Confirmation of level of tibial cut with stylus.

JAYPEE BROTHERS



FIG. 8: Proximal tibial cut taken with saw and eased out with osteotome.



FIG. 9: Proximal tibial cut achieved.

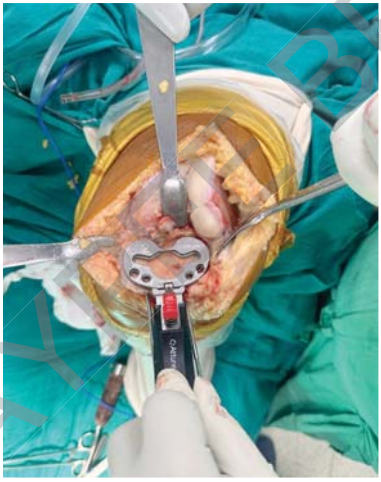

FIG. 10: Tibial sizing with trial tibial tray.



FIG. 11: Femoral entry with drill.

JAYPEE BROTHERS

and widened. The canal is washed to remove bony debris and loose marrow fat **(Fig. 11)**.

- Intramedullary jig is inserted into femoral canal with 5–7° valgus angulation, and 9-mm distal cut (slotted) is selected and fixed to the anterior surface of the distal femur with pins **(Figs. 12 and 13)**.



FIG. 12: Intramedullary femoral jig aligning distal femoral cutting block at 5–7° valgus angle.



FIG. 13: Distal femur cutting block set to desired level of cut and fixed with pins.



FIG. 14: Intramedullary jig removed and distal femoral cut taken.



FIG. 15: Distal femoral cut achieved.

- Alignment can be confirmed with an alignment rod inserted onto the jig.
- Intramedullary rod with distal valgus jig is extracted.
- Distal femoral cut is completed **(Figs. 14 and 15)**.

JAYPEE BROTHERS

Femoral Component Sizing (and Rotation)

- The femoral sizing jig is placed on flat cut distal surface of femur and the femoral component sized, at the same time the insertion points of the AP cutting jig are marked. Medial pin slot is anterior and lateral pin slot is posterior, and thus, the line joining these points is angulated 3° to the posterior intercondylar line (horizontal), providing the 3° external rotation needed for ensuring a rectangular flexion gap.
- Femoral component rotation is *confirmed* by using either the transepicondylar axis (ensuring that the posterior femoral cut is parallel to a line drawn between the medial and lateral femoral epicondyles), anteroposterior axis (posterior femoral cut perpendicular to this axis), posterior femoral condyles (3° of external rotation off a line between them), or the cut surface of the proximal tibia (posterior femoral cut parallel to the proximal tibial cut in flexion, after the soft tissues have been balanced in extension) **(Fig. 16)**.

Anteroposterior Femoral Bone Cuts

- Appropriate size AP cutting jig is then placed into the pin marks created on the distal surface and fixed **(Fig. 17)**. Alternatively, Ranawat's jig may be used (to make the anterior-posterior cuts) **(Fig. 18)**.



FIG. 16: Femoral sizing jig imparting 3° external rotation to femoral cuts.

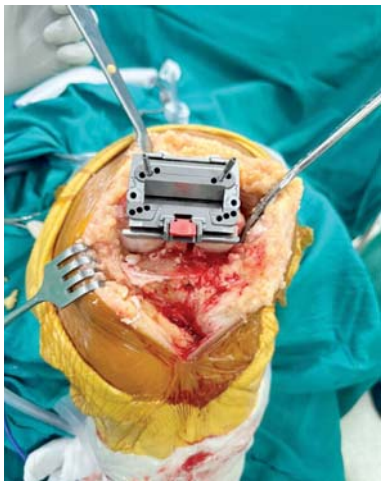

FIG. 17: Placement of AP cutting jig into the pin sites marked by the sizing jig.

JAYPEE BROTHERS

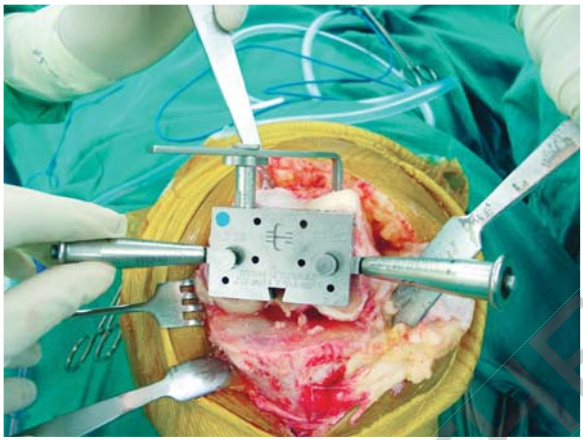

FIG. 18: Ranawat's jig (alternative method) used for sizing.



FIG. 19: Anterior femoral cut achieved.

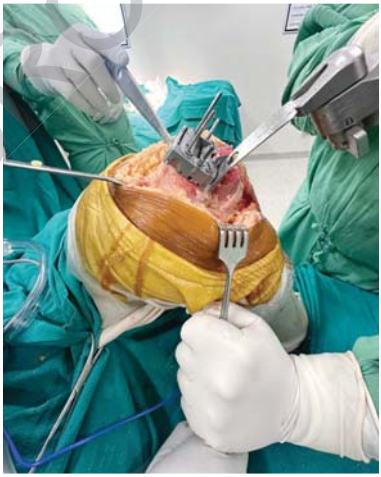

FIG. 20: Posterior femoral cuts achieved.

- Amount to be resected is checked with the angel's wing guide to prevent notching.
- Anterior and posterior cuts are taken (cutting through slots to prevent skiving of the saw blade) **(Figs. 19 and 20)**.

JAYPEE BROTHERS

Gap Assessment and Alignment

- An appropriate size spacer block is placed between resected bone ends in flexion and extension at this point in time and checked to be equal and balanced **(Figs. 21 and 22)**. Necessary corrections are made to correct nonrectangularity and flexion/extension gap mismatch, if needed.
- Joint stability in varus-valgus is checked, appropriate releases as required may be carried out **(Fig. 23)**.
- In extension, the femoral and tibial alignment rods are inserted into the spacer block and appropriate mechanical axis achieved (and marked on the tibia).

Final Femoral Cuts (Notch and Chamfer)

- Combined chamfer and notch cutting jig are then placed onto distal femur (ensuring that it sits flat on anterior and distal surfaces and matches the posterior femoral cut) **(Fig. 24)**.
- Notch is prepared using a reciprocating saw blade and completed with osteotomes and hammer **(Figs. 25 and 26)**.
- Chamfers are then cut **(Fig. 27)**.
- Jig is removed and any irregularities shaved and freshened with rasp, if necessary.

JAYPEE BROTHERS



FIG. 21: Checking flexion-extension gap in extension.



FIG. 22: Checking flexion-extension gap in flexion.

- Remove any medial or lateral osteophytes that tent the collateral ligaments. Remove posterior condylar osteophytes with a curved osteotome (because they can tent the posterior capsule and narrow the extension gap or impinge during knee flexion) **(Fig. 28)**.



FIG. 23: Checking for varus-valgus stability in extension with spacer block.



FIG. 24: Placement of combined chamfer-notch cutting jig on distal femur.



FIG. 25: Cutting of notch with reciprocating saw (in cruciate-substituting designs).



FIG. 26: Excision of femoral intercondylar notch.

JAYPEE BROTHERS



FIG. 27: Chamfer cuts achieved.



FIG. 28: Removal of posterior osteophytes with osteotome and hammer.

Blocking the Femoral Canal

Bone derived from chamfer cuts is cut, shaped, and punched over the femoral entry point to block the canal (and reduce bone bleed from the marrow) **(Fig. 29)**.

Trial Implantation and Reduction

- Trial femoral implant (prepared size and side) is placed onto the distal cut surface of the femur and gently impacted maintaining flexion at knee joint **(Fig. 30)**.
- If there is incongruent fit, check for oblique/skived cuts, hard sclerotic bone on any surface, impinging posterior osteophytes, or intercondylar notch irregularities, and correct the same.
- Trial tibial tray is similarly placed on tibial surface. Trial tibial insert corresponding on size to tibial tray and 8 mm thickness (with aforementioned described cuts for femur and tibia, 8 mm insert is required to recreate stability) is placed over the tibial tray and the joint reduced **(Fig. 31)**.

Alignment, Stability, and Mobility Check

- Once the knee is straightened, alignment rods are placed in the jig holding the tibial tray and overall mechanical alignment checked in AP and profile views **(Figs. 32 and 33)**.

JAYPEE BROTHERS



FIG. 29: Removal of jigs and placement of bony block for femoral canal.



FIG. 30: View of joint with trial femoral implant.



FIG. 31: Placement of trial tibial tray with trial insert.



FIG. 32: Alignment rod placed through trial tibial tray—anterior view.

- Varus-valgus balance, anteroposterior stability, and range of movement (ROM) are then checked **(Figs. 34 and 35)**. This can be fine-tuned with medial or lateral soft tissue releases, if needed.

JAYPEE BROTHERS



FIG. 33: Alignment rod placed through trial tibial tray—profile view.



FIG. 34: Checking stability with trial implants—varus stress.



FIG. 35: Checking stability with trial implants—valgus stress.

- The knee stability and alignment are then checked in flexion, and appropriate tibial rotational alignment is attained and marked with cautery (the tibial tray holding jig may need to be externally rotated to achieve this) **(Fig. 36)**.
- After bone deficiencies have been treated, ligamentous balancing is satisfactory, and the extensor mechanism is tracking properly, the trial components are removed.

JAYPEE BROTHERS

for detailed information on orthopedics books, visit our website www.jaypeebrothers.com, for detailed information on orthopedics

KNEE REPLACEMENT

Salient Features

- Highlights all aspects of surgical replacement of knee including basic principles, indications, techniques, management of complications, postoperative care, etc.
- Includes colored photographs of every step of the surgery to make the procedures easy, simple, and sequential.
- Covers broadly, preoperative, perioperative, and postoperative aspects of patient's care management.
- A must for orthopedic surgeons (trainees and practitioners), students, and teachers.



SKS Marya is the Chairman and Chief Surgeon (Pan Max)—Orthopedics and Joint Replacement at Max Healthcare, New Delhi, India. Dr Marya has been in the field of "Medicine and Orthopedic Surgery" for over 43 years. Dr SKS Marya has completed his MBBS as best graduate and MS (Orthopedics) from PGI (as best postgraduate) Chandigarh with honors and then got his MCh (Orthopedics) and FRCS from UK and was awarded DSc (Honoris Causa) by Amity University. Dr Marya's areas of specialization include Joint Replacement Surgery for the joints of upper and lower limbs (Primary and Revision). Dr Marya has performed more than 25,000 joint replacements of "Knees, Hips, Shoulders, Toes, and Finger joints." Dr Marya has authored nine books and published 100 papers worldwide. He has been the President of Indian Orthopedic Association, Indian Hip and Knee Society, Indian Arthroplasty Association and ASIA. He is an Honorary Visiting Professor to five universities. He has served on Editorial Board of 10 journals. Dr SKS Marya has also been honored with many prestigious awards namely Dhanvantari Award, Bharat Jyoti Award (Glory of India Award), DMA Distinguish Services Award, Haryana Vigyan Ratna, and Praman Patra from Punjab Government and BN Sinha Meritorious Award. Dr Marya has been appointed Chairman Central Athlete Injury Management System by Ministry of Sports and Youth Affairs, Government of India. He is also an Advisor to Mission Olympic Cell. Dr Marya is a Member of Clinical Specialist Committee National Health Authority of India. He has been appointed Convenor Specialist Board in Arthroplasty by the National Board of Examinations. Most recently he has been a Member of International Surgeon design team for a new hip replacement implant which has been launched in the USA and would shortly be launched worldwide.



Rajiv Thukral is currently the Director Orthopedics and Head of the Joint Replacement Program at the Yatharth Group of Hospitals, Faridabad, Delhi NCR, India. He graduated from GMC, Mumbai, did his dual postgraduation (MS Orth and DNB Orth) from LTMMC, Sion, Mumbai, and then completed fellowships in primary and revision joint replacement surgery from the US, UK, Germany, and Italy. Prior to joining the Yatharth Group, he was the Director Orthopedics at Metro Multispecialty Hospitals and Asian Institute of Medical Sciences, Faridabad; and the Principal Consultant and Head, Hip and Pelviacetabular Surgery at Max Healthcare, Saket, New Delhi. Dr Thukral has been an Associate Editor with the "Indian Journal of Orthopedics" and "Journal of Clinical Orthopedics and Traumatology" for over 9 years, while also being on the editorial and reviewer board of five reputed international arthroplasty/orthopedic journals. He has been a visiting faculty with Delhi University since 2010, mentoring many young orthopedic surgeons and physiotherapists, giving numerous lectures at national and international fora for undergraduate and postgraduate students. Dr Thukral has co-authored books (and chapters) on hip and knee replacement, and has more than 20 peer-reviewed publications on the subject of arthroplasty. Dr Thukral has initiated routine fast-track technology-assisted (minimally invasive computer and robotic-assisted) joint replacement surgery in Faridabad, Delhi NCR, and holds the distinction of performing the first three-dimensional (3D) printed (finger and elbow) joint replacement

Printed in India

Available at all medical bookstores or buy online at www.ejaypee.com

JAYPEE BROTHERS
Medical Publishers (P) Ltd.
EMCA House, 23/23-B, Ansari Road, Daryaganj, New Delhi - 110 002, INDIA
www.jaypeebrothers.com

Join us on facebook.com/JaypeeMedicalPublishers
Follow us on instagram.com/JaypeeMedicalPublishers

Shelving Recommendation
ORTHOPEDICS

ISBN 978-93-6616-390-1
9 789366 163901