thers.com, for detailed information on neurology books, visit our website www.jaypeebrothers.com, for detailed information on neurology books



PAM Kunju's Simplified Pediatric Neurology

A Graphic Textbook for Neurologists, Neuro-Pediatricians, Developmental Pediatricians and Practitioners

Editor-in-Chief
PAM Kunju

Editors
Ahamed Subir H
Greeshma Baby

JAYPEE

Contents

Chapter 1	**Localization in Neurology** *PAM Kunju, Ahamed Subir H*	1
Chapter 2	**Examination of Higher Mental Functions** *PAM Kunju, B Aarthi*	19
Chapter 3	**Pediatric Functional Motor Evaluation** *PAM Kunju, Rashma Mohammed*	32
Chapter 4	**Cranial Nerve Localization** *PAM Kunju, Greeshma Baby*	49
Chapter 5	**Approach to Peripheral Neuropathy in Children** *Karthika Ajit V, PAM Kunju*	61
Chapter 6	**Developmental Neurology–Habilitation** *MKC Nair, Swapna S*	76
Chapter 7	**Autism Spectrum Disorder** *PAM Kunju, Aiswarya Mohan S*	90
Chapter 8	**Attention Deficit Hyperactivity Disorder** *PAM Kunju, Varsha H*	103
Chapter 9	**Coma** *Greeshma Baby, PAM Kunju*	111
Chapter 10	**Seizure and Epilepsies** *PAM Kunju, Anzeen Nazir Kanth, Khurshid Ahmed Wani*	120
Chapter 11	**Basics of Electroencephalography** *Kavita Srivastava*	132
Chapter 12	**Basics of Nerve Conduction Study and Electromyography** *Karthika Ajit V, PAM Kunju*	150
Chapter 13	**Myopathies and Muscular Dystrophies** *Dona Teresa Thomas, PAM Kunju*	162
Chapter 14	**Myasthenia Gravis** *PAM Kunju, Jayshree Mahigh*	182
Chapter 15	**Spinal Cord and Its Applied Disorders** *PAM Kunju, Jayshree Mahigh, Akash Wakchaure*	190

Chapter 16 **Neurocutaneous Syndromes** 200
PAM Kunju

Chapter 17 **Cerebral Palsy** 217
PAM Kunju, Hashma Mohammed

Chapter 18 **Pediatric Stroke** 237
Ahamed Subir H, Rashma Mohammed, PAM Kunju

Chapter 19 **Childhood Ataxia: Pearls and Clues for Approach** 255
PAM Kunju, Badiginchala Naga Jyothi

Chapter 20 **Movement Disorders** 263
Rashma Mohammed, PAM Kunju

Chapter 21 **Headache in Children and Adolescent: A Pictorial Tour** 283
PAM Kunju, Hashma Mohammed

Chapter 22 **Genetic Testing in Pediatric Neurology** 293
Sankar VH, PAM Kunju

Chapter 23 **Hypotonia: Floppy Infant Syndrome** 306
PAM Kunju

Chapter 24 **Spinal Muscular Atrophy** 317
Greeshma Baby

Chapter 25 **Basics of Neuroradiology: CT, MRI, and Different Sequences and Advanced Imaging Techniques** 329
Jagruthi Prathipati, PAM Kunju

Chapter 26 **Recent Advances in Neurometabolic Disorders** 343
Badiginchala Naga Jyothi

Chapter 27 **Neurodegenerative Disorders** 357
Greeshma Baby, PAM Kunju

Chapter 28 **Approach to Abnormal Size and Shape of Skull** 385
Greeshma Baby, PAM Kunju

Chapter 29 **Autoimmune and Other Related Encephalitis** 400
Ahamed Subir H, PAM Kunju, Dhurva Sandeep SV

Chapter 30 **Nystagmus: Made Ridiculously Simple!!!** 411
V Jayakumar

Index 423

CHAPTER 10

Seizure and Epilepsies

PAM Kunju, Anzeen Nazir Kanth, Khurshid Ahmed Wani

JAYPEE BROTHERS

INTRODUCTION

Epilepsy was defined conceptually in 2005 by the International League Against Epilepsy (ILAE) as a disorder of the brain characterized by an enduring predisposition to generate epileptic seizures. The task force proposed that epilepsy be considered to be a disease of the brain defined by any of the following conditions: (1) At least two unprovoked (or reflex) seizures occurring >24 hours apart; (2) one unprovoked (or reflex) seizure and a probability of further seizures similar to the general recurrence risk (at least 60%) after two unprovoked seizures, occurring over the next 10 years; (3) diagnosis of an epilepsy syndrome.

After excluding seizure mimics, typing of seizures has to be done to decide on treatment and to identify the seizure syndrome. Seizure type can be generalized, focal, or unclassified. **Figure 1** shows a seizure mimic—(gratification phenomenon). Typical generalized seizure is—absences. Electroencephalogram (EEG) of absence seizures shows 3/sec spike and wave activity **(Fig. 2)**, Clinically hyperventilation can induce absence seizure **(Fig. 3)**.

One of the common epileptic syndromes in children is SelECTS (self-limiting epilepsy with centrotemporal spikes). EEG is shown in **Figure 4**.

MRI finding seen in medial temporal epilepsy (focal impaired awareness seizure of temporal lobe origin) is shown in **Figure 5B** (left medial temporal sclerosis). **Figure 5A** shows a child with focal impaired awareness seizure.



FIG. 1: Rule out seizure mimics—gratification.

SEIZURE MIMICS

What is the essential difference between an "epileptic seizure" and a "nonepileptic seizure"?

"Epileptic seizure"

"An epileptic seizure is a transient occurrence of signs and/or symptoms due to abnormal excessive or synchronous neuronal activity in the brain".

"Nonepileptic seizure"

"Nonepileptic seizure" can look the same but arises as a consequence of a different "nonepileptic" mechanism.

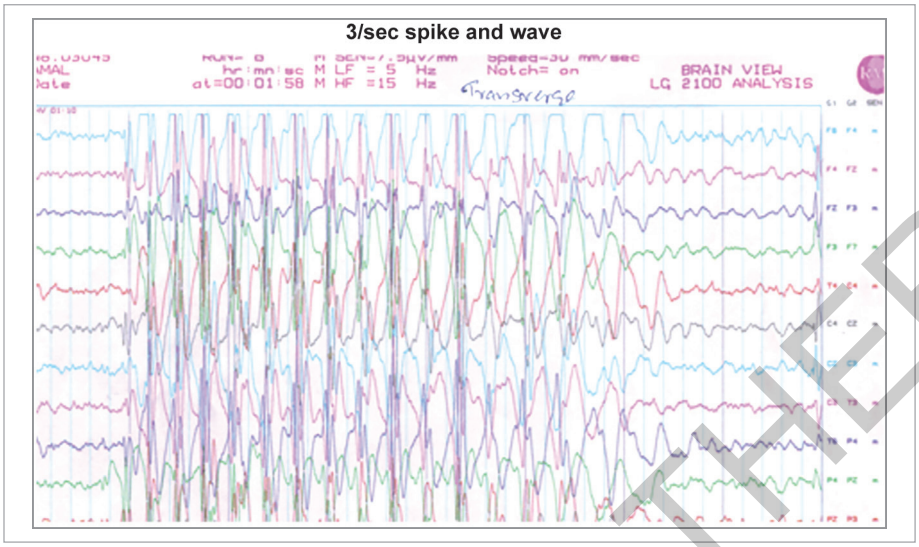

FIG. 2: Typical electroencephalogram (EEG) of generalized seizure = absence.



FIG. 3: Hyperventilation to induce absence seizures.

Epilepsy

Epilepsy refers to a group of different neurological conditions characterized by recurrent epileptic seizures.

Think *epilepsies* rather than *epilepsy!*

Epilepsy Diagnosis

Five axis diagnosis of epilepsy is shown in **Table 1**.

Can use the British Paediatric Neurology Association (BPNA) mnemonic *"DESSCRIBE"* for detailing seizure.

- *D*escription of event
- *E*pileptic or nonepileptic episode(s)
- *S*eizure type(s)
- *S*yndrome?
- *C*ause? (genetic, structural, and metabolic)
- *R*elevant
- *I*ntellectual
- *B*ehavioral
- *E*motional problems

Differential Diagnosis of Epilepsy

In patients presenting with transient loss of consciousness/convulsive movements the history and physical examination may be sufficient for diagnosis in 85% of patients in whom a diagnosis is established.

The most common disorders to be distinguished from epileptic seizures are vasovagal syncope, psychogenic nonepileptic attacks (pseudoseizures), and anxiety attacks.

Clinical Gem: All that shakes is not epilepsy and all epilepsy is not associated with shakes.

JAYPEE BROTHERS

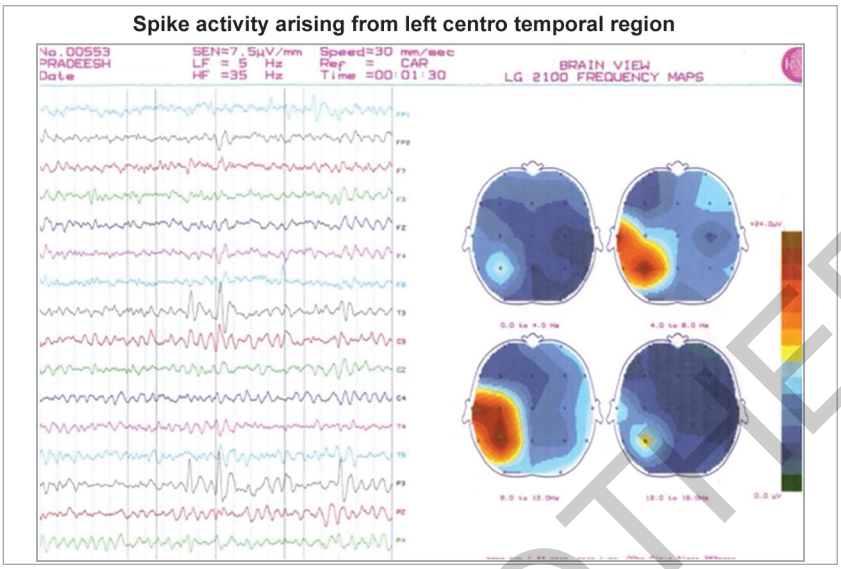

FIG. 4: Focal seizure—centrotemporal spikes on left side.

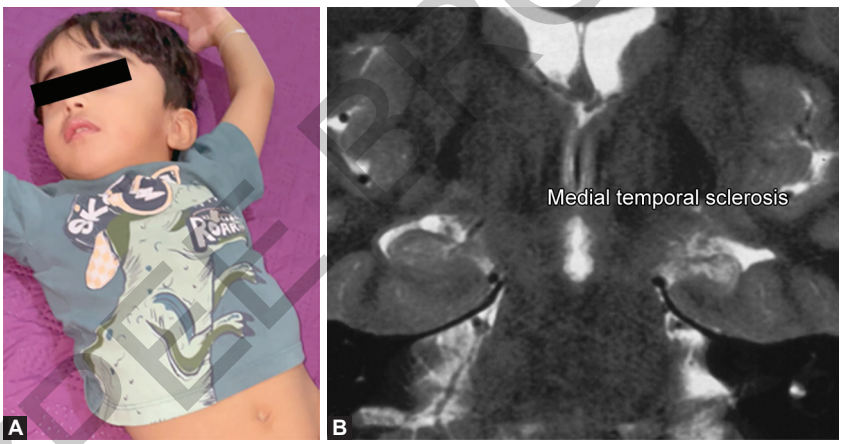

FIGS. 5A AND B: Left hippocampal sclerosis in focal impaired awareness seizure.

TABLE 1: The use of the 5-axis diagnosis.	
Axis 1	• Are the paroxysmal events epileptic seizures? • To be differentiated from nonepileptic events
Axis 2	Define type of seizures: Focal, generalized, or unknown. If focal or generalized (e.g., epileptic spasm)
Axis 3	• Syndrome diagnosis • Age, seizure semiology, sleep/wake EEG features
Axis 4	Etiologic diagnosis (genetic, structural —metabolic or unknown). Detailed description should follow
Axis 5	Description of associated deficits. ID, ADHD, social, educational, etc.
(ADHD: attention-deficit/hyperactivity disorder; EEG: electroencephalogram; ID: intellectual disability)	

JAYPEE BROTHERS

Syncope—due to vasovagal attacks, impaired autonomic function, e.g., drug effects and autonomic neuropathy.

Breath-holding spells—cyanotic form and the pallid form. Infant becomes unresponsive owing to anoxia at the height of the attack. *Cyanotic* Episode is heralded by a brief, shrill cry. *Pallid spells* are typically initiated by a painful experience.

Panic attacks—fear anxiety, light-headedness, peripheral paresthesia, often in anxiety-inducing situations.

Hypoglycemia—stupor, confusion, bizarre behavior, tremulousness, and seizures.

Transient ischemic attacks (TIA) of moyamoya—differentiate from simple partial seizures.

Paroxysmal movement disorders—very rare, presents with sudden choreoathetosis or dystonia, may be triggered by movement (kinesigenic), could be mistaken for partial motor seizures.

Tics—multiple tics could be confused with myoclonic jerks, but in the most important disorder, Gilles de la Tourette, there is also an obsessive-compulsive behavior with accompanying vocalizations.

Idiopathic drop attacks with sudden devastating falls without loss of consciousness, and therefore differs from the atonic seizures.

Migrainous aura—a march of less than a minute suggests partial seizures; over several minutes suggests migraine.

Benign paroxysmal vertigo—develops in the toddler and is relatively rare beyond 3 years of age. Consciousness and the ability to verbalize are not disturbed.

Benign paroxysmal torticollis of infancy—head tilt associated with pallor, agitation, and vomiting onset between 2 and 8 months of age.

Hereditary chin trembling—repeated episodes of rapid 3/sec chin trembling movements.

The episodic dyscontrol syndrome may be confused with CPS.

Gratification phenomenon (masturbation) occurs in female infants of 2 months and 3 years.

TABLE 2: Nonepileptic paroxysmal events in neonates.

Event	Age range (peak age of onset)
Apnea	All, mostly premature infants
Jitteriness	Birth to 10.5 months (0–7 days)
Benign neonatal sleep myoclonus	1 day to 10 months (1–16 days)
Hyperekplexia	Birth–infant (birth)
Hemifacial spasm	All ages (birth)

Transient global amnesia, with amnesia lasting from 30 minutes to a few hours.

SEIZURE MIMICS: NEONATES

Nonepileptic paroxysmal events in neonates are described in **Table 2**.

SEIZURE MIMICS: INFANTS (TABLE 3)

Stereotypies/Rhythmic Movement Disorder

- Rhythmic and stereotyped movements, typically present <3 years.
- Usually in autism or developmental delays, also seen in normally developing children.

Sandifer Syndrome (Fig. 6)

- Paroxysmal episodes of stiffening, dystonia, and/or opisthotonic posturing in response to gastroesophageal reflux.
- There can be associated bradycardia due to triggering of the vagal reflex.
- Episodes often occur within 30 minutes after a meal.
- Can involve staring, head/eye version, and subtle jerking.
- A temporal relationship to eating and lack of mental status changes suggest a nonepileptic etiology.

JAYPEE BROTHERS

TABLE 3: Nonepileptic paroxysmal events in infants.	
Event	**Age range (peak age of onset)**
Breath-holding spells	6 months to 6 years (6–18 months)
Sandifer syndrome	Preschool age
Benign myoclonus of infancy	3 months to 3 years (4–7 months)
Benign paroxysmal torticollis in infancy	1 week to 3 years (5–7 months)
Shuddering attacks	Infant
Stereotypy/rhythmic movement disorder	All ages (9 months to 4 years)
Infantile self-gratification	2 months to 3 years (4–13 months)
Alternating hemiplegia of childhood	3 months to adult (<18 months)
Paroxysmal extreme pain syndrome	Neonatal–adult (infancy)
Ocular phenomena	
Oculomotor apraxia	Neonatal–infancy
Spasmus nutans	2 months to 5 years (4–12 months)
Opsoclonus-myoclonus	6–36 months (6–18 months)



FIG. 6: Sandifer syndrome.



FIG. 7: Benign paroxysmal torticollis.

Benign Paroxysmal Torticollis (Fig. 7)

- Sustained episodes of neck and head deviation to one side with the face deviated toward the other side.
- Episodes are self-resolving, last minutes to days.
- The child is alert and responsive throughout the episodes; typically dissipate by 3 years of age.
- Associated with a family history of migraine.
- Many children with benign paroxysmal torticollis develop typical migraine headaches later in life.

Infantile Self-gratification

Most common in late infancy—female > male, characterized by rocking against a seat, rubbing their legs together, or making pelvic movements **(Figs. 1 and 8)**.

JAYPEE BROTHERS



FIG. 8: Gratification in an young boy.

Spasmus Nutans

Asymmetric pendular nystagmus described in chapter on Nystagmus.

Alternating Hemiplegia of Childhood

- Progressive disorder presenting before 18 months characterized by abrupt episodes of hemiplegia, often accompanied by abnormal eye movements, ataxia, or dystonia, which all resolve with sleep.
- In most patients, the eye movements start within the first 3 months of life.
- Seizures occur in 50% of patients later in life.
- Most cases are caused by de novo mutations in the *ATP1A3* gene.

Nonepileptic paroxysmal events in school-aged children are given in **Table 4**.

Parasomnias

The most common parasomnias seen in children are disorders of arousal **(Box 1)**.

Confusional Migraine

- Confusional migraines are a rare migraine variant characterized by agitation, disorientation, and aphasia, which may continue even after the headache has resolved.
- There is often a strong family history of migraines, and most children go on to develop more typical migraines later in life.

TABLE 4: Nonepileptic paroxysmal events in school-aged children.

Event	Age range (peak age of onset)
Nonepileptic staring spells	All (5 years)
Syncope (vasovagal and convulsive)	Childhood–adulthood (adolescence)
Parasomnia	
Sleepwalking	4 years to adulthood (8–12 years)
Night terrors	1.5–12 years (5–7 years)
Confusional arousal	3–13 years (2.5–5 years)
Tic disorders	3 years to adulthood (6–10 years)
Tourette syndrome	3 years to adulthood (6–10 years)
Benign paroxysmal vertigo	2–10 years (2–4 years)
Migraine	4 years to adulthood (7–11 years)
Acute confusional migraine	7.5–17 years (11–12 years)
Stiff person syndrome	1–14 years (5–11 years)

BOX 1 Parasomnias.

- Confusional arousals
- Night terrors
- Sleep walking

SYNCOPE (BOX 2)

Syncope involves a sudden decrease in cerebral perfusion leading to loss of muscle tone and consciousness.

Vasovagal Syncope

- In vasovagal syncope, heart rate → vagal tone → reflex bradycardia, vasodilation, and transient reduction in cerebral perfusion.
- Triggers include pain, dehydration, high temperatures, sleep deprivation, postural changes, etc.

JAYPEE BROTHERS

BOX 2 Syncope.

- *Reflex/Neurally mediated*:
  - Vasovagal
  - Situational (eg. defecation)
  - Carotid sinus syndrome
- *Cardiac*:
  - Structural
  - Arrhythmia
  - Great vessel defect

3. *Orthostatic hypotension*:
   - Volume depletion
   - Autonomic failure

- *Prodrome*: Lightheadedness, palpitations, dimming or tunnel vision, nausea, pallor, and changes in hearing are common.
- *Convulsive syncope*: Once a child has fainted, myoclonic jerks of the extremities, at times rhythmic and synchronous, abnormal eye movements such as eye rolling and deviation may be seen.
- Confused with tonic-clonic seizures. The most helpful factors in distinguishing between the two are the typical prodromal symptoms and the absence of a postictal state in syncope.
- Urinary incontinence can occur in both disorders; tongue biting (tip of tongue) is rare in syncope but is reported.

Cardiac Syncope

Cardiac arrhythmias may have prodromal palpitations, pallor is common.

Prolonged QT syndrome **(Fig. 9)** is characterized by sudden loss of consciousness during exercise or an emotional and stressful experience. Those due to acquired heart disease (myocarditis, mitral valve prolapse, electrolyte abnormalities, and drug induced) and two congenital forms—autosomal recessive and autosomal dominant **(Fig. 10)**.

Orthostatic Hypotension

- *Volume depletion*: Hemorrhage, vomiting, diarrhea
- *Autonomic failure*: Primary, secondary, drug induced.

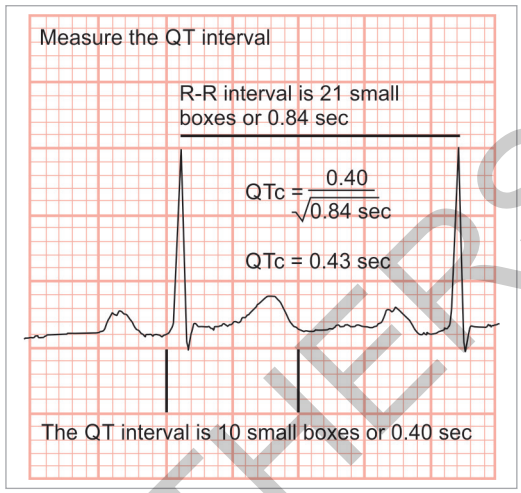

FIG. 9: Pronged QT.

BENIGN PAROXYSMAL VERTIGO

- Migraine-related syndrome characterized by episodes of vertigo commonly associated with nystagmus, pallor, diaphoresis, nausea, and vomiting.
- Episodes are brief, lasting <1 minute but can occur in clusters.
- A fearful expression often signals the start of an episode of benign paroxysmal vertigo, which can be confused with temporal lobe epilepsy.
- Episodes of vertigo often first present in children aged 1–3 years old and remit by age 5–8 years.
- There is no change in mental status.

Psychogenic Nonepileptic Seizures

- Psychogenic nonepileptic seizures (PNESs) are a form of functional neurological disorder seen in children as young as 5 years but more commonly in adolescents.
- Involve reduced levels of consciousness, with complete unresponsiveness in one-third, and seizure-like movements. The movements most commonly resemble tonic-clonic seizures, but without accompanying electrophysiologic changes.

JAYPEE BROTHERS

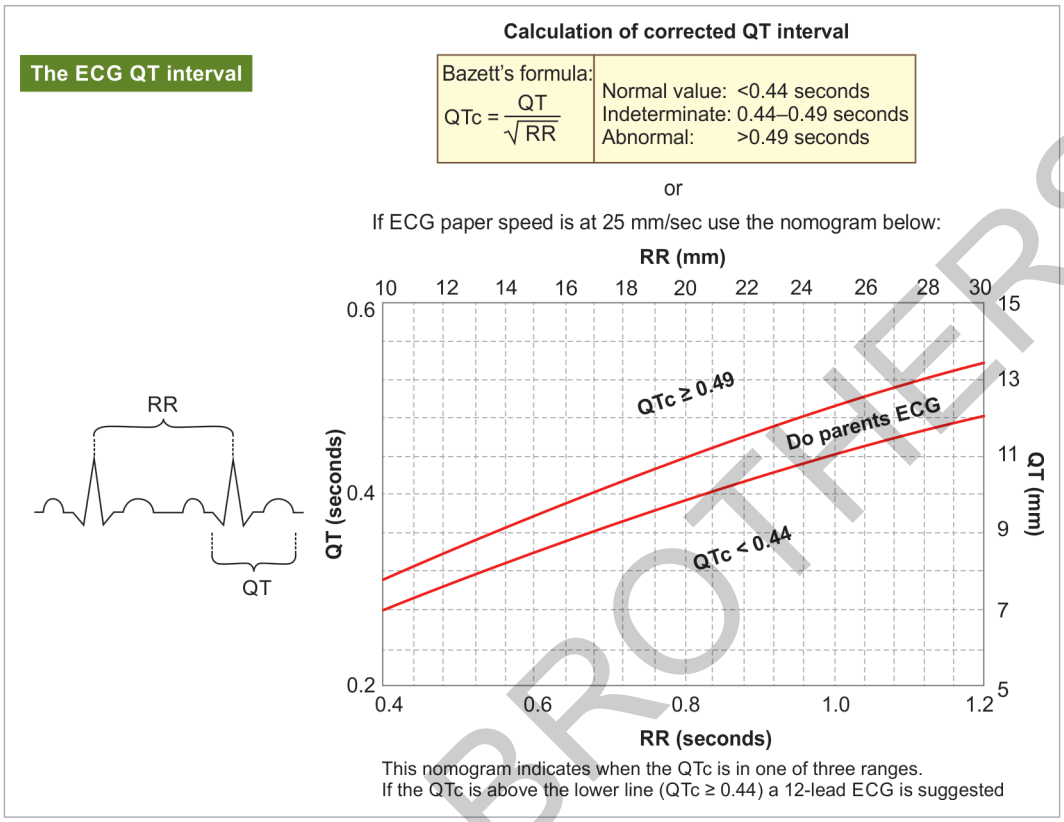

FIG. 10: Approach to prolonged QT syndrome.

- Episodes are often seen in patients with a history of difficulties in school or at home, fear of rejection, or physical or sexual abuse.
- The challenge in diagnosing PNES is that episodes can sometimes very closely resemble seizures, and a large proportion of children have coexisting epilepsy and PNES. To complicate matters further, PNES episodes in children with epilepsy resemble their own seizures nearly 50% of the time.

Narcolepsy with Cataplexy

- Cataplexy is characterized by abrupt loss of muscle tone triggered by laughing or other changes in emotional state.
- Cataplexy can appear like atonic seizures.
- However, further history reveals excessive daytime sleepiness, rapid transitions to sleep, hypnagogic/hypnopompic hallucinations, and sleep paralysis in narcoleptic patients.

Paroxysmal Dyskinesia

Paroxysmal dyskinesias are a rare group of abnormal movement disorders that may be characterized by ballism, dystonia, or choreoathetosis **(Fig. 11)**.

THE ILAE CLASSIFICATION OF SEIZURES

Seizure Classification

Most widely used classification system: The International League Against Epilepsy (ILAE) **(Flowchart 1)**.

JAYPEE BROTHERS

Classification of Seizures: Methods

Historical elicitation or observation of certain symptoms and signs (semiology of seizures) that are known to be associated with common seizures.

Electroencephalography, imaging, or laboratory studies are sometimes needed to properly classify a seizure. For these cases, classification of seizure type begins to merge imperceptibly with diagnosis of epilepsy syndromes.



FIG. 11: Paroxysmal dyskinesia.

Classification of Seizures: Steps

Type of onset:

- Generalized onset **(Figs. 12 and 13)**
  - Focal onset **(Figs. 14 and 15)**
  - Unknown onset
- Generalized seizures
  - Originating at some point within, and rapidly engaging, bilaterally distributed networks.

Summary of Classifying Seizure

- *Onset*: Decide whether seizure onset is focal or generalized, using an 80% confidence level. Otherwise, onset is unknown.
- *Awareness*: For focal seizures, e.g., by the history a tonic seizure can be identified as focal or generalized **(Fig. 16)** decide whether to classify by degree of awareness or to omit awareness as a classifier. Focal aware seizures correspond to the old simple partial seizures and focal impaired awareness seizures to the old CPS.

ILAE 2017 classification of seizure types expanded version[1]

Focal onset		Generalized onset	Unknown onset
Aware	Impaired awareness	**Motor** • Tonic-clonic • Clonic • Tonic • Myoclonic • Myoclonic-tonic-clonic • Myoclonic-atonic • Atonic • Epileptic spasms[2] **Nonmotor (absence)** • Typical • Atypical • Myoclonic • Eyelid myoclonia	**Motor** • Tonic-clonic • Epileptic spasms **Nonmotor** • Behavior arrest
Motor onset • Automatisms • Atonic[2] • Clonic • Epileptic spasms[2] • Hyperkinetic • Myoclonic • Tonic **Nonmotor onset** • Autonomic • Behavior arrest • Cognitive • Emotional • Sensory **(Fig. 17)**			Unclassified[3]
Focal to bilateral tonic-clonic			

[1]Definitions, other seizure types and descriptors are listed in the accompanying paper and glossary of terms.
[2]These could be focal or generalized with or without alteration of awareness.
[3]Due to inadequate information or inability to place in other categories.

FLOWCHART 1: The basic International League Against Epilepsy (ILAE) 2017 operational classification of seizure types.

JAYPEE BROTHERS

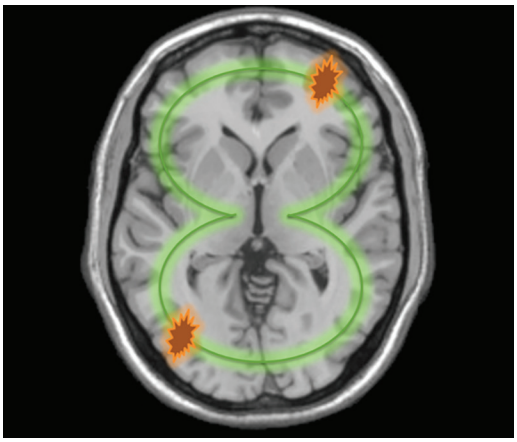

FIG. 12: Generalized seizure genesis originating at some point within, and rapidly engaging, bilaterally distributed networks.

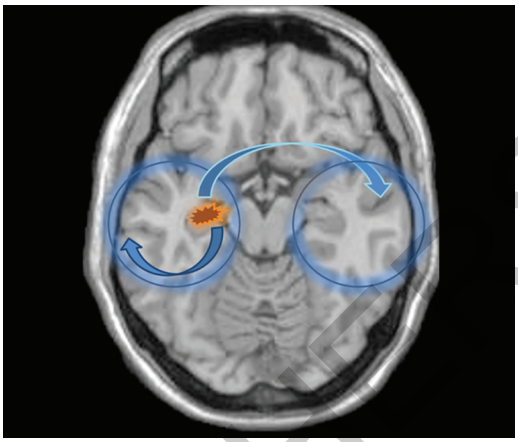

FIG. 14: Focal seizure originating within networks limited to one hemisphere. They may be discretely localized or more widely distributed.

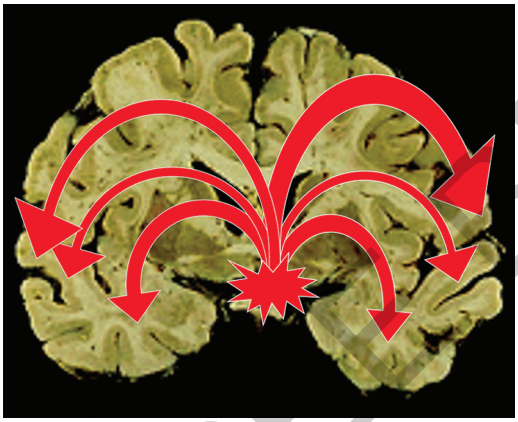

FIG. 13: Generalized seizure genesis centrencephalic origin.

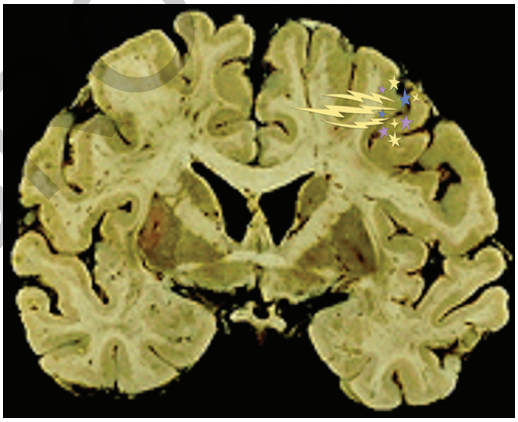

FIG. 15: Focal seizure restricted origin.



FIG. 16: Tonic seizures can be focal or generalized focal tonic seizure.

JAYPEE BROTHERS

- *Behavior arrest*: A focal behavior arrest seizure shows arrest of behavior as the prominent feature of the entire seizure.
- *Motor/nonmotor*: A focal aware or impaired awareness seizure may be further subclassified by motor or nonmotor characteristics.
- *Atypical absence*: Absence is atypical if it has slow onset or offset, marked changes in tone, or EEG spike-waves at <3/second.
- *Clonic versus myoclonic*: Clonic refers to sustained rhythmic jerking and myoclonic to regular unsustained jerking.
- *Eyelid myoclonia*: Absence with eyelid myoclonia refers to forced upward jerking of the eyelids during an absence seizure.

Common descriptors of behaviors during and after seizures are given in **Figures 17 and 18**.

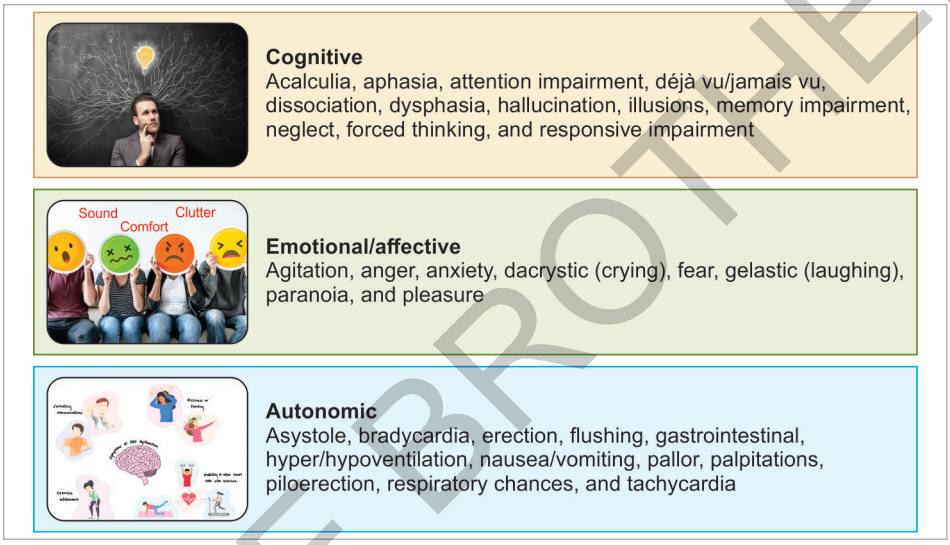

FIG. 17: Focal seizure (cognitive and emotional—previously classified as psychic).

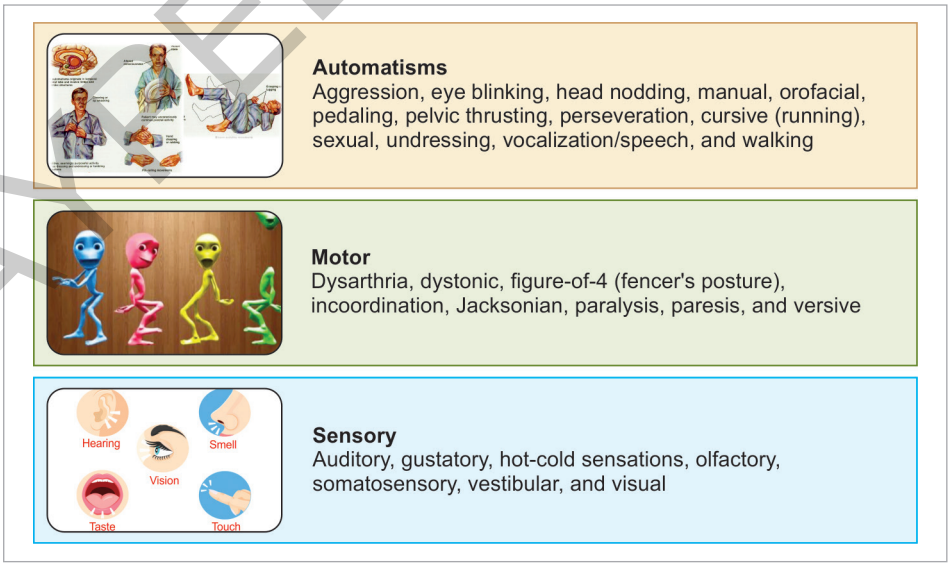

FIG. 18: Focal seizures motor and sensory seizures.

JAYPEE BROTHERS

Epilepsy syndrome (ES) are defined by the presence of characteristic electroclinical features. They have a specific seizure type, age of onset, specific pattern of EEG involvement, specific comorbidities and prognosis. Etiologically syndromes are—structural, genetic, metabolic, immune, and infectious or idiopathic.

These can be self-limiting epilepsies or severe pharmacoresistant seizure syndromes. Among them can be childhood absence epilepsy which is primary generalized epilepsy that can be easily treated with ethosuximide. Severe epilepsy syndromes are termed now as DEE.

DEE can occur either due to underlying (developmental encephalopathy) and superimposed epileptic activity (epileptic encephalopathy). These spectrum include the EIEE (early infantile epileptic encephalopathy) with supression burst pattern-Ohtahara syndrome to West syndrome (infantile epileptic spasm syndrome) and LGS (Lennox–Gastaut syndrome). ILAE denote clearly defined entities with a distinct phenotype and a specific etiology, examples are monogenic epilepsies, such as CDKL5 DEE and PCDH19 clustering epilepsy, and structural entities such as mesial temporal lobe epilepsy with hippocampal sclerosis and gelastic seizures with hypothalamic hamartoma (details of ES are given elsewhere).

CONCLUSION

Seizure is defined as "a transient occurrence of signs and/or symptoms due to abnormal excessive or synchronous neuronal activity in the brain". After excluding seizure mimics, typing of seizures has to be done to decide on treatment and to identify the seizure syndrome. Seizure type can be generalized, focal or unclassified. 5-axis diagnosis is used to manage epilepsies in a systematic manner. Syncope due to vasovagal attacks, impaired autonomic function, e.g., drug effects, and autonomic neuropathy should always be excluded rather than going for an EEG to diagnose epilepsy. Historical elicitation or observation of certain symptoms and signs (semiology of seizures) that are known to be associated with common seizures will give the diagnosis. EEG is used to make an epileptic syndrome diagnosis.

SUGGESTED READINGS

1. Scheffer IE, Berkovic S, Capovilla G, Connolly MB, French J, Guilhoto L, et al. ILAE classification of the epilepsies: Position paper of the ILAE Commission for Classification and Terminology. Epilepsia. 2017;58:512-21.
2. Fisher RS, Cross JH, French JA, Higurashi N, Hirsch E, Jansen FE, et al. Operational classification of seizure types by the International League Against Epilepsy: Position Paper of the ILAE Commission for Classification and Terminology. Epilepsia. 2017;58:522-30.
3. Fisher RS, Cross JH, D'Souza C, French JA, Haut SR, Higurashi N, et al. Instruction manual for the ILAE 2017 operational classification of seizure types. Epilepsia. 2017;58:531-42.
4. Berg AT, Berkovic SF, Brodie MJ, Buchhalter J, Cross JH, van Emde Boas W, et al. Revised terminology and concepts for organization of seizures and epilepsies: report of the ILAE Commission on Classification and Terminology, 2005–2009. Epilepsia. 2010;51:676-85.

JAYPEE BROTHERS

for detailed information on neurology books, visit our website www.jaypeebrothers.com, for detailed information on neurology books, visit our we

PAM Kunju's Simplified Pediatric Neurology

A unique "*coffee table book*" designed to serve as an engaging visual experience for all. Each chapter begins with a pictorial guide of the disease discussed, followed by an interesting approach through photos, graphics, triads, and mnemonics. As you thumb through the pages, all topics pertaining to pediatric neurology are covered from basics to recent advances till 2024. The electrodiagnostic testing as well as the latest advances in neuroimaging techniques and mode of botulinum therapy are discussed clearly and practically. The book aims to give an idea about topics through a lot of photographs which are contributed by the chief editor.



PAM Kunju MD(Pediatrics) DM(Neurology) FRCP(London) WHO Fellowship Ped Neuro(USA) FIAPN FIAP FIAN is an Editor-in-Chief of this book. Professor Dr PA Mohammed Kunju (popularly known as "PAM Kunju/Kunju Sir") is former Professor and Head of Pediatric Neurology, Government Medical College, Thiruvananthapuram. He is also In-Charge as Dean Faculty of Medicine, University of Kerala, India. He is a versatile teacher with huge number of fans following in India and abroad. He received numerous awards including the *"Best Doctor Award of Government of Kerala"* in 2016. He is the Editor of IAP Textbook of Pediatric Neurology, Section Editor of IAP Color Atlas and various other IAP books. As an administrator he started the first ever Pediatric Neurology Department in India, and started DM and DrNB in pediatric neurology.



Ahamed Subir H MBBS MD DM DNB FNB FEBN EDSI SCE MRCP(UK) Neurology is an Editor of this book. Subir is a distinguished neurologist and neurointerventionist (FNB) and a passionate teacher renowned for his expertise and dedication to neurology and neurovascular medicine. He is an Associate Professor in Neurology and Neurointervention at MES Medical College, Kerala, India. He has several publications in esteemed journals, and has received numerous awards.



Greeshma Baby MBBS DCH DNB Fellowship in Pediatric Neurology is also an Editor of this book. She is also a Senior Resident in "Pediatric Neurology" at KIMS Health, Thiruvananthapuram, Kerala, India, where she combines her dedication to patient care with a passion for research. She has many best paper awards to her credit. She has also contributed to the IAP Textbook of OSCEs, and IAP Textbook of Epilepsy.

Printed in India

Available at all medical bookstores or buy online at www.ejaypee.com

JAYPEE BROTHERS
Medical Publishers (P) Ltd.
EMCA House, 23/23-B, Ansari Road, Daryaganj, New Delhi - 110 002, INDIA
www.jaypeebrothers.com

Join us on facebook.com/JaypeeMedicalPublishers
Follow us on instagram.com/JaypeeMedicalPublishers

Shelving Recommendation
NEUROLOGY

ISBN 978-93-6616-423-6