ur website www.jaypeebrothers.com, for detailed information on dermatology books, visit our website www.jaypeebrothers.com



TRICHOSCOPY

A Text and Atlas

Editors
Subrata Malakar
Surit Malakar

2nd Edition

JAYPEE

Contents

SECTION 1: INTRODUCTION

1. **Introduction** 3
   Samipa S Mukherjee

SECTION 2: DEVICES AND TOOLS

2. **Devices and Tools** 9
   Subrata Malakar, Surit Malakar

SECTION 3: TRICHOSCOPIC TERMINOLOGIES

3. **Trichoscopic Terminologies** 13
   Subrata Malakar

SECTION 4: TRICHOSCOPIC LANGUAGE AND PATTERN ANALYSIS

4. **Follicular and Perifollicular Patterns** 57
   Subrata Malakar, Purva Mehta Movdawalla

5. **Interfollicular Pattern** 69
   Subrata Malakar, Surit Malakar

6. **Pattern of Hair Shafts** 72
   Subrata Malakar

7. **Pattern of Scaly Scalp** 89
   Subrata Malakar

SECTION 5: NORMAL SCALP

8. **Normal Scalp** 101
   Subrata Malakar

   8A Scalp Dysesthesia 120
   Surit Malakar, Subrata Malakar

   8B Fox–Fordyce Disease 122
   Surit Malakar, Subrata Malakar

SECTION 6: NONSCARRING ALOPECIAS

9. Androgenetic Alopecia 127
Subrata Malakar, Purva Mehta Movdawalla, Surit Malakar

10. Female Pattern Hair Loss 142
Subrata Malakar, Surit Malakar, Purva Mehta Movdawalla

11A. Alopecia Areata Incognito 152
Subrata Malakar

11B. Alopecia Areata 155
Subrata Malakar

12. Trichotillomania 173
Subrata Malakar

13. Traction Alopecia 191
Subrata Malakar

14. Telogen Effluvium 195
Subrata Malakar, Purva Mehta Movdawalla, Surit Malakar

15. Anagen Effluvium 201
Subrata Malakar, Barnali Chowdhury

SECTION 7: SCARRING ALOPECIAS

16. Lichen Planopilaris 219
Subrata Malakar, Surit Malakar

17. Frontal Fibrosing Alopecia 228
Subrata Malakar

18. Discoid Lupus Erythematosus 232
Subrata Malakar, Samipa S Mukherjee, Surit Malakar

19. Acne Keloidalis Nuchae 237
Subrata Malakar, Purva Mehta Movdawalla, Priya Diwaker

20. Central Centrifugal Cicatricial Alopecia 241
Subrata Malakar

21. Folliculitis Decalvans 246
Subrata Malakar

22. Dissecting Cellulitis 251
Subrata Malakar

23. Pseudopelade of Brocq 252
Subrata Malakar

SECTION 8: HAIR WEATHERING

24. Trichoscopy of Damaged Hair 261
Samipa S Mukherjee, Subrata Malakar

SECTION 9: INFECTION AND INFESTATION

25. Tinea Capitis 271
Subrata Malakar

26. Pediculosis Capitis 277
Subrata Malakar

27. Scalp Psoriasis, Seborrheic Dermatitis, and Sebopsoriasis 283
Subrata Malakar

28. Trichoscopy in Autoimmune Bullous Disorders 298
Souvik Sardar, Subrata Malakar

29. Trichoscopy in Autoimmune Connective Tissue Diseases 305
Souvik Sardar, Subrata Malakar

30. Pediatric Hair Disorders 314
Samipa S Mukherjee, Subrata Malakar

31. Body Hair 326
Subrata Malakar

32. Trichoscopy in Hair Transplantation 354
Madura C, BS Chandrashekar

33. Algorithm 361
Samipa S Mukherjee

34. Trichoscopic Monitoring and Follow-up 365
Subrata Malakar

Index 377

6

SECTION

Nonscarring Alopecias

JAYPEE BROTHERS

CHAPTER

9

Androgenetic Alopecia

Subrata Malakar, Purva Mehta Movdawalla, Surit Malakar

INTRODUCTION

- Both androgenetic alopecia (AGA) and female pattern hair loss (FPHL) are androgen-dependent conditions which develop in genetically predisposed persons.[1] AGA affects around 80% of males whereas FPHL affects around 50% of females.[1-4]
- They share the same histopathological criteria of hair follicle miniaturization.
- They also share the same pathway of pathogenesis. Dihydrotestosterone (DHT) binds to androgen receptor in susceptible hair follicles. This activates the genes responsible for the transformation of terminal follicles to miniaturized ones.[1-4]
- AGA affects the front-temporal areas and vertex which follows a pattern corresponding to Hamilton–Norwood scale.
- Whereas FPHL produces diffuse thinning of the crown where the frontal hairline is maintained (Ludwig pattern). It can easily be demonstrated by making a central parting.



Figs. 1A and B: Androgenetic alopecia is more prominent in frontal than occipital area.

JAYPEE BROTHERS

KEY FEATURES

- Hair diameter diversity of > 20%
- Peripilar sign
- Yellow dots
- Vellus hairs
- Reduced number of hairs per follicular unit
- AGA is more pronounced in the frontal rather than occipital area in trichoscopic examination.
- Coexistence of other causes of hair loss is not uncommon which can be excluded trichoscopically.

HAIR DIAMETER DIVERSITY

- A diversity of >20% per field of dermoscope in frontal area is diagnostic for AGA.
- However, an exception to this if found across scalp one has to suspect diffuse unpatterned alopecia (DUPA).
- It is characterized by simultaneous presence of hairs of different diameters such as thick, thin, intermediate, and vellus hairs. It reflects follicular miniaturization.[5,6]
- Trichoscopy is highly effective in differentiating FPHL from acute and chronic telogen effluvium.[7]



Fig. 2: Peripilar sign and hair diameter variability.

JAYPEE BROTHERS



Fig. 3: Marked hair diameter diversity which is more apparent due to a recent haircut. Honeycomb pigmentation and white dots are also observed through reduced hair length.



Fig. 4: Hair diameter variability can also be observed in alopecia areata. However, in alopecia areata trichoscopy shows uniform miniaturization. Note the peripheral terminal hairs surrounding the alopecic patch.

JAYPEE BROTHERS

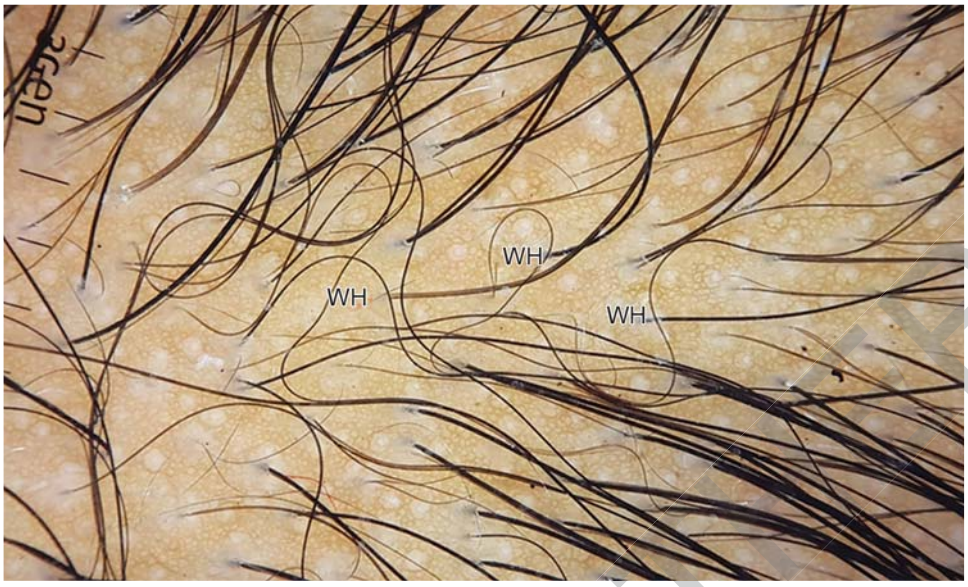

Fig. 5: Thin wavy hairs (WH)—hair diameter diversity is characterized by simultaneous presence of hairs of different diameters such as thick, thin, intermediate (WH) and vellus hairs. The diameter of WH is in between thick and thin hairs and is a result of incomplete miniaturization of hair follicles. Thin wavy hairs may also be found in *alopecia areata incognita*.[8]



Fig. 6: Diameter of thin wavy hairs is 0.03–0.05 mm. They are thinner than terminal but thicker than vellus hairs.

JAYPEE BROTHERS



Fig. 7: This field has terminal (T), vellus (V), and thin wavy hairs (WH).

PERIPILAR SIGN

- It is seen as a brown depressed halo of approximately 1 mm diameter at the follicular emergence. It correlates with perifollicular inflammation.[9] Inui et al. hypothesized peripilar sign in Asians as a result of postinflammatory hyperpigmentation.[5]
- This sign is observed in 20–66% of patients.[5]
- This is commonly found in patients with early AGA.
- Karadog and Gulec indicated that peripilar sign is specific for AGA. <5% of hair follicle openings with brown peripilar discoloration is observed in healthy scalp.[10]
- Extensive peripilar sign is a poor prognostic factor for AGA.[8]



Fig. 8: Peripilar sign.

JAYPEE BROTHERS



Fig. 9: Peripilar sign.

VELLUS HAIRS

- They are a sign of severe miniaturization.
- Up to 10% of normal human scalp hairs are vellus hairs. They are defined as hypopigmented, nonmedullated hairs < 30 µm thick and <3 mm long.[11,12]
- In normal population, proportion of vellus hairs are 6.15 ± 4.6%. In FPHL this proportion is 20.9 ± 12% which is much greater than in normal population.[13]



Fig. 10: Vellus hairs (VH).

JAYPEE BROTHERS

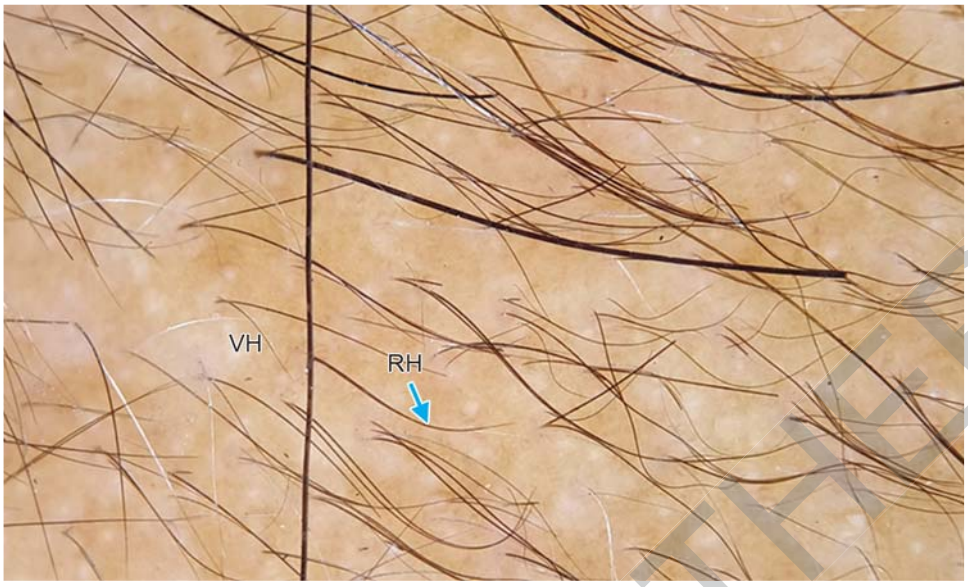

Fig. 11: Vellus hairs versus short regrowing hairs. Vellus hairs (VH) should be differentiated from regrowing hairs (RH). Regrowing hairs are short and thin, not hypopigmented, they are firm and have pointed ends. Whereas vellus hairs are hypopigmented and thin hairs.

A DECREASED NUMBER OF HAIRS PER FOLLICULAR UNIT

- It is a characteristic but nonspecific feature of AGA and FPHL.
- The normal values for the frontal area in healthy Caucasian females have been established. This is < 35% for one-hair follicular unit, 46–70% for two-hair units, and >10% for three-hair units. The respective numbers for occipital area are < 30%, 45–73%, and >10% and for temporal area, <40%, 50–75%, and >10%.[11]



Fig. 12: Reduced number of hairs per follicular unit in androgenetic alopecia (AGA). Note hair diameter diversity.

JAYPEE BROTHERS

YELLOW DOTS

- They are a feature of severe miniaturization and are more numerous in patients with severe FPHL and severe AGA.
- They correspond to follicular ostia filled with keratosebaceous material.
- They were first described in alopecia areata.
- Rudnicka et al. hypothesized that yellow dots in AGA consist mainly of sebum.[13] Yellow dots of DLE correspond to wide infundibula filled with keratotic material.[14]



Fig. 13: Yellow dots (YD).

REFERENCES

1. Otenberg N, Finner AM, Shapiro J. Androgenetic alopecia. Endrocrinol Metab Clin North Am. 2007;36(2):379-98.
2. Olsen EA. Female pattern hair loss and its relationship to permanent/cicatricial alopecia: A new prespective. J Investig Dermatol Symp Proc. 2005;10(3):217-21.
3. Price VH. Androgenetic alopecia in women. J Investig Dermatol Symp Proc. 2003;8(1):24-7.
4. Trueb RM. Systematic approach to hair loss in women. J Dtsch Dermatol Ges. 2010;8(4):284-98.
5. Inui S, Nakajima T, Itami S. Scalp dermoscopy of androgenetic alopecia in Asian people. J Dermatol. 2009;36(2):82-5.
6. de Lacharriere O, Deloche C, Misciali C, Piraccini BM, Vincenzi C, Bastien P, et al. Hair diameter diversity: A clinical sign reflecting the follicle miniaturization. Arch Dermatol. 2001;137(5):641-6.
7. Vincenzi C, Tosti A. Nonscarring alopecias. In: Tosti A (ed). Dermoscopy of Hair and Nails, 2nd edition. New Delhi: CRC Press; 2016. pp. 29-49.
8. Rakowska A, Slowinska M, Kowalska-Oledzka E. Androgenetic alopecia. In: Rudnicka L, Olszewska M, Rakowska A (eds). Atlas of Trichoscopy. Philadelphia: Springer; 2012. pp. 231.
9. Deloche C, de Lacharriere O, Misciali C, Piraccini BM, Vincenzi C, Bastien P, et al. Histological features of peripilar signs associated with androgenetic alopecia. Arch Dermatol Res. 2004;295:422-8.
10. Karadag Kose O, Gulec AT. Clinical evaluation of alopecias using handheld dermatoscope. J Am Acad Dermatol. 2011;67:206-14.
11. Rakowska A. Trichoscopy (hair and scalp videodermoscopy) in healthy female. Method standardization and norms for measurable parameters. J Dermatol Case Rep. 2009;3(1):14-9.
12. Vogt A, McElwee KJ, Blume-Peytavi U. Biology of the hair follicle. In: Blume-peytavi U, Tosti A, Whiting D, Trueb R, editors. Hair; from basic science to clinical application. Berlin: Springer; 2008. pp. 1-22.
13. Rakowska A, Slowinska M, Kowalska-Oledzka E, Olszewska M, Rudnicka L. Dermoscopy in female androgenic alopecia: method standardization and diagnostic criteria. Int J Trichol. 2009;1(2);123-30.
14. Rudnicka L, Olszewska M, Rakowska A, Slowinska M. Trichoscopy update 2011. J Dermatol Case Rep. 2011;5(4):82-8.

JAYPEE BROTHERS

ASSESSMENT IMAGE-BASED QUESTIONS

1. Brown halo around the emergence of hair follicles. (A) What is the name of this phenomenon? (B) What is its pathological correlation? (C) Name the conditions where you can find it.



2. What is the trichoscopic finding of this field? In which condition you can find it?



JAYPEE BROTHERS

3. Red arrow points toward a thin wavy hair. Name the conditions where it may be found.



4. This trichoscopic observation is a very important distinguishing feature of AGA. What are the other trichoscopic findings of this condition?



JAYPEE BROTHERS

5. In this field of trichoscopic examination of AGA number of vellus hairs are increased. They are less than 30 μm in diameter and <3 mm long. They are hypopigmented and nonmedullated. What is the mechanism of vellus hair transformation from terminal hairs? Mention the percentage of normal vellus hairs.



6. The proportion of single hair units are increased in AGA. Usually 1–3 hairs emerge from one follicular opening. What is the normal proportion of single hair units?



JAYPEE BROTHERS

7. Yellow dots are follicular openings with keratosebaceous material. They are first described in AA and are also found in AGA. Yellow dots in AGA usually differ from those in AA; in AGA these dots are distributed irregularly and they have high variability in their size and shape. Try to locate the yellow dots in this picture.



8. Clinicodermoscopically this is a case of AGA. The main trichoscopic features are hair diameter diversity, peripilar sign and yellow dots. In which area of the scalp these features are more pronounced?





JAYPEE BROTHERS

9. Arrows 1 and 2 signify which conditions?



10. Arrows 1 and 2 indicate which trichoscopic features.



JAYPEE BROTHERS

11. What are the trichoscopic features of this image?



12. This trichoscopic image shows uniform miniaturization. Name the condition and its differential diagnosis.



JAYPEE BROTHERS

13. Thin wavy hairs are seen in this trichoscopic image. Name the conditions in which they are found.

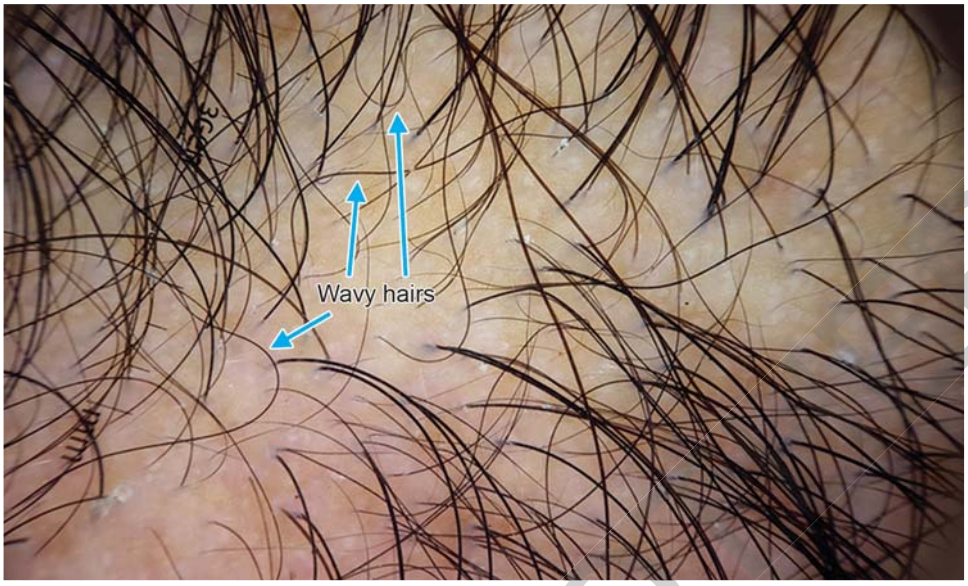

ANSWERS

1. (A) Peripilar sign; (B) Lymphocytic infiltrate around the follicle; (C) Anagen effluvium, androgenetic alopecia
2. Hair diameter diversity, androgenetic alopecia
3. AGA, Alopecia areata incognito
4. Hair diameter diversity. Peripilar sign, yellow dots
5. Miniaturization of hair due to hormonal influence. <10%
6. Up to 35%
7. 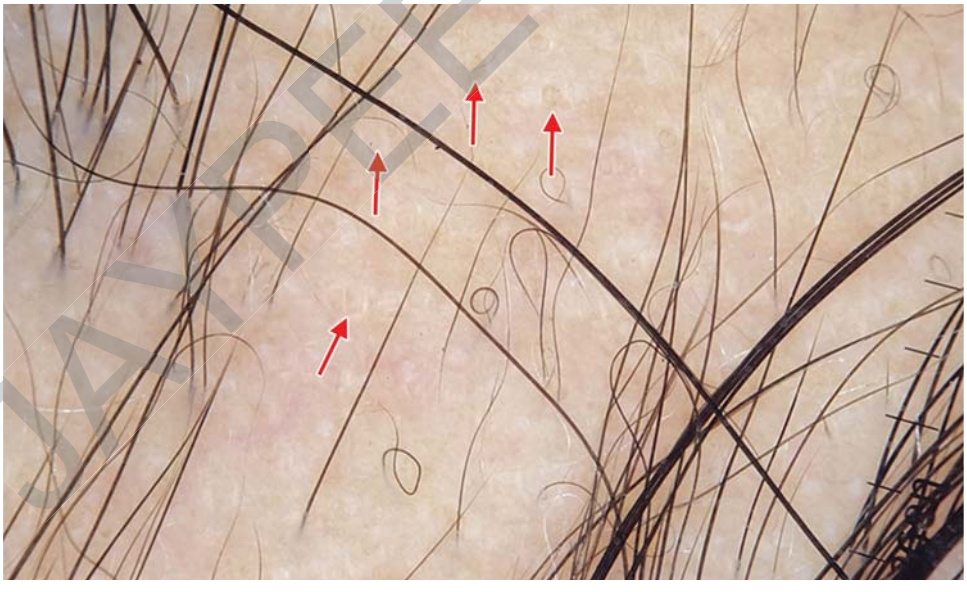
8. Frontal area
9. 1. Dark line; 2. Yellow dot
10. 1, 2. Dark line
11. Hair diameter diversity, terminal hair, vellus hair, peripilar sign, pinpoint white dots, yellow dots
12. Alopecia areata. Androgenetic alopecia, alopecia areata
13. Alopecia areata incognito, AGA

JAYPEE BROTHERS

for detailed information on dermatology books, visit our website **www.jaypeebrothers.com,** for detailed information on dermatolo

TRICHOSCOPY
A Text and Atlas

Salient Features

- The first book to demonstrate and decode the language of trichoscopy with illustrations
- Methodical demonstration of trichoscopic findings in hair disorders aids in understanding the subject
- Self-assessment images serve as an invaluable tool to judge the hold on the subject after a thorough reading
- Algorithms listed at the end of the book help in approaching any hair disorder in clinical practice with ease
- Demonstration of multiple new signs and findings arouses the inquisitiveness and interest of the readers



Subrata Malakar MBBS MD(Dermatology) DCH is an accomplished clinician and astute academician par excellence, heading Rita Skin Foundation, one of the premier dermatology centers in India. Having passed Dermatology in 1985, he has also completed a diploma in Child Health from one of the top institutes in Kolkata. His passion for dermatology, vision for innovation, and commitment to the subject have rendered him the status of a teacher and doctor par excellence. He has authored over 90 papers in various international and national journals, many chapters in various textbooks, and over 76 presentations in international and national conferences. Dr Malakar has received several prestigious honors and awards in his career. He is known among his peers as a visionary, always striving for excellence, and his passion for innovation distinguishes him in the field of dermatology.



Surit Malakar MBBS MD(Dermatology) is an accomplished clinician and one of the Directors at Rita Skin Foundation, a premier dermatology center in India. He has a particular passion for dermatosurgery, specializing in innovative procedures. With 20 publications and over 25 authored book chapters, he has made significant contributions to the field. He has also presented at more than 20 national and international conferences. His special interests include clinical dermatology, dermatosurgery, dermoscopy, and aesthetic dermatology.

Printed in India

Available at all medical bookstores or buy online at www.ejaypee.com

JAYPEE BROTHERS
Medical Publishers (P) Ltd.
EMCA House, 23/23-B, Ansari Road, Daryaganj, New Delhi - 110 002, INDIA
www.jaypeebrothers.com

Join us on facebook.com/JaypeeMedicalPublishers
Follow us on instagram.com/JaypeeMedicalPublishers

Shelving Recommendation
DERMATOLOGY

ISBN 978-93-6616-424-3