d information on nursing books, visit our website www.ejaypee.com, for detailed information on nursing books, visit our website www.ejaypee.com,

Complimentary Online Resource
MCQs, Flashcards and Videos Only with Genuine Book

Textbook of Applied Anatomy and Physiology for Nurses

Complimentary Books Inc

- One Stop Resource for All Your Exam Needs in Ap
- Practice Workbook

Semester-I

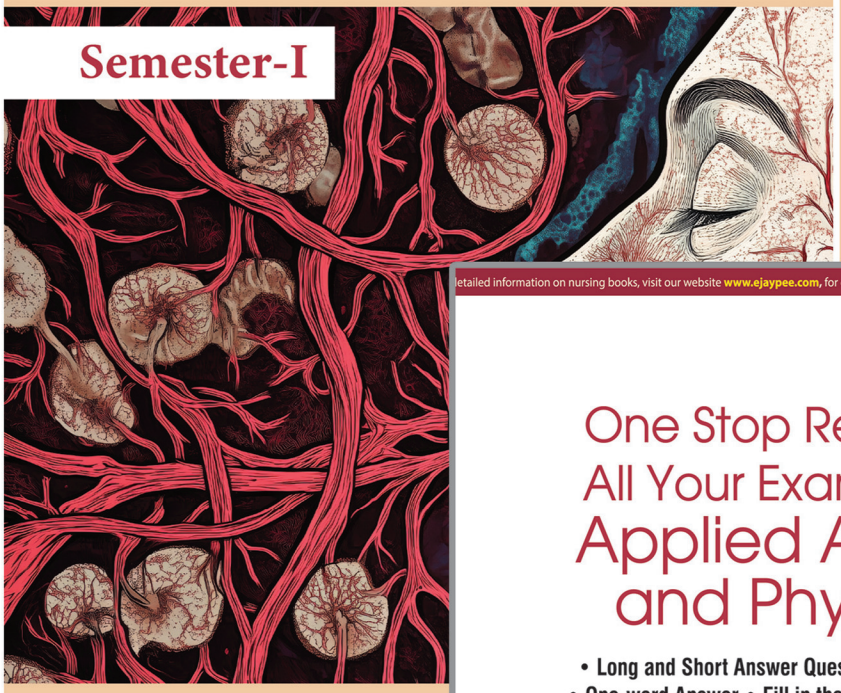

As per the Revised INC S

PR Ashalatha
G Deepa

tailed information on nursing books, visit our website www.ejaypee.com, for detailed information on nursing books, visit our website www.ejaypee.com,

Practice Workbook in Applied Anatomy and Physiology



Anatomy and Physiology for Nurses, 8e

5th Edition

JAYPEE

etailed information on nursing books, visit our website www.ejaypee.com, for detailed information on nursing books, visit our website www.ejaypee.com,

One Stop Resource for All Your Exam Needs in Applied Anatomy and Physiology

- Long and Short Answer Questions • Name the Following
- One-word Answer • Fill in the Blanks • True/False • MCQs

Semester-I



Complimentary to Textbook of Applied Anatomy and Physiology for Nurses, 8e

PR Ashalatha
G Deepa

JAYPEE

Contents

Quick Scan ..... *xxvii*

SECTION 1: Body and its Constituents



Chapter 1: Introduction to Anatomy and Physiolotgy 3

Introduction 3; Anatomy 3; Physiology 4;
Basic Anatomical Terminology 4; Anatomical Position 4; Anatomical Planes 4; Terminology 6;
Levels of Organization and Organ Systems of Body 10; Level of Organization 10;
Organ Systems of Body 11; Integumentary System 11; Skeletal System 11; Muscular System 12; Nervous System 12; Endocrine System 13; Urinary System 13; Cardiovascular System 14; Lymphatic System 14; Respiratory System 15 Digestive System 15; Female Reproductive System 16;
Skeleton 16 Male Reproductive System 16; Axial Skeleton 17; Appendicular Skeleton 18;
Cavities of the Body 19; Cranial Cavity 19; Thoracic Cavity 19; Abdominopelvic Cavity 20;
Composition of Body 22 Homeostasis 22; Components of Homeostatic System 23

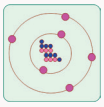

Chapter 2: Introduction to Chemistry of Life 26

Introduction to Chemical Basis of Life 26; Water 26; Carbohydrates 26; Proteins 27; Fats and Fatty Acids 28; Vitamins 29; Minerals 29; Source of Energy 30 Isotopes 30

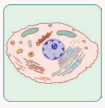

Chapter 3A: Organization of Human Body: Cell Level 33

Cell 33; Structure of A Cell 33;
Transport Across Cell Membrane 41; Basic Mechanism of Transport 42



Chapter 3B: Organization of Human Body: Tissue Level 45

Primary Tissues 45; Classification 45; Epithelial Tissue (Epithelium) 45; Classification of Epithelia 46; Glands 52; Connective Tissue 55; Special Connective Tissue 60; Muscular Tissue 62; Nervous Tissue 62; Supporting Tissues 62

SECTION 2: Organ Systems



Chapter 4: Respiratory System 67

Exchange of Gases 67; Air Passages 67; Nose and Paranasal Sinuses 67; Pharynx 72; Larynx 72; Trachea 76; Tracheobronchial Tree 77; Lungs 79; Pleura and Pleural Cavity 85; Physiology of Respiration 86; Ventilation 88; Gaseous Exchange In Lungs 89; Transport of Gases Between Lungs and Tissues 89; Regulation of Respiration 91; Nervous Control of Respiration 91

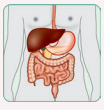

Chapter 5: Digestive System 96

Process of Digestion 96; Innervation of Gastrointestinal Tract 97; Parts of Digestive System 97; Pharynx 104; Salivary Glands 107; Saliva 111; Gut 112; Esophagus 112; Stomach 114; Small Intestine 120; Duodenum 121; Large Intestine 127;
Accessory Organs of Digestion 132; Liver 132; The Peritoneum 138; Gastrointestinal Hormones 146



Chapter 6A: Circulatory System: Heart 150

Heart 151; Electrocardiogram (ECG) 163; Cardiac Output 164; Arterial Blood Pressure 167

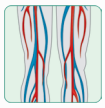

Chapter 6B: Circulatory System: Blood Vessels 172

Blood Vessels 172; Arteries 172; Veins 174; Exceptions 174; Aorta 174;
Blood Circulation of Head and Neck 178; Arterial Supply 178; Venous Drainage 180;
Blood Circulation of Upper Limb 184; Arterial Supply 184; Venous Drainage 186;
Blood Circulation of Thorax 187; Arterial Supply 187; Venous Drainage 187;
Blood Circulation of Abdomen 188; Arterial Supply 188; Celiac Trunk 188; Venous Drainage 189;
Portal Circulation 190; Portal Vein 190;
Blood Circulation of Pelvis and Lower Limb 191; Arterial Supply 191 Venous Drainage 194;
Fetal Circulation 195; Congenital Anomalies 197; Clinical Applications 197



Chapter 7: Blood 198

Erythrocytes (Red Blood Cells) 202; Leukocytes (White Blood Cells) 212;
Thrombocytes (Platelets) 215; Blood Groups 218; Blood Transfusion 220



Chapter 8: Lymphatic System 221

Lymph 221; Lymph Vessels 221; Lymphatic Tissue and Organs 223; Major Lymphatics of Body 225;
Spleen 228; Tonsil 230; Thymus 231



Chapter 9: Resistance and Immunity 234

Immunity 234; Classification of Immunity 234; Nonspecific Defense Mechanisms/Innate
Immunity 235; Humoral Immunity 236; Cell-Mediated Immunity 238



Chapter 10: Endocrine System 241

Hormone 242; Hypothalamus 243; Hypophysis Cerebri or Pituitary Gland 243; Thyroid Gland
(Thyroid = Shield-Like) 250; Hormones Regulating Calcium Metabolism 255;
Parathyroid Glands 256; Suprarenal or Adrenal Glands 258; Pancreas 263; Glossary 265

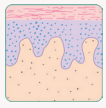

Chapter 11: Skin and Temperature Regulation 266

Skin 266; Structure of Skin 266; Types of Skin 267; Blood Supply 268; Nerve Supply 269;
Functions of Skin 269;
Appendages of Skin 269; Hair 269; Sebaceous Glands 271; Sweat Glands 271; Nails 272;
Receptors of Skin 272;
Temperature Regulation 272 Sources of Body Heat 273; Channels of Heat Loss 273; Mechanisms
Activated by Heat 273; Mechanisms Activated by Cold 274



Chapter 12: Sensory Organs 275

Sense of Smell or Olfaction 275; Mechanism 275; Olfactory Pathway 275;
Sense of Taste 276; Taste Pathway 277;
Sense of Hearing 277; External Ear 277; Middle Ear 279; Internal Ear 281;
Physiology of Hearing 284; Balance and Ear 286;
Sense of Vision 286; Living Eye 286; Eyebrows 286; Eyelids or Palpebrae 286;
Lacrimal Apparatus 287; Muscles of the Eyeball 287; Eye 288; Lens 292; Visual Processes 293;
Field of Vision 294; Visual Pathway 295; Color Vision or Chromatic Vision 297



Chapter 13A: Musculoskeletal System: Muscular System 299

Classification of Muscles 299; Skeletal Muscle 300; Cardiac Muscle 307; Smooth
Muscle 308; Distribution 309;
Muscles of the Body 309; Muscles of the Head 309; Muscles of the Neck 311; Muscles of the
Trunk 313; Muscles of Shoulder Girdle and Upper Limb 319; Muscles of the Lower Limb 328



Chapter 13B: Musculoskeletal System: Skeletal System 336

Bone 336; Osteology 336; Number of Bones 336; Classification 336; Gross Structure 337; Skeleton 347; **Axial Skeleton 349;** Skull 349; Individual Skull Bones 355; Skeleton of Thorax (Thoracic Cage) 361; Appendicular Skeleton 369; Upper Arm (Arm or Brachium) 372; Pelvic Girdle and Lower Limb 377



Chapter 13C: Musculoskeletal System: Joints 388

Joints 388; Joints of Upper Limb 391; Joints of Hands and Fingers 397; Joints of Lower Limb 398; Retinacula Related to Joints 407



Chapter 14: Renal System 410

Parts of Urinary System 410; Functions of Urinary System 410; Kidneys (Renes; Nephros) 411; Physiology of Urine Formation 418; Glomerular Filtration 418; Tubular Reabsorption 419; Urine 421; Water Balance 422; Ureters 423; Urinary Bladder 425; Urethra 426 Radiological Anatomy of Urinary System 427; Micturition 427



Chapter 15: Reproductive System 432

Female Reproductive System 432; External Genital Organs (Vulva) 432; Internal Genital Organs 434; **Physiology of Female Reproductive System 444;** Puberty 444; Mammary Gland or Breast 449; **Male Reproductive System 452;** Penis (L. Tail) 453; Scrotum 454; Testes (Singular—Testis) 454; Epididymis 456; Spermatic Cord 456; Vas Deferens Or Ductus Deferens 457; Seminal Vesicles 457; Ejaculatory Ducts 457; Prostate Gland 457; **Physiology of Male Reproductive System 458;** Control of Testicular Function 458; Spermatogenesis 459; Structure of Spermatozoon (Sperm) 459; Semen or Seminal Fluid 460; Puberty in Males 460; Pregnancy 460; Functions of Placenta 460; Diagnostic Tests for Pregnancy 461; Physiological Changes During Pregnancy 461; Lactation 462; Contraception 462



Chapter 16: Nervous System 464

Divisions of Nervous System 464; Tissues Constituting the Nervous System 465; Neurons 465; Nerves 467;
Synapse 473; Classification of Synapse 473; Structure of a Typical Chemical Axodendritic Synapse 473;
Neurotransmitters 474; Classification of Neurotransmitters 474;
Central Nervous System 475 Meninges 475;
Ventricles of the Brain and Cerebrospinal Fluid 477; Lateral Ventricles 478; Third Ventricle 478; Fourth Ventricle 478; Choroid Plexuses 478; Cerebrospinal Fluid (CSF) 478;
Brain 480; Internal Capsule 483; Basal Nuclei (Ganglia) 484; Functional Areas of Cerebral Cortex 486; Functions of Cerebrum 488;
Diencephalon 489; Subdivisions 489; Thalamus 489; Hypothalamus 491;
Brainstem 492; Midbrain 492; Pons (Bridge) 493; Medulla Oblongata 494; Reticular Formation 495; Cerebellum (Little Brain) 495;
Blood Supply of Brain 497; Arteries Supplying the Brain 497; Vertebrobasilar Arteries 498; Internal Carotid Artery 498; Venous Drainage 498;
Spinal Cord 498; External Features 499; Internal Structure of Spinal Cord 499; Blood Supply 502;
Reflexes 503; Classification of Reflexes 503;
Tracts of Spinal Cord and Brainstem 505; Ascending Tracts 505; Dorsal (Posterior) Column Tract or Fibers 506; Anterior (Ventral) Spinothalamic Tract 506; Lateral Spinothalamic Tract 507; Descending Tracts of Spinal Cord 507; Extrapyramidal Spinal Tracts 510;
Cranial Nerves 513; Olfactory Nerve—CN I 513; Optic Nerve—CN II 514; Oculomotor Nerve—CN III 514; Trochlear Nerve—CN IV 515; Trigeminal Nerve—CN V 515; Abducent Nerve—CN VI or Abducens 516; Facial Nerve—CN VII 516; Vestibulocochlear—CN VIII 518; Glossopharyngeal Nerve—CN IX 518; Vagus Nerve—CN X 519; Accessory Nerve—CN XI 519; Hypoglossal Nerve—CN XII 520; Nervi Terminalis—CN XIII 520; Summary of Cranial Nerves 520; Spinal Nerves 521; Nerve Plexuses 522; Brachial Plexus 522; Musculocutaneous Nerve (C5–7) 524; Median Nerve or "Laborer's Nerve" 524; Ulnar Nerve 525; Radial Nerve 525; Axillary Nerve 526; Lumbar Plexus 526; Femoral Nerve 526; Obturator Nerve 526; Sacral Plexus 527; Sciatic Nerve 527;
Autonomic Nervous System 528; Subdivisions of Autonomic Nervous System 528

Section 3: Genetics



Chapter 17: Introduction to Genetics 535

Chromosomes 535; Basic Structure of DNA 538; Protein Synthesis 539; Cell Division 541; **Genetic Basis of Inheritance 543;** Dominant Inheritance 543; Recessive Inheritance 544; Sex-linked Inheritance 544

Section 4: Nutrition

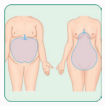

Chapter 18: Introduction to Nutrition 555

Importance of Food in Health and Disease 555; Classification of Food 556; Basal Metabolic Rate 556; Specific Dynamic Action 557; Energy Requirement by Adults 557; Energy Balance 557; Balanced Diet 557; Nutritional Disorders 557; Lifestyle Diseases 561

Appendices 563

Appendix 1: Memory Joggers!! 563
Appendix 2: Normal Values 565
Appendix 3: Common Prefix, Suffix, and Root 573
Appendix 4: Important Terms Used for Bones 574
Appendix 5: Largest and Smallest 575
Appendix 6: Alternative Names of Organs 576
Appendix 7: Different Types of Cells in Human Body 577
Appendix 8: Different Plexuses 578
Appendix 9: Neurotransmitters 578
Appendix 10: Regions of Brain and Their Functions 578
Appendix 11: Dissection 579
Photos of Specimens Obtained During Autopsy 584

Glossary 587

Index 593

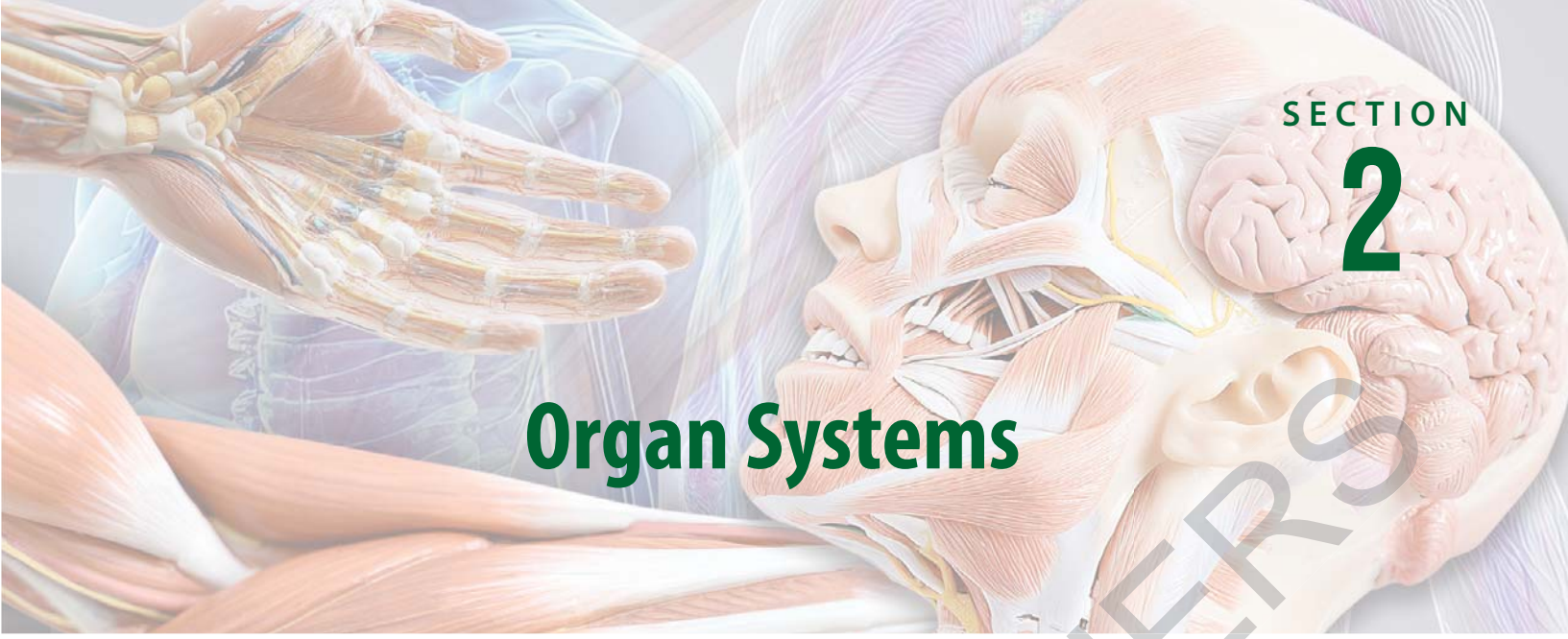

SECTION

2

Organ Systems

JAYPEE BROTHERS

Section Outline

4. Respiratory System
5. Digestive System
6A. Circulatory System: Heart
6B. Circulatory System: Blood Vessels
7. Blood
8. Lymphatic System
9. Resistance and Immunity
10. Endocrine System
11. Skin and Temperature Regulation
12. Sensory Organs
13A. Musculoskeletal System: Muscular System
13B. Musculoskeletal System: Skeletal System
13C. Musculoskeletal System: Joints
14. Renal System
15. Reproductive System
16. Nervous System

JAYPEE BROTHERS

CHAPTER 4

Respiratory System

CHAPTER AT A GLANCE

- Exchange of Gases
- Air Passages
- Nose and Paranasal Sinuses
- Physiology of Nose
- Pharynx
- Larynx
- Trachea
- Tracheobronchial Tree
- Lungs
- Pleura and Pleural Cavity
- Physiology of Respiration
- Pulmonary Function Tests
- Gas Exchange in Lungs
- Transport of Gases between Lungs and Tissues
- Regulation of Respiration

Learning Objectives

- Describe the structure of respiratory system
- Identify the muscles of respiration and examine their contribution to the mechanism of breathing
- Describe the physiology and mechanism of respiration

JAYPEE BROTHERS

INTRODUCTION

The essential features of respiration are the transference of:

- Oxygen from the atmosphere to the tissues
- Carbon dioxide from the tissues to the air.

EXCHANGE OF GASES

There are two phases in the exchange of gases:

1. External respiration
2. Internal respiration.

External Respiration

The ***external respiration*** takes place in the lungs. The oxygen is absorbed from air into the blood and CO_2 is excreted from the blood into the air.

Internal Respiration

The ***internal respiration*** or tissue respiration: O_2 is transferred from blood to the tissues, which give up CO_2.

AIR PASSAGES (FIG. 4.1)

The organs of respiratory system air passages are:

- Nose
- Pharynx
- Larynx
- Trachea
- Bronchi (two in number)
- Bronchioles

NOSE AND PARANASAL SINUSES

The nose has two functions to perform. These are:

1. It is a part of the respiratory passage
2. It has the olfactory function or the sense of smell.

External Nose (Fig. 4.2)

External nose forms a pyramidal projection in the middle of the face. It presents with the following features:

- ***Tip (or apex):*** It is the lower free end of the nose
- ***Root:*** The upper narrow part attached to the forehead is the root of nose.
- ***Dorsum of the nose:*** It is formed by a rounded border between the tip and root of nose along with the adjoining area.
- ***Nostrils or anterior nares:*** These are two piriform-shaped apertures present at the broad lower part of the nose.

Structure

External nose is made up of cartilaginous framework supported by bones and is covered with skin.

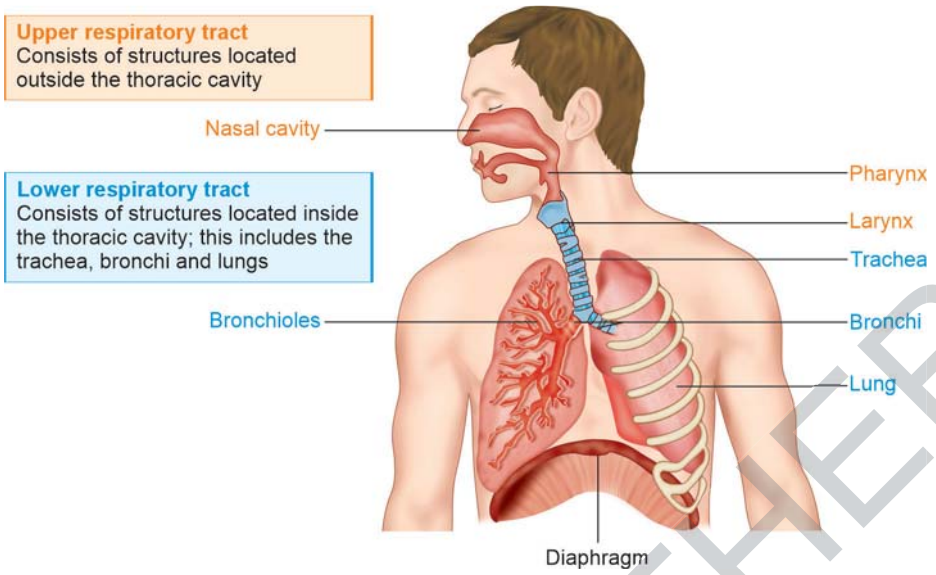

Fig. 4.1: Air passages (schematic representation).

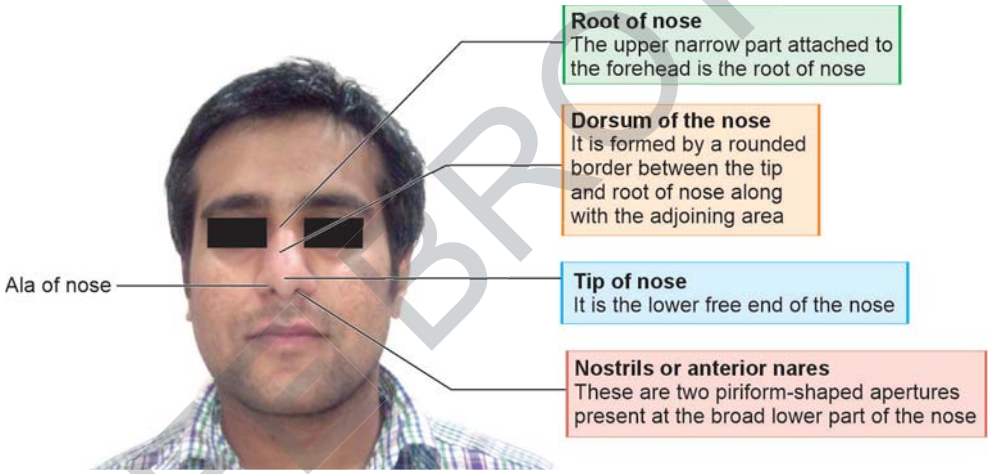

Fig. 4.2: External features of nose.

- The bony framework comprises of:
  - Two nasal bones, forming the bridge of the nose.
  - Frontal processes of maxillae.
- The cartilaginous framework comprises of five main cartilages and several additional tiny ones. The five main cartilages are:
  - Two lateral alar cartilages, one upper and one lower
  - Two major alar cartilages: Each major alar cartilage comprises of a medial and a lateral crus.
  - A single median septal cartilage.

Nasal Cavity

It is pyramidal in shape. It extends from the nostrils (anterior nares) to the posterior nasal apertures (choanae). The nasal cavity is divided into right and left halves by a median septum.

Subdivisions

- ***Vestibule:*** Vestibule is the dilated part, just inside the anterior nasal opening. There are numerous coarse hairs called ***vibrissae***, which help to filter the air.
- ***Olfactory region:*** The upper one-third of nasal cavity has the olfactory receptor cells. The mucosa is yellowish in color.
- ***The respiratory region:*** The lower two-third of nasal cavity is lined by thick mucous membrane; it is highly vascular. It is lined by pseudo-stratified ciliated columnar epithelium.

Boundaries

Each half of the nasal cavity has a roof, a floor, a medial wall and a lateral wall. Each half measures about 5 cm in height, 5–7 cm in length (anteroposterior), 1.5 cm in width (floor) and 1–2 mm at the roof.

The ***roof*** is mainly formed by the cribriform plate of the ethmoid bone. Anteriorly, the roof is formed by the nasal bone and nasal part of the frontal bone; posteriorly, the roof is contributed by the body of the sphenoid bone.

The floor is formed by the palate, which separates the nasal cavity from the oral cavity.

JAYPEE BROTHERS

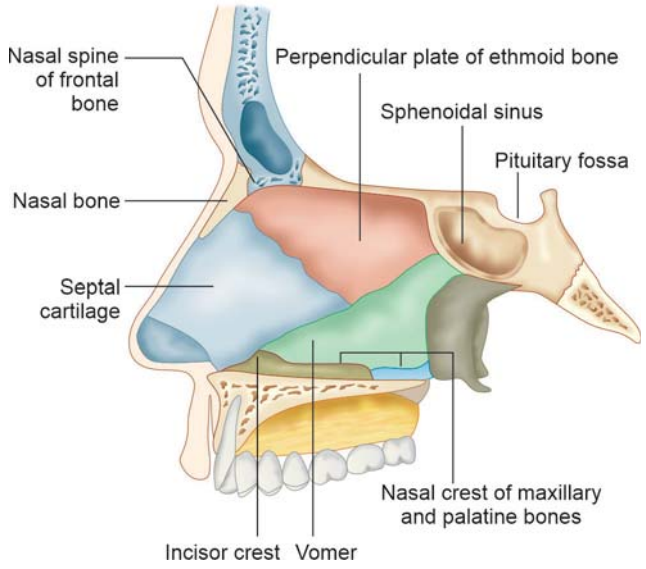

Fig. 4.3: Nasal septum (schematic representation).

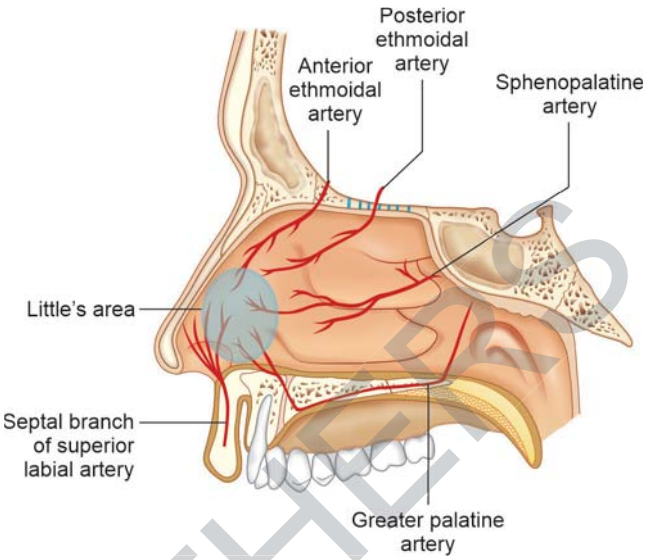

Fig. 4.4: Arterial supply of the nasal septum (schematic representation).

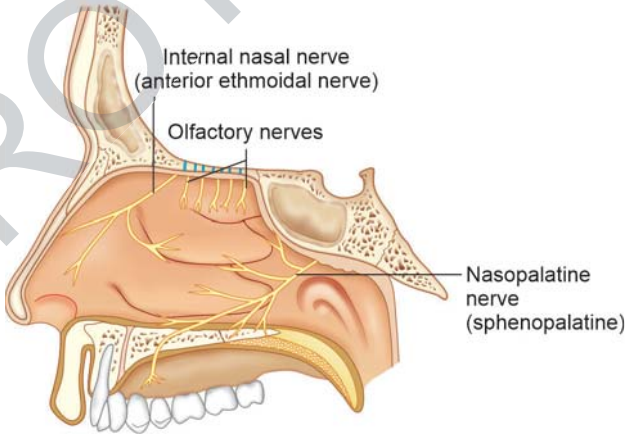

Fig. 4.5: Nerve supply of the nasal septum (schematic representation).

Medial Wall or the Nasal Septum (Fig. 4.3)

It is a median, osteocartilaginous partition between the two halves of the nasal cavity. It is covered on either side by mucous membrane (which is adherent to the underlying periosteum or perichondrium, forming mucoperiosteum or mucoperichondrium).

Components

- ***The bony part:*** The bony part of the nasal septum is formed mainly by the vomer and the perpendicular plate of the ethmoid bone.
- ***The cartilaginous part:*** It is formed by (1) the septal cartilage and (2) septal processes of inferior nasal cartilages.
- ***The cuticular part:*** The cuticular part is formed by fibrofatty connective tissue covered by skin. The lower margin of the septum is called the columella.

Arterial Supply (Fig. 4.4)

The septum is supplied by branches of anterior ethmoidal artery, posterior ethmoidal artery (branches of ophthalmic artery), the superior labial branch of facial artery, the sphenopalatine artery and greater palatine artery.

Key Points

At the anteroinferior quadrant, there is a rich anastomosis between the septal branches of superior labial artery, anterior ethmoidal artery, posterior ethmoidal artery and the branches of sphenopalatine artery. This area called the ***Little's area or Kiesselbach's area*** is a common site of epistaxis (bleeding from nose).

The corresponding veins drain into the facial vein and the pterygoid venous plexus.

Nerve Supply (Fig. 4.5)

The nasal septum gets its nerve supply from:

- Olfactory nerves
- Anterior ethmoidal nerve
- Nasopalatine nerve.

APPLICATION AND IMPLICATION IN NURSING

- ***Deviated nasal septum (DNS)*** refers to a condition where the nasal septum is not median but deflected or deviated to one side, more often to the right side. This condition may be symptomless or may lead to symptoms of nasal obstruction. It may require surgical correction.
- ***Saddle nose*** refers to a condition where the nasal dorsum is depressed (sagging of the bridge of nose). Depressed nasal dorsum may involve either bony, cartilaginous or both bony and cartilaginous components. Most common etiology is nasal **trauma.** It is also associated with **Down's syndrome.**

Lateral Wall of Nose

The lateral wall of the nose is irregular, owing to the presence of three shelf-like bony projections called "conchae" (L. shells) or "turbinates" **(Fig. 4.6A)**.

These elevations are called superior, middle and inferior nasal conchae according to their position on the lateral wall of the nasal cavity.

JAYPEE BROTHERS

The superior and middle conchae are parts of the ethmoid bone; the inferior concha is an independent (separate) bone.

The inferior and middle conchae project medially and inferiorly producing air passages called the inferior and middle meatus (L. passage) below them.

Below the short superior concha, lying hidden is the superior meatus.

The space posterosuperior to the superior concha is called the sphenoethmoidal recess. The sphenoidal air sinus opens in the sphenoethmoidal recess.

Superior Meatus

The superior meatus is a narrow passage between the superior and middle conchae. The posterior ethmoidal sinuses open into the superior meatus **(Fig. 4.6B)**.

Middle Meatus

- The middle meatus is a longer and wider passage between the middle and inferior meatus.
- There is a funnel-shaped opening in its anterosuperior part called the infundibulum.
- The frontal sinus opens into the infundibulum through a narrow frontonasal duct **(Fig. 4.6B)**.
- There is a rounded elevation lying in the middle meatus, under cover of middle concha, called the bulla ethmoidalis ("bubble").
- The middle ethmoid sinuses open on the surface of the bulla **(Fig. 4.6B)**.
- Inferior to the bulla is a semicircular groove called the hiatus semilunaris.
- The maxillary sinus and the anterior ethmoidal sinuses open here.

Inferior Meatus

The inferior meatus lies underneath the inferior concha.

- It is the largest of the three meatuses.
- The nasolacrimal duct opens into this meatus anteriorly.
- It is guarded by a mucosal fold called the ***valve of Hasner***.

Table 4.1: Openings of nasal meatuses.

Meatus	*Opening*
Superior meatus	Posterior ethmoidal sinuses
Middle meatus	Frontal sinus Maxillary sinus Anterior and middle ethmoidal sinuses
Inferior meatus	Nasolacrimal duct

Note: Openings in different meatuses of lateral wall of nasal cavity are described in **Table 4.1.**

Blood Supply

The lateral wall has a rich arterial supply from anterior ethmoidal artery and branches of maxillary artery.

Nerve Supply

Most of the nerves are branches of the trigeminal nerve; the upper one-third is olfactory in function.

Histology of Internal Nose

LINING OF INTERNAL NOSE

- ***Skin:*** Vestibule is lined by skin (stratified squamous epithelium), which contains **hair**, hair follicles and sebaceous glands. The hairs are called vibrissae because they keep on vibrating due to passage of air. They help in filtering the inhaled air
- ***Olfactory epithelium:*** The olfactory epithelium which is pale in color, lines the olfactory region. The olfactory region includes roof of nasal cavity and area above superior concha.
- ***Respiratory mucosa:*** The respiratory mucous membrane, which covers the lower two-third of the nasal cavity, shows variable thickness. It is thickest over nasal conchae, especially at their ends. It is thick over the nasal septum and thin in the meatuses and floor of the nose. This respiratory mucous membrane is pseudostratified ciliated columnar epithelium and contains plenty of goblet cells. It is highly vascular.

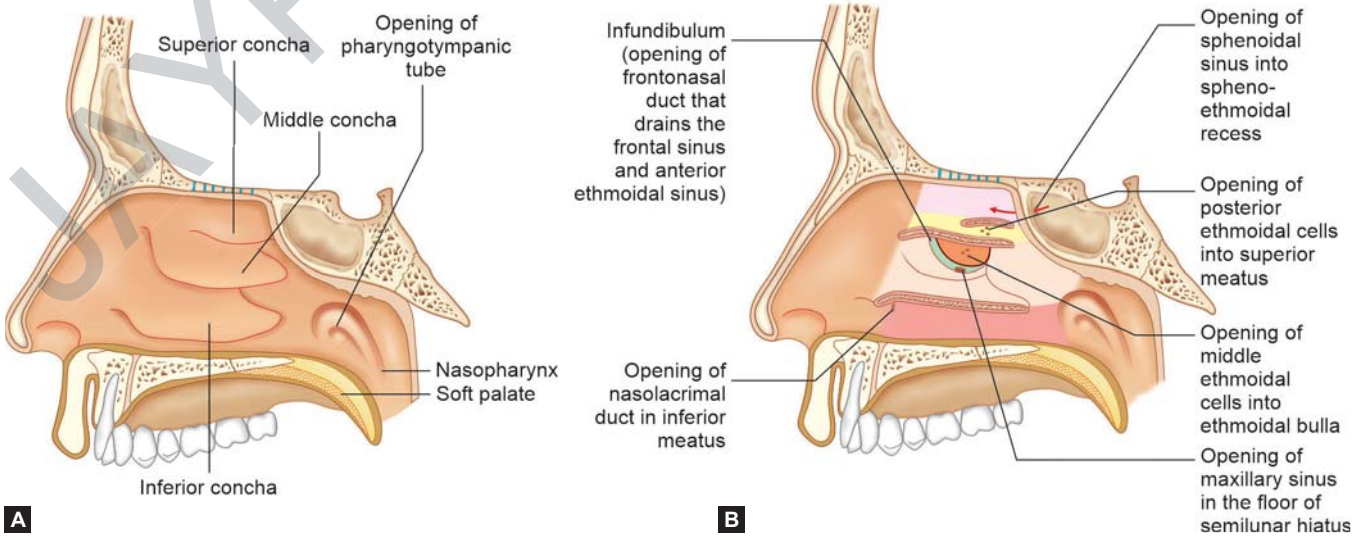

Figs. 4.6A and B: A. Lateral wall of nasal cavity showing conchae; B. Lateral wall of nasal cavity showing meatuses (schematic representation).

JAYPEE BROTHERS

Openings into the Nasal Cavity

The nasal cavity receives the following openings:

- The anterior nares or nostrils which connect nasal cavity to the exterior.
- The posterior nares which connect the nasal cavity to the pharynx.
- The paranasal sinuses.

Paranasal Air Sinuses

These are air-filled extensions of the respiratory part of the nasal cavity into the skull bones. They are named according to the bones in which they are situated:

- ***Frontal air sinus:*** This large air sinus is situated in the frontal bone.
- ***Ethmoidal air sinuses:*** These are the numerous air-filled cavities situated inside the ethmoid bone. They are divided into three groups—anterior, middle and posterior.
- ***Maxillary (air) sinus:*** It is the largest among the air sinuses.
- ***Sphenoidal (air) sinus:*** It is a cubical cavity within the body of the sphenoid. This sinus opens into the sphenoethmoidal recess of the nasal cavity.
- All of these open into the nasal cavity through its lateral wall. The sinuses are lined by pseudostratified ciliated columnar epithelium. The mucous membrane of sinuses is continuous with the mucous membrane of the nasal cavity.

Key Points

- The sinuses are absent or rudimentary at birth. They attain full size only after puberty.
- The paranasal air sinuses (PNS) are entirely different from dural venous sinuses.
- PNS contains air. Dural venous sinuses are situated between the two layers of dura contain venous blood.

Functions (Flowchart 4.1)

- They reduce the weight of the skull
- The inhaled air is warmed and humidified
- They add resonance to the voice
- The mucus secreted by the mucus glands helps to trap dust particles in the inhaled air; the cilia remove the dust particles.

Flowchart 4.1: Functions of paranasal sinuses.

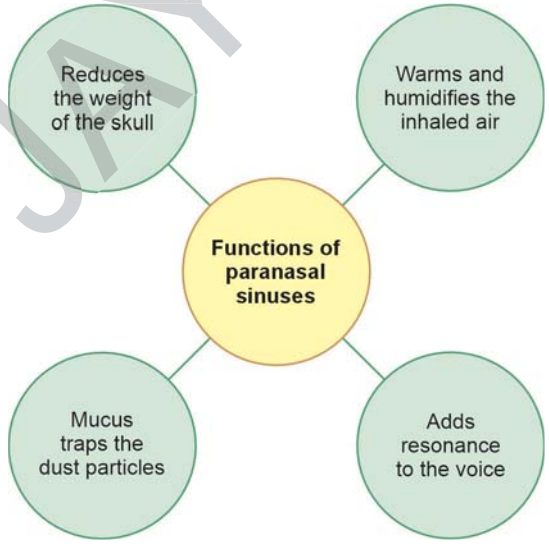

Blood Supply

The paranasal sinuses are supplied by the branches of both external carotid artery (facial artery and sphenopalatine branch of maxillary artery) and internal carotid artery (anterior and posterior ethmoidal branches of ophthalmic artery).

Nerve Supply

Paranasal sinuses are mainly supplied by branches of trigeminal nerve.

Development of Paranasal Sinuses

- The paranasal sinuses, which develop as out pouchings from the mucous membrane of nose, continue to grow during childhood and early adult life. At the time of birth, only the maxillary and ethmoidal sinuses are present.
- At birth, both frontal as well as sphenoid sinuses are absent and therefore, not clinically significant in young children.

APPLICATION AND IMPLICATION IN NURSING

- As all the paranasal sinuses are lined by mucosa, which is an extension of the mucosa of nasal cavity, infection may spread easily from nasal cavity to the sinuses, producing inflammation and swelling of the sinuses. This is called **sinusitis.**
- **The maxillary sinus** is the one **most commonly infected,** probably because its opening is situated superior to its floor. Similarly, infected material from the frontal and ethmoidal sinuses flows into the maxillary sinus.
- Infection from ethmoidal sinuses may spread to the orbit, because the medial wall of the orbit is thin and fragile (lamina papyracea). This can lead to orbital cellulitis or optic neuritis.
- Since the floor of the maxillary sinus and the roots of the maxillary molar teeth are very closely related, removal of the molar teeth may lead to the formation of a communication between the oral cavity and the maxillary sinus.
- The frontal air sinuses are closely related to the anterior cranial fossa and the orbit. Infection of the frontal sinus (frontal sinusitis) can lead to abscess formation in the frontal lobe of the brain and osteomyelitis of the frontal bone.

Physiology of Nose

Functions of Nose

- Respiration
- Air-conditioning of inspired air
- Protection of lower airway
- Vocal resonance
- Nasal reflex
- Olfaction

- ***Respiration:*** Humans are natural nose breathers. A newborn respires only with nose and, hence, when he has common cold, he feels irritated and is unable to sleep. Mouth breathing is learned later on in life. The nose also allows breathing during eating.

JAYPEE BROTHERS

- ***Air-conditioning of inspired air:*** Nose acts as an "air-conditioner" and filters, purifies, moistens and warms the inspired air for lungs. In 24 hours, we breathe 500 cubic feet of air. Air is efficiently filtered, humidified, adjusted to proper temperature and cleared of all the dust, bacteria and viruses by the nose.
- ***Protection of airway:***
  - ***Enzymes and immunoglobulins:*** They are present in nasal secretions. Muramidase (lysozyme) kills bacteria and viruses. Immunoglobulins (IgA and IgE) and interferon provide immunity against upper respiratory tract infections.
  - ***Sneezing:*** Foreign particles and irritating nasal mucosa are expelled by this protective reflex. Copious flow of nasal secretions (due to irritation) washes noxious substance out.
- ***Vocal resonance:*** Nose acts as a resonating chamber for the speech. For phonating nasal consonants (M/N/NG), sound passes via nasopharynx and nose. When either nose or nasopharynx is blocked (rhinolalia clausa), speech becomes denasal and M/N/Ng are pronounced as B/D/G, respectively.
- ***Nasal reflexes:***
  Sneezing—irritation of nasal mucosa causes sneezing. If a finger is pressed under the columella, it may abort sneezing.
- ***Olfaction:*** Olfactory system is highly developed in animals and is important for their communication and survival and gives warnings of the environmental dangers. In humans, it is comparatively less developed but plays an important role in enjoying delicious and sumptuous food. The olfactory pathway has been discussed in detail in Chapter 12.

PHARYNX

It is described in detail in Chapter 5.

LARYNX

- The larynx is the organ for the production of voice. It also serves as an air passage.
- The larynx lies in the anterior midline of the neck, extending from the root of the tongue to the trachea. It lies opposite the third to sixth cervical vertebrae.

Dimensions

- ***Length***: 4.3 cm
- ***Transverse diameter***: 4.2 cm
- ***Anteroposterior diameter***: 3.6 cm
- The male larynx is larger than that in females.

Key Point

The cavity of the larynx is lined by respiratory epithelium, except the surface of vocal cord, which is lined by stratified squamous epithelium.

Skeleton (Cartilages) of Larynx (Figs. 4.7A and B)

The larynx has nine cartilages; three of them are unpaired and three paired.

Unpaired Cartilages

- Thyroid cartilage
- Cricoid cartilage
- Epiglottis.

Paired Cartilages

- Arytenoids
- Corniculate
- Cuneiform.

Thyroid Cartilage

- It is the largest of the laryngeal cartilages.

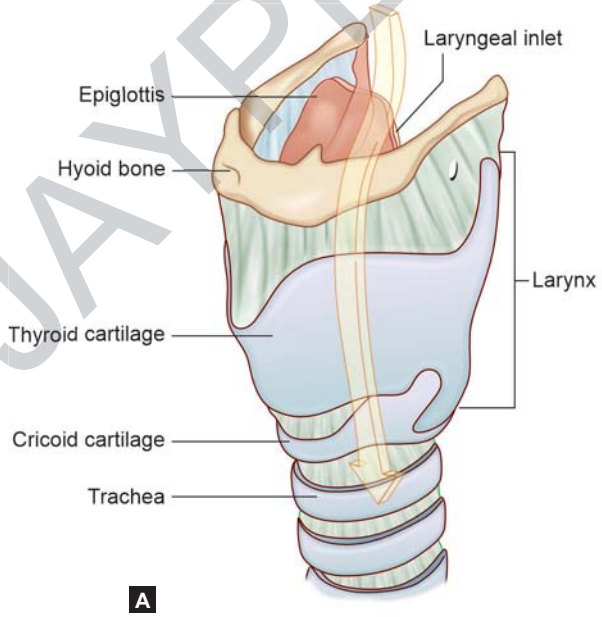

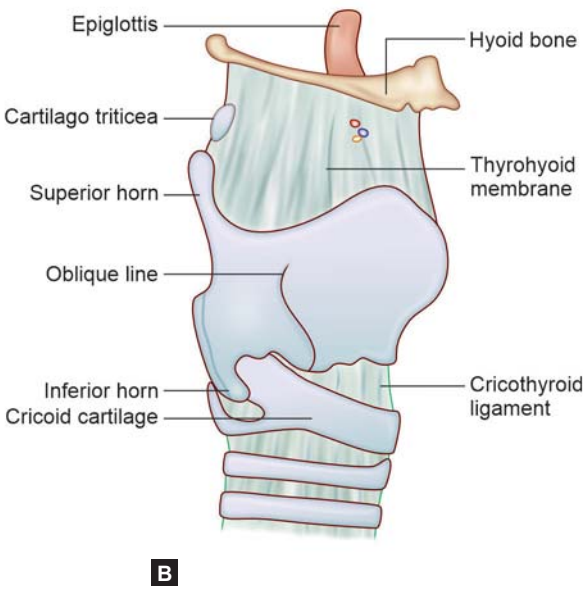

Figs. 4.7A and B: Cartilages of larynx (schematic representation).

JAYPEE BROTHERS

Table 4.2: Different types of cartilages in larynx.

Types of cartilage	*Example*
Hyaline cartilage	• Thyroid cartilage • Cricoid cartilage • Arytenoid cartilage
Elastic fibrocartilage	• Epiglottis

- It is a hyaline cartilage **(Table 4.2).**
- The cartilage is made of two quadrangular plates.
- The anterior borders of the two plates are united in their lower parts at an angle, which forms a prominence in the middle of the neck, called the ***laryngeal prominence or Adam's apple***.
- It is more prominent in males.
- In the upper part, the anterior borders are separated by a thyroid notch.
- The posterior borders extend superiorly as the superior horns; and inferiorly as the inferior horns **(Fig. 4.7B)**.
- To the upper border, the thyrohyoid ligament is attached.
- The outer surface of the lamina presents an ***oblique line*** which gives attachment to strap muscles, inferior constrictor muscle of pharynx and pretracheal fascia.

Applied Anatomy

Cricoid pressure, also known as the **Sellick manoeuvre or Sellick maneuver,** is a technique used in endotracheal intubation to try to reduce the risk of regurgitation.

The technique involves the application of pressure to the cricoid cartilage at the neck, thus occluding the esophagus which passes directly behind it.

Key Point

The anterior part of the epiglottis is lined with stratified squamous epithelium like the oral cavity and pharynx; the posterior part with ciliated columnar epithelium like the trachea.

Cricoid Cartilage

- It resembles a signet ring.
- It consists of a posterior quadrilateral lamina and an anterior arch.
- It is also a hyaline cartilage and is lined with ciliated columnar epithelium internally.

Epiglottis

- It is a leaf-shaped elastic cartilage. Its lower end is narrow and attached to the inner surface of the thyroid cartilage by a ligament **(Fig. 4.7A).**
- The upper end is broad and free. Its anterior surface overhangs the posterior part of the dorsum of the tongue.
- It is covered anteriorly with stratified squamous epithelium and posteriorly with respiratory epithelium.
- It acts like a lid for the larynx and closes off the larynx during swallowing; thus protecting the lungs from accidental inhalation of food.

Arytenoid Cartilages

- These are placed on the upper border of the lamina of the cricoid cartilage. Each arytenoid is pyramidal in shape.
- It gives attachment to the vocal cords and is lined by ciliated columnar epithelium.
- **Corniculate** and **cuneiform** cartilages are small cartilages, lying within the aryepiglottic folds.

Ligaments of Larynx

The ***extrinsic ligaments*** connect the cartilages.

- The ***intrinsic ligaments*** lie beneath the mucous membrane of the larynx
- In the upper part, it is called ***the quadrangular membrane and***, in the lower part, it is called ***the conus elasticus***.

Added Information

- The upper free border of the quadrangular membrane covered by mucous membrane is called the aryepiglottic fold.
- Its lower border is thickened and is called the *vestibular ligament*.
- With the mucosa covering it, it forms the false vocal cord or the vestibular fold **(Fig. 4.8)**.
- The upper border of conus elasticus is attached anteriorly to the deep surface of thyroid cartilage, near the midline; posteriorly, it is attached to the tip of the vocal process of the arytenoid.
- Between these attachments, the upper border is free; it is thickened to form the vocal ligament **(Fig. 4.8)**.

Cavity of Larynx

- It extends from the laryngeal inlet above, to the lower border of cricoid cartilage.
- Superiorly, it opens into the laryngeal part of pharynx and, inferiorly, it is continuous with the trachea.

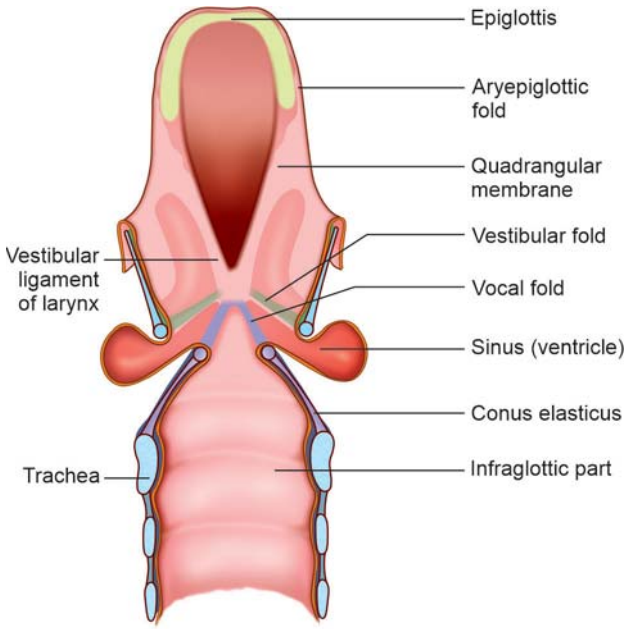

Fig. 4.8: Section through larynx showing its cavity and subdivisions (schematic representation).

JAYPEE BROTHERS

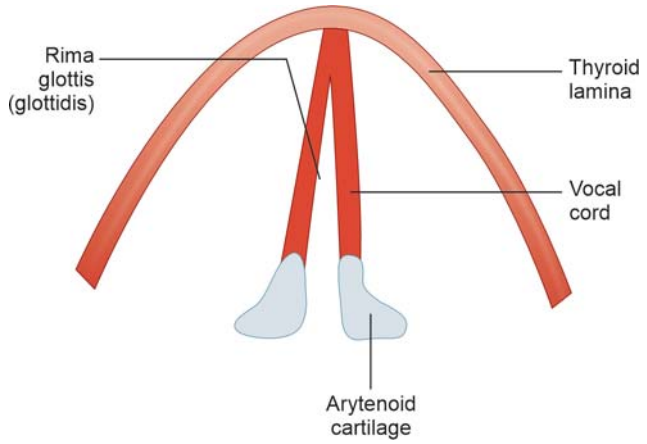

Fig. 4.9: Attachments of vocal cord (schematic representation).

- The interior is lined by mucous membrane.
- Two pairs of folds project into the cavity from the lateral walls.
- The upper pair of folds are the vestibular folds or the false vocal cords.
- The gap or fissure between them is called the rima vestibuli.

The lower pair of folds are the true vocal cords and the fissure between them is the rima glottis (glottidis) **(Fig. 4.9)**.

Added Information

CAVITY OF LARYNX (FIG. 4.8)

The cavity of the larynx is divided into three parts:

1. Vestibule
2. Sinus of the larynx
3. Infraglottic part.

Vestibule

It extends from the inlet of the larynx up to the vestibular folds.

Sinus or the Ventricle of the Larynx

It is the smallest of the three parts of the larynx. It is situated between the vestibular folds and the vocal folds.

Infraglottic Part

It extends from the level of true vocal folds to the beginning of the trachea.

Table 4.3: Differences between vocal fold and vestibular fold.

Features	*Vocal fold*	*Vestibular fold*
Color	Pearly white	Pink
Epithelium	Stratified squamous nonkeratinizing	Pseudostratified ciliated columnar epithelium
Submucosa	Absent	Present
Components	Vocal ligament, vocalis muscle and mucosa	Mucosa, submucosa and vestibular ligament
Function	Phonation (production of voice)	Prevents entry of food particles into larynx. No role in phonation

Vocal Folds (Vocal Cords or True Vocal Cords) (Fig. 4.9)

- They are two wedge-shaped, pearly white folds of mucous membrane stretching from the angle of the thyroid cartilage to the vocal process of the arytenoid cartilages.
- The fissure between the vocal cords is called the rima glottis or rima glottidis.
- They are concerned with voice production.
- Their average length varies in males and females; in the male, it is about 23 mm and in the female, 17 mm.
- Each vocal cord consists of:
  - Vocal ligament
  - Vocalis muscle
  - Mucous membrane

Histology of Vocal Cord

- Mucosa of vocal cord is firmly adherent to the underlying structures.
- There are no submucosa and blood vessels.
- Hence, the vocal cords are **pearly white** in color.
- The surface epithelium is stratified squamous, nonkeratinizing.

The differences between vocal folds and vestibular folds are given in **Table 4.3.**

Muscles of Larynx (Figs. 4.10A and B)

Extrinsic Muscles

- They are attached to the skeleton of the larynx and the bones above it.

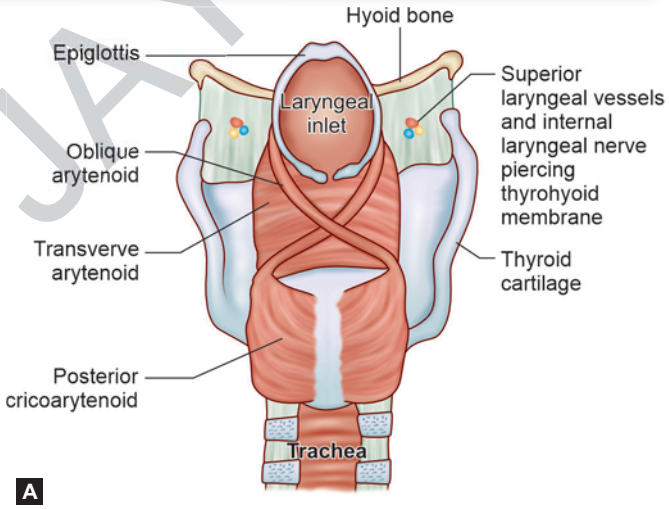

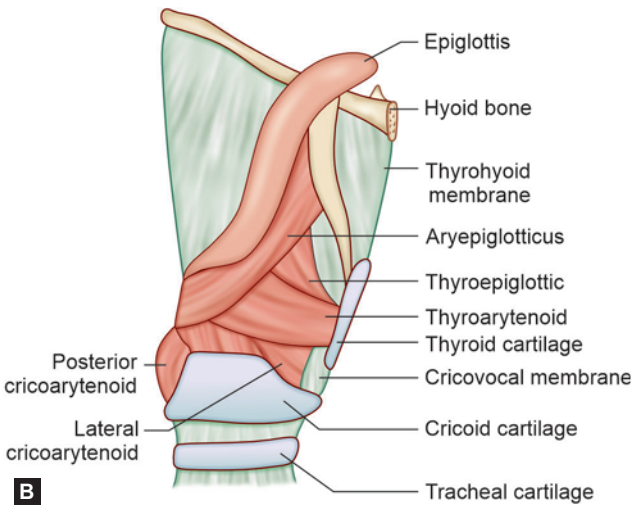

Figs. 4.10A and B: Muscles of larynx: A. Posterior aspect; B. Lateral aspect (schematic representation).

JAYPEE BROTHERS

- They move the larynx as a whole during respiration, deglutition, etc., and support the larynx
- Examples of extrinsic muscles are thyrohyoid, stylohyoid, omohyoid, geniohyoid and hyoglossus muscles.

Intrinsic Muscles

They are concerned with the movements of the vocal cords and, hence, are also concerned with the production of voice and respiration **(Flowchart 4.2)**.
They are:

- Cricothyroid
- Thyroarytenoid
- Vocalis.

Note: The **only** muscle which **abducts the vocal cord** is **posterior cricoarytenoid**, which is supplied by recurrent laryngeal nerve. Bilateral injury to recurrent laryngeal nerve would lead to an inability to abduct the vocal cords and hence difficulty in breathing.

- Posterior cricoarytenoid—the only abductor of vocal cord
- Lateral cricoarytenoid
- Transverse arytenoid
- Oblique arytenoid
- Aryepiglotticus
- Thyroepiglotticus.

Nerve Supply

Motor Supply

All the intrinsic muscles of larynx, **except** the cricothyroid, are supplied by **the recurrent laryngeal** nerves. The cricothyroid is supplied by the **external laryngeal nerve.**

Sensory Supply

The mucosa **above the vocal cords** is supplied by the **internal laryngeal nerve** and **below the vocal cords** by **recurrent laryngeal nerve.**

Blood Supply

Blood is supplied to the larynx by the superior and inferior laryngeal arteries and drained by the thyroid veins, which join the internal jugular vein.

Flowchart 4.2: Functions of intrinsic muscles.

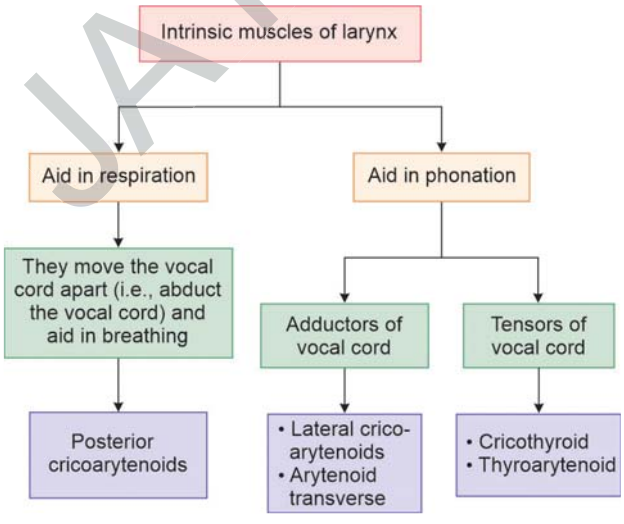

Functions of Larynx

The four main functions of larynx are *respiration, protection of lower respiratory tract, phonation* and *fixation of the chest*.

- *Protection of lower airways:* During swallowing, food entry into air passage is prevented by the closure of epiglottis. So, no food or vomitus can enter the larynx. Also, when food comes in contact with the oropharynx, reflex generated by afferent fibers of ninth nerve ceases the respiration temporarily.
  Cough reflex: Coughing dislodges and expels any foreign particle that comes in contact with respiratory mucosa. Larynx acts as a watchdog of lungs and immediately starts "barking" at the entry of any foreign body.
- *Phonation and speech:* Like a wind instrument, larynx produces voice. Vocal folds vibrate to create sound that is then modified. It is the laryngeal sound that is modified in the mouth. The vibration of the vocal cords produces sound, which is amplified by mouth, pharynx, nose and chest. The modulator action of lips, tongue, palate, pharynx and teeth converts the sound into speech.
  The air pressure produced by the lungs controls the intensity of sound. The frequency of vocal cord vibrations controls the pitch of sound.
- *Respiration:* The adduction of vocal cords during expiration and abduction of vocal cords during inspiration regulate the flow of air into the lungs.
- *Fixation of chest:* Closed larynx helps in the fixation of chest wall, which facilitates the action of various thoracic and abdominal muscles.
  This function plays an important role during digging, pulling and climbing, coughing, vomiting, defecation, micturition and childbirth.

APPLICATION AND IMPLICATION IN NURSING

- The term "glottis" refers to the vocal cords. The glottis is the part of the larynx most directly concerned with voice production. Rima glottis is the narrow part of larynx at the level of vocal cords. It is the usual place, where aspirated food or other "foreign bodies" become lodged, causing laryngeal obstruction. No air can enter the trachea, bronchi and lungs. Emergency treatment should be given to the patients to open the airway.
- The recurrent laryngeal nerve is vulnerable to injury during thyroidectomy. Injury to the nerve results first in the paralysis of abductors of the vocal cord than adductors (*Semon's law*).
  - When only one recurrent laryngeal nerve is paralyzed, phonation is possible, because the opposite vocal cord compensates for it.
  - When both recurrent laryngeal nerves are affected, phonation is completely lost; breathing also becomes difficult. The vocal cords lie in "cadaveric position" (in between adduction and abduction).
- When a foreign body enters the larynx, severe coughing is initiated to expel the object. But, when the internal laryngeal nerve is damaged, there is loss of sensation, and absence of the cough reflex. So, the foreign body can easily enter the larynx.
- The interior of the larynx can be examined directly through a laryngoscope (direct laryngoscopy) or indirectly through a mirror (indirect laryngoscopy).
- Hoarseness is the most common symptom of serious disorder of larynx, e.g., cancer of vocal cords.

Contd...

JAYPEE BROTHERS

Contd...

- Cancer of the larynx occurs between 40 and 60 years of age; males are 10 times more prone to cancer attack than females. 70% of growths arise from the vocal cords. Huskiness or hoarseness is the first symptom; it is progressive, and finally gives place to aphonia. Diagnosis is made by laryngoscopy and biopsy.
- **Heimlich maneuver (Fig. 4.11):** It is a first aid procedure, which every nursing student must practice on a mannequin. It helps in dislodging a foreign body obstructing the airway. A sudden strong thrust is applied on the abdomen of the choking person between the umbilicus and xiphoid process. Stand behind the person. Encircle your arms around the lower part of chest wall. Make a fist and keep it just below the xiphoid process. Cover the fist with the fingers of the other hand. Keep the back of the choking person pressed against your chest wall. Give a sudden thrust by pushing your hands into the diaphragm of the choking person.



Fig. 4.11: Abdominal thrusts—performing the Heimlich maneuver.

TRACHEA (FIG. 4.12)

The trachea or windpipe is a wide, fibrocartilaginous tube, about 11–12 cm long. Its upper half is situated in the neck and the lower part in the thorax.

Extent

It starts at the lower border of the cricoid cartilage (C6 vertebra) as the continuation of the larynx and ends at the level of the sternal angle (disc between T4 and T5, posteriorly) by dividing into right and left bronchi.

It is a tubular structure, with a flattened posterior wall.

Relations (Figs. 4.12 and 4.13)

Upper cervical part

- ❖ Anteriorly:
  - – Isthmus of the thyroid lies on the 2nd, 3rd and 4th tracheal rings **(Fig. 4.13)**

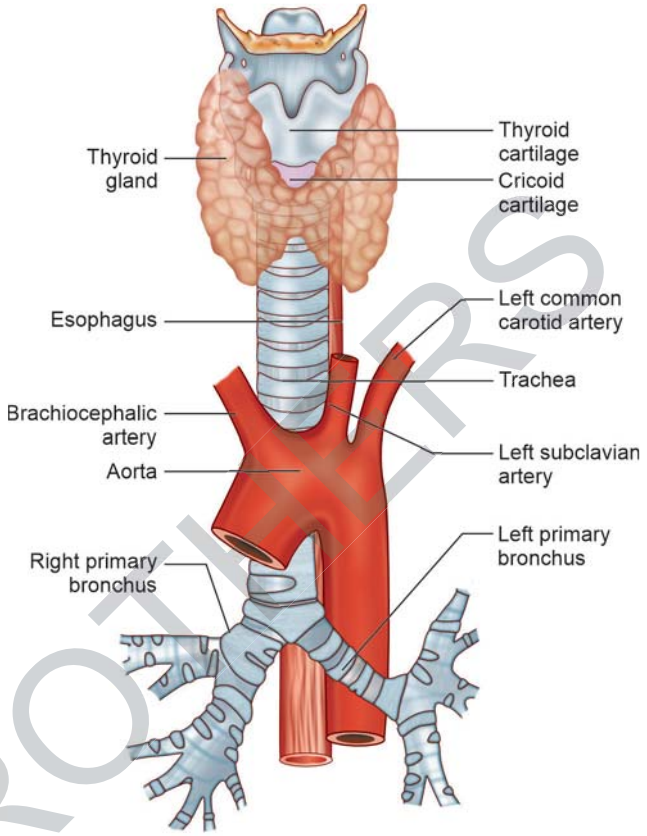

Fig. 4.12: Trachea and its related organs (schematic representation).

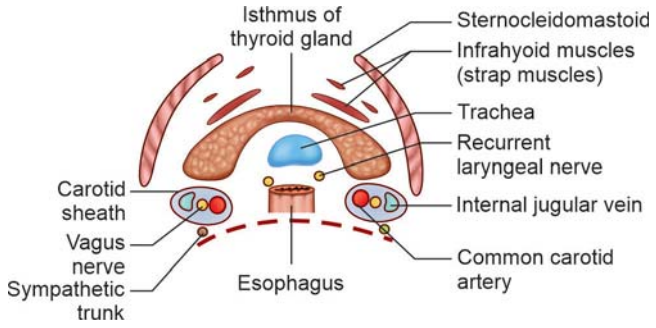

Fig. 4.13: Transverse section of neck at the level of isthmus of thyroid gland showing relations of trachea (schematic representation).

  - – Vessels of thyroid gland **(Fig. 4.13)**
  - – The strap muscles—sternohyoid and sternothyroid **(Fig. 4.13)**.

The lower thoracic part is related to:

  - – Manubrium sterni
  - – Arch of aorta **(Fig. 4.12)**
  - – Brachiocephalic and left common carotid arteries **(Fig. 4.12)**
- ❖ Posteriorly: Esophagus **(Fig. 4.13)**
- ❖ Laterally: Lobes of the thyroid gland and lungs
- ❖ Superiorly: Larynx **(Fig. 4.12)**
- ❖ Inferiorly: Right and left bronchi **(Fig. 4.12)**.

JAYPEE BROTHERS

Histology of Trachea (Fig. 4.14)

- Trachea consists of 16–20 C-shaped cartilaginous rings with fibrous tissue, smooth muscle fibers and mucous membrane.
- The mucous membrane consists of pseudostratified ciliated columnar epithelium with goblet cells lying on a layer of connective tissue.
- Subepithelial connective tissue contains serous glands and elastic fibers. Numerous aggregations of lymphoid tissue are present in the subepithelial connective tissue.
- The outermost layer consists of C-shaped rings of hyaline cartilage bridged by fibrous tissue posteriorly to complete the circle.

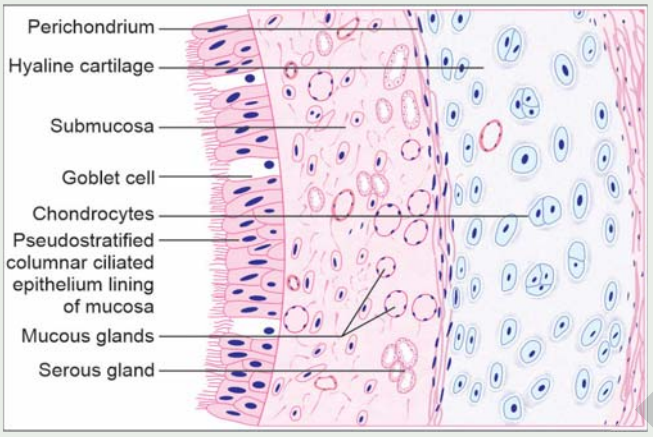

Fig. 4.14: Transverse section of trachea (schematic representation).

Carina

- The last tracheal ring is thick and broad.
- From its lower border, a hook-like process curves downwards and backwards between the bronchi. This projection is called the carina (L. keel).
- Mucous membrane lining this part of the trachea is extremely sensitive.
- Any dust particles or fluid entering the trachea will stimulate this region and produce a cough reflex so that the foreign body is thrown out.

During endoscopy (bronchoscopy), the surgeon will be able to visualize the carina, so that the endoscope can be directed to the affected side of the bronchus.

Blood Supply

Blood supply to the trachea is by inferior thyroid artery and bronchial arteries. Venous drainage is into inferior thyroid vein.

Lymphatic Drainage of Trachea

The tracheal lymphatics drain to the pretracheal and paratracheal lymph nodes.

Nerve Supply of Trachea

- ***Sympathetic supply*** to the trachea is derived from middle cervical ganglia. These fibers are vasomotor in function.
- ***Parasympathetic supply:*** It is derived from the vagus and recurrent laryngeal nerves. The fibers are motor to tracheal muscles, secretomotor to glands and sensory to the mucous membrane of trachea.

Applied Anatomy

TRACHEOSTOMY (Fig. 4.15)

Tracheostomy is an emergency surgery, usually done to relieve complete obstruction of the respiratory tract at laryngeal level. An opening is made in the trachea, just below the isthmus of the thyroid and a tracheostomy tube is inserted, so that air enters into the distal part of respiratory tract through it.

Other Indications of Tracheostomy

- To improve respiratory function by reducing the anatomical dead space, it also enables effective aspiration of bronchial secretions, e.g., chronic bronchitis with severe emphysema, chest injuries, particularly "flail-chest".
- *Respiratory paralysis:* It allows assisted or positive pressure ventilation; inhaled foreign material can also be removed, e.g., unconsciousness associated with head injuries, coma, following barbiturate poisoning, tetanus and bulbar poliomyelitis.
- As a preliminary to certain operations, e.g., laryngectomy.



Fig. 4.15: Patient with tracheostomy tube.

Courtesy: Dr Sreejayan MP, Professor, General Surgery, Government Medical College, Kozhikode, Kerala, India.

TRACHEOBRONCHIAL TREE (FIG. 4.16)

The air passages between trachea and alveoli are divided about 23 times and form the tracheobronchial tree **(Fig. 4.16).** This concept was first introduced by Weibel, a Swiss Anatomist.

The main airway—'trachea'—branches into two bronchi (primary pulmonary bronchus). Each principal bronchus enters a lung and gives rise to branches called lobar bronchi (secondary bronchi). Right bronchus gives rise to superior, middle and inferior lobar bronchi while left bronchus gives rise to superior and inferior lobar bronchi **(Table 4.4 and Flowchart 4.3)**.

Each lobar bronchus gives rise to segmental or tertiary pulmonary bronchi. The tertiary bronchi divide further into

JAYPEE BROTHERS

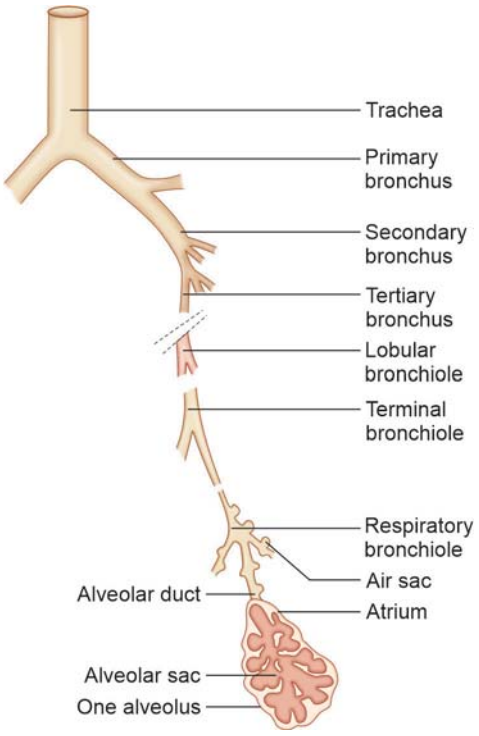

Fig. 4.16: Tracheobronchial tree (schematic representation).

Table 4.4: Differences between right and left bronchus.

Right bronchus	*Left bronchus*
• It is wider and shorter • Extrapulmonary part: It is 2.5 cm in length • It is more vertical and makes an angle of 25° with median plane • It enters the hilum at the level of T5 vertebra • Within the lung root, pulmonary artery is present anteriorly to the bronchus. Bronchus divides into an upper-eparterial branch and a lower hyparterial branch under the artery • *Intrapulmonary part* divides into superior, middle and inferior lobar bronchi	• It is narrower and longer • Extrapulmonary part—It is 5 cm in length • It is more oblique and makes an angle of 45° with median plane • It enters hilum at the level of T6 vertebra • The bronchus passes behind and below the pulmonary artery without dividing • *Intrapulmonary part* divides into superior and inferior lobar branches

successive generations of smaller bronchi and bronchioles within the parenchyma of lung.

Trachea and the first 16 generations of tracheobronchial tree constitute the ***'conducting zone'***, where no gas exchange occurs. The smallest airway in the conducting zone is the terminal bronchiole. The last seven generations of tracheobronchial tree constitute ***'the respiratory zone'***, where actual exchange of gases takes place. This zone consists of respiratory bronchioles, alveolar ducts and alveoli. The respiratory zone is surrounded by an extensive network of pulmonary capillaries. The alveolar ducts and the thin walled alveoli together form 'the respiratory unit.'

The multiple divisions of tracheobronchial tree increase the cross-sectional area, i.e., cross-sectional area of trachea is

Flowchart 4.3: Division of respiratory bronchiole.

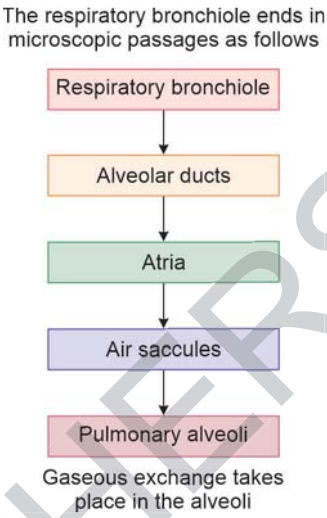

2.5 cm^2 and that of alveoli is 11,800 cm^2. There are about 300 million alveoli in human lungs. The pulmonary capillaries and alveoli form a 'blood-gas' interface.

Histology

- *Intrapulmonary bronchi:* The structure is similar to that of the trachea, i.e., it is lined by pseudostratified ciliated columnar epithelium.
- *Bronchioles:* Cartilage is absent in the wall of bronchioles.
- The amount of smooth muscle fibers in the wall of bronchus becomes more, as its size decreases. Spasm of these muscle fibers leads to bronchial asthma.
- As the bronchi become smaller, the epithelium changes from simple ciliated columnar, then nonciliated columnar and finally cuboidal.

Alveoli

- Each alveoli is like a pouch with diameter of 0.2–0.5 mm.
- It is lined by a layer of simple squamous epithelium.
- There is a capillary network around the alveoli.
- The blood in the capillaries and the air in the alveoli are separated by the alveolar epithelium, the capillary endothelium and two layers of basement membranes in between them (collectively called as respiratory membrane).
- At many places, the two basement membranes fuse together, thereby reducing the thickness of the barrier.

There are *various types of lining epithelial* cells in the alveoli:

- Type I alveolar cells—The most numerous cells are the squamous cells—these are called type I alveolar cells.
- Type II alveolar cells—these cells secrete **"pulmonary surfactant"**, which reduces surface tension and prevents collapse of the alveolus during expiration.
- Type III alveolar cells—exact function not known.

APPLICATION AND IMPLICATION IN NURSING

Bronchoscopy

By introducing a bronchoscope, the interior of the larynx, trachea and bronchi can be visualized. Foreign bodies can be removed and biopsies can be taken.

- During bronchoscopy, the carina is observed between the orifices of the main bronchi. Normally, the carina is in a sagittal

Contd...

JAYPEE BROTHERS

Contd...

plane. Enlarged tracheobronchial lymph nodes may alter the position of the carina; the carina may become distorted, widened and become immobile. Hence, changes in the carina are clinically important.

- The mucous membrane at the carina is one of the most sensitive areas of the tracheobronchial tree. It is associated with cough reflex. For example, when a foreign body stimulates the mucous membrane at the carina (e.g., an aspirated peanut), the patient chokes and coughs.
- Foreign bodies entering the trachea have a tendency to go to the right bronchus, since it is wider and more in line with the trachea.

LUNGS (FIGS. 4.17 AND 4.18)

The lungs or pulmones are the essential organs of respiration. Their main function is to oxygenate blood. They are present in the thoracic cavity.

In healthy people, who live in a clean environment, the lungs are light pink in color; but, in people living in polluted areas, lungs are dark and mottled due to the accumulation of dust or carbon particles, which get trapped in the phagocytes.

Each lung is conical in shape; it is enveloped by double layer serous membrane called as **pleura**. The lungs are separated from each other by the heart and the great vessels in the middle mediastinum.

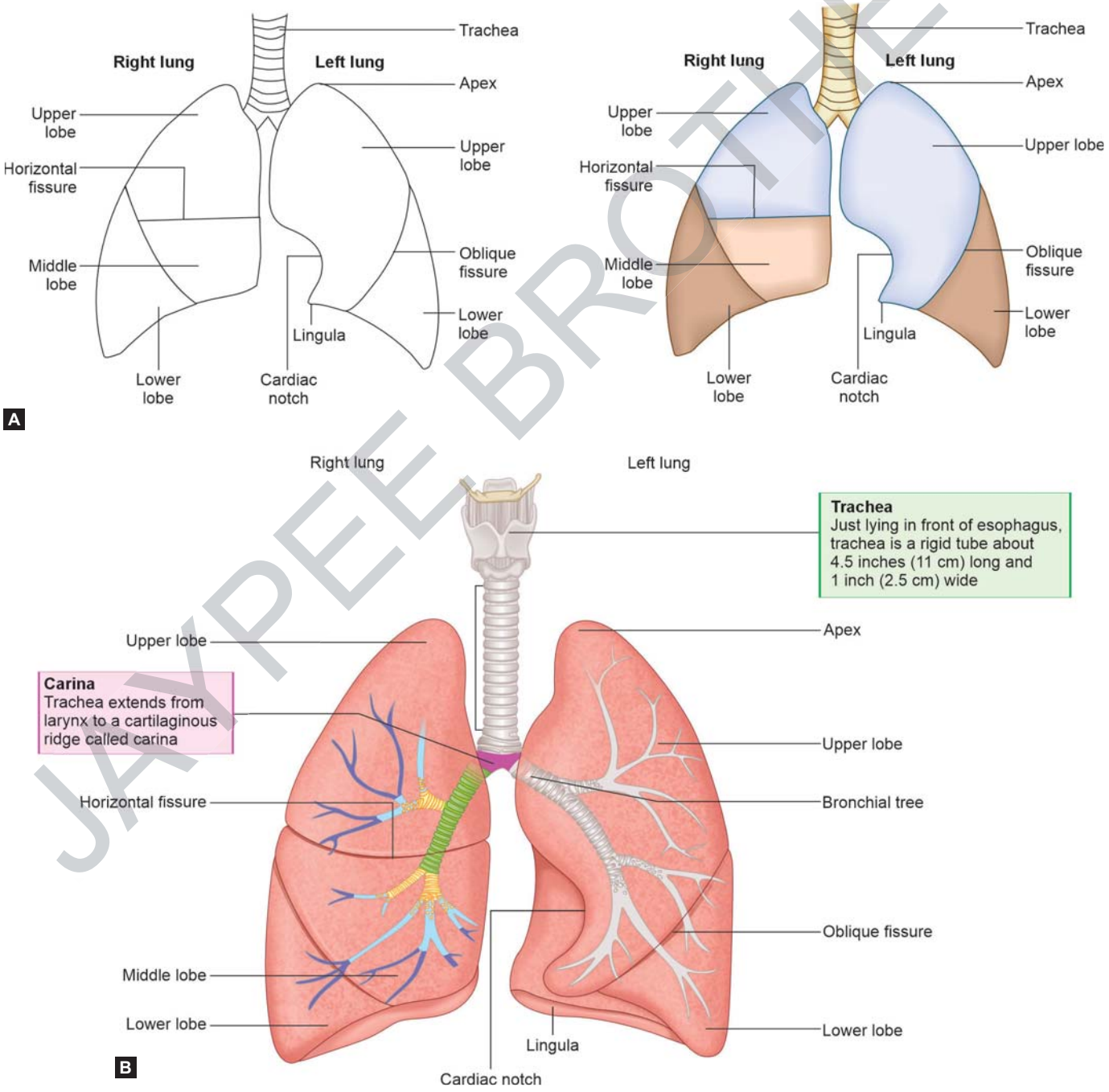

Figs. 4.17A and B: Lungs: External features.

JAYPEE BROTHERS

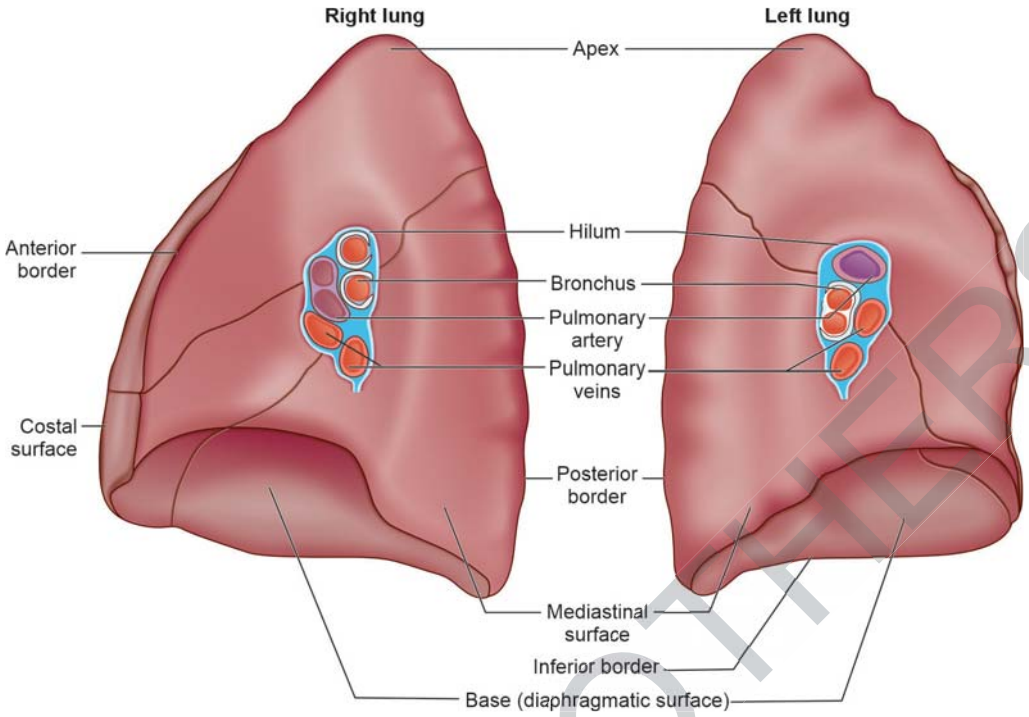

Fig. 4.18: Lungs—mediastinal surface (schematic representation).

The lungs are attached to the heart and the trachea by the structures in the roots of the lungs, i.e., the pulmonary artery, the pulmonary veins and the main bronchi.

Each lung has ***an apex*** at the upper end, ***a base*** resting on the diaphragm and ***two surfaces costal and medial*** (or mediastinal).

Presenting Parts

- ***Apex:*** It is the rounded upper end of lung which extends above the anterior end of the first rib to about 2.5 cm above the clavicle. It is covered by cervical pleura and further externally by the suprapleural membrane.
- ***Base:*** It is semilunar in shape and is concave downwards as it rests on the dome of diaphragm. On right side, the right lobe of liver lies below the diaphragm and on the left side are present the left lobe of liver, fundus of stomach and spleen.
- ***Two surfaces***
  1. ***Costal surface:*** It is the outer smooth and convex surface of the lung covered by the costal pleura. It is related to inner surfaces of the ribs and the costal cartilages with intervening intercostal spaces. The ribs form their impressions on the lung.
  2. ***Mediastinal surface (medial surface):***
     - » The characteristic feature of mediastinal surface of lung is the hilum present in the posterior half. Hilum is a roughly triangular area that gives passage to the bronchi, pulmonary and bronchial vessels, nerves and lymphatics.
     - » The mediastinal pleura at the hilum forms a tubular sheath which connects the hilum to the mediastinum. This is called the "root of lung".

Contents of Root of Lung

- Bronchus
- *Pulmonary artery:* Single
- *Pulmonary vein:* Two are present
- Bronchial arteries
- Bronchial veins
- Pulmonary plexus of nerves
- Bronchopulmonary lymph nodes
- Areolar tissue

Arrangement of structures within the root or hilum of lung **(Fig. 4.19).** From before backward:

- Superior pulmonary vein
- Pulmonary artery
- Bronchus with its vessels.

Note: The pulmonary artery carries deoxygenated blood and pulmonary veins carry oxygenated blood. That is why the artery is given blue or purple color and the veins in red.

Impressions and Relations of Mediastinal Surface (Table 4.5)

Impressions are seen on mediational surface due to various mediastinal structures which lie in relation to this surface of the lung. These are given in **Table 4.5.** The pleura separates these structures from the lung **(Figs. 4.19 and 4.20).**

Lobes of Lung

The right lung is divided into three lobes by an oblique and a horizontal fissure. The left lung is, however, divided into two lobes by a single oblique fissure.

Right Lung

- Upper lobe
- Middle lobe
- Lower lobe.

JAYPEE BROTHERS

Table 4.5: Organs associated with right and left lung.

Right lung	*Left lung*
• Anterior surface of right auricle • Right atrium • Part of right ventricle • Phrenic nerve • Superior vena cava • Origin of right brachiocephalic vein • Azygous vein-arches over the hilum • Origin of right subclavian artery • Trachea • Esophagus	• Left atrium and left auricle • Anterior surface of right ventricle • Phrenic nerve • Pulmonary trunk • Arch of aorta • Subclavian artery • Esophagus • Descending thoracic aorta • Esophagus, inferiorly

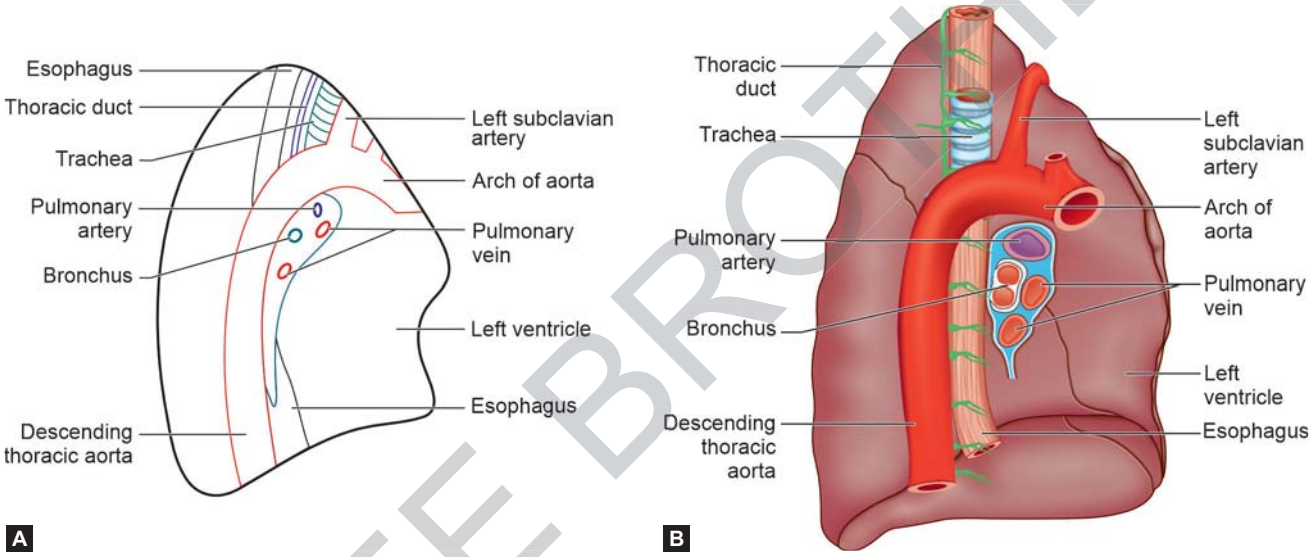

Figs. 4.19A and B: A. Impressions on the mediastinal surface of left lung; B. Impressions on the mediastinal surface of left lung (schematic representation).

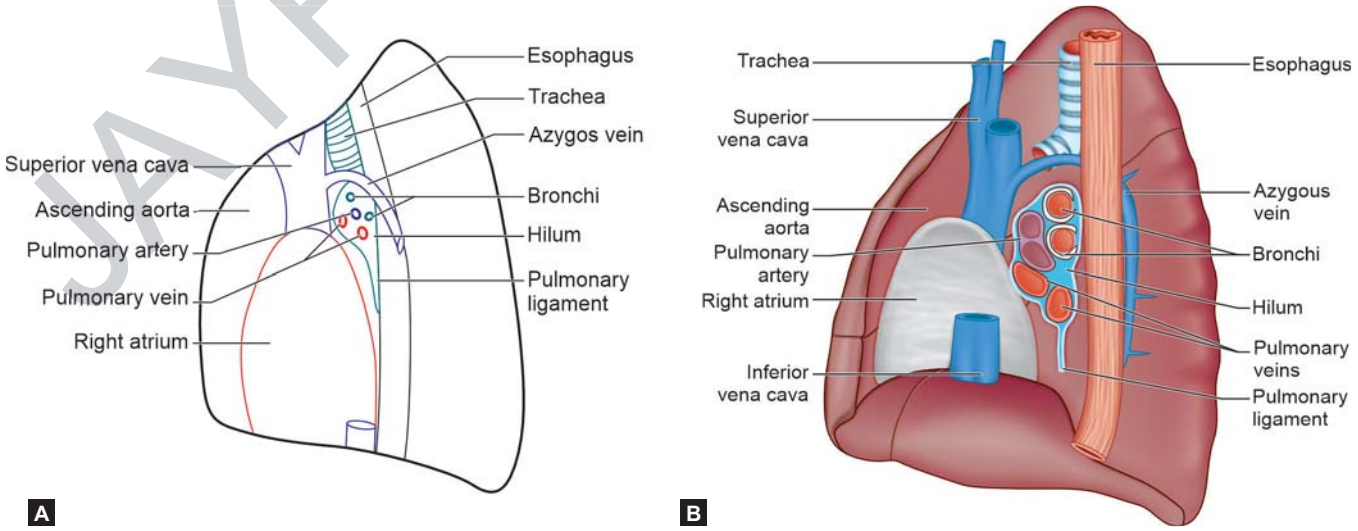

Figs. 4.20A and B: A. Impressions on the mediastinal surface of the right lung. B. Impressions on the mediastinal surface of right lung (schematic representation).

JAYPEE BROTHERS

Applied Anatomy

- Chest physical therapy (CPT or chest PT) **(Fig. 4.21)** is an airway clearance technique (ACT) to drain the lungs, and may include percussion (clapping), vibration, deep breathing, and huffing or coughing.
- In this the patient is made to assume different positions and the health care provider performs the percussion or vibration following which the mucus drains from the five lobes of lung with gravitational aid.

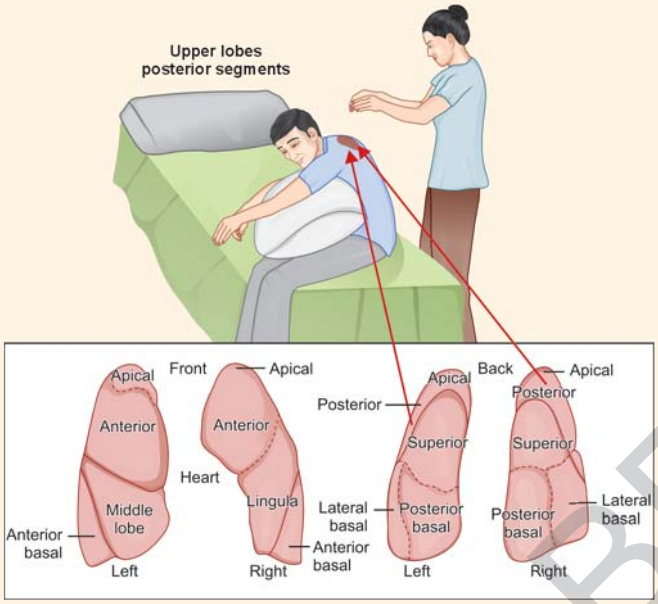

Fig. 4.21: Chest physiotherapy of upper lobe of lung.

Left Lung

- Upper lobe
- Lower lobe.

Differences between right and left lungs are given in **Table 4.6.**

Lingula of Left Lung

It is a tongue-shaped projection of lung below the cardiac notch.

Arterial Supply

Lung is supplied by bronchial and pulmonary arteries.

Bronchial Artery

This artery may arise from the thoracic aorta or one of the posterior intercostal arteries. It supplies the bronchial tree (as far as the respiratory bronchioles) and then anastomoses with pulmonary arteries.

Table 4.6: Differences between right and left lungs.

Right lung	*Left lung*
It has two fissures and three lobes normally	It has one fissure and two lobes normally
Anterior border straight	Anterior border shows a cardiac notch; there is a tongue-shaped "lingula" below it
It is shorter and broader	It is longer and narrower
It is heavier—about 700 g	Weighs about 600 g

Pulmonary Artery

One pulmonary artery enters the hilum of the lung, carrying deoxygenated blood from the right ventricle of the heart; it ends in the capillary plexus on the alveolar walls of the lung.

Venous Drainage

It is drained by bronchial and pulmonary veins.

Pulmonary Veins

Two veins emerge from the hilum of each lung. They carry oxygenated blood from the lung and empty into the left atrium.

Lymphatic Drainage

The lymph from both the lungs is drained into respective bronchopulmonary lymph nodes present at the hilum of lung.

Nerve Supply

- ***Parasympathetic supply:*** It is derived from vagus nerve. The fibers are motor to bronchial muscles, and secretomotor to glands of bronchial tree. Parasympathetic stimulation causes broncho-constriction.
- ***Sympathetic supply:*** Preganglionic fibers are derived from spinal segments of T2 to T5. Their action is opposite to the parasympathetic supply and cause bronchodilatation.

Structure of Lung (Fig. 4.22)

The lung parenchyma is made up of the bronchopulmonary tree accompanied by branches of pulmonary artery and tributaries of pulmonary veins with associated lymphatics and nerves enclosed in a connective tissue framework.

Application and Implication in Nursing

- Fresh, healthy lungs always contain some air. So, a part of the lung, when removed, will float in water. A fetal lung or lungs from a stillborn (baby who has never inspired air), which have never expanded, will sink when placed in water. This knowledge is of medicolegal importance in determining whether a dead infant was stillborn or whether it was born alive and had started to breathe.
- During the development of the lung in the fetus, the alveolar epithelium begins the secretion of surfactant at the seventh month. Hence, the seventh month is considered as the viable age for the fetus.
- Lack of surfactant causes respiratory distress syndrome of the newborn. The alveoli collapse leads to a condition called **Hyaline membrane disease.**
- Surfactant can be administered to premature babies through the endotracheal route.
- The lung and the visceral pleura are supplied by the autonomic plexus of nerves. They are, therefore, not pain sensitive. The parietal pleura is supplied by the intercostal or phrenic nerves. When the parietal pleura is involved, severe pain is experienced. Pain may be referred to the shoulder tip from the diaphragmatic

Contd...

JAYPEE BROTHERS

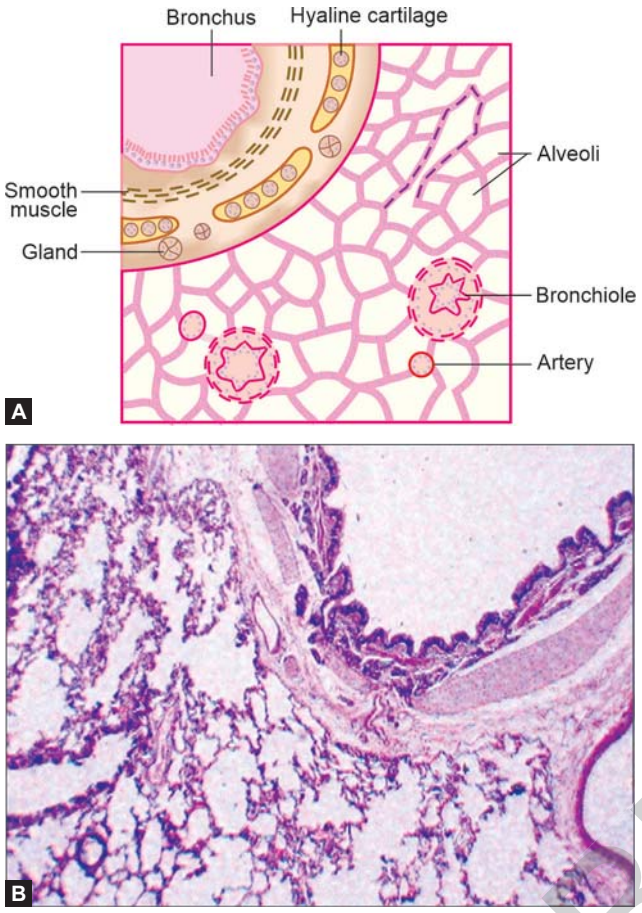

Figs. 4.22A and B: A. Histology of lung (schematic); B. Photomicrograph.

Contd...

pleura [along the phrenic and supraclavicular nerves, (C3, C4) or to the abdominal wall from the costal pleura (along the intercostal nerves].

- *Postural drainage:* Secretions from a lobe have to be drained by altering the position of the patient, so that gravity will assist the process of drainage. For example, a patient with bronchiectasis (dilated bronchus) on the right side is positioned in bed on his left side, secretions from the right lung and bronchi will flow toward the carina of the trachea. As this is a very sensitive area, the cough reflex is stimulated, bringing up the infected sputum. This clears the right bronchial tree.
- Similarly, if the left lung and bronchi are to be drained, patient is made to lie on his right side.
- In unconscious patients, infection from the nasal cavity or oropharynx may reach the lung leading to pneumonia. So, the position of very ill and unconscious patients should be changed frequently to promote good aeration of lungs. Pillow is not advised in such cases.
- **Pulmonary thromboembolism** is a serious condition; an embolus may reach the lung from a distant site (e.g. from the deep veins of the leg). It may partially or completely obstruct the arterial flow to the lung. It can lead to sudden death.
- Bronchogenic carcinoma (cancer of a bronchus) is the most common cancer in men, the major cause being cigarette smoking and living in polluted industrial areas. This type of

Contd...

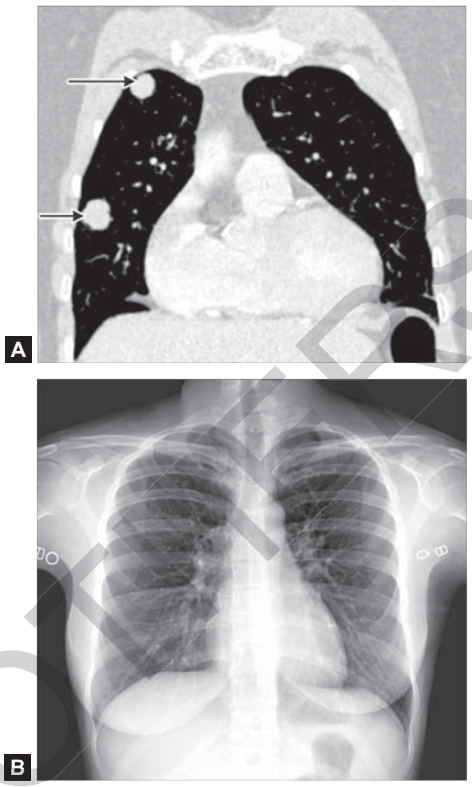

Figs. 4.23A and B: Radiographical anatomy: A. CT of thorax, coronal plane, right lung showing secondaries; B. Normal radiograph of chest.

Courtesy: Dr Devarajan, Professor and Head, Department of Radiodiagnosis, Government Medical College, Kozhikode, Kerala, India.

Contd...

cancer can spread directly to the adjacent structures, along the lymphatics to the lymph nodes and along the bloodstream to distant sites, like brain, bones, etc.

- Cancer can spread from other organs to lungs ('secondaries') **(Fig. 4.23A)**.
- *Radiological anatomy (Fig. 4.23B):* In the plain X-ray chest, the lung fields are seen as translucent shadows because of the air they contain. The blood vessels, containing blood, stand out as radiating shadows from the hilum. Hilar lymph nodes may also be visible.

Bronchopulmonary Segments (Fig. 4.24)

Definition: Bronchopulmonary segment is the independent functional unit of lung made up of a tertiary bronchus with its bronchial tree upto the alveoli accompanied by an

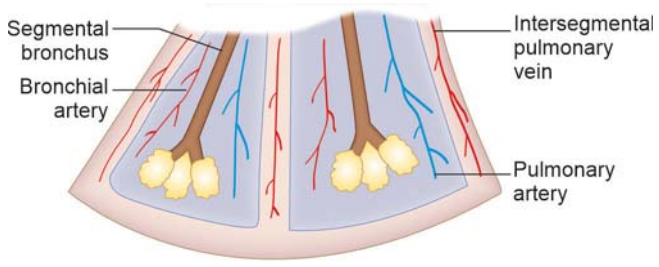

Fig. 4.24: Two adjacent bronchopulmonary segments.

UNDER PROOFERS

Table 4.7: Bronchopulmonary segments.

Lobe	*Right lung*	*Left lung*
Upper lobe	Apical	Apical
	Anterior	Anterior
	Posterior	Posterior
		Superior lingular
		Inferior lingular
Middle lobe	Medial	
	Lateral	
	Apical	Apical
	Medial basal	Medial basal
	Lateral basal	Lateral basal
	Anterior basal	Anterior basal
	Posterior basal	Posterior basal

independent branch from pulmonary artery. The venous drainage is, however, intersegmental. Each lung has ten bronchopulmonary segments **(Table 4.7)**.

Each unit of bronchopulmonary segments is surrounded by connective tissue, which is continuous with the visceral pleura.

APPLICATION AND IMPLICATION IN NURSING

- Usually infections are confined to each bronchopulmonary segment; but tuberculosis and malignancy breakthrough the septa and spread to the adjacent segments.
- A knowledge of the bronchopulmonary segment is essential for the interpretation of bronchogram and for doing bronchoscopy
- If a segment is damaged (by disease), it is possible to resect that segment only.

Functions of Lung and Tracheobronchial Tree

- Lung is the organ of exchange of gases, i.e., oxygen and carbon dioxide, which helps in oxygenation of blood.
- Surfactant secreted by Type–II pneumocyte of alveoli prevents the collapse of alveoli.

Nonrespiratory Functions of Lung

- Angiotensin-converting enzyme is present in pulmonary capillary endothelium. This converts angiotensin-I to angiotensin-II, which is responsible for the maintenance of blood pressure.
- APUD cells or neuroendocrine cells are present in the bronchiolar tree. They produce various vasoactive substances like VIP and substance P, which may have a role in maintaining tone of bronchioles.
- Lung contains tissue type plasminogen activator, which converts plasminogen to plasmin. Thus, it has a role in fibrinolytic mechanism of the body.

Defense Functions of Respiratory System

- Mucus secreted by goblet cells of upper respiratory tract helps to entrap foreign particles. The cilia of epithelium beat upwards and push the mucus towards the nose and exterior.
- Mucus also contains IgA antibodies that provide local immunity.
- Alveolar macrophages engulf foreign particles and destroy them by phagocytosis.
- Protective reflexes like cough reflex, sneezing reflex and bronchoconstriction reflex help to clear the passage from inhaled foreign particles.

Added Information

SURFACTANT

- The alveoli are air-filled structures. But, normally the alveoli do not collapse due to the presence of surface tension-lowering agent called "surfactant".
- *Surfactant* is a complex of phospholipids, proteins, carbohydrates and several ions (dipalmitoyl phosphatidyl choline).
- It is secreted by type II alveolar epithelial cells.
- It forms a layer at the fluid-air interface in the alveoli **(Fig. 4.25)**.

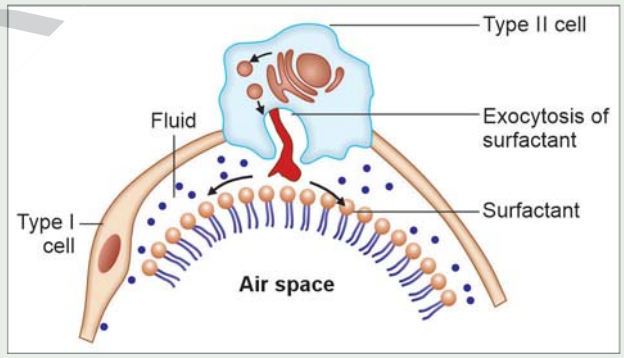

Fig. 4.25: Formation of pulmonary surfactant (schematic representation).

Role of Surfactant

- It lowers the surface tension in the alveoli.
- This increases the compliance of lungs and reduces the work of breathing.
- By reducing the surface tension, surfactant prevents fluid accumulation in the alveolus and keeps it dry. In the absence of surfactant, fluid from interstitial space flows into the alveolar space due to increased surface tension.
- Synthesis of surfactant starts in late fetal life.
- **Its synthesis is facilitated by glucocorticoid and thyroid hormones. Low doses of steroids and thyroid hormones can be given to the mother during pregnancy to enhance synthesis of surfactant in the fetus.**
- Insulin delays the synthesis of surfactant. Diabetic mother receiving insulin is likely to have a baby with hyaline membrane disease.

Contd...

JAYPEE BROTHERS

Contd...

- There is an increase in fetal as well as maternal cortisol near term, which accelerates maturation of surfactant in lungs.
- In-utero, the fetal lungs remain collapsed.
- After birth, the infant makes several strong inspiratory efforts and the lungs expand. They are prevented from collapsing again by the surfactant.

APPLICATION AND IMPLICATION IN NURSING

HYALINE MEMBRANE DISEASE OR INFANT RESPIRATORY DISTRESS SYNDROME

- This is a serious pulmonary disorder which develops in premature infants due to deficiency of surfactant.
- Surface tension of alveoli is high and many of them get collapsed
- Also there can be fluid accumulation in the lungs ("**pulmonary edema**").

PLEURA AND PLEURAL CAVITY (FIG. 4.26)

Pleura

The pleura is a serous membrane lined by a single layer of squamous cells (the mesothelium). There are two pleural sacs, one on either side of the mediastinum. Each pleural sac is invaginated from its medial side by the lung, so that it has an outer layer, called the parietal pleura and the inner visceral layer or pulmonary pleura.

These two layers are continuous with each other at the hilum of the lung. There is a potential space between the two layers, the pleural cavity, with a thin film of fluid, to prevent friction.

Visceral Pleura

The visceral layer or pulmonary pleura covers the surfaces and fissures of the lung, except at the hilum. It is firmly attached to the surface of the lung; it cannot be separated from it.

Parietal Pleura

The visceral pleura reflects over itself at the hilum to form an external layer covering the lung called as parietal pleura.

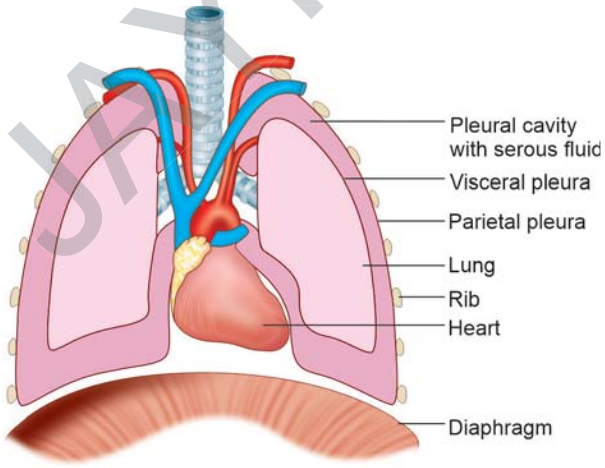

Fig. 4.26: Pleura and pleural cavity (schematic representation).

Note: The parietal pleura surrounding the root of the lung extends downwards as a fold called the pulmonary ligament. This fold contains a thin layer of loose areolar connective tissue. It provides a space for the pulmonary vein to expand during increased venous return (during exercise).

Differences between parietal and visceral pleurae are given in **Table 4.8**.

Table 4.8: Differences between parietal and visceral pleurae.

		Parietal pleura	*Visceral pleura*
1.	Form the covering of:	Covers the inner aspect of thoracic wall and visceral layer	Surfaces and fissures of lung
2.	Blood supply	Intercostal Internal thoracic Musculophrenic	Bronchial vessels
3.	Nerve supply	Intercostal nerves Phrenic nerves	Autonomic (same as that of the lung)
4.	Sensitivity to pain	Sensitive	Non-sensitive
5.	Lymphatic drainage	Intercostal Internal mammary Posterior mediastinal Diaphragmatic	Branchopulmonary nodes

APPLIED ANATOMY

- Inflammation of the pleura is called pleuritis or pleurisy. It may be associated with collection of fluid in the pleural cavity (pleural effusion). It is common in tuberculosis and cancer of bronchus or lung.
- Presence of air in the pleural cavity is called pneumothorax. Penetrating injuries of the thoracic wall can lead to this condition **(Fig. 4.27)**.
- Presence of blood in the thoracic cavity is called hemothorax. Usually follows penetrating injuries of thorax.

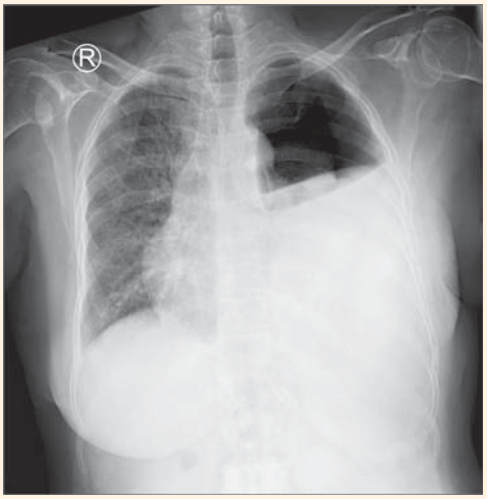

Fig. 4.27: Radiograph of chest showing hydropneumothorax (air and fluid) on the left side. Trachea is shifted to right.

Courtesy: Dr Devarajan, Professor and Head, Department of Radiodiagnosis, Government Medical College, Kozhikode, Kerala, India.

Contd...

JAYPEE BROTHERS

Contd...

- Presence of pus in the pleural cavity is called empyema.
- Aspiration of any fluid from the thoracic cavity is called paracentesis thoracis. It is usually done in the 6th intercostal space in the midaxillary line (in order to avoid injury to the liver).

Pleural Cavity

It is the potential space between the two pleurae, which contains a thin layer of lubricating serous fluid. The intrapleural pressure is –2 mm Hg during expiration and –6 mm Hg during inspiration. This prevents collapse of lung parenchyma and also aids in the venous return of body.

Pressure Changes during Respiration

Three types of pressure changes occur in the thoracic cavity during the process of respiration—intrapleural or intrathoracic pressure, intra-alveolar or intrapulmonary pressure and transpulmonary pressure.

Intrapleural Pressure

It is the pressure exerted by the pleural fluid in the pleural cavity. Due to continuous suction of fluid into the lymphatic channels, a negative suction pressure is developed. At the beginning of inspiration, the intrapleural pressure is –2 to –3 mm Hg and at the end of inspiration, it becomes –6 mm Hg **(Fig. 4.28)**. Intrapleural pressure is exerted throughout the thoracic cavity. Hence during inspiration, the increased negativity acts as a suction force in the great veins that helps to increase the venous return to the right atrium. This negativity also helps to prevent alveolar collapse, along with the surfactants.

Intra-alveolar Pressure

It is the pressure developed inside the alveolus. It is equal to the atmospheric pressure at the start of breathing, hence expressed as 0 mm Hg. During mid inspiration, it becomes –1 mm Hg, which helps to rush air inside the lungs from the atmosphere **(Fig. 4.28)**. This increases pressure inside the alveoli and at the end of inspiration, it becomes again 0 mm Hg. During mid expiration, as the alveoli become smaller, the pressure rises to +1 mm Hg, which pushes air outside. At the end of expiration, the intra-alveolar pressure again becomes same as that of atmospheric, i.e., 0 mm Hg **(Fig. 4.28)**.

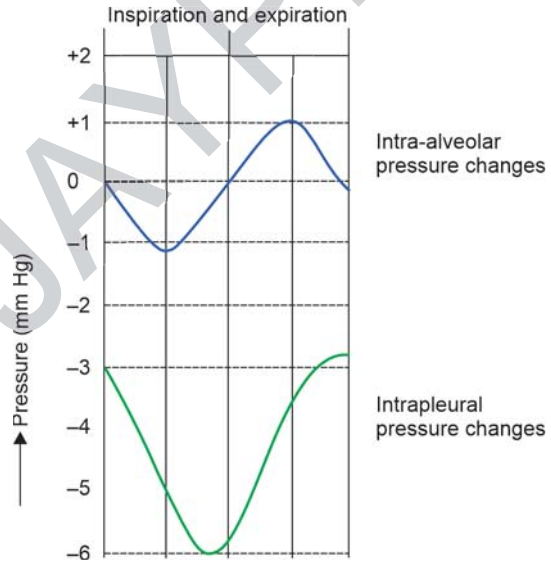

Fig. 4.28: Intrapleural and intra-alveolar pressure changes during respiration.

Transpulmonary Pressure

It is the difference between intra-alveolar and intrapleural pressures. It represents the pressure difference felt across the lungs, which determines the expansion and elastic recoiling of lungs.

PHYSIOLOGY OF RESPIRATION

Definition

RESPIRATION
It is the process of exchange of gases in the lung where there is uptake of oxygen in exchange for carbon dioxide. This is called *external respiration*. The exchange of oxygen and carbon dioxide at tissue level is called *internal respiration*.

At rest, a human being breathes about 12–15 times per minute. 500 mL of air is taken in each breath which equals to 6–8 liters of air in 1 minute.

Composition of Air

The inspired air is composed of:

- ***Oxygen (O_2):*** 21%
- ***Carbon dioxide (CO_2):*** 0.03%
- ***Nitrogen (N_2):*** 78%
- ***Other inert gases:*** about 1%

On breathing out (expiration), the air has 16% oxygen and 4% carbon dioxide.

Respiratory Movements

These consist of two phases:

1. ***Inspiration:*** It is accompanied by expansion of lungs for uptake of air.
2. ***Expiration:*** It is the expulsion of air from lungs due to retraction of lungs. These movements are accompanied by corresponding movements of the thoracic cage.

Inspiration

It is an active process. There is expansion of intrathoracic volume resulting in expansion of lungs. This creates a negative air pressure in the airway allowing the air to flow in. In normal conditions, inspiration lasts for two seconds.

The ***primary muscles of inspiration*** are diaphragm and external intercostals. In addition, scalene, sternocleidomastoids, neck and back muscles act as ***accessory muscles or secondary muscles of inspiration***. Consequences of their contraction are given in **Figure 4.29.** When the diaphragm contracts, it moves downward towards the abdomen and the vertical diameter of thoracic cage is increased.

Contraction of external intercostal muscles increases the transverse diameter ("bucket handle" effect) and the

JAYPEE BROTHERS

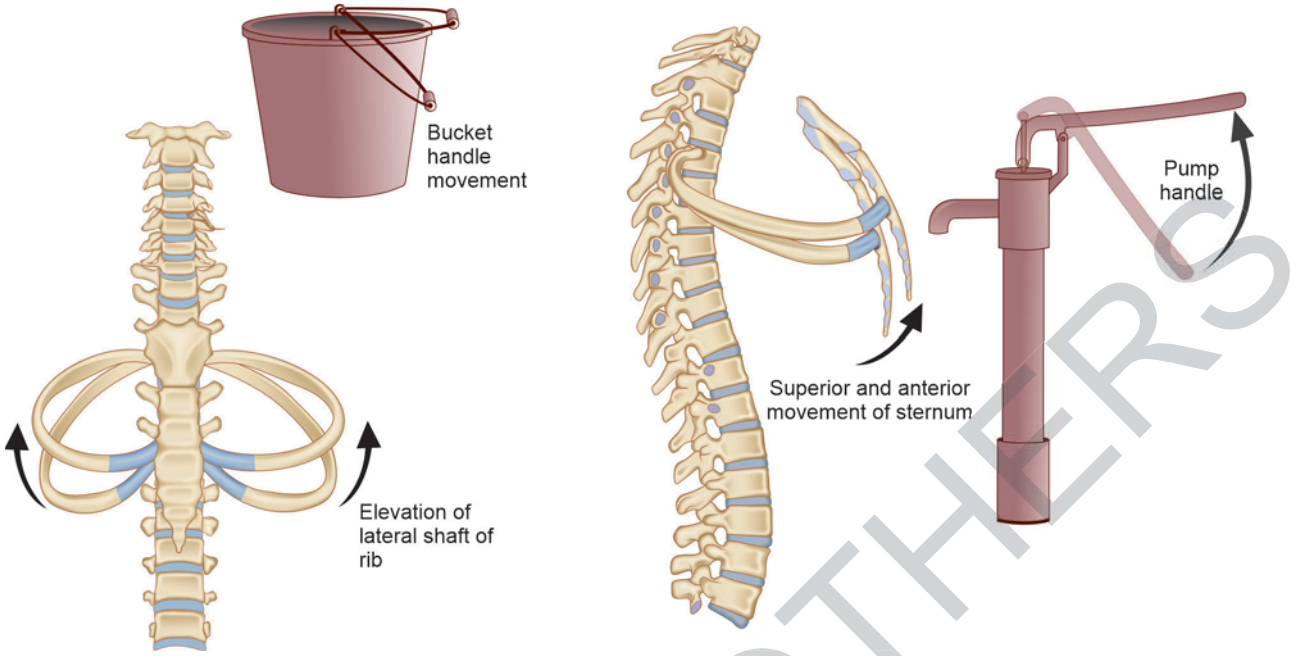

Fig. 4.29: Actions of inspiratory muscles (schematic representation).

anteroposterior diameter ("water pump-handle" effect) of thoracic cage **(Fig. 4.29)**.

Expiration

It is a passive process in normal breathing. It occurs due to recoil of lungs at the end of inspiration. This pushes out air from lungs.

In forced expiration, the following muscles are involved:

- ***Anterior abdominal wall muscles,*** namely rectus abdominis, internal oblique and transversus abdominis. Contraction of these muscles increases the intra-abdominal pressure and pushes up the diaphragm.
- ***Internal intercostal muscles:*** Contraction of these muscles pulls the upper ribs downwards. This decreases the intrathoracic volume.
- ***Accessory muscles:*** Adductor muscles of vocal cord. Their contraction is primarily protective, to prevent entry of food or fluid into trachea.

Added Information

BREATH SOUNDS

Breath sounds can be heard clearly by auscultation. Breath sounds are produced due to passage of air through airways and alveoli. But the sounds are attenuated and filtered by the lung tissue. According to the quality of intensity, these are of two types:

1. Vesicular
2. Bronchial

- Vesicular breath sounds are the normal breath sounds heard all over the chest wall. They are heard mainly during inspiration and early expiration without a distinct gap.
- Bronchial breath sounds are high-pitched sounds heard normally over trachea and bronchi, where there is less attenuation or filtration of sound. They are audible during

Contd...

Contd...

inspiration as well as during expiration and there is a distinct pause in between. Bronchial breath sounds heard over the chest wall are always pathological (e.g., in pulmonary fibrosis, collapse of lungs, etc.).

ADDED OR ADVENTITIOUS SOUNDS

- Wheezes or rhonchi are prolonged musical sounds heard in certain obstructive lung diseases like bronchial asthma. These sounds are produced due to spasm of smooth muscles lining the airway.
- Crackles or crepitations are short nonmusical, bubbling sounds. These sounds are produced due to bubbling of air through secretions as in lung infections and interstitial lung diseases.
- Pleural rub is the creaking or rubbing type of sound heard in inflammation of pleura or pleuritis.

Pulmonary Function Tests

Pulmonary function tests or lung function tests are useful in assessing the functional status of the respiratory system. These tests involve measurement of lung volumes and capacities.

The air in lung is classified into two divisions:

1. Lung volumes
2. Lung capacities

Pulmonary function tests are carried out mostly by using spirometer.

Most of the lung volumes and capacities can be easily determined by a water-filled spirometer attached to a kymograph. The recording is called ***spirogram***. Volume of air is plotted on Y-axis and time is plotted on X-axis of a spirogram **(Fig. 4.30).** A downward deflection in the recording obtained represents expiration and an upward deflection represents inspiration.

JAYPEE BROTHERS

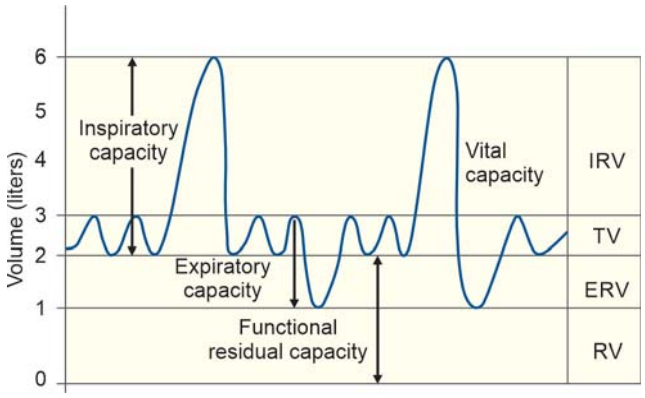

Fig. 4.30: Normal spirogram (schematic representation).

(IRV: inspiratory reserve volume; TV: tidal volume; ERV: expiratory reserve volume; RV: residual volume)

Lung Volumes (Fig. 4.30)

- ***Tidal volume (TV):*** It is the volume of air that moves into the lungs with each inspiration or the amount that moves out with each expiration. It is about 0.5 liters (500 mL) in an adult.
- ***Inspiratory reserve volume (IRV):*** It is the air inspired, with a maximal inspiratory effort, in excess of the tidal volume. It is about 3 to 3.3 liters.
- ***Expiratory reserve volume (ERV):*** It is the additional volume of air that can be expired out forcefully, after normal expiration. It is about 1000 mL (1L).
- ***Residual volume (RV):*** It is the air left in the lungs after a maximal expiratory effort. It is about 1.2 liters in males and 1.1 liters in females. This cannot be measured directly by simple spirometry.

Lung Capacities (Fig. 4.30)

Vital Capacity (VC)

It is the greatest amount of air that can be expired after a maximal inspiratory effort.

$$VC = IRV + TV + ERV$$

It is about 4.8 liters. This is an index of pulmonary function.

Total Lung Capacity (TLC)

It is the volume of air present in lungs after a deep (maximal) inspiration. It includes all four volumes. It is about 6 liters.

Factors Affecting Vital Capacity

- *Physiological*
  - *Sex:* Vital capacity is higher in males due to larger chest size, muscle power and body surface area.
  - *Age:* Vital capacity decreases with age due to gradual loss of elasticity or compliance of lungs.
  - *Posture:* Vital capacity is maximum while standing due to position of diaphragm.
  - *Pregnancy:* Vital capacity decreases because the diaphragm is pushed up by the pregnant uterus.
- *Pathological*
  - Diseases of lung parenchyma that decrease its compliance, decrease vital capacity, e.g., pulmonary fibrosis, emphysema, pleural effusion, etc.
  - Ascites results in decreased vital capacity due to pressure on diaphragm.

Inspiratory Capacity (IC)

It is the amount of air that a person can breathe, beginning at resting expiratory level and distending the lungs to the maximum amount.

$$IC = IRV + TV$$

Functional Residual Capacity (FRC)

It is the amount of air remaining in the lungs at the end of normal expiration.

$$FRC = RV + ERV$$

Timed Vital Capacity (TVC)

This is a dynamic lung function test where the subject is asked to inspire and expire forcefully and rapidly into a recording spirometer. The total volume of air thus expired is called timed vital capacity or forced expiratory volume (FEV).

The forced expiratory volume in each second is calculated and plotted on a graph against time. In normal individuals, the forced expiratory volume in 1st second (FEV1) is about 83%, in 2nd second (FEV2) is about 95% and in 3rd second (FEV3) is almost 100%. This measurement is used to detect obstructive and restrictive disorders of lungs.

Key Point

In an obstructive lung disorder (e.g., asthma), the forced vital capacity is significantly decreased and the FEV1: TVC ratio is low. In a restrictive lung disorder (e.g. fibrosis of lungs), both TVC and FEV1 are equally reduced and so the ratio of FEV1: TVC appears to be normal.

APPLICATION AND IMPLICATION IN NURSING

RESTRICTIVE AND OBSTRUCTIVE RESPIRATORY DISEASES

The diseases of respiratory tract are classified into two types:

1. Restrictive respiratory disease
2. Obstructive respiratory disease.

These two types of respiratory diseases are determined by lung functions tests, particularly FEV.

Restrictive Respiratory Disease

Restrictive respiratory disease is the abnormal respiratory condition characterized by difficulty in inspiration. The expiration is not affected. Restrictive respiratory disease may be because of abnormality of lungs, thoracic cavity or/and nervous system, e.g., Poliomyelitis, myasthenia gravis, paralysis of diaphragm.

Obstructive Respiratory Disease

Obstructive respiratory disease is the abnormal respiratory condition characterized by difficulty in expiration, e.g., asthma, chronic bronchitis, emphysema.

VENTILATION

- ***Respiratory minute volume or pulmonary ventilation:*** It is the amount of air inspired per minute, i.e., 500 mL/breath × 12 breaths/minute, which is about 6 L/minute.
- ***Alveolar ventilation:*** It is the volume of air that participates in the exchange of O_2 and CO_2. Out of the 500 mL of air entering into the lungs (tidal volume) during inspiration, only 350 mL reaches the alveoli.

JAYPEE BROTHERS

Therefore, alveolar ventilation = 350 mL × 12 breaths/minutes = 4.2 liters/minute.

- ***Dead space air:*** It is the volume of air present in the respiratory passage, which does not take part in gaseous exchange. The volume of air in the "conducting zone" of respiratory passage, i.e., from nose to terminal bronchioles, constitutes the 'anatomical dead space'. Normal anatomical dead space volume is about 150 mL.

Amount of air in this anatomical dead space along with the air present in the alveoli which is not taking part in gaseous exchange constitutes the physiological dead space or total dead space of lungs. In healthy individuals, anatomical dead space is equal to physiological dead space, i.e., 150 mL.

Ventilation–Perfusion Ratio

It is the ratio of the alveolar ventilation to the pulmonary blood flow. Normal alveolar ventilation at rest is 4.24 L/minute, and pulmonary blood flow is 5 L/minute. Therefore, the ventilation-perfusion ratio is 4.2 L/5 L or 0.84. The ventilation-perfusion ratio is high in the apex of the lungs and less in the base of the lungs (due to gravity).

GASEOUS EXCHANGE IN LUNGS

Gases diffuse from alveoli to blood circulation and vice versa, passing through alveolocapillary membrane or respiratory membrane. It consists of:

- Alveolar epithelium
- Pulmonary capillary endothelium
- Basement membrane of both lining cells **(Fig. 4.31)**.

Diffusing Capacity

The diffusing capacity is defined as the volume of gas that diffuses through the respiratory membrane each minute for a pressure gradient of 1 mm Hg.

Diffusing Capacity for Oxygen and Carbon Dioxide

Diffusing capacity for oxygen is 21 mL/minute/mm Hg. Diffusing capacity for carbon dioxide is 400 mL/minute/ mm Hg. Thus, the diffusing capacity for carbon dioxide is about 20 times more than that of oxygen.

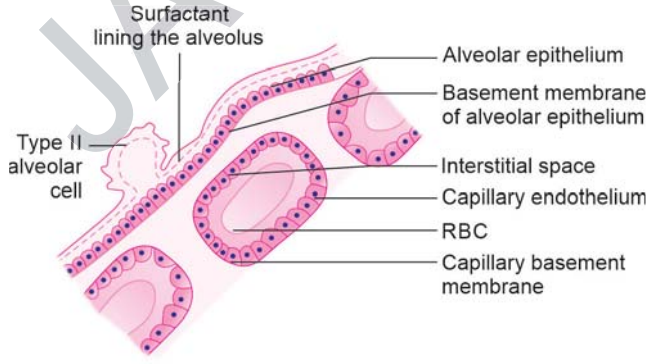

Fig. 4.31: Respiratory membrane (schematic representation).
(RBC: red blood cell)

TRANSPORT OF GASES BETWEEN LUNGS AND TISSUES

Transport of gases is one of the most important functions of the blood.

Transport of Oxygen

The partial pressure of dissolved O_2 (pO_2) in the pulmonary venous blood is 40 mm Hg and that in the alveolar air is 104 mm Hg **(Table 4.9)**. Because of this marked pressure gradient, O_2 diffuses from the alveolar air into the pulmonary capillary blood **(Fig. 4.32)**. However, the pO_2 becomes 100 mm Hg when the blood reaches the aorta. This is due to some mixing of blood occurring in the besian vessels and physiological shunts.

Methods by which O_2 is carried by the blood:

- About 97% of the O_2 transported from the lungs to the tissues is by chemical combination with Hb of RBCs.
- The rest 3% is carried in the dissolved state in plasma.
- The dissolved O_2 exerts the partial pressure, which actually determines the amount of O_2 that combines with hemoglobin. Thus, even though a small amount of O_2 is transported in dissolved form, it is very important in determining the total O transport.

Role of Hb in Oxygen Transport

Each of the four iron atoms of Hb can bind loosely and reversibly with one oxygen molecule, by oxygenation reaction (not oxidation), i.e.

$$Hb_4 + O_2 = Hb_4O_2$$
$$Hb_4O_2 + O_2 = Hb_4O_4$$

Table 4.9: Partial pressure of gases **(Figs. 4.32 to 4.35)**.

	In alveoli (mm Hg)	*In pulmonary capillaries (mm Hg)*	
		Arterial end	Venous end
pO_2	104	40	104
pCO_2	40	46	40

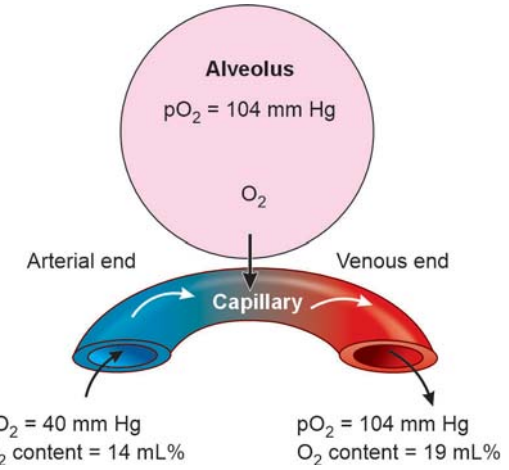

Fig. 4.32: Diffusion of oxygen from alveolus to pulmonary capillary (schematic representation).

JAYPEE BROTHERS

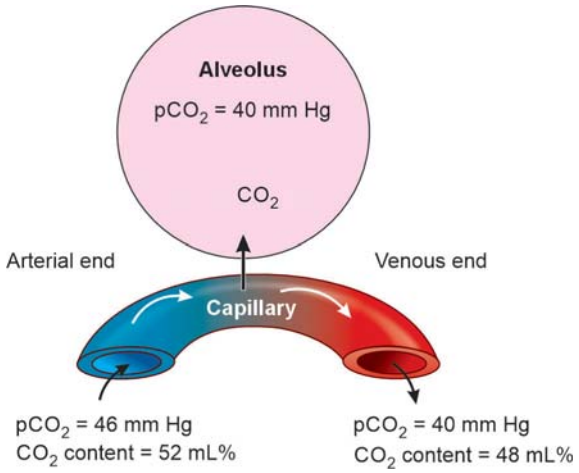

Fig. 4.33: Diffusion of carbon dioxide from pulmonary capillary to alveolus (schematic representation).

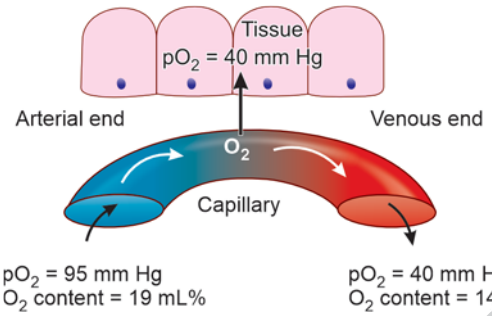

Fig. 4.34: Diffusion of oxygen from capillary to tissue (schematic representation).

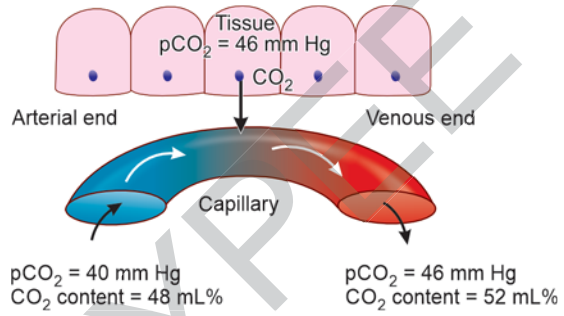

Fig. 4.35: Diffusion of carbon dioxide from tissue to pulmonary capillary (schematic representation).

$$Hb_4O_4 + O_2 = Hb_4O_6$$
$$Hb_4O_6 + O_2 = Hb_4O_8$$

The combination of the first heme in the Hb molecule with O_2 increases the affinity of the second heme for O_2 and oxygenation of the second increases the affinity of the third, etc. At a pO_2 of 100 mm Hg, Hb is fully saturated with oxygen.

One gram of Hb combines with 1.34 mL of O_2. Therefore, 15 g (average normal Hb) of Hb combine with $15 \times 1.34 \approx 20$ mL/100 mL of blood, i.e., each 100 mL of arterial blood can carry 20 mL of oxygen to the tissues. The maximum amount of O_2 that can be carried in the blood by Hb is called the oxygen carrying capacity of Hb **(20 mL/100 mL of blood)**. About 5 mL of O_2 is given off to the tissue.

Oxygen-Hemoglobin Dissociation Curve

This curve represents the relationship between the pO_2 and the degree of oxygen saturation of Hb **(Fig. 4.36)**. The curve is sigmoid shaped. This particular shape of the curve is due to the biological properties of Hb. When O combines with Hb, it assumes the relaxed or ***R-state***, which favors O_2 binding, and additional uptake of O_2 is facilitated. When all the four heme molecules have combined with O_2, it assumes the tense or T-state. The sigmoid shape is due to this T-interconversion.

At pO_2 values of 100 mm Hg or above, Hb is 100% saturated **(Fig. 4.36)**. Even when the pO_2 falls to 60 mm Hg, the Hb saturation is 90%. This provides a margin of safety when one ascends up to high altitudes, where there is decreased alveolar pO_2. Even then he will suffer only a small decrease in the arterial O_2 content.

Added Information

FACTORS AFFECTING OXYGEN DISSOCIATION CURVE

The important factors that affect the affinity of Hb for oxygen are:

- pH
- Temperature
- 2,3-DPG concentration in the RBC

A rise in temperature, a fall in pH and an increase in 2,3-DPG concentration can shift the O_2-Hb dissociation curve to right, i.e., there is decreased affinity of Hb for O_2 and more of O_2 is liberated or offloaded.

Bohr effect: The affinity of Hb for O_2 decreases when the pH of blood falls. This is called Bohr effect. At the tissue level, there is increased pCO_2 and decreased pO_2. This causes the Hb to liberate more O_2 into the tissues (Bohr effect).

The curve is shifted to the left by a fall in temperature, a rise in pH and a fall in 2,3-DPG concentration, i.e., the affinity of Hb for O_2 is more and their binding is favored. HbF or fetal Hb contains $a2g_2$ chains. G chains have little affinity for 2,3-DPG.

Contd...

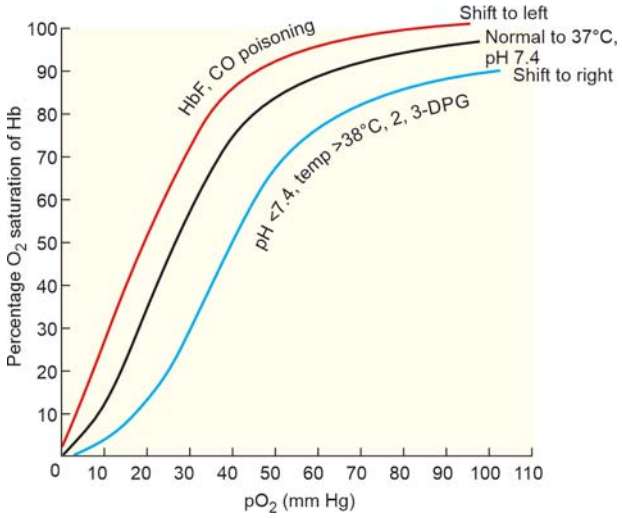

Fig. 4.36: Hemoglobin dissociation curve.

(CO: carbon monoxide; pO_2: partial oxygen; Hb: hemoglobin; 2,3–DPG: 2,3–diphosphoglycerate)

JAYPEE BROTHERS

Contd...

Hence HbF-O_2 dissociation curve is shifted to left when compared with the adult curve. The higher affinity of HbF for O_2 facilitates the extraction of O_2 by the fetus from the maternal circulation.

Transport of Carbon Dioxide

Carbon dioxide is carried in the blood in three forms:

1. ***As physically dissolved form:*** This accounts for about 10% of the total CO_2 in blood. CO_2 is 20 times more soluble in water than O_2.
2. ***As bicarbonate:*** About 80% of the CO_2 is transported
3. As bicarbonate CO_2 diffuses into the red cells where, in the presence of carbonic anhydrase enzyme, it rapidly reacts with water to form carbonic acid (H_2CO_3). The carbonic acid dissociates into HCO_3^- and H^+

$$H_2O + CO_2 \xrightarrow{\text{Carbonic anhydrase}} \begin{matrix} H_2CO_3 \\ \uparrow\downarrow \\ H^+ + HCO^-_3 \end{matrix}$$

H^+ ion formed is buffered by Hb, while HCO_3^- enters the plasma. DeoxyHb is a weaker acid than the oxyHb and, therefore, it binds to H^+ more than the oxyHb.

As the bicarbonate, which is formed in red cell, diffuses out to the plasma, Cl^- diffuses from the plasma into the red cells to maintain electrical neutrality. This phenomenon is called the *chloride shift* or *Hamburger shift*. This is the cause of the increased content of Cl^- in venous blood.

- ***As carbaminohemoglobin:*** About 10% of CO_2 is transported as carbaminohemoglobin CO_2 combines with the amino ($-NH_2$) group of Hb to form carbaminoHb.

$$R\text{-}NH_2 + CO_2 \; R\text{-}NH\text{-}COOH$$

No enzyme is required for this process. DeoxyHb can rapidly form carbamino compound than oxyHb. Therefore, in the tissues, where there is deoxyHb, the reaction shifts to right. In lungs, oxyHb shifts the reaction to left.

Added Information

HALDANE EFFECT

Deoxygenated Hb combines with more CO_2 compared to oxygenated Hb at any PO_2. This is called Haldane effect. Binding of O_2 to Hb thus reduces its affinity for CO_2.

Significance of Haldane Effect

Haldane's effect is essential for release of carbon dioxide from blood into the alveoli of lungs and uptake of oxygen by the blood.

Carbon Dioxide Dissociation Curve

This curve shows the relationship between pCO_2 and total CO_2 content of blood **(Fig. 4.37)**. The relationship is linear over a wide range of pCO_2, than in case of O_2-Hb dissociation curve. When Hb is oxygenated, the CO_2 dissociation curve shifts to the right, i.e., CO_2 is removed (Haldane effect) **(Fig. 4.37)**.

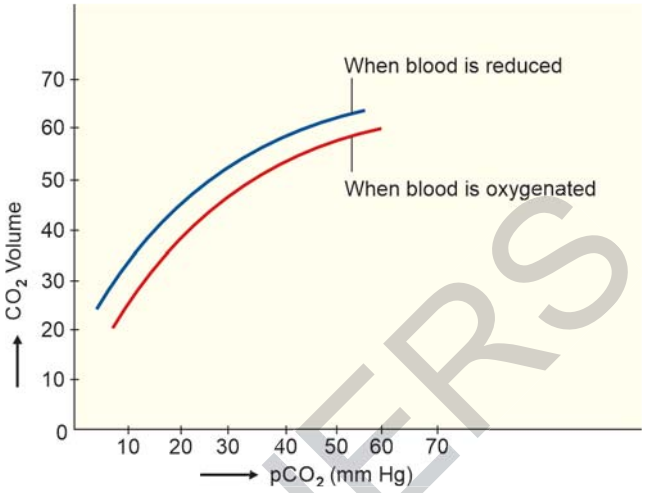

Fig. 4.37: Caron dioxide dissociation curve.
(pCO_2: partial carbon dioxide)

REGULATION OF RESPIRATION

Respiration is an automatic process that occurs without any conscious effort while we are asleep or awake. Rhythmical excitation of respiratory muscles occurs as a result of multiple neuronal interactions involving all levels of the nervous system.

Various neural and hormonal stimuli as well as chemical changes in blood (i.e. changes in blood pO_2, pCO_2 and pH) can influence the central control of respiration. Hence, regulation of respiration can be broadly classified as "Neural regulation" and "Chemical regulation".

NERVOUS CONTROL OF RESPIRATION

Nervous regulation of respiration includes:

- Voluntary control
- Automatic control

Voluntary Control

Respiration is a spontaneous (reflex) process. But to some extent, it can be controlled voluntarily because most of the muscles concerned with respiration are voluntary muscles. The center for voluntary control is the ***motor cortex***, which sends impulses through the corticospinal tract to the respiratory motor neurons.

Automatic Control

The automatic centers for control of respiration are located in the pons and medulla. The respiratory centers are located bilaterally **(Fig. 4.38)**.

Medullary Centers

- Pre-Botzinger complex
- Dorsal respiratory group (DRG) of neurons
- Ventral respiratory group (VRG).

JAYPEE BROTHERS

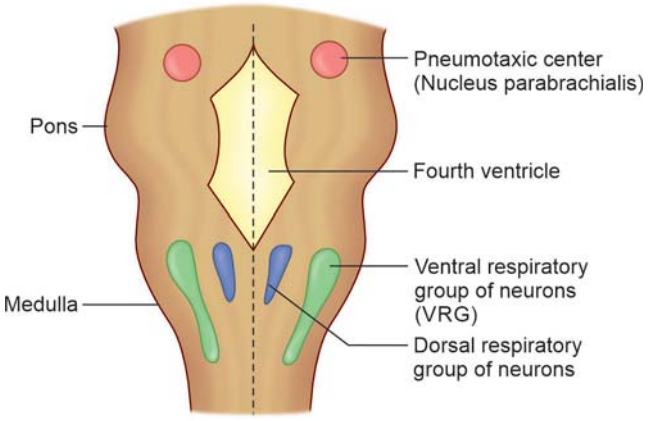

Fig. 4.38: Neural respiratory centers in the brainstem.

Pre-Botzinger complex is a group of pacemaker cells located on both sides of upper medulla. They spontaneously discharge and are responsible for the rhythmicity of respiration.

DRG is located in and near the nucleus of tractus solitarius (NTS). DRG is made up of I (inspiratory) neurons. They are active during inspiration. They also receive impulses from lungs, chemoreceptors, and baroreceptors through vagus **(Flowchart 4.4)**.

VRG is located in the ventrolateral part of medulla. It extends through ***nucleus ambiguus***. VRG is made up of 'E' (expiratory) neurons mainly. 'E' neurons inhibit 'I' neurons in expiration.

Pontine Centers

Although the rhythmic discharge of medullary respiratory neurons is spontaneous, it is modified by neurons in the pons. In the upper part of pons there is a pair of respiratory centers called ***pneumotaxic center***. Pneumotaxic center has inhibitory effect on 'I' neurons. When this area is stimulated, I neurons are inhibited. Respiration becomes shallow and rapid.

Flowchart 4.4: Process of inspiration.

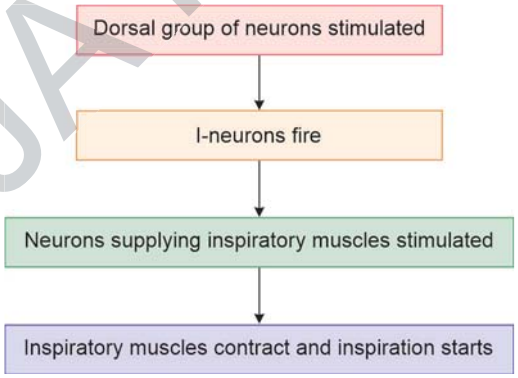

Vagal Influences on Respiration

Stretch of the lungs during inspiration stimulates stretch receptors in lung which generates vagal fibers. These impulses inhibit 'I' neurons and produce expiration.

Added Information

Hering-Breuer Reflex
Stretch receptors are present in the smooth muscles of bronchial wall. They are stimulated when the lung inflates above the tidal volume. Afferent impulses from these stretch receptors reach the nucleus of tractus solitarius of medulla, via the vagus nerve. These impulses inhibit inspiratory neuron discharge and limit the tidal volume, thereby increasing the respiratory rate. This phenomenon is called Hering-Breuer reflex.

Chemical Control of Respiration

Chemical control of respiration is exerted through the central and peripheral chemoreceptors **(Fig. 4.39)**. The chemoreceptors respond to changes in the pH, pO_2 and pCO_2 of blood.

A rise in pCO_2, arise in H^+ concentration or a decrease in pO_2 can stimulate respiration.

Central Chemoreceptors

They are located in the medulla, near the origin of IX and X cranial nerves.

Peripheral Chemoreceptors

They are the carotid and aortic bodies. Carotid bodies are located at the bifurcation of the common carotid arteries. The aortic bodies are located in the arch of aorta **(Fig. 4.39)**.

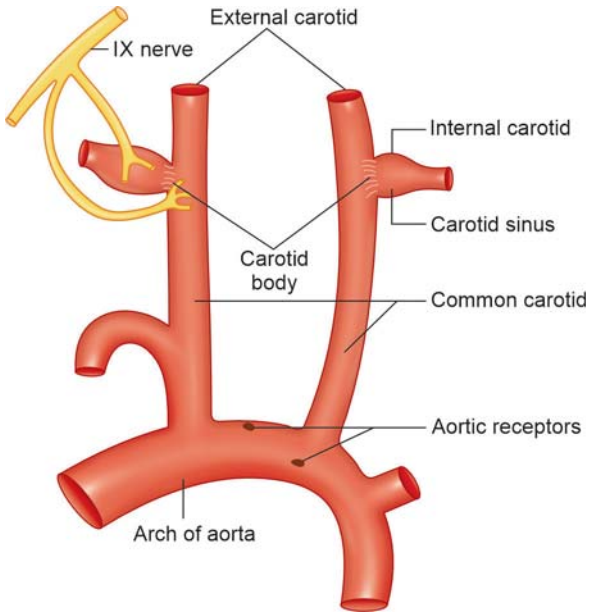

Fig. 4.39: Peripheral chemoreceptors (schematic representation).

JAYPEE BROTHERS

APPLICATION AND IMPLICATION IN NURSING

RESPIRATORY ADJUSTMENTS IN HEALTH AND DISEASE

This topic deals with the following aspects:

- Respiratory adjustments to different stresses in day-to-day life (e.g., during exercise, at high altitude, etc.).
- Abnormal respiratory patterns
- Respiratory disturbances like hypoxia
- Artificial respiration.
- *Respiratory adjustments during exercise:* During exercise, many complex adjustments are occurring in our body regarding the blood flow, basal metabolism, cardiovascular system, respiratory system, temperature regulation, secretion of hormones, etc. Of these, the important adjustments that occur in respiratory system are discussed below.

In mild and moderate exercises (e.g., steady and slow running or jogging), the increased O_2 uptake can be met by the body metabolism itself. But in severe exercise, the O_2 uptake or requirement shoots up to be >2 liters/minutes 85% of energy required for severe exercise comes from anerobic metabolism. So, there occurs an O_2 debt. O_2 debt includes the extra amount of O_2 consumed after exercise in order to remove excess lactate accumulation and to restore the ATP and creatine phosphate stores as well as to restore the small amount of oxygen that comes from myoglobin.

To meet the O_2 debt, following changes in respiration occur:

- Increased ventilation, due to stimuli like increased body temperature, accumulation of K^+, increased sensitivity to CO_2 during exercise, hypoxia, etc. There is an increase in the depth as in the well as rate of ventilation.
- Increased diffusion of O_2 into the pulmonary capillaries, i.e., increased pulmonary oxygen-diffusing capacity.
- There is no change in vital capacity.
- *Respiratory adjustments at high altitude:* At high altitudes, the percentage of oxygen in the atmosphere is the same as at the sea level, but the barometric pressure is low and so the partial pressure of oxygen is proportionately decreased.

MOUNTAIN SICKNESS

Mountain sickness or high altitude sickness occurs when a person, residing at sea level, ascends to a high altitude. Initially, he experiences the symptoms of hypoxia like breathlessness, headache, dizziness, palpitation, nausea, partial deafness, etc. These symptoms may disappear after a few days or weeks, due to a number of adjustments occurring in the body. This phenomenon by which they develop compensatory mechanisms is called *acclimatization.*

The compensatory mechanisms are:

- Hyperventilation to raise the arterial pO_2
- Increased erythropoietin secretion
- Polycythemia
- Increase in myoglobin and cytochrome oxidase enzyme
- Increase in 2, 3-DPG, causing the O_2-Hb dissociation curve to shift to right.
- Renal compensatory changes like renal alkalosis, leading to excretion of excess bicarbonate in urine.
- Increase in heart rate as well as cardiac output.
- *Decompression sickness or Caisson's disease:* Typically, this condition can occur when a diver, who was under the sea, is brought to the surface rapidly; or when an airplane without pressurized cabin ascends suddenly.

When the diver is beneath the sea for a long time, large amount of nitrogen gets dissolved in his body fluids. As he suddenly ascends to the surface of the sea, the dissolved N_2 diffuses out in the form of bubbles. These N_2 bubbles can block the blood vessels of heart, brain and kidney. The symptoms which result, constitute the decompression sickness, also called the "bends" or "Caisson's disease".

SYMPTOMS

- Pain in the muscles and joints
- Dizziness and unconsciousness
- Dyspnea or "chokes" (due to blocking of pulmonary capillaries by bubbles).

PREVENTION AND TREATMENT

Caisson's disease can be prevented by gradually and slowly bringing the diver to the sea surface. Treatment is by immediate recompression in a pressurized tank followed by slow decompression to normal atmospheric pressure.

ABNORMAL RESPIRATORY PATTERN

Eupnea means the normal respiratory pattern.

Apnea means temporary stoppage of breathing.

Dyspnea means increased pulmonary ventilation or difficult labored breathing where the person is aware of shortness of breath. A normal person is not aware of his respiration, until it is doubled. Dyspnea is one of the most important signs of lung diseases.

Causes of dyspnea are as follows:

- Respiratory diseases–like bronchial asthma, pneumonia, pleural effusion, pneumothorax, emphysema, etc.
- Cardiovascular diseases–like congestive cardiac failure
- Metabolic disorders–like acidosis, ketosis, hyperthyroidism, etc.

Contd...

JAYPEE BROTHERS

Contd...

- Anemia
- Dyspnea occurring in lying down position is called orthopnea, usually seen in cardiac failure.
- **Periodic breathing** is an abnormal pattern of respiration, which is characterized by alternate periods of respiratory activity and apnea. Two types of periodic breathing are usually seen:
  - Cheyne-Stokes breathing
  - Biot's breathing.

CHEYNE–STOKES BREATHING (FIG. 4.40)

It is a form of periodic breathing, which is characterized by a series of respirations that gradually increase in depth, reach a maximum and then progressively decline to stop in a state of apnea lasting for a few seconds. Again, breathing gradually begins and the whole cycle is repeated. This type of periodic breathing is normally seen in infants and in high altitudes. It is pathologically seen in:

- Uremia
- Heart failure
- After head injury

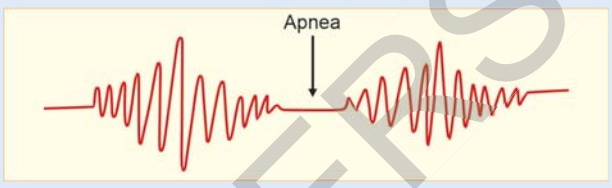

Fig. 4.40: Cheyne–Stokes breathing (schematic representation)

BIOT'S BREATHING

It is characterized by irregular episodes of respiratory activity and apnea. There is no waxing and waning pattern of respiration as in Cheyne-Stokes breathing.

This type of periodic breathing is seen in:

- Meningitis
- Pontine hemorrhage
- Cerebral ischemia.

HYPOXIA

Hypoxia means oxygen deficiency at the tissue level. Hypoxia can be of four types:

- Hypoxic hypoxia or anoxic hypoxia
- Anemic hypoxia
- Stagnant or ischemic hypoxia
- Histotoxic hypoxia.

HYPOXIC HYPOXIA

This is the most common type of hypoxia. It is due to a low pO_2 level in arterial blood. Conditions causing hypoxic hypoxia are:

- High altitude
- Obstruction of airways
- Pulmonary edema
- Asthma
- Congenital heart diseases.

ANEMIC HYPOXIA

Here the arterial PO_2 is normal, but the O_2 carrying capacity of the blood is reduced, i.e. the amount of Hb available for O_2 transport is reduced. Apart from severe anemia, this can also occur in carbon monoxide poisoning, where there is increased formation of carbon-monoxy Hb compound and there is less available Hb for O_2 transport.

STAGNANT HYPOXIA

This occurs when the tissue blood flow is markedly reduced as in shock, heart failure or local obstruction. Here pCO_2 and Hb concentration are normal.

HISTOTOXIC HYPOXIA

This occurs in cyanide poisoning, where cyanide inhibits the enzyme cytochrome oxidase required for tissue oxidation. Therefore, the cells cannot utilize the O_2 supplied to them.

CYANOSIS

Cyanosis means bluish discoloration of skin and mucous membranes due to excessive amount of reduced or deoxygenated Hb in blood (≥ 5 g%). A person with severe anemia cannot become cyanotic as there is no adequate Hb to be reduced.

Cyanosis is clinically diagnosed by looking under the tongue or nail beds of the patient. According to the region affected, cyanosis can be *peripheral and central*.

Central cyanosis is due to:

- Heart diseases
- Lung diseases

Contd...

JAYPEE BROTHERS

Contd...

- Hypertension
- Warm periphery

Peripheral cyanosis is due to:

- Circulatory shock
- Exposure to severe cold
- There is severe peripheral vasoconstriction.

Learning Capsule

- Alveolus is the functional unit of gas exchange. There are 300 million alveoli in humans
- Adenoids consist of lymphoid tissues; they are prominent in children up to 14 years of age and after that they atrophied gradually.
- The important function of Waldeyer's lymphatic ring (tonsils) is the production of antibody against common environmental antigens
- Posterior cricoarytenoid is known as the life saving muscle as it permits the air pass in and out through the abduction of vocal cords
- The longest known lung reflex is the Hering-Breuer reflex (inflation reflex), which is stimulated by inflation of the lung during inspiration. The reflex response is to inhibit inspiration. This reflex is too weak to control the depth of the tidal volume during normal breathing
- There is a circadian rhythm in bronchial tone, with maximal constriction at about 6 AM and maximal dilatation at 6 PM. That is why asthma attacks are more severe in the late night and early morning hours
- Hyperbaric oxygen therapy is the administration of 100% oxygen at increased pressure (2,000 mm Hg or 3 atmospheres). This achieves 6 mL/dL of dissolved oxygen.
- The chief muscle of inspiration is diaphragm. Diaphragm is a thin, dome-shaped muscle that separates the abdominal cavity from the thoracic cavity.

JAYPEE BROTHERS

for detailed information on nursing books, visit our website www.ejaypee.com, for detailed information on nursing books, visit our website www.ejayp

Textbook of Applied Anatomy and Physiology for Nurses

Salient Features

- Helpful textbook for nurses as it covers all major body systems, organs, tissues and their functions in detail.
- Rich visual aids, more than 800 diagrams and photographs, about 100 tables and 100 flowcharts are used to help in understanding the anatomy.
- Clear, concise, and easy-to-understand explanations of complex anatomical and physiological concepts without overwhelming jargon.
- Additional resources such as online access to videos, and complementary practice workbook to enhance learning and understanding.
- Pedagogical tools like tables, boxes, mnemonics, charts, learning capsules, extra knowledge bites, appendices, quick scan, nursing implications and clinical correlations to facilitate and retention of information.
- Use of Lucid language for better understanding.
- Prenatal diagnosis of genetic disorders is gaining more importance in the prevention of birth of children with serious congenital anomalies.
- Review questions are added at the end of each chapter, which will enable the students to face the examination with confidence.

PR Ashalatha MBBS MS (Anatomy) is currently working as Professor and Head, Department of Anatomy, Malabar Medical College and Research Centre, Former Professor and Head, Government Medical College, Kozhikode, Kerala, India. She graduated from Government Medical College, Kozhikode in the year 1988 and did her postgraduation in Anatomy from the same institution. Students of this institution have selected her as the "Best Teacher in Anatomy". She is the author of *Textbook of Anatomy for Nurses* and *Textbook of Anatomy and Physiology for GNM Students*. She has keen interest in medical genetics and has undergone training in genetics from AIIMS, New Delhi; CCMB, Hyderabad and CMC, Vellore. She has published several research papers in international journals.

G Deepa MBBS MD (Physiology) is Associate Professor, Department of Physiology, Government Medical College, Thiruvananthapuram, Kerala, India. She graduated in Medicine from Government TD Medical College, Alappuzha, Kerala and Masters in Physiology from Government Medical College, Kozhikode, Kerala. She is interested in research in medical physiology and has published research articles.

Scan for more nursing titles...

Buy from ejaypee

JAYPEE BROTHERS

ISBN 978-93-6616-462-5