tomy books, visit our website www.jaypeebrothers.com, for detailed information on anatomy books, visit our website www.jaypeebrothers.com, for detailed information on anatomy books

Complimentary Online
Dissection & Model Videos
121 Videos (Duration 3 hours)
only with Genuine Book

diginerve
A Jaypee Initiative
• Video Lectures • Dr. Wise AI Chatbot
• Question Bank • Notes
Download App

Volume 2

Dissection Manual

With Regions & Applied Anatomy

Lower Extremity, Abdomen, Pelvis and Perineum


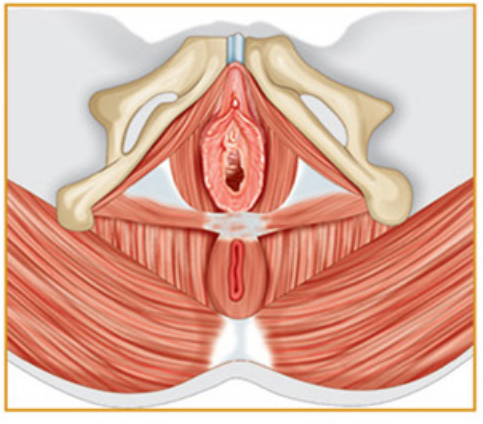
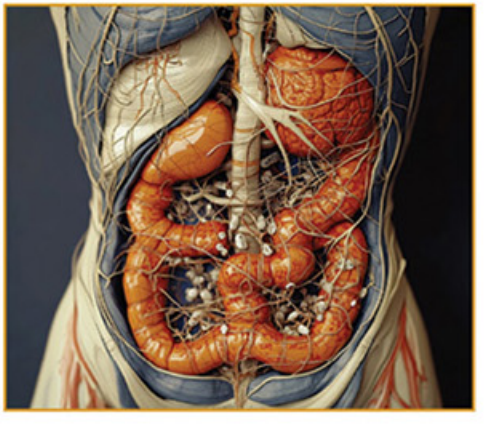

Mercy Navis

Forewords KS Ravindranath • Sriprakash KS

2nd Edition

JAYPEE

CONTENTS

SECTION 1 Lower Extremity

Chapter 1 Bones of the Lower Extremity 3
- Landmarks 3
- Hip Bone 4
- Femur 5
- Patella 5
- Tibia 6
- Fibula 6
- Bones of the Foot 7

Chapter 2 Anterior Compartment of the Thigh 10
- Landmarks 10
- Skin Incisions 10
- Great Saphenous Vein and Inguinal Lymph Nodes 11
- Cutaneous Nerves 12
- Fascia Lata 12
- Deep Inguinal Lymph Nodes, Inguinal Ligament and Femoral Sheath 14
- Femoral Triangle 15
- Muscles and Nerves 16
- Adductor Canal 20
- Femoral Nerve 21

Related Videos *(See Page xxi)*
1. Anterior Thigh and Anterior Leg
2. Femoral Nerve and Dorsum of Foot

Chapter 3 Medial Compartment of the Thigh 22
- Landmarks 22
- Medial Compartment of the Thigh 22
- Muscles 23
- Obturator Nerve 24
- Obturator Externus 25
- Obturator Artery 26

Related Videos *(See Page xxi)*
3. Medial Compartment of Thigh
4. Muscles of the Anterior and Medial Thigh

Chapter 4 Gluteal Region 27
- Landmarks 27
- Skin Incision 27
- Cutaneous Nerves 28
- Gluteal Muscles 28

Chapter 5 Posterior Compartment of the Thigh 35
- Skin Incision 35
- Cutaneous Nerves 35
- Hamstring Muscles 36
- Arteries 38

Related Videos *(See Page xxi-xxii)*
5. Femoral Artery and Branches
6. Gluteal Region and Posterior Thigh

Chapter 6 Popliteal Fossa 39
- Landmarks 39
- Cutaneous Nerves 39
- Deep Fascia of the Leg 40
- Popliteal Fossa 40
- Contents of the Popliteal Fossa 41

Chapter 7 Anterior Compartment of the Leg 44
- Landmarks 44
- Skin Incision 44
- Nerves 44
- Muscles of Anterior Compartment of Leg 45

Chapter 8 Lateral Compartment and Medial Side of the Leg 48
- Landmarks 48
- Lateral Compartment of the Leg 48
- Medial Side of the Leg 50

Chapter 9 Ankle Region and Dorsum of the Foot 52
- Landmarks 52
- Structures around the Ankle 52
- Structure in the Dorsum of the Foot 54

Related Videos *(See Page xxii-xxiii)*
7. Posterior Thigh, Popliteal Fossa and Lateral Leg
8. Popliteal Fossa and Lateral Leg
9. Anterior Thigh, Knee Joint, Lateral Leg and Dorsum of the Foot
10. Anterior Leg and Dorsum of Foot
11. Dorsum of the Foot

Chapter 10 Posterior Compartment of the Leg 58
- Landmarks 58
- Vessels, Nerves and Muscles 58
- Superficial Muscles 59
- Deep Muscles 60
- Nerves 62
- Arteries 63

Related Videos *(See Page xxiii)*
12. Popliteal Fossa and Posterior Leg
13. Posterior Leg
14. Deep Structures of Posterior Leg

Chapter 11 Plantar Region (Sole of the Foot) 65
- Landmarks 65
- Plantar Aponeurosis 65
- Cutaneous Nerves in Sole 66
- First Layer of Sole 67
- Second Layer of Sole 68
- Third Layer of Sole 69
- Fourth Layer of Sole 70
- Nerves and Arteries 72

Related Videos *(See Page xxiii-xxiv)*
15. First and Second Layers of Sole
16. Sole of the Foot
17. Muscles and Nerves of the Sole

Chapter 12 Joints of Lower Extremity 75
- Hip Joint 75
- Ligaments of the Knee Joint 77
- Tibiofibular Joint 78
- Ankle Joint 79
- Subtalar Joint 80
- Talocalcaneonavicular Joint 81
- Calcaneocuboid Joint 81
- Cuneonavicular Joint 82
- Cuboideonavicular Joint 82
- Tarsometatarsal Joint 83
- Intermetatarsal Joints 83
- Metatarsophalangeal Joints 83
- Interphalangeal Joint 84
- Arches of Foot 84

SECTION 2 Abdomen

Chapter 13 Bones of Abdomen 89
- Lumbar Vertebra 89

Chapter 14 Anterior Abdominal Wall 91
- Landmarks 91
- Boundaries of Abdomen 92
- Skin Incision 93
- Superficial Fascia 93
- Fascia and Vessels 94
- Muscles of the Anterior Abdominal Wall 95
- Rectus Sheath 99
- Inguinal (Hesselbach's) Triangle 101

Related Video *(See Page xxiv)*
1. Posterior Wall of the Rectus Sheath

Chapter 15 Male External Genital Organs 102
- Landmarks 102
- Structure of the Spermatic Cord 102

Related Video *(See Page xxiv)*
2. Testis and Spermatic Cord

Chapter 16 Loin Region 107
- Landmarks 107
- Thoracolumbar Fascia and Lumbar Triangle 107

Chapter 17 Abdominal Cavity and Peritoneum 109
- Peritoneum and Abdominal Viscera 109
- Greater Omentum, Lesser Omentum and Mesentery Proper 111
- Peritoneal Recesses 112

Chapter 18 Abdominal Part of Esophagus, Stomach, Celiac Trunk and Spleen 113
- Abdominal Part of Esophagus 113
- Stomach 114
- Arteries of Stomach 116
- Spleen 118

Chapter 19 Duodenum, Pancreas and Portal Vein 120
- Duodenum 120
- Pancreas 121
- Suspensory Muscle of Duodenum and Portal Vein 123
- Portocaval Anastomosis 123
- Splenic Vein 124
- Inferior Mesenteric Vein 124

Related Videos *(See Page xxiv-xxv)*
3. Duodenum, Liver and Omentum
4. Celiac Trunk and Liver
5. Celiac Trunk
6. Branches of the Celiac Trunk

7. Left Gastric, Splenic and Hepatic Arteries
8. Stomach, Spleen and Pancreas
9. Spleen and Blood Vessels

Chapter 20 Small and Large Intestines 125

- Small Intestine 125
- Large Intestine 126

Related Videos *(See Page xxv)*
10. Small and Large Intestines
11. Large Intestine and Inferior Mesenteric Artery
12. Small, Large Intestines and Female Pelvic Organs

Chapter 21 Superior and Inferior Mesenteric Vessels 128

- Superior Mesenteric Artery and Vein 128
- Inferior Mesenteric Artery and Vein 130
- Lymph Nodes 131

Related Videos *(See Page xxv)*
13. Superior Mesenteric Artery
14. Superior Mesenteric Vessels
15. Abdominal Aorta, Inferior Mesenteric Artery and Nerves

Chapter 22 Liver, Gall Bladder and Biliary Ducts 132

- Liver 132
- Biliary Apparatus 134

Related Videos *(See Page xxvi)*
16. Liver
17. Ligaments of Liver
18. Diaphragm and Liver

Chapter 23 Kidney, Ureter and Suprarenal Gland 136

- Kidneys 136
- Ureters 139
- Suprarenal (Adrenal) Glands 140

Related Videos *(See Page xxvii)*
19. Left Kidney, Muscles and Nerves
20. Arcuate Ligaments and Left Kidney
21. Section of the Kidney

Chapter 24 Diaphragm and Posterior Abdominal Wall 142

- Diaphragm 143
- Abdominal Aorta 144
- Inferior Vena Cava 146
- Lymph Nodes of Posterior Abdominal Wall 146
- Cisterna Chyli 147
- Fascia and Muscles of Posterior Abdominal Wall 147
- Nerves of Posterior Abdominal Wall 149
- Celiac Ganglion 151
- Hypogastric Plexuses 152

Related Videos *(See Page xxvii-xxviii)*
22. Posterior Abdominal Wall
23. Posterior Abdominal Wall and Female Pelvic Organs
24. Nerves and Diaphragm
25. Muscles and Female Pelvic Organs

SECTION 3 Pelvis

Chapter 25 Bones of Pelvis 155

- Bony Pelvis 155

Chapter 26 Male Pelvic Organs (Urinary Bladder, Prostate, Seminal Vesicle and Urethra) 157

- Male Pelvic Organs 157
- Urinary Bladder 158
- Relations of the Urinary Bladder 159
- Vas (Ductus) Deferens 160
- Seminal Vesicle 161
- Ejaculatory Duct 161
- Prostate Gland 161

Related Videos *(See Page xxviii)*
1. Male Pelvis
2. Cross Section of the Penis

Chapter 27 Female Reproductive Organs (Uterus, Vagina and Ovary) 163

- Female Pelvic Organs 163
- Vagina 168
- Ovaries 170

Related Video *(See Page xxviii)*
3. Female Pelvis

Chapter 28 Rectum and Anal Canal 171

- Rectum 171
- Anal Canal 174

Chapter 29 Muscles, Vessels and Nerves of Pelvis 176

- Muscles of Pelvis 176
- Blood Vessels of the Pelvis 179
- Nerves of the Pelvis 182
- Joints of the Pelvis 186



Related Videos *(See Page xxviii-xxix)*

4. Nerves and Blood Vessels
5. Iliac Arteries and Nerves
6. Internal Iliac Artery and Nerves of the Pelvis
7. Muscles, Nerves and Vessels of Male Pelvis
8. Muscles and Nerves of Male Pelvis
9. Muscles, Nerves and Vessels of Female Pelvis

SECTION 4 Perineum

Chapter 30 Perineum 191

- Perineum and its Divisions 191
- Urogenital Triangle 192
- Deep Transversus Perinei and Compressor Urethrae 201
- Perineal Fascia 201
- Perineal Body 202
- Anal Triangle 202
- Pudendal Nerve 203
- Internal Pudendal Artery 204
- Anococcygeal Ligament 204

Index 205

CHAPTER

4

Gluteal Region

JAYPEE BROTHERS

LEARNING OBJECTIVES

At the end of the dissection of gluteal region, the students will be able to identify the following structures:

1. Cutaneous nerves
2. Muscles of gluteal region
3. Superior and inferior gluteal nerves
4. Short lateral rotators of thigh
5. Superior and inferior gluteal arteries
6. Sciatic nerve
7. Sacrotuberous and sacrospinous ligaments

Introduction

1. Gluteal region consists of gluteus maximus, medius and minimus.
2. Short lateral rotators include the piriformis, superior gamelli, inferior gamelli, obturator internus, obturator externus and quadratus femoris.
3. The sciatic nerve emerges from the pelvis through the greater sciatic foramen.
4. The greater and lesser sciatic foramina transmit several structures.
5. Piriformis divides the greater sciatic foramen into two compartments.

Landmarks

1. Gluteal surface of ilium
2. Gluteal fold
3. Posterior superior iliac spine
4. Iliac crest
5. Greater trochanter
6. Gluteal tuberosity
7. Sacrum and coccyx
8. Ischial tuberosity.

Skin Incision

Skin incision marked in Figure 4.1.

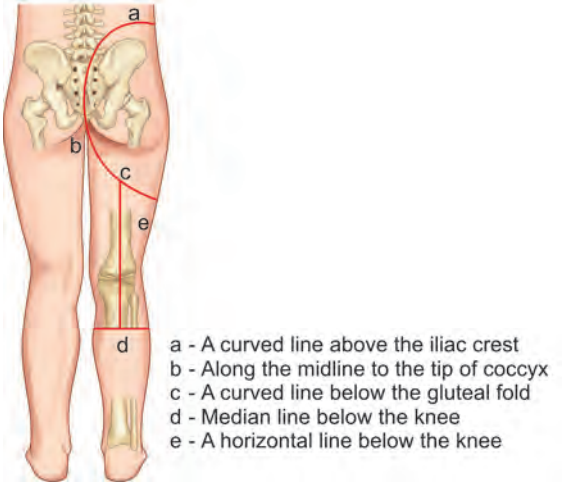

Fig. 4.1: Incisions

Cutaneous Nerves (Fig. 4.2)

Dissection

1. The body should be in prone position (face down), make a vertical incision from the spine of L5 vertebra to coccyx and a curved incision along the curve of iliac crest.
2. An oblique incision from coccyx along the gluteal fold, downwards and laterally to the middle of thigh and reflect the skin from the midline laterally.
3. Clean the large amount of fat in the **superficial fascia** of gluteal region and pay attention not to cut the **cutaneous nerves.**
4. Trace the **lateral cutaneous branch of subcostal nerve** close to iliac crest and trace the **lateral cutaneous branch of iliohypogastric nerve.**
5. Trace the dorsal rami of L1, L2, L3 nerves, dorsal rami of S1, S2, S3 nerves and **gluteal branches of posterior cutaneous nerve of thigh.**

Lateral cutaneous branch of the subcostal nerve supplies the skin of anterior part of gluteal region.

Lateral cutaneous branch of iliohypogastric nerve (L1) supplies the skin of posterolateral part of gluteal region.

Posterior branch of lateral cutaneous nerve of thigh supplies the skin of anteroinferior aspect of gluteal region.

Dorsal rami of L1, L2, L3 nerves supply the skin of gluteal region and as far as greater trochanter.

Dorsal rami of of S1, S2, S3 nerves supply the skin over posterior part of gluteal region.

Gluteal branches of posterior cutaneous nerve of thigh supply the skin over lower and lateral part of gluteus maximus.

Perforating branches of S2, S3 nerves supply the skin of medial and intermedial aspects of gluteal region.

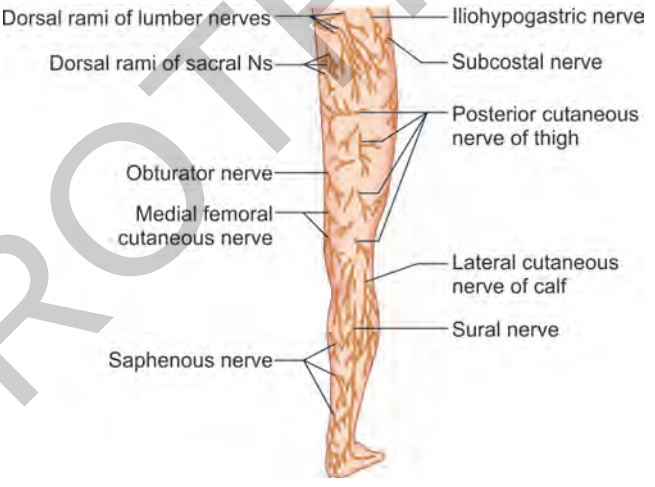

Fig. 4.2: Cutaneous nerves of gluteal region

Gluteal Muscles

Dissection

1. Remove the **fat** from **superficial fascia** and clean the deep fascia on **gluteus maximus** muscle and observe the deep fascia which is thick over the anterior border of muscle where the **iliotibial tract** splits to enclose the muscle.
2. Cut the **deep fascia** and expose **gluteus maximus** muscle and trace the upper and lower borders of the muscle.
3. Look for the branches of **posterior cutaneous nerve of thigh** along the lower border of the muscle and follow them upwards to the trunk of the nerve.
4. Observe the origin of gluteus maximus muscle from sacrum, coccyx and sacrotuberous ligament and its insertion into the iliotibial tract.

Gluteus Maximus

Gluteus maximus is a broad, thick, large and powerful muscle (Fig. 4.3).

It takes **origin** from the posterior gluteal line of ilium, iliac crest, dorsal surface of sacrum, coccyx, and sacrotuberous ligament, the superficial fibers **insert** into iliotibial tract and deeper fibers **insert** into the gluteal tuberosity of femur**.**

Innervated by inferior gluteal nerve.

Actions, it is a powerful extensor of hip joint, its upper fibers are active in powerful abduction of thigh and with tensor fascia lata, it stabilizes the pelvis on thigh and steadies the femur on tibia.

JAYPEE BROTHERS

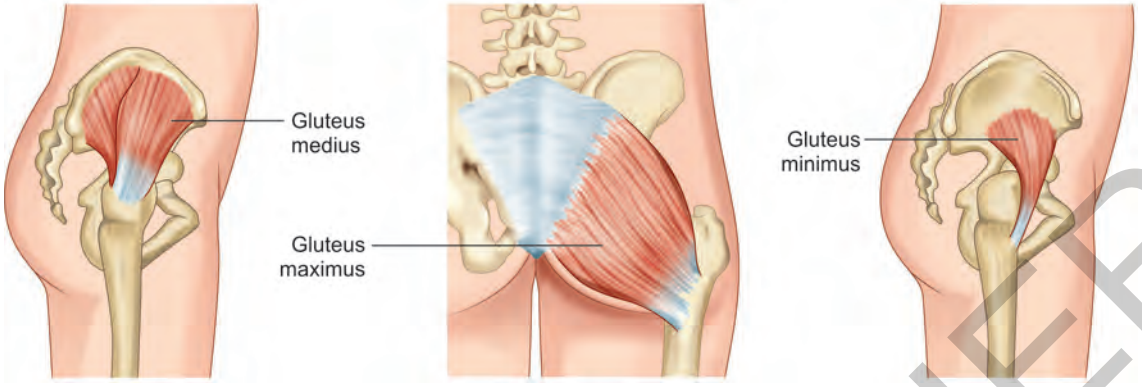

Fig. 4.3: Gluteal muscles

Structures Deep to Gluteus Maximus

Dissection

1. Cut the **gluteus maximus** from its origin, sacrum, coccyx, ilium and sacrotuberous ligament and reflect it laterally towards insertion.
2. While reflecting, insert two fingers deep to lower border of the muscle to avoid the injury to inferior gluteal nerves and vessels.
3. Trace the **inferior gluteal nerve** and **vessels** entering the deep surface of gluteus maximus muscle.
4. Look for the **trochanteric bursa** separating the muscle from greater trochanter, close to gluteal tuberosity and trace the **posterior cutaneous nerve of thigh** on the deep surface of medial part of the muscle.
5. Trace the inferior gluteal nerve and vessels along the lower part of the muscle and observe the superficial part of **superior gluteal nerve** and **vessels** entering upper part of the muscle.
6. Look for the **gluteofemoral bursa** between the muscle and upper part of vastus lateralis and **ischial bursa** between the muscle and ischial tuberosity.
7. Detach the muscle fibers from sacrotuberous ligament and observe the **perforating branches of posterior cutaneous nerve of thigh.**

Muscles

Muscles deep to gluteus maximus include gluteus medius, gluteus minimus, piriformis, superior gamellus, tendon of obturator internus, inferior gamellus and quadratus femoris, and the vessels include superior gluteal, inferior gluteal and internal pudendal vessels (Fig. 4.4).

Nerves

Nerves deep to gluteus maximus include the sciactic nerve, posterior cutaneous nerve of thigh, superior gluteal nerve, inferior gluteal nerve, pudendal nerve, nerve to obturator internus and nerve to quadratus femoris (Fig. 4.5).

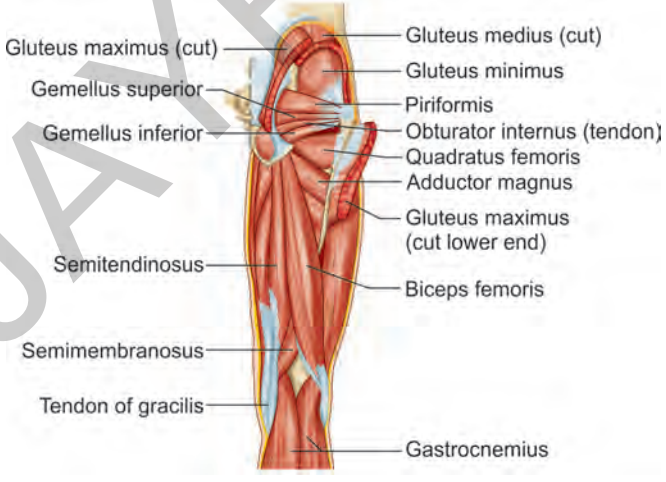

Fig. 4.4: Muscles deep to gluteus maximus

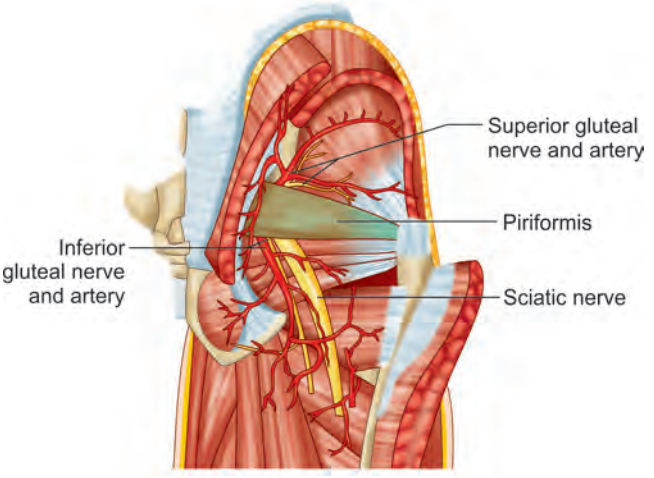

Fig. 4.5: Nerves and arteries deep to gluteus maximus

JAYPEE BROTHERS

Ligaments

Sacrotuberous ligament is attached to posterior superior iliac spines, lateral margin of lower part of sacrum and upper part of coccyx and the fibers run downwards and laterally and attach to medial margin of ischial tuberosity.

Sacrospinous ligament is attached to ischial spine and medially to lateral margin of sacrum and coccyx.

These two ligaments convert the greater and lesser sciatic notches into greater and lesser sciatic foramen.

Sciatic Foramina

Greater sciatic foramen is partially filled by piriformis muscle, which divides it into two parts (Fig. 4.6).

Above piriformis pass superior gluteal nerve and vessels.

Below piriformis pass inferior gluteal nerve and vessels, internal pudendal vessels, pudendal nerve, sciatic nerve, posterior cutaneous nerve of thigh, nerve to obturator internus and nerve to quadratus femoris.

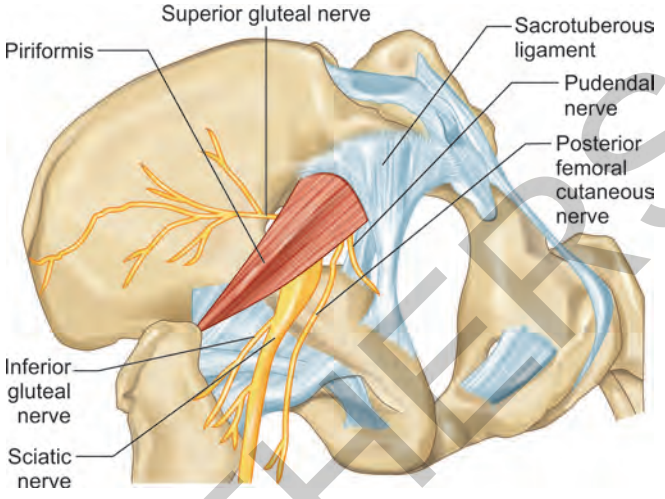

Fig. 4.6: Greater sciatic foramen

Lesser sciatic foramen transmits the tendon of obturator internus, nerve to obturator internus, internal pudendal vessels and the pudendal nerve.

Gluteus Medius and Minimus

Dissection

1. Remove the fascia on gluteus medius and piriformis muscles and trace the **superior gluteal nerve** and **vessels** between gluteus medius and piriformis.
2. Cut the **gluteus medius** muscle and reflect it laterally and follow its tendon towards its insertion, greater trochanter of femur and look for the **trochanteric bursa of gluteus medius** between the tendon and greater trochanter.
3. Observe the **gluteus minimus** muscle deep to gluteus medius and observe the attachment of **piriformis** and follow the tendon to greater trochanter.
4. Look for the **trochanteric bursa of gluteus minimus** between the tendon and greater trochanter.
5. Clean the fascia and expose **sciatic nerve** which exits below the lower border of piriformis muscle and trace the sciatic nerve downwards to the level of ischial tuberosity where it branches to hamstring muscles.
6. Observe the **posterior cutaneous nerve of thigh** which runs medial to sciatic nerve and **perineal branches of posterior cutaneous nerve of thigh** which runs medially below ischial tuberosity.
7. Look for the **branches of medial circumflex femoral artery** which runs with the branches of sciatic nerve.

Gluteus medius takes **origin** from the outer surface of ilium between anterior and posterior gluteal lines and **inserts** on the lateral surface of greater trochanter of femur.

Gluteus minimus takes **origin** from the outer surface of ilium between anterior and inferior gluteal lines and **inserts** into the anterior surface of greater trochanter of femur.

Both **gluteus medius** and **minimus** are innervated by **superior gluteal nerve.**

Actions, both gluteus medius and minimus acting from the pelvis, abduction, medial rotation of the thigh, play an important role in maintaining the trunk in upright position and very important muscles for walking.

Applied Anatomy (Clinical)

Trendelenburg sign (Fig. 4.7) is when standing on one leg, the pelvis drops on opposite side to reduce the work load on the hip abductors and the muscle weakness is present on the side of the standing leg, can occur in muscular dysfunction, weakness of gluteus medius or minimus and the body is not able to maintain the center of gravity on the side of the standing leg when lifting the leg to the side.

JAYPEE BROTHERS

Nerves in the Gluteal Region

Superior Gluteal Nerve

Superior gluteal nerve is a branch of sacral plexus, leaves the pelvis through the upper part of greater sciatic foramen and divides into a superior and inferior branches, the **superior branch** supplies gluteus medius and minimus and **inferior branch** supplies gluteus medius, gluteus minimus and tensor fascia lata.

Applied Anatomy (Clinical)

Gluteal gait is an abnormal gait due to the injury or neurological problems or lesion of superior gluteal nerve which causes motor loss and fail to control the gluteus medius and minimus properly producing an inability to tilt the pelvis while walking, result in a drastic sag of the pelvis toward the side in walking **(Trendelenburg sign).**

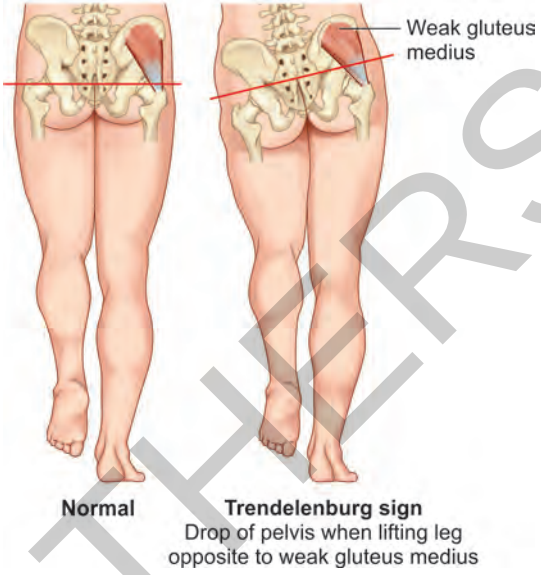

Fig. 4.7: Trendelenburg sign

Inferior Gluteal Nerve

Inferior gluteal nerve is a branch of sacral plexus (dorsal branches of ventral rami of L5, S1, S2) leaves the pelvis through greater sciatic foramen below piriformis muscle, divides into branches and enters the deep surface of gluteus maximus and supplies it.

Applied Anatomy (Clinical)

Inferior gluteal nerve injury may occur during operations on the hip during hip replacement, as a result of operative trauma associated with stretching and retraction of the nerve.

Sciatic Nerve (Fig. 4.8)

Sciatic nerve is the largest and thickest nerve in the body, arises from ventral rami of L4, L5, S1, S2, S3 spinal nerves, leaves the pelvis through the lower part of the greater sciatic foramen below the lower border of the piriformis muscle and enters the gluteal region deep to the glueus maximus.

It has two components, **tibial part** (supplies hamstring muscles) and **common peroneal part** (supplies short head of biceps femoris.

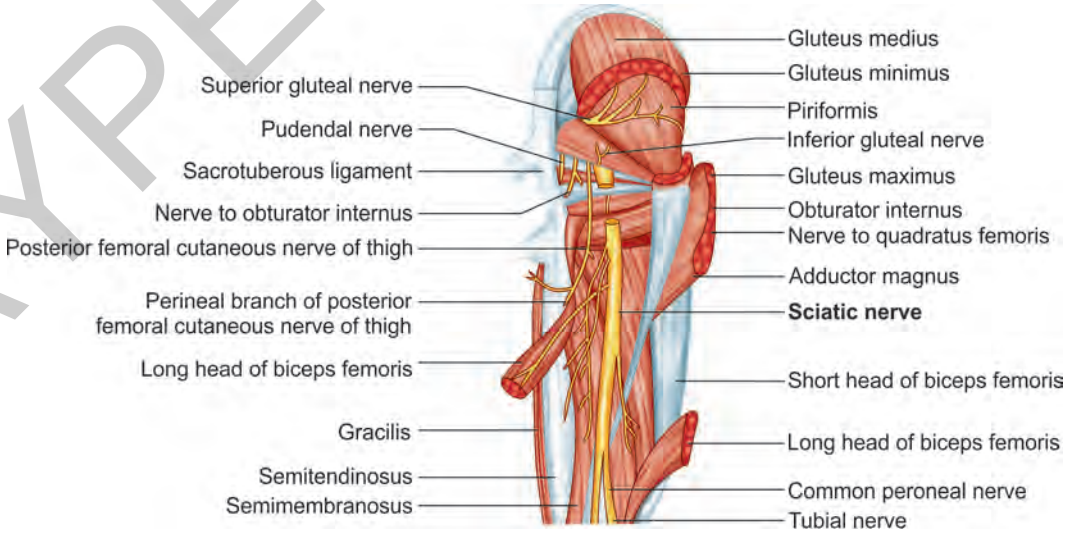

Fig. 4.8: Sciatic nerve

JAYPEE BROTHERS

In the lower third of thigh (in popliteal fossa) it terminates into two large branches, **tibial** (medial) and **common peroneal nerves** (lateral).

Applied Anatomy (Clinical)

Sciatica is the intense pain on the back of thigh due to compression or irritation to the nerve caused by piriformis muscle (piriformis syndrome), or a lumbar herniated disc (L5–L5), spinal stenosis (narrowing of spinal canal), bone spurs (bony growth along the joints), arthritis, nerve root compression (pinched nerve caused by injury), tumors or pregnancy.

Symptoms of sciatica include a constant sharp pain begins in the back or buttock which radiates along the course of the nerve, down to back of thigh, leg and foot, also burning sensation, weakness, tingling, or numbness in leg, makes it worse while sitting, standing or movements of flexion of spine.

Posterior Cutaneous Nerve of Thigh

Posterior cutaneous nerve of thigh is a branch of sacral plexus, leaves the pelvis through lower part of greater sciatic foramen below piriformis muscle, runs medial to sciatic nerve.

Pudendal Nerve

Pudendal nerve is a branch of sacral plexus, leaves the pelvis through lower part of greater sciatic foramen and enters gluteal region and accompanies **internal pudendal vessels.**

Arteries in the Gluteal Region

Superior Gluteal Artery

Superior gluteal artery is a branch of posterior division of internal iliac artery, emerges from the pelvis through greater sciatic foramen below piriformis muscle with the superior gluteal nerve and divides into a superficial and deep branches and supplies gluteus medius, gluteus minimus, tensor fascia lata, hip joint, neck and greater trochanter of femur.

Inferior Gluteal Artery

Inferior gluteal artery is a branch of anterior division of internal iliac artery, emerges from the pelvis through greater sciatic foramen below piriformis muscle, breaks up into branches.

Medial Circumflex Femoral Artery

Medial circumflex femoral artery is a branch of profund femoris artery arises in femoral triangle, passes backwards and divides into ascending, transverse and acetabular branches.

Cruciate Anastomosis

Arteries take part in cruciate anastomosis include the terminal part of transverse branch of lateral circumflex femoral, terminal part of transverse branch of medial circumflex femoral, inferior gluteal and first perforating arteries.

Applied Anatomy (Clinical)

The **cruciate anastomosis** is clinically important because if there is a blockage between the femoral artery and external iliac artery, blood can reach the popliteal artery by means of the anastomosis (Fig. 4.9).

Short Lateral Rotators of Thigh

Dissection

1. Lift the **sciatic nerve** and observe the muscles deep to it, **superior gamellus, tendon of obturator internus, inferior gamellus** and **quadratus femoris** from above downwards.
2. Look for the **nerve to the quadratus femoris** deep to the sciatic nerve and trace it downwards and note this nerve runs deep to obturator internus and two gamelli.
3. Observe the attachments of **sacrotuberous ligament** and deep to it, look for **sacrospinous ligament.**
4. Look for the **nerve to the obturator internus** passing to **superior gamellus** and split into superior and **inferior gamelli** and expose the **tendon of obturator internus** in between the two gamelli.

JAYPEE BROTHERS

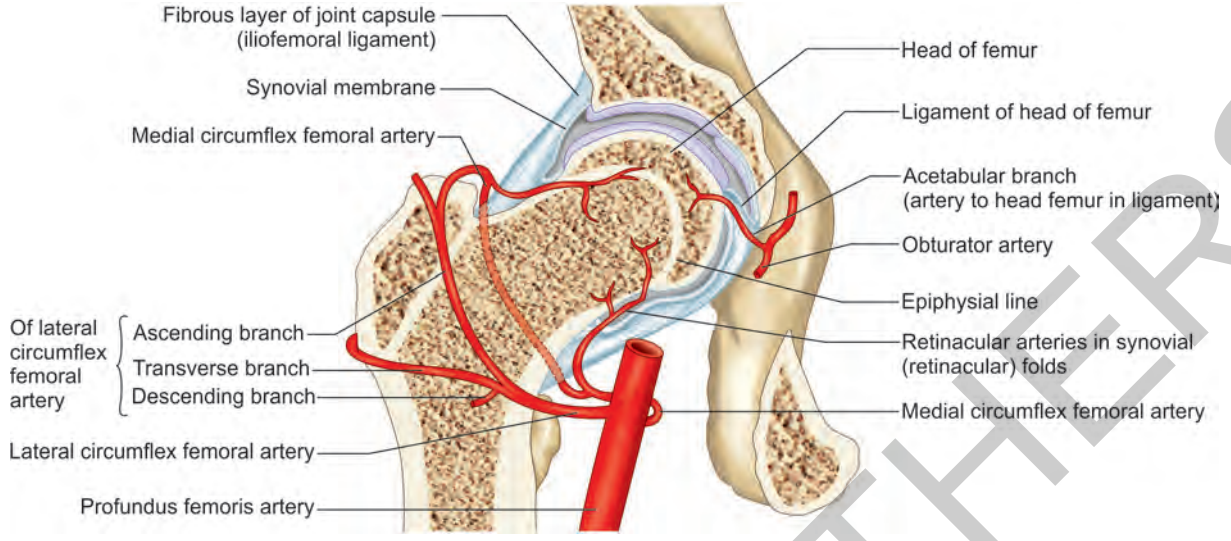

Fig. 4.9: Cruciate anastomosis

5. Trace the tendon to greater trochanter and observe the **quadratus femoris** muscle below inferior gamellus extending from ischial tuberosity to back of femur.
6. Look for the **branches of medial circumflex femoral artery** above and below quadriceps femoris muscle and observe the **adductor magnus** muscle inferior to quadratus femoris.
7. Look for the first perforating artery (branch of profunda femoris artery) piercing adductor magnus muscle close to the gluteal tuberosity.
8. Lift the gamelli and tendon of obturator internus and look for the nerve to quadratus femoris and trace it to the muscle and a branch to inferior gamellus.
9. Cut the quadratus femoris, separate it and observe the deep structures, **lesser trochanter of femur, medial circumflex femoral artery, capsule of hip joint** and **tendon of obturator externus.**

Short lateral rotators of thigh include piriformis, superior gamellus, obturator internus, inferior gamellus and quadratus femoris and obturator externus (Fig. 4.10).

Piriformis

Piriformis takes **origin** from ventral surface of sacrum, gluteal surface of ilium near posterior inferior iliac spine, capsule of sacroiliac joint and sacrotuberous ligament and inserts into upper border of greater trochanter of femur (Fig. 4.11).

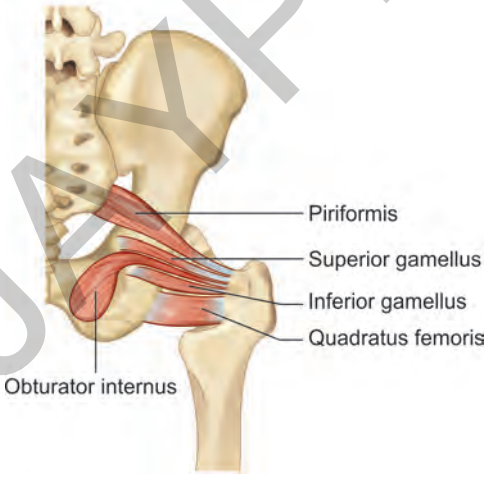

Fig. 4.10: Short lateral rotators of thigh

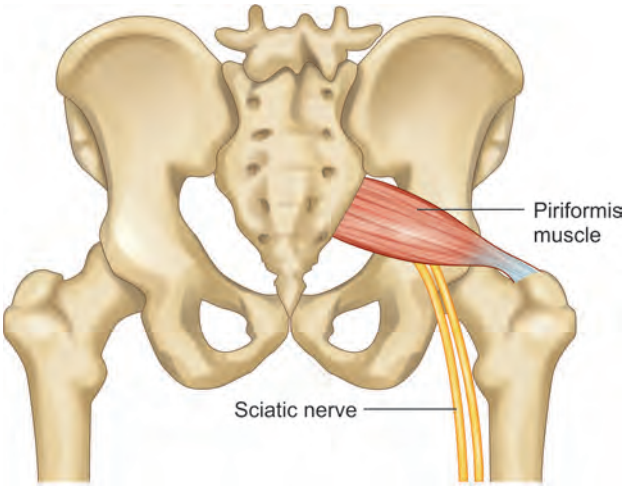

Fig. 4.11: Piriformis

JAYPEE BROTHERS

Innervated by nerve to piriformis (branch of sacral plexus, L5, S1, S2).

Actions, lateral rotation of extended thigh and abduction of flexed thigh.

Applied Anatomy (Clinical)

Piriformis syndrome is a neuromuscular disorder in which the piriformis muscle irritates the sciatic nerve while sitting for longer periods of time or running and usually triggered while climbing the stairs, starts with pain, tingling, and numbness in the buttocks and when the pain becomes severe it extends down along the course of sciatic nerve lower into the thigh and leg and this referred pain is known as **sciatica.**

Superior Gamellus

Superior gamellus takes **origin** from the posterior surface of ischial spine and **inserts** into the medial surface of greater trochanter.

Obturator Internus

Obturator internus takes **origin** from the inferior ramus of pubis, ramus of ischium, obturator membrane, obturator fascia and pelvis surface of hip bone below the pelvic brim and **inserts** into the medial surface of greater trochanter with the two gamelli.

Both **superior gamellus** and **obturator internus** are supplied by **nerve to obturator internus.**

Inferior Gamellus

Inferior gamellus takes **origin** from the upper part of ischial tuberosity and **inserts** into the medial surface of greater trochanter.

Quadratus Femoris

Quadratus femoris takes **origin** from the upper part of outer aspect of ischial tuberosity and **inserts** into the quadrate tubercle on the upper part of intertrochanteric crest of femur.

Both **inferior gamellus** and **quadratus femoris** are innervated by **nerve to quadratus femoris.**

All the above muscles have the same **actions,** lateral rotation of extended thigh, abduction of flexed thigh and steadies the head of femur in acetabulum**.**

Applied Anatomy (Clinical)

External (lateral) rotators of thigh muscles are usually injured when they are used to brake the movement in the opposite direction, down the hill, hard surface, lack of shoe cushioning.

Tightness of external rotator muscles will limit the internal rotation of hip and the nerves arising from sacral plexus may be compressed by pelvic tumors causing severe pain in lower limb.

JAYPEE BROTHERS

for detailed information on anatomy books, visit our website www.jaypeebrothers.com, for detailed information on anatomy books, visit our website www.jaypeebrothers.com, for detailed i

Dissection Manual

With Regions & Applied Anatomy

Lower Extremity, Abdomen, Pelvis and Perineum

Salient Features

- **Fully revised and aligned with the latest CBME guidelines** prescribed by the National Medical Commission (NMC), 2024.
- A comprehensive **three-volume practical guide** meticulously prepared with dedication to serve students and educators in **medical, dental, and allied health sciences.** The content is thoughtfully organized and enriched with numerous **detailed illustrations** to support effective cadaveric dissection.
- Each chapter is structured with **clearly defined Learning Objectives**, followed by **Introduction, Bony Landmarks,** and **Applied (Clinical) Anatomy**, ensuring a concept-based and outcome-driven approach in line with CBME guidelines.
- **Volume II** explains well about the cadaver **dissections of the lower extremity, abdomen, pelvis, and perineum** in a simple format with the osteology, cutaneous nerves, muscles, nerves, blood vessels, joints, abdominal and pelvic viscera, glands, male and female reproductive organs with their relations, the urogenital and anal triangles in male as well as female with **clinical importance**.
- Integrated with **dissection and model demonstration videos**, this edition provides a strong **visual learning aid**, facilitating better understanding of anatomical relationships and dissection techniques.
- Designed to be **student-friendly, exam-relevant,** and clinically oriented, this manual serves as an **indispensable resource** for students to master Gross Anatomy in both academic and practical settings.



Mercy Navis MSc has got her Master's degree in Human Anatomy from Madras Medical College, Chennai, Tamil Nadu, India, and has an extensive teaching experience of more than 38 years. In her career, she has taught undergraduate and postgraduate medical, dental, nursing, pharmacy, physical therapy, and Chiropractic students. Currently, she is working as Associate Professor of Anatomy, Department of Basic Sciences, Life University, Atlanta, USA. She was teaching for the past 25 years, in USA, Chiropractic students, both in Sherman College, South Carolina, and in Life University, Atlanta. She has also taught the premedical and predental students in the University of South Carolina and nursing students in Spartanburg Technical College. In the past, she has worked as Assistant Professor in MS Ramaiah Medical College, Bengaluru, Karnataka, for 16 years and also Sri Krishna Medical College, Muzaffarpur, Bihar, for 3 years. She has prepared several museum specimens and created the Anatomy Museum for Sri Krishna Medical College, Muzaffarpur. Life University has awarded her as the "Teacher of the Year 2011–2012" and she was also recognized by the graduating class of March 2014 as the "Faculty of the Basic Sciences". She has conducted Dissection Seminars for the Doctors of Chiropractic and Chiropractic Diplomats from Japan. She has already published the book in USA *Gross Anatomy Dissection Manual* in August 2013 by Kendall Hunt Publishing Company.

Printed in India

Available at all medical bookstores or buy online at www.ejaypee.com

JAYPEE BROTHERS
Medical Publishers (P) Ltd.
EMCA House, 23/23-B, Ansari Road,
Daryaganj, New Delhi - 110 002, INDIA
www.jaypeebrothers.com

Join us on facebook.com/JaypeeMedicalPublishers
Follow us on instagram.com/JaypeeMedicalPublishers

Shelving Recommendation
ANATOMY

ISBN 978-93-6616-521-9