ypee.com, for detailed information on surgery books, visit our website www.ejaypee.com, for detailed information on surgery book

# CLINICAL SURGERY PEARLS




**R Dayananda Babu**

*Forewords*
**S Vaidyanathan**
**Mathew Varghese**

diginerve®
A Jaypee Initiative
• Video Lectures • Dr. Wise AI Chatbot
• Question Bank • Notes
Download App

JAYPEE

# Contents


## SECTION 1: DEFINITIONS

Definitions 1

## SECTION 2: LONG CASES

1. Toxic Goiter 13
2. Solitary Thyroid Nodule (Nontoxic) 30
3. Papillary Carcinoma Thyroid with Lymph Node Metastases 38
4. Multinodular Goiter (MNG) (Thyroid Follicular Nodular Disease) 52
5. Early Breast Cancer 58
6. Advanced Breast Cancer (Locally Advanced Breast Cancer-LABC and Metastatic Breast Cancer-MBC) 76
7. Epigastric Lump 85
8. Right Hypochondrial Lump without Jaundice 98
9. Right Iliac Fossa Mass (Suspected Ileocecal Tuberculosis) 108
10. Suspected Carcinoma of the Cecum 113
11. Appendicular Mass/Lower Abdominal Mass/DD of Left Iliac Fossa Mass 123
12. Obstructive Jaundice 129
13. Varicose Veins 142
14. Peripheral Occlusive Vascular Disease 160
15. Lymphoma 176
16. Renal Swelling 188
17. Pseudocyst of Pancreas 197
18. Retroperitoneal Tumor 202
19. Testicular Malignancy 207
20. Portal Hypertension 217
21. Mesenteric Cyst 229

## SECTION 3: SHORT CASES

22. Nonthyroid Neck Swelling 233
23. Tuberculous Cervical Lymph Node 236
24. Cervical Metastatic Lymph Node (Carcinoma of Unknown Primary) and Neck Dissections 244
25. Carcinoma Tongue with Submandibular Lymph Node 256
26. Carcinoma of Gingivobuccal Complex (Indian Oral Cancer) 264
27. Parotid Swelling 268
28. Submandibular Sialadenitis 279

29. Ranula, Plunging Ranula, Sublingual Dermoid and Mucous Cyst 283
30. Thyroglossal Cyst, Lingual Thyroid, Ectopic Thyroid, Subhyoid Bursa and Carcinoma Arising in Thyroglossal Cyst 286
31. Branchial Cyst, Branchial Fistula, Cystic Hygroma and Carotid Body Tumor 291
32. Soft Tissue Sarcoma of the Extremities 298
33. Neurofibroma, Von Recklinghausen's Disease 306
34. Lipoma (Universal Tumor) 311
35. Sebaceous Cyst/Epidermoid Cyst/Wen/Dermoid Cyst 314
36. Ulcer 319
37. Malignant Melanoma 326
38. Basal Cell Carcinoma/Rodent Ulcer/Tear Drop Cancer 337
39. Squamous Cell Carcinoma (Epithelioma) 341
40. Carcinoma Penis 347
41. Congenital Arteriovenous Fistula/Hemangioma/Compressible Swelling 353
42. Unilateral Lower Limb Edema 360
43. Hydrocele of Tunica Vaginalis Sac (Epididymal Cyst, Spermatocele, Varicocele, Hematocele, Chylocele, etc.) 367
44. Inguinal Hernia/Femoral Hernia 374
45. Incisional Hernia (Ventral Hernia, Postoperative Hernia) 389
46. Epigastric Hernia (Fatty Hernia of the Linea Alba) 394
47. Paraumbilical Hernia, Umbilical Hernia in Adults and Children 396
48. Desmoid Tumor, Interparietal Hernia (Interstitial), Spigelian Hernia 401
49. Gynecomastia/Male Breast Carcinoma 404
50. Fibroadenoma/Cystosarcoma/Breast Cyst/Fibroadenosis/Fibrocystic Disease/Mastalgia/Mastopathy/Chronic Mastitis/Nipple Discharge 410

**SECTION 4: RADIOLOGY AND IMAGING**

Radiology Questions and Answers 419

**SECTION 5: IMPORTANT TABLES AND CHARTS**

General 461
Trauma 466
Burns 471
Neck 474
Breast 475
Abdomen 477
Vascular 485
Limbs 489
Anorectal 492

*Index* *495*

8

CASE

# Right Hypochondrial Lump without Jaundice

## CASE CAPSULE

A 50-year-old male patient with history of **chronic alcoholism** and previous **jaundice,** now presents with **loss of appetite**, generalized weakness and **loss of weight** for **six months** duration. On examination there is no jaundice but **pallor is present**. There are **no stigmata of liver disease**. On inspection of the abdomen, there is **right hypochondrial fullness**. The rest of the abdomen is normal and the abdomen moves with respiration. There are no dilated veins and no visible peristalsis. On palpation, there is a **right hypochondrial mass** that is moving with respiration. It is about **6 × 10 cm** size and **hard in consistency**. The mass is seen to descend from below the right costal margin. One **cannot get above the mass** and **fingers cannot be insinuated** between the mass and costal margin. There is dullness on percussion over the swelling and the **dullness is continuous with liver dullness** that is dull up to the 8th rib in the mid axillary line. The **edge of the swelling is irregular and rounded** and the surface of the mass is irregular. On auscultation a **bruit is heard over the swelling.** There is no splenomegaly, there is no ascites. There is no evidence of encephalopathy.

*Refer the checklist for examination in the previous chapter.*



Liver swelling

- Look for **jaundice**
- Look for **stigmata of liver disease**—palmar erythema, spider nevi, testicular atrophy, absence of pubic and axillary hair, caput medusae, etc.
- Rule out **Riedel's lobe**
- Measure the liver span in the midclavicular line
- Palpate for **spleen**
- Rule out **ascites**
- Look for **acquired umbilical hernia** in severe ascites

## SYMPTOMS OF HCC

- Sudden decompensation or weight loss in cirrhotic patient
- PUO
- Hemobilia
- Jaundice—10 to 30%
- Hematemesis—due to portal hypertension
- Bone pain
- Complications of peripheral tumor is rupture and hemoperitoneum

**Q 1. What is the probable anatomical diagnosis in this case?**

It is a liver swelling.

**Q 2. What are your points in favor of a liver swelling?**

**Clinical points in favor of liver swelling**

- Mass in the right hypochondrium moving with respiration
- You cannot get above the swelling
- Fingers cannot be insinuated between the swelling and the costal margin
- It is dull on percussion and the dullness is continuous with liver dullness
- The liver swelling will have an edge that may be sharp or round and a surface that will be smooth or irregular

JAYPEE BROTHERS

**Q 3. What are the causes for a knobby generalized enlargement of liver without jaundice?**

| Causes for generalized knobby liver enlargement without jaundice |
|---|
| • Secondary carcinoma (liver metastases)<br>• Primary liver carcinoma<br>• Polycystic disease<br>• Macronodular cirrhosis |

**Q 4. What are the causes for a knobby generalized enlargement of liver with jaundice?**

- Extensive secondary carcinoma
- Cirrhosis of liver.

**Q 5. What are the causes for localized swellings from liver?**

| Localized swelling from liver |
|---|
| • Riedel's lobe<br>• Secondary carcinoma<br>• Liver abscess<br>• Hydatid cysts<br>• Primary liver carcinoma |

**Q 6. What is Riedel's lobe?**

It is seen in 3.3 to 31% cases. This is an extension of the right lobe of the liver down below the costal margin along the anterior axillary line. It is often mistaken for a pathological enlargement of liver or gallbladder. It is a normal anatomical variation.

**Q 7. What is the probable pathological diagnosis in this case?**

A liver malignancy may be **primary** or **metastases.**

**Q 8. What are the points in favor of a primary malignancy in this case?**

- Chronic alcoholism that can lead onto cirrhosis and a primary malignancy may arise in cirrhotic liver.
- Previous history of jaundice—hepatitis B and hepatitis C lead on to primary malignancy.
- Cirrhosis itself will predispose to primary malignancy.

**Q 9. What are the points against metastases in the liver?**

- Usually multiple nodules are seen in metastases even though multifocal hepatocellular carcinoma is possible.
- The classical sign of **umbilication** will be palpable in the liver nodule.
- Other clinical swellings suggestive of a primary in another organ may or may not be palpable in the abdominal cavity.

**Q 10. What is the most common malignant swelling in the liver?**

Most common malignant swelling is **metastases** in the liver. Metastatic cancer is **20 times more** common than primary tumors in the liver. The cirrhotic liver, which often gives rise to primary hepatic tumors, is less susceptible than normal liver to implantation of metastases.

**Q 11. What are the usual presentations of primary malignancy of the liver?**

| Clinical presentation of primary malignancy of the liver |
|---|
| • Pain abdomen with or without hepatomegaly<br>• Sudden deterioration of the condition of cirrhotic patient owing to the appearance of hepatic failure, bleeding varices or ascites<br>• Sudden massive intraperitoneal hemorrhage<br>• Acute illness with fever and abdominal pain<br>• Distant metastases—lungs and bone<br>• No clinical finding |

**Q 12. Can there be associated metabolic or endocrine abnormalities in hepatocellular carcinoma (primary)? (PG)**

| Metabolic and endocrine abnormalities in hepatocellular carcinoma |
|---|
| • Erythrocytosis<br>• Hypercalcemia<br>• Hypoglycemic attack<br>• Cushing's syndrome<br>• Virilization |

**Q 13. What are the complications of hepatocellular carcinoma? (PG)**

- Sudden intra-abdominal hemorrhage because of spontaneous bleeding
- Obstruction of the portal vein resulting in portal hypertension
- Obstruction of hepatic veins resulting in Budd–Chiari syndrome
- Liver failure.

**Q 14. What is the classification of liver tumors?**

The broad classification is into benign and malignant.

| *Benign* | *Malignant* |
|---|---|
| • Hepatic adenoma (hepatic adenoma, cholangioadenoma or a combination)<br>• Focal nodular hyperplasia<br>• Hemangioma | • *Primary:*<br>♦ Hepatocellular carcinoma<br>♦ Cholangiocarcinoma<br>♦ Combination of hepato and cholangiocarcinomas<br>♦ Adenosquamous carcinoma<br>♦ Squamous carcinoma of bile duct<br>♦ Signet ring carcinoma<br>♦ Undifferentiated carcinoma<br>♦ Bile duct cystadenocarcinoma<br>• *Metastases* |

JAYPEE BROTHERS

### Q 15. What is the classification of metastases?

Metastases may be classified as:

- Carcinomatous, e.g., stomach, esophagus colon, pancreas, kidney, prostate, breast, etc.
- Carcinoid metastases—carcinoid syndrome will occur when the liver is metastasized and therefore 5HT cannot be metabolized to 5-hydroxyindoleacetic acid.
- Melanomatous metastases—**beware of "missing toes and glass eyes"**
- Neuroendocrine tumor (NET)
- GIST
- Sarcomatous metastases.
- Lymphomatous deposits.

### Q 16. What are the salient features of hepatic adenoma?

**Salient features of hepatic adenoma**

- Occur almost exclusively in women
- Associated with the use of oral contraceptives
- Well-circumscribed soft yellow tan tumors of 2–15 cm size
- 2/3rd are solitary and remaining are multiple
- Transition from adenoma to carcinoma may occur
- Pain, intra-abdominal hemorrhage and shock may occur
- Bleeding episode with menstruation is seen
- Regression is possible when the size is less than 6 cm and when the oral contraceptive pill is withdrawn
- Tumor should be followed-up periodically with ultrasound/CT
- When in doubt remove the hepatic adenoma

### Q 17. What are the stigmata of liver disease?

**Stigmata of liver disease**

- Spider nevi (>9 new crops indicate progressive disease)
- Palmar erythema (thenar and hypothenar eminences)
- Clubbing, leukonychia
- Dupuytren's contracture
- Body hair loss (axillary and pubic)
- Fetor hepaticus
- Gynecomastia
- Testicular atrophy
- Liver flap—flapping tremor
- Encephalopathy—cogwheel limb rigidity

### Q 18. How to manage this patient with liver mass?

Management includes investigations and treatment.

The investigations may be classified as:

a. Investigations for diagnosis
b. Investigations for staging
c. Investigations for surgical treatment.

**Note:** The most important investigations is **imaging.**

### Q 19. What is the role of ultrasound for imaging liver?

Look for echotexture (solid/cystic):

- It is a screening test
- Can identify mass lesions
- Can identify bile duct dilatation
- Ascites
- Useful for guiding biopsy
- Used for evaluation of portal vein and hepatic vein with color Doppler

**Note:** But it is operator dependent.

### Q 20. What is the role of CT in liver mass?

Triple phase, multislice spiral CT is the investigation of choice for liver mass.

- *A mass lesion up to 1 cm size can be identified*—hepatocellular carcinoma in contrast enhanced CT shows: Early arterial enhancing lesion with delayed venous phase.
- Early arterial enhancement phase followed by early washout of contrast during the portovenous phase is suggestive of hemangioma and in MRI, it will give the **light bulb sign.**
- *The venous phase:* Maps out portal vein and hepatic veins.

### Q 21. What are the CT findings of various mass lesions?

Triple phase CT scan is the investigation of choice for HCC.

| *Type of lesion* | *Imaging finding* | *Mode of treatment* |
|---|---|---|
| Hemangioma | Hyperechoic in US hypodense in CT without contrast Halo edge enhancement initially, then fills the center **(late, slow venous enhancement)** | No need for surgery |
| Hepatic adenoma | Well-circumscribed vascular solid tumor. Enlarged peripheral vessels in arteriography—needle biopsy will produce bleeding | Premalignant lesion. Resection is the treatment of choice. Withdrawal of oral contraceptives will produce regression |
| Focal nodular hyperplasia (FNH) focal over-growth of functioning liver with fibrous stroma | Central scarring in CT. Well-vascularized **sulfur colloid liver scan** is the investigation of choice—the lesion includes both hepatocytes and Kupffer cells | No need for surgery |

*Contd...*

JAYPEE BROTHERS

*Contd...*

| | | |
|---|---|---|
| Metastases | **Nonenhancing** lesion after **IV contrast** in CT | Surgery for colorectal metastases |
| Hepatocellular carcinoma | Early arterial phase **enhancing** lesion with IV contrast, rapid wash out, delayed peripheral enhancement, late enhanced capsule | Liver resection/liver transplantation |

### Q 22. What is the gold standard investigation for the diagnosis of hepatocellular carcinoma?

**Lipiodol-enhanced CT** scan is the gold standard investigation. The practice is an injection of lipiodol into the hepatic artery during selective angiogram followed by CT after 2 weeks. The lipiodol will be taken up by the tumor.

### Q 23. What is the role of magnetic resonance imaging (MRI)?

- A hyperintense lesion in T1 weighted and hypointense lesion in T2.
- It is useful for patients with iodine sensitivity, who cannot undergo a lipiodol-enhanced CT.
- Imaging of the biliary tract (**MRCP**) is possible.
- Hepatic artery and portal vein can be well-delineated.

### Q 24. What is the role of needle biopsy/FNAC in mass lesions of liver?

Percutaneous biopsy of lesions in patients with potentially operable disease is **contraindicated** because of the high incidence of **needle track recurrence and high mortality** associated with this procedure (spontaneous bleeds, pain, false positive and false negatives).

### Q 25. If so what is the indication for a needle biopsy?

- Unresectable tumors
- Diagnostic dilemma.

### Q 26. What are the needles for liver biopsy?

- Chiba needle (Chiba is the name of a university):
  - 20 cm long, 22 gauge, malleable needle with short bevel
- Vim Silverman needle
- Menghini needle.

### Q 27. What are the precautions to be taken before biopsy from liver?

- The coagulation profile should be checked and rectified (PT, aPTT and platelet count).
- In cases of jaundice (in coagulation failure also) **give vitamin K injections 10 mg IM/IV for 3 days.**

**Note:** The vitamin K1 (phytomenadione) only can be given IV. **Regular vitamin K is oily** and cannot be given intravenously.

### Q 28. What are the macroscopic types of hepatocellular carcinoma? (PG)

**Macroscopic types of hepatocellular carcinoma**

a. *Unifocal:*
   i. Expanding: Sharp demarcation between the tumor mass and compressed surrounding parenchyma
   ii. Pedunculated: Type 1—intrahepatic; type 2—extrahepatic (nourished by a branch of right hepatic artery)—not a true HCC
   iii. Spreading (Engel's massive form)—lack of demarcation between tumor and normal liver—may involve the whole liver as nodules
b. *Multifocal*—synchronous swellings
c. *Indeterminate*—different features in different parts
d. *Diffuse*

*Another macroscopic classification:*
a. Pushing
b. Hanging
c. Infiltrative or diffuse

*NCCN classification:*
a. Nodular
b. Massive
c. Diffuse

### Q 29. What are the pathological variants of HCC? (PG)

- Fibrolamellar HCC—good prognosis
- Mixed hepatocellular cholangiocellular—worse prognosis
- Clear cell variant—better prognosis
- Giant cell variant
- Childhood HCC—bad prognosis
- Carcinosarcoma—sarcomatoid variant.

### Q 30. What are the features of fibrolamellar carcinoma?

- Younger age group (median 25 years)
- 2 to 5% of liver malignancy
- Without history of cirrhosis
- More common on left side
- Well-circumscribed—large mass with central scar
- Better resectability (50–75% in contrast to 25% in ordinary HCC)
- Better prognosis
- Left lobe is more commonly affected
- Lymph node involvement is there
- Does not produce AFP (α fetoprotein)
- Neurotensin B and vitamin $B_{12}$ binding proteins are the tumor marker

JAYPEE BROTHERS

- Equal sex incidence
- CT finding—stellate scarring.

### Q 31. What are the etiological factors for HCC?

- Cirrhosis—cirrhomimetic (develops in the background of cirrhosis); noncirrhomimetic
- Hepatitis B virus (HBV)
- Hepatitis C virus (HCV)
- Alcoholic liver disease
- Hemochromatosis
- Hereditary tyrosinemia
- Mycotoxins (aflatoxin B)
- Hepatic helminthiasis—clonorchis sinensis for cholangiocarcinoma.

### Q 32. What is small and large HCC? (PG)

A tumor that is <2 cm as per Japanese general rules. But a tumor <3–5 cm may be considered small by some authorities. They are nodular and well-differentiated. More than 10 cm are considered large HCC.

### Q 33. What are the investigations for staging?

- CT abdomen with oral and IV contrast—LIRADS (liver protocol)
- CT chest—to rule out metastases to lung
- Bone scan—to rule out metastases
- Laparoscopy.

### Q 34. What is the role of Child–Turcotte–Pugh grading?

This is very important if one is planning for surgical resection. Resection should be contemplated in Child–Turcotte–Pugh A patients and occasionally in Child–Turcotte–Pugh B patients.

**Child–Turcotte–Pugh classification of functional status of liver**

| *Points* | *1 point each* | *2 points each* | *3 points each* |
|---|---|---|---|
| Serum bilirubin (mg/dL) | <2.0 | 2.0–3.0 | >3.0 |
| Serum albumin (g/dL) | >3.5 | 2.5–3.5 | <2.5 |
| Ascites | Absent | Easily controlled | Poorly controlled |
| Encephalopathy | None | Grades I–II | Grades III–IV |
| International normalized ratio (INR) | <1.7 | 1.7–2.2 | >2.2 |
| CTP-A—5 to 6 points, CTP-B—7 to 9 points, CTP-C—10 to 15 points | | | |

### Q 35. What are the treatment options available in HCC?

Based on tumor factors, liver factors, patient factors and logistic factors.

1. **Surgery**—anatomical resection and nonanatomical wedge excision:
   - Liver transplantation
2. **Liver directed therapy:**
   - Percutaneous injection of ethanol
   - RFA—small tumors of child A and B, solitary tumors less than 3 to 4 cm
   - Microwave ablation
   - Transarterial chemoembolization (TACE) with lipidol and doxorubicin/cisplatin for early and large lesions. Drug eluting beads are available and CT is repeated after 6 weeks. It is mainly used for portal vein tumor thrombus (PVTT)
   - Transarterial radioembolization (TARE) is better—used for bilobar and multiple lesions. $I^{131}$ microspheres and yttrium 90 are used. Lung and visceral toxicity and transient fatigue syndrome are complication.
3. **Systemic therapy**—sorafenib for unresectable and lenvatinib. Sorafenib will worsen liver function.
4. **Stereotactic body RT** (SBRT)—avoid in child C. Used in HCC with extrahepatic metastasis

### Q 36. What are the investigations required for surgery?

- Liver function test
- Tumor markers—AFP, CEA, CA19-9
- Viral markers
- PIVKA II (protein induced by vitamin K abnormality by antagonism)—it is positive in 80% HCC
- Lens culinaris agglutinin reactive AFP (isoform of alpha fetoprotein)
- Assessment of cardiac status
- Pulmonary status
- Renal status.

### Q 37. What is the TNM staging (AJCC 8th edition)? (PG)

- Tx Primary tumor cannot be assessed
- T0 No evidence of primary
- T1 Solitary tumor ≤2 cm or >2 cm with out vascular invasion
- T1a Solitary tumor ≤2 cm
- T1b Solitary tumor >2 cm without vascular invasion
- T2 Solitary tumor >2 cm with vascular invasion or multiple tumors none more than 5 cm
- T3 Multiple tumors atleast one of which is >5 cm
- T4 Single tumor or multiple tumors of any size involving a major branch of the portal vein or hepatic veins, or tumor with direct invasion of adjacent organs other than the gallbladder or with perforation of visceral peritoneum

*Regional nodes:*

- Nx Regional node cannot be assessed
- N0 No regional node metastasis
- N1 Regional node metastasis.

JAYPEE BROTHERS

*Metastasis:*
- M0 No distal metastasis
- M1 Distal metastasis.

**Q 38. What is model for end-stage liver disease (MELD) score? (PG)**

The following factors are considered for MELD:
- Creatinine
- Bilirubin
- International normalized ratio (INR).

**Q 39. What are the bad prognostic factors? (PG)**

In addition to MELD, alpha fetoprotein, fibrosis score and hepatitis serology.

**Q 40. What is Okuda staging? (PG)**

Four factors are considered in this staging:
- Tumor size
- Ascites
- Albumin
- Bilirubin.

**Q 41. What is Cancer of Liver Italia Program (CLIP) staging? (PG)**

It consists of: Child–Pugh, alpha fetoprotein, portal vein thrombosis and tumor morphology.

**Q 42. What is Chinese University Prognostic Index (CUPI)? (PG)**

The following are considered in this:
TNM staging, bhrubin, ascitis, ALP, AFP, disease symptoms.

**Q 43. What are the indications for resection in HCC? (PG)**

*Milan criteria:*
- Asymptomatic solitary lesion ≤5 cm size
- Those with 3 or less primary tumors ≤3 cm
- Combined diameter of <7 cm.

*University of California San Francisco Criteria:*
- Single tumor less than 6.5 cm
- Less than three tumors
- Total diameter less than 8 cm
- Largest less than 4.5 cm

**Q 44. What are the contraindications for liver resection in HCC? (PG)**

- Bilirubin >2 is a contraindication
- CHILD-C
- Extrahepatic disease
- Lymph nodes
- Peritoneal involvement
- Distant metastases
- 1 cm clear margin is not possible
- Multifocal hepatoma (>2 nodules)—treatment is transplantation.

**Q 45. What is Pringle maneuver?**

A clamp is put across the free border of the lesser omentum thus **occluding the inflow**. This is a method to reduce blood loss during parenchymal transection and to treat oozing from the resected surface of the remnant liver. Inflow occlusion for **15 minutes followed by 5 minutes** off and this can be repeated up to 4 times. The oozing can be controlled by topical agents like **fibrin glue** or fibrin impregnated collagen fleece or by **argon plasma coagulation**.

**Total vascular exclusion**—the Pringle is combined with supra- and infrahepatic IVC occlusion.

**Q 46. How much liver should be left behind in case of liver resection? (PG)**

Two segments of healthy liver must be left behind. The residual liver volume should be 30% if liver is normal and 40% if the liver is diseased.

**Q 47. What is major hepatic resection?**

When more than three segments are resected.

**Q 48. What is FLR and TELV? (PG)**

FLR is future liver remnant and is the ratio of the remaining liver volume to the total estimated liver volume (TELV). The safe minimum threshold for future liver remnant varies from **20–25%** for a normal liver to **>40%** for a cirrhotic liver. The FLR is calculated as total liver volume minus tumor volume.

**Q 49. What is portal vein embolization?**

This was first described by Makuuchi in 1984 before an extended hepatectomy for a bile duct carcinoma. This is preoperative procedure performed in interventional radiology to initiate hypertrophy of the anticipated future liver remnant a few weeks prior to major liver resection. The principle is to block the portal venous blood flow to the liver segment that requires resection. This induces atrophy of the ipsilateral liver segments and compensatory hypertrophy of the contralateral liver segments resulting in an increase in the size of the proposed FLR. Different embolization materials are used including **polyvinyl alcohol particles, coils, gelatin sponge, n-butyl cyanoacrylate and lipiodol or fibrin glue.**

**Q 50. What is special preoperative investigation before resection?**

CT volumetry of the liver before resection.

JAYPEE BROTHERS

**Q 51. What type of anesthesia is preferred for liver resection? (PG)**

**Low CVP anesthesia**

- The inflow to the liver can be blocked by clamping the free edge of the lesser omentum
- Bleeding results from hepatic vein during resection
- CVP is kept at 5 (If the CVP is decreased to zero, there will be little bleeding from hepatic veins)
- As a result, there is no need for blood transfusion

**Q 52. What are the methods of parenchymal resection of liver?**

- Kelly-clysis
- Finger fracture technique
- Crush clamp
- CUSA
- Harmonic
- Ligasure
- Water jet resection
- Stapler (vascular stapler technique)
- Thunder beat (harmonic + diathermy).

**Q 53. What you mean by staged procedure?**

The aim is to clear one lobe of the liver of all known disease followed 4 to 6 weeks later formal major resection to clear all residual disease.

**Q 54. Any role for laparoscopic/robotic resection?**

Laparoscopic surgery is safe and gradually replacing the conventional open surgery.

**Q 55. What are the indications for transplantation? (PG)**

Outlook is better for transplantation than resection provided:

- Tumor nodules are 3 cm or less in diameter
- Nodules are 3 or less in number.

**Q 56. What are the nonsurgical ablative therapies available? (read answer of question 35) (PG)**

- Radio frequency ablation (**RFA**)—for **>2 cm** size—complications are needle track recurrence, hemorrhage and liver failure.
- **Microwave ablation**—for **3 cm** size
- Cryoablation
- Laser ablation
- Irreversible electroporation (IRE)
- Percutaneous **alcohol injection**—destruction of tumors up to <2 cm size is possible—ineffective in colorectal metastases.
- **More than 5 cm is thermoresistant**
- Transarterial chemoembolization (**TACE**)—for small tumors only. A mixture of lipiodol, a particle and doxorubicin is injected directly into the hepatic artery. The complications are postembolization syndrome, liver failure, and liver abscess. 50% reduction in tumor size is seen 50% of cases.
- Transarterial radioembolization (**TARE**): Yttrium therapy is better for down staging.
  - **For surgically resectable tumors there is no role for TACE and TARE**
  - It is preferable to do transplantation after TACE/RFA.

**Note:** Patients with small volume resectable lesions or not fit to undergo resection should be considered for ablation.

**Q 57. What is the management of colorectal liver metastasis?**

- For operable cases 3 to 4 FOLFOX → liver resection → 3 to 4 FOLFOX.
- For borderline 3 to 4 FOLFOX + biological therapy → liver resection → 3 to 4 FOLFOX + biological therapy.

**Q 58. What is the role of metastasectomy in neuroendocrine tumor (NET)?**

- This will relieve symptoms with improved survival
- RO resection is not mandatory and cytoreduction is enough

**Q 59. What is targeted therapy? (PG)**

Sorafenib 400 mg. This is given only for CHILD A and B.

**Q 60. What is the prognosis of HCC?**

- It is a tumor with poor prognosis
- Median survival is in the region of 1 year
- Symptomatic patients survive for 6 months
- Resected patients (if suitable) the 5 years survival is around 30%
- Transplantation gives better results
- **Life expectancy is decided by the liver disease**.

## HYDATID DISEASE

**Q 61. What are the infections of the liver which will produce liver mass?**

- Pyogenic liver abscess
- Paracytic infections

**Q 62. What is hydatid disease?**

Hydatid disease is caused by a parasite called echinococcus granulosus commonly called the dog tape worm. It is common in the tropics and seen in sheep farming community.

JAYPEE BROTHERS

### Q 63. What are the clinical features?

- The parasite can colonize virtually every organ in the body.
- Gradually enlarging **painful mass** at the right upper quadrant (**hydatid liver cyst**). Liver is the organ most often affected. The **lung** is the next most common.
- The parasite can affect any organ or several organs at a time.
- Disease is may be **asymptomatic** or identified by imaging.
- The swelling can produce pressure effect and may cause dull pain from the **stretching of the liver capsule**.
- The daughter cysts may communicate with the biliary tree producing **obstructive jaundice**—by intrabiliary rupture (**IBR**).
- May present as emergency with features of **anaphylactic shock**.
- If the patient is **coughing up white material** one should suspect hepatopulmonary hydatid from rupture of hepatic hydatid on the diaphragmatic surface of liver.

### Q 64. What is the life cycle of hydatid?

The **dog is the definitive host** and is the **commonest source of infection** which is transmitted to the intermediate host like **humans, sheep and cattle**. In the dog the adult worm reaches the small intestine and the eggs are passed in the faeces. Close contact with the infected dog causes contamination by the oral route and thus the ovum gaining entry into the human GI tract. The ovum will form cysts in the liver of human, sheep and cattle. The cyst in the offal especially in the liver will reach again the definitive host. The life cycle is not completed in humans **(Fig. 8.1)**.

### Q 65. What are the parts of hydatid cyst?

Hydatid cyst has 3 layers **(Fig. 8.2)**:

- The outer **pericyst** which is derived from the compressed host organ
- The intermediate **ectocyst**, which is otherwise called **laminated membrane** which is noninfective
- The **endocyst** which is otherwise caller germinal membrane.

The germinal membrane contains viable parasites which will separate and form **daughter cyst**.

### Q 66. What is the ultrasound classification of hydatid cyst (WHO)?

- *Group I:* Active group—cysts larger than 2 cm and often fertile.

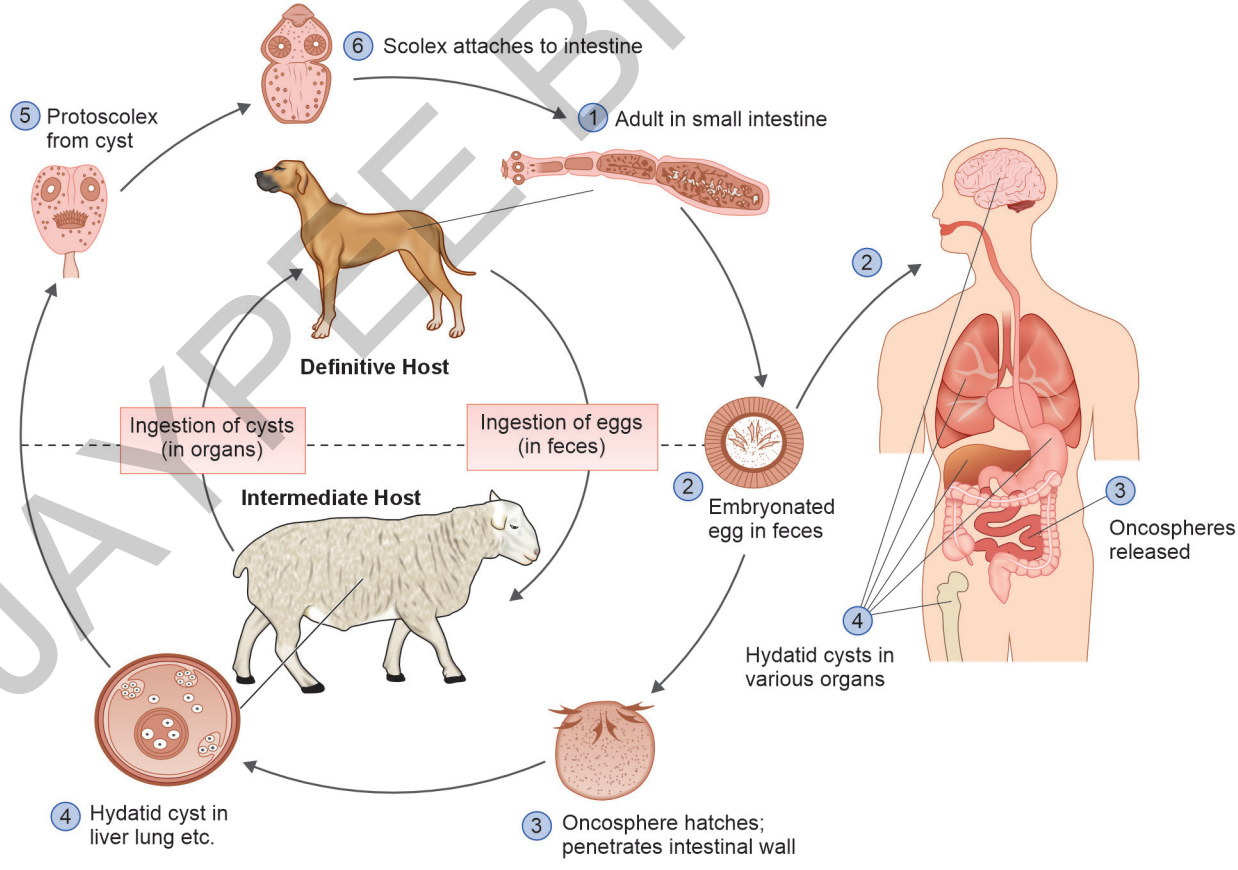


**Fig. 8.1:** Life cycle of echinococcus granulosus.

JAYPEE BROTHERS

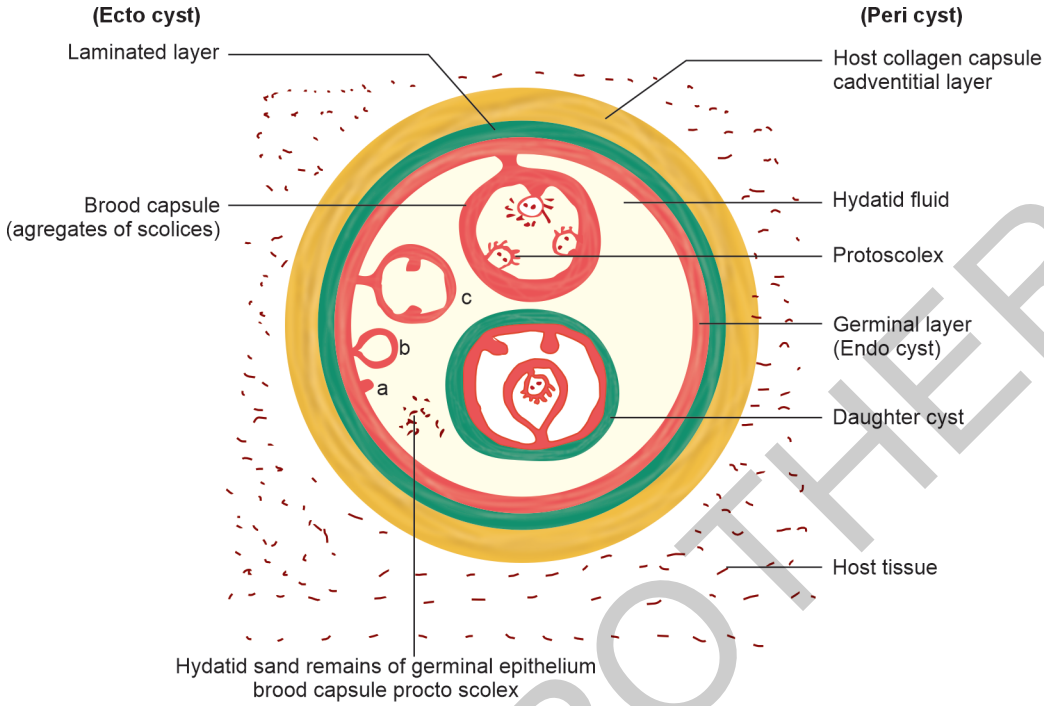


Fig. 8.2: Coverings of hydatid cyst.

- *Group II:* Transition group—cysts starting to degenerate and entering a transitional stage because of host resistance or treatment but may contain viable protoscolices.
- *Group III:* Inactive group—degenerated partially or totally calcified cysts unlikely to contain viable protoscolices.

### Q 67. What are the investigations?

- Plain radiograph—meniscus or crescent sign in chest X-ray if pulmonary hydatid.
- Raised ESR
- Serological tests—ELISA and immunoelectrophoresis
- USG—cartwheel appearance
- CT—space occupying hypodense lesion with septae—water-lily sign—delaminated endocyst floating in the cavity
- MRCP—may show multiple cysts communicating with biliary tree
- ERCP—for intrabiliary rupture and sphincterotomy if required can be done

### Q 68. What is the treatment of hepatic hydatid cysts?

1. Puncture, aspiration, injection of scolicidal agent (hypertonic saline) and reaspiration (PAIR)
2. Drug treatment:
   - Albendazole—400 mg twice daily for 28 days (act against germinal membrane—it is ovicidal, larvicidal and vermicidal). Preoperative use of albendazole begins 4 days prior to intervention and continued for 28 days. If mebendazole is used it must be continued for 3 months. The liver enzymes and CBC must be done every 2 weeks.
   - Praziquantel—25 mg/kg orally for first 2 weeks along with albendazole. May have to continue for 1 year.
3. Surgery—radical, total or partial **pericystectomy** with omentoplasty. If the lesion is peripheral hepatic segmentectomy.
4. **Laparoscopic approach**—laparoscopic **deroofing** consisting of removal of the cyst containing the endocyst along with the daughter cyst. Initially the cyst is aspirated avoiding spillage using hypertonic saline as the scolicidal agent. Any communication with the biliary tree is oversewn and **pedicled omentum** is sutured to the margins of the cyst. If the cyst is small a **cystopericystectomy** also can be done.

### Q 69. What are the scolicidal agents used during surgery?

- Hypertonic saline (15 to 20%)
- Ethanol (75 to 95%)
- Povidone iodine (5%)—10% will cause sclerosing cholangitis if biliary radicles are communicating with the cysts.

### Q 70. What is the radiological sign of pulmonary hydatid and what is the treatment?

- Usually it will affect the lower lobe of the right lung

JAYPEE BROTHERS

- The cyst is usually single (multiple can also occur)
- The condition may be silent and found incidentally
- The symptoms are cough with expectoration, fever, chest pain and sometimes hemoptysis
- Silent cyst may present as emergency after rupture or anaphylaxis
- X-ray chest will show **meniscus** or **crescent sign**—air between **pericyst** and **laminated membrane** which is the sign of impending rupture (erosion of bronchioles):
  - Water-lily sign—when the cyst ruptures the crumpled collapsed endocyst floats like a lily on the residual fluid in **CT scan**.
  - Pleural effusion after rupture.
- The treatment is cystotomy plus capitonnage. The capitonnage technique involves suturing the edges of the cavity wall together to prevent dead space.
- Praziquantel alone for pulmonary hydatid preoperatively. Albendazole will case cyst rupture in pulmonary. Post-operatively 2 weeks of praziquantel and albendazole.

### Q 71. What are the complications of hydatid cyst?

- Cystobiliary communication due to intrabiliary rupture (IBR) and jaundice
- Peritoneal perforation
- Secondary infection
- Anaphylaxis
- Hepatopulmonary hydatid by rupturing through the diaphragm and it can also rupture to the pericardium
- Secondary hydatidosis

### Q 72. What is the peculiarity of brain hydatid?

There is no pericyst in brain hydatid.

### Q 73. What is alveolar hydatid or malignant hydatid?

This is caused by echinococcus multilocularis which is usually seen in North America, Canada, Alaska, etc. There is invasive growth or infiltration like malignancy unlike the expansion seen in echinococcus granulosus. The lesion is not cystic and it is seen as a fibrous tissue mass with cavities of various sizes. The intermediate host is **rodent**. The complications are:

- Portal hypertension
- Budd–Chiari syndrome
- Cholestasis
- Secondary bacterial infection
- USG will give mixed hypo- and hyperechoic lesion.

### Q 74. What is the treatment of malignant hydatid?

The main stay of treatment is by surgery, which may be hepatic resection or liver transplantation. In inoperable cases albendazole is given indefinitely.

JAYPEE BROTHERS

for detailed information on surgery books, visit our website www.ejaypee.com, for detailed information on surgery books, visit our w

# CLINICAL **SURGERY PEARLS**

***Salient Features***

- Clinical capsule-based short and long cases
- Examination oriented
- Question-and-answer format
- Checklist for clinical history and examination
- More than 100 definitions
- Concepts are simplified to capsule form
- Flowcharts for quick review
- Separate chapter for radiology and tables/imaging
- Thoroughly revised and updated



**R Dayananda Babu** MS MNAMS FIMSA FRCS (Glasgow) is former Principal and Professor Emeritus of Surgery at Sree Gokulam Medical College and Research Foundation, Thiruvananthapuram, Kerala, India; former Senate Member of Kerala University of Health Sciences (KUHS) and Cochin University of Science and Technology (CUSAT); and former National President of the Indian Association of Endocrine Surgery. He is the author of two books—*Clinical Surgery Pearls* and *Surgical Handicraft* and also contributed chapters for two books. He was formerly Chairman, Secretary (State) and National GC Member of Association of Surgeons of India (ASI) for 6 years and Kerala Government Medical College Teachers' Association (KGMCTA) State President. He was given the Susrutha Award for Best Faculty and Visiting Professorship of ASI. He was awarded five national- and nine state-level orations. He is an examiner for MS, MCh (Endocrine Surgery), examiner for National Board, and inspector for National Board. He was awarded the National Jewel of ASI in 2023 and the distinguished alumnus award of Trivandrum Alumni Association. He is member of the ethical committee of Indian Medical Association (IMA) Kerala state.

Shelving Recommendation
**SURGERY**

ISBN 978-93-6616-567-7

9 789366 165677

Buy from ejaypee

JAYPEE BROTHERS