eebrothers.com, for detailed information on gastroenterology books, visit our website www.jaypeebrothers.com, for detailed information on gastroenterology

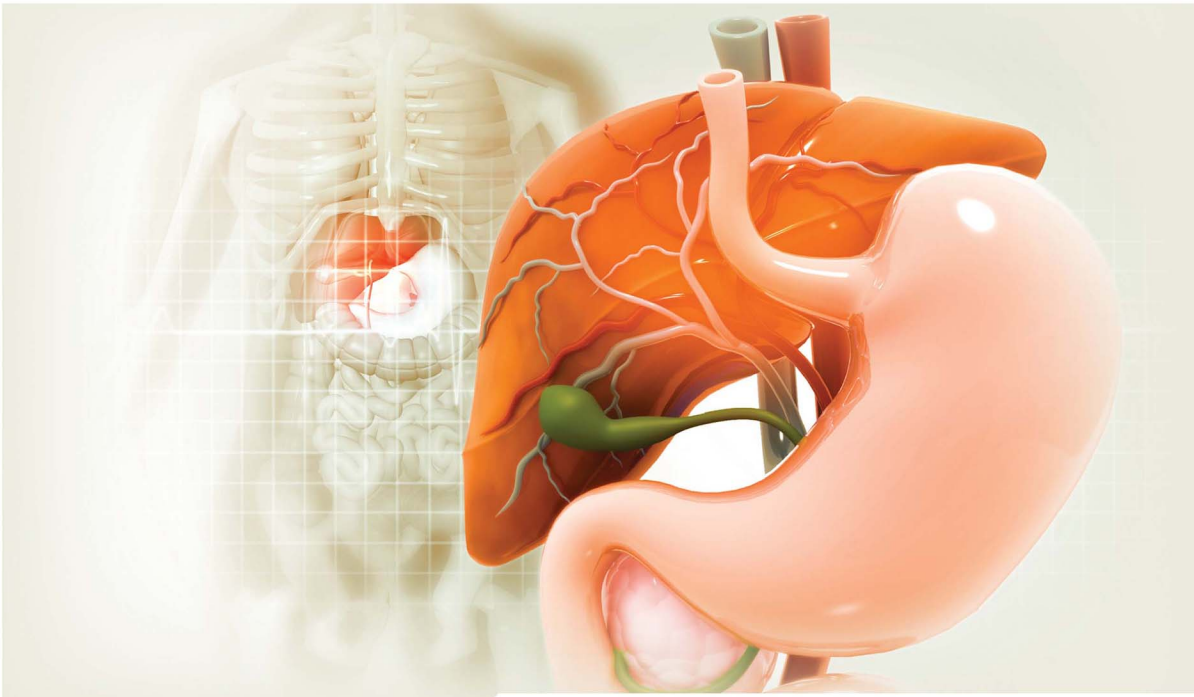

The Practical Approach to

Surgical Gastrointestinal and Hepatopancreatobiliary Diseases

A Clinical Handbook and Preparatory Manual

Advait Sanjay Sonar

Forewords
Baiju Senadhipan
Shailesh V Shrikhande
M Kanagevel
Nissar Hussain Hamdani

JAYPEE

Contents

1.	Few Tips for Overall Case Presentation	1
2.1.	Upper Gastrointestinal—Esophagus and Stomach Cases	5
2.2.	Upper Gastrointestinal—Corrosive Injury	35
2.3.	Upper Gastrointestinal—Ward	47
3.1.	Hepatopancreatobiliary: Malignant Surgical Obstructive Jaundice—History/Examination Discussion	53
3.2.	Hepatopancreatobiliary—Surgical Obstructive Jaundice Approach	61
3.3.	Hepatopancreatobiliary—Management of Cases besides Gallbladder Cancer	65
3.4.	Hepatopancreatobiliary—Gallbladder Cancer Management	85
3.5.	Hepatopancreatobiliary—Imaging Lesions	91
3.6.	Hepatopancreatobiliary—Ward	97
4.	Bile Duct Injury	107
5.	Chronic Pancreatitis	115
6.	Non-cirrhotic Portal Hypertension	131
7.1.	Colorectal—Rectal Prolapse and Cancer	145
7.2.	Colorectal—Inflammatory Bowel Disease and Intestinal TB	164
7.3.	Colorectal—Ward	176
8.	Lump in Abdomen	178
9.	Electrolytes and Calories in Two Minutes	191
10.	TNM Staging of Gastrointestinal and Hepatopancreatobiliary Cancers	193
11.	Clinical Trials	202
Index		215

5

CHAPTER

Chronic Pancreatitis

HISTORY AND EXAMINATION

History of abdominal pain: Pancreatitis related pain is dull aching, episodic, epigastric, radiating to back, and often precipitated/worsened by a fatty meal and relieved on bending forwards.

Increase in intensity of pain/worsening of pain (not getting relieved on oral medications but is requiring IV medication/opioids), forms an indication for surgery. Interference with academics or job also suggests need for intervention and recent change in nature of pain becoming continuous from intermittent, points toward malignant change.

History of persistence/recurrence of pain or upper abdominal lump points toward pseudocyst. However, mass arising on the background of chronic pancreatitis or palpable GB due to distal obstruction secondary to inflammatory biliary stricture/mass in head of pancreas (HOP) or splenomegaly secondary to sinistral portal hypertension (PHTN) can all be palpable and thus become differentials for lump in a case of chronic pancreatitis.

History of vomiting: In the setting of chronic pancreatitis, history of postprandial fullness and/or postprandial vomiting of gastric contents points toward gastric outlet obstruction (GOO) secondary to compression on the stomach, the differentials of which, in patients with chronic pancreatitis are:

- Pseudocyst
- Inflammatory/malignant head mass
- Inflammatory narrowing of duodenum

GI bleed: May occur due to either hemosuccus pancreaticus or left sided portal hypertension. Hemosuccus pancreaticus occurs due to pancreatic enzymes acting on the peripancreatic vessels resulting in pseudoaneurysm formation, which bleeds into the gastrointestinal (GI) tract via the pancreatic duct. Pancreatitis may result in splenic vein thrombosis which may lead to left sided portal hypertension with subsequent variceal bleed. Also grade the severity of bleed.

JAYPEE BROTHERS

History of pruritus, yellowish discoloration of eyes, high colored urine, clay colored stools: Points toward obstructive jaundice, secondary to compression of CBD, the differentials of which, in patients with chronic pancreatitis are:

- Inflammatory edema of the acute (on chronic) attack
- Pseudocyst
- Benign biliary stricture (BBS)
- Inflammatory/malignant head mass

History of fever: As a part of systemic inflammatory response syndrome, or in case of infected pseudocyst or cholangitis.

History of steatorrhea: Exocrine insufficiency manifests in the form of steatorrhea, i.e., malabsorption of fats resulting in excessive loss of fats in stools (>7 g/day), which leads to oily, frothy, malodorous stools which are difficult to flush. Ask if the patient has been taking any tablets for the same (PERT) and if the steatorrhea has reduced/resolved

History suggestive of fat-soluble vitamin deficiency: Due to long term fat malabsorption. Night blindness (vitamin A), osteomalacia leading to fractures (vitamin D), male infertility (vitamin E) and hemorrhage (vitamin K).

History of diabetes mellitus: Endocrine insufficiency as one of the tripods of symptomatology of chronic pancreatitis manifests in the form of diabetes mellitus. However, remember that worsening of glycemic control is a harbinger of malignancy.

Weight loss is seen in chronic pancreatitis due to severe pain often leading to fear of consuming food, exocrine insufficiency and the resulting malabsorption. However, loss of weight combined with loss of appetite points toward malignant change.

Treatment history for established chronic pancreatitis:

- Multiple episodes of admission for IV analgesics/opioids suggest poor pain control and becomes an indication for surgery in chronic pancreatitis.
- *History of endoscopic procedure*: Done for pseudocyst (endoscopic cystogastrostomy), biliary obstruction (ERCP with biliary stenting) and pancreatic duct stones (ESWL followed by pancreatic duct stenting). Failure of endoscopic procedures again becomes an indication for surgery in chronic pancreatitis.

Treatment history for acute/recurrent acute pancreatitis:

- *History of ICU admission*: Points toward severe course of disease: SIRS, infected pancreatic necrosis, Gl bleed.

Treatment history for infected pancreatic necrosis as a part of step up approach:

- *History of endoscopic procedure alone*: Endoscopic cystogastrostomy for pseudocyst (symptomatic/infected) or direct endoscopic necrosectomy for Walled off pancreatic necrosis (symptomatic/infected)

OR

- *History of percutaneous catheter drainage followed by minimally invasive surgery*: Video-assisted retroperitoneal debridement (VARD) or minimally

JAYPEE BROTHERS

invasive retroperitoneal necrosectomy (MIRN) if not settling with PCD alone, followed by abdominal laparoscopic approach or eventually open approach, if not settling with minimally invasive retroperitoneal approaches.

History of surgery: Surgery in an emergency setting is done for:
- Abdominal compartment syndrome
- Bleeding causing hemodynamic instability [not managed by interventional radiology (IR)]
- Bowel ischemia
- Infected pancreatic necrosis or pancreatic hemorrhage with hemodynamic instability.

Past history of:
- Blunt abdominal trauma
- Biliary colic/cholecystectomy
- Painful bones, renal stones, psychic moans (hyperparathyroidism leading to chronic pancreatitis)
- COPD, infertility (cystic fibrosis-*CFTR* gene mutation leading to chronic pancreatitis)

Personal history of alcohol consumption and smoking (etiology for chronic pancreatitis).

Family history of pancreatitis is related to PRSS1, SPINK-1 and CFTR gene mutations.

EXAMINATION PROFORMA

General Examination: Part A

- *Visual appearance*:
  - Young/middle aged/elderly
- *Gender*:
  - Male/female
- *Built*: Poor/average/good
- *Nourishment:* Poor/average/good
  - Measure height, weight, BMI
- *Clinical evaluation*:
  - Conscious/stuporous
  - Cooperative/uncooperative
  - Orientation to time, place and person: Present/absent
  - Hydration status: Hydrated/dehydrated
  - Lying comfortably bed/in discomfort/in pain
  - Whether patient prefers sitting or lying down position
  - Febrile/Afebrile
  - Vitals: Pulse, BP, respiratory rate, mention performance status here as well

JAYPEE BROTHERS

General Examination: Part B

Look for PICCLE, Oral Cavity, Skin

- PICCLE: Pallor, icterus, cyanosis, clubbing, generalized or localized lymphadenopathy, palpable cervical and left supraclavicular lymph node, pedal or dependent edema.
- Examination of oral cavity for hygiene, caries, mucosal lesions.
- Examination of skin for scratch marks (itching results due to obstructive jaundice).

Abdominal Examination

On inspection: See if—

- Any percutaneous drain (PCD) is in place (done for infected pancreatic necrosis)
- Note the nature of effluent: Serous/serosanguinous/sanguineous/purulent/seropurulent/milky (chylous) or cola colored (pancreatic fistula). Infected pancreatic necrosis has a dirty black/brown look
- Abdominal contour: Flat/distended/scaphoid
- Umbilicus: Central/displaced. Inverted/everted/flat
- All quadrants are moving equally with respiration or not

Look for any visible lump: Differentials of lump in abdomen in the context of chronic pancreatitis:

- Pseudocyst
- Inflammatory/malignant HOP mass
- Palpable GB secondary to distal CBD compression/block due to any of the above or benign biliary stricture (BBS)
- Palpable splenomegaly secondary to sinistral PHTN

If visible describe size, site, shape, surface and movement with respiration

- Look for scars of previous surgery or drain tube placement.
- Look for visible sinus, engorged veins, pulsations, peristalsis or cough impulse.
- Inspect the groin hernial sites and examine genitalia.
- Inspection of renal angles to look for fullness

On palpation: See if—

- Abdomen is soft, nontender

Remember the differentials of lump in abdomen in the context of chronic pancreatitis:

- Pseudocyst
- Inflammatory/malignant HOP mass
- Palpable GB secondary to distal CBD compression/block due to any of the above or BBS
- Palpable splenomegaly secondary to sinistral PHTN

If present describe:

- Site
- Size

JAYPEE BROTHERS

- Shape
- Surface
- Margins
- Tenderness
- Consistency
- Mobility
- Movement with respiration
- *Plane*:
    - To help differentiate between abdominal wall and intra-abdominal masses, perform the leg raising test (also known as Carnett's test): a parietal mass will become more prominent while the patient raises their legs, while an intra-abdominal mass will become less prominent.
    - To help differentiate between intraperitoneal and retroperitoneal masses, perform the lateral decubitus test: A retroperitoneal mass will not fall ahead, while an intraperitoneal mass will.
- Palpate groin hernia sites and examine genitals
- Look for tenderness in renal angles
- Examine back and spine for tenderness.

On percussion:
- Look for upper border of liver dullness (generally in the 5th intercostal space) in midclavicular line.
- Note the liver span (normal being 12–14 cm)
- Percussion note over lump if any
- Percussion note over rest of the abdomen
- Tests for free fluid.

Differentials of the ascites in the context of chronic pancreatitis:
- Nutritional (hypoalbuminemia due to poor intake)
- Pancreatic (due to anterior pancreatic ductal disruption leading to pancreatic fistula communicating with the abdominal cavity)
- Malignant (head mass)

On auscultation:
- Auscultate for bowel sounds.
- Bruit, hum and rub
- *Per-rectal examination*: Look for metastatic deposits in the pouch of Douglas (Blumer Shelf)

Respiratory Examination

Increased tactile vocal fremitus on palpation, dullnote on percussion and reduced breath sounds on auscultation are a clue toward pleural effusion (secondary to hypoalbuminemia or to posterior pancreatic ductal disruption forming a pancreatopleural fistula).

Rest systemic examination

JAYPEE BROTHERS

RECURRENT ACUTE PANCREATITIS (RAP)[1,2]

Definition of recurrent acute pancreatitis (AP): At least >2 attacks of AP with at least 3 months gap in between, without any clinical or imaging features of chronic pancreatitis (CP).

Alcohol, gallstones, trauma (blunt, post-ERCP) are most common causes of AP and if not eliminated, can cause RAP. But 10–25% are idiopathic of which, the causes are listed below, which lead to RAP. However, even after all investigations, the cause would not be found for some, which are the truly idiopathic cases.

Idiopathic RAP is most commonly seen due to: Mechanical/anatomical or toxic metabolic or miscellaneous factors.

Mechanical and anatomical:

- *Microlithiasis*: <3 mm stones (diagnosis best with EUS ~96% sensitivity). *Treatment*: Cholecystectomy
- Biliary parasites
- *Pancreatobiliary tumors* (ampullary tumors and IPMNs present with RAP in ~5%): Best diagnosed with EUS
- Types 1 and 4 choledochal cyst (CDC)
- Type 3 CDC causing main pancreatic duct (MPD) obstruction: Treatment is endoscopic sphincterotomy
- *Sphincter of Oddi dysfunction (SOD)*: Type 1 SOD has best prognosis after sphincterotomy
- Pancreas divisum (PD) (only if associated with a second hit of genetic mutation like *CFTR*, *SPINK1*, *PRSS1*). In PD, majority pancreas drains through minor papilla (longer superior duct), while the lower duct is small, drains only lower part of head and uncinate into major papilla. So on MR, PD appears as crisscrossing of the pancreatic duct with the CBD, whereas, a normal pancreatic duct meets the CBD at the lower end.
  Treatment is minor papilla sphincterotomy.

Toxic metabolic:

- Hypercalcemia
- Hypertriglyceridemia
- Drugs

Miscellaneous:

- Vascular
- Hereditary, familial pancreatitis
- Early CP (presents without calcification and ductal dilatation in it's initial stages)

1st phase investigations after 1st attack of AP:

- *History and examination*: Alcohol, biliary colic, trauma, viral illness (measles, mumps, rubella), painful bones and renal stones for hyperparathyroidism, dry eyes and dry mouth for autoimmune pancreatitis (AIP), chest infections and infertility for cystic fibrosis (CF), then drugs and family history.

JAYPEE BROTHERS

- *Biochemistry*: LFT (Bilirubin >3, ALT ≥3 times: means biliary pancreatitis. ALT >150 ~96% sensitive for it. Abnormal LFT in 48 hours, with a normal USG, suspect microlithiasis), calcium, lipids.
- *Imaging*: USG, CECT.

If negative, then labeled as idiopathic pancreatitis, and proceed to 2nd phase investigations.

2nd phase:

- EUS done 6–8 weeks of acute attack, so changes of AP resolve and CP if present can be diagnosed better.
  - EUS is best for diagnosis of microlithiasis, occult biliary tumors, congenital anomaly of the pancreas like divisum, early CP, evaluation of CP with head mass, and for evaluation of location of pseudocysts for possible drainage and for other cystic lesions for which EUS FNA can be done.
  - The changes suggestive of CP include both parenchymal (hyperechoic foci, hyperechoic strands, parenchymal lobularity, calcification) and ductal (pancreatic duct dilatation, irregularity, hyperechoic walls, visible side branches)
  - Rosemont major criteria: Hyperechoic foci with shadowing, lobularity with honeycombing, and MPD calculi.
- MRCP and Secretin MRCP if needed to rule out IPMN
- ERCP followed by bile microscopy to look for biliary crystals (indirect sign of microlithiasis), manometry (for suspected SOD)

If negative, then
3rd phase:
Genetic testing for *SPINK1*, *PRSS1*, *CFTR* (with sweat chloride test).

Just remember:

- AP, RAP and CP form a continuum
- Truly idiopathic RAP most often progresses to CP, hence regular follow-up recommended.
- Approximately 40–45% of RAP proceed to CP (necrosis-fibrosis and SAPE hypotheses).

TRIALS IN INFECTED NECROTIZING PANCREATITIS

1. PANTER: Step up approach: Percutaneous drainage (PCD) or endoscopic drainage followed by VARD/MIRP followed by open versus upfront open surgery. So 35% settled with PCD alone
2. PENGUIN (JAMA 2010): Endoscopic step up: Drainage followed by direct endoscopic necrosectomy (DEN)] versus upfront surgical. Death rates equal. Lesser perforation, pancreatic fistula (PF), new onset organ failure, endo and exocrine insufficiency, incisional hernia in endoscopic group
3. TENSION (LANCET 2017): Endoscopic step up versus surgical. PF and length of stay (LOS) less in endoscopic group

JAYPEE BROTHERS

4. MISER (J GASTRO 2019): Endoscopic step up versus minimally invasive surgery. None of the patients in endoscopic group had enteral or PF (vs. 28% in surgery) and physical quality of life (QOL) scores much better and cost lesser than compared to surgical.
5. POINTER (NEJM 2021): Immediate (≥24 hours of suspicion of infected necrosis) versus delayed PCD [after stage of Walled off necrosis (WON)]. So delayed PCD better as lesser complications and necrosectomy procedures required.

CHRONIC PANCREATITIS

Characterized by tripod of pain, exocrine pancreatic insufficiency (EPI) and endocrine insufficiency along with fibroinflammatory destruction of the pancreas.

EPI causes, diagnosis, management: Different causes of EPI in general: (DDs of EPI/steatorrhea can be asked during viva):

1. *Pancreatic causes*: Acute necrotizing pancreatitis, CP, and following pancreatic resectional surgeries
2. *Nonpancreatic causes*:
   - Celiac disease
   - Crohn disease
   - Zollinger–Ellison syndrome

EPI results in decreased absorption of:

- Fat including essential fatty acids
- Fat-soluble vitamins A, D, E and K
- Calcium, magnesium, zinc, thiamine and folic acid

Patients with EPI frequently experience:

- Abdominal distention, abdominal discomfort and/or pain, flatulence, diarrhea and grossly as steatorrhea [classically defined as at least 7 g of fecal fat over 24 hours (100 g of fat daily for 72 hours)] and weight loss
- Anemia resulting from malabsorption can be either microcytic (related to iron deficiency) or macrocytic (related to vitamin B12 deficiency).
- Intermediate and long-term malnutrition from EPI increases the incidence of osteopenia/osteoporosis, low-trauma fractures, cardiovascular diseases and infections.

The diagnostic options for EPI include:

- Indirect measures (i.e., 72–hour fecal fat and fecal elastase) or
- Direct measures (i.e., secretin–cerulein or secretin–pancreozymin tests).

Pancreatic Enzyme Replacement Therapy (PERT)

- Pancreatic enzymes are derived from swine or Ox pancreas
- Pancreatic enzyme products contains three pancreatic enzymes (i.e., amylase, protease, and lipase)
- Approximately 25,000–40,000 IU of lipase is required to digest a typical meal, and about 5,000–25,000 IU of lipase per snack.

JAYPEE BROTHERS

- Enteric coated (EC)-bicarbonate-buffered PERT has previously been shown to produce a significant increase in fat absorption in cystic fibrosis (CF) patients compared with treatment with EC-nonbuffered PERT at equivalent lipase doses.
- Lipase doses >6,000 units/kg/meal are associated with colonic stricture (fibrosing colonopathy)

Monitoring therapy:
- *Clinical improvement*:
  - Weight gain
  - Symptomatic improvement in diarrhea
  - Degree of symptom improvement does not always correlate with the patient's nutritional status
- *Blood investigations*:
  - Serum retinol-binding protein, ferritin, and prealbumin
- *Carbon-13 breath test*: 13C-labeled mixed triglyceride breath test
- Coefficient of fecal fat absorption (CFA)

If no improvement, get fecal chymotrypsin levels done (if normal, then it is good compliance, if not, then counsel).

So if it's normal, then change diet: Fat maximum 50–75 g/day, low fiber, no alcohol, increase lipase dose, and add PPI or H2 blockers.

If still no results, then check for alternative causes (bacterial overgrowth, blind loop syndrome, other secondary causes of diarrhea).

Complications of CP

- Pseudocyst
- Complications of pseudocyst like causing GOO, bleeding into cyst which may present as hemosuccus pancreaticus, CBD obstruction and cholangitis, infection, rupture leading to pancreatic ascites/pleural effusion
- Inflammatory mass/cancer in HOP
- Duodenal stenosis/BBS
- Splenic vein thrombosis leading to left sided PHTN, splenomegaly and gastric varices causing UGI bleed
- Arterial pseudoaneurysms

Lump in a Case of CP May be Due to

- Pseudocyst
- Inflammatory mass/cancer in HOP itself
- Distended stomach due to GOO (secondary to pseudocyst, mass, duodenal stenosis)
- Distended GB due to distal BBS or secondary to lower CBD compression due to pseudocyst/inflammatory mass/cancer in HOP
- Splenomegaly secondary to left sided PHTN due to splenic vein thrombosis

Causes of Jaundice in CP

- Cholelithiasis (CL) with choledocholithiasis (CDL)
- Inflammatory edema of acute attack

JAYPEE BROTHERS

- BBS
- Lower CBD compression due to pseudocyst/inflammatory mass/cancer in HOP

Clinical Pointers Toward Malignancy Developing in CP

- Change in the nature of pain, with episodic/intermittent becoming more continuous
- Progressively deepening jaundice
- Recent onset of DM (within 2 years of CP)/worsening of glycemic control OR onset after 50 years of age
- Anorexia with profound weight loss
- Tropical CP (non-alcoholic, young, large ductal stones) has more chances than alcoholic CP for malignancy

So now, to Begin with, Ask for Two Sets of Investigations for CP

One to confirm/arrive at a diagnosis and assess for complications and other to complete the workup of the patient.

So for workup:

- All blood tests
- *See LFT*: Raised bilirubin, ALP, GGT in OJ due to CDL/BBS or malignancy, also deranged LFT with enzymes seen in alcoholic hepatitis/cholangitis

And additionally:

- Serum amylase, lipase (to rule out acute on CP)
- Serum PTH level, calcium, lipids (as all can cause recurrent AP and lead to CP). Get IgG4 and sweat chloride test if indicated.
- For endocrine insufficiency: Blood glucose, HbA1c, glucose tolerance test (GTT)
- For exocrine insufficiency: Fecal fat, Sudan stain, fecal elastase (low levels <100 seen in CP) and fecal chymotrypsin (low levels seen when not compliant with PERT)
- *Ask for* Ca 19–9 for any suspicion of malignancy *only after USG abdomen and CXR* (to be repeated after biliary decompression)
- *For diagnosis*: USG to show status of liver (alcoholic), any space occupying lesion (SOL), IHBRD, status of GB (CL), CBD (CDL/BBS), pancreas for changes of CP like atrophy, calcifications, calculi, ductal dilatation, chain of lakes and complications of CP like pseudocyst, mass, ascites (nutritional or pancreatic or malignancy), pleural effusion, venous thrombosis, collaterals, varices, splenomegaly, pseudoaneurysms. Also look for peripancreatic fat stranding to rule out acute pancreatitis.
- Plain X-ray to see stones from L1 at right, to left of abdomen
- CECT to have a geographical location of stone load and to better assess other above-mentioned complications of CP as CECT is more sensitive than USG for all this and also to evaluate the mass.
- MRI abdomen for better delineation of any cystic lesion in pancreas or any indeterminate lesion in liver with MRCP for the ductal anatomy (CBD for CDL, BBS, and MPD for strictures, dilatations).

JAYPEE BROTHERS

- UGIE to look for ulcers, varices, bulge of pseudocyst, side viewing endoscopy (SVE) to assess periampullary region.
- EUS which will help to know microlithiasis (<3 mm stones), early CP by Rosemont criteria, EUS guided cystogastro/enterostomy and direct endoscopic necrosectomy can be done.
- EUS-FNA may help to take biopsy from head mass (EUS FNA is more preferable for head mass than tail mass, as in latter it may lead to peritoneal seeding).
- EUS will also help characterize cystic lesions of pancreas, and EUS FNA of cyst fluid for analysis can be done.

So Four Objective Criteria for HOP Mass in CP to be Malignant: (Stanley Criteria)

1. Raised bilirubin (>5.8 mg/dL)
2. Raised CA19–9 (>127)
3. Dilated CBD (14.5 mm)
4. Dilated MPD (11.5 mm)

Other Objective Pointers of the HOP Mass Being Malignant

- Imaging features: Heterogeneously hypoenhancing in arterial phase on CECT (whereas inflammatory mass is homogeneously hyperenhancing), with diffusion restriction on DW-MRI, with high SUV max on FDG PET CT.
- Confirmation by EUS FNA.

Standard Indications of Surgery in CP

- Intractable pain (not relieved by conservative treatment or requiring frequent and/or persistent use of opiates, side effects of narcotics/addiction and/or interfering with QOL).
- Inflammatory complications:
  - Symptomatic pseudocyst causing GOO, UGI bleed (due to bleed within the cyst resulting in hemosuccus pancreaticus OR splenic vein thrombosis secondary to inflammation leading to left sided PHTN with gastric varices) or peritoneal bleeding due to ruptured pseudoaneurysm, symptomatic CBD obstruction (jaundice/cholangitis), infected cyst or rupture leading to pancreatic ascites or pleural effusion.
  - Inflammatory mass causing GOO/CBD obstruction
  - Duodenal stenosis causing GOO
  - BBS leading to symptomatic CBD obstruction
- HOP mass suspicious for cancer (Stanley criteria + imaging features of mass on CECT, DW-MRI and FDG PET CT + confirmation with EUS FNA)

ESCAPE Trial in CP

Early surgery ≤3 years of onset of pain leads to better pain control and QOL along with better preservation of pancreatic function.

JAYPEE BROTHERS

Dilated CBD, with Dilated main Pancreatic Duct (MPD) in CP, Consider

- CDL
- CDC
- BBS
- Intraductal papillary mucinous neoplasm-Biliary (IPMN-B)
  All of the above cause dilated CBD, and may be seen with a dilated MPD due to CP itself or with an intraductal papillary mucinous neoplasm-Pancreatic (IPMN-P) associated also with CP.
- Periampullary lesion
- CP with head mass

Cause of Hugely Dilated CBD and Hugely Dilated MPD with Normal Bilirubin (So Nonobstructing Cause)

CDC/IPMN-B with CP/IPMN-P.

Causes of Hugely Dilated MPD with Normal Bilirubin

- CP
- IPMN-P

Types of Surgery for CP (Only the Ones in Actual Practice are Mentioned and Discussed Here)

- Drainage [lateral pancreaticojejunostomy (LPJ)]
- Resectional (DPPHR—Duodenum preserving pancreatic head resection—Beger's procedure and Whipple and total pancreatectomy)
- Hybrid procedures (Frey's and Izbicki) and
- For pain—celiac plexus block, thoracoscopic splanchnicectomy

Drainage Procedures

Lateral Pancreaticojejunostomy

Indication:
For ductal disease with dilated (>6 mm) pancreatic duct and pancreatic ductal calculi without inflammatory mass in the head/bulky head.

Crux of the procedure:
Pancreatic duct is filleted open along its entire length from the head to the tail, stones are removed and the opened duct is anastomosed side-to-side with a Roux-en-Y loop of jejunum. Extremely important to open the duct and remove the stones entirely in the tail, minor ducts and also in the uncinate region. *Not doing so* may lead to recurrent attacks of acute on chronic CP and pseudocyst formation which renders the index operation futile, thus giving LPJ a bad name.

How to identify the pancreatic duct:

- If the duct is dilated on imaging, then it may be seen obviously or felt as a fluctuant longitudinal bulge on the anterior surface of the body of the pancreas between its upper and lower borders

JAYPEE BROTHERS

- Needle puncture on the anterior surface of the body of the pancreas midway between the superior and inferior borders and aspiration of clear watery pancreatic fluid or hitting a large stone with a gritty sensation transmitted while doing so
- Head coring of pancreatic parenchyma as is done in Freys
- Intraoperative ultrasound to locate the duct followed by USG guided needle puncture
- Duodenotomy and cannulation of the pancreatic ampullary orifice with an infant feeding tube
- Preoperative placement of pancreatic stent

Advantage:
?Preservation of pancreatic function.

Disadvantage:
Cannot drain ducts completely in a bulky head/inflammatory HOP mass which form the indications for performing a hybrid/resectional procedure.

Resectional Procedures

Beger

Indication: Inflammatory mass in the head of pancreas.

Crux of the procedure:
Resection of the pancreatic head anterior to the portal vein-small rim of pancreatic parenchyma within the C loop of duodenum is preserved to protect the pancreato-duodenal arcades and the duodenal blood supply. Pancreas is transected at its neck (in front of the superior mesenteric vein portal vein). The remaining pancreas (along C loop on one side and body on the other) is anastomosed to a Roux loop of jejunum. Two pancreaticojejunal anastomoses to the same Roux loop (one to the end of the distal pancreas and other to the rim of the pancreatic tissue in the head).

Advantage:
Relieves biliary obstruction as well (which is however, relieved even with a Frey's procedure which is much safer to perform as it avoids the dangerous dissection and division of the pancreatic neck in front of the portal vein).

Disadvantages:
- Risky due to above-mentioned reason.
- Loss of parenchyma more as compared to LPJ and Freys—Higher risk of exocrine (steatorrhea) and endocrine (diabetes) insufficiency.
- Does not address the pancreatic duct in the body and tail and hence, should not be performed as the sole procedure in such case.

Modifications:
Berne modification: Pancreas is not transected at its neck and the cored head is anastomosed to a Roux loop of jejunum—with only a single anastomosis.

JAYPEE BROTHERS

Whipple

Indication:
HOP mass likely to be malignant as per stanley/other objective criteria mentioned above.

Advantage:
- R0 resection possible as tumor planes not breached as would be in head coring
- Relieves biliary obstruction as well
- Pacemaker of pain resected

Disadvantages:
- Loss of parenchyma more as compared to LPJ and Freys—Higher risk of exocrine (steatorrhea) and endocrine (diabetes) insufficiency
- Higher morbidity due to POPF/PPH/DGE

Total Pancreatectomy with Islet Auto-transplantation (IAT)

Indication:
Rescue surgery in intractable pain of chronic pancreatitis (after previous surgery for CP).

Requires:
Preserved islet cell function, which is a rarity due to endocrine insufficiency seen with CP.

Advantage:
When compared to Whipples procedure, in addition to its advantages, there is no morbidity of POPF as there is no pancreatic anastomosis.

Disadvantages:
- Brittle diabetes (insulin and glucagon, both are lost) and severe exocrine insufficiency (however, both are manageable medically)
- Autonomic sensitization may lead to pain even after such an extensive procedure

Hybrid Procedures: Drainage + Resection Combined

Frey's Procedure

Indication:
Bulky head/inflammatory HOP mass along with ductal strictures/stones in the pancreatic duct in body and tail.

Crux of the procedure: *Head coring + LPJ*
So unroofing of the pancreatic ducts in head and uncinate process of the pancreas anterior to the ducts or up to the posterior capsule+ opening of the entire pancreatic duct in the body and tail + LPJ.

Ligation of ASPDA branch of Gastro-duodenal artery (GDA) helps decrease bleeding during the coring of the head.

JAYPEE BROTHERS

Also, bleeding due to injury to the anterior pancreaticoduodenal arcade of vessels between the head of the pancreas and the C loop of the duodenum can be prevented by taking multiple deep sutures in the pancreatic parenchyma 0.5–1 cm away from the pancreaticoduodenal groove.

Advantages:
- Helps to identify an undilated pancreatic duct
- Drains all ducts in the head and uncinate process (achieved with anterior coring)
- Removes pacemaker of the pain in CP, which is the head of the pancreas (achieved with posterior coring)
- A well performed Frey's even decompresses the obstructed CBD

Izbicki Procedure

Indication:
Undilated ducts in the parenchyma with diffuse stone disease.

Crux of the procedure:
Excision of a V-shaped wedge of the parenchyma anterior to the pancreatic duct to expose the undilated pancreatic duct, followed by jejunal anastomosis.

Hamburg modification – Izbicki procedure + head coring

Few Tips in Surgery for Chronic Pancreatitis (CP)

How is obstructed (dilated) CBD in CP handled?
- CBD may get decompressed by head coring alone in Frey's: pre and post-coring intraoperative cholangiogram (IOC) will confirm this
- CBD may get opened unintentionally into the cored out cavity in Frey's. So at that time it may be marsupialized–the walls of the opened CBD sutured to the pancreatic parenchyma to keep it open. But this has high stricture rates, so even in this situation, a formal choledochoduodenostomy (CDD) OR choledochojejunostomy (CDJ) in the same loop OR HJ in a separate loop, is preferred.
- CDD is an option if the duodenum is soft, supple and can be easily mobilized.
- CDJ may be done into the same Roux loop of the jejunum into which LPJ is done.
- HJ is the best (done to a separate loop of jejunum) as BBS in CP may often be long, extending proximally, which may lead to inadequate drainage with CDD/CDJ.
- Biliary diversion with CDD/CDJ/HJ alone, if pancreatic ductal surgery is not indicated (rare).

What all to be handled during surgery for CP:
1. Drainage of MPD, parenchyma and pseudocyst (in same loop)
2. In case of BBS, drainage of CBD (discussed above)
3. If left sided PHTN with varices, then add splenectomy

JAYPEE BROTHERS

4. *If head mass/distal CBD stricture suspicious for malignancy, or even one EUS or intraoperative core biopsy (for head mass) or ERCP brush cytology/biopsy (of stricture) is suspicious for malignancy, then directly proceed with whipple/* Distal pancreatosplenectomy (Depending upon where the mass is), and do additional procedures for CP as required as per points 1–3.
5. In a case of CP with pseudocysts, with a malignancy, if there has been an acute attack of pancreatitis get a MDT discussion.

Ideally wait for at least 4 weeks for inflammation to resolve, and in the mean time, do EUS guided cystogastrostomy and simultaneously start on NACT, and then re-stage and operate for malignancy, while also addressing the CP and pseudocysts (if was not addressed adequately endoscopically).

REFERENCES

1. Kedia S, Dhingra R, Garg PK. Recurrent acute pancreatitis: an approach to diagnosis and management. Trop Gastroenterol. 2013;34(3):123-35.
2. Machicado JD, Yadav D. Epidemiology of Recurrent Acute and Chronic Pancreatitis: Similarities and Differences. Dig Dis Sci. 2017;62(7):1683-91.

JAYPEE BROTHERS

for detailed information on gastroenterology books, visit our website www.jaypeebrothers.com, for detailed information on gastroenterology books, visit our we

The Practical Approach to Surgical Gastrointestinal and Hepatopancreatobiliary Diseases

A Clinical Handbook and Preparatory Manual

This book is your ultimate companion for mastering Gastrointestinal and Hepatopancreatobiliary (GI & HPB) surgery, whether you are preparing for exit examinations, aiming for superspeciality in Surgical Gastroenterology or Surgical Oncology, or enhancing your skills as a general surgeon. Designed to address both practical and theoretical aspects, it serves as a one-stop reference crafted with insights from the premier surgical institutes in the country.

Key Highlights

- *Comprehensive examination guidance*: Begin with a detailed preface on how exit exams are conducted and practical tips to help you excel.
- *Core case discussions:* Dive into history-taking, examinations, and step-by-step case management for major GI & HPB cases. Each case mirrors real exam scenarios with in-depth discussions on investigations, decision-making, and treatment plans.
- *Ward-specific insights*: Explore a dedicated "ward" section after each case, covering postoperative complications and their management, crucial for both exams and real-world practice.
- *Concise reference material*: Wrap up your preparation with a quick-read chapter on electrolytes and nutrition, along with the latest TNM staging and clinical trial updates for a cutting-edge understanding.

Whether you are a general surgery resident, a budding clinician, or an experienced surgeon aspiring to specialize, this book distills complex concepts into an accessible, exam-oriented format, empowering you to approach every case with confidence.



Advait Sanjay Sonar completed his MBBS and MS training in General Surgery from Lokmanya Tilak Municipal Medical College and General Hospital, Mumbai and his Superspeciality training in Surgical Gastroenterology (GI & HPB surgery) from Government Medical College, Srinagar. He successfully cleared all his national entrance and exit examinations in the first attempt. Subsequently, he did his post doctoral fellowship in GI oncosurgery from Tata Memorial Hospital, Mumbai, India.

Achievements & Awards:

- All Maharashtra General Surgery Quiz (2019): Third Prize
- All India Physiology Quiz (2012): Second Prize
- National Balshree Presidential Honour (2009) for excellence in creative writing, conferred by the Honorable President of India, Smt. Pratibha Patil, at Rashtrapati Bhavan, New Delhi, India.

Printed in India

Available at all medical bookstores or buy online at www.ejaypee.com

JAYPEE BROTHERS
Medical Publishers (P) Ltd.
EMCA House, 23/23-B, Ansari Road,
Daryaganj, New Delhi - 110 002, INDIA
www.jaypeebrothers.com

Join us on facebook.com/JaypeeMedicalPublishers
Follow us on instagram.com/JaypeeMedicalPublishers

Shelving Recommendation
GASTROENTEROLOGY

ISBN 978-93-6616-624-7