nformation on obstetrics & gynecology books, visit our website www.ejaypee.com, for detailed information on obstetrics & gynecology books, visit our website www.ejaypee.com

Principles & Practice of COLPOSCOPY





4th Edition

B. Shakuntala Baliga

Foreword
Swee Chong Quek

JAYPEE

Contents

1. Introduction and Historical Survey 1
2. Tissue Basis of Colposcopy 8
3. Screening Tests for Cervical Cancer: An Update for the Gynecologist 26
4. The Colposcopy Unit 65
5. Colposcopic Terminology and Appearances of the Cervix 87
6. Assessment and Interpretation of Abnormal Colposcopic Appearances of the Cervix 100
7. Indications and Technique of Colposcopy of the Cervix 123
8. Problems and Errors in Colposcopy 143
9. Atlas of Colpophotographs: Normal Transformation Zone 155
10. Atlas of Colpophotographs of Abnormal Transformation Zone: Cervical Intraepithelial Neoplasia 169
11. Atlas of Colpophotographs of Abnormal Transformation Zone: Microinvasive and Invasive Cancer 211
12. Atlas of Colpophotographs: Miscellaneous and Nonspecific Colposcopic Findings 234
13. Colposcopy during Pregnancy 246
14. Colposcopy of the Vagina 254
15. Colposcopy of the Vulva 280
16. Colposcopy of Human Papillomavirus Genital Lesions in Women 294
17. Management of Women with Abnormal Primary Screening Test Results 308
18. Biopsy-proven Cervical Intraepithelial Neoplasia: Management Options 324
19. Ablative and Excisional Treatments for Cervical Intraepithelial Neoplasia 335
20. Problematic and Interesting Cases of Colposcopy 354
21. Gray Areas in Colposcopy 385
22. Immunostaining and Advances in Technology for Cervical Cancer Screening 399
23. Reprocessing and Cleaning in the Colposcopy Clinic 411
24. Quality Assurance in Colposcopy Services 418
25. Colposcopy Training, Certification, and Accreditation 423

APPENDICES

Appendix 1: Syllabus for Training in Colposcopy **429**

Appendix 2: Colposcopy Training Program. Patient Log Form **430**

Appendix 3A: 5% Acetic Acid and Lugol's Iodine **432**

Appendix 3B: Monsel's Paste and Glycerol Starch **433**

Appendix 4: Colposcopy Evaluation Form **434**

Appendix 5: Line Diagrams of Cervix **439**

Appendix 6: Line Diagrams of Vagina **440**

Appendix 7: Line Diagrams of Vulva **441**

Appendix 8: The 2014 Bethesda System for Reporting Cervical Cytology **442**

Appendix 9: International Federation for Cervical Pathology and Colposcopy: Colposcopic Terminology (2011) **444**

Appendix 10: Comprehensive Standards for Good Practice in Colposcopy **446**

Appendix 11: Cryosurgery Record **448**

Appendix 12: LEEP/LLETZ Record **452**

Appendix 13: Important Links **456**

Index *457*

CHAPTER

5

Colposcopic Terminology and Appearances of the Cervix

The International Federation for Cervical Pathology and Colposcopy (now renamed International Federation for Cancer Prevention and Colposcopy, IFCPC) approved a revised colposcopic terminology in 2011 **(Table 5.1)**.[1] The IFCPC recommends the use of this format worldwide for clinical diagnosis, treatment, and research in cervical cancer.

COMPARISON OF THE 2002 AND 2011 IFCPC COLPOSCOPIC TERMINOLOGY OF THE CERVIX

- A new category termed "general assessment" was introduced in the 2011 terminology, which includes the three types of transformation zones (TZs) and also

TABLE 5.1: The 2011 International Federation for Cervical Pathology and Colposcopy. Colposcopic terminology of the cervix.

General assessment		• Adequate/inadequate for the reason (e.g., the cervix is obscured by inflammation, bleeding, or scarring) • SCJ visualization: Complete/partial/none • Transformation zone types 1, 2, and 3		
Normal colposcopic findings		Original squamous epithelium: Mature and atrophic Columnar epithelium: Ectopy/ectropion Metaplastic squamous epithelium, Nabothian cysts, and crypt (gland) openings Deciduosis in pregnancy		
Abnormal colposcopic findings	General principles	• Location of the lesion: Inside or outside the TZ • Location of the lesion by clock position on the cervix • Size of the lesion: Number of cervical quadrants the lesion covers and/or size of the lesion as a percentage of cervix		
	Grade 1 (minor)	Thin acetowhite epithelium, fine mosaic, fine punctation, irregular, geographic border		
	Grade 2 (major)	Dense acetowhite epithelium	Sharp border	Rapid appearance of acetowhitening
		Coarse mosaic	Inner border sign	Cuffed crypt (gland) openings
		Coarse punctation	Ridge sign	
	Nonspecific findings	Leukoplakia (keratosis, hyperkeratosis), erosion, Lugol's staining (Schiller's test): Stained/nonstained		
Suspicious for invasion		• Atypical vessels • Additional signs: Fragile vessels, irregular surface, exophytic lesion, necrosis, ulceration (necrotic), and tumor/gross neoplasm		
Miscellaneous findings		Congenital transformation zone	Polyp (ectocervical/endocervical)	Stenosis
		Erosion (traumatic)	Condyloma	Congenital anomaly
		Inflammation	Endometriosis	Post-treatment consequence

(SCJ: squamocolumnar junction; TZ: transformation zone)
Source: Bornstein J, Bentley J, Bösze P, Girardi F, Haefner H, Menton M, et al. The 2011 colposcopic terminology of the International Federation for Cervical Pathology and Colposcopy. Obstet Gynecol. 2012;120(1):166-72.[1]

JAYPEE BROTHERS

the reason for an "inadequate" visualization of the squamocolumnar junction (SCJ).

- The term "unsatisfactory colposcopic examination" has been removed.
- Atrophy, deciduosis, erosion, and keratosis (now termed leukoplakia) have been removed from the "Miscellaneous" category of the 2002 terminology. The first two are included in the "normal colposcopic findings" and the other two are included in a new category termed "nonspecific findings" under the "abnormal colposcopic findings" of the 2011 terminology.
- Under "abnormal colposcopic findings" certain characteristics of the lesion have to be mentioned under "general principles." This most importantly includes the location and size of the abnormal lesion. This makes it easier to recommend appropriate treatment, compare outcomes of different treatments, and compare outcomes of treatments between different centers.
- Surprisingly, the results of iodine staining have been included under "nonspecific abnormal findings" and not under minor/major grade of abnormality.
- Erosion (due to trauma) has been included as a new term under the "miscellaneous" category.

Additionally, the 2011 IFCPC terminology has also introduced colposcopic terminology for the excision treatment types; details are presented in **Table 5.2**. Tatti et al. have tabulated details of the excision treatment types, making use of the 2011 IFCPC terminology **(Table 5.3)**.[2]

Inadequate Colposcopy (Previously "Unsatisfactory" Colposcopy)

The conditions that give rise to an inadequate colposcopy are continuous bleeding from within the uterus (e.g., menstrual blood or cancer) or from the fragile inflamed or cancerous cervical epithelium, thick cervical mucus (seen during pregnancy and during the luteal phase of the menstrual cycle), thick abnormal cervical discharge,

TABLE 5.2: The 2011 International Federation for Cervical Pathology and Colposcopy. Colposcopic Terminology of the Cervix—Addendum.

Section	*Pattern*
Excision treatment types	Excision types 1, 2, and 3
Excision specimen dimensions	• Length—the distance from the distal or external margin to the proximal or internal margin • Thickness—the distance from the stromal margin to the surface of the excised specimen • Circumference (optional)—the perimeter of the excised specimen

Source: Bornstein J, Bentley J, Bösze P, Girardi F, Haefner H, Menton M, et al. The 2011 colposcopic terminology of the International Federation for Cervical Pathology and Colposcopy. Obstet Gynecol. 2012;120(1):166-72.[1]

TABLE 5.3: Classification of excisional treatment.

Excision type	*Type 1 excision*	*Type 2 excision*	*Type 3 excision*
Transformation zone type	Type 1	Type 2	Type 3
Condition	In any grade of squamous CIN, serious consideration should be given to excising CIN3 disease	• Any grade of squamous CIN • Glandular disease in women <36 years • Suspected microinvasion	• Any grade of squamous CIN • Glandular disease in women >36 years • Suspected microinvasion
Other circumstances		Previous treatment	Previous treatment
Techniques included in this category of excision	LLETZ/LEEP Laser excision	• LLETZ/LEEP, SWETZ • Laser excision • Cold knife cone biopsy/ cylindrical excision	• LLETZ/LEEP, SWETZ • Cold knife cone biopsy/ cylindrical excision
Alternative treatment choices	Type 1 ablation		

(CIN: cervical intraepithelial neoplasia; LEEP: loop electrosurgical excision procedure; LLETZ: large loop excision of the transformation zone; SWETZ: straight wire excision of the transformation zone)
Source: Tatti S, Bornstein J, Prendiville W. Colposcopy: a global perspective. Introduction of the new IFCPC colposcopy terminology. Obstet Gynecol Clin North Am. 2013;40(2):235-50.[2]

JAYPEE BROTHERS

or difficulty in visualizing the cervix (e.g., severe cervical and/or vaginal and vulvar atrophy).

COLPOSCOPIC TERMINOLOGY AND APPEARANCES

Normal Colposcopic Findings

Original Squamous Epithelium

It is smooth, pink, and covers the ectocervix and vagina. There are no remnants of gland openings or Nabothian cysts. It does not turn white after acetic acid application and stains a dark mahogany brown after application of Lugol's iodine. Sometimes an inconspicuous vascular pattern can be seen as looped capillaries or a fine network. This is *mature* squamous epithelium seen in women of reproductive age group **(Figs. 5.1A to C)**. *Atrophic* squamous epithelium occurs due to low estrogen states as is seen in postmenopausal and prepubertal girls. It is pale pink in color, with partial iodine uptake and prominent stromal vessels **(Figs. 5.2A and B)**.

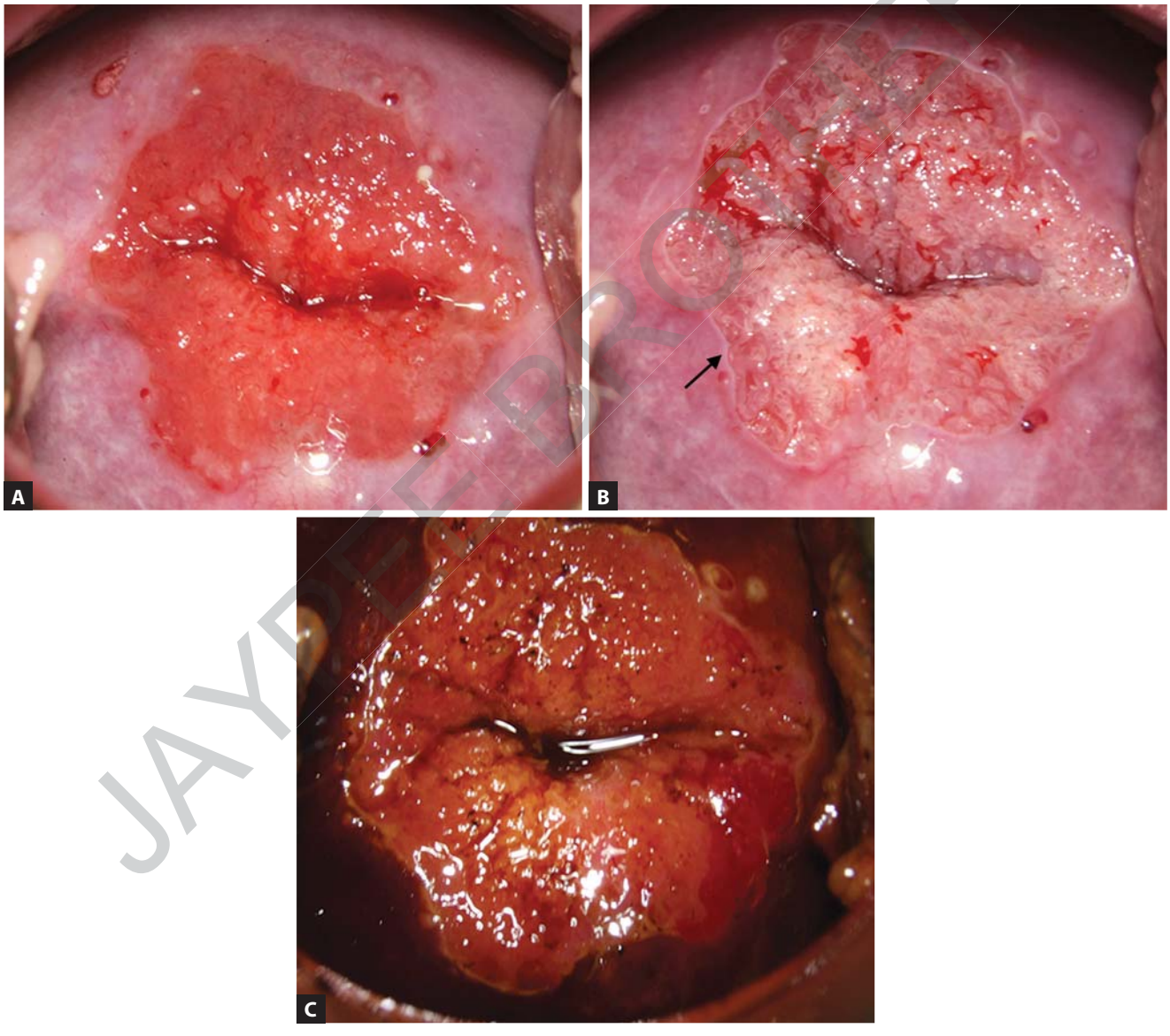

Figs. 5.1A to C: (A) Cervix with gray-pink squamous and red columnar epithelium. This photograph was taken after opening the speculum; there is no ectropion. 7,5x; (B) After acetic acid wash. Type 1 normal transformation zone. Note the new squamocolumnar junction (SCJ) (arrow). 7.5x. and (C) After Lugol's iodine wash. Mahogany brown squamous and largely unstained columnar epithelium and new SCJ. 7.5x.

JAYPEE BROTHERS

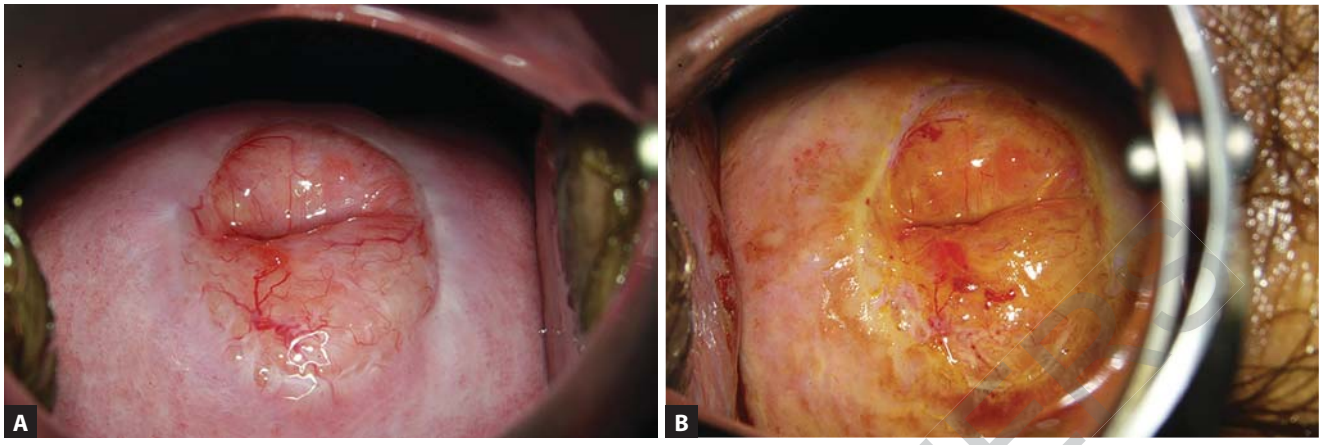

Figs. 5.2A and B: (A) Severe atrophy. Pale epithelium with prominent wide caliber vessels, some are tortuous. Type 3 TZ. 7.5x; and (B) After Lugol's iodine wash. Largely unstained epithelium. 7.5x.

Columnar Epithelium

It extends between the endometrium cranially and the metaplastic squamous epithelium caudally. It has a typical grape-like appearance after the application of acetic acid. Normally, it is present in the endocervix and may be present on the ectocervix (ectopy) or, on rare occasions, in the vagina **(Figs. 5.1A to C)**. It does not stain with Lugol's iodine as it does not contain glycogen.

Metaplastic Squamous Epithelium

The TZ extends between the original squamous epithelium and the columnar epithelium, within which varying degrees of maturity of the metaplastic epithelium can be identified **(Figs. 5.3 to 5.5)**. Immature metaplastic epithelium turns white after acetic acid application and is iodine negative; whereas mature metaplastic epithelium may turn slightly white after acetic acid application and be partially or completely stained brown with Lugol's iodine **(Figs. 5.3 and 5.4)**.

The area includes islands of columnar epithelium surrounded by metaplastic squamous epithelium, gland/cleft openings, and Nabothian cysts. The various stages of metaplasia have already been described previously in **Chapter 2**. It may contain fine regular patterns of mosaic vessels **(Fig. 5.4)** and fine punctations. In a small percentage of women, the TZ may extend caudally onto the vagina, usually in a tongue-shaped manner anteriorly and posteriorly.

Types of TZ: There are three types of TZ.[1]

1. A *type 1* TZ is completely ectocervical and fully visible and may be small or large **(Figs. 5.1A to C and 5.3A and B)**.
2. A *type 2* TZ has an endocervical component, is fully visible, and may have an ectocervical component that may be small or large **(Figs. 5.6A to D)**.
3. A *type 3* TZ has an endocervical component that is not fully visible and may have an ectocervical component that may be small or large **(Figs. 5.5A to C)**.

Colposcopic features suggestive of metaplastic change include a smooth surface with fine, uniform caliber vessels, mild acetowhite change, and negative or partial positivity with Lugol's iodine.

Deciduosis

This is a change seen during pregnancy, in which the stroma becomes edematous, softened, and hyperplastic. It sometimes manifests as polypoidal lesions at the external os, referred to as "decidual polyps." These polyps have no epithelial covering and are grayish or yellowish in color. In contrast, the conventional polyps are covered by smooth, pink metaplastic squamous epithelium or grape-like columnar epithelium.[3]

Abnormal Colposcopic Findings

Acetowhite Epithelium

Thin acetowhite epithelium: Areas of high nuclear activity appear white. The effect takes some time to be noted after the application of acetic acid and disappears rapidly. This is seen in columnar epithelium, low-grade squamous intraepithelial lesion (SIL), and in areas of immature metaplasia **(Figs. 5.3 and 5.4)**.

Dense acetowhite epithelium: A severe lesion is generally associated with a dense acetowhite change that appears

JAYPEE BROTHERS

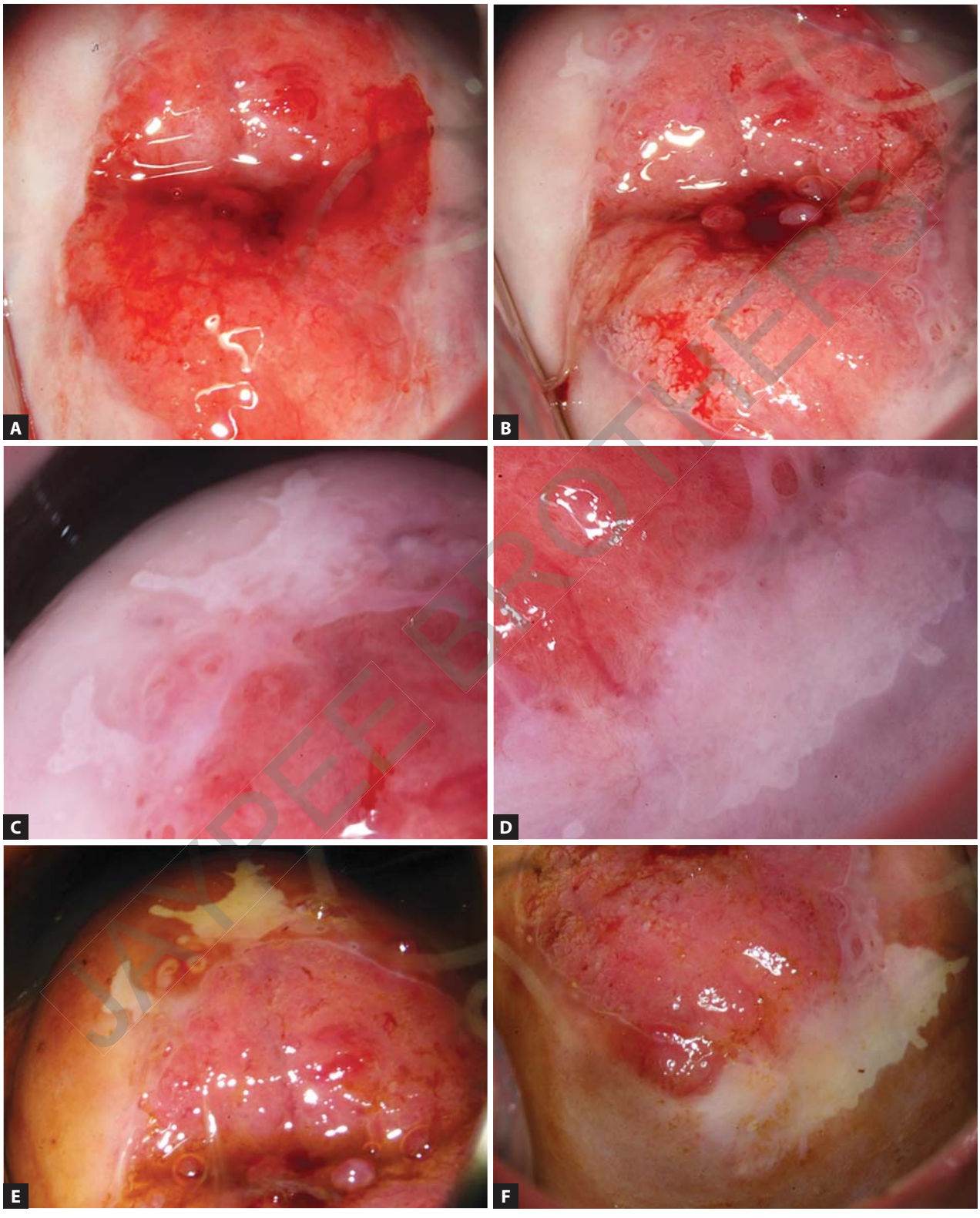

JAYPEE BROTHERS

Figs. 5.3A to F: (A) Cervix with two small endocervical polyps. 7.5x; (B) After acetic acid wash. Type 1 transformation zone (TZ) with three small endocervical polyps. 7.5x; (C) Thin acetowhite epithelium within TZ on the anterior lip. 15x; (D) Thin to dense acetowhite area within TZ on the posterior lip. 15x; (E) After Lugol's iodine wash. The acetowhite area was unstained at 10 o'clock, and was partially stained at 12 o'clock position. 15x; and (F) Unstained acetowhite area. Biopsy showed metaplastic epithelium. 15x.

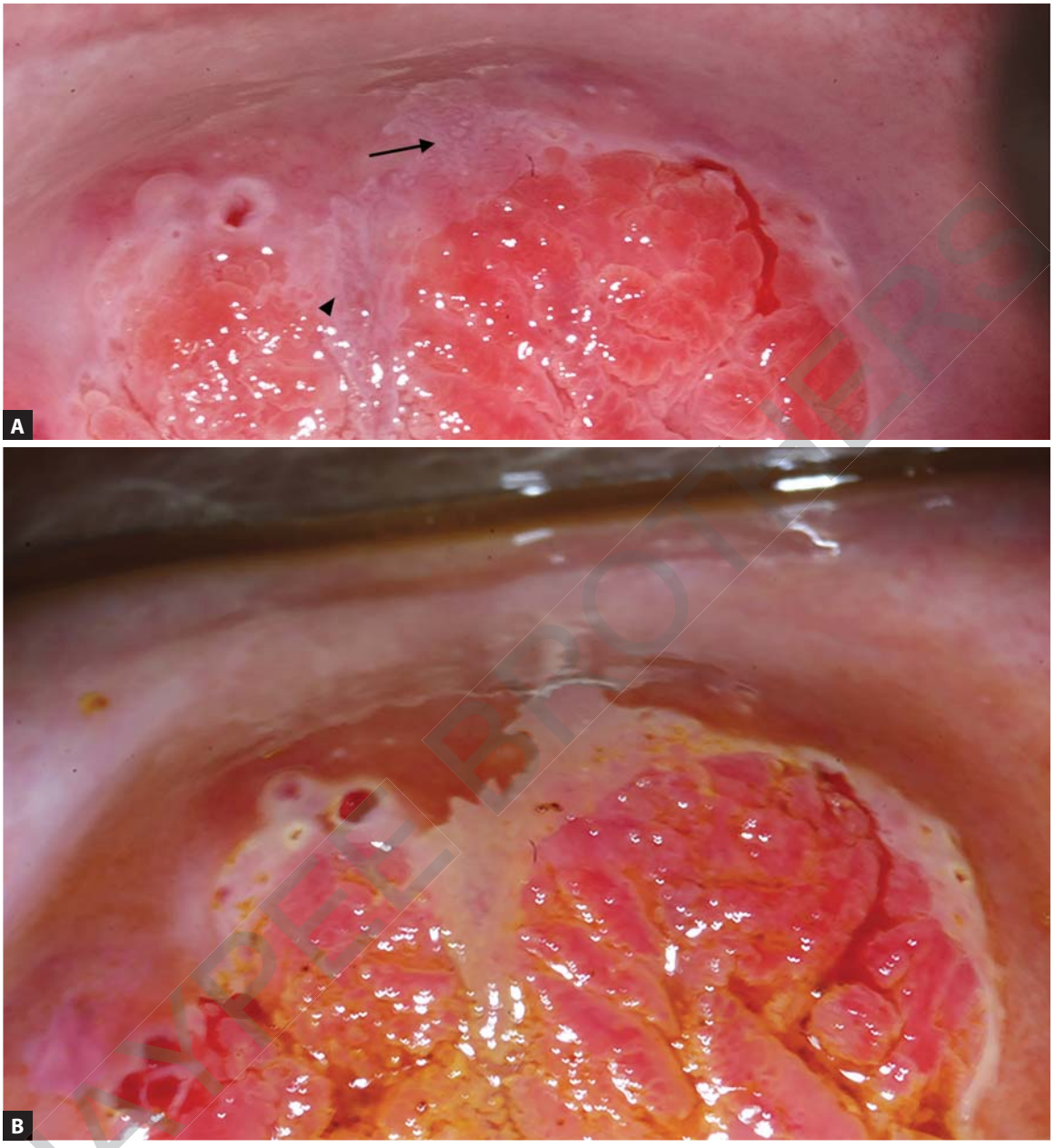

Figs. 5.4A and B: (A) Part of normal transformation zone with thin acetowhite epithelium on the anterior lip with fine mosaic (arrow) and a strand of metaplastic epithelium covering the columnar epithelium (arrowhead); and (B) After Lugol's iodine wash. The mosaic and strand of metaplastic epithelium show significant iodine negativity. Normal squamous epithelium stains mahogany brown and columnar epithelium is iodine negative.

JAYPEE BROTHERS

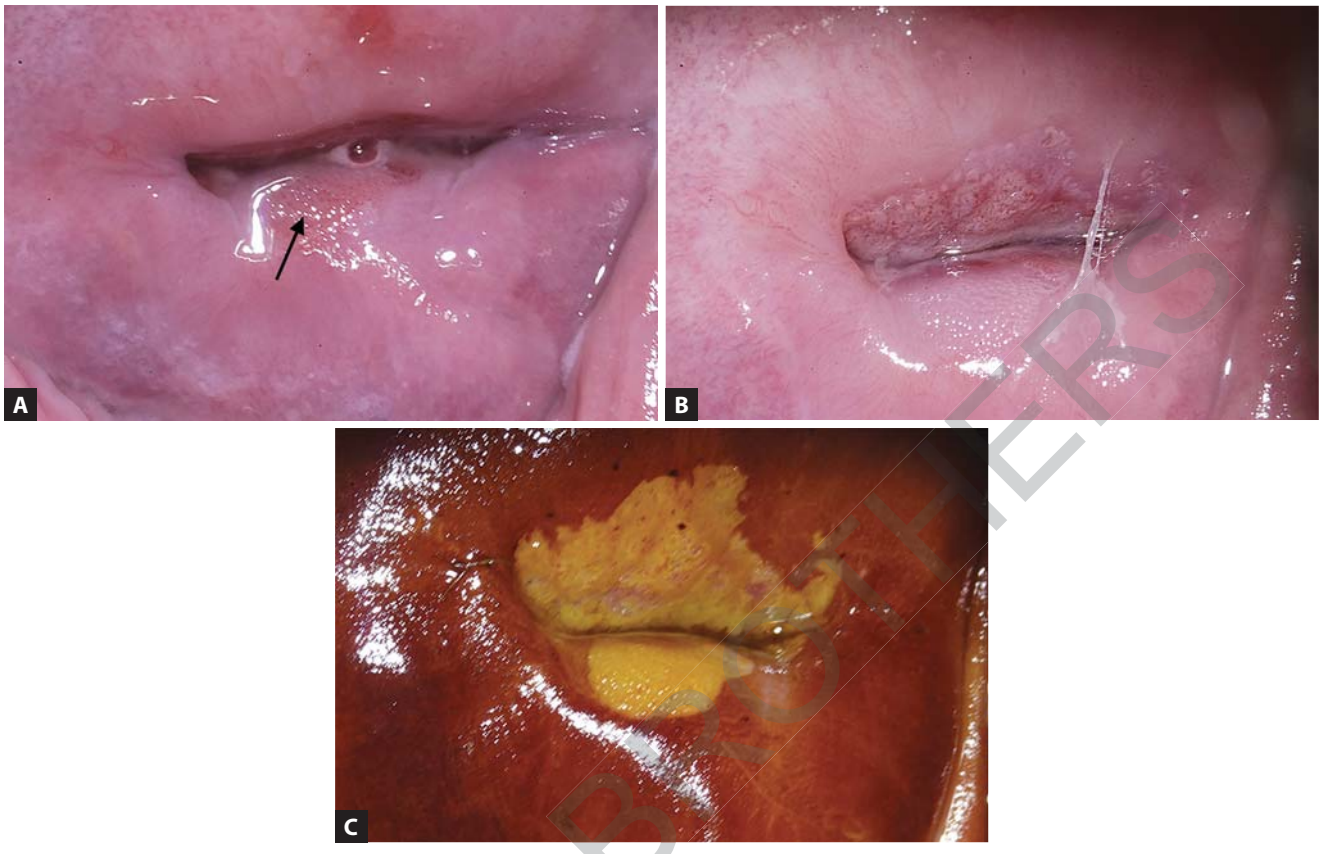

Figs. 5.5A to C: (A) After saline wash. Medium punctations seen on posterior lip (arrow). 15x; (B) Dense acetowhite area on the posterior lip and medium punctations seen on the anterior lip. Type 3 transformation zone; and (C) After Lugol's iodine wash. Loop electrosurgical excision procedure biopsy of the posterior lip showed metaplastic epithelium with koilocytes without atypia.

JAYPEE BROTHERS

fast and persists for a long time **(Figs. 5.7 to 5.9)**. Dense acetowhite change within columnar epithelium may indicate glandular disease.

Punctation

Fine punctation: This is a focal area with the capillaries appearing in a stippled pattern like dots. The finer the punctation, the more likely the lesion is of low grade or metaplasia **(Fig. 5.5B)** or inflammation.

Coarse punctation: The coarser the punctation, the more likely the lesion is of severe or major grade **(Fig. 5.9)**.

Mosaic

Fine mosaic: A focal colposcopic appearance in which the capillaries appear to surround abnormal areas appearing as tiles. The finer the mosaic, the more likely the lesion is of low grade or metaplasia **(Figs. 5.4A and B)**.

Coarse mosaic: The coarser, wider, and more irregular the mosaic, the more likely the lesion is of major grade **(Figs. 5.7 and 5.8)**.

Atypical Vessels

A focal area where the vessels are not such as punctations and mosaics but appear as horizontal, superficial vessels with irregular caliber and branching, often appearing, such as commas, hair pins, corkscrews, and spaghetti-like forms. These vessels usually are indicative of cancer **(Fig. 5.10)**.

Colposcopic Features Suspicious (Suggestive) of Invasion

- Irregular surface contour **(Figs. 5.8 and 5.9)**, growth **(Fig. 5.10)**, or ulcer (erosion).
- Dense acetowhite change **(Figs. 5.8 and 5.9)**.

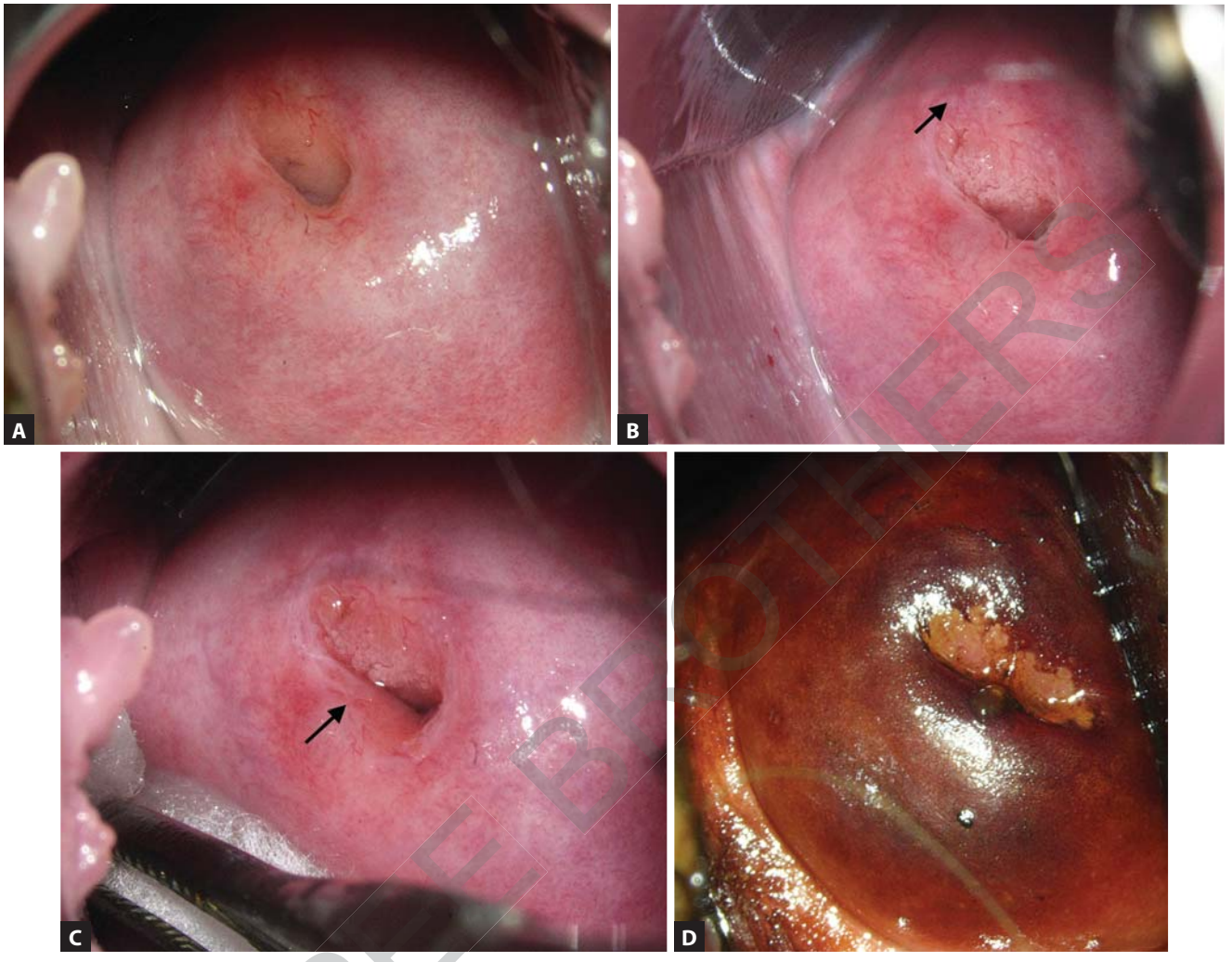

Figs. 5.6A to D: (A) After saline wash. Patulous external os. 7.5x; (B) After acetic acid wash. The new squamocolumnar junction (SCJ) is visible on the anterior lip (arrow) but not on the posterior lip. 7.5x; (C) The new squamocolumnar junction (SCJ) is visible on the posterior lip of cervical canal (arrow) after depressing the posterior lip with a sponge on a holder. Type 2 normal transformation zone. 7.5x; and (D) After Lugol's iodine wash. 7.5x.

JAYPEE BROTHERS

- Wide, irregular, and coarse punctation and mosaic **(Figs. 5.8 and 5.9)**.
- Atypical vessels **(Fig. 5.10)**.

Nonspecific Abnormal Colposcopic Findings

Leukoplakia (Previously Termed Keratosis)

These are white areas visible with the naked eye even before the application of acetic acid. They represent areas of hyperkeratosis, and preclude proper visualization of the underlying TZ. The leukoplakia in subclinical papillomavirus infection (SPI) is usually fine and smooth **(Fig. 5.11)**, in contrast to the coarse leukoplakia seen in high-grade squamous intraepithelial lesions (HSILs) and cancer **(Figs. 5.8 to 5.10)**.

Erosion

It is an area of denuded epithelium that can be caused by severe inflammation, severe atrophy (atrophy is now considered under "Normal colposcopic findings"), and trauma due to the introduction of the speculum (categorized under the "Miscellaneous colposcopic findings"), and ischemic necrosis [**(Fig. 5.12)**, decubitus ulcer). Sometimes it may be an indication that the epithelium is abnormal like in HSIL or early cancer.

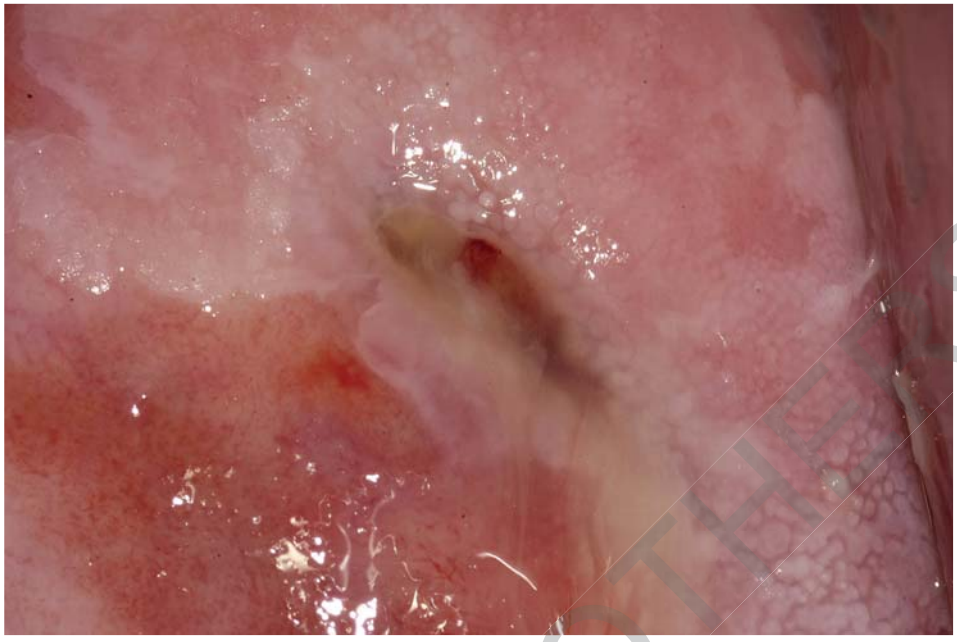

Fig. 5.7: Coarse mosaic and dense acetowhite epithelium with sharp borders. High-grade squamous intraepithelial lesion (HSIL). 15x.

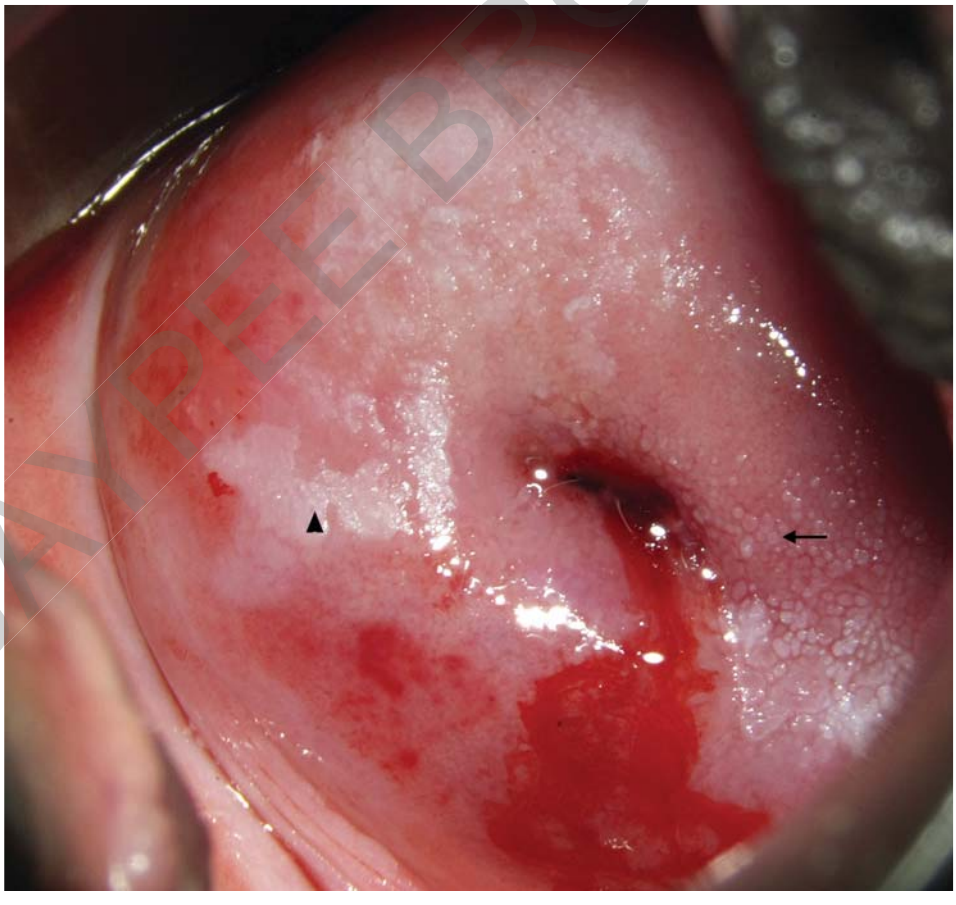

Fig. 5.8: Coarse mosaic (arrow), coarse leukoplakia (arrowhead), and dense acetowhite epithelium with an irregular surface covering >75% of the cervix. Suspect cancer. 7.5x.

JAYPEE BROTHERS

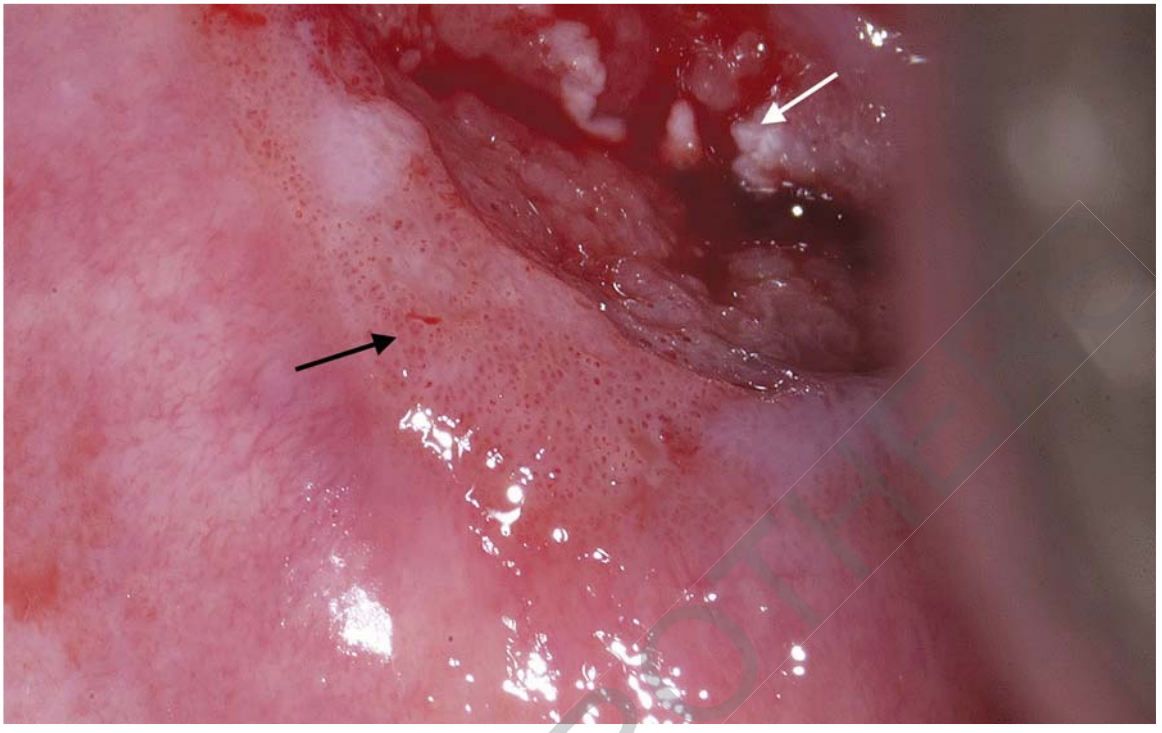

Fig. 5.9: Cancer cervix. Coarse punctations within dense acetowhite epithelium (black arrow), friable irregular epithelium within the canal, and coarse leukoplakia (white arrow). 15x.

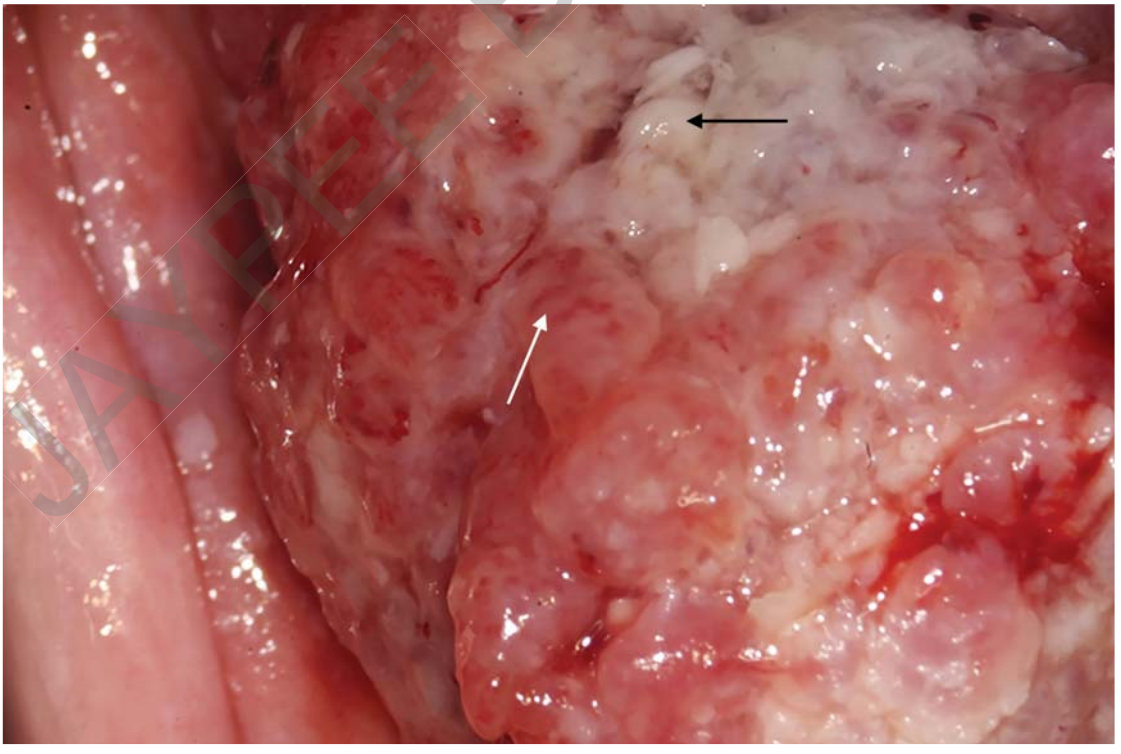

Fig. 5.10: Growth on the cervix with coarse leukoplakia (black arrow)and wide caliber atypical vessels (white arrow). The biopsy showed cancer. 15x.

JAYPEE BROTHERS

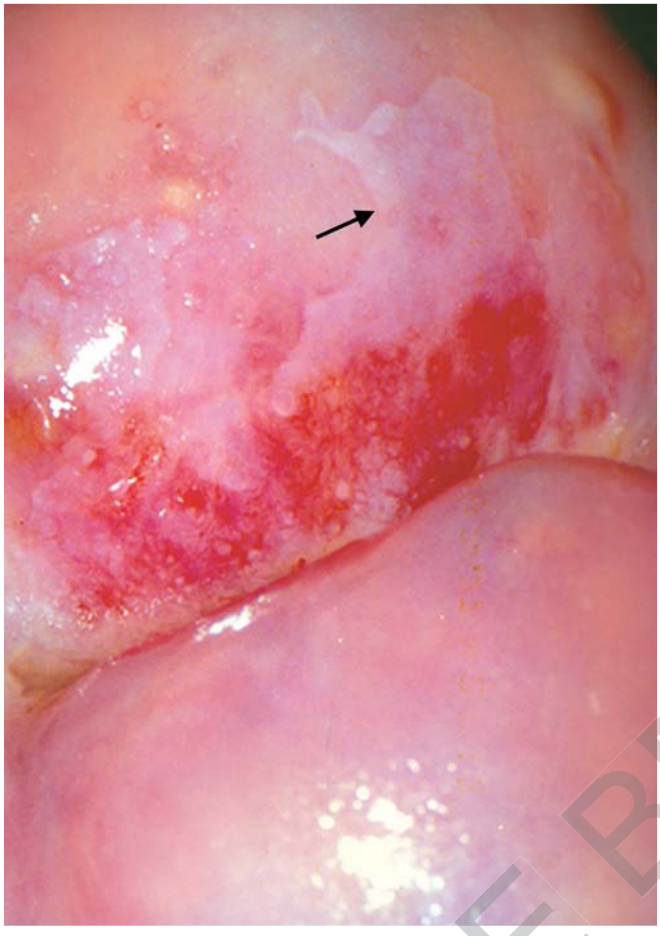

Fig. 5.11: Fine leukoplakia (arrow).



Fig. 5.12: Erosion (arrow) in a case of prolapse uterus.

Erosion due to severe atrophy is depicted in **Fig. 8.13** in Chapter 8.

Lugol's Staining (Schiller's Test): Stained or Nonstained

Tissue rich in glycogen, like mature squamous epithelium, stains a deep mahogany brown with Lugol's iodine **(Fig. 5.1C)**.

Iodine negativity: These areas may represent columnar epithelium **(Fig. 5.1C)**, immature metaplasia **(Figs. 5.3E and F) (Fig. 5.4B)**, atrophy **(Fig. 5.2B)**, inflammation, SPI, cervical intraepithelial neoplasia (CIN)/SIL or cancer.

Iodine partial positivity: A speckled appearance within an area of slight acetowhite change may be due to immature metaplasia **(Fig. 5.3E)**, regenerating epithelium, SPI, or low-grade CIN/SIL. A yellowish color within an area of dense acetowhiteness is highly suggestive of high-grade CIN/SIL (depicted in **Fig. 2.10B** in Chapter 2), or cancer.

Miscellaneous Colposcopic Findings

Inflammation

In acute inflammation, the vascularity is increased, and the cervix appears red. There may be punctations and an increased number of vessels, which can be of large but regular caliber and branching regularly **(Fig. 5.13A)**. The punctations may appear intermediate between fine and coarse. As the inflammation usually involves the vagina as well, the punctations usually extend onto the vagina also. Sometimes the punctations coalesce and form deep red areas. There can be erosions and discharge at the external os. In severe cases, there may be small depressed yellow necrotic areas surrounded by a red halo due to microabscess formation surrounded by hyperemic stroma.[4] The application of acetic acid is painful and does not cause any change. After the application of Lugol's iodine, there may be a granular appearance; in severe cases, the cervix stains a diffuse orange–red due to lack of glycogen and increased vascularity **(Fig. 5.13B)**.

JAYPEE BROTHERS

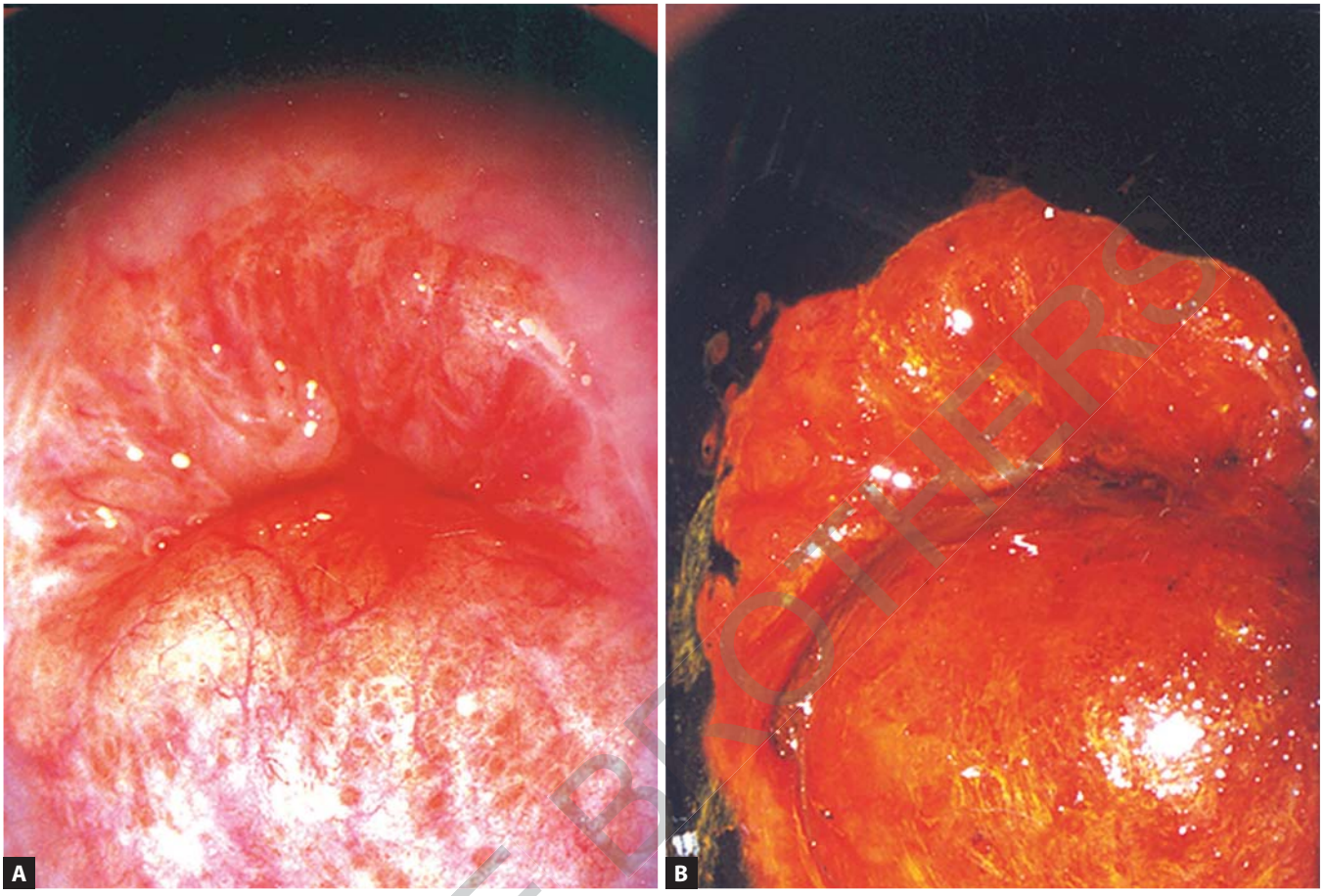

Figs. 5.13A and B: (A) Inflammation with prominent vessels and a yellow-red color; and (B) Inflamed area turns orange color after iodine staining.

JAYPEE BROTHERS

In chronic inflammation, white punctations are seen against a pink background. This is follicular cervicitis and is due to the formation of lymphoid follicles in the stroma.[4]

Polyps

These can be adenomatous and covered with columnar and/or metaplastic squamous epithelium **(Figs. 5.14A and B)**, can be leiomyomatous, decidual (categorized under "Normal colposcopic findings") or cancerous (categorized under "Abnormal colposcopic findings").

Condyloma

These may occur within or outside the TZ and indicate human papillomavirus (HPV) infection. They may appear as acetowhite epithelium: Thin, as in SPI, or as dense acetowhite change with irregular surface contour. Atypical vessels—punctate, hairpin-like, and fine mosaic—may be present in lesions within and outside the TZ. The surface can have (1) micropapillary projections (asperities) **(Fig. 5.15)**, or (2) microconvolutions that are broader than the former, have mosaic patterns of vessels, and resemble brain-like convolutions.[5]

Condylomas with irregular surface contour, dense aceto-whiteness, iodine negativity, and with vessels resembling atypical vessels can be easily misdiagnosed as invasive cancer. Condylomas, however, have regular finger-like processes, with a capillary loop within each of these processes.[5] Details of colposcopic appearances of HPV infection are described in Chapter 16.

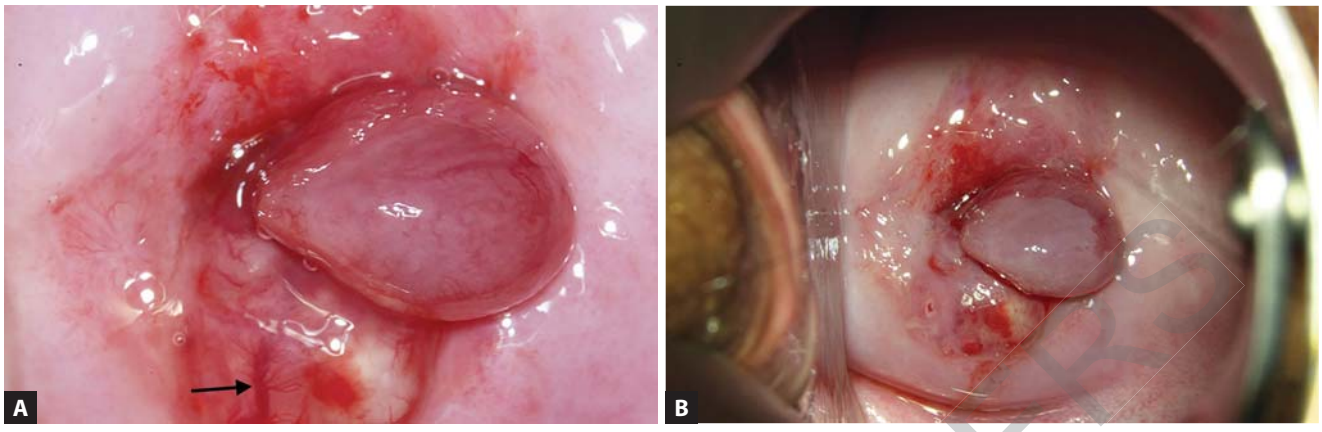

Figs. 5.14A and B: (A) Inadequate colposcopy due to endocervical polyp. Prominent vessels (arrow) and two Nabothian cysts were seen. 15x; and (B) After acetic acid wash. Acetowhite metaplastic epithelium partly covering polyp. Excision biopsy showed an adenomatous cervical polyp. 15x.

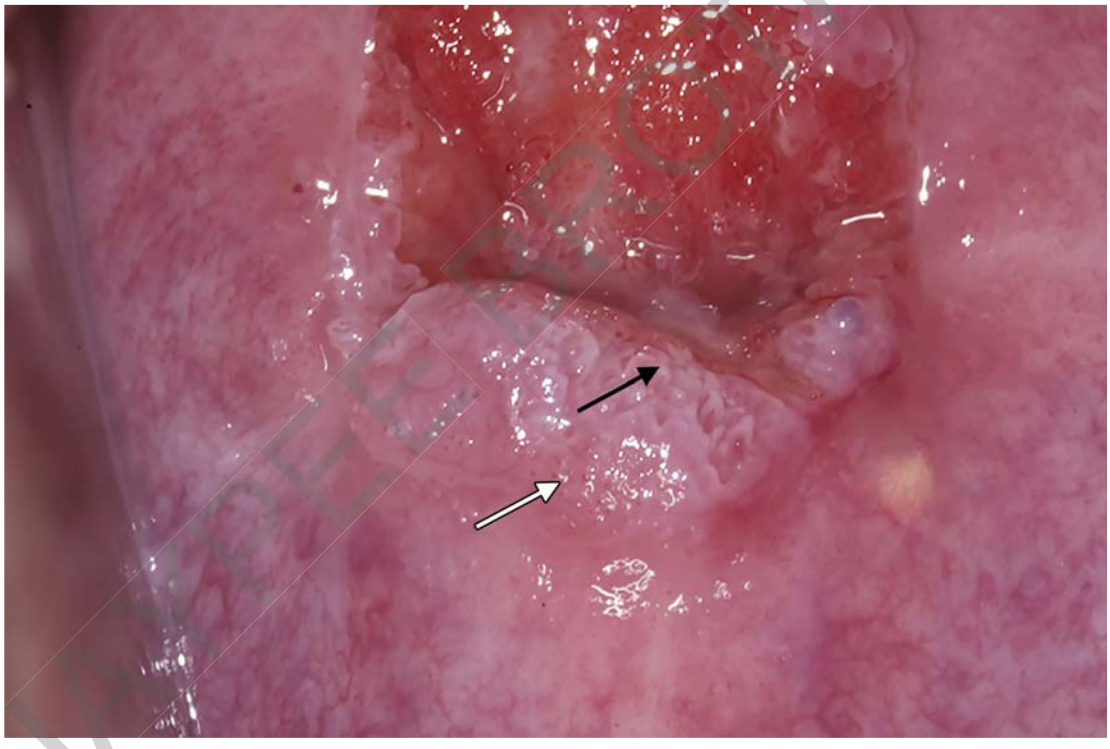

Fig. 5.15: Condyloma cervix showing asperities (black arrow) and coarse punctations (white arrow). 15x.

JAYPEE BROTHERS

REFERENCES

1. Bornstein J, Bentley J, Bösze P, Girardi F, Haefner H, Menton M, et al. The 2011 colposcopic terminology of the International Federation for Cervical Pathology and Colposcopy. Obstet Gynecol. 2012;120(1):166-72.
2. Tatti S, Bornstein J, Prendiville W. Colposcopy: a global perspective: introduction of the new IFCPC colposcopy terminology. Obstet Gynecol Clin North Am. 2013;40(2):235-50.
3. Burghardt E, Pickel H, Girardi F. Colposcopy, Cervical Pathology: Textbook and Atlas, 3rd edition. New York (NY): Thieme; 1998. pp. 203-17.
4. Das SK, Nigam S, Batra A, Chandra M. An Atlas of Colposcopy, Cytology and Histopathology of Lower Female Genital Tract (Text with Colour Atlas). New Delhi: CBS Publishers; 1995. pp. 45-68.
5. Coppleson M, Pixley EC. Colposcopy of cervix. In: Coppleson M (Ed). Gynecologic Oncology: Fundamental Principles and Clinical Practice, 2nd edition. New York: Churchill Livingstone; 1992. pp. 297-324.

for detailed information on obstetrics & gynecology books, visit our website www.ejaypee.com, for detailed information on obstetrics & gynecology books, visit our website www.ej

Principles & Practice of COLPOSCOPY

The fourth edition of this book will update the readers with the current World Health Organization recommendations, and the advances in technology for screening and diagnosis of cervical intraepithelial neoplasia and early cancer. The author has shared her experience and insights gained over the years of practicing colposcopy to help both the experienced and the trainee colposcopists understand the minutiae and nuances of colposcopy. Chapters 3 and 22 are completely rewritten, and chapter 17 is extensively edited. The book has new colpophotographs and several edits in other chapters. Two new chapters, 24 and 25, have been added. The gynecologist has a central role in the screening services. Chapter 3 is an update on the screening tests for cervical cancer. Chapter 17 deals with the updated management of women with abnormal screening test results. Chapter 22 deals with the utility of immunostaining of cervical smears and biopsies, high-risk human papillomavirus (HPV) mRNA tests, and the use of artificial intelligence in screening. Chapters 24 and 25 deal with quality assurance in the colposcopy services and training, certification, and accreditation in colposcopy, respectively. The importance of regular audits and meetings of the multidisciplinary team has been emphasized.

This book will be extremely useful for both the experienced colposcopists and the colposcopists in training for providing their patients with optimal services with the judicious use of recommended guidelines and available technology.

B. Shakuntala Baliga MD FICOG is an alumna of the All India Institute of Medical Sciences (AIIMS), New Delhi, India. After completing her undergraduate and postgraduate studies and registrarship (Senior Residency) at AIIMS, she joined Lady Hardinge Medical College (LHMC), New Delhi, as faculty. She started and lead the Colposcopy Services at LHMC for more than a decade. She was a Professor for almost 11 years and took voluntary retirement from Central Health Services of the Government of India after almost two decades of service and relocated to Bengaluru, Karnataka. She joined Mazumdar Shaw Medical Center of Narayana Health in Bengaluru as Professor and Senior Consultant and Head of Academics in the Department of Obstetrics and Gynecology. She was Founder and Chief of the Colposcopy Services here for more than 13 years till she retired in January 2023. She was involved in clinical practice, teaching, and research. Her forte is colposcopy and diagnosis and management of precancers and early gynecological cancers. She has many publications, including three books on colposcopy that are internationally acclaimed. She was awarded the distinguished NBE Teacher Award from ANBAI Karnataka in 2019, and the Zee Swastha Bharat Samaan in 2011.

Shelving Recommendations
OBSTETRICS & GYNECOLOGY

ISBN 978-93-6616-639-1

9 789366 166391

Buy from ejaypee

JAYPEE BROTHERS