radiology books, visit our website www.jaypeebrothers.com, for detailed information on radiology books, visit our website www.jaypeebrothers.com, for detailed information on radiology books



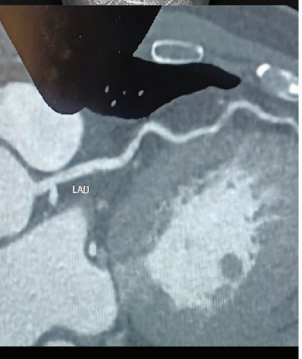







Meenakshi Radiology Cases

In Association with TNPY–IRIA
Part-1

Editors
Shanmuga Jayanthan S
Chinnadurai Abdullah
Flora Nelson
G Rupesh

JAYPEE

Contents

Chapter	Title	Page No.
1	Marchiafava–Bignami Disease	1
2	Herlyn–Werner–Wunderlich Syndrome	3
3	Glomangioma of Knee	5
4	Extragastrointestinal Stromal Tumor	7
5	Hypertrophic Pachymeningitis	9
6	Pyogenic Ventriculitis	11
7	Sinus Tarsi Syndrome	13
8	PIPA with Lung Hypoplasia	15
9	Chiari II Malformation	17
10	Colloid Cyst with Obstructive Hydrocephalus	19
11	WOPN with Portal Vein Thrombosis	21
12	Medulloblastoma	23
13	Spinal Cord Astrocytoma	25
14	Coronary Artery—Pulmonary Artery Fistula	27
15	Sella Metastasis	29
16	Infected Right Para Tracheal Cyst	31
17	Testicular Germ Cell Tumors	33
18	Renal Lymphangiectasia with Ascites	35
19	Common Carotid Artery Occlusion with Retrograde Collateral ICA Flow	37
20	Central Neurocytoma	39
21	Azygos ACA with Saccular Aneurysm	41
22	Submucosal Fibroids	43
23	Wunderlich Syndrome	45
24	Leriche Syndrome	47
25	Isolated Renal Mucormycosis	49

Chapter	Title	Page No.
26	Bilateral Endometriotic Cysts with Possible Rupture on Right Side	51
27	Giant Cell Tumor with Hemorrhage or Secondary Aneurysmal Bone Cyst Component	53
28	Intraventricular Tuberculoma with Paradoxical Reaction	55
29	Median Prostatic Cyst—Isolated Müllerian Duct Cyst	57
30	Meningioma En Plaque	59
31	The Facet Joint Syndrome	61
32	Hypervascular Liver Metastases with Possible Pancreatic or Renal Primary	63
33	Pott's Puffy Tumor	65
34	Testicular Neoplasm—Seminoma	67
35	Focal Nodular Hyperplasia	69
36	Guillain–Barré Syndrome	71
37	Pituitary Macroadenoma with Cavernous Sinus Invasion	73
38	Primary Extradural (Intraosseous) Meningioma	75
39	Adnexal Torsion—Paraovarian Cyst	77
40	Dysembryoplastic Neuroepithelial Tumor	79
41	Idiopathic Thyroid Cartilage Purulent Chondritis	81
42	Rectal Malignancy: Role of MRI	83
43	Ortner's Syndrome (Cardiovocal Syndrome)	85
44	Mycotic Aneurysm	87
45	Giant Pseudomeningocele	89
46	Vestibular Schwannoma	91
47	SMA and Nutcracker Syndromes	93
48	Psammomacarcinoma of Ovary	95
49	Lipoma Arborescens	97
50	Pigmented Villonodular Synovitis	99
51	Disseminated Tuberculosis	101
52	Otogenic Brain Abscesses	103
53	TB Meningoencephalitis with LETM	105

Chapter	Title	Page No.
54	Cerebral Abscess in Tetralogy of Fallot	107
55	Scimitar Syndrome	109
56	Minimal Aortic Injury	111
57	Aggressive Giant Cell Tumor	113
58	Giant Superior Vena Cava Aneurysm	115
59	Cephalic Arch Stenosis: Post AVF	117
60	Intraconal Orbital Dermoid Cyst	119
61	Leptomeningeal Carcinomatosis—Carcinoma Breast	121
62	Cervical Rib with Subclavian Artery Pseudoaneurysm—Thoracic Outlet Obstruction Syndrome with Distal Emboli	123
63	Cerebellar Hemangioblastoma	125
64	Post Varicella—Pediatric Stroke	127
65	Solitary Fibrous Tumor of Pleura	129
66	Scalp Arteriovenous Malformations	131
67	Adhesive Capsulitis	133
68	Acute Traumatic Aortic Injury	135
69	As with Chalk-Stick Fracture	137
70	Diversion Colitis	139
71	Acute Mesenteric Ischemia	141
72	Budd–Chiari Syndrome due to RCC	143
73	Heterotopic Pregnancy with Ruptured Ectopic	145
74	Diabetic Foot with Calcaneum Osteomyelitis	147
75	Midgut Malrotation with Bowel Ischemia	149
76	Unhappy Triad of O'Donoghue	151
77	Seminal Vesiculitis	153
78	TB Spondylodiscitis with Bilateral Psoas Abscess: Pigtail Drainage of Psoas Abscess	155
79	Mid Aortic Syndrome	157
80	C-section Scar Dehiscence	159

Chapter	Title	Page No.
81	Hepatic Arterioportal Shunt with Giant IMV in CLD	161
82	Peristomal Varices	163
83	Bilateral Atretic Transverse Sinuses with Persistent Occipital Sinus and Emissary Condylar Vein	165
84	Pediatric Abdominal Mass: Inflammatory Myofibroblastic Tumor	167
85	Anomalous Origin of Left Vertebral Artery Supplying the Right Lower Lobe Lung Sequestration	169
86	Giant Lipoma of Finger	171
87	Cardiac Calcified Amorphous Tumor	173
88	Inflammatory Manubriosternal Arthritis	175
89	Necrotizing Retroperitoneal Fasciitis	177
90	Septic Arthritis Shoulder	179
91	VALF: A Rare Cause of Cervical Radiculopathy	181
92	Ectopic Duodenal Varices	183
93	INH Induced Cerebellar Toxicity	185
94	Myocardial Bridging: Left Anterior Descending	187
95	Prolapsed Submucosal Leiomyoma—Cellular Variant	189
96	Malignant Colonic Stricture	191
97	CT Cisternography in CSF Rhinorrhea	193
98	Takayasu Arteritis	195
99	Urinary Bladder Rupture	197
100	Calcifying Epithelioma of Malherbe	199
	Index	201

8 PIPA with Lung Hypoplasia

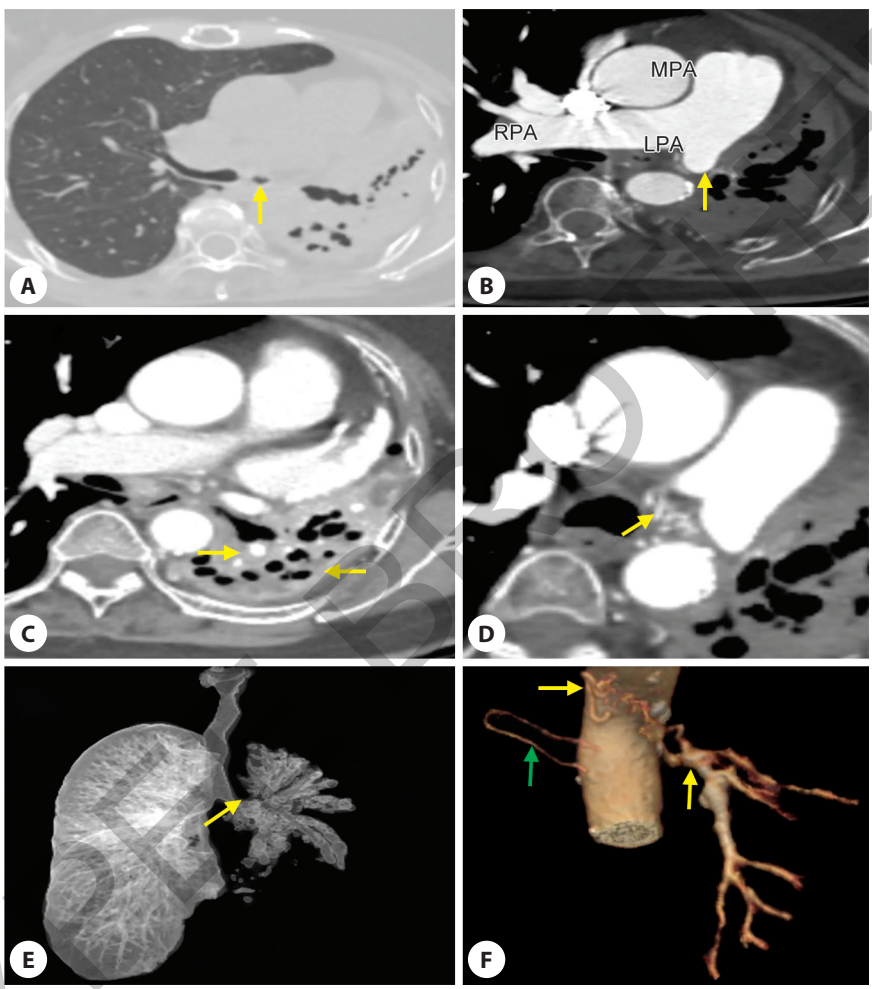

CLINICAL BACKGROUND

A 60-year-old female patient c/o hemoptysis.

IMAGING FINDINGS

Hypoplastic left main bronchus and left lung with bronchiectasis. Absent left pulmonary artery, except for 1 cm from its origin. Bronchial artery hypertrophy on left side supplying the lung (yellow arrows) compared to normal appearance of right bronchial artery **(Figs. 1A to F)**.

JAYPEE BROTHERS

DISCUSSION

Unilateral pulmonary hypoplasia has a prevalence of 1–2 per 12,000 births and commonly seen on left side (70%). Primary lung hypoplasia remains silent, due to compensatory hypertrophy of contralateral lung and also due to the absence of associated embryological abnormalities.[1]

Proximal interruption of pulmonary artery (PIPA) is a rare congenital anomaly with a prevalence of 1 in 200,000.[2] It can be an isolated abnormality or can occur in association with many congenital heart diseases, lung hypoplasia etc.[2]

Interruption is the preferred terminology over absence as in this condition, the intrapulmonary vascular network is intact.[3] A well-developed pulmonary arterial tree is present in the lung, with a proximal blind ending at hilum via collaterals.[4]

CECT of thorax is the imaging modality of choice to diagnose above condition. Lung hypoplasia is characterized by the small hemi thorax, ipsilateral mediastinal shift and herniation of hypertrophied contralateral lung.[5] Pulmonary vessel termination may occur at or within 1cm, of the origin in PIPA with distal collaterals from systemic vessels like bronchial, internal mammary, innominate and subclavian vessels.[5]

PIPA can present with life-threatening hemoptysis and imaging plays an important role to delineate the vascular anatomy before intervention. Associated congenital cardiac anomalies must be excluded.

REFERENCES

1. Kant S. Unilateral pulmonary hypoplasia—a case report. Lung India. 2007;24(2):69-71.
2. Pool PE, Vogel JH, Blount SG. Congenital unilateral absence of the pulmonary artery: Importance of flow in pulmonary hypertension. Am J Card. 1962;10:706-32.
3. Castaner E, Gallardo X, Rimola J, et al. Congenital and Acquired Pulmonary Artery Anomalies in the Adult: Radiologic Overview. Radiographics. 2006;26:349-71.
4. Ten Harkel AD, Blom NA, Ottenkamp J. Isolated Unilateral Absence of a Pulmonary Artery: A Case Report and Review of the Literature. Chest. 2002;122:1471-77.
5. Anand SH, Jasper A, Mani SE, et al. Proximal Interruption of the Pulmonary Artery: A Case Series. J Clin Diagn Res. 2015;9(12):TD04–TD06.

JAYPEE BROTHERS

for detailed information on radiology books, visit our website www.jaypeebrothers.com, for detailed information on radiology books, visit our website www.jaypeebrothers.com, for detailed info

Meenakshi Radiology Cases

In Association with TNPY–IRIA

Part-1

This textbook of Radiology cases features a curated selection of real-world cases, combining high-quality radiological images with detailed pathological insights and clinical context. Each case is meticulously presented, emphasizing key diagnostic features. Designed for both trainees and experienced professionals, this book bridges the gap between radiology and pathology, fostering a multidisciplinary approach to patient care and advancing diagnostic accuracy.



Shanmuga Jayanthan S, is an MBBS graduate of Mahatma Gandhi Medical College, Puducherry (Pondicherry), and has completed DNB Radiology (All India DNB-CET Rank-31) from Meenakshi Mission Hospital and Research Center, Madurai, India, and is serving presently as a Senior Consultant Radiologist and Head of the Department, Meenakshi hospital, Thanjavur, Tamil Nadu—the first and only DNB accredited hospital for Radiology in Delta region. With a passion for teaching and scientific writing, he plays an instrumental role in resident education and has contributed extensively to many publications in indexed journals.



Chinnadurai Abdullah is a Postgraduate from the Department of Radiology of Madurai Medical College. He has been practicing "Radiology" for more than 30 years in Ramanathapuram district, Tamil Nadu. He introduced nonvascular interventional radiology to Ramanathapuram district. He has organized several CME programs in the field of Radiology.



Flora Nelson is an MBBS graduate of Thanjavur Government Medical College, completed MD Radiology from Barnard Institute of Radiology, Madras Medical College, Chennai. Presently, she is the Head of the Department of Radiology in Government Thoothukudi Medical College in Thoothukudi, Tamil Nadu. Her commitment is to strive hard to elevate the level of learning for Radiology Residents through the academic activities of Indian Radiological and Imaging Association.



G Rupesh, an MD Radiology graduate from Bangalore Medical College and Research Institute (Bengaluru), brings his expertise to Meenakshi Hospital as a Consultant Radiologist. His commitment to the advancement of "Radiology" is evident in his numerous publications in respected medical journals.

Printed in India

Available at all medical bookstores or buy online at www.ejaypee.com

JAYPEE BROTHERS
Medical Publishers (P) Ltd.
EMCA House, 23/23-B, Ansari Road,
Daryaganj, New Delhi - 110 002, INDIA
www.jaypeebrothers.com

Join us on facebook.com/JaypeeMedicalPublishers
Follow us on instagram.com/JaypeeMedicalPublishers

Shelving Recommendation
RADIOLOGY

ISBN 978-93-6616-650-6