y books, visit our website www.jaypeebrothers.com, for detailed information on radiology books, visit our website www.jaypeebrothers.com, for detailed information on radiology books

AIIMS-MAMC-PGI IMAGING SERIES

DIAGNOSTIC RADIOLOGY

Chest and Cardiovascular Imaging

Editors
Gaurav Shanker Pradhan
Raju Sharma
Paramjeet Singh

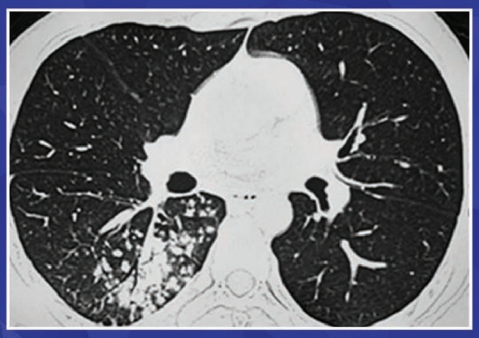



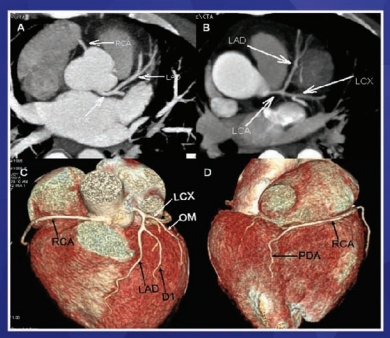

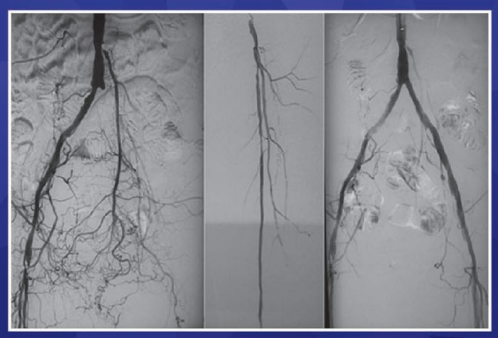

5th Edition

Associate Editors
Alpana Manchanda
Jyoti Kumar
Ashu Seith Bhalla
Priya Jagia
Mandeep Garg
Manphool Singhal

JAYPEE

Contents

1. The Chest Radiograph: Techniques, Anatomy and Interpretation **1**

Gaurav Shanker Pradhan, Radhika Batra, Rashmi Dixit

• Chest Radiography: Techniques *1*; • Radiographic Projections *3*; • Normal Anatomy on the Chest Radiograph *6*; • Evaluation of the Chest Radiograph *10*

2. The Essentials of Thoracic Ultrasound **28**

Madhurima Sharma, Mahesh Prakash, Anindita Sinha, Ajay Gulati

• Physics of Lung Ultrasonography *28*; • Ultrasound Technique *29*; • Normal Anatomy *31*; • Thoracic Ultrasound in Specific Disease Entities *31*

3. Cross-sectional Imaging of Chest: Techniques and Anatomy **40**

Rashmi Dixit, Anjali Prakash, Alpana Manchanda

Multidetector Computed Tomography of Thorax 40

• Computed Tomography Technology *40*; • Computed Tomography Acquisition and Reconstruction Protocols *41*; • High-resolution Computed Tomography *41*; • Acquisition Protocol and Contrast Opacification for Computed Tomography Pulmonary Angiography *42*; • Evaluation of the Aorta and Coronary Arteries *44*; • Evaluation of Pulmonary Veins *44*; • Extended Chest Pain Protocol or Triple Rule-out Computed Tomography *44*; • Postprocessing Techniques *44*; • Dose Considerations and Dose Reduction Techniques in Thoracic Computed Tomography *47*;

Magnetic Resonance Imaging 49

• Technical Considerations *49*; • Protocol and Sequences *50*; • Magnetic Resonance Pulmonary Angiography *50*; • Magnetic Resonance Perfusion Imaging *50*; • Other Advanced/Newer Imaging Techniques *50*; • Clinical Applications of Magnetic Resonance of Thorax *52*;

Normal Anatomy 54

• Mediastinum *54*; • Thymus *58*; • Lymph Nodes *58*; • Mediastinal Divisions on Cross-sectional Imaging *58*; • Tracheobronchial Tree *58*; • Lung Segments, Fissures, and Pleura *63*

4. Patterns of Lung Diseases on Computed Tomography **67**

Alpana Manchanda, Satyam, Gaurav Shanker Pradhan

• High-resolution Computed Tomography Patterns of Lung Disease *67*; • Decreased Lung Opacity without Discernible Wall *87*; • High-resolution Computed Tomography Findings Manifesting as Inhomogeneous Lung Opacity *89*

5. Imaging of Pulmonary Tuberculosis **93**

Mandeep Garg, Anmol Bhatia, Naveen Kalra

• Role of Imaging in Pulmonary Tuberculosis *93*; • Radiological Patterns of Pulmonary Tuberculosis *93*

6. Nontubercular Pulmonary Infections **101**

Anju Garg, Swati Gupta, Jyoti Kumar, Satyam

• Imaging Modalities *101*; • Radiographic Pattern *102*; • Etiopathogenesis of Pulmonary Infections *105*; • Specific Pneumonia *108*; • Fungal Infections *120*; • Parasitic Infections *124*; • Complications of Pneumonia *126*; • Delayed Resolution of Pneumonia *128*; • Diagnostic Algorithm in Patients Suspected of Pneumonia *129*

7. Pulmonary Manifestations in Immunocompromised Host **133**

Mandeep Kang, Pankaj Gupta, Mandeep Garg

• Human Immunodeficiency Virus/Acquired Immunodeficiency Syndrome *133*; • Systematic Approach to Imaging Diagnosis *134*; • Imaging Methods *134*; • Radiological Pattern Approach to Diagnosis *134*; • Nonhuman Immunodeficiency Virus Immunocompromised Hosts *136*; • Bacterial Infections *137*; • *Pneumocystis jirovecii* Pneumonia *138*; • Mycobacterial Infections *139*; • Viral Infections *140*; • Fungal Infections *141*; • Noninfectious Manifestations of Acquired Immunodeficiency Syndrome *142*; • Noninfectious Manifestations in Hematopoietic Stem Cell Transplantation *143*; • Pre-engraftment Period *143*; • Early Post-transplant Period *144*; • Late Pulmonary Complications *144*

8. Pattern Approach to Interstitial Lung Disease and Imaging of Idiopathic Interstitial Pneumonias **148**

Uma Debi, Mandeep Garg, Ajay Gulati, Manphool Singhal

• Imaging *148*; • Anatomy of the Secondary Pulmonary Lobule (Miller's) *148*; • Systematic Approach To Diagnosis of Pulmonary Fibrosis at Computed Tomography *152*; • Role of Multidisciplinary Discussion In Patient with Interstitial Lung Disease *152*; • Idiopathic Interstitial Pneumonias *153*; • Chronic Fibrosing Idiopathic Interstitial Pneumonias *153*; • Smoking-related Interstitial Pneumonias *155*; • Acute and Subacute Interstitial Pneumonias *156*; • Rare Interstitial Pneumonias *157*

9. Imaging of Interstitial Lung Disease of Known Etiology **160**

Surabhi Vyas, Stanzin Spalkit, Smriti Hari

• Systemic Autoimmune Rheumatic Diseases Interstitial Lung Disease *160*; • Granulomatous Disease *165*; • Exposure-Related Diseases *168*; • Miscellaneous *172*

10. Miscellaneous Interstitial Lung Diseases **177**

Manisha Jana, Ashu Seith Bhalla, Ekta Dhamija

• Diffuse Lung Diseases Presenting with Ground-glass Opacity and Consolidation *177*; • Septal Thickening Predominant Diffuse Lung Diseases *184*; • Diffuse Lung Diseases Presenting with Nodules *187*; • Diffuse Lung Diseases Presenting with Cysts *187*

11. Imaging Approach to Mediastinal Pathology **195**

Ankur Goyal, Ankita Aggarwal, Raju Sharma

• Compartments of the Mediastinum *195*; • Imaging Modalities *197*; • Mediastinal Masses *199*; • Miscellaneous *209*; • Approach *220*

12. Imaging of Solitary Pulmonary Nodule **224**

Sapna Singh, Anjali Prakash, Jyoti Kumar

• Spurious Solitary Pulmonary Nodule *224*; • Morphological Characteristics of SPN *224*; • Other Characteristics of SPN *230*; • Assessment of Malignant Potential of SPN *232*; • Newer Imaging Techniques for the Evaluation of SPN *236*; • ACR Appropriateness Criteria for Incidentally Detected Indeterminate Pulmonary Nodules *239*; • Guidelines for the Management of Solitary Pulmonary Nodule *239*; • Morphological Characteristics in Specific Lesions *241*

13. Imaging of Pulmonary Neoplasms **253**

Priyanka Naranje, Mukesh Kumar Yadav, Chandan Jyoti Das

• The WHO Classification *253*; • Clinical Features *253*; • Imaging Modalities *254*; • Radiological Characteristics by Cell Type *259*; • Sampling for Suspected Lung Cancer *261*; • Staging of Lung Cancer *262*; • Treatment of Lung Cancer *266*; • Screening for Lung Cancer *267*; • Follow-up Imaging *267*; • Recurrent Lung Cancer *268*; • Rare Lung Malignancies *268*; • Pulmonary Lymphoma Primary *269*; • Pulmonary Neuroendocrine Neoplasms *270*

14. Imaging of the Large Airways **278**

Ashu Seith Bhalla, Smita Manchanda

• Role of Imaging *278*; • Imaging Modalities *278*; • Normal Airway Anatomy *283*; • Anatomic Variants *283*; • Tracheobronchial Tree Pathologies *284*

15. Small Airway Imaging **303**

Radhika Batra, Swati Gupta, Alpana Manchanda

• Anatomy *303*; • Imaging of Small Airway Disease *303*; • Direct and Indirect Signs of Small Airway Disease *304*; • Bronchiolitis *305*; • Chronic Obstructive Pulmonary Disease *311*; • Asthma *314*

16. Radiographs and Computed Tomography in Intensive Care Unit Patients **316**

Nidhi Prabhakar, Akshay Kumar Saxena, Kushaljit Singh Sodhi, Veenu Singla

• Chest Radiograph *316*; • Computed Tomography *317*; • Imaging of Cardiopulmonary Complications in Intensive Care Unit Patients *317*; • Imaging of Support and Monitoring Apparatus *322*

17. Imaging in Thoracic Trauma **326**

Atin Kumar, Shivanand Gamanagatti, Amarinder Singh Malhi

• Role of Imaging *326*; • Pulmonary Parenchymal Injuries *327*; • Pleural Injuries *330*; • Injuries of the Mediastinum *332*; • Injury of Diaphragm *337*; • Injury of Chest Wall *337*

18. Imaging of Pleura **340**

Anjali Prakash, Rashmi Dixit, Sapna Singh

• Imaging Modalities *340*; • Pleural Pathology *342*; • Pleural Effusion *342*; • Imaging in Pleural Effusion *344*; • Pleural Effusion or Ascites *348*; • Pleural Fistula *354*; • Pleural Thickening *355*; • Pleura and Asbestosis *357*; • Asbestosis Pseudotumor (Round Atelectasis) *358*; • Pleural Calcification *358*; • Pneumothorax *358*; • Imaging Findings of Pneumothorax *359*; • Pleural Neoplasm *363*; • Mesothelioma (Malignant Pleural Mesothelioma) *363*; • Tumor-like Conditions of the Pleura *369*

19. Imaging of the Diaphragm and Chest Wall **371**

Ujjwal Gorsi, Arun Sharma, Anupam Lal, Tulika Singh

• Functions *372*; • Imaging Modalities *372*; • Normal Variants *374*; • Elevated Hemidiaphragm *375*; • Diaphragmatic Movements *376*; • Diaphragmatic Weakness and Paralysis *376*; • Diaphragmatic Hernias *376*; • Diaphragmatic Injury *378*; • Tumors of the Diaphragm *379*; • Chest Wall *380*; • Tumors of the Chest Wall *382*; • Chest Wall Invasion by Thoracic Malignancy *386*

20. Hemoptysis: Imaging Approach and Interventions **387**

Rajendra Kumar Behera, Ashu Seith Bhalla, Priyanka Naranje, Ankur Goyal

• Pathophysiology and Etiology *387*; • Management Approach *388*; • Preprocedure Diagnostic Workup *389*; • Section A: Bronchial Artery Embolization *390*; • Section B: Pulmonary Artery Embolization *398*

21. Nonvascular Thoracic Interventions **404**

Harish Bhujade, Naveen Kalra, Mandeep Kang, Anupam Lal, Ujjwal Gorsi

• Image Guidance Modalities *404*; • Nonvascular Interventions *405*; • Thermal Ablation of Lung Lesions *412*; • Vascular Interventions *414*

22. Chest Radiograph in Cardiac Disease **419**

Priya Jagia, Niraj Nirmal Pandey

• Cardiac Silhouette *419*; • Assessment of Chamber Enlargement *421*; • Aorta *422*; • Pulmonary Vasculature *422*

23. Cardiac and Coronary Imaging on CT and MRI: Techniques and Anatomy **427**

Arun Sharma, Manphool Singhal, Amarinder Singh Malhi

• Anatomy *427*; • Techniques *431*

24. Imaging Approach in Children with Congenital Heart Disease **439**

Priya Jagia, Sanjeev Kumar, Akshit Kumar

• Physical Examination *439*; • Radiological Approach *439*; • Multislice Cardiac CT *443*; • Cardiac MRI *444*; • Cardiac Catheterization *449*

25. Imaging in Ischemic Heart Disease **452**

Niraj Nirmal Pandey, Sanjeev Kumar

• Pathophysiological Basis of Ischemic Heart Disease *452*; • Imaging Modalities *453*; • Evaluation of Various Components of Ischemic Heart Disease *459*; • Evidence-based Guidelines for the Use of Imaging in Ischemic Heart Disease *463*

26. Imaging in Non-ischemic Cardiomyopathies **466**

Priya Jagia, Vineeta Ojha

• Classification of Cardiomyopathies *466*; • Diagnostic Techniques *466*; • Non-ischemic Dilated Cardiomyopathy *468*; • Hypertrophic Cardiomyopathy *469*; • Restrictive Cardiomyopathy *471*; • Anderson–Fabry Disease *475*; • Arrhythmogenic Cardiomyopathy *475*; • Left Ventricular Non-compaction *477*; • Takotsubo Cardiomyopathy *477*; • Myocarditis *477*; • Myocardial Tuberculosis *478*; • Peripartum Cardiomyopathy *478*

27. Imaging Evaluation of Cardiac Masses **481**

Sanjeev Kumar, Aprateem Mukherjee

• Clinical Features *481*; • MRI Sequences for Evaluation of Cardiac Masses *483*; • Classification of Cardiac Masses *483*; • Variant and Normal Anatomical Structures Simulating a Cardiac Mass *494*

28. Imaging of Valvular Heart Disease **496**

Vineeta Ojha, Niraj Nirmal Pandey

• Introduction and Epidemiology *496*; • Clinical Presentation and Management *496*; • Imaging Techniques *496*; • Mitral Valve *499*; • Tricuspid Valve *504*; • Aortic Valve *505*; • Pulmonary Valve *509*; • Prosthetic Heart Valve *509*

29. Imaging of the Pericardium **512**

Jyoti Kumar, Sapna Singh, Gaurav Shanker Pradhan

• Anatomy *513*; • Transverse Sinus and Recesses *514*; • Physiology *515*; • Congenital Pericardial Anomalies *516*; • Congenital Absence of the Pericardium *516*; • Pericardial Effusion *517*; • Cardiac Tamponade *519*; • Pericarditis *520*; • Pneumopericardium *523*; • Pericardial Tumors *524*

30. Imaging and Interventions of Aorta **527**
Manphool Singhal, Arun Sharma, Sanjeev Kumar

• Segmentation Anatomy of Aorta *527*; • Imaging of Aorta: Basics *528*; • Imaging Modalities *529*; • Indications for Imaging the Aorta *533*; • Congenital Aortic Anomalies *533*; • Acquired Aortic Diseases *536*; • Aortic Aneurysms *537*; • Acute Aortic Syndrome *545*; • Aortic Dissection *545*; • Imaging *546*; • Intramural Hematoma *551*; • Penetrating Aortic Ulcer *552*; • Aortitis *553*; • Aortic Trauma *556*; • Atherosclerosis *558*

31. Imaging in Pulmonary Thromboembolism **564**
Manphool Singhal, Arun Sharma, Ujjwal Gorsi, Mandeep Garg

• Acute Pulmonary Embolism *564*; • Chronic Thromboembolic Disease *570*

32. Peripheral Vascular Diseases: Imaging and Interventions **574**
Devasenathipathy Kandasamy, Shivanand Gamanagatti, Chandrashekhara SH

• Clinical Assessment for Peripheral Arterial Disease *576*; • Diagnostic Testing for Peripheral Arterial Disease *577*; • Teaching Points *598*

33. Role of Artificial Intelligence in Thoracic Imaging **601**
Amit Gupta, Krithika Rangarajan

• Current Challenges and Future Directions *606*

Index **609**

CHAPTER

29

Imaging of the Pericardium

JAYPEE BROTHERS

INTRODUCTION

Pericardial diseases could be a variety of benign and malignant disorders.[1] The initial approach to the evaluation of pericardial disease is usually performed with echocardiography and chest radiography. While echocardiography has its own advantages, namely high temporal and spatial resolution, easy availability, no involvement of ionizing radiation, it is usually limited by poor acoustic window, poor soft tissue characterization and operator variability. In addition, it can be very difficult to detect pericardial thickening or calcification.[2,3] Plain radiography, on the other hand, may not be able to differentiate various pericardial disorders.[4]

Computed tomography (CT) and magnetic resonance imaging (MRI) techniques are complementary to echocardiography and used as second line modality. They provide excellent anatomic details, help in localizing pericardial pathology as well as depicting associated abnormalities of the lung and mediastinum. The advent of multidetector CT with its excellent temporal resolution helps us to image pericardium devoid of cardiac motion artifacts. Multiplanar reformats allow better visualization of pericardial pathology with easy communication to the referring physician.[5] A cinematic display of cardiac motion is now possible on CT with electrocardiography (ECG) gating and high-resolution thin section images can be obtained. Increased sensitivity to detect calcification is another advantage of CT. MRI provides superior soft tissue characterization than CT and echocardiography. MRI can provide excellent display of cardiac motion in patients with regular heart rhythm.[5-8] The role of various imaging modalities based on European Society of Cardiology (ESC) guidelines[9] and American Society of Echocardiography (ASE) consensus[10] is depicted in **Table 1**.

TABLE 1: Various imaging modalities to evaluate pericardial pathology as per ESC guidelines and ASE consensus.

	Echocardiography	Computed Tomography	Cardiac Magnetic Resonance
Role	First modality of choice	Second modality of choice	Second modality of choice
Advantages	• Can be used bedside • Functional evaluation possible • Hemodynamic assessment can be done on Doppler	• Short acquisition time • Calcification diagnosed reliably • Extracardiac findings assessed	• Superior tissue characterization compared with Echo and CT • Excellent temporal resolution for hemodynamic evaluation • Late gadolinium imaging (LGE) with MRI can delineate ongoing pericardial inflammation
Disadvantages	• Limited evaluation in case of poor acoustic window, in obesity • Operator dependent • Less soft tissue characterization	Ventricular function not assessed (in case of prospective gating)	Time-consuming examination

(ESC: European Society of Cardiology; ASE: American Society of Echocardiography)

ANATOMY

The pericardium has an outer fibrous layer and an inner serous layer. The inner serosal layer is further composed of outer parietal and inner visceral layers. The outer parietal layer lines the inner surface of the fibrous pericardium, and the inner visceral layer forms the epicardium.[11-13] The pericardial cavity lies between the parietal and visceral layers. Normally, up to 50 mL fluid may be present in this potential space created by two opposing serosal surfaces.

Ligaments attach the outer pericardium to sternum and diaphragm. The serosal layer forms two complex sleeves as it reflects around major vessels. One of these sleeves encloses the aorta and pulmonary trunk, and the other encloses the superior and inferior vena cava and the four pulmonary veins. These reflections form the sinuses and recesses **(Fig. 1)**. The transverse sinus is the channel in between these two sleeves around the arteries and veins and the oblique sinus is the channel behind the left atrium. The recesses are the blind ends of these sinuses **(Box 1)**. These sinuses and recesses can collect fluid within them in case of pericardial effusion. With the advent of MDCT, visualization of pericardial recesses without fluid accumulation is also possible.[13]

The normal pericardium can be seen as a thin line <2 mm in thickness.[14] On CT, it appears as a thin linear density surrounding the heart better visualized over the right ventricle **(Fig. 2A)**. It appears as a hypointense line on MR surrounded by epicardial fat on one side and pericardial fat on the other side on T1, T2 weighted and gradient images **(Fig. 2B)**. [15-17] Pericardial fat is the anterior meditational fat seen anterior to the pericardium while the epicardial fat lies between the visceral layer of pericardium and the outer wall of myocardium.[1] The volume of epicardial fat has been linked with the risk of coronary artery disease.

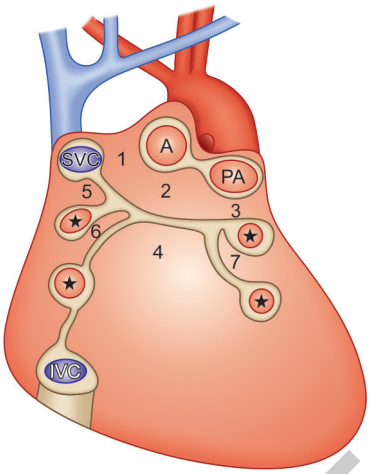

FIG. 1: Schematic representation of pericardium. Transverse sinus (2) with right and left pulmonic recesses (1 and 3). Oblique sinus (4), postcaval recess (5) and right and left pulmonary venous recesses (6 and 7).

(A: aorta; PA: pulmonary artery; SVC: superior vena cava; IVC: inferior vena cava; H: pulmonary veins)

BOX 1: Sinuses and recesses of pericardium.

- *Transverse sinus*:
  - Superior aortic sinus
    - Anterior triangular extension
    - Posterior crescentic extension
    - Right lateral extension
  - Inferior aortic recess
  - Right and left pulmonic recesses
- *Oblique sinus*:
  - Posterior pericardial recess
- *Recesses of pericardial cavity proper*:
  - Right and left pulmonary venous recesses
  - Postcaval recess

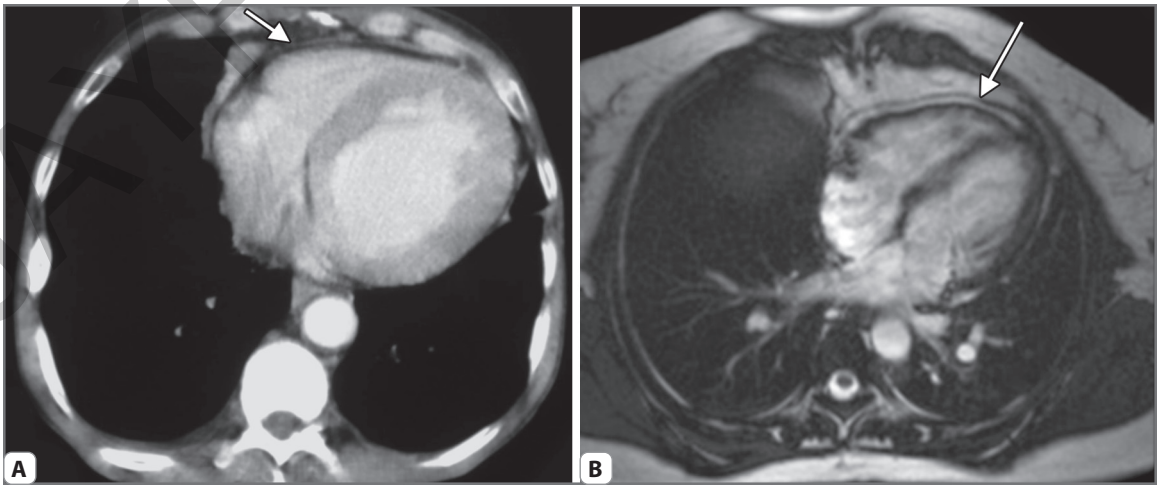

FIGS. 2A AND B: (A) Axial contrast enhanced CT scan shows normal pericardium (arrow) outlined by epicardial fat and mediastinal fat on either side. Note made of subsegmental atelectasis in right lung; (B) Short axis cine gradient echo MR image shows normal pericardium as a thin curved line (arrow) surrounded by bright epicardial and pericardial fat on either side.

JAYPEE BROTHERS

TRANSVERSE SINUS AND RECESSES

The transverse sinus lies behind the aorta and the main pulmonary artery and superior to the left atrium.

Superior Aortic Recess

The cranial most extent of this sinus is the superior aortic or superior pericardial recess. It can further be divided into posterior, right, and anterior portions depending on relationship with aorta. The posterior portion is seen as a crescentic fluid collection just posterior to the ascending aorta. It can be mistaken for a lymph node. The fluid in this posterior portion lies directly posterior to the aorta with no intervening fat. The crescent shape and fluid attenuation are other distinguishing features from lymph nodes. Multiplanar reformats aid in depicting continuity of the pericardial recesses with the fluid in the pericardial sac. The anterior portion passes between the aorta and pulmonary artery, resulting in a triangular shape between them **(Fig. 3A)**.[13]

Inferior Aortic Recess

Inferiorly, the transverse sinus extends between the ascending aorta and the right atrium and forms the inferior aortic recess. This extends caudally till the level of the aortic valve annulus and lies anterior to the left atrium **(Figs. 4A and B)**.

Right and Left Pulmonic Recesses

Laterally, the transverse sinus ends in right and left pulmonic recesses **(Figs. 3B to D)**. The former lies inferior to the right pulmonary artery. The left pulmonic recess lies below the left pulmonary artery. Below this lies the left superior pulmonary vein. Fluid within these recesses can sometimes simulate lymph nodes.[18]

Oblique Sinus and Recess

The oblique sinus lies superior and posterior to the left atrium and posteromedial to the superior pulmonary veins **(Figs. 5A and B)**. It is separated from the transverse

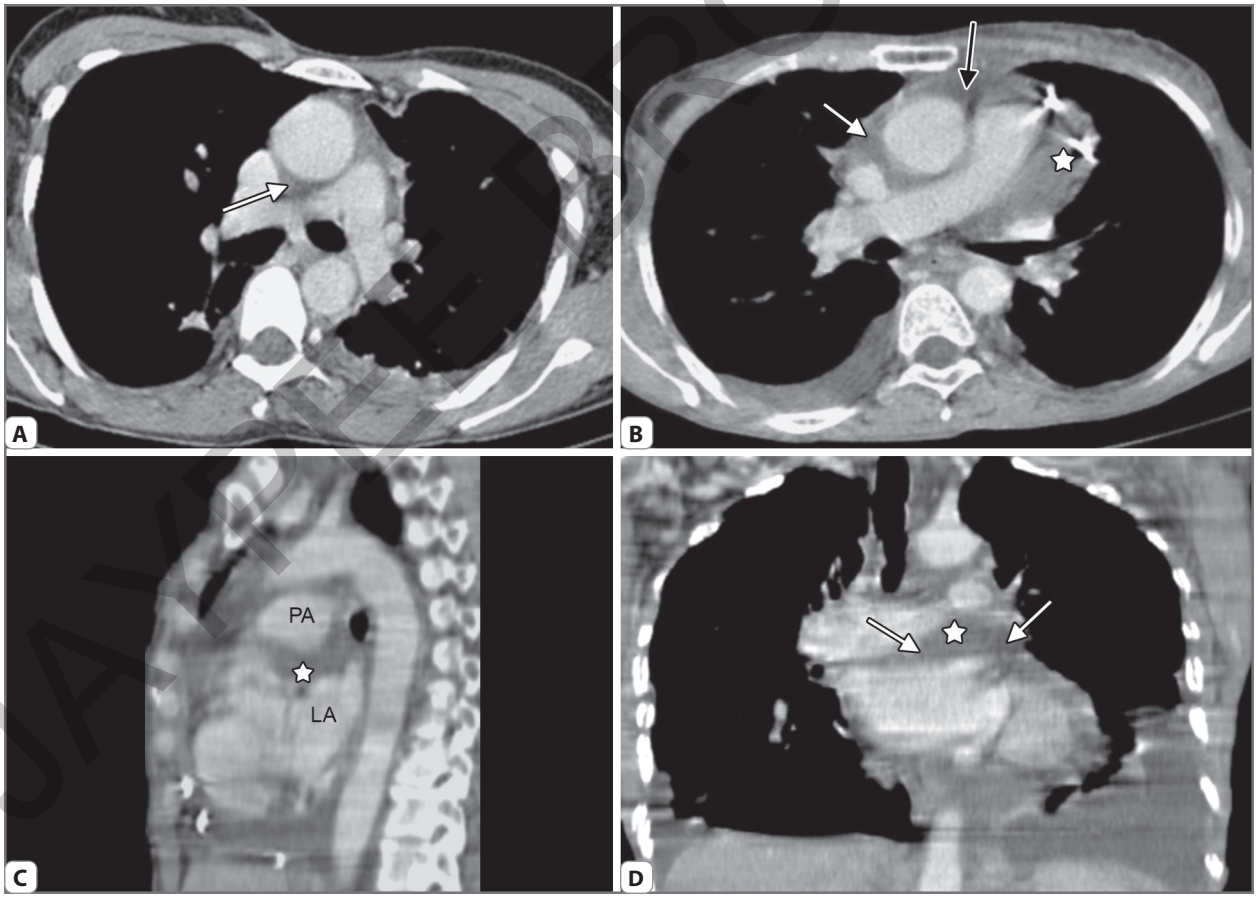

FIGS. 3A TO D: (A) Axial CECT shows the posterior extension of the superior aortic recess posterior to the ascending aorta, as a crescentic fluid collection (arrow); (B) Axial CECT shows left pulmonic recess of the transverse sinus (asterisk). Pericardial fluid is also seen in the anterior (black arrow) and right (white arrow) portions of the superior aortic recess. Note made of pericardial drainage catheter in situ; (C) Sagittal reformation shows the transverse sinus (asterisk) between pulmonary artery (PA) and left atrium (LA). Note made of pericardial drainage catheter in situ; (D) Coronal reformation shows transverse sinus (asterisk) along with right and left pulmonic recesses (arrows) at its right and left ends.

JAYPEE BROTHERS

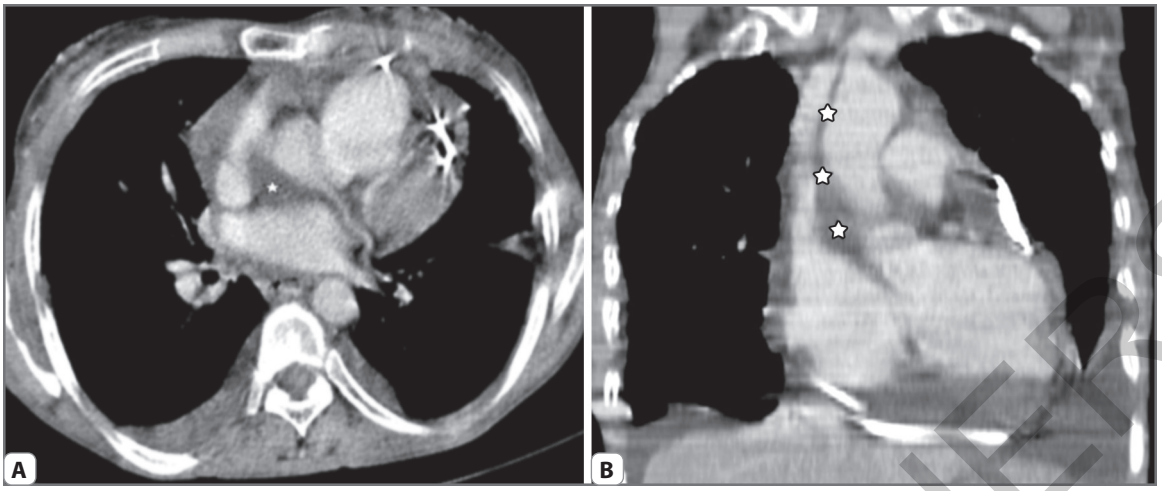

FIGS. 4A AND B: (A) Axial contrast enhanced CT scan shows inferior aortic recess between the right atrium and aortic root (asterisk). Note made of pericardial drainage catheter in situ; (B) Coronal reformation shows the vertical extent of the transverse sinus with its superior and inferior aortic recesses (asterisk). Note made of pericardial drainage catheter in situ.

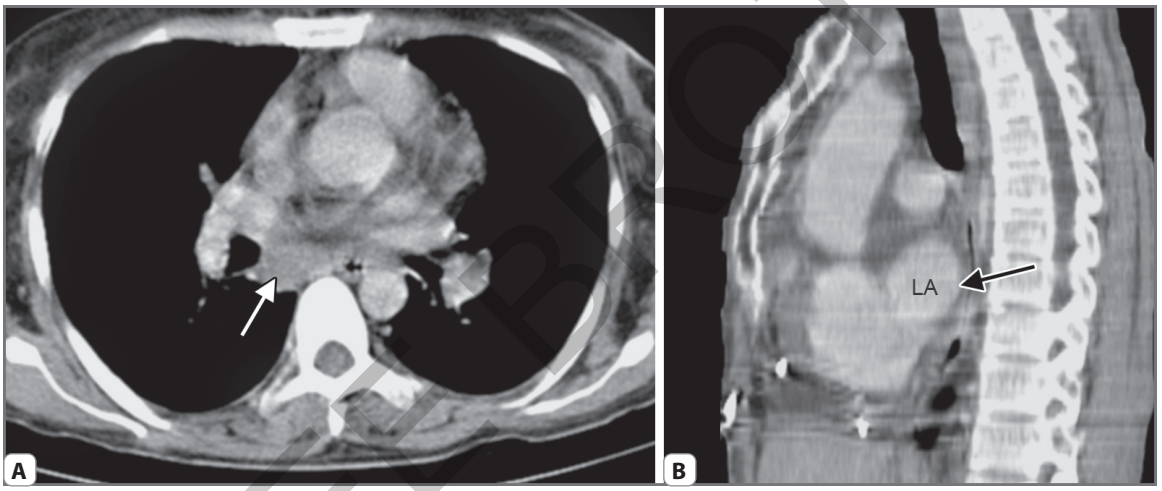

FIGS. 5A AND B: (A) Axial contrast enhanced CT scan shows posterior pericardial recess of the oblique sinus (arrow) superior to the left atrium, medial to bronchus intermedius and posteromedial to the superior pulmonary veins; (B) Sagittal reformation shows the oblique sinus (arrow) between the left atrium anteriorly and the esophagus posteriorly.

sinus by a pericardial reflection between the right and left superior pulmonary veins. Since this lies just anterior to the esophagus, fluid here may be mistaken for esophageal lesions and sometimes even as bronchogenic cysts.

The cranial reflection is the posterior pericardial recess. This extends behind the right pulmonary artery and medial to the bronchus intermedius **(Fig. 5A)**. Fluid within this recess can mimic peribronchial or subcarinal lymph nodes.[11]

Recesses of the Pericardial Cavity Proper

Right and Left Pulmonary Venous Recesses

The right and left pulmonary venous recesses are recesses of the pericardial cavity proper, located between the superior and inferior pulmonary veins on either side.

Fluid in these pulmonary venous recesses can be mistaken for bronchopulmonary lymph nodes. These may be distinguished by the fact that fluid lies both anterior and posterior to the veins whereas, lymph nodes lie only on one side and may narrow the vein.[11]

Postcaval Recess

The postcaval recess is another small recess from the pericardial cavity proper, lying posterior to the superior vena cava (SVC) and to its right.[11]

PHYSIOLOGY

The pericardium supports the heart and cardiac function in the following major ways:[19]

- It fixes the heart within the anterior mediastinum protecting it from surrounding organs
- Its elasticity limits excessive dilatation of cardiac chambers in response to increased preload

JAYPEE BROTHERS

- It equalizes compliance between right and left ventricle. When stroke volume of left ventricle is altered due to elevated systemic vascular resistance, it helps in adaptation of stroke volume of the right ventricle accordingly (ventricular coupling).
- The respiratory changes in intrathoracic pressure are directly transmitted to the pericardial cavity and then to the cardiac chambers. The effect is greater on the right ventricle than on the left because of its thinner wall.

CONGENITAL PERICARDIAL ANOMALIES

Congenital pericardial abnormalities include pericardial cyst, pericardial diverticula and congenital absence of pericardium.

Pericardial Cyst (Box 2)

Pericardial cyst is a rare lesion which results from pinching off of parietal pericardial recess. It can be found throughout the mediastinum, but the most common location is the right anterior cardiophrenic angle. A pericardial cyst elsewhere in the mediastinum may be difficult to differentiate from a bronchogenic or thymic cyst.[8] When a pericardial cyst has a residual communication with the pericardial space, it is called a pericardial diverticula.[4] This communication may however be difficult to delineate. Owing to this communication, there may be changes in size and shape of the diverticula when evaluated at different points of time.

Although usually asymptomatic, few patients may have chest pain, dyspnea, cough, pneumothorax, or fever. Another rarer presentation may be due to bronchial compression.

The pericardial cyst is usually sharply demarcated round or ovoid mass in the region of right cardiophrenic angle silhouetting the cardiac border. The cyst may have a pointed upper border as it droops down into the cardiophrenic region from higher up. On cross-sectional imaging, it is a well-defined unilocular, thin walled homogenous nonenhancing mass contiguous with the pericardium. Ultrasound can depict the cystic lesion adjacent to pericardium. On CT, it has fluid attenuation and on MRI, it matches the signal characteristics of water.

BOX 2: Pericardial cyst.

- Rare congenital lesion
- Most common location is right cardiophrenic angle
- Typical imaging features—well-defined cyst with thin wall, no internal septations, low signal on T1 weighted MR and high signal on T2 weighted MR images
- Mass effect and enhancement not seen unless infected

Presence of proteinaceous contents within the cyst can result in occasional high signal on T1 weighted images. There is no restriction on diffusion imaging. Additionally, a pericardial cyst does not normally cause mass effect on the heart. The cysts may get infected and then show peripheral enhancement and mass effect. Internal enhancement, soft tissue or fat component, thickened wall or septae or mass effect raise the suspicion of a cystic tumor. Symptomatic and complicated cysts may need to be resected.[11]

CONGENITAL ABSENCE OF THE PERICARDIUM (BOX 3)

Congenital absence of the pericardium is an uncommon abnormality which may be partial or complete. Apart from congenital etiology, pericardial defect may also be acquired after surgery or trauma.[20]

Absence of left pericardium is more common than complete absence.[3] Bilateral and isolated right sided defects are very rare. There may be other congenital anomalies along with pericardial defect which include cardiac anomalies (atrial septal defect, patent ductus arteriosus), and anomalies of the lung (bronchogenic cysts, pulmonary sequestration), chest wall (pectus excavatum) and diaphragm.[21] Patients are generally asymptomatic although vague chest pain can occur due to lack of fixation.[20,21] A focally deficient pericardium may allow a part of the heart to herniate through the defect. It most often involves the left atrial appendage. Rarely, there may be left atrial infarction resulting in sudden death. The left coronary artery may also be compressed by the herniation through this defect. This can rarely result in ischemia, especially during activity. In such situations, surgical closure or enlargement of the defect may be performed.[19]

In complete absence of left pericardium, heart is displaced to the left side on plain radiographs. The segments of the heart that make up the left heart border can be seen more distinctly. The aorta and main pulmonary artery are

BOX 3: Congenital absence of pericardium.

- Rare anomaly
- Left-sided absence commoner than complete absence
- *Radiographic findings*:
  - Left ventricle and pulmonary artery displaced to left
  - Main pulmonary artery borders distinctly seen
  - Pulmonary artery/left atrial appendage may be prominent in partial absence
- *CT/MR findings*:
  - Leftward shift of cardiac axis
  - Prominent atrial appendage
  - Lung seen interposed between aorta and main pulmonary artery

JAYPEE BROTHERS

seen more clearly due to the interposition of lung between them. In partial absence of the left pericardium, pulmonary artery or left atrial appendage may be prominent depending upon the location of pericardial defect.[4,22]

Normally, CT and MR may not depict the pericardium along its entirety. The pericardium may not be normally seen over the left atrial appendage and the left ventricle and should not be misinterpreted as pericardial defect. Secondary signs, which include posterior and leftward shift of the cardiac axis, prominent atrial appendage and separation of the aorta and main pulmonary artery due to lung tissue interposition become more important features. Occasionally, lung tissue can be seen inferior to the heart, interposed between the heart and the diaphragm. The herniation may be intermittent; hence left lateral decubitus position of the patient can assist in diagnosing pericardial defects. Also, functional examination can pick up greater mobility of the cardiac apex which is otherwise essentially stationary in a normal cardiac cycle.[23]

PERICARDIAL EFFUSION

The various causes of pericardial effusion include heart failure, renal insufficiency, infection (bacterial, viral, tubercular), neoplasm (carcinoma of the lung, breast, lymphoma, melanoma) and injury (trauma, myocardial infarction). Other causes may be hypothyroidism, connective tissue disorder, acquired immune deficiency syndrome (AIDS) or radiation pericarditis.[24]

The role of imaging is to confirm the presence and extent of fluid, to characterize the nature of fluid, to rule out pericardial inflammation, to determine its hemodynamic impact and to guide pericardiocentesis. Echocardiography is generally the first imaging modality used because of high sensitivity, specificity, easy availability and low cost **(Fig. 6A)**. Limited acoustic window may impair the utility of this modality in many cases. With the exception of transesophageal echocardiography, it is not a reliable technique for estimating pericardial thickness and in assessment of loculated pericardial effusions. CT and MR provide a wider field of view and are superior in detecting the amount, nature and distribution of the fluid. Focal fluid accumulation may be seen posterolateral to the left ventricle and along the inferolateral wall of the right ventricle owing to their dependent locations. Superior pericardial recess is another common location of focal fluid accumulation.[19]

The size of a pericardial effusion may be semi-quantitatively assessed by the thickness of fluid anterior to the right ventricle. Pericardial width of >4 mm may be regarded as abnormal. Using criteria established by echocardiography, a pericardial effusion may be quantified as small (<5 mm); moderate (5–10 mm); or large (>10 mm).[24,25] On a chest radiograph, pericardial effusion is suspected when there is diffuse cardiac silhouette enlargement without specific chamber enlargement. Filling of the retrosternal space, enlargement of normal cardiac borders, development of "flask" configuration and bilateral hilar overlay may be seen in larger effusions **(Fig. 6B)**. On the lateral projection, "epicardial fat pad" sign is diagnostic of pericardial disease. This is positive when the anterior pericardial stripe, bordered by the epicardial fat and mediastinal fat on either side, is seen to be thicker than 2 mm. It may also be seen in the frontal view because of the presence of abundant fat between the pericardium and pleura at the cardiac apex. This is seen as a radiolucent stripe internal to and parallel to the left lower cardiac border.[19] Rapid increase in cardiac size also suggests presence of pericardial effusion. On a chest radiograph, pan chamber cardiac enlargement and large anterior mediastinal tumor may simulate pericardial effusion.

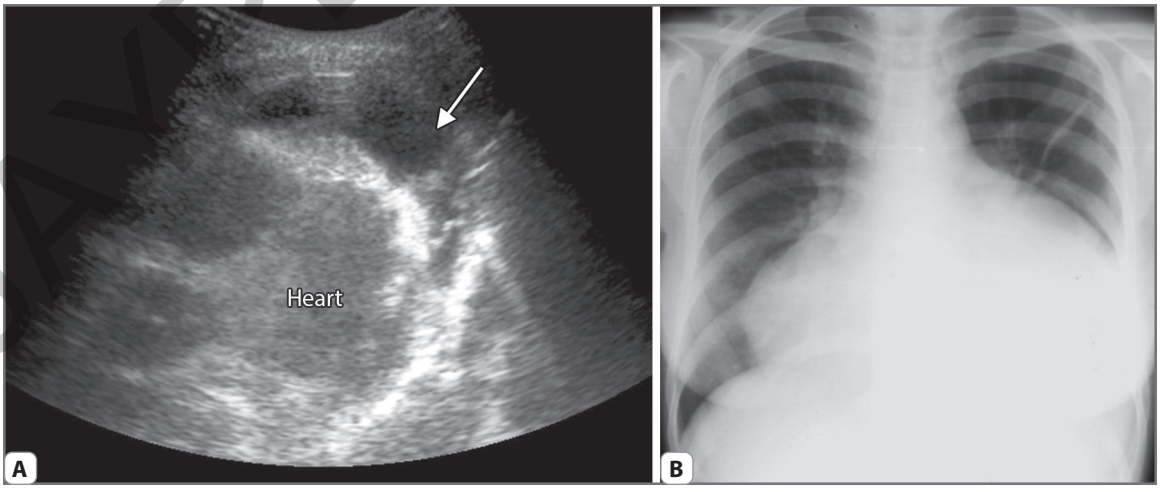

FIGS. 6A AND B: (A) Pericardial effusion. Ultrasound chest depicts fluid in the pericardial cavity (arrow); (B) Frontal chest radiograph shows enlarged "flask" shaped cardiac silhouette without specific chamber enlargement with bilateral hilum overlay sign.

JAYPEE BROTHERS

On CT, the attenuation values of pericardial fluid are only of limited value. Serous effusions tend to have near-water attenuation values (<10 HU) **(Figs. 7A and B)**, while exudative effusions can range from 20 to 60 HU **(Figs. 7C and D)**. Chylopericardium can also present with low attenuation values but may be difficult to distinguish from transudative effusions. Acute hemopericardium can have attenuation values in the range of 60–80 HU, but if blood represents only a portion of the fluid, the attenuation values can then be similar to that of exudative effusions. High attenuation suggests hemopericardium in the history of trauma, surgery or aortic dissection. Generally, 30 HU is a useful cut off between simple effusions and bloody or proteinaceous effusions.[12] Pericardial enhancement can be seen in case of pericardial inflammation. It may sometimes be difficult to distinguish between pericardial effusion and thickening on CT which is better appreciated on echocardiography or MRI. Echocardiography is limited by poor acoustic window, location of effusion and characterization of pericardial effusion.

MRI may be performed to further characterize pericardial effusions. Transudates have a low signal intensity on T1-weighted images and high signal intensity on T2-weighted images and GRE cine images **(Figs. 8A and B)**. Exudates have a higher signal intensity on T1-weighted images and low signal intensity on T2-weighted images due to high cellularity and protein content within **(Figs. 9A and B)**. Hemopericardium is characterized by high signal on T1-weighted images and may be low signal on T2-weighted images and GRE cine images. Hemorrhage or infection should be suspected on cine imaging when the effusion fluid is clearly complex and inhomogeneous, containing regions of different signal intensity.[26,27] The gradient images may better characterize a hemopericardium as they facilitate the visualization of fibrinous strands and presence of coagulated blood. The T1 and T2 signal intensity of a hemorrhagic pericardial effusion is dependent on the duration of the hematoma. However, certain artifacts like non-linear motion of pericardial fluid during cardiac motion may falsely cause high signal on T1-weighted

MAY BE PROTHERS

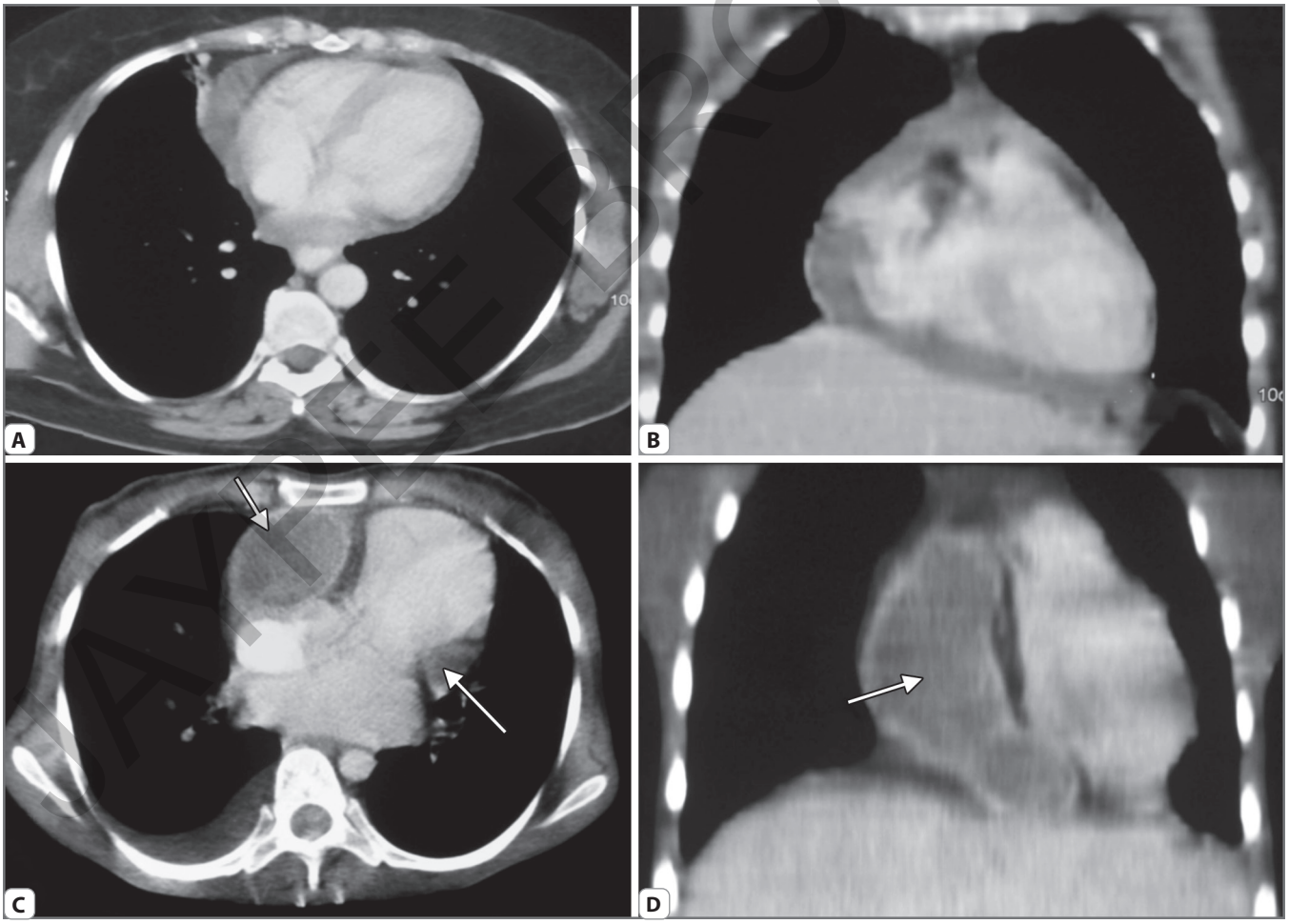

FIGS. 7A TO D: (A and B) Pericardial effusion. Axial CECT (A) and coronal reformatted (B) images show small simple pericardial effusion (HU = 10); (C and D) Exudative pericardial effusion. Axial CECT (C) and coronal reformatted (D) images show high attenuation loculated effusion (HU = 45) (arrows) in atrioventricular groove in a case of tubercular pericarditis.

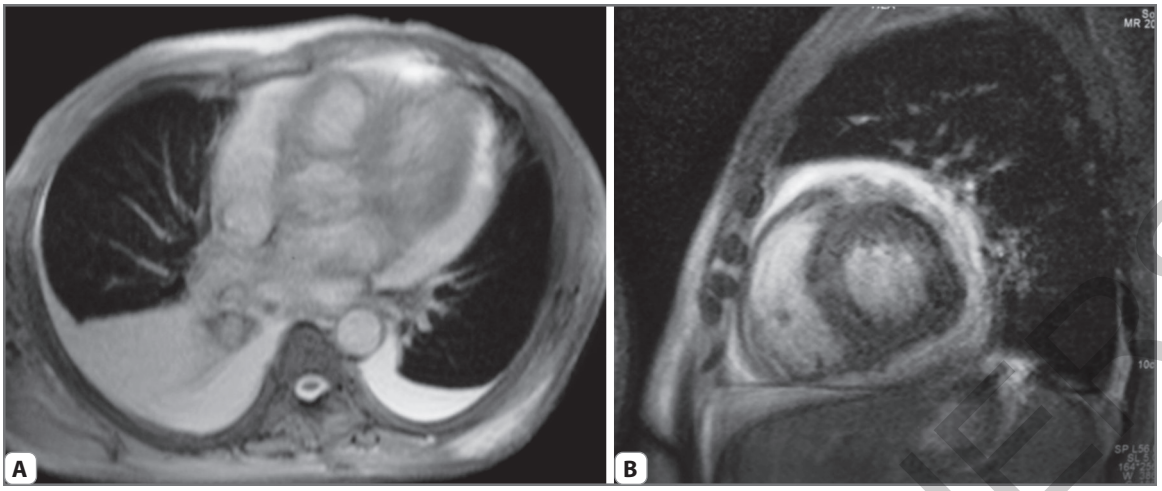

FIGS. 8A AND B: Pericardial effusion. Moderate simple effusion is seen on four chamber (A) and short axis; (B) cine SSFP images. Bilateral pleural effusions are also seen.

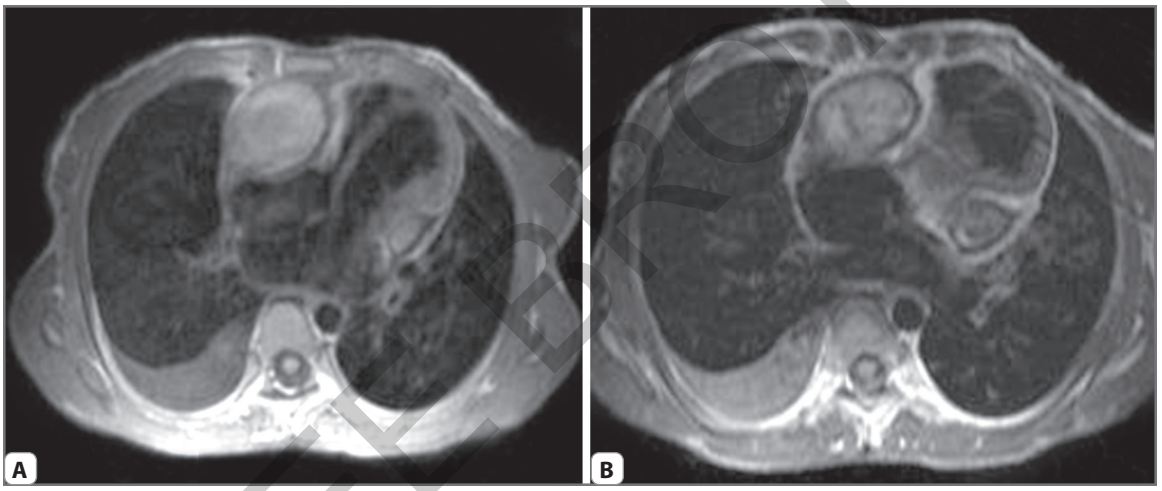

FIGS. 9A AND B: Exudative pericardial effusion. Axial dark blood T1 and T2-weighted images show exudative effusion in the atrioventricular groove and associated pericardial thickening. It is seen as high signal intensity on T1-weighted images (A) with complex and inhomogeneous signal intensity on T2-weighted images (B). Note made of right pleural effusion.

spin-echo CMR even within a transudative effusion.[12] Effusion secondary to malignancy may have associated pericardial thickening and nodularity. MR is superior to CT in differentiating pericardial effusion from thickening. The high signal intensity on cine and T2-weighted images allows to clearly distinguish between pericardial effusion and thickened pericardium which is low signal intensity on these sequences. Phase sensitive inversion recovery (PSIR) delayed enhancement imaging not only aids in assessing pericardial and myocardial inflammation but can also help in distinguishing dark appearing pericardial fluid from bright epicardial fat on this sequence.

CARDIAC TAMPONADE (BOX 4)

Slow accumulation of pericardial fluid may cause adaptive expansion of the pericardium with accumulation of up to 3 L of fluid without significant hemodynamic consequence.[28] However, in cases of rapid accumulation, as little as 100–200 mL of fluid may result in an effusion under tension or cardiac tamponade, especially if the pericardium has limited compliance owing to pericardial inflammation/scarring.[20] The resultant increased pericardial pressure is then transmitted to the cardiac chambers. Cardiac

BOX 4: Cardiac tamponade.

- Life-threatening condition requiring urgent intervention
- Causes include trauma, cardiac surgery, inflammation, pericardial neoplasm, aortic dissection
- Speed of fluid accumulation key determinant of symptoms
- Primarily a Clinical diagnosis, in combination with findings on echocardiography
- Role of CT and MR limited to atypical/chronic cases

JAYPEE BROTHERS

tamponade is a low cardiac output state due to excessive fluid in the pericardial space that compresses the heart, especially the right ventricle. Owing to decreased filling of the right ventricle, tamponade can result in life-threatening hemodynamic compromise. Diagnosis is primarily clinical. It is based on clinical criteria in combination with hemodynamic findings on echocardiography that can depict collapse of right ventricular free wall during diastolic phase, right atrial collapse during late diastole/systole, paradoxic motion of the interventricular septum, greater respiratory variations and distended hepatic veins and inferior vena cava due to back flow. "Flow velocity paradoxus" refers to increased flow across tricuspid and pulmonic valves and decreased flow across mitral and aortic valves during inspiration.

CT and MR have a limited role in the evaluation of acute cardiac tamponade; only long standing or less severe forms may sometimes be seen. CT and MRI may be helpful in nonemergent situations when echocardiographic findings are equivocal. The heart size, excluding the pericardial space is normal or decreased. This is contrary to restrictive cardiomyopathy and pericardial constriction in which the atria are typically enlarged.[3,5] The cavae and hepatic veins which are exterior to the pericardium dilate to accommodate back pooling of blood. Eventually, if pericardial pressure exceeds the ability of the circulation to fill the heart, the right sided cardiac chambers collapse.[5] Leftward bowing of the interventricular septum is a nonspecific finding that may be seen in any condition with right side volume or pressure overload.

Cine CT and MRI can show the dynamic features suggestive of tamponade. There is collapse of the right ventricular free wall in early diastole and collapse of the right atrial free wall in early systole. This is because in early diastole less blood is present in the right ventricle than in the right atrium, and so, the right ventricle has the least pressure to counteract the pressure of the pericardial effusion. In early systole, the right atrium has less blood than the right ventricle, so the right atrium has less pressure. This collapse is especially evident during expiration which decreases the right heart filling. Throughout the cardiac cycle there is enhanced ventricular coupling from the taut pericardial space. This most often manifests as abnormal motion of the intraventricular septum. This is seen on cine images as septal rocking or sigmoid septum configuration. The diastolic dysfunction characteristic of tamponade is also well-evaluated on cine images.[5]

When cardiac tamponade is atypical, CT and MR may be better than echocardiography. In these unusual situations, the effusions tend to be loculated and exert mass effect on a part of the heart not well-visualized by transthoracic echocardiography, including the right atrium and left atrium. Oftentimes, these effusions are malignant, postradiation, or postinfectious.

PERICARDITIS

Nonconstrictive Pericarditis (Box 5)

Pericarditis is an inflammatory response of the pericardium which may be a result of various conditions, which include infectious, noninfectious and idiopathic causes **(Table 2)**. Most of the idiopathic causes may be viral in etiology, occurring weeks after the viral infection, secondary to an immune response to the infection. After myocardial infarction, pericarditis may occur in the first few days or less commonly a few weeks later secondary to inflammatory response to cardiac proteins. The latter is known as Dressler syndrome and can present with fever and pericardial friction rub.

In acute pericarditis, the pericardium may develop a small effusion and become slightly thickened. On contrast enhanced CT and MRI, acute pericarditis shows enhancement of the pericardium, which can show smooth thickening (>4 mm) **(Fig. 10)**. Enhancement is better appreciated in the venous phase than in the arterial phase of contrast administration. Associated small effusion may or may not be seen. There are accompanying inflammatory changes in the pericardial fat which may be increased or stranded. The absence of these findings does not exclude the diagnosis. On CT imaging, it may sometimes be

BOX 5: Nonconstrictive pericarditis.

- Inflammatory response of pericardium involving pericardial thickening and effusion
- Enhancement of pericardium can be seen
- Findings may be localized to part of pericardium
- No features of constriction

TABLE 2: Causes of pericarditis.

Infectious	• Viral • Bacterial (*Mycobacterium tuberculosis* most common) • Fungal • Parasitic
Noninfectious	• Post cardiac injury • Systemic inflammatory disorders (systemic lupus erythematosus, rheumatoid arthritis, scleroderma) • Drug reaction • Radiation • Metabolic conditions (chronic renal disease) • Pericardial trauma • Surgery • Malignancy

JAYPEE BROTHERS

difficult to differentiate a small effusion from pericardial thickening which may be resolved on echocardiography. Also, care needs to be taken for assessment of pericardium in its entirety as the findings may only be localized. The presence of myopericarditis on imaging increases the risk of complications. On follow-up, the findings may resolve or progress to scarring.

Pericarditis secondary to tuberculosis, radiation, chronic renal failure, systemic inflammatory disorders, trauma and surgery is more likely to become chronic than viral or drug related pericarditis.

In chronic inflammatory pericarditis, there is development of fibrosis, adhesions and calcification. The effusion may increase or pericardium can get more thickened. The thickened pericardium may show calcification and irregular contour. On MRI, the pericardium is thickened, irregular with variable early enhancement. Delayed enhancement is seen owing to fibrosis. Tagging sequence in MRI can be used to detect adhesions, in which case the grid lines remain intact **(Figs. 11A to C)**. MRI cannot show calcification as well as seen on CT. Fibrous/calcific pericarditis may be asymptomatic or can lead to constrictive pericarditis.[1,29]

Constrictive Pericarditis (Box 6)

Constrictive pericarditis is a condition in which cardiac function is impaired by a thickened, rigid and often calcified pericardium. This results in diastolic dysfunction of the heart and subsequent right heart failure. Clinical symptoms and radiological concordance are required to make this diagnosis. It can clinically mimic restrictive cardiomyopathy, hepatic disease, and congestive heart failure. The distinction between constrictive pericarditis and restrictive cardiomyopathy is very important, since the former would benefit from pericardial stripping and the latter would not. Constrictive pericarditis may be secondary to prior surgery, infection, trauma, radiation, uremia, connective tissue disorder, neoplasm or may be

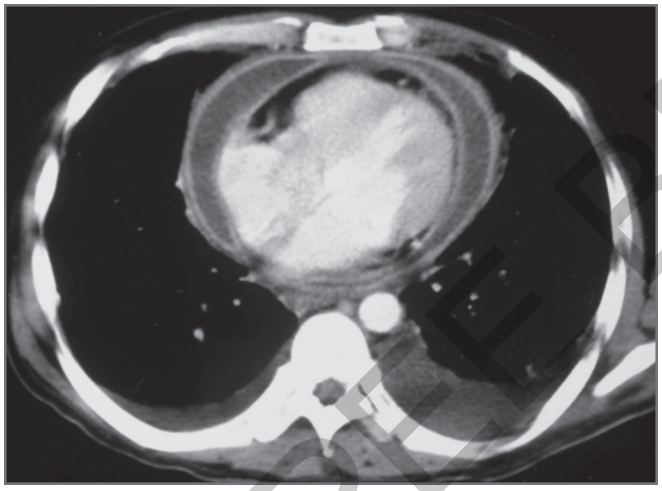

FIG. 10: Nonconstrictive pericarditis. Axial CECT shows enhancing thickened smooth pericardium with associated effusion in a known case of tuberculosis. Bilateral pleural effusions are also seen.

BOX 6: Constrictive pericarditis.

- Reduced pericardial compliance leading to diastolic dysfunction
- Causes include infection, radiation exposure, prior surgery, trauma and postoperative setting
- *Morphological findings*:
  - Pericardial thickening, calcification, enhancement
  - Tubular shape of ventricles
  - Compression of right sided chambers
  - Sigmoid shaped ventricular septum
  - Atrial enlargement
  - Dilated hepatic veins/IVC
  - Pleural effusion, ascites
- *Findings on functional evaluation*:
  - Septal bounce on cine MRI
  - MR tagging technique—tag lines remain unbroken in case of pericardial adhesions
- Dynamic MRI findings help distinguish constrictive pericarditis from restrictive cardiomyopathy

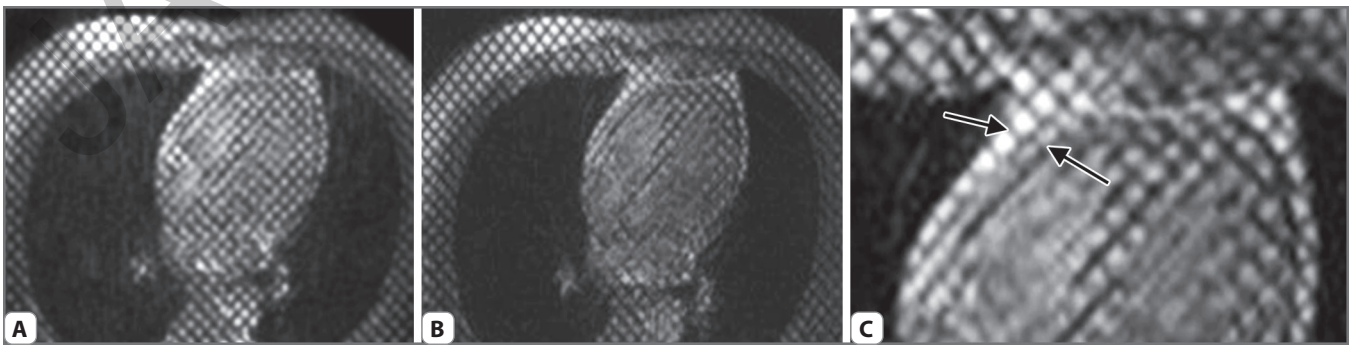

FIGS. 11A TO C: GRE tagging MRI in a healthy volunteer in axial plane. The continuity of the tags is lost during cardiac contraction because of shear motion between visceral and parietal layer of the pericardium [seen on the enlarged view (C)].

MAYEE BROTHERS

idiopathic. It is more often a sequel to purulent and tubercular pericarditis than viral amongst infectious causes.[30] In addition to diastolic dysfunction, there is ventricular interdependence where volume increase in one ventricle results in decrease in volume in the other ventricle.

Echocardiography is the initial modality used. However, if findings are equivocal, additional imaging may then be required using CT and MRI. Both morphological and functional hemodynamic aspects aid in the diagnosis. CT and MRI findings center on the demonstration of global or focal thickened or calcified pericardium which is usually greater over the right ventricle, along with secondary morphologic signs of constriction. These include a conical or tubular shape of the ventricles, compression of the right-sided cardiac chambers, sigmoid-shaped interventricular septum, enlargement of the atria, narrowing of the atrioventricular grooves and large inferior and superior vena cava in comparison with descending aorta[30-32] **(Fig. 12)**. The absence of pericardial thickening does not rule out pericardial constriction.

Delayed pericardial enhancement is usually seen owing to presence of fibrosis (>70 seconds postcontrast imaging). A small amount of pericardial effusion may also be seen. Calcification of the pericardium is better visualized on CT and strongly suggests constriction of tubercular etiology.[13] Other causes of pericardial calcification include viral, uremic pericarditis, collagen vascular disease, postoperative setting, radiation exposure and asbestosis. However, the presence of constriction and calcification are not always related. Atrial dilatation may or may not be seen depending on whether the entire pericardium is abnormal or just the anterior part. This is an insensitive finding as patients with restrictive cardiomyopathy may also demonstrate atrial dilatation. Pleural effusions, hepatic congestion, and ascites are the other non-specific findings. It should be remembered that the diagnosis of pericardial constriction is made only in the appropriate clinical setting.[33,34]

Since the diagnosis of constriction is ultimately that of altered physiology, cine imaging is a more direct means of confirming the diagnosis. The most sensitive and specific

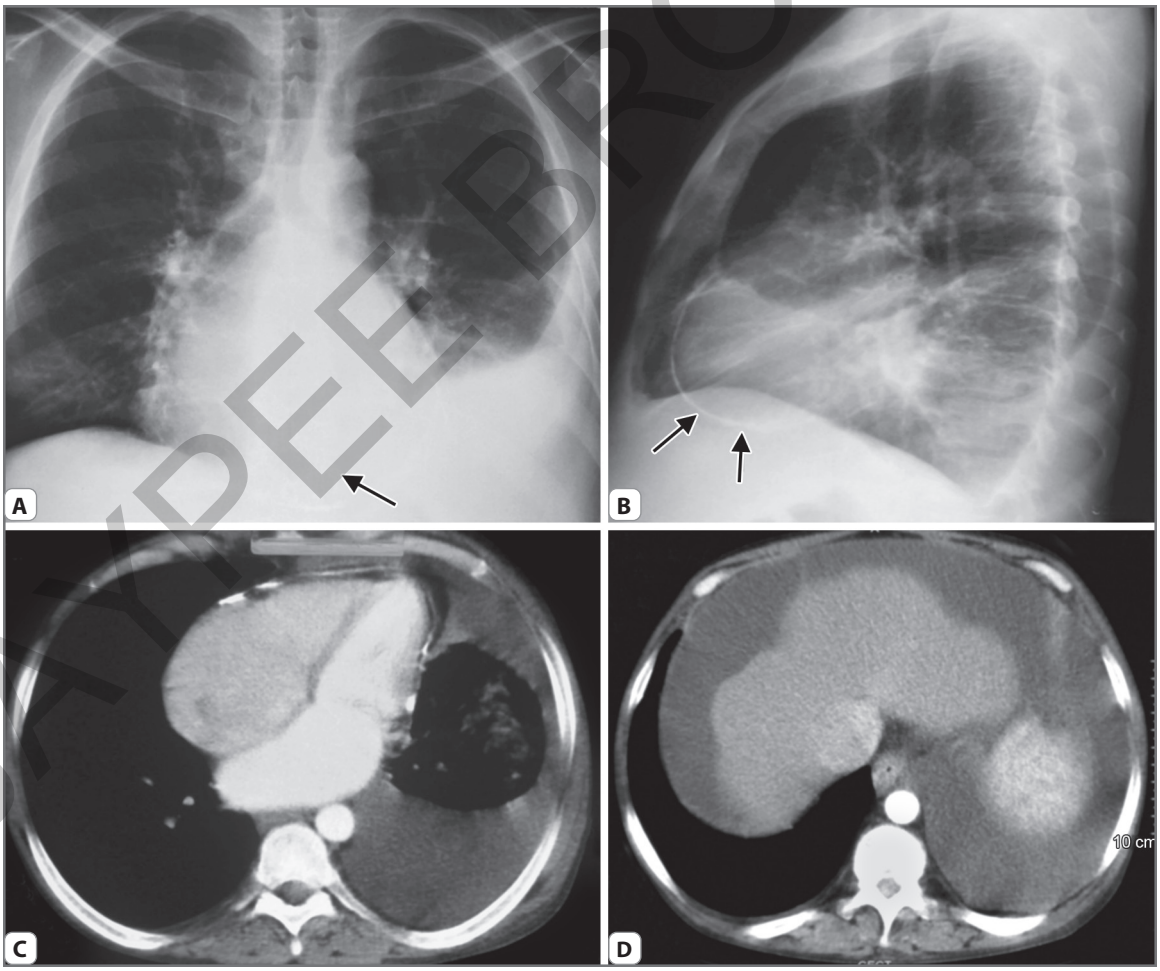

FIGS. 12A TO D: Calcific constrictive pericarditis. In a patient with distant history of tuberculosis, posteroanterior (A) and lateral (B) chest radiographs demonstrate curvilinear calcification (arrows) along the lower left and diaphragmatic cardiac border; (C and D) Axial CECT shows global pericardial thickening with calcification. The ventricles are tubular shaped with dilated atria and IVC. Associated left pleural effusion and ascites noted. Liver appears congested with irregular outline suggestive of cardiac cirrhosis.

JAYPEE BROTHERS

finding is the septal bounce, seen on retrospectively gated cine MRI or cardiac CT angiography. In early diastole, the pressure in the right ventricle is transiently higher than the left, causing the septum to bow leftward due to ventricular interdependence **(Fig. 13)**. When the left ventricular pressure once again becomes higher, it pushes the septum rightward; the result is shivering of the ventricular septum or septal bounce.[1] Although septal bounce may be seen in other conditions, it is highly pronounced in constrictive pericarditis.

Septal bounce is most pronounced during inspiration, as the negative intrathoracic pressure results in more rapid right heart filling than the left. On expiration, there is increased pulmonary venous return as the intrathoracic pressure increases, septum appears relatively normal. Respiratory variations of the diastolic septal bounce can be assessed using non-gated free breathing on MRI. This technique aids in differentiating constrictive pericarditis from restrictive cardiomyopathy.[4,33-35]

Underlying myocardium also needs to be evaluated in cases of constrictive pericarditis as the presence of the myocardial factor (myocardial atrophy or fibrosis) is a contraindication to pericardiectomy, because of the risk of acute dilatation or rupture of one or both cardiac chambers following surgery.[28] Imaging also aids in planning surgery. The presence of a fat plane between the myocardium and pericardium indicates easier dissection.[36]

There are atypical forms of constrictive pericarditis. *Effusive constrictive pericarditis* is a rare variant that represents a combination of pericardial tamponade and constrictive pericarditis. Large pericardial effusion is seen along with features of noncompliant pericardium. This is seen most often following radiation therapy. The typical clinical setting is that pericardial effusion is identified in a patient with symptoms of heart failure and despite drainage of the effusion, the patient continues to have abnormal pericardial dynamics. *Transient or inflammatory constrictive pericarditis* results often secondary to viral insult which may result in transient constrictive physiology.[16] There is accompanying active inflammation of the pericardium. Increased T2 signal with prominent late gadolinium enhancement suggests actively inflamed pericardium. Normal T2 signal with increased late gadolinium enhancement is suggestive of subacute form while normal T2 signal and no late gadolinium enhancement represents chronic phase.

Focal pericarditis may result in constriction if present in strategic location. *Occult constrictive pericarditis* refers to presence of constriction only when there is volume overload and not on routine examination **(Fig. 13)**.

PNEUMOPERICARDIUM

Pneumopericardium may result from blunt or penetrating trauma. Other rarer causes may be infectious pericarditis or from a gastrointestinal fistula, increased intrathoracic pressure as in asthma or barotrauma in intubated patients, with adjacent lung infection/cancer, esophageal rupture, cocaine abuse or liver abscess rupture. Pneumopericardium following pneumothorax or pneumomediastinum usually indicates a disruption of the pericardium. On erect chest radiographs, it is seen as a radiolucent band around the heart ("halo sign") limited superiorly by the pericardial reflection at the root of great vessels **(Fig. 14)**. Air may be seen in the transverse pericardial sinus giving the "transverse band of air" sign. Lateral radiographs may show lucency of air behind the sternum and anterior to the base of heart and root of aorta ("triangle of air" sign).[37,38] In the setting of penetrating trauma, the presence of pneumopericardium should prompt investigation for potential cardiac laceration. Rarely, tension pneumopericardium may result in tamponade. This may be seen as a progressively decreasing cardiothoracic ratio. CT shows distension of SVC, IVC, hepatic veins, renal veins and periportal lymphedema.

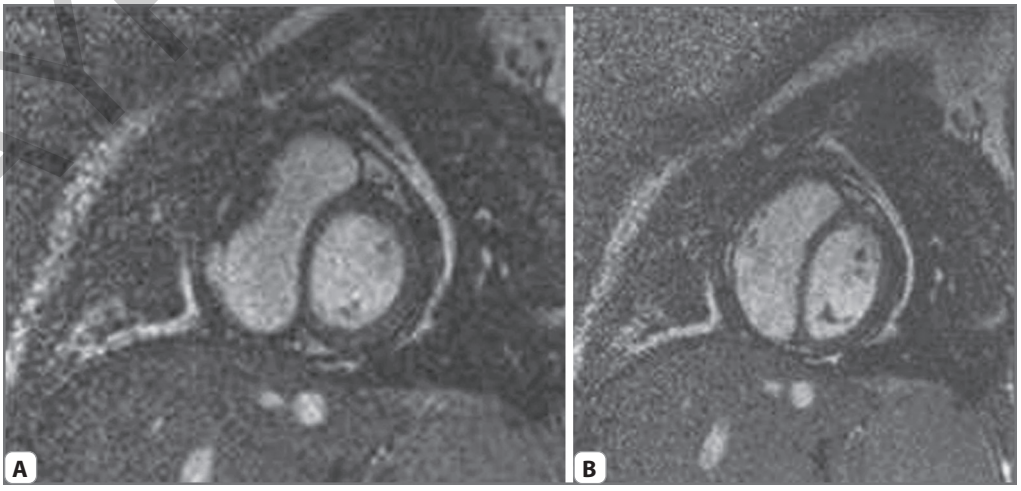

FIGS. 13A AND B: Short axis cine MR images in a patient with constrictive pericarditis in systole (A) and diastole (B) show straightening of the interventricular septum in diastole indicative of impaired right ventricular filling. Pericardium is focally thickened posterior to the left ventricle.

JAYPEE BROTHERS

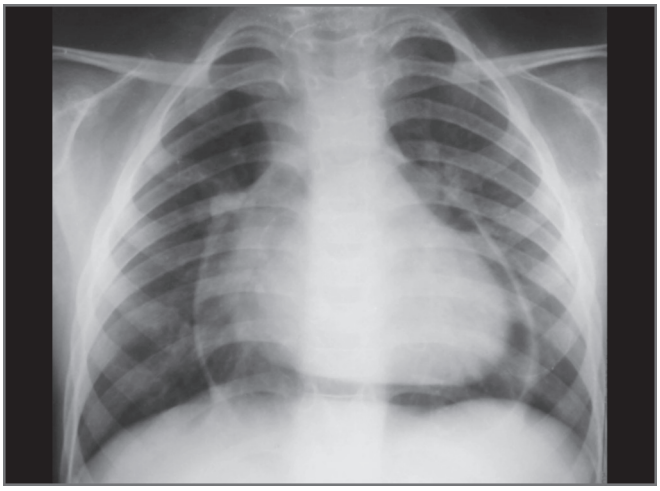

FIG. 14: Pneumopericardium. Posteroanterior chest radiograph shows radiolucent band of air surrounding the heart giving the "halo sign".

BOX 7: Pericardial metastases.

- Metastases are commoner than primary pericardial tumors
- *Mode of spread to pericardium*:
  - Direct spread
  - Lymphatic
  - Hematogenous
  - Transvenous
- *Imaging findings include*:
  - Pericardial effusion
  - Pericardial thickening
  - Pericardial mass
- Hemorrhagic pericardial effusion adjacent to a lung/mediastinal mass is suggestive of pericardial invasion

PERICARDIAL TUMORS

Metastases (Box 7)

Metastases to the pericardium are more common than involvement of pericardium by primary tumors.

Metastases to the heart and pericardium have been reported at autopsy in 10–12% of patients with known primary malignancies.[4,11] Pericardial metastases may result from contiguous spread from lung or mediastinum. Other modes may be lymphatic, hematogenous or transvenous route. The common sources of pericardial metastases are lung and breast cancer. Leukemias, lymphomas and melanomas are the other malignancies that can spread to the pericardium. Pericardial metastases when seen are a negative prognostic factor.

An effusion is the most common manifestation of metastatic pericardial disease. Pericardium can get irregularly thickened, and nodularity or tumor deposits may be seen. To distinguish between inflammatory etiology and metastases (when effusion and thickening are the only findings), follow-up may be required. With metastatic involvement, pericardium may be diffusely involved encasing the heart or there may be enhancement of portions of pericardium. Direct pericardial invasion may be suggested when the pericardial line is not seen between the adjacent primary mass and the pericardium and there is pericardial effusion. However, pericardium may remain intact adjacent to a primary lung mass. In these cases, hemorrhagic effusion, seen as high-signal on spin echo MR images confirms the extension of the mass to the pericardium **(Figs. 15A and B)**.[39] On MRI, most deposits show low-signal on T1 and high-signal on T2-weighted images. Metastatic melanoma is an exception; high-signal intensity on T1-weighted images is virtually pathognomonic of this diagnosis. The malignant tumor usually enhances significantly after the administration of contrast material. In a patient with a known primary tumor and pericardial effusion, other differential diagnoses are drug-induced and radiation-induced effusions.

Primary Pericardial Tumors

Primary pericardial tumors are rare and are more likely to be malignant than primary cardiac tumors. Pericardial tumors include benign tumors (lipoma, benign teratoma, fibroma, and hemangioma) and malignant tumors (mesothelioma, lymphoma, sarcoma and liposarcoma, malignant teratoma). Although pericardial mesotheliomas are rare tumors accounting for less than 1% of all malignant mesotheliomas, they account for nearly half of primary pericardial tumors.[39]

Chest radiography in patients with pericardial mesothelioma typically demonstrates cardiac enlargement, evidence of pericardial effusion, an irregular cardiac contour or diffuse mediastinal enlargement. In the early stage of disease, CT and MR may only show pericardial thickening and complex effusion which can mimic chronic pericarditis. Later in the disease, enhancing masses may be seen. Pericardial mesothelioma carries a very poor prognosis.

Lymphoma and sarcoma typically present with large masses accompanied by effusion. Most lymphomas occur secondary to systemic disease. Primary pericardial lymphoma may also be encountered, presenting as diffuse infiltration or a solitary mass. Rarely, there may be effusion without soft tissue mass in primary effusion lymphoma.

Most intrapericardial germ cell tumors are benign tumors, although malignant teratomas may be encountered in the pediatric population as a heterogeneous mass.

Histopathology is usually necessary to achieve a definitive diagnosis of most pericardial tumors. The diagnosis of few tumors can be aided by specific signal and attenuation characteristics. Lipoma has low attenuation on CT images and high signal intensity on T1-weighted SE images. Presence of calcium or fat in a pericardial mass on CT suggests the diagnosis of a teratoma. Fibroma characteristically has low signal intensity on T2-weighted images with poor enhancement characteristics.[40,41]

Other entities that may simulate a pericardial mass are pericardial hematoma, lymphatic malformation, coronary artery aneurysm and pericardial gossypiboma.[5,19] The signal

JAYPEE BROTHERS

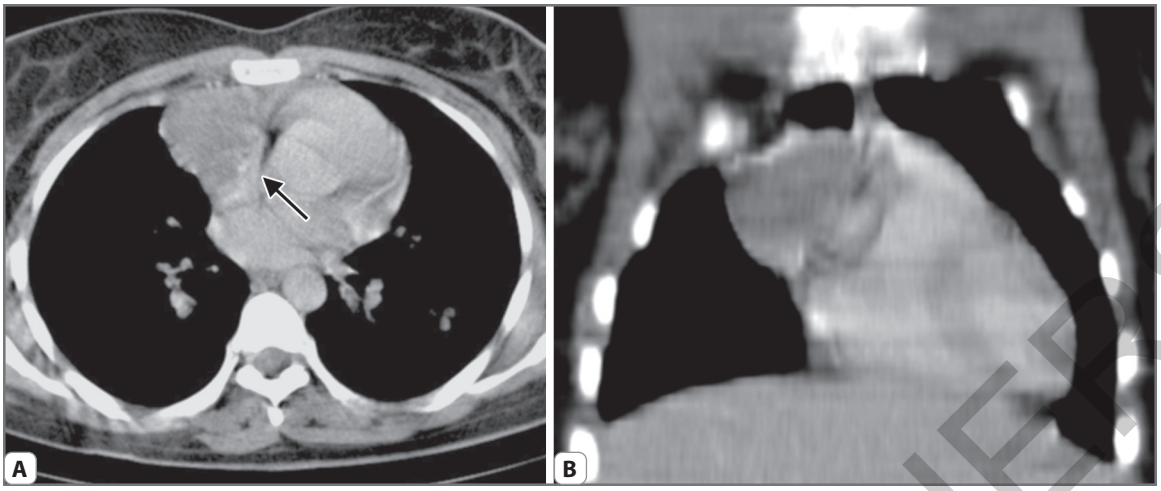

FIGS. 15A AND B: Axial CECT (A) and coronal reformation (arrow); (B) shows thymic carcinoma with direct invasion of the pericardium.

characteristics of pericardial hematoma are age related. Lymphatic malformation is seen as a nonenhancing fluid attenuation serpiginous lesion with internal septations (septations are usually absent in a pericardial cyst). There is no surrounding invasion. A coronary artery aneurysm should be suspected when a smooth enhancing mass is seen along the expected course of a coronary artery. Pericardial gossypiboma should be considered in a patient with previous cardiac surgery.

CONCLUSION

Congenital disease, infection, injury, neoplasm may all affect the pericardium. Although echocardiography is often initially used to evaluate the pericardium, CT and MR are useful for further evaluation of the disease processes. Integrated role of multiple imaging modalities helps establish the diagnosis in the appropriate clinical setting and facilitates management decisions.

REFERENCES

1. Fadl SA, Nasrullah A, Harris A, Edwards R, Kicska G. Comprehensive review of pericardial diseases using different imaging modalities. Int J Cardiovasc Imaging. 2020;36(5):947-69.
2. Gulati G, Sharma S, Kothari SS, et al. Comparison of echo and MRI in the imaging evaluation of intracardiac masses. Cardiovasc Intervent Radiol. 2004;27(5):459-69.
3. Grizzard JG, Ang GB. Magnetic resonance imaging of pericardial disease and cardiac masses. Magn Reson Imaging Clin N Am. 2007;15:579-607.
4. Ünal E, Karcaaltincaba M, Akpinar E, Ariyurek OM. The imaging appearances of various pericardial disorders. Insights Imaging. 2019;10(1):42.
5. Misselt AJ, Harris SR, Glockner J, Feng D, Syed IS, Araoz PA. MR imaging of the pericardium. Magn Reson Imaging Clin N Am. 2008;16:185-99.
6. Budoff MJ, Achenbach S, Blumenthal RS, et al. Assessment of coronary artery disease by cardiac computed tomography: A scientific statement from the American Heart Association Committee on Cardiovascular Imaging and Intervention, Council on Cardiovascular Radiology and Intervention, and Committee on Cardiac Imaging, Council on Clinical Cardiology. Circulation. 2006;114(16):1761-91.
7. Coles DR, Smail MA, Negus IS, et al. Comparison of radiation doses from multislice computed tomography coronary angiography and conventional diagnostic angiography. J Am Coll Cardiol. 2006;47(9):1840-5.
8. Wang ZJ, Reddy GP, Gotway MB, Yeh BM, Hetts SW, Higgins CB. CT and MR imaging of pericardial disease. Radiographics. 2003;23:S167-80.
9. Adler Y, Charron P, Imazio M, Badano L, Barón-Esquivias G, Bogaert J, et al. 2015 ESC Guidelines for the diagnosis and management of pericardial diseases: The Task Force for the Diagnosis and Management of Pericardial Diseases of the European Society of Cardiology (ESC) Endorsed by: The European Association for Cardio-Thoracic Surgery (EACTS). Eur Heart J. 2015;36(42):2921-64.
10. Klein AL, Abbara S, Agler DA, Appleton CP, Asher CR, Hoit B, et al. American Society of Echocardiography clinical recommendations for multimodality cardiovascular imaging of patients with pericardial disease: endorsed by the Society for Cardiovascular Magnetic Resonance and Society of Cardiovascular Computed Tomography. J Am Soc Echocardiogr. 2013;26(9):965-1012.
11. Rajiah P, Canan A, Saboo SS, Restrepo CS, Bolen MA. MRI of the Pericardium. Radiographics. 2019;39(7):1921-2.
12. Lopez Costa I, Bhalla S. Computed tomography and magnetic resonance imaging of the pericardium. Semin Roentgenol. 2008;43(3):234-45.
13. Truong MT, Erasmus JJ, Gladish GW, Sabloff BS, Marom EM, et al. Anatomy of pericardial recesses on multidetector CT: Implications for oncologic imaging. AJR Am J Roentgenol. 2003;181:1109-13.

JAYPEE BROTHERS

14. Delille JP, Hernigou A, Sene V, et al. Maximal thickness of the normal human pericardium assessed by electron-beam computed tomography. Eur J Radiol. 1999;9:1183-89.
15. Oyama N, Oyama N, Komuro K, Nambu T, Manning W, Miyasaka K. Computed tomography and magnetic resonance imaging of the pericardium: anatomy and pathology. Magnetic Resonance in Medical Sciences. 2004;3(3):145-52.
16. Chetrit M, Xu B, Verma BR, Klein AL. Multimodality Imaging for the Assessment of Pericardial Diseases. Curr Cardiol Rep. 2019;21(5):41.
17. Kligerman S. Imaging of Pericardial Disease. Radiol Clin North Am. 2019;57(1):179-99.
18. Broderick LS, Brooks GN, Kuhlman JE. Anatomic pitfalls of the heart and pericardium. Radiographics. 2005;25:441-53.
19. Bogaert J, Francone M. Cardiovascular Magnetic resonance in pericardial diseases. J Cardiovasc Magn Reson. 2009;11(1):14.
20. O' Leary SM, Williams PL, Williams MP. et al. Imaging the pericardium: appearances on ECG – gated 64 detector row cardiac computed tomography. BJR. 2010;83:194-205.
21. Van Son JA, Danielson GK, Schaff HV, et al. Congenital partial and complete absence of the pericardium. Mayo Clin Proc. 1993;68(8):743-47.
22. Ellis K, Leeds NE, Himmelstein A. Congenital deficiencies in partial pericardium: Review with two new cases including successful diagnosis by plain roentgenography. AJR Am J Roentgenol. 1959;82:125-37.
23. Psychidis-Papakyritsis P, de Roos A, Kroft LJM. Functional MRI of congenital absence of the pericardium. Am J Roentgenol. 2007;189:W312-4.
24. Rajiah P. Cardiac MRI: Part 2, Pericardial disease. AJR. 2011;197:W621-34.
25. Czum Jm, Silas AM, Althoen MC. Evaluation of the pericardium with CT and MR. ISRN cardiology 2014 :2014:174908.
26. Glockner JF. Imaging of pericardial disease. Magn Reson Imaging Clin N Am. 2003;11(1):149-62, vii.
27. Yared K, Baggish AL, Picard MH, Hoffmann U, Hang J. Multimodality imaging of pericardial disease. JACC Cardiovasc Imaging. 2010;3(6):650-60.
28. Rienmuller R, Groll R, Lipton MJ. CT and MR imaging of pericardial disease. Radiol Clin North Am. 2004;42(3):587-601.
29. Kim JS, Kim HH, Yoon Y. Imaging of pericardial diseases. Clinical Radiol. 2007;62:626-31.
30. Imazio M, Brucato A, Maestroni S, et al. Risk of constrictive pericarditis after acute pericardiectomy. Circulation. 2011;124(11):1270-5.
31. Suh SY, Rha SW, Kim JW, et al. The usefulness of three-dimensional multidetector computed tomography to delineate pericardial calcification in constrictive pericarditis. Int J Cardiol. 2006;113:414-16.
32. Bogaert J, Francone M. Pericardial disease: Value of CT and MR imaging. Radiology. 2012;267(2):340-56.
33. Thavendiranathan P, Verhaert D, Wall MC, et al. Simultaneous right and left heart realtime, free-breathing CMR flow quantification indentifies constrictive physiology. JACC Cardiovasc Imaging. 2012;(1):15-24.
34. Verheart D, Gabriel RS, Johnston D, Lytle BW, Desai, MY Klein AL. The role of multimodality imaging in the management of pericardial disease. Circ Cardiovasc Imaging. 2010;3(3): 333-43.
35. Francone M, Dymarkowski S, Kalantzi M, et al. Realtime cine MRI of ventricular septal motion: A novel approach to assess ventricular coupling. J Magn Reson Imaging. 2005;21(3): 305-9.
36. Westwood MA, Moon JC. Cardiovascular magnetic resonance for pericardial disease. Indian J Radiol Imaging. 2007;17(2):133-6.
37. Ho ML, Gutierrez FR. Chest radiography in thoracic polytrauma. AJR Am J Roentgenol. 2009;192:599-612.
38. Mirvis SE. Imaging of acute thoarcic injury: The advent of MDCT screening. Semin Ultrasound CT MRI. 2005;26:305-31.
39. Grebenc ML, Christenson MLR, Burke AP, et al. Primary cardiac and pericardial neoplasms: radiologic-pathologic correlation. Radiographics. 2000;20:1073.
40. Fussen S, De Boeck BW, Zellweger MJ, et al. Cardiovascular magnetic resonance imaging for diagnosis and clinical management of suspected cardiac masses and tumours. Eur Heart J. 2011;32(12):1551-60.
41. Hoffmann U, Globits S, Frank H. Cardiac and paracardiac masses: Current opinion on diagnostic evaluation by magnetic resonance imaging. Eur Heart J. 1998;19:553-63.

JAYPEE BROTHERS

for detailed information on radiology books, visit our website www.jaypeebrothers.com, for detailed information on radiology books, visit our website www.jaypeebrothers.com, for de

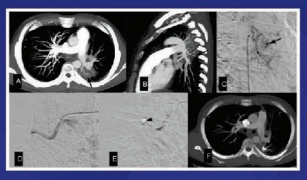

AIIMS-MAMC-PGI IMAGING SERIES

DIAGNOSTIC RADIOLOGY

Chest and Cardiovascular Imaging

In 1996, a pioneering collaboration between the faculty of Radiodiagnosis at AIIMS (New Delhi), MAMC (New Delhi), and PGI (Chandigarh) led to the creation of an innovative continuing medical education (CME) program. This initiative introduced a structured series of imaging courses, accompanied by a comprehensive textbook covering all organ systems. The objective was twofold: To provide cutting-edge knowledge to postgraduate students and practicing radiologists, and to establish a standardized teaching framework in radiology across India.

The first series of seven imaging courses concluded successfully in 2000, setting the stage for subsequent editions. The second series (2002–2005), third series (2008–2013), and fourth series (completed in 2020) continued this tradition, each evolving to reflect advancements in the field. These programs have been instrumental in shaping radiology education, with the accompanying textbooks garnering widespread acclaim, particularly among postgraduate students.

The rapid technological progress and emerging trends in medical imaging have necessitated the launch of a fifth series and a comprehensive revision of its corresponding textbook. This volume, dedicated to Chest and Cardiovascular Imaging, presents an in-depth exploration of the subject through 33 Chapters which have been meticulously written and compiled.

Key enhancements in this edition include: A renewed focus on chest radiograph interpretation, reviving the art of analyzing fundamental imaging findings; expanded coverage of interstitial lung disease, incorporating the latest diagnostic approaches; emphasis on image-guided interventions, reflecting their growing role in contemporary radiology; and integration of tables, flowcharts, and structured formats to facilitate quick reference and streamlined learning.

More than just a supplement to the imaging courses, this book serves as a valuable resource for radiologists in training, a practical reference for practicing radiologists, and an insightful guide for clinicians. We hope it continues to inspire and enhance radiology education, contributing to excellence in patient care.



Gaurav Shanker Pradhan
MAMC, New Delhi



Raju Sharma
AIIMS, New Delhi



Paramjeet Singh
PGI, Chandigarh

Printed in India

Available at all medical bookstores or buy online at www.ejaypee.com

JAYPEE BROTHERS
Medical Publishers (P) Ltd.
EMCA House, 23/23-B, Ansari Road,
Daryaganj, New Delhi - 110 002, INDIA
www.jaypeebrothers.com

Join us on facebook.com/JaypeeMedicalPublishers
Follow us on instagram.com/JaypeeMedicalPublishers

Shelving Recommendation
RADIOLOGY

ISBN 978-93-6616-667-4