brothers.com, for detailed information on orthopedics books, visit our website www.jaypeebrothers.com, for detailed information on orthopedics bo


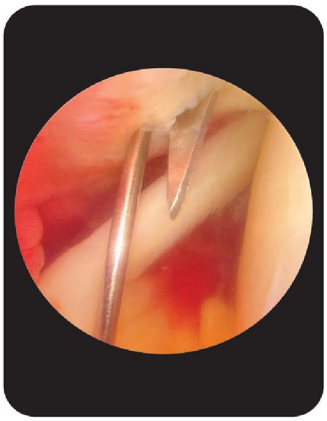


Handbook of Arthroscopy

Editors
Sachin Yashwant Kale
Rohit Mahesh Sane

Foreword
Nicholas Antao

Co-Editors
Prasad Chaudhari
Bhushan Patil
Sandeep Deore
Pramod Bhor
Aditya Gunjotikar
Vaibhav Koli
Rahul Davari

JAYPEE

Contents

1. **Introduction to Arthroscopy** 1
   Rohit Mahesh Sane, Sachin Yashwant Kale, Arvind J Vatkar, Shivam Mehra

2. **Knee Positioning, Draping, and Portals** 11
   Aditya R Gunjotikar, Vaibhav J Koli, Sachin Yashwant Kale, Prakash D Samant

3. **Grafts** 23
   Sandeep Narayan Deore, Rohit Mahesh Sane, Shikhar D Singh, Sanjay B Dhar, Sachin Yashwant Kale

4. **Diagnostic Round (Knee), Indications, and Contraindications** 37
   Vaibhav J Koli, Vishal Kumar, Sachin Yashwant Kale, Rohit Mahesh Sane

5. **Anterior Cruciate Ligament** 45
   Aditya R Gunjotikar, Rohit Mahesh Sane, Prasad Liladhar Chaudhari, Gaurav Kanade

6. **Meniscus** 58
   Bhushan Jaywantrao Patil, Sandeep Narayan Deore, Prasad Liladhar Chaudhari, Sushmit Singh

7. **Posterior Cruciate Ligament** 69
   Bhushan Jaywantrao Patil, Sandeep Narayan Deore, Sachin Yashwant Kale, Pramod Bhor

8. **Shoulder Positioning, Draping, and Portals** 75
   Pramod Bhor, Rahul V Davari, Sachin Yashwant Kale, Rohit Mahesh Sane

9. **Diagnostic Round (Shoulder), Indications and Complications** 87
   Prasad Liladhar Chaudhari, Rohit Mahesh Sane, Sandeep Narayan Deore, Sachin Yashwant Kale

10. **Rotator Cuff** 92
    Sandeep Narayan Deore, Pramod Bhor, Sunil H Shetty, Sachin Yashwant Kale

11. **Anterior Instability** 104
    Vaibhav J Koli, Aditya R Gunjotikar, Rohit Mahesh Sane, Shivam Mehra

12. Frozen Shoulder **126**
Sachin Yashwant Kale, Anup Krishnan, Arvind J Vatkar, Aditya R Gunjotikar, Vishal Kumar

13. The Psychology of an Arthroscopy Surgeon **132**
Bhushan Jaywantrao Patil, Anup Krishnan, Sachin Yashwant Kale, Pramod Bhor, Sachiti Sachin Kale

14. Rehabilitation in Knee Ligament Arthroscopic Surgeries **139**
Sagar Subhash Deshpande, Prerna Pradeep Ghodke, Sachin Yashwant Kale

15. Rehabilitation in Arthroscopic Rotator Cuff Repair and Capsular Release in Frozen Shoulder **150**
Sagar Subhash Deshpande, Prerna Pradeep Ghodke, Sachin Yashwant Kale

Author Publications **165**

Index **167**

CHAPTER 3

Grafts

Sandeep Narayan Deore, Rohit Mahesh Sane, Shikhar D Singh, Sanjay B Dhar, Sachin Yashwant Kale

JAYPEE BROTHERS

INTRODUCTION

Several graft options are available—patellar tendon (the central one-third with attached bone plugs), semitendinosus tendon (ST tendon), ST and gracilis tendons, quadriceps tendon, and peroneus longus tendon (PL tendon).

Graft remodeling is time-consuming but well researched. The success of an anterior cruciate ligament (ACL) reconstruction depends critically on the biological remodeling of the graft, which basically can be described as a "free-grafted avascular connective tissue structure." Initially, the graft becomes partially necrotic before undergoing a remodeling process that resembles the stages of wound healing. It is reasonable to assume, therefore, that a graft in the human knee significantly alters its mechanical properties and histologic structure within a short period of time. It remains unclear whether this tissue structure becomes increasingly "ligamentous" and approaches the normal histologic structure of the ACL.

Patellar Tendon (Bone-tendon-bone)

One of the most widely used graft for ACL reconstruction is the central one-third of the patellar tendon **(Fig. 1)**. This graft includes bone plugs from the patella



FIG. 1: Bone-patellar tendon-bone graft.

and tibial tuberosity to provide a very stable primary fixation that allows for early motion and weight bearing (modulus of elasticity—225 MPa).

Surgical Technique

Anterior paramedial incision is taken between patella and tibial tuberosity. Subcutaneous plane is created for rotating window. Patellar tendon is identified.

Paratenon is incised in the midline to expose the tendon. Central third of patellar tendon along with patellar and tibial bone plug is marked with skin marker. Central third patellar tendon is incised full thickness extending to bony attachments. Patellar bone plug (size 10 mm by 7 mm) is harvested with help of 5-mm saw blade to the depth of 7 mm in triangular fashion to avoid patellar fracture. After dissecting central patellar tendon, tibial bone plug (size 20 by 10 mm) is harvested with 5-mm saw blade. In each bone plug, two drill holes are made for passage of ultra braid or fiber wires. Average length of the harvested graft varies between 70 and 90 mm. The extra bone removed from the bone plugs is filled in the donor site and remaining tendon is sutured tightly to avoid fluid extravasation.

Advantages

- Variable graft width. Normally a sufficiently wide patellar tendon is available for graft harvest. The usual graft width is 8–10 mm.
- *Availability*: The patellar tendon is always available and shows little anatomic variation. This permits a constant and technically simple harvesting technique.
- *Bone to bone healing and strong primary fixation*: The bone plugs allow for strong primary fixation of the graft. This method provides high primary stability.
- *Preservation of active internal rotation*: Because the tendons responsible for internal rotation of the knee are not violated, harvesting the graft does not compromise internal rotation.
- *Weakening the antagonist*: The quadriceps femoris muscle is the strongest antagonist of the ACL, and so weakening of the muscle during the graft healing period is considered beneficial.

Disadvantages

Donor site morbidity includes several problem areas:

- *Bony defects*: Because a longitudinal strip is harvested from the patellar tendon along with bone blocks from the patella and tibial tuberosity, a palpable bone defect and fat pad herniation during knee flexion can be felt in skinny patients giving cosmetic concerns. This can be avoided by cancellous bone grafting in the defects and proper repair of paratenon.
- *Compromise of the extensor apparatus*: A quadriceps deficit of approximately 15% persists for up to 1 year. This is particularly disabling to athletes who rely on an intact extensor apparatus (skiers, basketball players, and volleyball players). A well-structured supervised physiotherapy is required to strengthen extensor mechanism.

JAYPEE BROTHERS

- *Anterior knee pain*: There are multiple reasons for anterior knee pain—retropatellar crepitus in patients with preexisting patellofemoral cartilage disease, scarring of the infrapatellar fat pad, scar tissue in the donor defect, and patellar apex syndrome. This may lead to difficulty in kneeling down. This can be prevented by timely mobilization on the knee and local physical therapy to prevent scar formation. Scarring of skin to underlying tibial tuberosity and patellar apex can lead to limitation of knee flexion. This can be prevented by taking paramedian or oblique skin incision.
- *Risk of patellar fracture*: A longitudinal or transverse fracture of the patella may occur when the patellar bone block is harvested. If a large bone block is removed, the patella may be fractured weeks or months later by a trivial trauma.
- *Injury to the pes anserinus*: If the bone-tendon-bone (BTB) graft is long, the bone plug must either be placed high in the femoral tunnel or, if the femoral end of the graft is fixed with an interference screw on the articular side, the tibial tunnel must be started at a very low level. This may cause injury to the pes anserinus complex. If a revision is necessary, the ST tendon may be unsuitable for use or very difficult to dissect and harvest.
- *Risk of cyclops syndrome*: The volume of the graft increases during remodeling, and scar tissue forming anterior to the distal attachment site can create a mechanical block to extension (cyclops syndrome).

Contraindications to the Bone-tendon-bone Technique

These are previous surgery on the patellar tendon, Osgood–Schlatter disease, patella baja, significant patellofemoral osteoarthritis, and prior ACL reconstruction of the opposite knee using the BTB technique.

Hamstrings: Semitendinosus and Gracilis Tendon

Semitendinosus is one other commonly used graft.

Given the disadvantages of the BTB technique listed above, the ST tendon is becoming increasingly popular as an alternative graft material for ACL reconstruction.

Advantages

- *Small incision*: The ST tendon can be harvested through an incision only about 3 cm long.
- *No compromise of the extensor apparatus*: The quadriceps muscle, patellar tendon, and tibial tuberosity remain intact.
- No incidence of anterior knee pain as found in BTB
- *Favorable elastic modulus*: The three- or four-strand ST tendon graft has an elastic modulus similar to that of the normal ACL (modulus of elasticity—145 MPa, native—120 MPa).
- *Less risk of cyclops syndrome*: Less scar formation occurs during graft remodeling than in the BTB technique.

JAYPEE BROTHERS

Disadvantages

- *Posterior thigh ecchymosis* due to hematoma at the donor site.
- *Weakening of the agonist*: The ST muscle is an important part of the hamstring group, which is the principal agonist of the ACL.
- *Injury to saphenous nerve* leading to hypoesthesia over anterolateral border of the leg. Oblique incision is preferable to avoid this complication.
- Prior surgery around proximal tibia with metallic implants may make it difficult to find the anatomical landmarks for tendon harvesting.
- Premature amputation of the ST due to incomplete release of the fibrous bands. Chubby patients may have smaller tendons.

Surgical Technique

Incision: Three finger width below the joint line and medial to the tibial tuberosity. Anatomy of pes anserinus is such that round-shaped gracilis and flat ST are covered by a curtain of sartorius. Finger can be rolled over round gracilis tendon as an identification landmark **(Figs. 2 and 3)**.

There are two methods to approach the hamstrings. In the first method, horizontal incision is taken between rounded gracilis and flat ST so that either of them can be harvested depending upon the need. In the second method, a reverse "L" incision is taken with horizontal limb at upper border of gracilis and vertical limb cutting the attachments of ST and gracilis so that both tendons are detached from insertion **(Figs. 4 to 6)**.

Care must be taken not to injure medial collateral ligament just beneath the pes anserinus.

Mixter forceps is used to lift up the ST. Ethibond is rolled around the tendon.

The tibial attachment is cut parallel to the fibers to include periosteum. ST is pulled to expose the vincula connecting to the medial gastrocnemius. Care is taken to cut all bands connecting the two structures. Saphenous nerve need to be protected **(Fig. 7)**.

JAYPEE BROTHERS

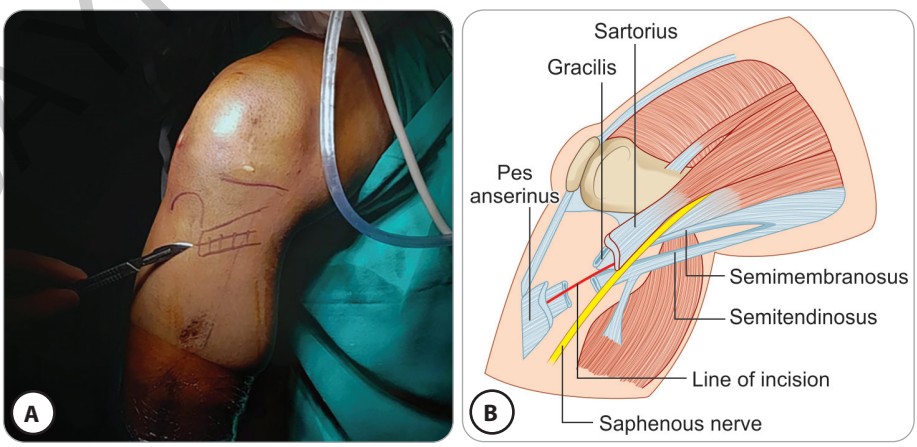

FIGS. 2A AND B: Surface anatomy and skin marking.



FIG. 3: Split between gracilis and semitendinosus.



FIG. 4: Isolation of tendinosis and gracilis.



FIG. 5: Isolation of semitendinosus with fibrous band connecting to gastrocnemius.

JAYPEE BROTHERS



FIG. 6: Medial collateral ligament below pes anserinus to be protected.



FIG. 7: Instruments required for graft harvesting.

A close-ended tendon stripper is passed around the ST to strip the tendon off the muscle fibers. Average length we obtain is between 270 and 300 mm. Open-ended tendon stripper can be used if tibial attachment is to be kept intact in procedures like medial collateral ligament reconstruction.

Similar procedure is repeated for gracilis tendon. The second method to harvest the tendons is through an "L"-shaped incision starting from the superior border of gracilis to the vertical tibial crest where both the tendons are attached. With the help of blunt periosteum, the muscles fibers are stripped off the tendon. Depending upon the length, the graft is a folded on itself over fiber–wire loop three to four times, the aim being diameter greater than 8 mm. The graft is mounted on the adjustable or fixed loop and button, and kept for pretensioning on the graft board, covered by a vancomycin-soaked sterile gauze piece **(Figs. 8 and 9)**.

If the ST tendon is very thin or very short (< 24 cm), the gracilis tendon can be harvested to make a combined graft.

JAYPEE BROTHERS

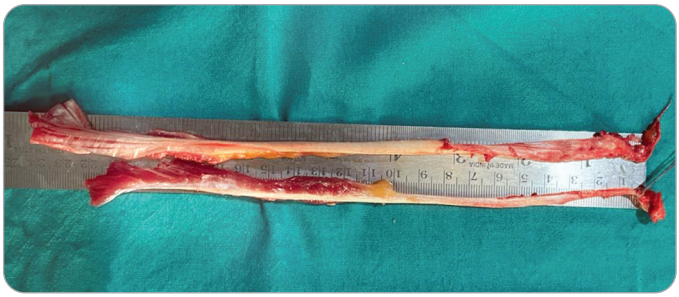

FIG. 8: Harvested tendon graft.

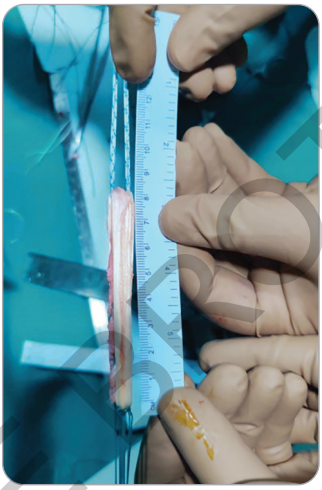

FIG. 9: Measurement of graft length.

Quadriceps Tendon

Increasingly, the quadriceps tendon is being used for ACL and posterior cruciate ligament (PCL) reconstructions.

Surgical Procedure

A 3–4 cm suprapatellar midline vertical incision is taken. Subcutaneous plane is created to make a sliding window to increase work area. Paratenon is incised. Medial and lateral border of quadriceps tendon is identified. Central third tendon is incised at 8 mm depth keeping deep tendon intact. This central strip is extended vertically up to a length of 80 mm and cut. Distal part of the graft involves area up to periosteum over patella. We can also take 10 mm of patellar bone plug with the help of a saw. After harvesting the graft, remnant tendon is sutured together with No. 1 Vicryl in double layer to avoid saline seepage during arthroscopy **(Figs. 10 to 12)**.

Recently, minimally invasive methods of quadriceps harvesting are available which involve a cylindrical calibrated harvester and graft cutter at the end of the tube **(Fig. 13)**.

JAYPEE BROTHERS

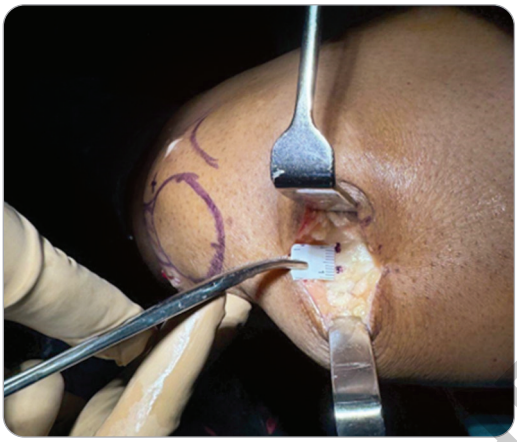

FIG. 10: 10-mm wide graft measured.

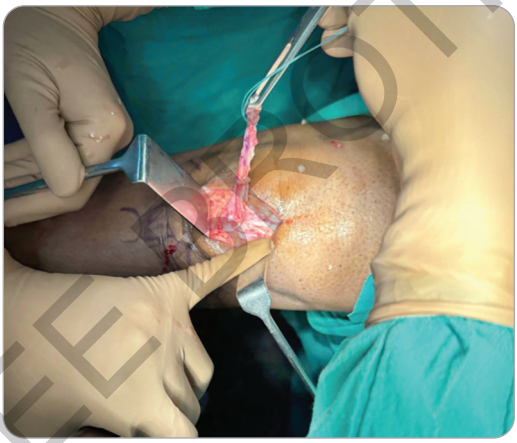

FIG. 11: Central third quadriceps tendon dissected.



FIG. 12: 75-mm graft harvested.

JAYPEE BROTHERS

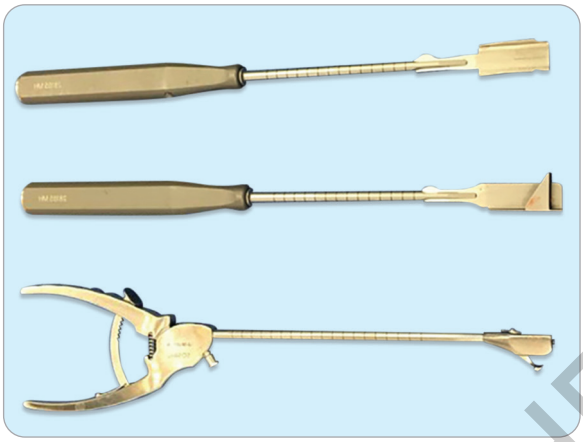

FIG. 13: Quadriceps tendon harvesting instruments.

Advantages

- *Larger cross-section of the graft*: The quadriceps tendon has the same width as the patellar tendon but a larger cross-sectional area with relatively better initial strength, and hence is preferred for procedures like PCL reconstruction.
- *Bony fixation*: The patellar bone block allows for bony fixation of the graft at the level of the joint space (e.g., in the femoral tunnel).
- *Less donor site morbidity*: Use of the quadriceps tendon is associated with less donor site morbidity than the patellar tendon.
- *Less irritation of patellofemoral joint*: Because the quadriceps tendon attaches to the base of the patella over a very broad area, and therefore, the patella is weakened on its broader side when the graft is harvested, there is less impact on the femoropatellar joint then when the central third of the patellar tendon (BTB technique) is used.

Disadvantages

- *Extra incision*: Because of its location, the graft must always be harvested through a separate skin incision.
- Quadriceps wasting and weakness is a potential complication and hence robust physiotherapy protocol is required.
- *Fluid outflow*: As roof of the suprapatellar pouch is opened, watertight repair of the quadriceps defect in two layers is required to prevent fluid outflow.

Peroneus Longus Graft

Peroneus longus is harvested from ankle region. This graft choice is considered as a spare graft for revision surgery and female patients with obesity and short stature.

JAYPEE BROTHERS

Advantages

- *Longer and thicker graft*—has comparable diameter and tensile strength to hamstring and quadriceps tendons, especially useful in revision surgeries.
- Does not interfere with knee function as donor site morbidity
- Minimal dissection as there are no bands connecting to other muscles unlike in the knee
- No weakness in ankle function
- Surgery on extra joint apart from the knee

Contraindications

- Flat foot
- Peroneal nerve injury
- Foot or ankle deformities

Surgical Procedure

With foot in international rotation, a 2-cm incision is taken on the lateral part of the ankle just behind the lateral malleolus. After achieving hemostasis, peroneal sheath is incised longitudinally **(Figs. 14 to 16)**. Care is taken to avoid injury to sural nerve which lies posteriorly. More superficial PL tendon is isolated and tagged with Ethibond No. 5. With foot in everted position, tendon is cut distally. The remnant can be sutured to peroneus brevis or left alone. A tendon stripper is passed along the leg vertically with constant pull on the sutures to receive long and thick tendon. Care is taken to avoid injury to peroneal nerve. As per the need, PL tendon can be tripled or quadrupled as graft for ACL or PCL reconstruction **(Figs. 17 and 18)**.

Synthetic Materials

Various polymeric materials have been used for ACL reconstruction (Nylon, Dacron, Teflon, Trevira, and Gore-Tex). These prosthetic ligaments are specially woven and braided, depending on the manufacturer.



FIG. 14: Incision for peroneus longus tendon taken.

JAYPEE BROTHERS

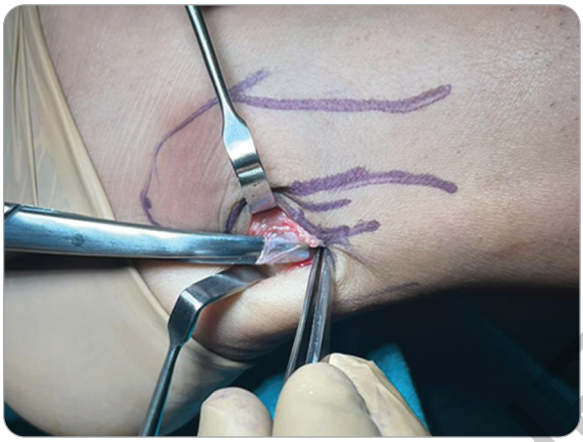

FIG. 15: Peroneus sheath incised longitudinally.



FIG. 16: Peroneus longus and peroneus brevis isolated.



FIG. 17: Harvesting the tendon.

JAYPEE BROTHERS

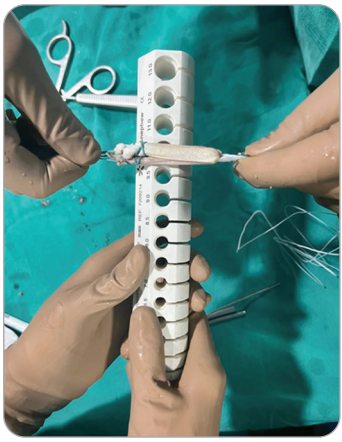

FIG. 18: Measurement of graft diameter.

Disadvantages

- *Poor biocompatibility*: The rupture of a Dacron or Gore-Tex ligament, e.g., incites a characteristic synovitis that causes pain and persistent effusions.
- *Infection*: Relatively higher rate of infection being a foreign material. Complete removal of the synthetic ligament is necessary to relieve the symptoms.
- *High rupture rate*: Approximately, 50% of synthetic ligaments undergo partial or complete rupture within 5 years. Sites of predilection are—the site of emergence from the femoral tunnel, the entry site into the tibial tunnel (bending on flexion and extension), and osteophytes in the intercondylar notch (guillotine like action on extension).
- *High incidence of synovitis*: Some prosthetic ligaments, especially those containing carbon fibers, have very high reported rates of postoperative synovitis.
- *High costs*: The procurement and storage costs can be considerable.
- *Need for a lateral incision*: Because the prosthetic ligaments are not fixed in the bone tunnel with an interference screw, a separate lateral incision is required for the insertion of screws, staples, or both, as recommended by the manufacturer. This extra incision increases the morbidity of the procedure.

Allografts

The use of "cadaveric ligaments" offers a conceivable alternative to prosthetic materials. The main advantage of allografts is the absence of donor site morbidity. An allograft is a useful treatment option, and sometimes the only option, in some revision procedures (e.g., after multiple failed ligament reconstructions) and in patients with multiple injuries (e.g., bilateral ruptures of the ACL and PCL) accompanied by complex peripheral instabilities.

Available options are—tendoachilles and BTB.

JAYPEE BROTHERS

TABLE 1: Comparison of different grafts.

Type of graft	Pros	Cons
Autograft		
Bone-patellar tendon-bone (BPTB)	• Strong fixation due to bone plugs • Fast bone-to-bone healing	• Risk of anterior knee pain and kneeling discomfort • Patellar fracture or tendinitis risk
Hamstring tendons	• Minimal donor site morbidity • Smaller incision • High tensile strength	• Slower graft healing • Risk of hamstring weakness • Difficult fixation compared to BPTB
Quadriceps tendon	• Large graft diameter • Lower risk of donor site complications compared to BPTB	• Risk of extensor mechanism weakness • Limited long-term data
Peroneus longus tendon	• Long and strong tendon • Minimal functional deficit after harvest • Easy to harvest	• Limited data on long-term outcomes • Risk of lateral ankle weakness
Allograft:		
Tibialis anterior/ posterior or Achilles	• No donor site morbidity • Shorter operative time • Useful for multiligament reconstructions	• Higher risk of graft rejection or infection • Delayed graft incorporation • Expensive
Synthetic grafts	E.g., LARS ligament	• Immediate strength • No donor site morbidity
Xenografts	• Readily available • Avoids donor site morbidity	• Risk of immune rejection • Limited use due to ethical and cultural concerns

(LARS: ligament augmentation and reconstruction system)

Advantages

- No donor site problems
- Always available
- Suitable for revision cases

Disadvantages

- *Immune reaction*: Many recipients have developed chronic synovitis with pain and recurrent effusions.
- *Softened bone at tunnel entrances*: If revision becomes necessary after an allograft reconstruction, marked softening of the bone is typically found at the intra-articular tunnel entrances. This can greatly increase the difficulty of the revision procedure (cancellous bone grafting of the softened areas).

JAYPEE BROTHERS

- *Costs*: The procurement and storage costs must be taken into account.
- *Finite risk of HIV/HBV/HCV transmission*: Allograft transmission of human immunodeficiency virus is extremely unlikely, and the risk has been characterized as extremely low in publications. Nevertheless, the risk cannot be completely eliminated.

SUGGESTED READING

1. Strobel MJ. Manual of arthroscopic surgery. Berlin: Springer; 2002. pp. 384-91.

JAYPEE BROTHERS

detailed information on orthopedics books, visit our website www.jaypeebrothers.com, for detailed information on orthopedics books, visit our website

Handbook of
Arthroscopy

This book provides an in-depth exploration of arthroscopy, meticulously covering fundamental concepts, advanced techniques, and practical applications.

Salient Features

- **Structured and systematic approach:** Each chapter is systematically organized to facilitate understanding, starting from basic principles to advanced surgical techniques for various joints
- **Expert insights:** Authored by a panel of seasoned arthroscopic surgeons, the book offers valuable insights drawn from years of clinical experience
- **Detailed illustrations and procedures:** Includes step-by-step descriptions of key procedures, supported by diagrams and photographs for clarity and ease of comprehension
- Fundamentals of arthroscopy, including indications, contraindications, and diagnostic techniques
- Detailed protocols for knee and shoulder positioning, draping, and portal placement
- Comprehensive sections on ACL, PCL, meniscus, and rotator cuff repair
- Discussions on complex conditions such as anterior instability and frozen shoulder
- **Case-based learning:** Features caselets summarizing real-life clinical scenarios, enhancing problem-solving skills and practical knowledge
- **Psychological perspective:** Unique insights into the psychology of arthroscopic surgeons, addressing the mental and emotional aspects of the profession
- **Ideal for practitioners and learners:** An invaluable resource for orthopedic surgeons, trainees, and medical professionals seeking to enhance their expertise in arthroscopy

Printed in India

Available at all medical bookstores or buy online at www.ejaypee.com

JAYPEE BROTHERS
Medical Publishers (P) Ltd.
EMCA House, 23/23-B, Ansari Road, Daryaganj, New Delhi - 110 002, INDIA
www.jaypeebrothers.com

Join us on facebook.com/JaypeeMedicalPublishers
Follow us on instagram.com/JaypeeMedicalPublishers

Shelving Recommendation
ORTHOPEDICS

ISBN 978-93-6616-701-5