dicine books, visit our website www.ejaypee.com, for detailed information on medicine books, visit our website www.ejaypee.com, for detailed information on medicine book



3rd Edition

Complementary 150+ Clinical Videos and Audios only with Genuine Book Access by scanning QR codes inside

Part-1

An Insider's Guide to CLINICAL MEDICINE

Archith Boloor
Anudeep Padakanti

Foreword **RN SHARMA**

As per the Revised Competency-based Medical Education Curriculum (NMC)

diginerve
A Jaypee Initiative
• Video Lectures • Dr. Wise AI Chatbot
• Question Bank • Notes
Download App



Genuine?
Scratch, Scan & Validate



Dr. Wise
Innovative & Genius AI Chatbot
access code inside

JAYPEE

Contents

1. Introduction 1
- The Importance of History Taking *1*
- Prerequisites for Practical Examination *5*
- Checklist for Practical Examination *5*
- Format of Clinical Examination *6*
- Common Examination Cases *6*

2. General Examination 7

A. Case Sheet Format 7
- Body Mass Index *7*
- Vitals Examination *7*
- Physical Examination *7*
- Others *7*

B. Vitals Examination 8
- Pulse *8*
- Respiration *16*
- Blood Pressure *18*
- Ankle-Brachial Index *21*
- Jugular Venous System *22*
- Body Temperature *26*
- Pain: The Fifth Vital Sign *29*

C. Physical Examination 31
- Pallor *31*
- Icterus *32*
- Cyanosis *34*
- Clubbing (Hippocrates Fingers) *35*
- Edema *38*
- Lymphadenopathy *40*
- Nutritional Assessment *46*
- Nail Changes *48*

D. Anthropometry 49
- Height *49*
- Arm Span *50*
- Upper Segment and Lower Segment *50*
- Skinfold Thickness *51*
- Body Mass Index *52*
- Waist-Hip Ratio *52*
- Mid-Arm Circumference *52*
- Neck Circumference *52*
- Neck Height Ratio *53*
- Miscellaneous Topics *53*
- Marfan's Syndrome: Diagnostic Criteria and Features *54*

3. Respiratory System Examination 55

A. Case Sheet Format 55
- History Taking *55*
- General Examination *56*
- Systemic Examination *56*

B. Diagnosis Format 60
- Anatomical Diagnosis *60*
- Pathological Diagnosis *60*
- Etiological Diagnosis *60*
- Complications *60*
- Examples *60*

C. Discussion on Cardinal Symptoms 61
- Cough *61*
- Expectoration/Sputum *62*
- Hemoptysis *63*
- Dyspnea *64*
- Timing of Dyspnea *67*
- Chest Pain *68*
- Other Symptoms *68*

D. Discussion on Examination 70
- General Examination *70*
- Examination of Respiratory System *72*
- The Most Important Examination Finding is to Check for Hemithorax Expansion and Hemithorax Measurement *81*

E. Respiratory System: Summary of Findings in Common Respiratory Diseases 91

4. Cardiovascular System Examination 93

A. Case Sheet Format 93
- History Taking *93*
- General Examination *94*
- Systemic Examination *95*
- Other System Examination *96*

B. Diagnosis Format 97
- Acquired/Congenital Heart Disease *97*

C. Discussion on Cardiac Cycle 98
- Systole and Diastole *98*
- Events of Cardiac Cycle *98*
- Cardiac Murmurs—Timing with Other Cardiac Events *99*
- ECG Waveform—Timing with Other Cardiac Events *100*
- Standard Representation of All Cardiac Events in Cardiac Cycle *100*

D. Discussion on Cardinal Symptoms 102
- Chest Pain *102*
- Palpitations *104*
- Dyspnea *105*
- Syncope *105*
- Pedal Edema *106*

E. Discussion on Examination 109
- General Examination *109*
- Physical Examination *109*

- Systemic Examination *111*
- Cardiac Cycle and Heart Sounds *119*
- Third Heart Sound (S3) *122*
- Pericardial Knock *122*
- Fourth Heart Sound (S4) *122*
- Clicks and Snaps *123*
- Pericardial Rub *123*
- Summary of Auscultation of Heart Sounds *124*
- Murmurs *124*
- Summary of Heart Murmurs *131*
- Other System Examination *132*
- Pulsatile Liver *132*

F. Summary of Findings in Common Cardiovascular Diseases 135

5. Gastrointestinal System..... 137

A. Case Sheet Format 137
- History Taking *137*
- General Examination *138*
- Systemic Examination *138*

B. Diagnosis Format 141
- Cirrhosis/Liver Disease *141*
- Example *141*

C. Discussion on Cardinal Symptoms 142
- Abdominal Swelling *142*
- Jaundice *142*
- Gastrointestinal Bleeding *142*
- Nausea and Vomiting *143*
- Diarrhea *144*
- Constipation *145*
- Dyspepsia *145*
- Dysphagia *146*
- Odynophagia *146*
- Pain in Abdomen *146*

D. Discussion on Examination 151
- General Examination *151*
- Oral Cavity Examination *156*
- Systemic Examination *157*
- Auscultation *160*
- Palpation and Percussion of the Abdomen *161*
- Examination of Individual Organs *161*
- Inspection *161*
- Renal Angle *170*
- Murphy's Kidney Punch (Costovertebral Angle Tenderness) *170*
- Complications of Cirrhosis *177*
- Sites of Portosystemic Anastomosis *179*
- Classification of Portal Hypertension *179*

6. Nervous System..... 181

A. Case Sheet Format 181
- History Taking *181*
- Higher Mental Function *181*
- Cranial Nerve Dysfunction *181*
- Motor Dysfunction *181*
- Sensory Dysfunction *182*
- Cerebellar History *182*
- History Suggesting Meningitis/Raised Intracranial Pressure *182*
- History Suggesting Autonomic Dysfunction *182*
- Review of Common Neurological Symptoms *182*
- General Examination *183*
- Nervous System Examination *184*
- Higher Mental Functions *184*
- Motor System *185*
- Reflexes *186*
- Sensory System *186*
- Cerebellar Signs *186*
- Gait *187*
- Soft Neurological Signs *187*
- Other Systems *187*

B. Diagnosis Format 188
- General Format *188*
- For Cerebrovascular Accident *188*
- For Neuropathy *188*
- For Spinal Cord Disease *188*
- For Extrapyramidal (Parkinson's Disease) *188*
- For Ataxia *188*

C. Central Nervous System: Discussion on Cardinal Symptoms 189
- Discussion on Cardinal Symptoms *189*
- Higher Mental Function *189*
- Cranial Nerve Dysfunction *189*
- Motor Dysfunction *189*
- Sensory Dysfunction *191*
- Cerebellar Examination *191*
- Autonomic Dysfunction *192*
- Meningeal Signs *192*
- Others *192*
- Neck Pain *192*
- Backache *193*
- Red Flags for Acute Low Back Pain *193*

D(i). General Examination in Neurology 195
- General Physical Examination in Nervous System *195*
- Neurocutaneous Syndromes/Phakomatoses *195*
- Nerve Thickening *197*

D(ii). Higher Mental Functions 200
- Nervous System Examination *200*
- Consciousness *200*
- Orientation *201*
- Appearance/Behavior *201*
- Memory *201*
- Attention *202*
- Intelligence/Calculation *202*
- Cognition Assessment Tool *202*
- Speech *202*
- Aphasias *204*
- Dysarthrias *205*
- Apraxia *206*
- Agnosia *206*
- Delusions *206*
- Hallucinations *206*

D(iii). Cranial Nerves 209
- Cranial Nerve I—Olfactory Nerve *209*
- Cranial Nerve II—Optic Nerve *210*
- Stages of Diabetic Retinopathy *214*
- Stages of Hypertensive Retinopathy *214*
- Causes of Optic Atrophy *214*
- Cranial Nerves III, IV and VI—Oculomotor, Trochlear and Abducens *215*
- Ocular Movement Testing *218*
- Diplopia *218*
- Strabismus/Squint *221*
- Pupillary Abnormalities *222*
- Ophthalmoplegia *226*
- Nystagmus *228*
- Cranial Nerve V—Trigeminal Nerve *228*
- Facial Nerve *233*
- Facial Nerve Palsy *236*
- Cranial Nerve VIII—Vestibulocochlear Nerve *239*
- Cranial Nerve IX and X: Glossopharyngeal and Vagus *243*
- Glossopharyngeal Nerve IX *243*
- Cranial Nerve X—Vagus *244*
- Cranial Nerve XI—Spinal Accessory *245*
- Cranial Nerve XII—Hypoglossal Nerve *246*
- Multiple Cranial Nerve Palsies *248*

D(iv). Motor System Examination 250
- Attitude *250*
- Muscle Bulk/Nutrition *250*
- Muscle Tone *252*
- Motor Power *254*
- Examination for Subtle Hemiparesis *263*

D(v). Reflexes 265
- Definition *265*
- Mechanism of Reflex Generation *265*
- Types of Reflexes *265*
- Grading of Reflexes (for DTRs) NINDS Scale *265*
- Reinforcement Mechanism and Methods *265*
- Deep Tendon Reflexes *266*
- Superficial Reflexes *272*
- Plantar Reflex and Variations *272*
- Latent Reflexes of Upper Limb *275*
- Primitive Reflexes *275*
- Inverted and Perverted Reflexes *277*
- Signs to Identify Hysterical Weakness *277*

D(vi). Sensory System Examination 278
- Primary Modalities *278*
- Secondary Modalities *281*
- Homunculus, Sensory Pathway, Dermatomes and Clinical Patterns of Sensory Loss *283*
- Sensory Dermatomes *284*
- Nonorganic Sensory Loss *285*

D(vii). Cerebellum and Coordination 287
- Signs of Cerebellar Disorders *287*
- Heel Knee Test *288*
- Toe Finger Test *289*
- Nose-Finger-Nose Test *290*
- Dysdiadochokinesia *291*
- Foot Tapping/Foot Pat Test *292*
- Straight Line Walking *292*
- Tandem Walking *292*
- Approach to Ataxia *293*
- Cerebellar Ataxia *293*
- Causes of Cerebellar Ataxia *293*
- Localization of Cerebellar Lesions *294*

D(viii). Gait 295
- Normal Gait Cycle *295*
- Abnormalities of Gait *295*
- Gait Abnormalities Analysis *298*
- Bedside Tests to Diagnose Pes Cavus and Pes Planus *299*

D(ix). Approach to Involuntary Movements 300
- Movement Disorders *300*
- Tremor *301*
- Chorea *301*
- Athetosis *301*
- Hemiballismus *301*
- Myoclonus *302*
- Tic *302*
- Dystonia *302*
- Myokymia *302*
- Akathisia *302*
- Restless Legs Syndrome/ "Ekbom's Syndrome" *302*
- Synkinesis/Mirror Movements *302*
- Fasciculations *303*

D(x). Meningeal Signs, Skull, and Spine 304
- Signs of Meningeal Irritation *304*
- Meningism *305*
- Examination of Skull *306*
- Examination of Spine *306*
- Autonomic Nervous System Testing *306*
- Diseases Associated with Autonomic Dysfunction *308*

7. Rheumatology 309

A. Case Sheet Format 309
- History Taking *309*
- Examination *310*

B. Diagnosis Format 312
- Examples *312*

C. Discussion on Symptomatology and Examination 313
- Discussed in the Following Headings *313*
- Symptomatology *313*
- Examination of Skin, Hands, and Eyes *314*
- Examination Pattern of Musculoskeletal System *317*
- Examination of Upper Limbs *319*
- Examination of Lower Limb *323*
- Examination of Spine *325*
- Examination of Other Joints *327*
- Examination of Other Systems in Rheumatological Disorders *327*

- Discussion on Common Rheumatological Diseases *328*
- Scoring Systems for Severity of Disease *332*

8. Comprehensive Geriatric Assessment 335

Case Sheet Format 335
- History Taking *335*

Diagnosis Format 337

Discussion 338
- Frailty Syndrome *339*
- Dementia *339*
- Incontinence *340*
- Falls in the Elderly *341*

9. Approach to Psychiatric Illness..... 342

Case Sheet Format 342
- History *342*
- Examination *342*

Diagnosis Format 344

Discussion on History and Examination 345
- Salient Points in History *345*
- Salient Points in General Physical and Systemic Examination *346*
- Mental Status Examination *346*
- Delusion *347*
- Obsessions *348*
- Mood and Affect *348*
- Illusions *348*
- Hallucination *348*
- Pseudohallucination *348*

Discussion on Diagnosis of Psychiatric Disorders 350
- Approach to Diagnosis in Psychiatry *350*
- Clinical Institute Withdrawal Assessment for Alcohol (CIWA-A) Scale *353*
- General Outline of Plan of Management of Psychiatric Disorders *354*

10. Semilong Cases 355
- Semilong/Therapeutic Cases *355*

11. Simplified Approach to ECG (Reading and Diagnosis)..... 362
- Conduction System of the Heart *362*
- ECG Waveforms and Intervals *362*
- Reading 12-Lead ECGS *364*
- Types of LVH *373*
- ECG Changes in Myocardial Infarction *374*
- Electrolytes and ECG *376*
- Examples *377*

12. A Systematic Approach to Chest X-rays..... 414
- Approach to Chest X-rays *414*
- Discussion on Common X-rays *427*
- Computed Tomography *436*
- Magnetic Resonance Imaging *437*
- Contrast Agents *438*

13. Basic Instruments and Procedures in Viva..... 439
- Gastric Lavage Tube *439*
- Laryngoscope *440*
- Metal Tracheostomy Tube *440*
- Endotracheal Tube *441*
- Oropharyngeal Airway *441*
- Ambu Bag *442*
- Ryles Tube—Nasogastric Tube *442*
- Suction Catheter *443*
- Foleys Catheter *443*
- Sahli's Hemoglobinometer *444*
- Neubauer Chamber/Hemocytometer *444*
- Insulin Syringe *444*
- Tuberculin Syringe *444*
- Vim Silverman Liver Biopsy Needle *445*
- Trucut Biopsy Gun *445*
- Bone Marrow Aspiration Needle *446*
- Bone Marrow Biopsy Needle (Jamshidi Needle) *446*
- Lumbar Puncture Needle *446*
- Intravenous Drip Set *447*
- Intravenous Cannula *448*
- Oxygen Mask *449*
- Nasal Cannula *449*
- Venturi Mask *449*
- Non-rebreather Mask *449*
- Inhaler Devices *450*
- Nebulizers *451*
- Urinometer *451*
- Westergren Tube *452*
- Peak Flow Meter *452*

14. Spotters..... 454

15. Discussion on Drugs and Medical Emergencies 464
- Antimalarials *464*
- Antitubercular *465*
- Antiepileptics *466*
- Antihistaminics *466*
- Antiarrhythmics *467*
- Antianginal and Antiplatelets *468*
- Antiparkinson *470*
- Antipsychotics and Antidepressants *471*
- Analgesics *472*
- Diuretics *473*
- Drugs for Asthma *474*
- Antihypertensives *476*
- Drugs Acting on Autonomic System *479*
- Endocrine *480*
- Antibiotics *484*
- Antiviral Oseltamivir *488*
- Antiretroviral *488*
- Anticoagulation *490*
- Fibrinolytic *491*
- Disease-Modifying Antirheumatic Drugs *491*
- For Inflammatory Bowel Disease *492*

- Antiencephalopathy *493*
- COVID-19 Drugs *493*
- Antifungal *494*
- For *H. pylori* *494*
- For Diarrhea *495*
- Toxicology *495*
- Intravenous Fluids *496*
- Common Drugs Used in Emergencies *497*

16. Annexures 499

A. Miscellaneous Topics 499
- Pedigree Analysis *499*
- Alcohol Use *501*
- Smoking *503*

B. Definitions 504
- Pulse *504*
- Blood Pressure *504*
- Hypertension *504*
- Resistant Hypertension *505*
- Refractory Hypertension *505*
- Pseudoresistant Hypertension *505*
- Pseudohypertension *505*
- Secondary Hypertension *505*
- Masked Hypertension *505*
- White Coat Hypertension *505*
- Hypertensive Crisis *505*
- Hypertensive Emergency *505*
- Malignant Hypertension *505*
- Hypertensive Urgency *505*
- Jugular Venous Pressure *505*
- Anemia *505*
- Erythrocytosis and Polycythemia *505*
- Jaundice *506*
- Cyanosis *506*
- Clubbing *506*
- Fever *506*
- Fever of Unknown Origin *506*
- Revised Definition of Fever of Unknown Origin *506*
- Hyperpyrexia *506*
- Hyperthermia *506*
- Heatstroke *507*
- Dyspnea *507*
- Orthopnea *507*
- Paroxysmal Nocturnal Dyspnea *507*
- Platypnea *507*
- Orthodeoxia *507*
- Trepopnea *507*
- Bendopnea *507*
- Palpitations *507*
- Tachycardia *507*
- Bradycardia *507*
- Apex Beat *507*
- Acute Coronary Syndrome *507*
- Pulmonary Hypertension *508*
- Heart Failure *508*
- Dilated Cardiomyopathy *508*
- Cough *508*
- Massive Hemoptysis *508*
- Lung Sounds *508*
- Chronic Obstructive Pulmonary Disease *508*
- Chronic Bronchitis *509*
- Emphysema *509*
- Chronic Cor Pulmonale *509*
- Asthma *509*
- Bronchiectasis *509*
- Unintentional Weight Loss *509*
- Dysphagia *509*
- Dyspepsia *509*
- Nausea *509*
- Retching *509*
- Vomiting *509*
- Regurgitation *509*
- Diarrhea *509*
- Constipation *510*
- Fecal Incontinence *510*
- Hematemesis *510*
- Malena *510*
- Hematochezia *510*
- Severe Gastrointestinal Bleeding *510*
- Occult Gastrointestinal Bleeding *510*
- Obscure Gastrointestinal Bleeding *510*
- Acute Liver Failure *510*
- Cirrhosis of Liver *511*
- Portal Hypertension *511*
- Hepatic Encephalopathy *511*
- Polyuria *511*
- Nocturia *511*
- Oliguria *511*
- Anuria *511*
- Hematuria *511*
- Moderately Increased Albuminuria *511*
- Severely Increased Albuminuria *511*
- Acute Kidney Injury *511*
- Chronic Kidney Disease *511*
- Nephrotic Syndrome *512*
- Uncomplicated UTI and Complicated UTI *512*
- Asymptomatic Bacteriuria *512*
- Neutropenia and Agranulocytosis *512*
- Febrile Neutropenia *512*
- Lymphadenopathy *512*
- Generalized Lymphadenopathy *512*
- Massive Splenomegaly *512*
- Hypersplenism *512*
- Stupor *512*
- Coma *513*
- Confusion *513*
- Dementia *513*
- Delirium *513*
- Akinetic Mutism *513*
- Locked in Syndrome *513*
- Abulia *513*
- Attention and Concentration *513*
- Memory *513*
- Amnesia *513*
- Agnosia *513*

- Insomnia *513*
- Aphasia *514*
- Dysarthria *514*
- Aphonia and Dysphonia *514*
- Agraphia/Dysgraphia *514*
- Alexia *514*
- Echolalia *514*
- Palilalia *514*
- Perseveration *514*
- Neologisms *514*
- Idioglossia *514*
- Dyslogia *514*
- Confabulation *514*
- Tone *514*
- Rigidity *514*
- Cogwheel Rigidity *515*
- Akathisia *515*
- Asterixis *515*
- Athetosis *515*
- Chorea *515*
- Dystonia *515*
- Hemiballismus *515*
- Myoclonus *515*
- Myokymia *515*
- Restless Leg Syndrome *515*
- Tics *515*
- Tremor *515*
- Agraphesthesia *516*
- Allodynia *516*
- Alloesthesia *516*
- Analgesia *516*
- Asterognosis *516*
- Anesthesia *516*
- Dysesthesias *516*
- Extinction *516*
- Hypalgesia *516*
- Hyperalgesia *516*
- Hyperpathia *516*
- Kinesthesia *516*
- Pallesthesia *516*
- Paresthesias *516*
- Neglect *517*
- Anosognosia *517*
- Constructional Apraxia *517*
- Ataxia *517*
- Paralysis and Paresis *517*
- Apraxia *517*
- Stroke *517*
- Transient Ischemic Attack *517*
- Lacunar Stroke *517*
- Epileptic Seizure *517*
- Epilepsy *517*
- Syncope *518*
- Metabolic Syndrome *518*
- Sepsis *518*
- Systemic Inflammatory Response Syndrome *518*
- Acute Respiratory Distress Syndrome *518*
- Macule *518*
- Patch *518*
- Papule *518*
- Nodule *519*
- Tumor *519*
- Plaque *519*
- Vesicle *519*
- Pustule *519*
- Bulla *519*
- Wheal *519*
- Telangiectasia *519*
- Lichenification *519*
- Scale *519*
- Crust *519*
- Erosion *519*
- Ulcer *519*
- Excoriation *519*
- Atrophy *519*
- Scar *519*
- Purpuric Lesions *519*
- Gynecomastia *520*

C. Grading Systems 521

- 1952 MRC Breathlessness Scale *521*
- Modified MRC Dyspnea Scale *521*
- MRC Muscle Scale *521*
- NYHA Breathlessness *521*
- Canadian Cardiovascular Society—Grading of Angina Pectoris *522*
- NINDS Myotactic Reflex Scale *522*
- Freeman and Levine Grading of Systolic Murmur *522*
- ABCD and ABCD2 Scores *523*
- BODE Index *523*
- COPD Assessment Test *524*
- CHADS2 *524*
- CHADS-VASC *524*
- HAS-Bled *524*
- EHRA Score *525*
- Child-Turcotte-Pugh Score *525*
- Framingham Heart Failure Criteria *525*
- GCS *525*
- West Haven Grading of Hepatic Encephalopathy *526*
- CKD Stages *526*
- 2015 Revised Jones Criteria *527*
- Modified Duke's Criteria *527*
- Cage Questionnaire *528*
- Light's Criteria *528*
- qSOFA *528*
- SOFA *529*
- CURB 65 *529*
- Forrest Grading of Gastrointestinal Ulcers *529*
- Severity Index for Ulcerative Colitis *529*

D. Laboratory Values of Clinical Importance 530

- Hematology and Coagulation *530*

E. Short List of Routinely Used Formulas in Medicine 535

Index *537*

3 CHAPTER

Respiratory System Examination

JAYPEE BROTHERS

A. CASE SHEET FORMAT

HISTORY TAKING

Name:
Age:
Sex:
Residence:
Occupation:

Chief complaints:
1. _____ × days
2. _____ × days
3. _____ × days

History of presenting illness:

Cough:
- Duration
- Onset
- Progression
- Variation
  - Diurnal variation
  - Seasonal variation
  - Postural variation
- Aggravating factors
- Relieving factors

Expectoration:
- Duration
- Onset
- Progression
- Variation
  - Diurnal variation
  - Seasonal variation
  - Positional variation
- Aggravating and relieving factors
- Quantity of sputum (to be measured in mL)
- Color
- Smell
- Blood tinged
  - How often
  - Quantity
  - Fresh or altered

Dyspnea:
- Duration
- Onset
- Grade (MMRC grading is preferred)
- Progression
- Aggravating factors
- Relieving factors
- Orthopnea
- Trepopnea
- Platypnea
- Paroxysmal nocturnal dyspnea (PND)
- Any respiratory system complaints
  - Wheeze
  - Cough with expectoration

Chest pain:
- Duration
- Onset
- Site
- Type of pain/character of pain
- Radiation
- Diurnal variation (nocturnal angina)
- Variation with respiration
- Aggravating factors
- Relieving factors
- Associated symptoms
  - Nausea, vomiting, sweating
- Local tenderness

Wheeze:
- Duration
- Onset
- Progression
- Episodic or continuous
- Variation (diurnal or seasonal)
- Allergy
- Skin rashes
- Aggravating and relieving factors

Fever:
- Episodic or continuous
- Grade

- Chill and rigors
- Aggravating factors
- Relieving factors
- Variation
  - Diurnal variation

History of:
- Nasal discharge
- Recurrent cold/epistaxis
- Recurrent headaches
- Weight loss
- Anorexia
- Evening rise of temperature
- Smoking
- Belching
- Regurgitation of food
- Hoarseness of voice

Past history:
- Asthma
- Chronic obstructive airway disease
- Tuberculosis
- History of contact with tuberculosis
- Diabetes mellitus (DM)
- Hypertension (HTN)
- Ischemic heart disease (IHD)
- Seizure disorder

Family history: Respiratory diseases with a genetic component, e.g., cystic fibrosis, emphysema (alpha-1-antitrypsin deficiency).
(Draw pedigree chart representing three generations)

Personal history:
- Bowel habits
- Bladder habits
- Appetite
- Loss of weight
- Occupational exposure: Environmental inhalation is a significant cause of respiratory diseases. Coal miners ("black lung"), quarry workers (silicosis), insulation installers and shipyard workers (asbestosis), and cotton mill workers (byssinosis) represent notable COPD categories.
- Sleep
- Dietary habits and taboo
- Food allergies
- Smoking (in Smoking Index or Pack years)
- Alcohol history (___grams of alcohol/day or____units of alcohol/week)

Menstrual and obstetric history:
- G__P__L__A__
- Age of menarche__
- Menopause at__
- Flow—amenorrhea/oligomenorrhea/menorrhagia

Summarize:
Differential diagnosis:
1.
2.
3.

GENERAL EXAMINATION

Patient:
- Conscious
- Cooperative
- Obeying commands

Body mass index:
Weight (kg)/H² (m)
(Grading according to WHO for Southeast Asian countries)

Vitals:
- Pulse
  - Rate
  - Rhythm
  - Volume
  - Character
  - Vessel wall thickening
  - Radio-radial delay and radiofemoral delay
  - Peripheral pulses
- Blood pressure
- Respiratory rate
  - Regular
  - Abdominothoracic (male) or thoracoabdominal (female)
  - Usage of accessory muscles
- Jugular venous pulse
  - Waveform
- Jugular venous pressure
  - _____cm of blood above sternal angle (+ 5 cm water)
- Pulse oximetry
- Pain

On physical examination:
- Pallor:
- Icterus:
- Cyanosis:
- Clubbing:
- Lymphadenopathy:
- Edema:

Others:
- Use of accessory muscles of respiration
- Features suggesting type of respiratory failure
- External markers of tuberculosis if any
- External markers of malignancy if any

SYSTEMIC EXAMINATION

Upper Respiratory Tract Examination

- Nostrils:
- Nasal septum:
- Nasal polyps:
- Sinus tenderness:
- Tonsils:
- Postpharyngeal wall:

Lower Respiratory Tract Examination

Inspection

- Shape and symmetry:

JAYPEE BROTHERS

- Supraclavicular hollowing/infraclavicular flattening
- Intercostal indrawing or rib crowding
- Spine:
- Sub costal angle:
- Trachea:
- Apex beat:
- Respiratory movements:

Area	*Right*	*Left*
Infraclavicular area—upper anterior chest		
Mammary area—lower anterior chest		
Supraclavicular area—upper posterior chest		
Inter- and infrascapular area—lower posterior chest		

- Visible pulsations/sinus/scars:

Palpation

Warm the palms by rubbing against each other before palpation:

- Spine: Position and tenderness
- Trachea:
- Apex:

Respiratory movements:

Area	*Right*	*Left*
Supraclavicular		
Infraclavicular		
Mammary		
Suprascapular		
Infrascapular		

Dimensions/measurements:

Transverse diameter		
Anteroposterior diameter		
Transverse/ anteroposterior ratio		
Chest circumference	Expiration	
	Inspiration	
Right hemithorax	Expiration	
	Inspiration	
Left hemithorax	Expiration	
	Inspiration	
Chest expansion	Right hemithorax	
	Left hemithorax	
	Total	
Spinoscapular distance	(Right side) and (left side)	
Spinoacromial distance	(Right side) and (left side)	

Vocal fremitus:

Areas	*Right*	*Left*
Supraclavicular		
Infraclavicular		

Contd...

Contd...

Mammary		
Axillary		
Infra-axillary		
Suprascapular		
Interscapular		
Infrascapular		

- Tactile fremitus:
- Friction fremitus:
- Tenderness:
- Subcutaneous emphysema:
- Rib crowding:
- Bony tenderness:

Percussion

Areas	*Right*	*Left*
Clavicular (direct percussion)		
Supraclavicular		
Infraclavicular		
Mammary		
Axillary		
Infra-axillary		
Suprascapular		
Interscapular		
Infrascapular		

- Shifting dullness:
- Tidal percussion:
- Traube's space:
- Kronig's isthmus:
- Liver dullness:
- Liver span:

Heart border:

- Right heart border:
- Left heart border:

Auscultation

Breath sounds:

- Vesicular/bronchovesicular/bronchial (tubular/cavernous/amphoric)
- Comment on intensity of breath sound—normal/increased/decreased

Areas	*Right*	*Left*
Supraclavicular		
Infraclavicular		
Mammary		
Axillary		
Infra-axillary		
Suprascapular		
Interscapular		
Infrascapular		

JAYPEE BROTHERS

Vocal resonance:

Areas	*Right*	*Left*
Supraclavicular		
Infraclavicular		
Mammary		
Axillary		
Infra-axillary		
Suprascapular		
Interscapular		
Infrascapular		

Adventitious sounds (mention in specific areas):
- Crepitations (fine/coarse, inspiratory/expiratory)
- Rhonchi (inspiratory or expiratory/polyphonic or monophonic)
- Pleural rub

Additional tests (only in specific cases):
- Bronchophony:
- Egophony:
- Whispered pectoriloquy:
- Succussion splash:
- Post-tussive crepitations:
- Post-tussive suction
- Shifting dullness:
- Coin test:

Other Systems

Cardiovascular system:
- Inspection:
- Palpation:
- Percussion:
- Auscultation:

Gastrointestinal system:
- Inspection:
- Palpation:
- Percussion:
- Auscultation:

Nervous system:
- Higher mental functions:
- Cranial nerves:
- Sensory system:
- Motor system:
- Reflexes:
- Cerebellar system:
- Meningeal signs:

JAYPEE BROTHERS

NOTES

JAYPEE BROTHERS

B. DIAGNOSIS FORMAT

ANATOMICAL DIAGNOSIS

- Lung (right/left/bilateral) disease with (upper/middle/lower) lobe
- Pleural disease

PATHOLOGICAL DIAGNOSIS

Consolidation/fibrosis/collapse/obstructive lung disease/restrictive lung disease/effusion/pneumothorax.

ETIOLOGICAL DIAGNOSIS

Tuberculosis/bronchogenic carcinoma/smoking/occupation/trauma, etc.

COMPLICATIONS

Respiratory failure (type I or type II)/cor pulmonale.

EXAMPLES

Example 1

Right upper lobe fibrosis post-tubercular etiology, no evidence of respiratory failure or cor pulmonale.

Example 2

Bilateral obstructive lung disease—emphysema secondary to smoking with evidence of type 2 respiratory failure and cor pulmonale.

Example 3

Left-sided pleural effusion secondary to malignancy with no evidence of respiratory failure or cor pulmonale.

NOTES

JAYPEE BROTHERS

C. DISCUSSION ON CARDINAL SYMPTOMS

Symptoms discussed include:

1. Cough
2. Expectoration
3. Hemoptysis
4. Dyspnea
5. Chest pain (with respect to respiratory system)
6. Others

COUGH

Definition: A sudden and variable expiratory thrust of air from the lungs through the air passages associated with phonation, which momentarily interrupts the physiological pattern of breathing.

Mechanism of cough production: Cough reflex initiated by chemical/mechanical stimuli **(Flowchart 3C.1)**. This is carried by the afferents which are type C and type 1 fibers and innervate pharynx, larynx, large airways, terminal bronchiole and lung parenchyma. Afferents travel via vagus and superior laryngeal nerve. Nucleus tractus solitarius (NTS) in brainstem is the cough center. Efferents travel via vagus, phrenic, spinal motor nerves to the larynx, trachea, bronchi, diaphragm producing cough.

Mechanical events during cough production: The mechanical events involved in a typical cough are rapid successions of **(Figs. 3C.1A to C)**:

1. Inspiratory phase: A fairly deep initial inspiration (2.5–3 L)
2. Compressive phase: The tight closure of the glottis, reinforced by the supraglottic structures
3. Expiratory phase: The quick and forceful contraction of the expiratory muscles → the sudden opening of the glottis while the contraction of the expiratory muscles continues.

Flowchart 3C.1: Algorithm showing cough reflex.

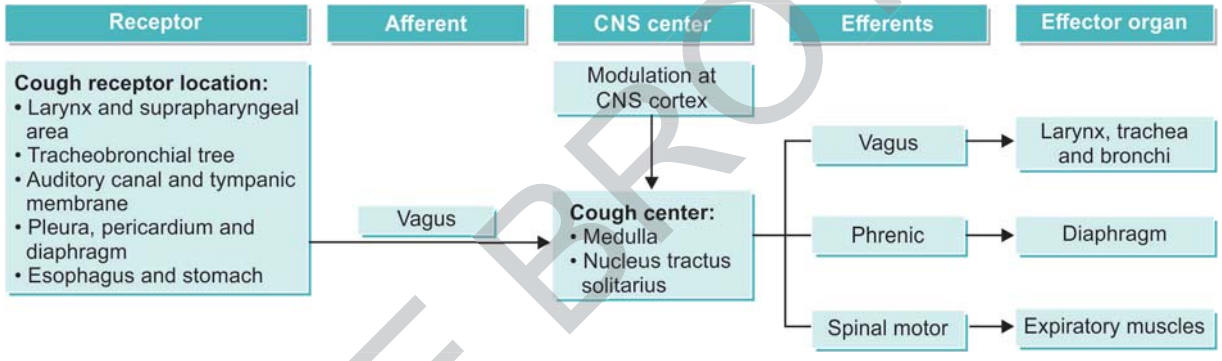

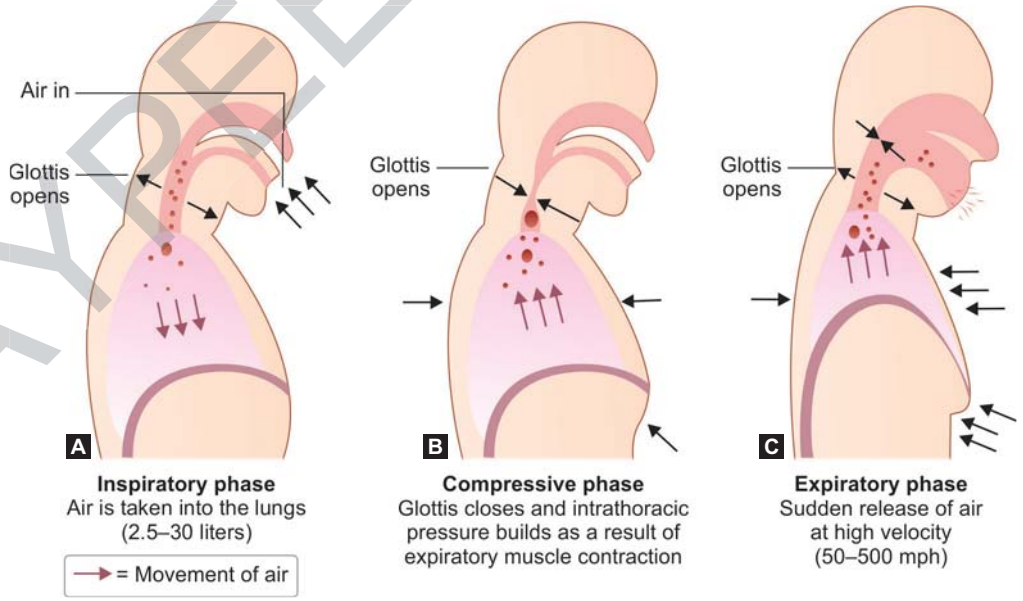

Figs. 3C.1A to C: Mechanical events during cough production: (A) Inspiratory phase; (B) Compressive phase; (C) Expiratory phase.

JAYPEE BROTHERS

Classification:

- **Based on etiology:** The etiology can be classified into respiratory causes and nonrespiratory causes.
- **Based on duration of cough:** Cough has been classified into acute (less than 3 weeks), subacute (3–8 weeks), and chronic (more than 8 weeks; **Box 3C.1**).
- **Based on expectoration:** It is also classified into productive or dry cough depending on the presence or absence of expectoration, respectively **(Table 3C.1)**. Different types of coughs are summarized in **Table 3C.2**.

Box 3C.1: Chronic cough with normal chest X-ray.

- Cough variant asthma
- Tropical eosinophilia
- Upper airway cough syndrome
- Aspiration
- Habitual cough
- Foreign body
- Drugs, angiotensin converting enzyme inhibitors
- Chronic bronchitis
- Chronic idiopathic cough

TABLE 3C.1: Classification of cough based on etiology.

Cough	*Duration*	*Respiratory causes*	*Nonrespiratory causes*
Acute cough	Less than 3 weeks	▪ Tracheobronchitis ▪ Upper respiratory tract infections (URTI) ▪ Bronchopneumonia ▪ Viral pneumonia ▪ Acute-on-chronic bronchitis ▪ Pulmonary embolism **Sudden onset:** ▪ Bronchial asthma ▪ Asthmatic bronchitis ▪ Whooping cough ▪ Foreign body	▪ LVF ▪ GERD
Subacute cough	3–8 weeks	▪ Tuberculosis, pneumonia (bacterial, viral, fungal) ▪ *B. pertussis* ▪ Bronchiectasis ▪ Postviral tussive syndrome	▪ GERD ▪ Tourette's syndrome ▪ Intentional cough
Chronic cough*	Lasting for more than 8 weeks	▪ COPD, asthma ▪ ILD ▪ Tuberculosis ▪ Lung cancer ▪ Pneumoconiosis (asbestosis, silicosis, anthracosis, etc.) ▪ Mesothelioma of lung ▪ Upper airway cough syndrome	▪ Drug induced (ACE inhibitors, beta blockers, NSAIDs) ▪ Habit cough syndrome

**Chronic cigarette smoking is the most common cause of chronic cough.*

(LVF: left ventricular failure; GERD: gastroesophageal reflux disease; COPD: chronic obstructive pulmonary disease; ILD: interstitial lung disease; ACE: angiotensin converting enzyme; NSAIDs: nonsteroidal anti-inflammatory drugs)

TABLE 3C.2: Different types of cough.

Types	*Features*
Dry cough	Pleural disorders, diseases of interstitium, mediastinal lesions
Productive cough	Suppurative lung disease, airway diseases
Brassy/Gander cough	Metallic sound due to compression of trachea by intrathoracic space occupying lesions or aortic aneurysms also known as leopards growl
Bovine cough	Loss of expulsive nature as in a tumor pressing on the recurrent laryngeal nerve
Paroxysmal cough	Whooping cough, chronic bronchitis, foreign body, bronchial asthma
Barking cough	Involvement of epiglottis, croup (laryngotracheobronchitis), hysteria
Spluttering cough	Tracheoesophageal fistula, cough while swallowing
Hacking cough	Heavy smokers, chronic pharyngitis or laryngitis
Otogenic cough	Due to stimulation of Arnold's nerve in the external auditory meatus (impacted wax/ foreign body)

EXPECTORATION/SPUTUM

Sputum can be described under the following headings:

- Quantity
- Quality
- Odor

JAYPEE BROTHERS

Quantity	
Normal	10–15 mL/24 hours
Bronchorrhea	▪ Production of more than 100 mL/20 teaspoons in 24 hours ▪ Bronchiectasis ▪ Lung abscess ▪ Bronchoalveolar carcinoma ▪ Organophosphorus poisoning ▪ Pulmonary alveolar proteinosis
Quality	
Mucoid	Chronic bronchitis, bronchial asthma
Mucopurulent	Infections
Purulent	Lung abscess, bronchiectasis
Rust-colored purulent sputum	Pneumococcal pneumonia
Currant-jelly and sticky sputum	*Klebsiella pneumoniae*
Blood-tinged foamy sputum	Pulmonary edema (pink frothy)
Greenish	*Pseudomonas*
Granules—yellow/black	Actinomycosis
Anchovy sauce (brown)	Amebic abscess rupturing into lung
Black (melanoptysis)	Carbon particles discolor the sputum gray (as in cigarette smokers) or black (as in coal miners or with smoke inhalation)
Odor	
Foul smelling sputum	Anaerobic infection seen in lung abscess, bronchiectasis

Special Points

- Chronic expectoration of large amounts of purulent and foul-smelling sputum is strongly suggestive of bronchiectasis.
- Sudden production of such sputum in a febrile patient
- Indicates a lung abscess.
- **Three-layer sputum** consisting of a foamy upper layer, mucous middle layer, and viscous purulent bottom layer is pathognomonic of bronchiectasis.
- **Postural variation** in sputum: Bronchiectasis, lung abscess.

TABLE 3C.3: Causes of hemoptysis.

Structure involved	*Common causes*	*Uncommon causes*
Bronchial disease	Bronchial carcinoma, bronchiectasis, acute and chronic bronchitis	Bronchial adenoma, foreign body
Parenchymal disease of lung	Pulmonary tuberculosis (Rasmussen's aneurysm—dilation of a pulmonary artery in a tuberculous cavity), lung abscess, pneumonia (particularly *Klebsiella*), fungal infections (aspergilloma and invasive aspergillosis), pulmonary contusion/laceration (traumatic)	Parasites (e.g. hydatid disease, flukes), trauma, actinomycosis, mycetoma
Vascular diseases of the lung	Pulmonary infarction	Goodpasture's syndrome, polyarteritis nodosa, idiopathic pulmonary hemosiderosis, primary pulmonary hypertension
Cardiovascular disease	Acute left ventricular failure	Mitral stenosis, aortic aneurysm, pulmonary thromboembolism
Hematological disorders		Leukemia, hemophilia, anticoagulants, hemorrhagic diathesis

HEMOPTYSIS

Definition: Hemoptysis is defined as coughing of blood originating from below the vocal cords. Hemoptysis can range from blood-streaking of sputum to the presence of gross blood in the absence of any accompanying sputum. The different causes of hemoptysis are given in **Table 3C.3**.

The clinical clues of hemoptysis, differences between true and false hemoptysis and differences between hemoptysis and hematemesis are described in **Tables 3C.4 to 3C.6**, respectively.

TABLE 3C.4: Clinical clues of hemoptysis.

Clinical clues	*Suggested diagnosis*
Anticoagulant use	**Medication effect, coagulation disorder**
Tobacco use	**Acute bronchitis, chronic bronchitis, pneumonia, lung cancer**
Dyspnea on exertion, fatigue, orthopnea, paroxysmal nocturnal dyspnea, frothy pink sputum	**Congestive heart failure, left ventricular failure and mitral stenosis**
Fever, productive cough	**Upper respiratory tract infection, acute bronchitis, pneumonia, lung abscess**
History of cancer (e.g., breast, colon, or kidney)	**Endobronchial metastasis from carcinoma**
History of chronic lung disease, recurrent lower respiratory tract infection, cough with copious purulent sputum	**Bronchiectasis, lung abscess**
Pleuritic chest pain, calf tenderness	**Pulmonary embolism or infarction**
Toxic symptoms	**Tuberculosis**

Contd...

JAYPEE BROTHERS

Contd...

Weight loss	**Emphysema, lung cancer, tuberculosis, bronchiectasis, lung abscess**
Melena, alcoholism, chronic use of nonsteroidal anti-inflammatory drugs (NSAIDs)	**Gastritis, gastric or peptic ulcer, esophageal varices**
Association with menses	**Catamenial hemoptysis**
Cachexia, clubbing, hoarseness	**Lung cancer, small cell carcinoma**
Clubbing	**Lung cancer, bronchiectasis, lung abscess**
Dullness to percussion, fever, crepitations	**Pneumonia**

TABLE 3C.5: Differences between true and false hemoptysis.

True hemoptysis	*False hemoptysis/pseudo-hemoptysis*
Below vocal cords	Above vocal cords (gum bleeding/upper airway (nasopharyngeal) bleeding
Persists as blood tinged sputum	Does not persist
May be mixed with sputum	Not mixed with sputum
History of cardiopulmonary disease	Obvious by ENT examination
Chest X-ray may be abnormal	Normal chest X-ray

TABLE 3C.6: Differences between hemoptysis and hematemesis.

Hemoptysis	*Hematemesis*
Coughing of blood. Cough precedes hemoptysis	Vomiting of blood. Nausea and vomiting precedes hematemesis
History of cardiopulmonary disease	History of gastrointestinal disease
Bright red in color	Dark brown/coffee brown in color
Sputum remains blood stained after the attack for few days	Usually followed by melena
Mixed with sputum	Mixed with gastric contents
Blood is frothy due to admixture of air	Airless and not frothy
Alkaline	Acidic
Sputum contains hemosiderin laden macrophages	No
Melena absent	Melena present

Massive hemoptysis: Life-threatening (or) massive hemoptysis is defined as coughing of blood >150 mL/episode (or) >600 mL/24 hours. Only 5% of hemoptysis is massive but mortality is 80%. Clinical definition of massive hemoptysis is any bleeding that result in a threat to life because of airway or hemodynamic compromise due to bleeding. The different causes of massive hemoptysis are given in **Box 3C.2**.

Box 3C.2: Causes of massive hemoptysis.

- Pulmonary tuberculosis
- Pulmonary infarction
- Bronchiectasis
- Bronchogenic carcinoma
- Massive pulmonary embolism
- Cystic fibrosis
- Lung abscess
- Necrotizing pneumonia
- Mitral stenosis
- Pulmonary arteriovenous malformation

DYSPNEA

Definition

"Dyspnea" is a term used to characterize a subjective experience of breathing discomfort that is comprised of qualitatively distinct sensations that vary in intensity (undue awareness of unpleasant breathing).

Mechanism of Dyspnea

Chemoreceptors	
Peripheral	Carotid and aortic bodies (sensitive to changes pO_2, pCO_2 and H^+)
Central	Medulla (sensitive only to changes in pCO_2, not pO_2, change in pH of cerebrospinal fluid)
Increased work of breathing	
Airflow obstruction	Bronchial asthma, chronic obstructive pulmonary disease (COPD), tracheal obstruction
Decreased pulmonary compliance	Pulmonary edema, fibrosis, allergic alveolitis
Restricted chest expansion	Ankylosing spondylitis, respiratory paralysis, kyphoscoliosis
Increased ventilatory drive	
Increased physiological dead space (V/Q mismatch)	Consolidation, collapse, pleural effusion (PE), pulmonary edema
Hyperventilation due to receptor stimulation	
Chemoreceptors	Acidosis, hypoxia (shock, pneumonia), hypercapnia
J receptors at alveolocapillary junction	Pulmonary edema, pulmonary embolism, pulmonary congestion (activates Hering-Breuer reflex which terminates inspiratory effort before full inspiration is achieved—rapid and shallow)
Muscle spindles in intercostal muscles	Tension-length disparity
Central	Exertion, anxiety, thyrotoxicosis, pheochromocytoma
Impaired respiratory muscle function	
Diseases with impaired muscle function	Poliomyelitis, Guillain-Barre syndrome (GBS), myasthenia gravis

JAYPEE BROTHERS

TABLE 3C.7: Differences between paroxysmal nocturnal dyspnea (PND) orthopnea.

	Paroxysmal nocturnal dyspnea	*Orthopnea*
Definition	Episode of sudden onset of dyspnea 2–2.5 hours after sleep	Dyspnea in recumbent posture
Timing	Patient wakes up from rapid eye movement (REM) sleep	Occurs soon after lying down
Method of relief	Sits up with legs hanging down, stands up, air hunger, self-ventilates of comfort	Gets up, uses more pillows, sleeps in erect posture
Mechanism	Depressed respiratory center. Sympathetic overactivity during REM→ catecholamine surge resulting in tachycardia → interstitial pulmonary congestion → respiratory center lags behind → perceived as acute dyspnea. There is sudden transient increase in PCWP	Shifting of venous blood (>400 mL) into pulmonary circulation, V/Q mismatch, compression of diaphragm, postural diastolic dysfunction. There is a slow sustained rise in pulmonary capillary wedge pressure (PCWP)
Associated symptoms	Angina, perspiration, palpitation, rarely hemoptysis	All the symptoms of congestive cardiac failure (CCF)
Oxygen saturation	Transient hypoxia	Normal
Differential diagnosis	Night mares/panic attacks/nocturnal hypoglycemia/ obstructive sleep apnea (OSA)	COPD/gross obesity/ acute asthma/gross ascites

Orthopnea

Dyspnea develops in recumbent position and is relieved by sitting up or by elevation of the head with pillows.

The severity can be graded by the number of pillow used at night, e.g., three pillow orthopnea.

Pathophysiology of Orthopnea

- Pulmonary congestion during recumbency (cannot be pumped out of LV) seen in congestive heart failure (CHF), chronic obstructive pulmonary disease (COPD) and bronchial asthma.
- Increased venous return.
- Diaphragm elevation leading to decreased vital capacity.

Conditions Associated with Orthopnea

Orthopnea is classically seen in left heart failure but can also occur in constrictive pericarditis, COPD, bilateral diaphragmatic palsy, asthma triggered by gastric reflux, and gross ascites.

Paroxysmal Nocturnal Dyspnea

Attacks of dyspnea occur at night and awaken the patient from sleep. The important differences between orthopnea and PND are given in **Table 3C.7**.

Mechanism (Fig. 3C.2)

- It is due to decreased responsiveness of respiratory center in brain during sleep and pulmonary congestion (due to increased sympathetic activity during REM sleep), that occurs 2–3 hours after onset of sleep.
- Absorption of edema fluid with increase in right ventricular output causing over filling of the lungs.
- Takes 10–30 minutes for recovery after upright posture.
- Specific sign of LV dysfunction and includes ischemic heart disease, aortic valve disease, hypertension, cardiomyopathy.
- It has low sensitivity (<30%) but 75% specificity to diagnose heart disease.

Differential Diagnosis for Paroxysmal Nocturnal Dyspnea

- Left heart failure
- Nocturnal episodes of asthma
- Postnasal discharge with attendant severe cough
- Sleep apnea with arousal

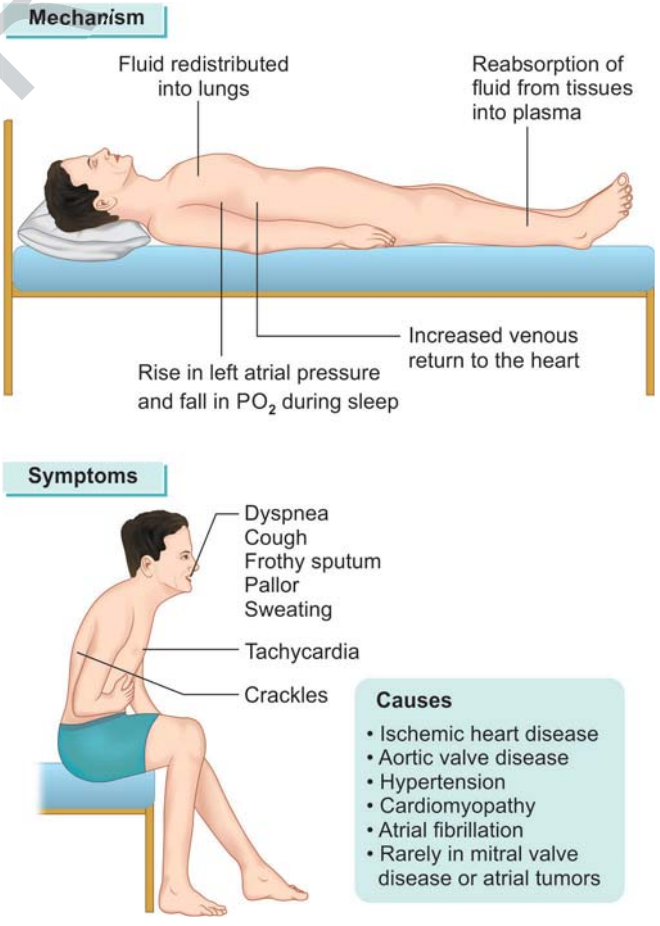

Fig. 3C.2: Mechanism of paroxysmal nocturnal dyspnea (PND).

JAYPEE BROTHERS

- Nightmares
- Nocturnal angina with dyspnea (angina equivalent)
- Nocturnal aspiration in gastroesophageal reflux disease
- Nocturnal episodes of recurrent minute pulmonary emboli
- Nocturnal hypoglycemia.

Trepopnea

Aggravation of dyspnea when lying on one side and relieved by lying on opposite side.

Causes

- **Unilateral lung disease:** Uninvolved normal lung receives more blood supply due to gravity.
- **Congestive heart failure:** Lying on right side enhances venous return and sympathetic activity.
- **Lung tumor:** Gravity-induced compression of blood vessels or lung.
- **Pleural effusion:** Dyspnea is seen when lying on unaffected side due to compression of healthy lung.

Platypnea

Dyspnea on sitting or standing and relieved by supine position.

Causes

- Venous to arterial shunting (lung bases)
- Intracardiac shunts (ASD, pneumonectomy)
- Intrapulmonary right to left shunt [hepatopulmonary syndrome, pulmonary embolism (PE), COPD]
- Acute respiratory distress syndrome (ARDS)
- Straight back syndrome
- Pericardial effusion or constrictive pericarditis.

Bendopnea

A newly described symptom in patients with heart failure is mediated via a further increase in ventricular filling pressures during bending in subjects whose sitting ventricular filling pressures are already high, particularly in patients with low cardiac index **(Fig. 3C.3)**.



Fig. 3C.3: A patient sits in a chair, bends at the waist, and touches his or her feet. Bendopnea is considered present if dyspnea occurs within 30 seconds of bending.

Causes of acute severe breathlessness is shown in **Box 3C.3**.

Box 3C.3: Acute severe breathlessness.

- Pulmonary edema
- Massive pulmonary embolism
- Acute severe asthma
- Acute exacerbation of COPD
- Severe pneumonia
- Tension pneumothorax
- Foreign body/mucous plug
- Epiglottitis (children)
- Metabolic acidosis
- Psychogenic

Approach to Dyspnea

Onset and duration	
Minutes to hours (rapid onset)	Pneumothorax, acute asthma, pulmonary embolism (PE), pulmonary edema, foreign body
Hours to days (gradual onset)	Pneumonia, pleural effusion, anemia, Guillain–Barre syndrome (GBS)
Months to years (slow onset)	Pulmonary tuberculosis (PTB), COPD, carcinoma, fibrosing alveolitis
Severity	
Medical Research Council (MRC) (Table 3C.8)	Discussed below
Modified Medical Research Council (mMRC) (Table 3C.9)	
New York Heart Association (NYHA) (Table 3C.10)	

Aggravating and relieving factors	
Improves on weekend/ holidays	Occupational asthma, extrinsic alveolitis
Recumbency/sleep	Orthopnea/paroxysmal nocturnal dyspnea (PND)
Associated symptoms (Table 3C.11)	
Pleuritic chest pain	Pneumonia, pulmonary infarction, rib fracture, pneumothorax
Central nonpleuritic chest pain	Myocardial infarction, massive pulmonary embolism
Cough or wheeze	Asthma, pulmonary embolism, pneumothorax

TABLE 3C.8: Medical Research Council (MRC) grading of breathlessness.

1. Note troubled by breathlessness except on strenuous exertion
2. Short of breath when hurrying on level ground or walking up slight hill
3. Walks slower than people of same age or stops after 15 minutes when walking at own pace on level
4. Stops after 100 yards (90 m) or after few minutes in level ground
5. Too breathless to leave house, dress or undress

JAYPEE BROTHERS

TABLE 3C.9: Modified Medical Research Council (MMRC) grading of breathlessness.

Grade	*Description of breathlessness*
Grade 0	I only get breathless with strenuous exercise
Grade 1	I get short of breath when hurrying on level ground or walking up a slight hill
Grade 2	On level ground, I walk slower than people of the same age because of breathlessness, or I have to stop for breath when walking at my own pace on the level
Grade 3	I stop for breath after walking about 100 yards or after a few minutes on level ground
Grade 4	I am too breathless to leave the house or I am breathless when dressing

TABLE 3C.10: New York Heart Association (NYHA) classification of breathlessness.

NYHA Class	*Patients with cardiac disease (description of heart failure related symptoms)*
Class I (Mild)	Patients with cardiac disease but without resulting in limitation of physical activity. Ordinary physical activity does not cause undue fatigue, palpitation, dyspnea or anginal pain
Class II (Mild)	Patients with cardiac disease resulting in **slight limitation** of physical activity. They are comfortable at rest. Ordinary physical activity results in fatigue, palpitation, dyspnea, or anginal pain
Class III (Moderate)	Patients with cardiac disease resulting in **marked limitation** of physical activity. They are comfortable at rest. Less than ordinary activity causes fatigue, palpitation, dyspnea or anginal pain
Class IV (Severe)	Patients with cardiac disease resulting in the inability to carry on any physical activity without discomfort. Symptoms of heart failure or the anginal syndrome may be present even at rest. If any physical activity is undertaken, discomfort is increased

Note: NYHA classification system is subjective and poorly reproducible.

TABLE 3C.11: Causes of acute and chronic dyspnea.

Acute dyspnea	*Chronic dyspnea*
Cardiovascular system	
Cardiogenic acute pulmonary edema	Chronic heart failure, myocardial ischemia
Respiratory system	
▪ Acute severe bronchial asthma ▪ Acute exacerbation of COPD ▪ Spontaneous pneumothorax ▪ Pneumonia ▪ Acute pulmonary embolism ▪ Acute respiratory distress syndrome ▪ Inhaled foreign body (especially in children) ▪ Lobar collapse ▪ Laryngeal edema (e.g., anaphylaxis) or obstruction	▪ Chronic obstructive pulmonary disease (COPD) ▪ Chronic bronchial asthma ▪ Bronchial carcinoma ▪ Interstitial lung disease (e.g., sarcoidosis, fibrosing alveolitis, extrinsic allergic alveolitis, pneumoconiosis) ▪ Chronic pulmonary thromboembolism ▪ Lymphatic carcinomatosis ▪ Large pleural effusion(s) ▪ Severe anemia ▪ Obesity ▪ Deconditioning

Contd...

Contd...

Nonrespiratory, noncardiac causes	
Metabolic acidosis (e.g., diabetic ketoacidosis, lactic acidosis, uremia, overdose of salicylates, ethylene glycol poisoning)	Psychogenic hyperventilation (anxiety or panic-related)

Pitfalls of mMRC Grading

- The mMRC dyspnea scale quantifies disability attributable to breathlessness, and is useful for characterizing baseline dyspnea in patients with respiratory diseases.
- It describes baseline dyspnea, but does not accurately quantify response to treatment of COPD.

TIMING OF DYSPNEA

The timing and pattern of respiration helps to determine the structure most likely responsible for the dyspnea. Dyspnea may occur during inspiration, expiration or both (mixed). Clinically inspiratory dyspnea implies a lesion in the respiratory tract outside the thorax, whereas expiratory and mixed dyspnea occur in patients with thoracic or metabolic disease. Expiratory dyspnea should be further classified as obstructive or restrictive.

Causes of inspiratory dyspnea	*Causes of obstructive expiratory dyspnea*
▪ Stenotic nares ▪ Gross deviated nasal septum ▪ Nasal polyps ▪ Rhinosinusitis ▪ Enlarge adenoids in young children ▪ Foreign body aspiration ▪ Laryngotracheal trauma ▪ Tonsillar hypertrophy ▪ Peritonsillar abscess ▪ Retropharyngeal abscess ▪ Vocal cord/vocal fold palsy ▪ Acute laryngotracheitis ▪ Epiglottitis ▪ Pertussis ▪ Spasmodic croup	▪ Tracheal collapse ▪ Tracheobronchitis ▪ Foreign body ▪ Neoplasia ▪ Enlarged lymph nodes ▪ Enlarged left atrium ▪ Asthma ▪ COPD
Causes of noisy restrictive dyspnea	*Causes of silent restrictive expiratory dyspnea*
▪ Pulmonary edema ▪ Pneumonia ▪ Pulmonary fibrosis ▪ Neoplasia ▪ Pulmonary infarction ▪ Pulmonary embolism ▪ Ascites ▪ Pregnancy ▪ Organomegaly ▪ Gastric dilatation—volvulus ▪ Neoplasia	▪ Pneumothorax ▪ Pleural effusion ▪ Thickened pleura ▪ Diaphragmatic hernia ▪ Chest tumors

JAYPEE BROTHERS

CHEST PAIN

Chest pain discussed in detail under Chapter 4.

Respiratory Causes

- Upper sternal—tracheitis
- Pleuritic—associated with breathing
- Neurologic—invasion of nerves.

Pleuritic chest pain is characterized by sudden and intense sharp, stabbing, or burning pain in the chest when inhaling and exhaling. It is exacerbated by deep breathing, coughing, sneezing, or laughing. When pleuritic inflammation occurs near the diaphragm, pain can be referred to the neck or shoulder. Pleuritic chest pain is caused by inflammation of the parietal pleura (dry pleurisy) and can be triggered by a variety of causes.

Pulmonary embolism, myocardial infarction, pericarditis, aortic dissection, pneumonia, and pneumothorax are the six serious conditions that cause pleuritic pain.

- Chest tightness also known as chest pressure. It is combination of dull chest pain as well as chest discomfortness. Common causes of chest tightness are high blood pressure, asthma, COPD and gastroesophageal reflux disease (GERD).

OTHER SYMPTOMS

Noisy breathing (partial obstruction of airway):

Laryngeal level	Stridor (inspiratory sound)
Oropharyngeal level	Stertor
Tracheal level	Rattling
Bronchial level	Wheezing (inspiratory/expiratory)

Hoarseness of voice:

- Inflammatory: Acute and chronic laryngitis
- Smoke inhalation
- Neoplastic: Carcinoma/laryngeal papillomatosis
- Recurrent laryngeal nerve damage: Post-thyroidectomy carcinoma of lung/breast
- Neurological: Myasthenia gravis, hypothyroidism
- Rheumatoid arthritis: Involvement of cricoarytenoid joint
- Habitual dysphonia
- Reinke's dysphonia
- Singer's nodules/vocal cord polyps
- Gastroesophageal reflux disease (GERD).

Hiccoughs

Respiratory causes include basal pneumonia and pleurisy.

Snoring

Feature of obstructive sleep apnea.

JAYPEE BROTHERS

NOTES

JAYPEE BROTHERS

D. DISCUSSION ON EXAMINATION

GENERAL EXAMINATION

Built and Nourishment

Body mass index (BMI), anthropometry has been discussed in detail in Chapter 2D of general examination.

Respiratory diseases associated with emaciation:
1. Respiratory diseases associated with HIV
2. Pulmonary tuberculosis
3. Malignancy.

Pickwickian syndrome (obesity hypoventilation syndrome):
1. Obesity
2. Hypoxia
3. Pulmonary HTN.

Vital Examination (with Respect to Respiratory System)

Pulse:
- Rate—tachycardia (any pneumonia, febrile illness, hypoxia)
- Irregular pulse seen in multifocal atrial tachycardia, atrial fibrillation
- Bounding pulse—CO_2 retention
- Pulsus paradoxus—acute exacerbation of COPD/asthma.

Respiratory rate:
(For details on respiratory rate refer chapter on vitals examination).

Blood pressure:
- Wide pulse pressure—in hypercapnia
- Low blood pressure—seen with hypoxia, acute respiratory distress
- Postural hypotension—Addison's disease, paraneoplastic.

Jugular venous pressure:
- Elevated: In cor pulmonale, tricuspid regurgitation. Pulmonary hypertension
- Nonpulsatile jugular venous pressure (JVP): Superior vena cava (SVC) obstruction.

Temperature:
- Evening rise of temperature: Tuberculosis
- High spiking fevers: Lung abscess, empyema, pneumonias.
- Temperature fall by crisis: Pneumonias.

Pallor:
- Tuberculosis
- Malignancy
- Any cause of massive hemoptysis.

Polycythemia:
Chronic respiratory diseases with underlying hypoxia are usually associated with polycythemia.

So, if patient with COPD has anemia look for other causes like GI bleed, CKD or coexistent malignancy.

Icterus:
- Hepatitis secondary to antitubercular (ATT) drugs
- Atypical pneumonias (hemolytic jaundice)
- Cor pulmonale—congestive hepatomegaly
- As a part of multiple organ dysfunction syndrome (MODS)
- Rarely metastasis to liver.

Edema:
- Cor pulmonale
- Bronchiectasis leading to hypoproteinemia (due to loss of protein in the sputum and nephrotic syndrome secondary to amyloidosis)—100 mL of sputum can cause 3–4 g of protein loss.
- Hypercapnia-induced dilation of the precapillary sphincters.
- Reduced renal blood flow with relatively preserved glomerular filtration rate and elevated levels of renin, aldosterone, arginine vasopressin and atrial natriuretic peptide.

Cyanosis, clubbing, and lymphadenopathy described in detail in the Chapter 2D of general examination.

Lymphatic drainage of lung	
Most of the lung (right upper lobe, right middle lobe, right lower lobe, left lower lobe)	Right tracheobronchial → right bronchomediastinal → right supraclavicular lymph node
Left upper lobe	Left tracheobronchial → left bronchomediastinal → left supraclavicular lymph node
Lymphatic drainage of pleura (Fig. 3D.1)	
Cervical pleura	Axillary lymph nodes
Parietal pleura	▪ Anterior: Internal mammary nodes ▪ Posterior: Extrapleural nodes
Diaphragmatic pleura	▪ Internal mammary nodes, cardiophrenic nodes ▪ Para-aortic, intercostal and posterior mediastinal nodes
Mediastinal pleura	Internal mammary nodes

Oral Cavity Examination

- Halitosis seen in suppurative lung diseases
- Tobacco staining of the teeth
- Poor oral hygiene
- Oral markers of malignancy—leukoplakia, erythroplakia, submucous fibrosis.
- Cyanosis or polycythemia.
- Oral candidiasis—due to inhaled steroids.
- Posterior pharyngeal wall/tonsils—infection.

External markers of tuberculosis:
- Matted lymph nodes
- Erythema nodosum

JAYPEE BROTHERS

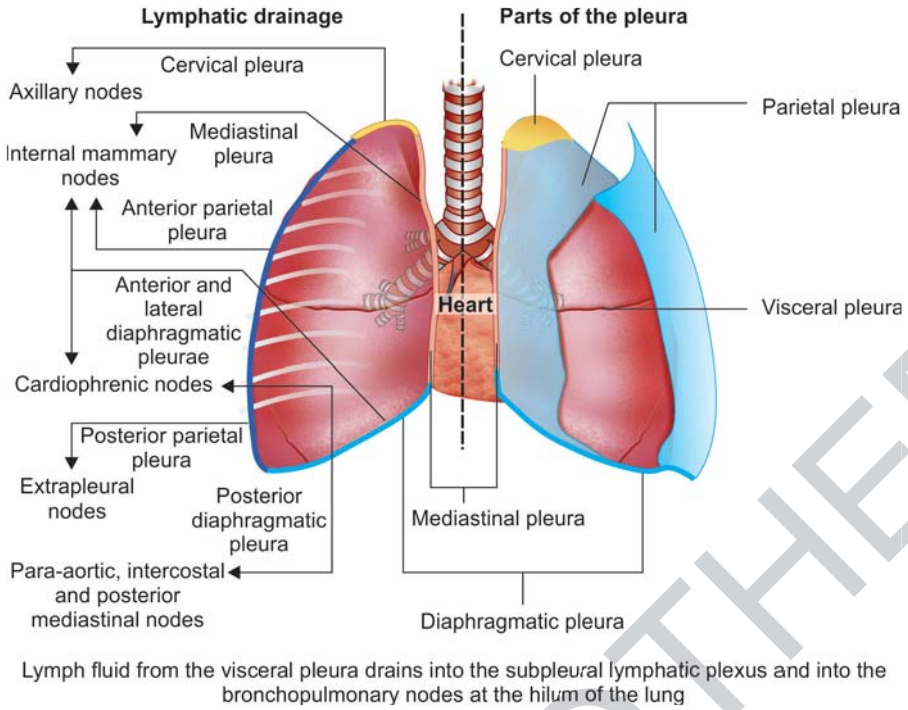

Fig. 3D.1: Parts of pleura with corresponding lymphatic drainage.

- Phlyctenular conjunctivitis
- Choroid tubercle
- Discharging sinuses
- Scrofuloderma
- Lupus vulgaris, tuberculids
- Beaded vas deferens
- Positive Mantoux test
- Generalized tinea versicolor
- Uveitis.

External markers of malignancy:

- Cachexia
- Grade IV clubbing (HPOA)
- Hard lymph nodes
- Acanthosis nigricans
- Horner's syndrome
- Superior vena cava (SVC) obstruction features—non-pulsatile, dilated jugular venous pressure (JVP), facial flushing and edema, conjunctival suffusion, papilledema, dilated veins on the chest wall.

Features of respiratory failure:

	Type 1	*Type 2*
Definition	Hypoxemic respiratory failure (type 1) is characterized by an arterial oxygen tension (PaO_2) lower than 60 mm Hg with a normal or low arterial carbon dioxide tension ($PaCO_2$)	Hypercapnic respiratory failure (type 2) is characterized by a $PaCO_2$ higher than 50 mm Hg
Sensorium	Anxious agitated	Drowsy to comatose

Contd...

Contd...

Peripheries	Cold	Warm
Pulse	Feeble	Bounding
Blood pressure	Low	Wide pulse pressure
Cyanosis	+	–
Asterixis	–	+
Respiratory rate	Tachypneic	Normal to low
Papilledema	–	+
Cause	▪ ARDS ▪ Pneumonia ▪ Acute severe asthma ▪ Tension pneumothorax	▪ COPD ▪ Obesity ▪ Respiratory muscle paralysis
Type 3 (perioperative): Functional residual capacity falls below closing volume as a result of atelectasis in postoperative patients. This is generally a subset of type 1 failure but is sometimes considered separately because it is common		
Type 4 (shock): Secondary to cardiovascular instability like in severe septic shock, causing hypoperfusion of respiratory muscles leading to hypercapnia and hypoxia		

Features of Cor Pulmonale

Right ventricular dilatation:

- Parasternal heave
- Epigastric pulsation.

Right ventricular failure:

- Raised JVP
- Pedal edema
- Tender hepatomegaly
- Ascites
- Sustained abdominojugular reflux is first sign of RVF.

JAYPEE BROTHERS

EXAMINATION OF RESPIRATORY SYSTEM

Examination of Upper Respiratory Tract

Demarcation of upper and lower respiratory tract:

- Externally: Demarcated by cricoid cartilage
- Internally: Demarcated by glottis.

Nose

- Deviated nasal septum
- Nasal flaring (outward inspiratory motion of the nares) is a valuable sign of respiratory distress
- Nasal polyps may be seen in:
  - Asthma (atopic variety)
  - Allergic bronchopulmonary aspergillosis (ABPA)
  - Cystic fibrosis
  - Wegener's granulomatosis
- Color of nasal mucosa
  - Pale and moist mucosa found in allergic rhinitis
  - Swollen and red mucosa found in chronic rhinitis
- Nasal discharge
  - Bilateral
    - Mucoid nasal discharge found in allergic rhinitis
    - Watery nasal discharge found in vasomotor rhinitis
    - Purulent nasal discharge found in bacterial infection, such as after common cold, in localized sinus infection and rhinosinusitis.
  - Unilateral
    - Purulent discharge found when there is a foreign body in the nose.
    - New onset, unilateral, crystal clear discharge following head injury suggests a cerebrospinal fluid leak.
- Epistaxis
  - Trauma, rhinitis, hypertension, impaired coagulation from disease, drug induced, i.e., anticoagulants, nonsteroidal anti-inflammatory drugs and alcohol excess.

Throat (Oropharynx)

Postnasal drip resembles like cobblestone: Caused by various medical conditions including sinusitis (inflammation of the sinuses), viral infections such as the common cold, rhinitis (a runny nose that may be acute or chronic), allergies, or bacterial infections, reflux, or gastroesophageal reflux disease.

Significant findings in the upper respiratory tract:

- Nasal turbinate hypertrophy or polyps causing airway obstruction
- Sinus tenderness suggestive of sinusitis
- Kartagener's syndrome:
  - Recurrent sinusitis with ciliary dyskinesia
  - Bronchiectasis
  - Situs inversus
  - Male infertility
- Granulomatosis with polyangitis (GPA)
  - Necrotizing granulomas of the upper airway
- Samter's triad
  - Aspirin sensitivity
  - Bronchial asthma
  - Ethmoidal polyps
- Young's syndrome
  - Sinopulmonary disease
  - Azoospermia
- Eosinophilic granulomatosis with polyangiitis (EGPA)
  - Asthma/allergic rhinitis
  - Eosinophilia
  - Vasculitis
  - Granuloma

Inspection (Lower Respiratory Tract)

Surface marking of lung:

Right side 3 lobes	*Left side 2 lobes*
1. Right upper lobe (RUL) 2. Right middle lobe (RML) 3. Right lower lobe (RLL)	1. Left upper lobe (LUL) 2. Left lower lobe (LLL)

Demarcating lower lobe of either side (Figs. 3D.2 to 3D.5):
Lower lobe of either lungs can be demarcated from other lobes by drawing a curvilinear line (major interlobar fissure/oblique fissure) joining three bony points:

1. Starting from T2/T3 spinous process, curvilinear line along the medial border of scapula
2. Crossing the 5th rib in the midaxillary line
3. Reaching the 6th rib in midclavicular line part of lung below this line is lower lobe.

Marking right middle lobe:
Draw a straight line (minor interlobar fissure/horizontal fissure) from the 4th rib at right sternal border towards the midaxillary line cutting the major interlobar fissure at 5th rib. The triangular area represents RML.

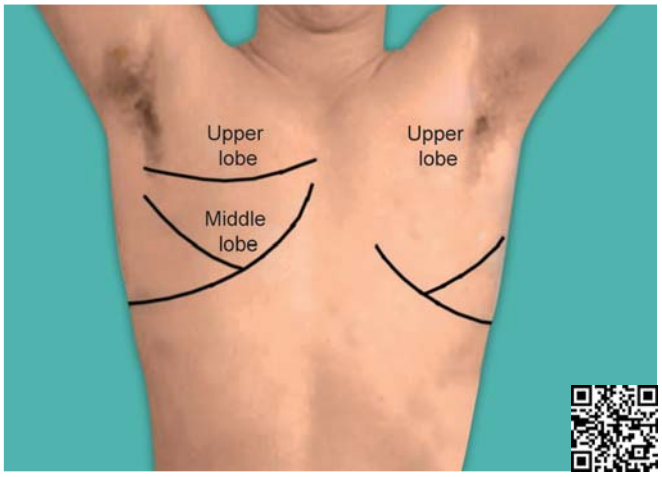

Fig. 3D.2: Anterior view of chest showing surface marking of lung fissures and lobes.

JAYPEE BROTHERS

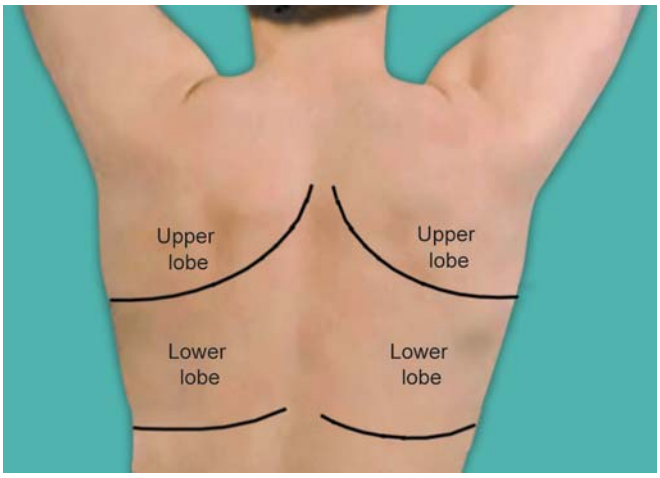

Fig. 3D.3: Posterior view of chest showing surface marking of lung fissures and lobes.

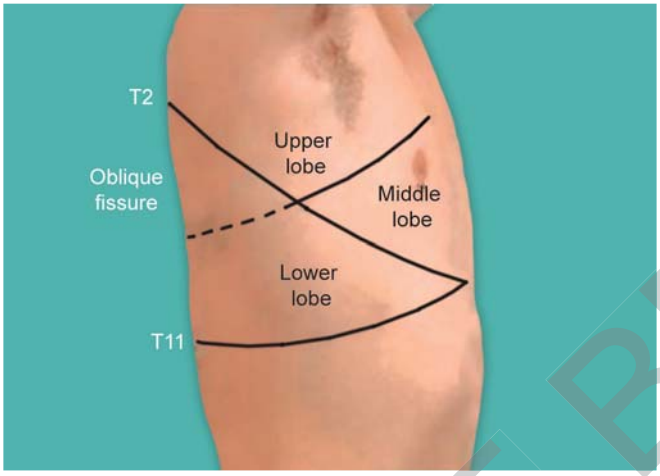

Fig. 3D.4: Right lateral view of chest showing right major interlobar (IL) fissure and right minor IL fissure.

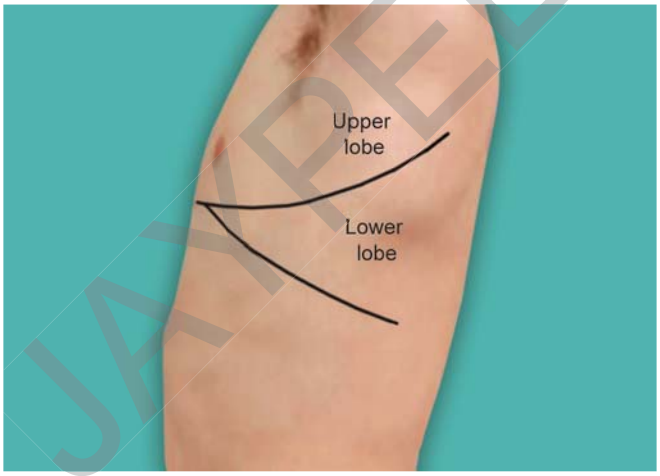

Fig. 3D.5: Left lateral view of chest showing left major interlobar fissure.

Level of lower border	*Midclavicular line*	*Midaxillary line*	*Scapular*
Lung (Figs. 3D.6 and 3D.7)	6th rib	8th rib	10th rib
Pleura	8th rib	10th rib	12th rib

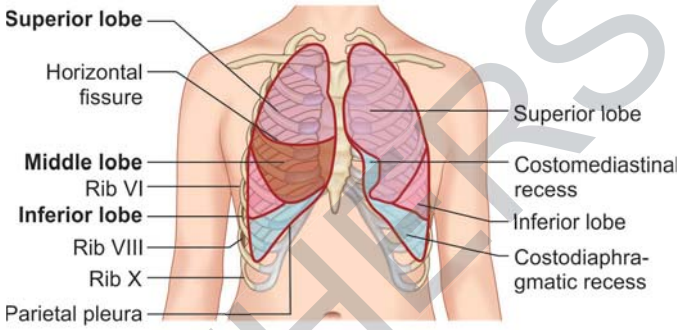

Fig. 3D.6: Lower margin of lung in midclavicular line and midaxillary line.

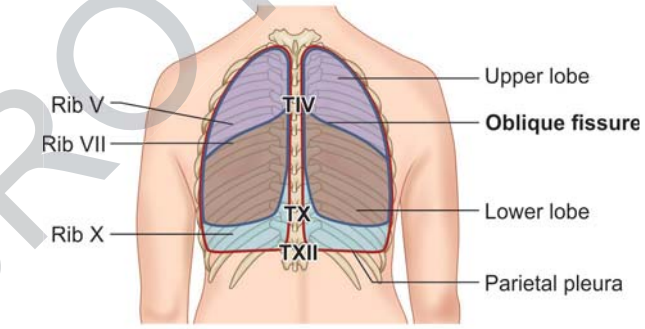

Fig. 3D.7: Lower margin of lung in scapular line.

Examination of chest:

Front examination	*Back examination*	*Axillary examination*
Predominantly to look for upper and middle lobe	Predominantly to look for lower lobe pathology	All three lobes can be assessed
Examined with patient in upright sitting position with hand by the side	Examined with patient in sitting upright with hands placed on the opposite shoulder and neck flexed	Examined with patient in the sitting position with hands raised above the shoulder and placed on the occiput

Position of patient during examination can be:

- Sitting—most of the examination is done in this position
- Standing—spine and shoulder droop
- Supine—shifting dullness.

JAYPEE BROTHERS

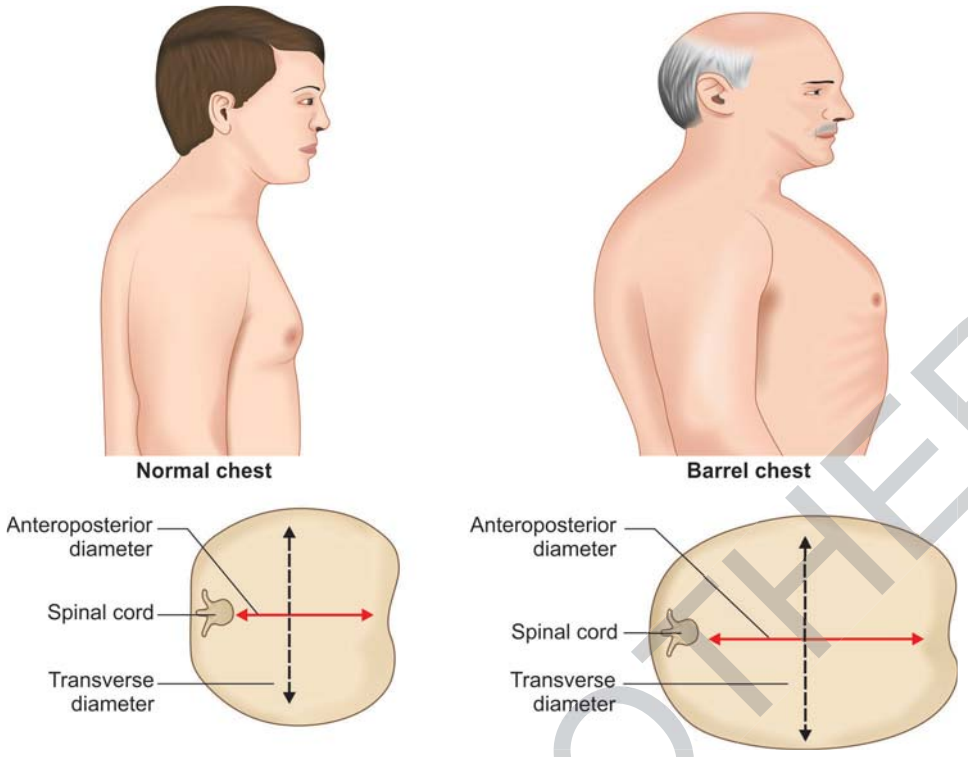

Fig. 3D.8: Normal- and barrel-shaped chest.

Normal chest (Fig. 3D.8):

- Spine—central
- Shape
  - Circular—infants and early childhood
  - Elliptical—adults
  - Circular—old age
- Vertical length > transverse diameter > AP diameter
- Transverse: AP = 7:5 (called as **Hutchinson's index**)
- Subcostal angle ≤90 (more acute in males).

Deformities of chest	
1. Flat chest (alar chest)	Anterioposterior ratio is 2:1
2. Pectus carinatum (Fig. 3D.9) (pigeon chest/keel chest)	Forward protrusion of sternum seen in rickets and childhood respiratory disease like asthma. Can also be seen in Marfan syndrome
3. Pectus excavatum (Fig. 3D.9) (funnel chest, cobbler's chest)	Funnel like depression at the lower end of the chest, seen in Marfan syndrome. Displaces the heart to the left. Ventilation capacity of the lung is restricted
4. Rachitic chest	▪ Funnel shaped ▪ Keel breast ▪ Harrison sulci (horizontal groove where the diaphragm attaches to the ribs—seen in rickets, chronic asthma and COPD) ▪ Vertical grooves on either side of sternum ▪ Rachitic rosary (bead like enlargement of costochondral junction especially 4/5/6 ribs)—painless and seen in vitamin D deficiency

Contd...

Contd...

5. Scorbutic rosary	▪ Sharp angulation of the ribs arising due to backward displacement of sternum ▪ Painful and seen in vitamin C deficiency
6. Barrel-shaped chest (Fig. 3D.8)	COPD—emphysema ▪ Anteroposterior: Transverse diameter is 1:1 ▪ Exaggerated thoracic kyphosis ▪ Wide subcostal angle
7. Phthinoid chest	Combination of alar and flat chest
8. Flail chest	Paradoxical movement of the chest in fracture of 3 or more consecutive ribs
9. Shield-like chest	Turner's and Noonan syndrome

Asymmetry of chest	
Deformity of spine	▪ Scoliosis ▪ Kyphoscoliosis ▪ Gibbus
Unilateral bulge	▪ Pleural effusion ▪ Pneumothorax ▪ Compensatory hypertrophy ▪ Malignancy of lung or pleura
Unilateral flattening	▪ Fibrosis ▪ Collapse ▪ Fibrothorax ▪ Pneumonectomy ▪ Agenesis of one lung (McLeod's syndrome/Swyer–James syndrome) ▪ Mastectomy ▪ Absent pectoralis major (Poland's syndrome)

Contd...

JAYPEE BROTHERS

Contd...

Local bulging (fullness)	▪ Supraclavicular fullness (pancoast tumor/lymphadenopathy/ massive pleural effusion/tension pneumothorax) ▪ Empyema necessitans (cough impulse present) ▪ Aortic aneurysm ▪ Malignant infiltration ▪ Pericardial effusion ▪ Surgical emphysema
Local retraction	▪ Apical tuberculosis (**Morenheims** fossa/infraclavicular fossa) ▪ Lung fibrosis

Trachea:
Normally central or slightly deviated to right.

Trail sign (Fig. 3D.10):
In the presence of tracheal deviation, there is prominence of the clavicular head of sternocleidomastoid of same side. The investing layer of cervical fascia splits to enclose the sternocleidomastoid and then falls back and continues as the pretracheal fascia. When there is tracheal shift to one side, the fascia covering the ipsilateral sternocleidomastoid relaxes. The sternocleidomastoid goes into a state of contraction making the clavicular head prominent.

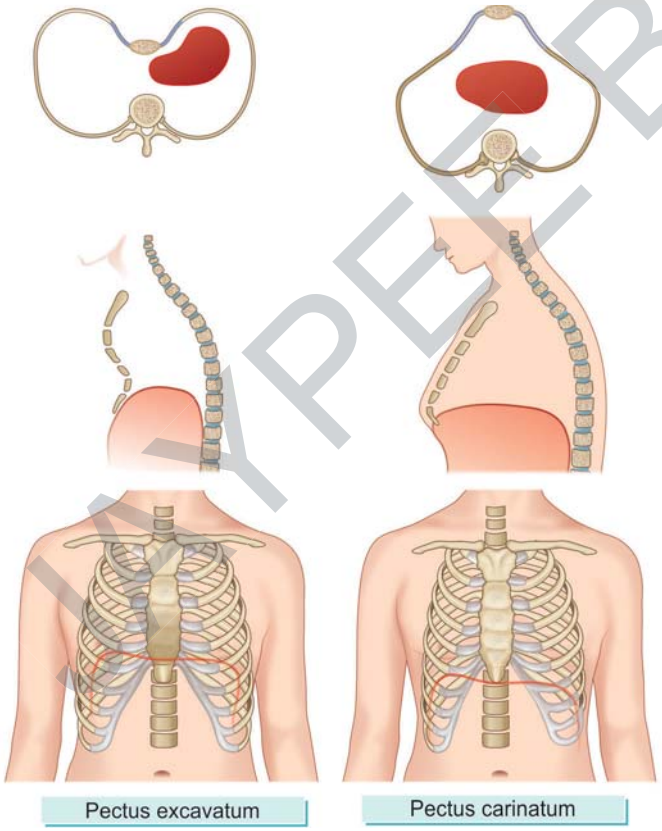

Fig. 3D.9: Pectus excavatum and pectus carinatum.

- Clinical implication of tracheal shift: It suggests upper mediastinal shift.
- Indicates upper lobe fibrosis or collapse.

Apical impulse:
- Normally 10 cm from sternal margin or ½ inch medial to Mid clavicular line.
- Clinical implication: Suggests lower mediastinal shift.

Examination of drooping of shoulder (Fig. 3D.11):
Examine the standing patient from behind to look for position of shoulder. Drooping of shoulder indicates volume loss on that side (collapse/fibrosis/fibrothorax/pneumonectomy). Rarely, it can be seen with paralysis of trapezius.

Associated features include:
- Prominent medial border of scapula on the affected side
- Space between medial border of scapula and spine is decreased
- Inferior angle of scapula is at the lower level (normally it is at level of T7 vertebra).

Examination of spine:
- Look for position of spine
- Look for scoliosis/kyphosis/lordosis/gibbus **(Figs. 3D.12A and B)**
- In emphysema there is exaggerated thoracic kyphosis.



Fig. 3D.10: Trail sign showing undue prominence of sternocleidomastoid on the right side due to tracheal shift to right.

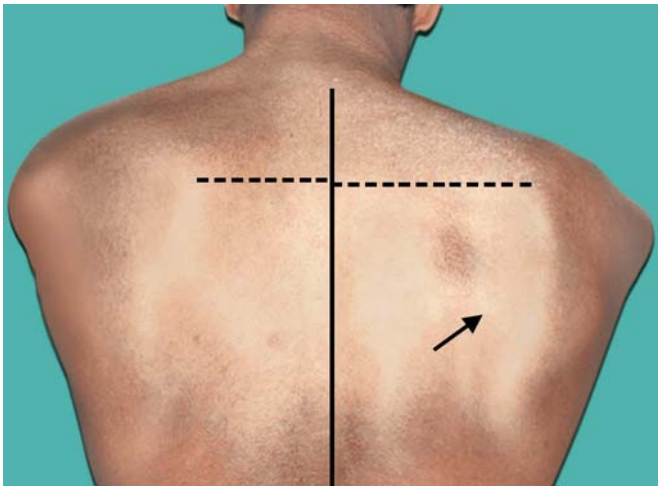

Fig. 3D.11: Shoulder drooping on right side.

JAYPEE BROTHERS

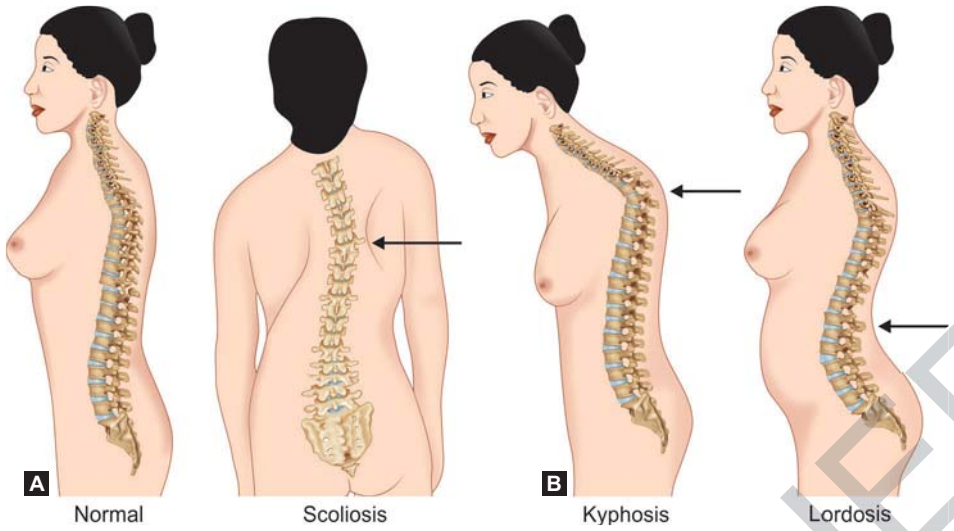

Figs. 3D.12A and B: Spine deformities.

Causes of scoliosis	
Neuromuscular causes	▪ Spina bifida ▪ Marfan syndrome ▪ Cerebral palsy ▪ Friedreich's ataxia ▪ Spinocerebellar degeneration ▪ Charcot-Marie-Tooth disease ▪ Syringomyelia ▪ Poliomyelitis ▪ Muscular dystrophy (Duchenne's, facioscapulohumeral, myotonic dystrophy)
Degenerative	▪ Osteoporosis ▪ Postspine surgery
Osteopathic	Klippel Feil syndrome
Congenital scoliosis	▪ Down's syndrome ▪ Prader-Willi syndrome
Respiratory diseases	▪ Fibrosis ▪ Fibrothorax
Idiopathic	—

Contd...

Contd...

Differentiation of congenital versus acquired scoliosis: On bending forwards acquired scoliosis disappears but congenital scoliosis persists.

Respiratory movements: (describe as equal/diminished in a particular area).

Abnormal signs in respiratory system	
1. Sitting up and catching the edge	Described in COPD where the patient sits up and fixes shoulders to use latissimus dorsi for expiration
2. Tripod position (Fig. 3D.13A)	Patient is sitting in leading forward posture with their outstretched hands on their knees. This position fixes and lifts the shoulder girdle and improves the function of pectoralis major and minor
3. Hoover sign	Paradoxical inspiratory indrawing of lateral rib cage (costal margin). It is a sign of chronic airflow obstruction. Pulmonary hyperinflation leads to loss of apposition of the diaphragmatic fibers resulting in horizontal orientation of fibers. When these horizontally oriented fibers contract, the costal margins get pulled inwards
4. Pursed lip breathing (Fig. 3D.13B)	Seen in COPD to increase the intra-alveolar pressure to maintain a positive intraluminal pressure which reduces the airway collapse, airway resistance and residual volume and hence improves ventilation
5. Dahl's sign	Patches of hyperpigmentation/bruising above the knees due to constant tenting position of the hands and elbows
6. Litten's sign	To look for the diaphragmatic movement, sit to one side of the patient lying in supine position and look at the diaphragmatic movements
7. Excessive usage of SCM and scalene	COPD or asthma
8. Paradoxical respiration	Indrawing of abdominal wall when the rib cage moves outwards. Best felt by bimanual palpation with one hand over the patient's chest and other on the abdomen. Indicates respiratory muscle weakness

JAYPEE BROTHERS

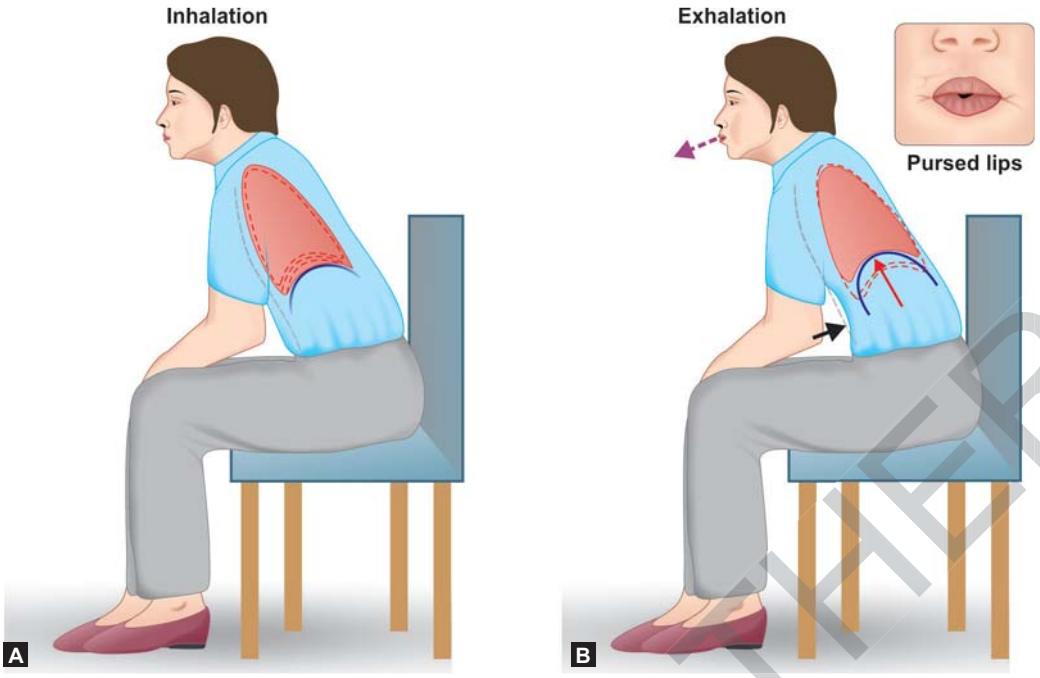

Figs. 3D.13A and B: Tripod position with pursed lip breathing.



Fig. 3D.13C: Intercostal retractions.

Inspiratory intercostal retraction (Fig. 3D.13C):
Mild degree of intercostal retraction in the lower chest is normal. Bilateral lower intercostal retractions is seen in COPD.

Unilateral intercostal retraction	Bilateral intercostal retraction
▪ Collapse ▪ Fibrosis ▪ Adherent pericarditis (**Broadbent's sign**—indrawing of lower anterior chest wall with each ventricular systole)	▪ Indicates upper airway obstruction (adenoids/foreign body) ▪ Hyperinflation of chest (COPD)

Visible pulsations/scars/sinuses:

Visible pulsation or vessels	
Collaterals around scapula	Coarctation of aorta (**Suzman's sign**)
Engorged veins over the anterior part of chest	**SVC obstruction seen in** ▪ Bronchogenic carcinoma ▪ Mediastinal growth ▪ Mediastinal lymph nodes ▪ Aortic aneurysm ▪ Chronic mediastinal fibrosis
Pulsatile swelling in anterior chest wall	Aortic aneurysm
Visible scars	
▪ Previous surgery (lobectomy) ▪ Pleural fluid aspiration site ▪ Lymph node biopsy site	
Sinuses	
▪ Abscess draining points ▪ Empyema thoracis (usually in tuberculosis/actinomycosis)	

Palpation (Lower Respiratory Tract)

Trachea:

- Normal length: 4–5 cm above suprasternal notch
- Normal cricoid to suprasternal notch distance is 3–4 finger breadth (decreased in COPD due to hyperinflation).

JAYPEE BROTHERS

Method of palpation for tracheal position:

Keep the index and ring finger of the right hand on medial ends of the clavicle

↓

With middle finger trace the trachea from above downwards **(Fig. 3D.14)**

↓

Then, insinuate the middle finger between the trachea and sternal head of sternocleidomastoid, and feel for resistance **(Fig. 3D.15)**

Note: **Implication of tracheal shift**—upper mediastinal shift



Fig. 3D.14: Tracing the trachea down with the middle finger.



Fig. 3D.15: Insinuate the middle finger between the trachea and sternal head of sternocleidomastoid, and feel for resistance.

Oliver's sign (tracheal tug sign) (Fig. 3D.16):
Stand behind patient and hold cricoid cartilage give a slight upward thrust.

Positive test	Downward pull with each heart beat suggestive of aortic aneurysm
Negative test	Normal
False positive	Mediastinal tumor attached to abdominal aorta
False negative	Thrombosed aortic aneurysm



Fig. 3D.16: Demonstration of Oliver's sign.

- **Tracheal descent on inspiration (Campbell sign):** Due to downward pull of the depressed diaphragm in long standing hyperinflation of lung.
- **Laryngeal fixation:** Increased pressure on cricoid cartilage due to inflammatory or neoplastic lesion in mediastinum.

Apical impulse:
- Confirm the position of apex
- Comment on character
- Watch for thrills and other palpable heart sounds
- **Implication of apical impulse shift:** It suggests lower mediastinal shift.

Apex not felt/seen in respiratory diseases:
1. Emphysema
2. Left-sided pleural effusion
3. Left-sided pneumothorax.

Mediastinal shift with respect to respiratory diseases	
Shift to same side	▪ Fibrosis ▪ Collapse ▪ Pneumonectomy/lobectomy
Shift to opposite side	▪ Pleural effusion ▪ Pneumothorax ▪ Tumor or mass
No shift of mediastinum	Unilateral disease ▪ Pneumonia Bilateral disease ▪ COPD ▪ Asthma ▪ Bronchiectasis ▪ Interstitial lung disease

Examination of respiratory movements	
Upper anterior chest (Figs. 3D.17A and B)	▪ Examined by placing the palms in the infraclavicular areas ▪ Look for superior anterior movement of the palms ▪ This examines the **pump handle** movement of the upper lobes

Contd...

JAYPEE BROTHERS

for detailed information on medicine books, visit our website www.ejaypee.com, for detailed information on medicine books, visit our website www.ejaypee.com, for detailed

An Insider's Guide to
CLINICAL MEDICINE

Salient Features

- Authored and peer-reviewed by experienced bedside teachers
- Infused with real-world clinical challenges and practical insights
- Crafted with the intention to help students prepare for practical examinations and vivas
- Clinically oriented format focusing on symptoms, signs, and differential diagnoses
- Clear instructions on how to examine systems and do's and don'ts
- High-quality visuals of clinical sign demonstration, ECGs, and X-rays
- Includes "How to Present a Case" templates of each system
- Prepares students for new MBBS curriculum and PG curriculum as per NMC
- QR codes for video demonstrations of examinations

Archith Boloor MBBS MD (Internal Medicine) is Additional Professor and HOU, Department of Medicine, Kasturba Medical College, Mangaluru, Karnataka, India. His passion for teaching of more than 17 years has trickled into multiple books such as: *Exam Preparatory Manual for Undergraduates—Medicine, An Insider's Guide to Clinical Medicine, Mastering Medicine—MRCP Made Easy, Antibiotic Basics for Clinicians—The ABCs of Choosing the Right Antibacterial Agent—SAE, Comprehensive Medicine for Dental Students, ABC of ECG, An Insider's Guide to Cases in Clinical Medicine, The Washington Manual of Medical Therapeutics—SAE, An Insider's Guide to OSCE in Medicine*, and *Mastering MCQs in Medicine*. He is also a frequent researcher, having more than 70 research publications, many in high impact journals such as Nature and The Lancet. He has been awarded the "Best Outgoing Student in Internal Medicine" during his MD in 2008. He has received awards for contribution to medical research eight times and the "Best Teacher Award" six times in Kasturba Medical College.

Anudeep Padakanti MBBS MD (Internal Medicine) DM (Medical Oncology) has done his graduation from Osmania Medical College in Hyderabad, Telangana, India. He has done his postgraduation from Kasturba Medical College, Manipal Academy of Higher Education, Mangaluru, Karnataka, India and DM from Medical Oncology from MNJ Institute of Oncology and Regional Cancer Centre, Hyderabad. During his postgraduate course, he developed interest in teaching and used to take classes for the fellow and junior postgraduates along with undergraduates. In this process, he has developed his unique skills in teaching and formatting notes. He has contributed chapters for *Exam Preparatory Manual for Undergraduates—Medicine, Mastering Medicine—MRCP Made Easy,* and *The Washington Manual of Medical Therapeutics (South Asian Edition)*. With his unique perception toward medical education, he has made this book a palatable delight for all students.

Shelving Recommendation
MEDICINE

ISBN 978-93-6616-760-2

Buy from ejaypee

JAYPEE BROTHERS