rmation on cardiology books, visit our website www.jaypeebrothers.com, for detailed information on cardiology books, visit our website www.jaypeebrothers.com

Volume 2

rmation on cardiology books, visit our website www.jaypeebrothers.com, for detailed information on cardiology books, visit our website www.jaypeebrothers.com

Volume 1

Cardiological Society of India

CARDIOLOGY

UPDATE 2024



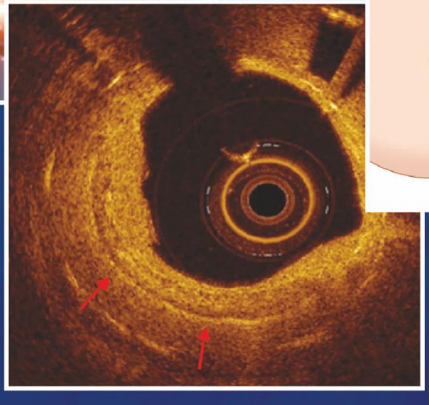

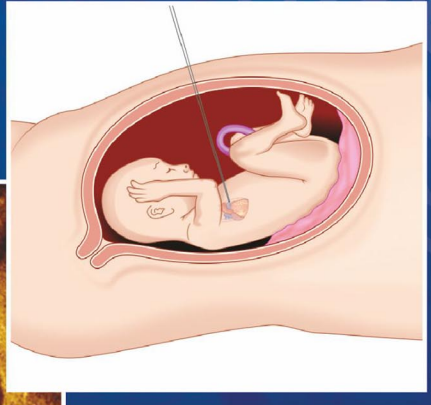

Editor-in-Chief
Sanjay Tyagi

JAYPEE

Contents

VOLUME 1

SECTION 1: GENERAL CARDIOLOGY

1. **Cardiovascular Disease Epidemic in India** 3
   Debabrata Biswas, Debabrata Roy

2. **Epidemiology of Coronary Heart Disease in India and Important Risk Factors: Recent Evidence** 9
   Rajeev Gupta, Kiran Gaur

3. **Recent Trials in Cardiology** 19
   Subrahmanya Murti V, Vinay Kumar Bahl

4. **Genetic Testing in Cardiovascular Disorders** 27
   Ajay Bahl

5. **Cardiovascular Symptoms: Assessment and Interpretation** 31
   Vivek Narasimha V, Dayasagar Rao V

6. **Dynamic Auscultation** 36
   Mohit D Gupta, Dixit Goyal, Girish MP

7. **Biomarkers in Cardiovascular Medicine: Toward Precision Medicine** 43
   Ashish Kumar Jha, Advait Akash, Vinit Kumar

8. **Role of Pollution in Cardiovascular Diseases** 48
   Abhishek Chaturvedi, Dorairaj Prabhakaran

9. **Frailty in Cardiac Intensive Care Units: Assessment and Impact on Management** 54
   Ajay Kumar Sinha, Sanjeev Kumar, Samshad Alam, Shreya Rani

SECTION 2: ECHOCARDIOGRAPHY/IMAGING

10. **Speckle-derived Strain: Technique, Applications, and Pitfalls** 61
Manish Bansal, Ravi R Kasliwal

11. **Impact of Bedside Echocardiography in Clinical Cardiology** 71
Vibhav Sharma, Satyavir Yadav

12. **Echocardiographic Guidance in Percutaneous Approaches to Primary and Secondary Mitral Regurgitation** 76
Sameer Shrivastava, Arif Mustaqueem, Jaideep Dey

13. **Atrial Functional Mitral Regurgitation: Diagnosis and Therapy Implications** 89
Pankaj Harkut, Sunita Kumbhalkar, Seenu Prasanth A

14. **Left Atrial Strain: Clinical Applications and Limitations** 96
Jacob Jose, Jesu Krupa

15. **Coronary CT Angiography: Principles, Techniques, and Clinical Application** 102
Priya Jagia, Sreelal Thazhathu Veettil

16. **Cardiac Magnetic Resonance Imaging for Cardiologists** 111
Mona Bhatia, Amit Garg, Prasit Maity, Sachin Raiya

SECTION 3: ARTIFICIAL INTELLIGENCE IN CARDIOLOGY

17. **Artificial Intelligence in Echocardiography: Where are We and Where are We Going** 121
Ramdas G Pai, Ajit D Pai, Vinutha Rajesh

18. **Artificial Intelligence and Heart Failure** 128
Arijit Kumar Ghosh

19. **Artificial Intelligence in Transcatheter Aortic Valve Replacement** 135
Preetish Rath, Pradeep Kumar Mustepally, PC Rath

20. **Use of Artificial Intelligence Including Multimodal Systems to Improve the Management of Cardiovascular Disease** 138
Biyanka Jaltotage, Juan Lu, Girish Dwivedi

21. **Effects of Air Pollution on Cardiovascular Diseases: AI-based Analysis of Pollutant–Disease Relationships from PubMed Articles** 144
Sudeshna Jana, Manjira Sinha, Tirthankar Dasgupta

22. **Essentials for Artificial Intelligence Research in Cardiology: Challenges and Mitigations** 151
Biyanka Jaltotage, Girish Dwivedi

23. **Wearable Technology in Cardiovascular Disease** 158
Satyavan Sharma, Akash Shah

SECTION 4: DYSLIPIDEMIA MANAGEMENT

24. **CSI Clinical Practice Guidelines for Dyslipidemia Management** 165
JPS Sawhney

25. **Lipid Metabolism: Insights into Regulation and Dysregulation** 175
Subrat Kumar Muduli

26. **Intensive Lipid-lowering Therapy for Early Achievement of Low-density Lipoprotein-C Targets in Cardiovascular Disease** 181
Saumitra Ray, Somnath Mukhopadhay, Srina Ray

27. **New Low-density Lipoprotein Cholesterol—Lowering Agents: Update on PCSK9 Inhibitor Monoclonal Antibodies, Inclisiran, and Bempedoic Acid** 189
Vimal Mehta, Pratishtha Mehra, Jamal Yusuf

28. **Lipoprotein(a) in Clinical Practice: A Guide for Clinicians** 196
Arvind Kumar, Vipin Kumar

29. **Lipoprotein(a): Why Measure and What to Do** 200
Tanmoy Majee, Sidhartha Chattopadhyay, Arup Dasbiswas

30. **Elevated Triglyceride: Current Concepts** 203
Manoranjan Mandal, Anindya Mukherjee, Mainak Mandal

31. **Dyslipidemia in Asymptomatic Young Indians** 208
Sunandan Sikdar, Rathindra Nath Karmakar

32. **Ten Commandments of Lipidology** 212
Arpita Katheria, Rakesh Maurya, Aditya Kapoor, Rajeev Agarwal

33. **Management of Pediatric Hyperlipidemia** 217
Amit Malviya, Preethi Caleb Harris, Animesh Mishra

SECTION 5: HYPERTENSION

34. Ambulatory and Home Blood Pressure Monitoring: Update 2024 **227**
A Muruganathan

35. Various Guidelines for Hypertension: Which One Best Suits for India **233**
Abhishek Garg, Gautam Singal, Gurpreet S Wander

36. Initiating Combination Therapy for Hypertension: Background and Rationale **238**
Tiny Nair

37. The Role of Calcium Channel Blockers in Modern Treatment of Hypertension in 2024: Beyond Cilnidipine **241**
Nakul Sinha

38. Diuretics for the Modern Management of Hypertension in 2024: Beyond Hydrochlorothiazide **246**
Dipankar Ghosh Dastidar

39. Inhibition of Angiotensinogen in the Treatment of Hypertension **257**
Sudhir Chandra Sinha, G Venkateshwara Reddy

40. Nocturnal Hypertension **262**
Amal Khan, Anish Kumar Khan, Amartya Khan

41. Secondary Causes of Hypertension: A Quick Guide for Diagnosis **267**
Vinod Sharma, Ruchi Sharma

42. Resistant Hypertension: Latest Advances in Management **274**
Satyendra Tewari, Harshit Khare

43. Drugs for True Resistant Hypertension **277**
SS Iyengar

44. Endovascular Interventions for Secondary Hypertension: Update 2024 **281**
Sanjay Tyagi, Vivek Kumar, Amit Mittal

45. Hypertensive Crisis: Clinical Diagnosis and Management **287**
Vishal Batra, Bhushan Shah

46. Hypertension in Chronic Kidney Disease: Management Dilemmas **297**
Dharmendra Jain, K Arun Kumar, Umesh K Pandey, Suyash Tripathi, Soumik Ghosh, Rajpal Prajapati

47. **Management of Hypertension in Pregnant and Postpartum Patients** 302
Chhabi Satpathy, Biraja Prasad Beura, Hemant Kumar Satpathy, Trinath Kumar Mishra

48. **Grappling with Hypertension Management in the Old, Very Old, and Frail Patients: A Double-edged Sword** 309
C Venkata S Ram

49. **Chronic Orthostatic Intolerance and POTS Syndrome: Update 2024** 315
Sura Kishore Mishra, Siddhartha Pandey

50. **Orthostatic Hypotension: Evaluation and Management** 319
Vijay Garg, Shivangi Tiwari, Monika Jain, Ghanshyam Sharma

51. **Newer Antihypertensive Drugs** 326
Vijay Kumar Chopra

SECTION 6: HEART FAILURE

52. **Heart Failure: Definition, Terminology, and New Concepts in Recent Guidelines** 333
Gaurav Tripathi, Dipankar Das, Sulabh Chandrakar

53. **Transformation of Guidelines of Heart Failure from Dropsy to Remodeling** 338
Mrinal Kanti Das

54. **Heart Failure and Left Ventricular Remodeling: Current Understanding** 347
Abraham Oomman, Narra Lavanya

55. **Diuretic Therapy for Patients with Heart Failure: Update 2024** 353
Subhasis Roy Chowdhury, Arijit Ghosh, Mainak Mukhopadhyay

56. **Emerging Drugs in Heart Failure beyond SGLT-2 Inhibitors** 357
PS Banerjee, Tanmay Mukhopadhyay, Gourav Bhattacharya

57. **Personalized Therapeutic Approach in Heart Failure with Reduced Ejection Fraction** 366
Navjyot Kaur, KK Talwar

58. **Efficacy of Ferric Carboxymaltose Treatment of Heart Failure in Iron Deficiency** 371
Pintu Nahata, Nadeem Akhtar

59. **Heart Failure with Preserved Ejection Fraction Diagnosis and Management: Where do We Stand in 2024** 380
Sarumathi Thangavel, Ravikumar Rathnagiri

60. Heart Failure with Preserved Ejection Fraction and Left Atrial Atriopathy: Diagnostic, Prognostic, and Therapeutic Implications **385**
HK Chopra, Manish Bansal, Ravi R Kasliwal

61. Cardiovascular–kidney–metabolic Syndrome: Pathophysiology **391**
Prakas Chandra Mondal

62. Advanced Heart Failure: Diagnosis and Management **395**
Lekha Adik Pathak, Ronak V Ruparelia

63. Challenges in Management of Heart Failure in End-stage Renal Disease Patients **399**
DP Sinha, Kaushik Manna, Navanil Biswas

64. Revascularization in Heart Failure: Current Concept **405**
Vidyut Jain, Avani Jain

65. Revascularization for Heart Failure **409**
Vivekanand S Gajapati

66. Acute Heart Failure: Management **412**
SN Routray, NK Mohanty

67. Worsening Heart Failure: Advances in Management **419**
Punitha Lakxmi Ramesh, Harikrishnan S

68. Inflammation in Heart Failure: Pathophysiology and Therapeutic Strategies **428**
Jayagopal PB

69. Aging-associated Cardiovascular Changes and Their Relationship to Heart Failure **432**
Vijaya Kumar Varada, Bhanu Duggal, Rupendra Nath Saha

70. Statins and Heart Failure: What is the Evidence **437**
Ankit Kumar Sahu, Aditya Kapoor

SECTION 7: CARDIOMYOPATHY/MYOCARDITIS

71. Genetics of Cardiomyopathy **445**
Biswajit Majumder, Ratul Ghosh, Somnath Maji

72. Dilated Cardiomyopathy: A Review **451**
Tharun David Varghese M, Louie Fischer

73. Pacing-induced Cardiomyopathy: Current Treatment Options **457**
Soormpally Vijay, Gautam Sharma

74. **Tachycardiomyopathy: A Not-to-Miss Diagnosis** 461
Jaishankar Krishnamoorthy, Sivashanmuganathan Velu

75. **Reversible Cardiomyopathy** 469
Girish MP, Subrat Kumar Muduli, Mohit D Gupta

76. **Sudden Death Risk Assessment in Hypertrophic Cardiomyopathy Across Lifespan** 476
Shitij Chaudhary, Aseem Basha, Rakesh Yadav

77. **Hypertrophic Cardiomyopathy and Its Mimics: From Diagnosis to New Therapeutics** 483
Jagdish Chander Mohan, Vinayak Agrawal, Madhu Shukla

78. **Cardiovascular Complications during Cancer Chemotherapy: Prevention, Monitoring, and Management** 497
Sankar Chandra Mandal, Ferooz Ahmad Banday, Nilesh Giri, Bidyut Roy

79. **Viral Myocarditis in India: Diagnosis, Treatment Options, and Current Controversies** 506
Tanuja Makhani, Prashant Panda, Yash Paul Sharma

80. **Cardiac Amyloidosis: When to Suspect, Newer Therapeutics** 511
Goutam Datta, Anirban Das

81. **Cardiac Amyloidosis in India** 520
Ashish Kumar Jain, Vivek BS, Rajiv Passey, Rajneesh Jain

82. **Heart Transplant: Pre- and Postmanagement** 527
Devesh Kumar, Sandeep Seth

SECTION 8: CARDIO-OBSTETRICS

83. **Cardiovascular Diseases in Women: Challenges and Differences** 537
Mohit M Bhagwati, Roopa Salwan

84. **Pregnancy and Valvular Heart Disease** 543
Shibba Takkar Chhabra, Abhishek Garg

85. **Management of Cardiac Emergencies in Pregnancy** 551
Preeti Gupta, Abhinav Aggarwal

86. **Paracardiac Fat, Coronary Calcification, and Postmenopausal Women** 557
Meenakshi Kadiyala, R Rameshwar, SR Sharath Shanmugam

87. **Cardio-Obstetrics as a Subspecialty: How to Start the Program** 561
Justin Paul Gnanaraj, Anne Princy Steaphen, Anish Keepanasseril

SECTION 9: CONGENITAL HEART DISEASE

88. **Cardiovascular Symptom Assessment and Interpretation** 567
SK Dwivedi, Ayush Shukla, Umesh Tripathi

89. **Electrocardiography in Congenital Heart Diseases** 574
Neeraj Awasthy, Sudeep Verma

90. **Chest X-ray in Congenital Heart Disease** 596
Ankur Handa, Praveen Arumugam, Nirmal Ghati

91. **Computed Tomography in Congenital Heart Disease** 607
Krishnamoorthy KM, Gopalakrishnan A, Valakkada J

92. **Hemodynamics Interpretation in Congenital Heart Disease** 623
Anuja Gadre, Manojkumar Rohit

93. **Timing of Surgery/Intervention for Congenital Heart Diseases: Indian Perspective** 630
Snehal Kulkarni, Ronak Sheth

94. **Palliative Surgeries in Congenital Heart Diseases** 641
Rishika Mehta, Amitabha Chattopadhyay

95. **Tetralogy of Fallot: Evaluation for Total Correction** 648
Anil Sivadasan Radha, Jenu Rose Jose E

96. **Repaired Tetralogy of Fallot: An Overview** 655
Ankit Garg, S Radhakrishnan

97. **Approach to Adults with Congenital Heart Defects** 662
Ranjit K Nath, Bhushan Tile

98. **Coarctation of Aorta in Infants, Children, Adolescents, and Adults** 669
Jayranganath M, Sabyasachi Pandey

99. **Diagnosis and Management of Fetal Heart Disease** 679
Chandan Kumar Das

100. **Fontan Circulation: An Overview** 686
Sakshi Sachdeva, Saurabh Kumar Gupta

101. **Interventional Palliation for Cyanotic Congenital Heart Disease in Cath Lab** 693
Deepa S Kumar

102. **Congenital Complete Heart Block: Management in Fetus, Childhood, and Beyond** 701
Sanjeev Hanumantacharya Naganur, Abhishek Mallick

SECTION 10: VALVULAR HEART DISEASE/MISCELLANEOUS

103. Top 10 Papers in Valvular Heart Disease 2023–2024 **709**
Rajeev Garg, Vardhini Vijaykumar

104. Rheumatic Fever and Rheumatic Heart Disease in India: Current Status **713**
Anita Saxena

105. Multivalvular Heart Disease: Clinical Assessment of Severity and Management **719**
T Govindan Unni

106. Latest Guidelines for Infective Endocarditis **723**
Joy M Thomas, Arun Arul David

107. Venous Thromboembolism: Recent Advancements and Future Perspectives **737**
Vipin Kumar, Arvind Kumar

108. Constrictive Pericarditis—Diagnosis and Management **742**
Rajesh Thachathodiyil, C Rohit Swaminathan, Meenu Nair

109. Cardiac Rehabilitation Postcoronary Artery Bypass Graft **750**
Chandra Bhan Meena, Aishwarya Vyas

SECTION 11: PULMONARY VASCULAR DISEASE

110. Pulmonary Thromboembolism: Recent Advances in Management **757**
A Kader Sahib, AD Arun Mohan, M Shanmathi

111. Pediatric Pulmonary Arterial Hypertension: An Overview **765**
Satish Kumar, Prashant Bobhate

112. Pulmonary Embolism: Current Status and Update **776**
Gaurav Singhal, Aishwarya Gaur

Index ***i1–i20***

VOLUME 2

SECTION 12: CHRONIC CORONARY SYNDROMES

113. Latest Guidelines in Management of Stable Angina **785**
Jamal Yusuf, Dixit Goyal

114. Anti-inflammatory Drugs to Inhibit Atherosclerosis: Old and New **801**
SS Mishra, BR Mishra, Asharam Panda

115. Latest Guidelines on Management of Chronic Coronary Disease (Syndromes) **805**
Nagaraj Desai, Prabahakar Koregol, Akash Gopi, Sunil Kumar S

116. Management of Coronary Ectasia and Coronary Aneurysms: Current Concepts **811**
P Chandrasekhar, G Ravi Kiran

117. Cardiac Syndrome X **816**
Hetan C Shah, Tamagna Ghosh

118. Coronary Vasospasm: Update **822**
Kranthi Kumar Gedala, Jaideep C Menon

119. Nonobstructive Coronary Artery Disease: MINOCA and INOCA **826**
Devanu Ghosh Roy, Deepanjan Bhattacharya

SECTION 13: ACUTE CORONARY SYNDROME

120. Finding Vulnerable Plaque: Is Vessel Wall Imaging Ready for Primetime **833**
Upendra Kaul, Manish Narang

121. Latest Guidelines in Management of Non-ST-elevation Myocardial Infarction **840**
Sujatha Vipperla

122. Approach to Late Presenter in ST-elevation Myocardial Infarction **844**
Kavita Tyagi, Juhi Singh

123. Management of Acute Coronary Syndrome in Renal Dysfunction **851**
Ashish Deshpande, Milind Kharche

124. Choice of Dual Antiplatelet Therapy in Acute Coronary Syndrome **856**
Arvind Kumar Jaiswal, Ayush Shukla, Sharad Chandra

125. ST-elevation Myocardial Infarction in Young: Indian Perspective **868**
Mohsin Raj Mantoo, Ganesan Karthikeyan

126. Invasive versus Conservative Management of Older Patients with Non-ST-elevation Acute Coronary Syndrome **874**
Dibya Kumar Baruah, P Chakradhar, D Anuradha

127. Latest Clinical Practice Guidelines for Non-ST-elevation Acute Coronary Syndrome: What is New **878**
AN Patnaik, Soumya Patnaik

128. Hemodynamics of Cardiogenic Shock **882**
Anil Dhall, Ayush Malhotra, Mahendra Chouhan

129. Percutaneous Coronary Intervention in Acute Myocardial Infarction with Shock: Current Strategies of Management **900**
Ajay S Chaurasia, Shreyak P Kadu, Arjun Mali, Pankaj Kashyap, Nikhil Borikar, Sandeep Kamat

130. STEMI! Strategic Difference in the Treatment and Management in Men and Women **908**
Subroto Mandal, B Shukti, Rajeev Gupta

131. Diagnostic and Management Dilemmas in Women Presenting with Acute Coronary Syndrome **913**
Sarita Rao, Roshan Rao, Vaibhav Shukla, Achukatla Kumar

132. Ventricular Tachycardia after Myocardial Infarction **917**
Nishad Chitnis, B Hygriv Rao

133. Open Artery Ischemia: Comprehensive Management **924**
Mainak Mukhopadhyay, Sandipta Ray, Kajal Ganguly, Subhasis Roy Chowdhury, Arijit Ghosh

134. Dilemma of Asymptomatic Three-vessel Coronary Artery Disease after Myocardial Infarction **927**
Kamal K Sethi, Kabir Sethi

135. Current Status of Biomarkers in Reinfarction **931**
Rajeev Gupta, Manu Gupta, Anuj Gupta, Pooja Sharma Gupta

136. Post-PCI Physiology: Current Concepts **935**
Rajiv C, Abraham Paul

137. Non-ST-elevation Acute Coronary Syndrome in Previous Coronary Artery Bypass Graft: Management **940**
Avinash Mani, Vishal Rastogi, Vijay Kumar, Ashok Seth

138. Myocardial Hibernation: Clinician Perspective **946**
Puneet Rastogii

139. Takotsubo Syndrome **952**
Madhu Sreedharan

140. Spontaneous Coronary Artery Dissection **959**
K Sivaprasad, Manju Bhargav BR

141. Myocarditis as an Acute Coronary Syndrome Mimicker: Diagnosis and Management **966**
Gopal Chandra Ghosh, Suvro Banerjee

142. Ischemic Mitral Regurgitation: Mechanisms and Management **970**
S Shanmugasundaram, Ilayaraja U, Samuel Jebavaram, BG Vinodkumar

143. Cardiac Rehabilitation after Acute Myocardial Infarction **981**
Madhuvanthi Rajendran, Thomas Alexander

SECTION 14: CORONARY INTERVENTION

144. Clinical Use of Intracoronary Imaging: Guidance and Optimization of Coronary Interventions **991**
Sajan Narayanan

145. Step-by-Step Physiological Assessment to Accomplish Physiology Guide Percutaneous Coronary Intervention **1011**
S Selvamani, JS Thomas Xavier Paulsingh

146. Intravascular Imaging in Coronary Stent Restenosis: Prevention, Characterization, and Management **1021**
Parayaru Kottayil Asokan

147. Imaging-guided Left Main Coronary Artery Percutaneous Coronary Intervention: Current Concepts **1030**
Vijay Bang, Ashish Deshpande

148. Physiological Assessment of Intermediate Left Main Coronary Artery Lesion **1041**
Arun Mohanty, Ashish Kumar Jain, Sonal Jain

149. Management of Thrombus-containing Coronary Lesions **1049**
Ajit Desai, Vishal Gavali

150. Saphenous Vein Graft Failure: Pathophysiology to Treatment **1060**
Dhiman Kahali, Debasish Mohapatra, Padma Madhab Bisoi

151. Chronic Total Occlusion: When to and When not to Revascularize **1068**
Prathap Kumar N, Manu R, Blessvin Jino

152. Is Chronic Total Occlusion Opening Worthy: Current Status and Evidence **1073**
Dilip Kumar, Abhinay Tibdewal

153. Chronic Total Occlusion Revascularization: Indications and Techniques **1080**
Sridhar Kasturi

154. Chronic Total Occlusion—Toolkit **1096**
Pravin K Goel, Saurav Mishra

155. In-stent Restenosis: Mechanism and Diagnostic and Therapeutic Options **1107**
KN Srinivasan, I Sathyamurthy

156. Imaging and Management of In-stent Restenosis **1113**
Nitin K Kabra

157. Contemporary Coronary Drug-eluting Stents versus Drug-coated Balloons Update 2024 **1120**
Panchanan Sahoo, Sateesh Reddy

158. Intravascular Lithotripsy: When and How **1130**
Debdatta Bhattacharyya, Saurabh Dhumale

159. Orbital Atherectomy for Calcified Coronary Stenosis: Basics and Beyond **1139**
Rohan Naik, Shabbir Ali Shaik, PC Rath

160. Current Treatment Options for Refractory Angina **1144**
Tarun Kumar, Abhishek Kumawat, Karthikeyan R

161. Multivessel Coronary Artery Disease with Left Ventricular Dysfunction: Management **1150**
Saroj Mandal, Shubhanshu Pal

162. Nonmetal Coronary Interventions: DCB and BRS **1156**
Rishi Sethi, Monika Bhandari

163. Metal Less Percutaneous Coronary Interventions: Future of Angioplasty **1162**
Mahesh Nalin Kumar, Joyal J Kandathil, Arya Subhadra, Ashwin Mahesh

164. FFR Angiography versus Catheter-based FFR: Pros, Cons, and Caveats **1170**
Prasant Kr Sahoo, Nitish Prasad, Shyam Prasad Sahoo

165. Tips and Tricks for Saphenous Venous Graft and Left Internal Mammary Artery Stenting **1176**
Satya S Mandava, Rajesh Vijayvergiya

166. Myths and Facts about Arterial Coronary Artery Bypass Grafting **1183**
OP Yadava

167. Postcoronary Artery Bypass Grafting Management: Advances **1189**
Srinivas Rao Maddury, Kartik Pandurang Jadhav, MS Prashant

SECTION 15: STRUCTURAL INTERVENTION

168. Aortic Stenosis: Core Concepts in Diagnosis and Prognosis in Different Cohorts **1199**
Satish K Parashar

169. Spectrum of Aortic Valve Diseases from Neonates to Elderly and Its Management **1205**
Tom Devasia, Monika P Jawanjal, Mukund Prabhu

170. Transcatheter Aortic Valve Implantation in Degenerated Surgical Aortic Valve: New Hope **1221**
Ashish Kumar, Himanshu Dabral, Rajneesh Kapoor

171. Transcatheter Aortic Valve Replacement: Status 2024 **1226**
Harinder K Bali, Navdeep Singh Sidhu

172. Transcatheter Aortic Valve Replacement for Aortic Regurgitation: Next Steps and Future Challenges **1233**
Raghav R Nagpal, Haresh Mehta

173. Transcatheter Aortic Valve Implantation: Recent Advances **1239**
Vijay Kumar, Vishal Rastogi, Vivudh Pratap Singh, Avinash Mani, Dhananjay Kumar, Ashok Seth

174. Bicuspid Aortic Valve: Most Frequent, Not Benign Congenital Heart Disease **1249**
BS Yadav

175. Percutaneous Transcatheter Mitral and Tricuspid Valve-in-Valve Implantation **1253**
Nandhakumar Vasu, Ajit S Mullasari

176. Transcatheter Therapies for Tricuspid Regurgitation: 2024 **1260**
Rajendra Kumar Jain, Shirisha Reddy Kommareddy

177. Transcatheter Mitral Valve Repair for Mitral Regurgitation: Is it Now Choice for Selected Patients **1271**
Balbir Singh, Sneha Garg

178. Transcatheter Pulmonic Valve Therapies: Techniques, Current Roles, and Future Implications **1278**
Nirat Beohar, Sanjay Tyagi

179. Tricuspid Valve Endovascular Interventions **1283**
Viveka Kumar, Purneshwar Pandey, Sangeeta Dhir

180. Valve Thrombosis and Valve Degeneration: How to Detect **1289**
John Jose E, Paul V George

181. Tips and Tricks of Transseptal Puncture in Different Structural Heart Interventions **1298**
A Sreenivas Kumar, Ramakrishna J

182. Acute Emergencies in Cardiac Valves **1305**
Smit Shrivastava

183. Atrial Septal Defects Device Closures: Basics and Beyond **1312**
Sriram Easwaran, Milind Phadke, Bharat Dalvi

184. Ruptured Sinus of Valsalva Device Closure: Current Status **1328**
Mohsin Raj Mantoo, Sivasubramanian Ramakrishnan

185. Left Atrial Appendage Closure **1334**
Lakshmi Durga Kumaraguruparan, Nagendra Boopathy Senguttuvan

SECTION 16: MECHANICAL CIRCULATORY SUPPORT

186. Recent Advances in Cardiogenic Shock **1345**
Dev B Pahlajani, Kayan Siodia

187. Management of Right Ventricular Shock **1355**
Anil Sharma, Akash Shah, Anushree Kumbhalkar

188. Mechanical Circulatory Support in Severe Heart Failure **1364**
Ashmit Bhardwaj, Mukesh Goel

189. Right Ventricular Support: When and How **1368**
Pawan Sharma, Himanshu Jindal

SECTION 17: VASCULAR INTERVENTIONS

190. Advances in the Management of Chronic Limb Ischemia **1379**
Manoj Kumar Agarwala, Rufus Demel X

191. Advances in Management of Acute Limb Ischemia **1384**
NN Khanna, Saurabh Bhardwaj

192. Advances in the Management of Endovascular Treatment of Aortic Dissection **1391**
Sanjay Mehrotra

193. Atherosclerotic Carotid Disease: Revascularization—When, Why, and How 1398
Bhavuk Jaiswal, Ashish Jai Kishan, Atul Mathur

194. Interventional Approach to Central Venous Occlusion 1402
BC Srinivas, Disha Shetty, Vijay Kumar, Babu Reddy, CM Nagesh

SECTION 18: RHYTHM AND CONDUCTION ABNORMALITIES

195. Top Ten Papers in Arrhythmia Treatment: 2023–2024 1415
Sanjeev Asotra, Rajesh Sharma, Sachin Maggo

196. Electrocardiogram Approach to Narrow QRS Complex Tachycardia 1419
Sundaram Chandrashekhar, Yash Lokhandwala

197. Recent Advances in the Management of Ventricular Tachycardia 1429
Vinayaga Pandian, Ravikishore Amancharla

198. Cardiac Channelopathies 1433
Sudipta Mondal, Ajit Kumar Valaparambil

199. The Role of Radiofrequency Ablation in Management of Ventricular Tachycardia in Ischemic Cardiomyopathy: Two Decades of Advances 1440
Abhishek Goyal, Naved Aslam, Gurpreet S Wander

200. Difficult-to-treat Atrial Fibrillation: Management Options 1446
Ajay M Naik, Aarya A Naik, Aditi A Naik

201. Atrial Fibrillation in India: The Burden and the Way Forward 1453
Vivek Chaturvedi

202. Premature Ventricular Contraction Localization 1459
Sanjeev Kathuria, Ankit Bansal, Rahul Nijhawan

203. Management of Refractory Ventricular Tachycardia 1468
Satya Sahitya Mandava, Parag Barwad

204. Novel Nonradiofrequency Ablation Modalities in the Management of Cardiac Arrhythmias: An Update 1474
Oruganti Sai Satish, Purushotham Reddy Ramireddy Gari

205. Approach to a Patient with Syncope 1481
Shivani Rao, Pradyumna Kumar Singh, Karthikeyan R

206. Approach to Ischemic Ventricular Tachycardia 1489
Muralidharan TR, Preetam Krishnamurthy, Abhilasha

207. Sudden Cardiac Death 1496
Avishkar Agrawal, Mohsin Raj Mantoo, Sandeep Singh

208. Implantable Cardioverter Defibrillator Therapy: Critical Evaluation of Selection Criteria and Postimplant Care 1502
Anish Bhargav, Raja J Selvaraj, Balachander Jayaraman

SECTION 19: CARDIORENAL DIABETES

209. Top Ten Papers in Diabetes and Metabolic Disorders: 2023–2024 1509
Ravi Vishnu Prasad

210. Advances in the Management of Type 2 Diabetes Mellitus 1516
Barun Kumar, Kanika Kukreja

211. Cardiovascular–kidney–metabolic Syndrome: Staging and Prevention 1520
Umeshwar Pandey, Kumar Himanshu, Awadesh Kumar Sharma

212. Diabetic Cardiomyopathy 1524
AK Pancholia

213. Metabolic Ill Health: A New Therapeutic Target for Improving Outcome of Cardiometabolic Diseases 1530
PC Manoria, Pankaj Manoria

214. Antidiabetics and Cardiorenal Safety 1535
Amit Aggarwal, MPS Chawla

SECTION 20: EMERGING DRUGS FOR CARDIOVASCULAR DISEASE

215. Review of Thrombosis and Antithrombotic Trials of 2023–2024 1545
Deepthi Kodati, Achukatla Kumar, Maddury Jyotsna

216. Antiplatelet Agents in STEMI: Which, How, and When 1555
Akhilesh Kumar, Suman Bhandari

217. What are Future and Novel Antithrombotic Drugs in Acute Coronary Syndrome and Percutaneous Coronary Intervention: Are there Still Unmet Needs 1561
Archit Dahiya, Harsh Wardhan

218. Emerging Promising Drugs for Cardiovascular Disease 1565
Safal, Mayank Shami

219. Glucagon-like Peptide-1 Analogs in Cardiometabolic Disorders: State of the Art **1571**
Arijit Kumar Ghosh, Shinjan Patra

220. Mitochondria-based Therapies in the Cardiovascular System **1577**
Ashwani Mehta, Kavita Tyagi

221. Different Response to Same Drug: Effect of Pharmacogenomics on Statin Efficacy **1580**
S Ramesh, SR Sharath Shanmugam

SECTION 21: PREVENTIVE CARDIOLOGY

222. Prevention of Coronary Artery Disease **1587**
Hem Chandra Kalita, Anupam Srivastava

223. Management of Inflammation in Cardiovascular Disease **1594**
SR Sharath Shanmugam, S Murugarajan, MS Ravi

224. Geriatric Preventive Cardiology **1603**
Aftab Khan, Navanil Biswas, Debayan Sarkar

225. Vegetarian and Vegan Diets: Benefits and Drawbacks **1608**
Asha Moorthy, Supraja Moorthy, Prashant Moorthy

226. Beneficial Cardiovascular Plants **1616**
Shridhar Dwivedi, Deepti Chopra

Index ***i1–i22***

Scan the QR code to access references of all the chapters.

CHAPTER

44

Endovascular Interventions for Secondary Hypertension: Update 2024

Sanjay Tyagi, Vivek Kumar, Amit Mittal

ABSTRACT

Secondary hypertension (HTN) is elevated blood pressure (BP) secondary to an identifiable cause. Though the prevalence of secondary HTN is relatively low, it comprises the subset of HTN that is potentially treatable. Endovascular interventions have emerged as potential therapeutic options for specific secondary HTN subtypes. Clinical workup to identify potentially reversible causes for nonendocrine secondary HTN is essential. These reversible causes include coarctation of aorta, Takayasu disease (aortoarteritis), and renal artery stenosis. In this chapter, we discuss the current status and clinical outcomes of these endovascular interventions and highlight areas for future research.

Keywords: Secondary hypertension, endovascular interventions, renal artery stenosis, Takayasu arteritis, aortic coarctation

JAYPEE BROTHERS

INTRODUCTION

Secondary hypertension (HTN) occurs in about 5–10% of patients with HTN.[1] It results from specific, identifiable conditions such as renal parenchymal disease, renal artery stenosis, aortic coarctation, and endocrine disorders.[2] The prevalence of secondary HTN is bimodal and it is most prevalent at the extremes of age. It accounts for 70–85% of HTN cases in children <12 years of age and approximately 17% of cases in adults aged 65 and older.[2,3] Identification of the etiology and pathophysiology of secondary HTN is essential. It does not just guide toward the appropriate therapy but in some subsets, the treatment may result in a complete cure of HTN and elimination of antihypertensive therapy. Management includes pharmacological therapy and lifestyle modifications. However, endovascular interventions have gained traction as potential treatment options, offering minimally invasive alternatives to surgical revascularization in patients with secondary HTN due to vascular stenosis.

RENOVASCULAR HYPERTENSION

Renovascular hypertension (RVH) is one of the most common causes of secondary HTN and can result in resistant HTN. HTN can occur due to stenosis of the unilateral or bilateral renal arteries.[5] Atherosclerosis is the cause of renal artery stenosis (RAS) in elderly. In younger populations, especially females, RAS is usually due to Takayasu's arteritis (TA) or to fibromuscular dysplasia (FMD).[6]

Renal artery stenosis reduces blood flow to the affected kidney, triggering renin–angiotensin–aldosterone system (RAAS) and leading to HTN.[7] Persistent reduced renal blood flow leads to renal ischemia, worsens renal failure, and contributes to disease progression. Percutaneous revascularization is recommended along with medical therapy in selected patients to improve renal perfusion.

The first renal angioplasty in India for TA was performed by Dr Sanjay Tyagi at GB Pant Hospital in 1986 and the first case series of angioplasty in 27 patients with RAS was published in 1989.[6] Most of these patients (21/27) were of TA, four had atherosclerotic RAS while other two had FMD. The angiographic success rate in this early series was 94.4%.

Atherosclerotic Renal Artery Stenosis

Randomized controlled trials comparing medical therapy with percutaneous transluminal renal angioplasty (PTRA) to medical therapy alone have failed to show a benefit of atherosclerotic PTRA; however, the patients with the most severe RAS, who would be more likely to benefit from PTRA, might not have been enrolled in these trials. Severe RAS with HTN is associated with an increased risk of progressive

decline in renal function, cardiac destabilization syndromes including "flash" pulmonary edema, and recurrent congestive heart failure. PTRA with stenting has been shown to be helpful in such patients with severe RAS.[1]

Several trials have evaluated the impact of renal artery angioplasty on BP control. The ASTRAL trial, a landmark study, found no significant difference in BP reduction between angioplasty and optimal medical therapy alone.[8,9] Similarly, the CORAL trial showed that angioplasty combined with stenting did not offer substantial long-term benefits over medical management in terms of BP control.[10] In contrast, observational studies have reported positive outcomes, including improvements in BP and renal function following angioplasty.[11] The variability in outcomes highlights the importance of patient selection and procedural technique. JACC appropriate use criteria (AUC) recommends renal artery intervention with hemodynamically significant RAS defined as RAS with 70–99% stenosis or RAS with 50–69% stenosis associated with hemodynamic significance **(Figs. 1A and B)**.[11]

The endovascular technique of PTRA with or without stenting is one of the standard treatments for RAS. According to the AUC, scenarios in which revascularization is appropriate are for patients who present with acute decompensated heart failure with flash pulmonary edema, bilateral RAS alongside worsening kidney function, CKD with unilateral RAS associated with worsening renal function, and patients with hypertension who remain uncontrolled despite optimized medical therapy.[12] Another indication could be RAS in solitary functioning kidney. A meta-analysis study showed that renal artery stent placement could stabilize or even improve renal function with a benefit rate of 77% **(Figs. 2A and B)**.[13]

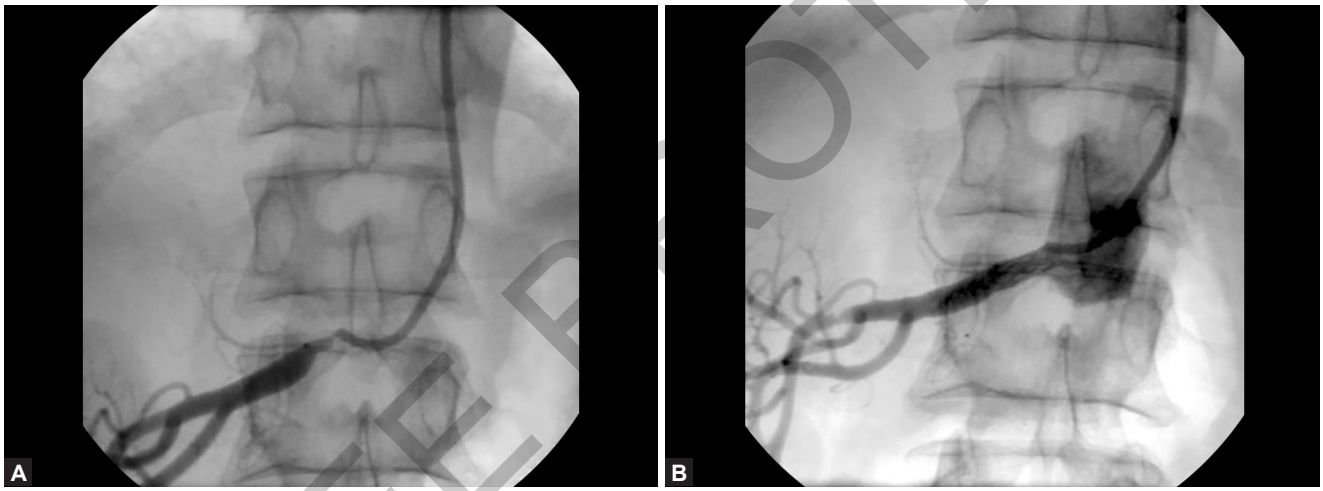

FIGS. 1A AND B: (A) Atherosclerotic right renal artery stenting by brachial approach in an elderly patient with hypertension, renal failure, solitary functioning kidney, and occlusion of infrarenal aorta. (B) Patient had improvement in hypertension and renal failure after angioplasty.



FIGS. 2A AND B: Atherosclerotic left renal artery stenting by femoral approach in a patient with refractory hypertension. Patient had reduction in antihypertensive medications.

JAYPEE BROTHERS

Contraindications to Renal Revascularization

Contraindications to renal revascularization include refusal of consent, advanced disease (creatinine level >3–4 mg/dL or kidney length <8 cm), limited life expectancy, generally poor surgical or PTRA candidates (e.g., bleeding diathesis) and pregnancy.[5]

NON-ATHEROSCLEROTIC RAS

Fibromuscular dysplasia: FMD is less common cause of RVH in India than in Western countries. Medial FMD has string-of-bead appearance on angiography. Balloon angioplasty (BA) has been the traditional treatment of choice for renal artery fibromuscular medial dysplastic lesions and stents are rarely required.

In our experience, BA alone is sufficient in most cases **(Figs. 3A and B)** with improvement in HTN. The procedural success rate is 82–100% and restenosis occurs in about 10% of cases. Clinical results show cure of HTN in about 58% of patients, improvement in 35%, and failure in 7%.[13]

TAKAYASU'S DISEASE (NONSPECIFIC AORTOARTERITIS)

The pathogenesis of HTN in TA is complex and multifactorial. Important factors are RAS, followed by stenosis of the thoracic descending aorta, abdominal aorta, noncompliant aorta, and severe aortic regurgitation. Aorta is one of the key vessels responsible for BP regulation because of its elastic component. Dense fibrosis leads to loss of elasticity of aorta in TA. This is an important contributor to HTN in TA. Monitoring and control of BP may be difficult in cases with absent or reduced pulses in upper extremities. BP measurements should be made in the unaffected extremities.

In medical therapy for HTN in patients with Takayasu's disease, drugs are used based on severity of HTN. Combined medical treatments of glucocorticoids and conventional disease-modifying antirheumatic drugs should be used in patients with disease activity for early control of inflammation. Biological disease-modifying antirheumatic drugs should be used in patients with refractory disease activity.[7]

Percutaneous transluminal angioplasty is preferred for patients with renal and aorta stenosis.[14] Results are best in severe, discrete stenosis. It produces marked improvement in HTN. Surgical treatment is limited to total occlusion or long-segment stenosis. It should preferably be done after remission induction if angioplasty is not possible **(Figs. 4A and B)**.[7]

Hypertension secondary to TA in a large cohort was retrospectively analyzed in a single-center study in China in 381 TA patients with HTN.[15] Diagnosis of HTN was according to clinic BP or the central BP measured during angiography. RAS was the most common cause (264, 69.3%), followed by the thoracic descending aorta stenosis (98, 25.7%), abdominal aorta stenosis (78, 20.5%), and severe aortic regurgitation (45, 11.8%). More than two kinds of pathologies were found in 98 (25.7%) patients.[15]

At our center (GB Pant PGI), in three decades, a total of 267 renal angioplasty procedures were performed for 353 stenotic lesions in patients with TA.[16] BA had a procedural success rate of 89.3%. Cutting balloon was used in one-third of cases, which improved the success rate. Renal artery stenting was reserved as a bailout procedure. 89% of patients with procedural success showed good clinical response and improvement in HTN. Periprocedural complications including local-site complications occurred in 5.4% of patients. There was no procedure-related mortality. The

JAYPEE BROTHERS

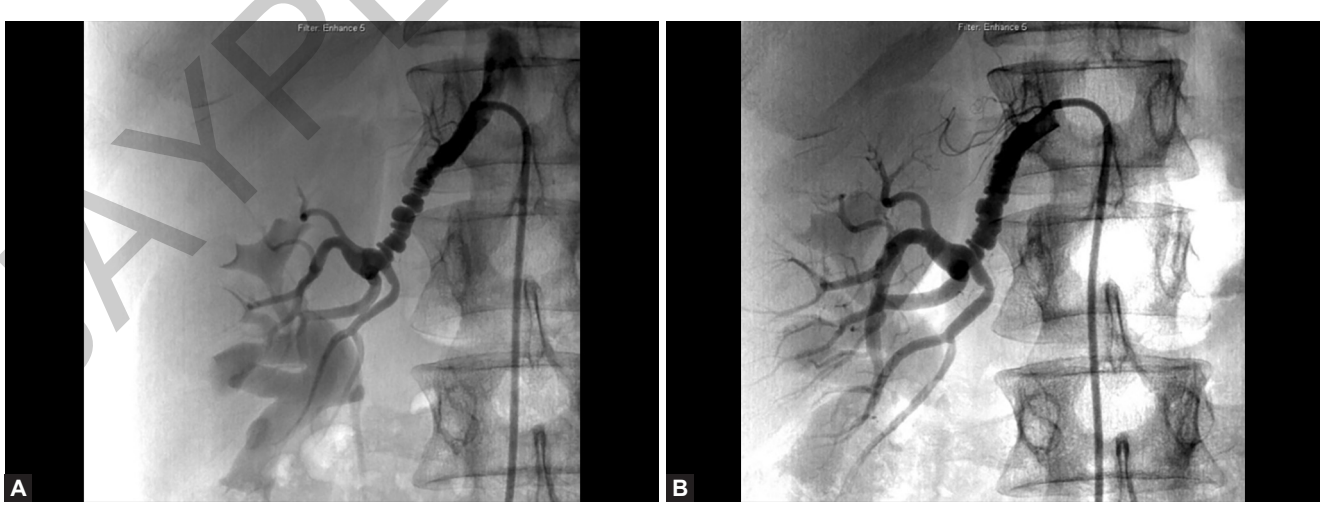

FIGS. 3A AND B: Balloon angioplasty for renal artery medial fibromuscular dysplasia in a young woman with severe hypertension. (A) String-of-bead appearance before and (B) improvement in lumen after balloon angioplasty.

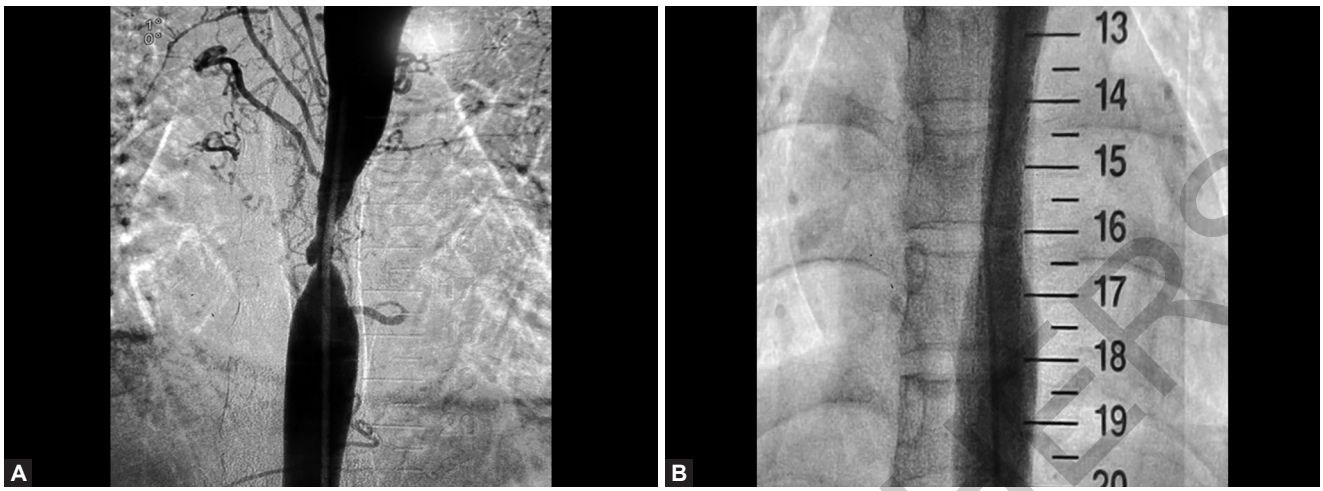

FIGS. 4A AND B: A young girl presented to emergency with severe HTN and CVA due to cerebral hemorrhage. (A) Her angiogram showed severe stenosis of thoracic aorta, (B) which was treated by endovascular balloon angioplasty and stenting with relief of stenosis and no residual gradient in thoracic aorta. Her blood pressure normalized and she does not require any antihypertensive medications even on long-term follow-up.

restenosis rate at a median of 27.7 months was 18.2%, with active disease and length of stenosis being the most important predictor of restenosis. Restenosis was almost associated with recurrence of HTN. Repeat angioplasty, was attempted in all patients with restenosis, mostly with cutting balloon improvement in HTN.[16]

While a lot is said about the high restenosis rates in TA, a word must also be added about the phenomenon of late beneficial remodeling observed in some patients, whereby one is pleasantly surprised to find the follow-up angiogram showing actually better results than what had been achieved immediately postprocedure **(Fig. 5)**.

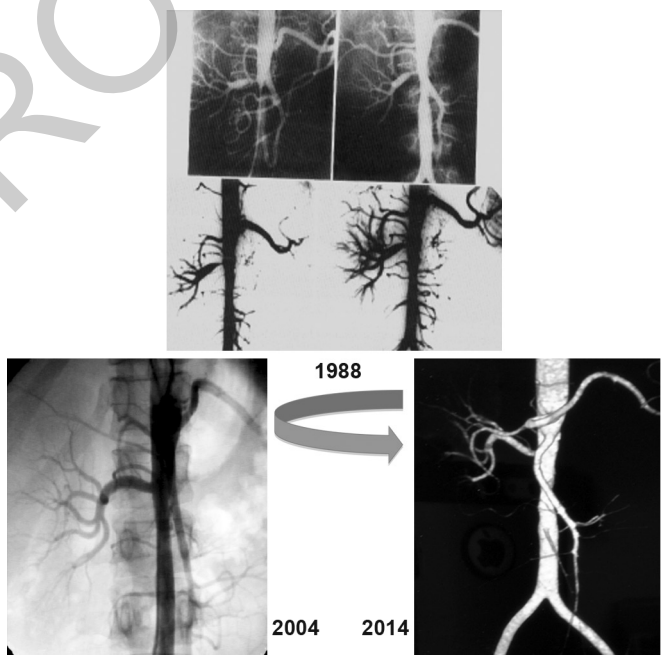

FIG. 5: Long-term follow-up after balloon angioplasty of right renal artery in a patient with Takayasu's arteritis and resistant hypertension: Excellent long-term results 26 years after initial procedure. Of special note is the late beneficial remodeling due to which lumen diameter on follow-up is even better than immediately postprocedure.

RVH in Indian Children

A number of series from India, including ours, show aortoarteritis to be the most common cause of RVH in children in our country. Overall, anywhere between 3 and 10% of children referred for evaluation of severe HTN are subsequently found to have clinically significant renovascular lesions.[2] Vis-à-vis adults, children with RVH have a shorter duration of disease, are more likely to present with malignant HTN, heart failure or hypertensive encephalopathy, have less severe disease angiographically, and respond better to revascularization.

In a series of 35 consecutive children with RVH published by us,[17] 31 (88.6%) were due to aortoarteritis and 4 (11.4%) were attributable to juvenile idiopathic fibromuscular disease. Thus, we concluded that TA is the most common cause of RVH in children in our country as opposed to Western countries where FMD is the most common cause of RVH in children. Overall BA was technically successful in 31 (88.6%) patients. Although restenosis at a mean follow-up of 23 months was to the tune of 25.8%, the restenosed lesions could be easily redilated. 93.1% of patients with technically successful procedure had a beneficial BP response on long-term follow-up, which included complete cure of HTN in about one-third. BP response was better in the FMD group as compared to aortoarteritis group **(Figs. 6A and B)**.[17]

JAYPEE BROTHERS

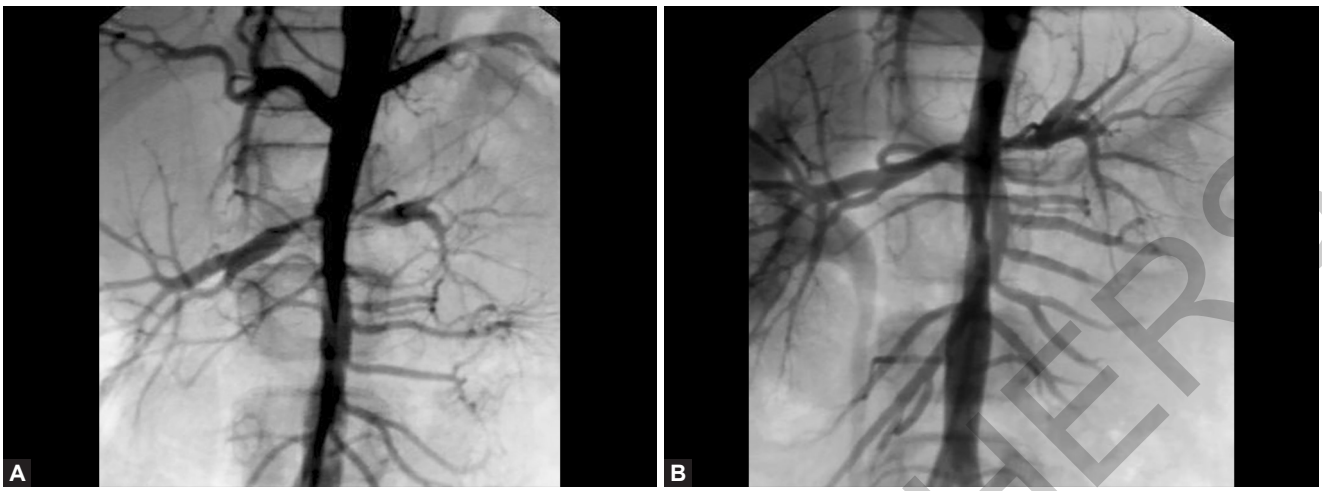

FIGS. 6A AND B: (A) Bilateral ostial renal artery stenosis due to aortoarteritis in a young girl with severe hypertension and (B) marked improvement in luminal diameter after cutting balloon angioplasty with normalization of blood pressure.

As in case of adults, effort should be made to intervene only in the quiescent phase of aortoarteritis, except in severe HTN with heart failure where it needs to be done without waiting for complete cessation of disease activity. Renal stenting in TA should be reserved as bailout for flow-limiting dissection.

In pediatric age group, TA is more often the cause of RAS as compared to FMD in our country. Relief of RAS by BA produces marked improvement in HTN in these subgroups of patients. It is safe and highly effective, and therefore, should be the treatment of choice in pediatric renovascular HTN.

CONGENITAL COARCTATION OF AORTA

Aortic coarctation impedes blood flow and can lead to secondary HTN, particularly affecting the upper body. The treatment of HTN in coarctation of the aorta (CoA) besides drugs is managed by early surgical or transcatheter repair to reduce the risk of irreversible aortopathy and refractory HTN.[4] It improves BP in addition to other associated risks of premature coronary artery disease, stroke, aortic aneurysm, dissection, and rupture.

Transcatheter BA and endovascular stent placement offer less invasive approaches compared to surgery for the treatment of CoA for adolescents and young adults.[18] Endovascular stent implantation is safe and effective in improving suboptimal results after BA for CoA. Self-expandable stents are easier to implant and are adapted better to the wall of the aorta, and most patients had similar efficacy in reducing coarctation as balloon-expandable stents.[19,20] Endovascular stenting of aortic coarctation has shown promising results in terms of reducing BP and improving patient outcomes.[19-21] Surgical treatment is used in infancy due to higher chances of recoarctation after BA **(Figs. 7 and 8)**.

The COAST trial demonstrated that endovascular repair with the NuMED Cheatham Platinum Stent® for treatment of CoA, was effective and was associated with a lower procedural risk.[22] The subsequent COAST II trial [Covered Cheatham-Platinum Stents (CCPS) for Prevention or Treatment of Aortic Wall Injury Associated with Coarctation of the Aorta Trial] established the importance of covered CP stent. The CCPS could effectively treat and potentially prevent AWI associated with CoA.[23] Recently long-term outcomes of stent implantation trials in CoA including both COAST and COAST II trials cohorts were published.[24] It showed that coarctation stenting was effective at maintaining obstruction relief up to 60 months postimplant with reduction in the number of patients requiring antihypertensive medication. An increase in stent fractures and reinterventions was observed between medium and long-term follow-up.

Hypertension in CoA: Persistent HTN is seen after repair of native CoA in adults and is associated with suboptimal LVMI regression and cardiovascular events.[25] Many long-term complications are related to HTN, which is a common finding late after coarctation repair. In a systemic review by Panzer J et al., the prevalence of hypertension after CoA repair was found to be around 47%, ranging from 20 to 70% in various studies.[26] The prevalence of HTN after CoA repair is substantial and progressive, and higher routine 24-hour BP measurement is recommended in the follow-up of patients after CoA repair to identify HTN.[25] LV diastolic dysfunction and LVH are common in patients with repaired CoA, even in the absence of HTN, and correlates with worse long-term outcome. Residual HTN has been linked to several mechanisms, including abnormal geometry of the aortic arch or hypoplasia of the arch, hyperactivation of the renin–angiotensin system, and attenuation of baroreflexes.[26] Optimal BP control with medical therapy after CoA repair may result in improved clinical outcomes.

JAYPEE BROTHERS

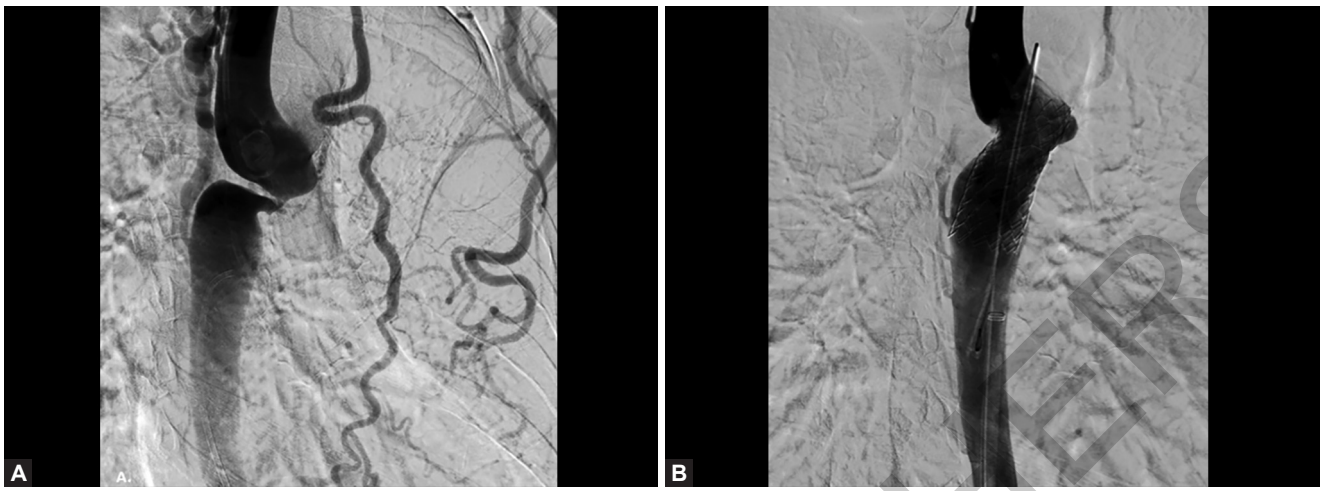

FIGS. 7A AND B: Pre (A) and post (B) stenting digital subtraction angiography (DSA) image. (A) Prestenting DSA showing tight postductal coarctation of the aorta with large collaterals and (B) Poststenting DSA showing a reduction in collaterals and well-expanded coarctation segment after aortic stent implantation. Patient had marked improvement in hypertension after stent implantation with reversal of paraparesis.[21]

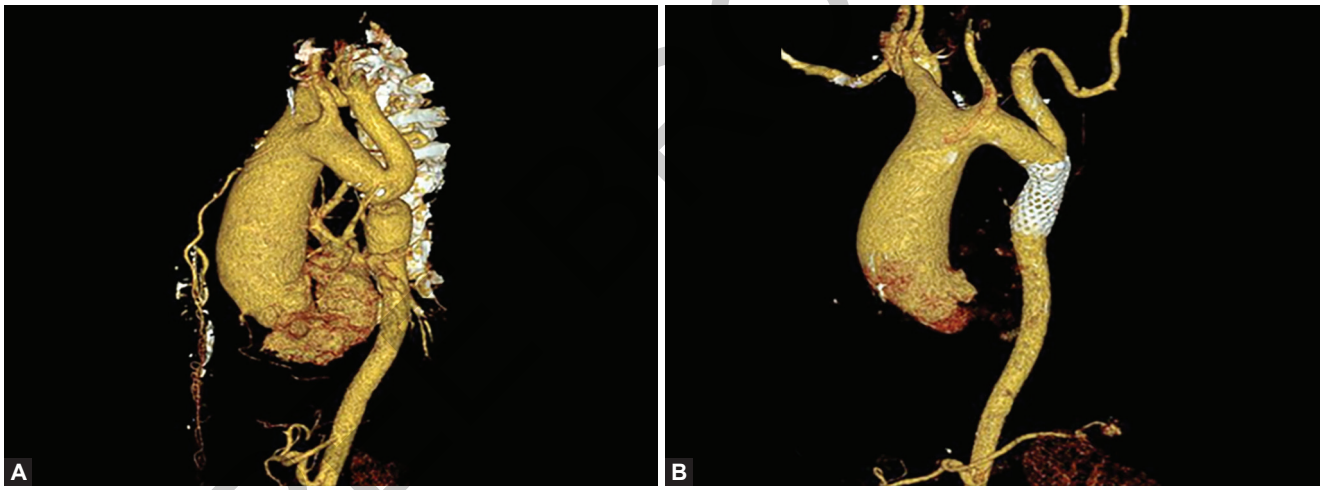

FIGS. 8A AND B: Pre (A) and post (B) stenting multidetector computed tomography angiography images. (A) 3D volume-rendered colored projection showing tight postductal coarctation of the aorta with post stenotic dilation, prominent tortuous anterior abdominal wall, and posterior intraspinal collaterals and (B) Post stenting 3D volume-rendered colored projection showing stent across the coarct with complete resolution of stenosis.[21]

CONCLUSION

Future research should focus on optimizing patient selection criteria, refining techniques, and assessing long-term outcomes of endovascular interventions in management of secondary HTN. Large-scale, multicenter trials will be essential to validate current findings and establish best practices. Endovascular interventions offer promising options for managing secondary HTN due to vascular obstruction, with ongoing advancements enhancing their efficacy and safety.

ONLINE REFERENCES

Please scan the QR code provided at the end of the table of contents for References of this chapter.

JAYPEE OTHERS

CHAPTER

108

Constrictive Pericarditis—Diagnosis and Management

Rajesh Thachathodiyil, C Rohit Swaminathan, Meenu Nair

ABSTRACT

Constrictive pericarditis is a common, significant clinical condition characterized by fibrotic and calcified thickening of the pericardium leading to impaired diastolic filling and heart failure. This chapter delves into the contemporary approaches to diagnosing and managing constrictive pericarditis. This remains a potentially curable form of disease, thus providing good quality of life for the patient. Hence, the diagnosis/management is of prime importance. Early and accurate diagnosis is critical and relies on a combination of clinical evaluation, imaging techniques such as echocardiography, cardiac MRI, and CT, as well as invasive hemodynamic assessment. Pericardiectomy remains the definitive treatment for this condition.

Keywords: Constrictive pericarditis, constrictive physiology, constrictive versus restrictive

INTRODUCTION

Constrictive pathophysiology of the pericardium results from an extended insult to the structure over a few months to years with the end result being a fibrotic, calcified pericardium. In the developed world, the main causes are idiopathic, postsurgical, and radiation. But in developing countries, tuberculosis (TB) remains till date to be the predominant cause ranging from 22 to 91% in varied analysis globally (developing countries). Since the clinical characteristics are suggestive of diastolic heart failure, there is a diagnostic dilemma between constrictive pericarditis and restrictive cardiomyopathy. Fibrous casing of the pericardium results in ineffective cardiac filling and a subsequent low output state. The resultant clinical picture/symptomatology is of right heart failure.[1]

NORMAL CARDIAC/PERICARDIAL HEMODYNAMICS

Diastolic filling is dependent on both factors external such as vascular load on the cardia and the nature of pericardium, as well as internal factors such as myocardial properties/stiffness. The ventricular diastole though complicated in actual physiological interplay can be largely simplified into three stages—(1) ventricular relaxation, (2) filling by passive means, and (3) atrial systole contributing to ventricular filling.

Early and passive fillings are contributed mainly by ventricular relaxation, elevated left atrial pressure, interventricular dependance, and myocardial compliance. The atrial contraction distends the ventricle, providing the nidus for further ventricular systole.

Structures within the Pericardium

Left and right ventricles, right atrium, and majority of the left atrium are intrapericardial. The pulmonary venous system, SVC, and IVC are extrapericardial. In addition to this, the SVC and IVC are outside the thoracic cavity, while the pulmonary venous system is largely intrathoracic. The effects of respiration are largely applicable to the pulmonary veins, but not the SVC and IVC.

Hence, during inspiration, there is augmentation of right-sided filling as there is a decrease in thoracic cavitary pressure of approximately 10 mm Hg with the systemic venous pressure being constant. There is a gradual yet not a significant decrease in left-sided heart filling as the pulmonary veins are largely intrathoracic.

JAYPEE BROTHERS

HEMODYNAMICS OF CONSTRICTIVE PERICARDITIS: FIXED CARDIAC VOLUME

The hemodynamic hallmark of constrictive pericarditis is equal and raised diastolic pressures in the left and right sides and fixed intracardiac volume during the diastolic phase throughout the respiratory cycle.

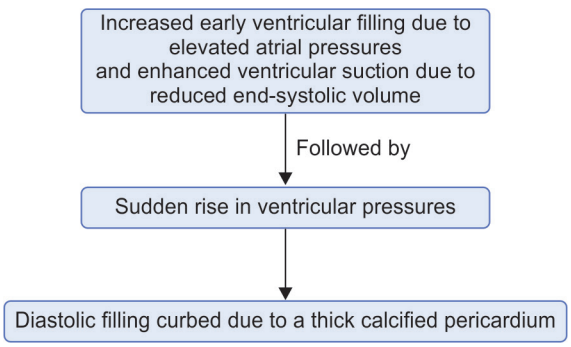

The rapid ventricular filling is accounted by the rapid "Y descent" on JVP and the square root sign during invasive hemodynamic assessment.

The rigid pericardium detaches the cardia from changes in the respiratory variations in intrathoracic pressure. On inspiration, the intrathoracic pressures are transmitted to the pulmonary venous system as they are intrathoracic, but not the left side. As there is a fixed total cardiac volume by the thick pericardium, there is increased right-sided filling with the interventricular septum moving toward the left side.

INSPIRATORY INTERVENTRICULAR SEPTAL MOTION TOWARD LEFT VENTRICLE

Kussmaul's Sign

During inspiration there is an increase in IVC inflow to right side, which is accentuated by enhanced transdiaphragmatic pressures, this competes with SVC inflow into the high pressure RA.

With expiration there is increase in intrathoracic pressures, which are transmitted to the pulmonary venous/capillary system thus increasing the inflow to the left side, pushing the IVS to the right side and thereby reducing RV inflow.

DIAGNOSIS—CLINICAL

The clinical picture depicts predominant presentation with right heart failure symptoms:

- Lower extremity edema
- Ascites

Progressing to:

- Congestive hepatopathy
- Anasarca

Can have features of extreme low cardiac output such as:

- Fatigue
- Cachexia

HALLMARK CLINICAL SIGNS

- Sudden and rapidly collapsing Y descent, with normal X descent resulting in M-shaped venous pressure contour
- Kussmaul's sign—inspiratory increase in JVP
- *Pulsus paradoxus*—in effusive constrictive pericarditis

Classically defined as an exaggerated inspiratory decline in systolic blood pressure > 10 mm Hg. This phenomenon was first explained by Kussmaul in 1873. The paradox being, total obliteration of Korotkoff sounds on inspiration, while there is cardiac activity. Cardiac tamponade is the prototype of this phenomenon, while other conditions such as acute exacerbation of COPD/constrictive pericarditis can exhibit this.

Mechanism of pulsus paradoxus: The exact mechanism of pulsus paradoxus in CCP is not known,[2] but multiple theories have been published.

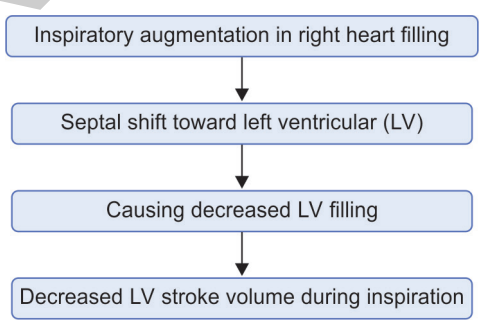

Ling et al. documented this sign in 19% of patients with CCP.[3] It is more common in effusive constrictive pericarditis, as observed by Sagrista et al. in up to 66% of patients.[4]

Pericardial knock on auscultation: Early, high-pitched diastolic sound

CHEST X-RAY IN CONSTRICTIVE PERICARDITIS

X-rays play a limited but useful role in diagnosing CP. It can reveal signs such as pericardial calcification which appears as dense, curvilinear shadows along heart borders. Enlarged cardiac silhouette and the pleural effusions may also be observed. However, X-ray lacks the specificity and detail of advanced imaging modalities like CT. Despite these limitations, chest X-rays are valuable for initial assessment and can prompt further, more detailed investigations if CP

JAYPEE BROTHERS

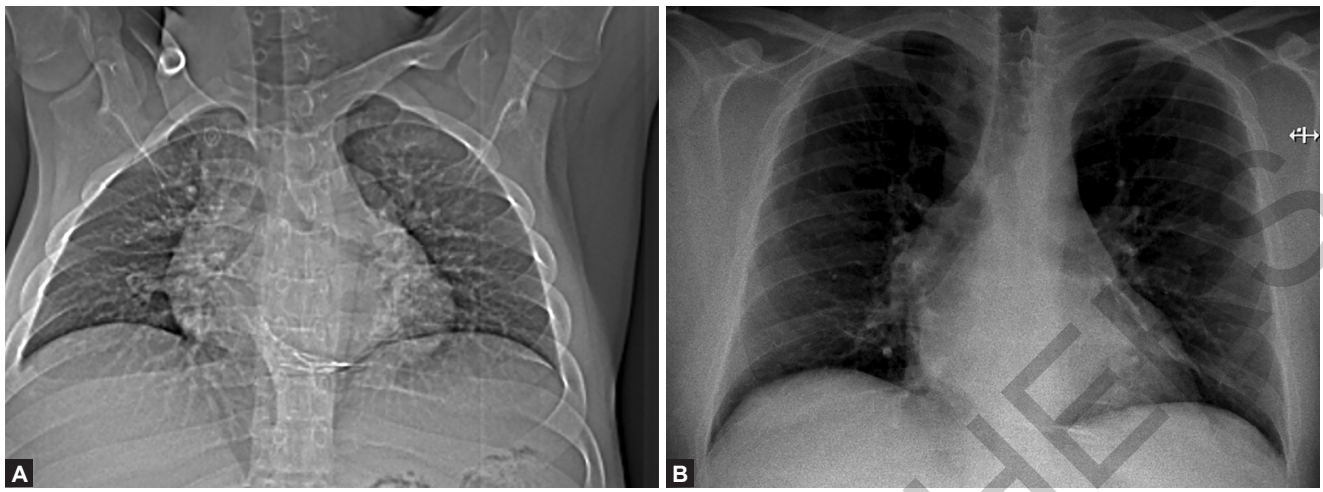

FIGS. 1A AND B: Pericardial calcification seen on chest X-ray.

is suspected based on clinical and radiographic findings **(Figs. 1A and B)**.

TRANSTHORACIC ECHOCARDIOGRAPHY

Noninvasive and extremely accurate for diagnosing pericardial pathology/thickening **(Fig. 2)**.

General Considerations

- Accurate assessment of septal motion with respect to the respiratory cycle (ventricular interdependence), to obtain long record (>12 beats), covering the entire cycle.
- While attempting to demonstrate constrictive physiology on echocardiography, the use of respirometry should be mandatory and a prerequisite while recording Dopplers of mitral/tricuspid inflow, hepatic vein, SVC, and while looking for septal motion.
- Hepatic vein Doppler assessment is important, as it can be dilated in both constrictive and restrictive physiology.[5]

Ventricular Septal Bounce and Interventricular Dependance

Septal bounce and inspiratory leftward septal shift along with expiratory rightward septal shift are typical in CP. The respirophasic septal movement provides the initial differential whether we are dealing with a constrictive physiology.

Septal bounce is simply reflective of the early LV and RV differential diastolic filling and its sudden cessation due to the pericardial nature in CP. IVS bounce is sensitive, it is not specific for CP and it can arise from various conditions such as postsurgery or conduction/pacing-associated septal movements. This is associated with septal notch on M-Mode and diastolic flattening of posterior wall in CP, but are still far less sensitive and specific.

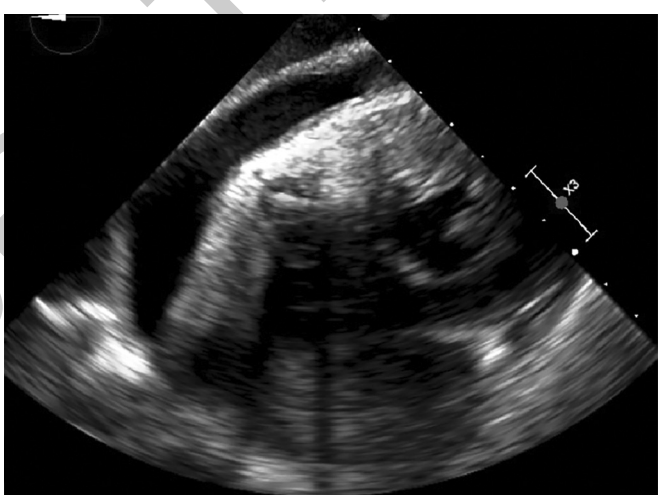

FIG. 2: Echocardiogram showing: Thickened pericardium with localized pericardial effusion alongside right ventricle.

In a series of patients with constrictive pericarditis, the septal shift suggestive of interventricular dependence had 92% PPV and 94% NPV.

Tissue Doppler Imaging on Echocardiography

The early mitral annulus velocity (*E'*) is a marker of adequate LV relaxation/diastolic function. Normally, the lateral mitral annular velocity is higher than the medial velocity due to unrestricted movement. In constrictive physiology due to lateral pericardial adhesions, there is a restraint on the movement of cardia. Hence the mitral annular *E'* is more than lateral annular *E'*—*"annulus reversus"*.

JAYPEE BROTHERS

In view of the adhesions and restriction of the lateral LV myocardium, LV filling is more dependent on the septal relaxation.

In a small series by Welch et al., medial E' > 9 cm/s and the ratio of medial and lateral E' of >0.91 had a positive predictive value of 90%. Hence in a patient with known myocardial pathology and congestive cardiac failure, a high medial E' should alert the physician whether constrictive physiology is at play.[6]

HEPATIC PULSE VEIN DOPPLER

The most specific sign for constrictive pericarditis on echocardiography is the accentuated expiratory flow reversal in hepatic vein. The specificity and positive predictive value are >90%.

Mechanism for Hepatic Vein Expiratory Flow Reversal

During expiration increase in left-sided filling, curbs the filling of the right side due to interventricular dependence. This reduces the forward hepatic vein outflow and accentuates the normal late diastolic velocity **(Fig. 3)**.

The hepatic vein expiratory diastolic reversal velocity as calculated by:

$$\frac{\text{Late diastolic reversal velocity}}{\text{Systolic forward flow velocity}}$$

If >0.79, positive predictive value is >95%.

Mitral and Tricuspid Inflow Respiratory Variations

More than 25% variation in mitral inflow Doppler with increased velocity during expiration is noted with >40% occurring on the tricuspid inflow Doppler. The tricuspid respiratory variations that so occur, do so while on inspiration **(Figs. 4 and 5)**.

The specificity and positive predictive value are <80%.

Two-dimensional Speckle Tracking

Additional and new tool in differentiation of CP from RCM/myocardial pathologies. Torsional and circumferential strain, both predominantly from subepicardial myocardium are decreased in constrictive pericarditis compared to restrictive cardiomyopathy. On the other hand, longitudinal strain is markedly affected in cardiac amyloidosis.[7]

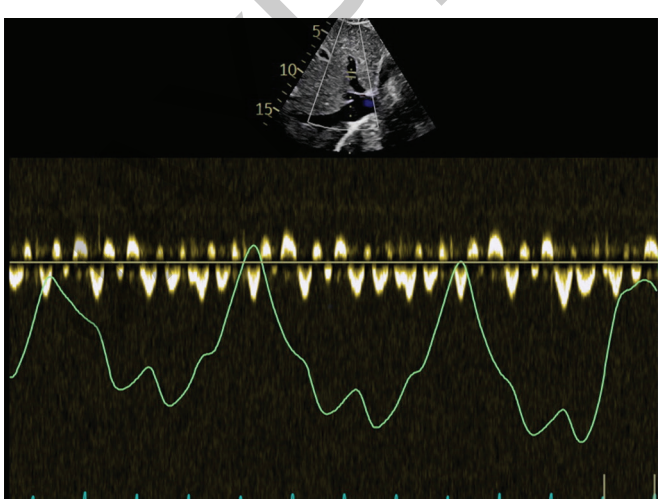

FIG. 3: Echocardiogram—hepatic vein expiratory flow reversal.

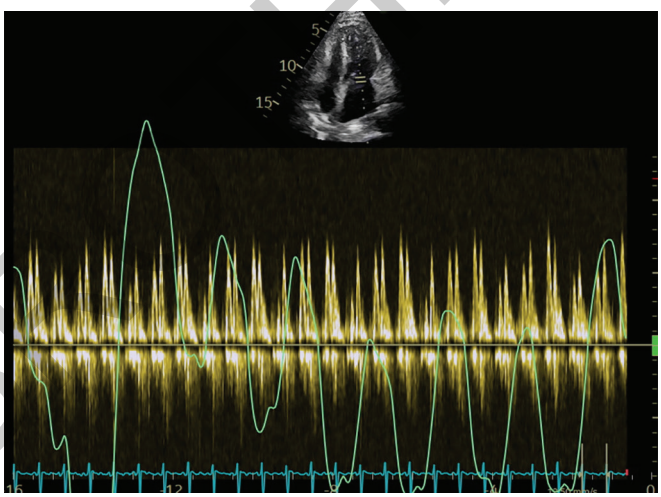

FIG. 4: Echo: Mitral expiratory increase in inflow on PW Doppler.

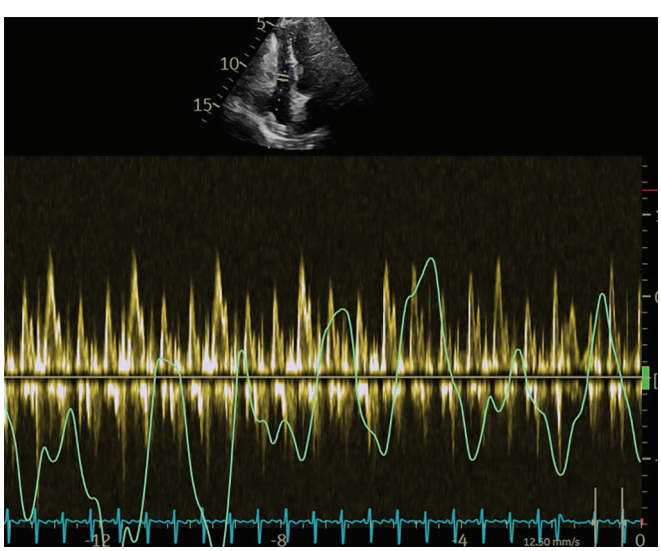

FIG. 5: Echo: Tricuspid inspiratory increase in inflow on PW Doppler.

FREE BOOKS

COMPUTED TOMOGRAPHY

The CT scanning, particularly using MDCT, is highly effective in evaluating the structural aspects of CP. It proven to be highly effective in evaluating the structural aspects of CP. It provides high-resolution images that can detail the extent of pericardial thickening and calcification. The advantages of CT in diagnosing CP include **(Fig. 6)**:

- *Pericardial thickening and calcification*: CT can precisely measure the pericardial thickness, with values > 4 mm typically suggestive of CP. Calcifications, commonly seen in CP, are well visualized on CT often appearing as dense, bright areas within the pericardium.
- *Evaluation of pericardial effusion*: CT can assess presence and size of pericardial effusions, which may coexist with CP. It also aids distinguishing between CP and other causes of effusion.
- *Cardiac chamber morphology*: It can reveal secondary signs of CP, such as abnormal septal motion and changes in the size and shape of the cardiac chambers.
- *Vascular assessment*: Vena caval enlargement or hepatic vein congestion, providing a comprehensive view of the circulatory impact of CP
- *Coronary status*: Coronary atherosclerosis/graft patency can also be checked while doing the CT.[8]

MRI IMAGING IN CONSTRICTIVE PERICARDITIS

An MRI has achieved great strides in diagnosing various cardiac especially myocardial disorders, providing a wealth of information in every dimension possible. The temporal and spatial resolution achieved from CMRI allows us to examine every little detail of cardiac anatomy and physiology. With various sequences that can be used, cardiac structures can be noninvasively characterized to a great extent. In the strata of pericardial disorders too, CMRI has a place in the diagnostic tree.

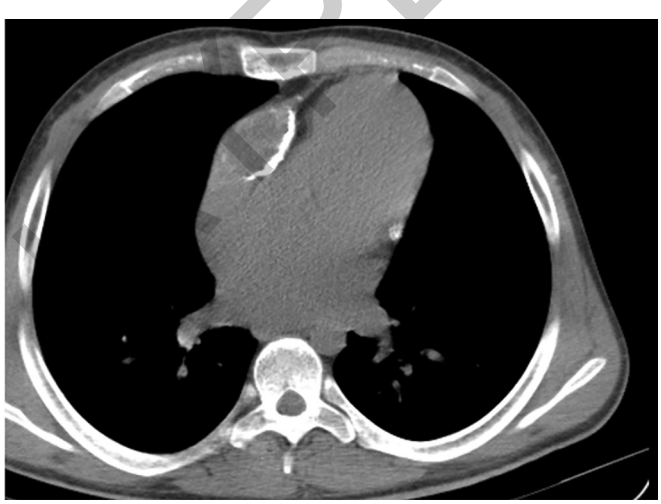

FIG. 6: CT chest showing: Thickened pericardium with interspersed calcium.

Cardiac Anatomy

Interestingly biatrial dilatation can be seen in both RCM and CP, but the relative ratio (left atrial to right atrial volumes) is found to be higher with CP. The ratio of 1.32 is found to have higher specificity and sensitivity. In such cases, a fibrotic pericardium and thickened pericardium (>4 mm) increase the positive predictive value to >90%.

Myocardial Characterization

LGE might not be present in a pure constrictive pericarditis, but pericardial LGE could be a feature of myopericarditis.

Hemodynamic Evaluation

Hemodynamic assessment is possible similar to echocardiography. Mitral/tricuspid inflow phase contrast sequences are possible. 3D/4D imaging has supported study of intracardiac flow patterns and abnormalities associated with it.

Real-time, breathing CMRI allows recording of respirophasic septal shift.

Septal shift on MRI is defined as the maximal difference in expiratory and inspiratory position of IVS. A baseline cut-off of 11.8 % has been published to distinguish CP and RCM **(Figs. 7A and B)**.

HEMODYNAMIC CATHETERIZATION

Constrictive pericarditis or physiology though has an array of echocardiographic signs, it is still to date a hemodynamic diagnosis. Cardiac catheterization is done to differentiate from restrictive cardiomyopathy, which is a close mimicker as there is equalization of diastolic pressures with subtle but important signs **(Fig. 8)**.

Square Root/Dip and Plateau Sign

There is rapid increase in early ventricular filling pressures followed by a plateau due to the pericardial restraint on cardiac filling. This can be noted in both RCM and CP, but a LV filling curve of height > 7 mm Hg points more toward CP **(Fig. 9)**.

Kussmaul's Sign

Observed as <5 mm Hg decrease in inspiratory RA pressures, can be present in both CP and RCM.

Equalization of Diastolic Pressures

A difference in RV and LV end-diastolic pressures of <5 mm Hg results from fixed cardiac volume and from ventricular interdependence **(Fig. 10)**.

PEE BROTHERS

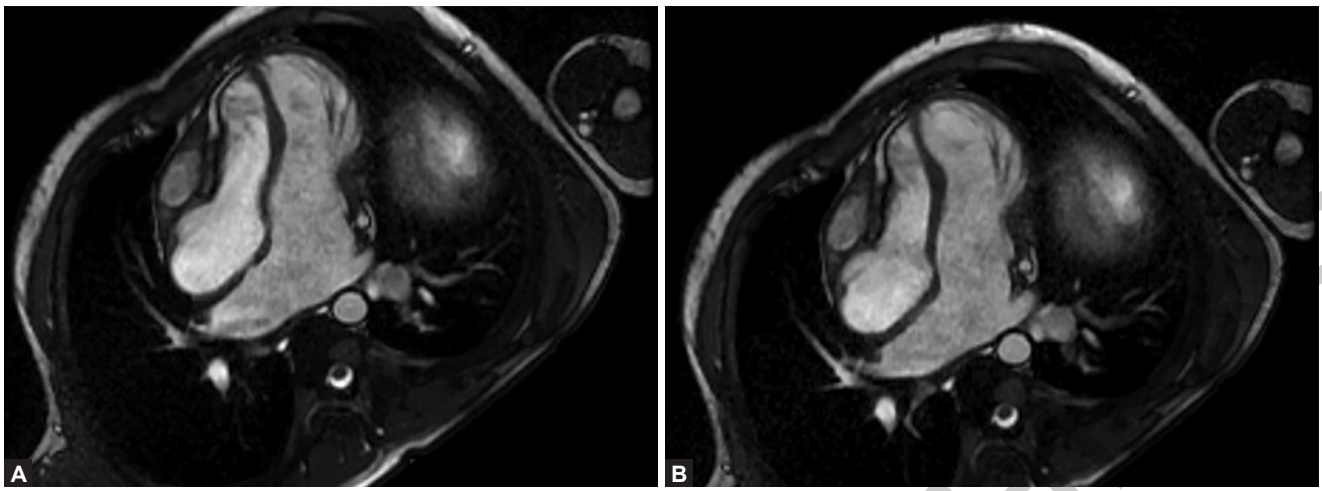

FIGS. 7A AND B: MRI four-chamber cine showing interventricular dependence. (A) The septal shift toward to the LV during inspiration. (B) The septal shift toward the RV during expiration.

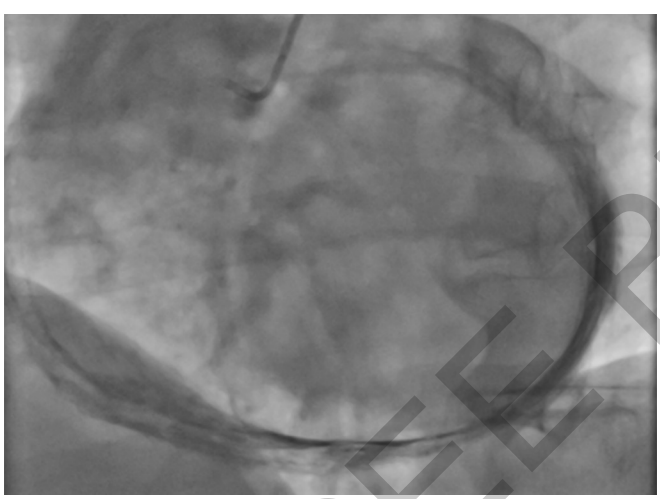

FIG. 8: Cine image of a calcific thickened pericardium while performing cardiac catheterization.

MANAGEMENT

A multidisciplinary heart team approach is always key in managing such patients with complex diagnosis where both hemodynamic physiology and anatomy is at question.

Surgical pericardiectomy remains the treatment of choice.

Pericardiectomy

The first pericardiectomy done by Rehn in 1913 in Germany and by Churchill in 1929 in the United States.

Risk factors for poor post operative outcomes include:

- Radiation associated constrictive pericarditis
- Medical comorbidities
- COPD/renal disease
- LV dysfunction
- Higher NYHA class

Diuretics and salt restriction though help in relieving congestive symptoms are not mainstay. Since sinus tachycardia is a protective mechanism to maintain forward output, it is best not to administer rate control medications.

Pericardiectomy is mostly performed through median sternotomy or bilateral thoracotomy with or without CP bypass. More extensive involvement of the epicardium has been handled with "waffle procedure" by means of longitudinal incisions in the epicardium. Symptomatic and physiological improvement is dramatic after pericardiectomy, which happens in a few patients, can appear after few weeks to months in others. The 5-year survival rates have been satisfactory, >80% and 10 year survival rates 50–80%.

INDIAN CONTEMPORARY DATA

Follow-up outcomes of patients with constrictive pericarditis and who have undergone pericardiectomy were studied by Bashi et al. in CMC Vellore. Though this study was done in 1988 reviewing patients done prior, the outcomes and results still hold valid in today's era. About 118 patients were included, of which males were predominant (86 males). Preoperatively >95% patients fell under NYHA III to IV for breathlessness and 100 patients had anasarca. TB was the proven predominant cause of the pathology with 72 patients affected. However in contrast to modern literature, anterolateral thoracotomy was done in 107 cases. Median sternotomy was done in three patients. Postoperatively a low output state was observed in 34 patients, in which 12 patients expired. At follow-up, there were 72 patients, among whom 63 patients were in Class I/II NYHA.[9]

JAYPEE BROTHERS

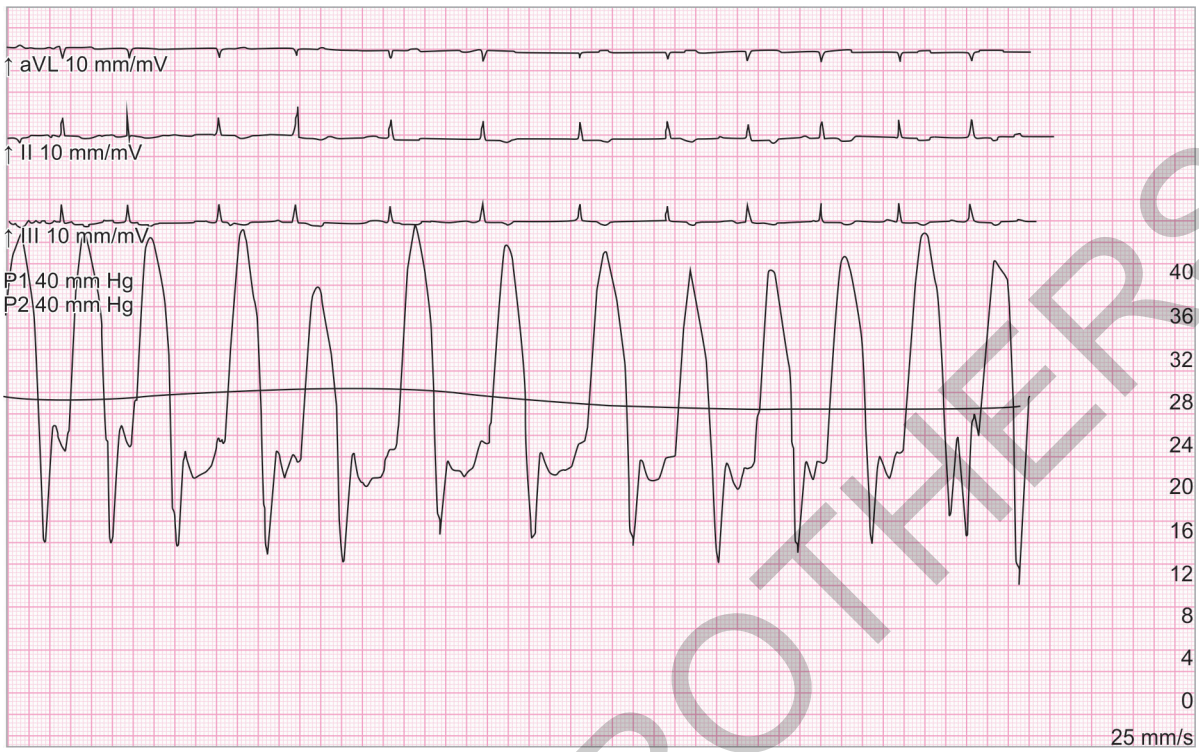

FIG. 9: Square root sign/dip and plateau sign.



FIG. 10: Respirophasic changes in LV/RV pressures.

JAYPEE BROTHERS

COMPREHENSIVE META-ANALYSIS

Tzani et al. conducted a comprehensive meta-analysis search of the MEDLINE, Embase, and Cochrane databases up to April 1, 2020, for studies assessing pericardiectomy outcomes. Studies with patients enrolled before 1985, pediatric patients, or those including >10% of cases with tuberculous pericarditis were excluded. They analyzed 27 eligible studies encompassing 2,114 patients. The most common etiology of constrictive pericarditis was idiopathic (50.2%), followed by postcardiac surgery (26.2%), and radiation (6.9%). The patient population was predominantly male (76%) with a mean age of 58 years and advanced symptoms (NYHA class III/IV in 70.1%). Advanced heart failure (NYHA class III-IV) was present in 70.1% of patients, and 33.1% had ascites. Peripheral edema (64.7%) and hepatomegaly (35.6%) were common, but not consistently reported.[10]

The surgical approach favored total pericardiectomy (85.8%) with midline sternotomy with a significant proportion undergoing concomitant cardiac surgeries (23.8%). The operative mortality was 6.9%, while the 5-year mortality was 32.7%. The 10-year survival rate for patients who underwent pericardiectomy for constrictive pericarditis, according to the meta-analysis, was 55%.

The analysis revealed that pericardiectomy practices have evolved over the years, with an increasing preference for complete pericardiectomy and concomitant cardiac surgeries post-2000. The inpatient and 30-day all-cause mortality rates had not significantly changed over the years, indicating a persistent high-risk profile for these patients. Long-term outcomes, including reoperation and rehospitalization for heart failure, remain concerns, with pooled rates of 8% and 11%, respectively.

PERSONAL EXPERIENCE

In our setting, we have had 20 patients in the past 25 years diagnosed to have constrictive physiology and undergone pericardiectomy, out of which three patients had pericardiectomy done in the pediatric age group (<14 years), etiology in two being TB and one patient idiopathic. All patients were males. About 17 patients had features suggestive of right heart symptoms, ascites along with fever and constitutional symptoms. About 19 patients were in NYHA class III dyspnea on exertion prior to the surgery. On echocardiogram, features suggestive of septal bounce and interventricular dependence could be seen in >90%. Hepatic vein systolic reversal on PW doppler proved to be specific sign which could be noted in all patients. Four patients had dense circumferential calcification while others had thickened pericardium with varying degrees of pericardial effusion with interspersed calcium.

All patients underwent pericardiectomy through midline sternotomy. Three patients had concomitant revascularization done with one graft in each patient. About 12 patients had undergone complete pericardiectomy. Eight patients had proven TB from tissue/MTB PCR. Three patients had expired in immediate postoperative period. Two patients died due to a low cardiac output state, while other cause was sepsis associated multiorgan dysfunction. At follow-up, 15 patients are currently still under follow-up, in functional class I to II.

CONCLUSION

Constrictive pericarditis and its different forms remain a potentially curable form of cardiac disease, with postsurgery patients having good quality of life. The most common cause in developing countries continues to be TB, whereas in the West it is idiopathic pericarditis. Multimodality noninvasive imaging and the latest advancements in the field of imaging do help increase the diagnostic power, and provide an insight toward the diagnosis, and planning an efficient surgical procedure.



ONLINE REFERENCES

Please scan the QR code provided at the end of the table of contents for References of this chapter.

JAYPEE BROTHERS

for detailed information on cardiology books, visit our website www.jaypeebrothers.com, for detailed information on cardiology books, visit our website www.jay

Cardiological Society of India

CARDIOLOGY UPDATE 2024

This latest edition of *CSI Cardiology Update 2024* offers state-of-the-art, concise, comprehensive coverage on recent advances in cardiology from a galaxy of experts in the field. It features chapters on cutting-edge diagnostic imaging, advanced coronary, structural interventions and breakthroughs in cardiovascular genetics. This edition is crafted to meet the needs of modern cardiologists, fellows, and medical students. Key updates include expanded coverage of precision medicine, emerging therapeutics for hypertension, heart failure, and the latest guidelines for arrhythmia management. Authored by leading experts, this resource combines clinical insights with the latest evidence, providing a practical and authoritative guide to patient care in a fast evolving field.

The book has 226 chapters in a clear, easy-to-follow organization:

- **Volume one** has chapter on General Cardiology, Echocardiography/Imaging, Artificial Intelligence in Cardiology, Dyslipidemia Management, Hypertension, Heart Failure, Cardiomyopathy/Myocarditis, Cardio-Obstetrics, Congenital Heart Disease, Valvular Heart Disease/Miscellaneous, and Pulmonary Vascular Disease
- **Volume two** deals mainly with Chronic Coronary Syndromes, Acute Coronary Syndrome, Coronary Intervention, Structural Intervention, Mechanical Circulatory Support, Vascular Interventions, Rhythm and Conduction Abnormalities, Cardiorenal Diabetes, Emerging Drugs for Cardiovascular Disease, and Preventive Cardiology

It is an ideal resource for Cardiovascular disease practitioners at all levels of experience.

Sanjay Tyagi
MD(Medicine) DM(Cardiology) FAMS FICP FCSI FICA FRCP(Edinburgh) FSCAI FESC FACC(USA)
Dr BC Roy National Awardee
Senior Consultant, Academic Advisor (HOD) and Clinical Director Cardiology
Apollo Hospitals, Northern Region, New Delhi, India
President-Elect, Cardiological Society of India
Secretary General (India), International College of Cardiology (USA)
National Coordinator, Cardiology and Interventional Cardiology, National Board of Examination

Formerly
Director General Health Services, Government of India
Dean, Maulana Azad Medical College, New Delhi
Director, Professor and HOD, Cardiology
GB Pant Institute of Postgraduate Medical Education and Research

Printed in India

Available at all medical bookstores or buy online at www.ejaypee.com

JAYPEE BROTHERS
Medical Publishers (P) Ltd.
EMCA House, 23/23-B, Ansari Road,
Daryaganj, New Delhi - 110 002, INDIA
www.jaypeebrothers.com

Join us on facebook.com/JaypeeMedicalPublishers
Follow us on instagram.com/JaypeeMedicalPublishers

Shelving Recommendation
CARDIOLOGY

ISBN 978-93-6616-795-4