te www.ejaypee.com, for detailed information on dental books, visit our website www.ejaypee.com, for detailed information on dental books, visit our website www.ejaypee.com,

Thoroughly revised multiple choice questions and fill in the blanks according to the latest syllabus of DCI

Includes 2025 Papers

Mastering the BDS Ist Year

Last 20 Years Solved Questions



- Anatomy, Functional Anatomy
- Genetics, Neuroanatomy
- Embryology, Osteology
- Histology
- Physiology, Biochemistry
- Dental Anatomy, Dental Histology
- Oral Physiology

Image-based Questions as per NEET-MDS & INI-CET Examination

Hemant Gupta

12th Edition

JAYPEE

CONTENTS

SECTION 1: Anatomy

Head, Neck and Brain 3

1. Mandible 3
2. Scalp 5
3. Face 10
4. Side of the Neck 18
5. Anterior Triangle of Neck 24
6. The Parotid Region 30
7. Temporal and Infratemporal Region 36
8. Submandibular Region 51
9. Structures in the Neck 58
10. The Prevertebral and Paravertebral Region 65
11. Back of the Neck 69
12. The Cranial Cavity 70
13. Contents of the Orbit 77
14. The Mouth and Pharynx 79
15. The Nose and Paranasal Sinuses 91
16. Larynx 99
17. The Tongue 103
18. The Ear 109
19. Miscellaneous 110

Functional Anatomy of Musculoskeletal System 113

1. Introduction 113
2. Skeleton 113
3. Joints 117
4. Circulatory System 120

Genetics 122

1. Chromosomes and their Classification 122
2. Chromosomal Anomalies 124

Neuroanatomy 128

1. Introduction to Brain 128
2. Meninges of the Brain and Cerebrospinal Fluid 128
3. The Spinal Cord 130
4. Cranial nerves 135
5. The Brainstem 145
6. The Cerebellum 149
7. The Fourth Ventricle 151
8. Cerebrum 153
9. The Third Ventricle, Lateral Ventricle and Limbic System 161
10. Blood Supply of Spinal Cord and Brain 161

Upper Limb and Thorax 164

1. Pectoral Region 164
2. Axilla 164
3. Scapular Region 168
4. Cutaneous Nerves, Superficial Veins and Lymphatic Drainage 170
5. Arm 170
6. Bone and Joints of Thorax 171
7. Wall of Thorax 172
8. Thoracic Cavity and Pleurae 173
9. Lungs 173
10. Mediastinum 178
11. Pericardium and Heart 179
12. Trachea, Esophagus and Thoracic Duct 188

Lower Limb, Abdomen and Pelvis 190

1. Front of Thigh 190
2. Popliteal Fossa 192
3. Abdominal Part of Esophagus and Stomach 193
4. Small and Large Intestine 198
5. Spleen, Pancreas and Liver 201
6. Kidney and Ureter 205
7. Diaphragm 209
8. Urinary Bladder and Urethra 210
9. Female Reproductive Organs 210

- *Multiple Choice Questions* *215*
- *Fill in the Blanks* *220*
- *Additional Matter* *222*
- *One Liners* *232*

SECTION 2: Embryology

1. Introduction and Some Preliminary Considerations 239
2. Reproductive System, Gametogenesis, Ovarian and Menstrual Cycles 239
3. First Week of Development: Stages of Embryology/ Gestational Period 242
4. Third Week of Development: Germinal Period 246
5. Placenta, Fetal Membranes and Twinning 248
6. Formation of Tissues of the Body 249

7. Branchial Apparatus (Pharyngeal Arches + Endodermal Pouches + Ectodermal Clefts) 249
8. Skeletal System and Muscular System 254
9. Face, Nose and Palate 255
10. Alimentary System I: Mouth, Pharynx and Related Structures 260
11. The Nervous System 263
12. Fate of Germ Layers 263

SECTION 3: Osteology

1. Osteology 267

SECTION 4: Histology

1. Epithelial Tissue 277
2. Cartilage 278
3. Bone Tissue 280
4. Muscular Tissue 281
5. Cardiovascular System 282
6. Lymphatic Tissue 283
7. Skin 286
8. Respiratory System 286
9. The Digestive System I: Oral Cavity 287
10. The Digestive System II: Alimentary Canal 292
11. The Digestive System III: Liver, Gallbladder and Pancreas 292
12. The Endocrine System 295
13. The Urinary System 296
14. Male Reproductive System 298
15. The Nervous System 298

- *Multiple Choice Questions* 300
- *Fill in the Blanks* 305
- *Viva-voce Questions for Practical Examination* 308

SECTION 5: Physiology

1. General Physiology 315
2. Blood 323
3. Muscle Physiology 346
4. Digestive System 357
5. Renal Physiology and Skin 373
6. Endocrine System 388
7. Reproductive System 409
8. Cardiovascular System 418
9. Respiratory System 441
10. Nervous System 457
11. Special Senses 484
12. Metabolism and Nutrition 494
13. Miscellaneous 494

- *Multiple Choice Questions* 495
- *Viva-voce Questions for Practical Examination* 500
- *Additional Matter* 503
- *One Liners* 513

SECTION 6: Biochemistry

1. Biomolecules and the Cell 521
2. Carbohydrates: Chemistry, Metabolism and Regulation 521
3. Amino Acids and Proteins: Chemistry, Metabolism and Regulation 540
4. Nucleic Acids: Chemistry, Metabolism and Regulation 556
5. Lipids: Chemistry, Metabolism and Regulation 572
6. Mineral Metabolism 584
7. Biological Oxidation 593
8. Enzymology 596
9. Hemoglobin and Porphyrin 607
10. Energy Metabolism and Nutrition 611
11. Detoxification, Free Radicals and Antioxidants 619
12. Organ Function Tests 622
13. Vitamins 631
14. Plasma Proteins 643
15. Water, Electrolyte and Acid-Base Balance 645
16. Cancer 649
17. Tissue Proteins and Body Fluids 650

- *Multiple Choice Questions* 652
- *Viva-voce Questions for Practical Examination* 657
- *Additional Matter* 659
- *One Liners* 662

SECTION 7: Dental Anatomy

1. Introduction of Dental Anatomy 667
2. Tooth Numbering Systems 675
3. Chronology of Tooth Development 678
4. Form and Function of Orofacial Complex 680
5. The Primary (Deciduous) Dentition 682
6. Differences between Primary and Permanent Dentition 685
7. The Maxillary and Mandibular Incisors 690
8. The Maxillary and Mandibular Canines 696
9. The Maxillary and Mandibular Premolars 703
10. The Maxillary and Mandibular Molars 716
11. Pulp Morphology 726
12. Occlusion 729
13. Review of Tooth Morphology 735
14. Temporomandibular Joint 736

- *Multiple Choice Questions* 740
- *Fill in the Blanks* 743

- *Viva-voce Questions for Practical Examination* 744
- *Additional Matter* 747
- *One Liners* 751

SECTION 8: Dental Histology

1. Development of Face and Oral Cavity 755
2. Development and Growth of Teeth 757
3. Enamel 766
4. Dentin 780
5. Pulp 787
6. Cementum 794
7. Periodontal Ligament 803
8. Bone 812
9. Oral Mucous Membrane 820
10. Salivary Gland 837
11. Tooth Eruption 848
12. Shedding of Deciduous Teeth 852
13. Temporomandibular Joint 854
14. Maxillary Sinus 855
15. Age Changes in Oral Tissues 857
16. An Outline of Histochemistry of Oral Tissues 860
17. Preparation of Specimens for Histologic Study 861

- *Multiple Choice Questions* 865
- *Fill in the Blanks* 872
- *Viva-voce Questions for Practical Examination* 873
- *Additional Matter* 876
- *One Liners* 880

SECTION 9: Oral Physiology

1. Vascular and Nerve Supply of Orofacial Region 885
2. Calcium and Phosphorus Metabolism 886
3. Deglutition 887
4. Mastication 888
5. Speech 890
6. Theories of Mineralization 891

Image-based Questions ***893***

SECTION 9

Oral Physiology

1. Vascular and Nerve Supply of Orofacial Region
2. Calcium and Phosphorus Metabolism
3. Deglutition
4. Mastication
5. Speech
6. Theories of Mineralization

JAYPEE BROTHERS

JAYPEE BROTHERS

1. VASCULAR AND NERVE SUPPLY OF OROFACIAL REGION

Q.1. Answer in brief branches of mandibular nerve.
(Feb 2016, 2 Marks)

Ans. Following are the branches of mandibular nerve:

Branches from Undivided Nerve

- **Nervous spinosus:** It re-enters the skull via foramen spinosum along with middle meningeal artery to supply dura mater and lining of mastoid cells.
- **Nerve to medial pterygoid:** It supplies medial pterygoid muscle.

Branch from Anterior Division

- Masseteric nerve supplies masseter muscle and tempo-romandibular joint.
- Deep temporal nerve supplies temporalis muscle.
- Nerve to lateral pterygoid supplies to lateral pterygoid muscle.
- Buccinator nerve supplies skin and mucous membrane which is related to buccinator muscle.

Branch from Posterior Division

- Auriculotemporal nerve divides into following parts:
  - Auricular part supplies to skin of tragus, upper part of pinna, external acoustic meatus, tympanic membrane.
  - Temporal part supplies to skin of temporal region.
  - Auricular branch supplies to temporomandibular joint.
  - Parotid branch supplies to parotid gland.
- **Lingual:** This nerve carries sensation from mucus membrane of anterior two third of tongue and mucosa on lingual side of mandible.
- **Inferior alveolar nerve:** Inferior alveolar nerve along with the inferior alveolar artery enters the mandibular foramen to run anteriorly and downward below the teeth in mandibular canal, till it reaches mental foramen. At mental foramen the nerve terminates by giving off two branches, i.e., incisive and mental. Various branches of inferior alveolar nerve and their innervations are as follows:
  - Mylohyoid nerve: This branch arises from inferior alveolar nerve before it enters in mandibular foramen. This nerve runs anteroinferiorly over the medial surface of mandible to reach mylohyoid muscle. This nerve pierces sphenomandibular ligament to supply mylohyoid muscle and anterior belly of digastric muscle.
  - Alveolar branches: They supply the teeth. Nerve twigs which arises from inferior alveolar nerve corresponding to every tooth. These nerve twigs enter the pulp of teeth via apical foramen present at root tips.
  - Incisive branch: This is one of the terminal branch of inferior alveolar nerve. This branch runs anteriorly in inferior alveolar canal to supply both canine and incisors.
  - Mental nerve: This is also the terminal branch of inferior alveolar nerve. It comes out from inferior alveolar nerve via mental foramen. Mental nerve emerges through it and divides into three branches which supply the skin over chin and skin as well as mucus membrane of lower lip.

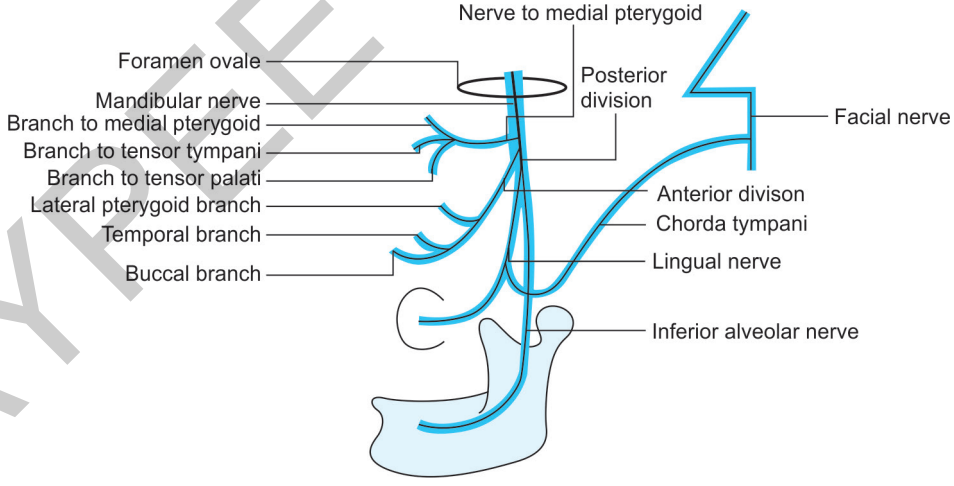

Fig. 1: Branches of mandibular nerve.

Q.2. Write short note on inferior alveolar nerve.
(Aug 2016, 3 Marks)

Ans. Inferior alveolar nerve is the largest branch of mandibular nerve.

Inferior alveolar nerve along with the inferior alveolar artery enters the mandibular foramen to run anteriorly and downward below the teeth in mandibular canal, till it reaches mental foramen. At mental foramen the nerve terminates by giving off two branches, i.e., incisive and mental. Various branches of inferior alveolar nerve and their innervations are as follows:

- **Mylohyoid nerve:** This branch arises from inferior alveolar nerve before it enters in mandibular foramen. This nerve runs anteroinferiorly over the medial surface of mandible to reach mylohyoid muscle. This nerve pierces sphenomandibular ligament to supply mylohyoid muscle and anterior belly of digastric muscle.
- **Alveolar branches:** They supply the teeth. Nerve twigs which arises from inferior alveolar nerve corresponding to every tooth. These nerve twigs enter the pulp of teeth via apical foramen present at root tips.

JAYPEE BROTHERS

- **Incisive branch:** This is one of the terminal branch of inferior alveolar nerve. This branch runs anteriorly in inferior alveolar canal to supply both canine and incisors.
- **Mental nerve:** This is also the terminal branch of inferior alveolar nerve. It comes out from inferior alveolar nerve via mental foramen. Mental nerve emerges through it and divide in three branches which supply the skin over chin and skin as well as mucus membrane of lower lip.

Q.3. List branches of inferior alveolar nerve.

(Sep 2017, 2 Marks)

Ans. Following is the listing of branches of inferior alveolar nerve:

- Mylohyoid nerve
- Alveolar or dental branch
- Incisive branch
- Mental nerve

Q.4. Write short answer on nerve supply of teeth.

(May 2019, 3 Marks)

Ans. Teeth are supplied by the branches of trigeminal nerve. Branches of trigeminal nerve are ophthalmic, maxillary and mandibular. Teeth are mainly supplied by maxillary and mandibular nerve.

Maxillary Branch

- It supplies maxillary teeth. During its course when it passes through pterygopalatine fossa it gives 5 branches out of which one is posterior superior alveolar branch.
- An internal branch of posterior superior alveolar nerve goes along with a branch of the maxillary artery through the posterior alveolar canal which opens on the posterior surface of the maxilla.
- In the bone, nerve passes down the posterior or posterolateral wall of the maxillary sinus, giving of sensory fibers. It then supplies the maxillary molars except the mesiobuccal root of the first molar.
- Within the depth of the alveolar bone or tooth socket some nerve fiber passes to supply the periodontal ligament whereas other, the pulpal fibers passes through the apical foramina of the roots of the molar teeth to supply the dental pulp.
- When maxillary nerve passes through inferior orbital groove and canal it gives off:
  1. **Middle superior alveolar nerve:** From inferior orbital canal it passes in a downward and anterior direction and supplies the maxillary premolars and mesiobuccal root of the first molar.
  2. **Anterior superior alveolar nerve:** The anterior superior alveolar nerve descends in fine canal in the maxilla to pass the roots of the maxillary central incisor, lateral incisor and canine teeth.

Mandibular Division

- It supplies mandibular teeth.
- Inferior alveolar nerve which is the largest of the branches of the posterior division of the mandibular part of the trigeminal nerve supply mandibular teeth.
- In the inferior alveolar canal it gives off branches to the mandibular teeth as apical fibers that enter the apical foramina of the mandibular teeth to supply the dental pulp of mandibular molars and premolars.
- As the inferior alveolar nerve reaches the region of mental foramina it gives incisive branch which forms a fine incisive plexus that supplies the canine and the incisor teeth.

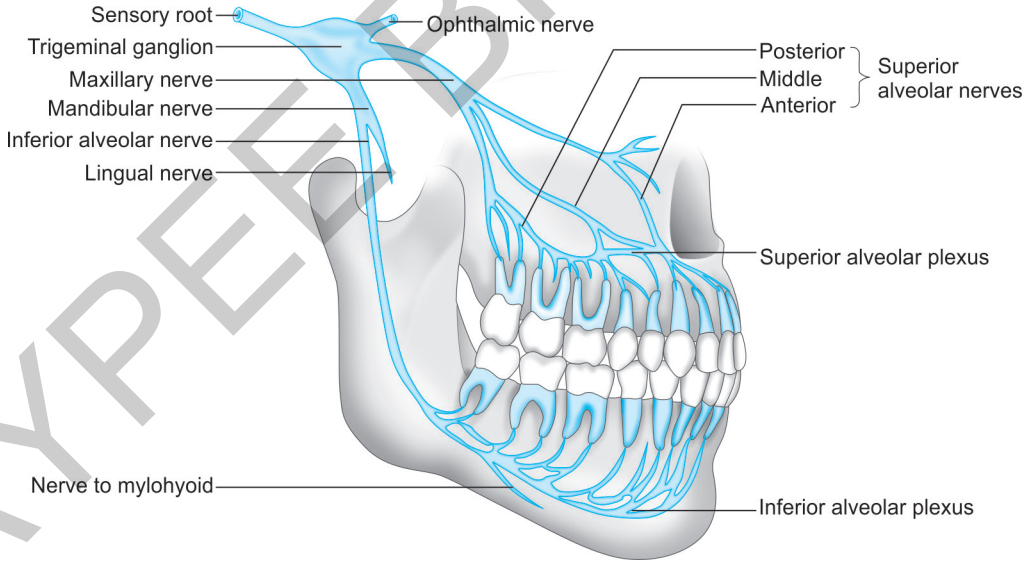

Fig. 2: Nerve supply of teeth.

2. CALCIUM AND PHOSPHORUS METABOLISM

Q.1. Write short note on calcium metabolism.

(Sep 2017, 3 Marks) (Feb 2016, 3 Marks)

Or

Write short answer on calcium metabolism.

(Mar 2021, 3 Marks)

Or

Write short essay on calcium metabolism.

(Feb 2023, 3 Marks)

Ans. Calcium Metabolism

Calcium Absorption

Calcium is absorbed in duodenum by energy-dependent active process. Following are the factors which influences absorption:

A. **Factors promoting calcium absorption**

- Vitamin D induces synthesis of calcium binding protein in intestinal epithelial cells and promotes the calcium absorption.

JAYPEE BROTHERS

- Parathyroid hormone enhances calcium absorption through increased synthesis of cholesterol.
- Acidity is favorable for calcium absorption.
- Lactose promote calcium uptake via intestinal cells.
- Arginine and lysine facilitate absorption of calcium.

B. **Factors inhibiting calcium absorption**
- Phytates and oxalates lead to the formation of insoluble salts and interfere with the absorption of calcium.
- High content of dietary phosphate leads to the information of insoluble calcium phosphate and prevent uptake of calcium.
- Free fatty acids react with calcium to form insoluble calcium soaps.
- Alkaline condition is unfavorable for calcium absorption.
- High content of dietary fiber interfere with calcium absorption.

Excretion of Calcium

Calcium is excreted in feces as well as in urine. In feces, it is excreted through exfoliated gastrointestinal tract cells and in urine, it is excreted as calcium phosphate and calcium chloride.

Regulation of Calcium Level

The regulation of blood calcium level took place through three hormones.

1. **Parathormone:** It is secreted by parathyroid gland and its main function is to increase blood calcium level by mobilizing calcium from bone. Parathormone maintains blood calcium level by following actions, on bones, kidney and GIT:
   a. By increasing reabsorption of calcium from bones.
   b. By decreasing excretion of calcium through kidneys.
   c. By increasing absorption of calcium from GIT.
2. **1, 25-dihydroxycholecalciferol:** It is a steroid hormone synthesized from vitamin D by means of hydroxylation reactions in liver and kidneys. The main action is to increase blood calcium level by increasing calcium absorption from small intestine. The main actions of 1,25-dihydroxycholecalciferol are:
   a. It increases the absorption of calcium from intestine. It does this by increasing the formation of calcium-binding proteins in intestinal epithelial cells. These proteins act as carrier proteins for facilitated diffusion by which calcium ions are transported. The proteins remain in cells for several weeks after 1,25-dihydroxycholecalciferol has been removed from the body, thus causing prolonged effect on calcium absorption.
   b. It increases the synthesis of calcium-induced ATP in intestinal epithelium.
   c. It increases synthesis of alkaline phosphates in intestinal epithelium.
3. **Calcitonin:** It is secreted by parafollicular cells of thyroid. It is a calcium lowering hormone. It decreases blood calcium level by decreasing reabsorption. It reduces blood calcium level by acting on bone, kidney and intestine.
   a. **On bones:** It facilitates deposition of calcium on bones. It suppresses the activity of osteoclasts which are responsible of calcium from bones.
   b. **On kidney:** It increases excretion of calcium through urine by inhibiting reabsorption of calcium from renal tubules.
   c. **On intestine:** It prevents the absorption of calcium from intestine into blood.

Other Hormones Involved in Calcium Metabolism

- **Growth hormone:** It increases absorption of calcium from intestine and enhances protein synthesis in bone.
- **Insulin:** It is an anabolic hormone which favors bone formation.
- **Sex hormones:** These hormones increases calcium absorption, decreases calcium excretion and enhances bone mineralization. Estrogen has direct effect on bone resorption.
- **Prolactin:** It increases calcitriol production and increases calcium absorption during lactating period.
- **Thyroid hormone:** It increases in levels of thyroid hormone which is accompanied by osteoporosis and hypercalcinuria.

Q.2. Write short essay answer on calcium-phosphate metabolism. *(Oct 2024, 5 Marks)*

Ans. *For calcium metabolism refer to Ans 1 of same chapter*

Phosphate Metabolism

Phosphorus is the second most abundant material in human body after the calcium. It does not occur in the free form and it is present as the phosphate. In the blood, this is present as organic phosphates namely phosphate esters and phospholipids, and also as the inorganic phosphate.

Absorption

It is absorbed predominantly in the jejunum of the small intestine. Unlike, the calcium there is absence of the carrier protein which is involved in the phosphorus absorption. This uses sodium-phosphate cotransporter, or diffuses passively to enter in circulation. As the phosphorus remain present in the abundance in many of the foods and most of ingested phosphate is absorbed much more efficiently than calcium, nutritional deficiency of the phosphorus is rarely appreciated. Factors which favors the calcium absorption, i.e., parathyroid hormone and vitamin D3, favors the phosphorus absorption. Factors which decrease the calcium absorption, i.e., excessive phytates, vitamin D3 deficiency also causes the decrease in phosphorus. High levels of the aluminum and calcium decreases the absorption by forming salts with phosphates.

Excretion

Nearly 85% of the phosphorus which get filtered via renal glomeruli is resorbed back in the circulation. Around 750 to 1,000 mg/day is excreted in the urine. Both dietary phosphorus intake and parathyroid hormone control the reabsorption. Decrease in the dietary intake favors the reabsorption while the parathyroid hormone consists of the phosphaturic tendency. Around 500 mg/day of the unabsorbed phosphorus from intestine is excreted in feces.

Homeostasis

Three of the important factors which maintain phosphorus homeostasis are 1.25-dihydroxycholecalciferol. Parathyroid hormone and fibroblast growth factor-23. Together, they ensure tight regulation of the phosphorus absorption, distribution and excretion. Reabsorption of the phosphorus should be promoted by 1,25 dihydroxycholecalciferol. Parathyroid hormone promotes the urinary excretion of the phosphate and also stimulates the FGF-23 production by the osteoblasts and osteocytes in bone. FGF-23 act on kidneys and promotes the excretion of phosphorus. This also consists of inhibitor effect 1,25 dihydroxycholecalciferol. So, there is presence of the system of promoters and the inhibitors of renal absorption of phosphorus, that ensure serum levels are maintained in the desired range. Kidneys are main organ which control phosphorus level by altering resorption in such factors.

3. DEGLUTITION

Q.1. Write a short note on deglutition. *(Feb 2016, 3 Marks) (Mar 2007, 3 Marks) (Sep 2006, 5 Marks) (Dec 2010, 5 Marks) (Feb 2014, 3 Marks) (Feb 2019, 5 Marks)*

JAYPEE BROTHERS

Or

Write on phases of deglutition. *(Feb 2013, 5 Marks)*

Or

Answer in brief stages of deglutition. *(Aug 2016, 2 Marks)*

Or

Write short answer on deglutition. *(Dec 2023, 3 Marks) (May 2018, 3 Marks)*

Or

Write short answer on stages of deglutition. *(Nov 2019, 3 Marks)*

Or

Write short note on stages of deglutition. *(June 2022, 2 Marks)*

Or

Write short answer on swallowing. *(May 2022, 3 Marks)*

Or

Write short answer on phases of deglutition. *(Nov 2022, 3 Marks)*

Ans. Deglutition is defined as the act of swallowing.

Mechanism of deglutition or swallowing of food occurs in following phases:

Preparatory Phase

- In this phase formation of bolus occur.
- Bolus is a round or oval shaped mass of food formed in mouth after chewing.

Oral or Buccal Phase

- As bolus takes its position on dorsum of tongue, oral phase begins.
- This phase is voluntary in character.
- Anterior part of tongue is raised and pressed against hard palate by intrinsic muscles of tongue.
- The movement takes place from anterior to posterior side. This pushes food bolus to oropharynx.
- Nasopharynx gets shut due to upward movement of soft palate and forward movement of posterior pharyngeal wall. This prevents regurgitation of food in nose.

Pharyngeal Phase

- This phase is involuntary in character.
- During this the food is pushed from oropharynx to lower part of laryngopharynx, i.e., hypopharynx.
- Constrictors of pharynx move upward and forward and propel bolus through pharynx by contractions.
- Simultaneously upper esophageal sphincter opens and bolus enter esophagus.
- During this phase laryngeal vestibule closes due to movement of epiglottis.
- Epiglottis move to horizontal position due to elevation of hyoid bone and larynx as well as contraction of thyrohyoid muscle.
- Epiglottis directs the bolus in piriform sinuses around opening of airway in esophagus.

Esophageal Phase

As food reaches the upper end of esophagus its sphincter contracts and leads to peristaltic contractions which pass bolus to stomach. Lower esophageal sphincter allows bolus in stomach.

Q.2. Describe in brief pharyngeal phase of deglutition. *(June 2010, 5 Marks) (May 2014, 2 Marks)*

Ans. *Refer to Ans 1 of same chapter.*

Q.3. Enumerate stages of deglutition. *(Sep 2015, 2 Marks)*

Ans. Following are the stages of deglutition:

1. Preparatory phase
2. Oral or buccal phase
3. Pharyngeal phase
4. Esophageal phase.

Q.4. Define deglutition. Enumerate phases of deglutition and write the importance. *(Sep 2018, 1 + 2 + 2 Marks)*

Ans. Deglutition is defined as the act of swallowing.

Phases of Deglutition and their Importance

Name of phase of deglutition	Importance of phase of deglutition
Preparatory phase	In this phase, there is formation of food bolus which is the preparatory event for swallowing
Oral or buccal phase	In this phase, bolus is propelled from oral cavity to pharynx
Pharyngeal phase	In this phase, bolus is transported from oropharynx into esophagus by a peristaltic wave caused by contraction of pharyngeal constrictor muscle
Esophageal phase	In this phase, bolus moves down the length of esophagus to stomach. This is an involuntary phase. Esophagus helps to move food from pharynx to stomach

Q.5. Write short answer on applied physiology of deglutition. *(Nov 2018, 3 Marks)*

Ans. Following is the applied physiology of deglutition:

- **Dysphagia:** It is difficulty in swallowing. It can occur when the oral cavity, pharynx and esophagus are affected by any inflammation, infection or nutritional deficiency.
- **Nasal regurgitation:** It can occur in patients with palatal clefts or paralysis of soft palate where nasal cavity cannot be sealed off from oropharynx.
- Due to inefficiency of the lower esophageal sphincter, there is reflux of the gastric contents into the esophagus. In healthy persons, it is called gastroesophageal reflux. If it is too frequent, it is called gastroesophageal reflux disease.
- It can also cause heart burn by reflux into the respiratory tract causing choking during sleep, mimicking angina pain.
- Persistent gastroesophageal disease may lead to Barrett's esophagitis which can eventually progress to esophageal cancer.
- If the lower esophageal sphincter fails to relax properly, the bolus of the food is held up in the esophagus, a condition known as achalasia.

4. MASTICATION

Q.1. Write a short note on muscles of mastication. *(Dec 2010, 5 Marks) (May 2016, 3 Marks) (Apr 2022, 3 Marks) (July 2017, 3 Marks)*

Or

Enumerate muscles of mastication with nerve supply. *(Feb 2019, 2 Marks)*

Or

Describe muscles of mastication. *(June 2010, 10 Marks)*

Or

Write short answer on muscles of mastication. *(May 2020, 3 Marks)*

Ans. The muscles of mastication are:

1. Temporalis.
2. Masseter.
3. Lateral pterygoid.
4. Medial pterygoid.

JAYPEE BROTHERS

Muscles of mastication					
S. No.	**Muscle**	**Origin**	**Insertion**	**Nerve supply**	**Action**
1.	Masseter	a. Superficial layer: From anterior 2/3 of lower border of zygomatic arch adjoining zygomatic process of maxilla b. Middle layer: From anterior 2/3 of deep surface and posterior 1/3 of lower border of zygomatic arch c. Deep layer: From deep surface of zygomatic arch	a. Superficial layer: Into lower part of lateral surface of ramus of mandible b. Middle layer: Into middle part of ramus c. Deep layer: Into upper part of ramus and coronoid process of mandible	Anterior division of mandibular nerve	a. Elevates mandible to close the mouth to bite b. It clenches the teeth
2.	Temporalis	a. Temporal fossa b. Temporal fascia	a. Margins and deep surface of coronoid process b. Anterior border of protruded mandible	Two deep temporal branches from anterior division of mandibular nerve	a. Elevates mandible b. Posterior fibers retract protruded mandible c. Helps in side to side grinding movement
3.	Lateral pterygoid	a. Upper head: From intratemporal surface and crest of greater wings of sphenoid b. Lower head: From lateral surface of lateral pterygoid plate	a. Pterygoid fovea on the anterior surface of neck of mandible b. Anterior margin of articular disc and capsule of temporomandibular joint	A branch from anterior division of mandibular nerve	a. Depresses mandible to open mouth with suprahyoid muscle b. Lateral and medial pterygoid protrude mandible c. Left lateral pterygoid and right medial pterygoid turn the chin to left side as a part of grinding movement
4.	Medial pterygoid	a. Superficial head: From tuberosity of maxilla and adjoining bone b. Deep head: From medial surface of lateral pterygoid plate and adjoining process of palatine bone	Roughened area of medial surface of angle and adjoining ramus of mandible below and behind mandibular foramen and mylohyoid groove	Nerve to medial pterygoid, branch of the main trunk of mandibular nerve	a. Elevates mandible b. Helps in protruding mandible c. Right medial pterygoid with left lateral pterygoid turn the chin to left side

For more details refer to the table in Ans 1 of chapter TEMPORAL AND INFRATEMPORAL REGION IN ANATOMY SECTION.

Q.2. Define occlusion. Write in detail about muscle of mastication. *(Dec 2012, 8 Marks)*

Ans. Occlusion is defined as the "static and dynamic contact relationship between the occlusal of teeth during function." **Glossary of prosthodontic terminology (GPT).**

For muscles of mastication refer to Ans 1 of same chapter.

Q.3. Enumerate the muscles of mastication. *(Jan 2018, 2 Marks) (Sep 2015, 2 Marks)*

Ans. Following are the muscles of mastication:

- Temporalis.
- Masseter
- Lateral pterygoid.
- Medial pterygoid.

Q.4. Define mastication and deglutition. *(Apr 2017, 2 Marks)*

Ans. Mastication

It is defined as act of chewing food, and it consists of coordinated function of various parts of oral cavity to prepare the food for swallowing and digestion.

Deglutition

Deglutition is the process by which food is passed in stomach from oral cavity or deglutition is defined as the act of swallowing.

Q.5. Write short answer on physiology of mastication. *(Aug 2019, 3 Marks)*

Or

Write short note on physiology of mastication. *(June 2022, 3 Marks)*

Or

Write short essay on physiology of mastication. *(June 2023, 3 Marks)*

Ans. Mastication is the sensory motor activity aimed at the preparation of food for swallowing.

Changes Observed in Masticatory Muscle during Chewing Cycle

- During opening phase and in the beginning of closing phase masticatory muscles undergo isotonic contraction, i.e., they shorten to produce jaw movements against a constant load and then undergo relaxation.
- In the latter part of closing phase and occlusal phase, tension occur in the elevation muscles which undergoes isometric contraction (produce contractile tension with no change in length); when the teeth are in contact or when there is a hard object in between the teeth.
- During opening phase the lateral pterygoid muscle is active and also the suprahyoid muscles (digastric, geniohyoid and mylohyoid).
- During initial closing phase the depressor muscles are first activated, then relax to allow the mouth to be closed by the passive tension in the elevator muscles.
- In the closing phase, first the temporalis on the working side become active followed by masseter and temporalis muscle of the non-working side. Masseter and medial pterygoid are active during incisive movement and lateral pterygoid during protrusive movement.

Jaw Movement during Masticatory Cycle

- Both condylar head and mandibular body move during masticatory cycle.

JAYPEE BROTHERS

- Mandibular and condylar movements associated with mastication are coordinated result of sequenced mandibular muscle contractions.
- When the movement of mandible is traced during masticatory stroke 'a tear drop' shaped tracing is observed.
- In the opening phase mandible drops downward from the intercuspal position to a point where the incisal edge of the teeth are about 16–18 mm apart.
- Mandible then moves 5–6 mm laterally from the midline as the closing movement begins.
- First phase of closure traps the food between the teeth and is known as crushing phase. As the teeth approach each other the lateral displacement gets lessened and the jaw occupies a position only 2–4 mm lateral to the starting position of the chewing stroke.
- As the mandible closes, the bolus of food gets trapped between the teeth and grinding phase starts. At the time of grinding the mandible is guided by occlusal surface of teeth which has come back to the intercuspal position.
- During early stages of mastication where food has to be incised, the mandible moves forward to a greater distance. In later stages, the crushing of food is concentrated and very little anterior movement occurs. Similarly, the lateral movements are also greater when the food is initially introduced into the mouth and then becomes lesser as the food is broken down. The lateral movement also varies according to the consistency of food. The harder the food the more the lateral closure stroke becomes.
- Condylar heads rotate and translate to allow the jaw to open and close during masticatory movements. During opening phase the condyle on the working side move laterally whereas the opposing condyle on the balancing side moves medially downward and forward. These condylar movements make the mandible shift to the working side.
- In early closing phase, condyle of the working side resumes its position within the articular fossa whereas balancing side condyle returns only in late period of closing phase. The mandible swings back to intercuspal position.

Control of Mastication

- Movements include in the mastication need the integrated activity of various muscles which are controlled by trigeminal, hypoglossal, facial and possibly other motor nuclei in brainstem.
- Coordination of activity in these motor nuclei relies on the sensory input from oral cavity which terminates primarily in trigeminal nucleus and solitary tract nucleus. Other brainstem structures, i.e., reticular formation are also involved.
- Motor and sensory nuclei contained in the brainstem play a pivotal role in the control of mastication.
- The basic oscillatory pattern of masticatory movements originates in a neural pattern generator located in the brainstem. Finally, higher brain centers influence the brainstem masticatory coordinating system.
- Interconnected neural circuits form a neural oscillatory network that is capable of generating the pattern of masticatory movements. This neural oscillator is called pattern generator or masticatory center.
- A number of reflexes can be elicited from the orofacial area. These include tongue, facial and various jaw reflexes. Because reflex activity of muscles in other body areas has proved useful in understanding neural connections.
- Mastication process is controlled by central pattern generator and masticatory muscles exhibit specific reflex patterns.
- Three types of muscle reflexes of masticatory apparatus are:
  1. **Jaw-closing reflex:** Reflex activity of jaw moving the teeth into occlusion is known as jaw closing reflex. This is an example of stretch reflex. The jaw-closing reflex can be produced by giving a sharp downward tap on the chin when the mandible is out of occlusion in the rest position. The reflex activity of the masseter brings the teeth into occlusion. This is a monosynaptic reflex occurring because of the stretching or loading of muscle spindles in the masseter muscle. The reflex lasts for 7–12 milliseconds, after which there is a silent period in the electromyogram which represents spindle unloading.
     Depressor muscles relax during jaw-jerk reflex, and their activity is not noticed because of presence of few muscle spindles.
  2. **Jaw-opening reflex:** This is initiated by mechanical stimulation of periodontal ligament and mucosal mechanoreceptors. Result is excitation of jaw opening muscles and inhibition of jaw closing muscles. This reflex is initiated by stimulation of numerous other areas innervated by trigeminal and other cranial nerves so there may be number of reflex pathways involved in this reflex.
  3. **Unloading reflex:** It protects teeth during heavy occlusal load. This reflex stops mandibular closure by decreasing masseter and digastric muscle activity. Sudden reduction is the result of inactivation of muscle spindles.

5. SPEECH

Q.1. Write short answer on speech. *(Aug 2018, 3 Marks)*

Ans. Speech is described as an overlaid process which is secondary to vegetative functions.

Speech process consists of four mutually dependent divisions:

1. Respiration
2. Phonation
3. Resonation
4. Articulation

These above mentioned process coordinate to produce dynamic acoustic modulation of speech.

Respiration

- It is also known as power division.
- First step during speech-producing phenomenon is respiration where the energy source for speaking is given by the respiratory system.
- Exhaled airstream moves via resonating cavities and get shaped into discrete sounds.

Phonation

- Second step in speech phenomenon is phonation.
- Breath stream which is emitted from the lungs strikes to the vocal folds which are housed inside the larynx.
- Phonation occurs due to vibratory activity of vocal folds.
- Exhaled airstream get interrupted by vibratory pattern of vocal folds, and air puffs emerging from this process create sound. This sound is called as source excitation.
- It serves as an acoustic material from which speech sounds are later developed.

Resonation

- Resonation is usually the third step in speech process.

JAYPEE BROTHERS

- Resonance provides a distinguishing quality which is the characteristic of each voice.
- Sounds get modified by selective alteration of both size and shape of vocal tract.
- Depending on the configuration of vocal tract, certain frequencies are amplified whereas others are attenuated.

Articulation

- Articulation is the fourth step in speech producing phenomenon.
- Articulators and articulatory valves are solely responsible for this act.
- Vocal organs are the articulators and the articulatory valves are the places at which airstream is modified to produce speech sounds.
- When vocal organs assume a certain position they produce sound, simultaneously articulatory valves stop, constrict and narrow the airstream, thus producing speech sounds.
- So, articulation thus refers to placement and movement of lips, teeth, tongue, mandible and the soft palate as well as associated structures at the time of speech to produce speech sound.

6. THEORIES OF MINERALIZATION

Q.1. Write short answer on matrix vesicle theory of mineralization. *(Nov 2021, 3 Marks)*

Or

Write short answer on matrix vesicle. *(June 2023, 2 Marks)*

Ans. Matrix vesicle theory states that the amorphous calcium phosphate should be formed inside secretory or matrix vesicle of hard tissue matrix which is secreting the cells such as osteoblast. Alkaline phosphate which is present inside such cells increase the content of phosphate ion inside the cell and mitochondria leads to the release of the calcium from its stores which cause the formation of an amorphous calcium phosphate in secretory (matrix) vesicle. These are now released in the nucleating sites inside the collagen fiber. So, this theory incorporate both booster as well as seeding mechanisms.

Matrix vesicles are generally the membrane bound vesicles which are isolated from areas of calcification. These structures bud off from the synthetic cells and they are released into the organic matrix. It has been observed that the matrix vesicles induces the precipitation of hydroxyapatite crystals in vitro from solutions which consists of both calcium and phosphate ions and also are capable of crystal formation even when the solubility of product of calcium and phosphate are as low as 2 mm^2. The above factors suggest that the matrix vesicles have a capacity to initiate mineralization.

Two Types of Matrix Vesicles have been Identified

- Type I matrix vesicle are round or ovoid in shape which resemble to lysosomes. They contain enzymes such as acid phosphatase and aryl phosphatase. These enzymes can break down proteoglycans and glycosaminoglycans which are inhibitors of mineralization.
- Type II matrix vesicles are irregular membrane bound structures having enzymes such as ATPase, alkaline phosphatase, pyrophosphatase, proteoglycans and metalloproteinases but relatively less acid phosphatase. These vesicles are also rich in phospholipids with great affinity for calcium and a large amount of annexin V.

Role of Matrix Vesicle in Mineralization

- Matrix vesicles provide a local environment for initial crystal formation.
- They have all the characteristics needed for the induction of calcification.
- Freshly isolated vesicles contain relatively high Ca^{2+} content bound to phospholipids which act as a nucleating site within the vesicle.
- By being extremely rich in alkaline phosphatase activity, the vesicles have the capacity to hydrolyze a variety of organic phosphate substrates, to increase substantially the local availability of free phosphate ions which binds to calcium ions to initiate apatite crystallization.
- Such enzymatic activity may also eliminate the putative inhibitors of mineralization, including pyrophosphate.
- In addition the vesicles also contain a large amount of annexin V, a membrane-associated protein which mediates the influx of Ca^{2+} into matrix vesicles, enabling intraluminal crystal growth. In addition, annexin V binds directly to type II and X collagen which may be important for anchoring the vesicle to fibrous components of the matrix. Thus the first crystal is formed in the matrix vesicle.
- Crystal growth continues in the vesicle by further addition of ions which is followed by rupture of vesicle membrane. The crystals are released into the organic matrix, where they grow by using ions in the tissue fluid and mineralization spreads to surrounding matrix.
- The mineralization progresses in the form of spherical or calcospheric masses which fuses with each other forming uniformly mineralized matrix.
- In summary, matrix vesicles help in extrafibrillar calcification.

Many of the inhibitors of mineralization are present to regulate the process. One such inhibitor is known as the pyrophosphate. The pyrophosphatases remove inhibitors pyrophosphate from the nucleating sites which lead to the facilitation of mineralization. Growth of the crystals, its size and shape should be regulated by inhibitors of the mineralization, which becomes attached to crystals to prevent their growth or to alter their shape.

JAYPEE BROTHERS

JAYPEE BROTHERS

or detailed information on dental books, visit our website www.ejaypee.com, for detailed information on dental books, visit our website www.ejaypee.com, for detailed information o

Mastering the BDS Ist Year (Last 20 Years Solved Questions)

Salient Features

- Written in simple and lucid language.
- Provides broad coverage of all the subjects in BDS Ist year.
- Includes vast topics in simple flowcharts, tables, and diagrammatic forms so as to make the content easy to understand and recall.
- Supports in quick revision during examinations.
- One weapon, three targets, i.e., BDS examination, PG and PSC entrance, and MDS examination (Basic Sciences): It is the only book written that can be used to clear university graduation exams and postgraduate entrance exams and crack basic sciences exam for postgraduate students.

The earlier editions have been immensely popular among the dental students, postgraduate aspirants, and dental practitioners. Other highlights of 12th edition are:

- Exam-oriented book with unique collection of solved question papers of the last 20 years.
- Extensively revised and updated chapters to provide knowledge of the present era.
- All the sections are thoroughly revised. Various answers of previous editions have been changed in this present edition because of changes in various concepts and inculcation of new researches.
- In this section anatomy, physiology, and biochemistry are rewritten with the changed answers.
- Consists of solved multiple choice questions (MCQs) and fill in the blanks, which are added by the Dental Council of India (DCI) in the latest curriculum.
- Since image-based questions are asked in NEET PG, PGI, and AIIMS examinations, an idea regarding these have been introduced to the BDS student, which will further help them to study for the above-mentioned competitive examinations.
- Additional information at the end of every section is introduced to quickly memorize and revise the topic in short. This will also help in solving MCQs very fast in university as well as in competitive examinations.
- Includes Viva-Voce questions with answers which aid students to enhance their skills in practical examinations.
- One liners are added for quick revision of dental postgraduate entrance examinations such as NEET, PGI, AIIMS, PSCs, etc.
- Contains illustrations and high-quality photographs with explanatory legends for easy explanation of text.
- Provides recent and internationally accepted classification systems by eminent professional bodies such as WHO.
- Includes solved papers of years 2024 and 2025, with better and improved answers.
- Explains questions in a point-wise manner for clear overview and eye-catching remembrance.
- Illustrates hematoxylin and eosin (H&E) stained histological photographs in color plates which help students to understand the general histology and dental histology section.
- The text, MCQs, and fill in the blanks aid students in preparation of Viva-Voce and provide basics for competitive examination.
- Incorporates a clinical overview in various chapters for highlighting the clinical applications.
- A highly structured, user-friendly, systemic, and attractive layout with enriched illustrations.

Most of the features of previous editions are retained:

- Content is more but with less pages—Gives a handy look which saves the time of the student.
- Concise, bullet format, and to-the-point text which is easy to read during BDS and MDS basic sciences examination.
- Language is simple and lucid which makes the understanding easy.
- MCQs, IBQs, fill in the blanks, viva-voce questions, additional matter and one liners are present at the end of each subject.

Hemant Gupta MDS (Oral and Maxillofacial Pathology, Microbiology and Forensic Odontology) has over two decades of experience of authorship. He is CEO of Shivom Multispecialty Dental Clinic, Indore, Madhya Pradesh, India. He is a general practitioner and also a consultant as oral cancer diagnostician at various clinics and hospitals. He has also specialized in pathology techniques such as immunohistochemistry. He has published research papers in various indexed journals of national and international repute. He has an experience of coaching dental students at a personal level, which helps them to build up the basics in dentistry and also to clear the various university examinations. His pioneer work in Forensic Odontology is on Ameloglyphics.

Dr Gupta has also authored several other popular books which are extremely appreciated among the BDS and MBBS students:

1. Mastering the BDS IInd Year
2. Mastering the BDS IIIrd Year
3. Mastering the BDS Final Year–Part I
4. Mastering the BDS Final Year–Part II
5. Mastering the MBBS Ist Year

Printed in India

Available at all medical bookstores or buy online at www.ejaypee.com

JAYPEE BROTHERS
Medical Publishers (P) Ltd.
EMCA House, 23/23-B, Ansari Road,
Daryaganj, New Delhi - 110 002, INDIA
www.jaypeebrothers.com

Join us on facebook.com/JaypeeMedicalPublishers
Follow us on instagram.com/JaypeeMedicalPublishers

Shelving Recommendation
DENTISTRY

ISBN 978-93-6616-802-9