ailed information on nursing books, visit our website www.ejaypee.com, for detailed information on nursing books, visit our website www.ejaypee.com,



MIDWIFERY CASEBOOK

A Practical Record of Maternal and Newborn Nursing for GNM Students

With Important Notes on Care of Mother and Newborn

Annamma Jacob

Name of the Institution: _____

_____

Name of the Candidate: _____

Edited by
Jadhav Sonali Tarachand

6th Edition

JAYPEE

CONTENTS

1. Notes on Midwifery 1

2. Nursing Diagnoses (Selected Few) 39

3. Clinical Nursing Procedures (Selected Few) 67

4. Midwifery Record 89

- Antenatal Examinations Performed 90
- Normal Deliveries Witnessed 92
- Normal Deliveries Conducted 94
- Vaginal Examinations Performed in Labor 96
- Episiotomies and Suturing Performed/Assisted 98
- Abnormal Deliveries Witnessed (Forceps/Ventouse) 100
- IUCD Insertions Assisted/Carried Out 102
- Cesarean Sections Witnessed 104

5. Care Studies

- Prenatal Mothers Nursed (Normal and High Risk) (10) 114
- Intranatal Mothers Nursed (20) 174
- Postnatal Mothers and Newborns Nursed including Cesarean Mothers (15) 274
- High Risk Neonates Nursed (5) 409
- Insertion of IUCD (Cu-T)–1 (5) 444

Notes on Midwifery

JAYPEE BROTHERS

STRUCTURE OF FEMALE PELVIS (FIGURE 1)

The pelvis is a skeletal ring often referred to as pelvic girdle formed by two innominate bones, the sacrum and the coccyx.

Innominate Bones

Each innominate bone is made up of three bones—(1) ilium, (2) ischium, and (3) pubis.

Sacrum

The sacrum is a wedge-shaped bone consisting of five fused vertebrae and lies between the two ilia. The prominent upper margin of the first sacral vertebra is called the sacral promontory. The anterior surface of the sacrum is concave from above downward and from side to side and is referred to as the hollow of sacrum. There are four pairs of foramina through which the sacral nerves pass.

Coccyx

The coccyx is a small triangular bone which articulates with the lower end of the sacrum.

Pelvic Joints

- **Sacroiliac joints:** These are two slightly movable joints formed where the ilium joins with the first two sacral vertebrae on either side.
- **Symphysis pubis:** It is a cartilaginous joint between the two pubic bones.
- **Sacrococcygeal joint:** It is a hinge joint between the sacrum and the coccyx.

Pelvic Ligaments

The pelvic girdle requires great strength and stability in order to fulfill its function of support. The pelvic joints are reinforced by powerful ligaments.

- **Sacroiliac ligaments:** These ligaments pass in front of and behind each sacroiliac joint.
- **Pubic ligaments:** The superior pubic ligament connects the top portion of the pubic bones. The arcuate pubic ligament runs under the symphysis pubis and connects the lower portion.
- **Sacrotuberous ligaments:** One ligament on each side runs from sacrum to the ischial tuberosity.
- **Sacrospinous ligaments:** One ligament on each side runs between the sacrum and ischial spine.
- **Sacrococcygeal ligaments:** One ligament on each side from the sacrum to the coccyx.

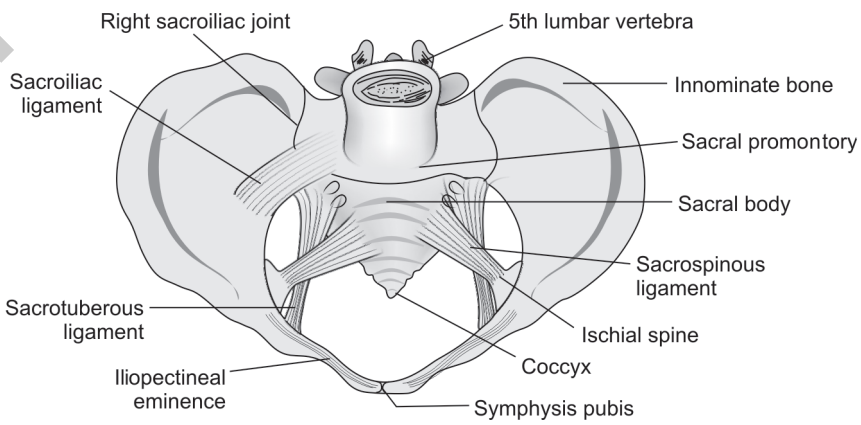

Figure 1: Normal female pelvis

Division of the Pelvis

1. **False pelvis:** Lies above an imaginary line called linea terminalis at the level of brim. Function of the false pelvis is to support the enlarged uterus.

JAYPEE BROTHERS

2. **True pelvis:** Lies below the linea terminalis or pelvic brim. It is the bony canal through which the fetus must pass. It is divided into three planes **(Figure 2)**.

   a. Brim or inlet

   It is the upper boundary of true pelvis. The brim is bounded by upper margin of symphysis pubis in front, linea terminalis on sides and sacral promontory in the back. Largest diameter of the inlet is transverse and smallest diameter is anteroposterior.

   i. *Anteroposterior diameter* of the inlet is measured clinically by *diagonal conjugate*, the distance from the lower margin of symphysis pubis to the sacral promontory and usually measures 13.5 cm.
   Obstetric or true conjugate is the distance between the inner surface of symphysis and sacral promontory. The measurement is obtained by subtracting 1.5–2.0 cm (thickness of symphysis pubis) from diagonal conjugate. Adequate diameter is usually 11.5 cm.

   ii. *Oblique diameters:* Right and left oblique diameters are measured from the sacroiliac joint on the one side to the iliopectineal eminence on the opposite side. It is named in relation to the mother's anatomical position. Right oblique is from right sacroiliac joint and measures 12 cm.

   iii. *Transverse diameter:* It is the maximum distance between two farthest points of pelvic brim. This diameter is nearest the sacrum than the pubis. It measures 13 cm.

   b. Cavity

   Cavity is circular in shape and is the space between the plane of brim and that of outlet. It is a curved canal with shallow anterior and deep posterior wall. Anterior wall measures 4 cm and posterior wall 12 cm and curved. Diameters of the inlet cannot be measured clinically. Clinical evaluation of adequacy is made by noting the ischial spines. All the diameters are considered to be 12 cm.

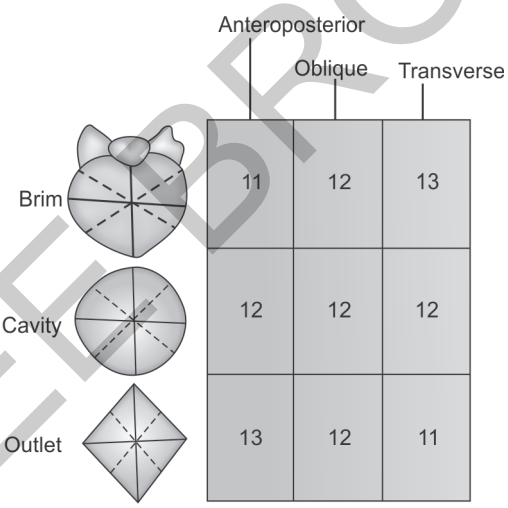

Figure 2: Measurements of the pelvic canal in centimeters

   c. Outlet

   Outlet is diamond shaped, bounded by lower margin of symphysis pubis in front, ischial tuberosities on sides and tip of sacrum posteriorly.

   i. *Anteroposterior diameter* extends from the apex of the pubic arch to the tip of the coccyx. This diameter increases by half an inch during labor by the coccyx being displaced backwards as the head descends, and measures 13 cm.

   ii. *Transverse diameters*: There are two transverse diameters *bi-spinous* 10 cm, at the upper boundary of outlet and *intertuberischial* 11 cm at the lower border of outlet, distance between the inner borders of ischial tuberosities.

Shapes of the Pelvis (Figure 3)

There are four types of pelvic shapes-based essentially on the shape of the brim.

1. Gynecoid (normal female pelvis)
   Has optimal diameters in all three planes. Seen in 50% of women.

JAYPEE BROTHERS

2. Android (normal male pelvis)
   Posterior segments are decreased in all three planes. Deep transverse arrest and failure of rotation of the fetus are common. Seen in 20% of all women.
3. Anthropoid (apelike pelvis)
   Anteroposterior diameter is longer, may allow for easy delivery of an occiput posterior presentation of fetus. Seen in 25% of all women.
4. Platypelloid (flat female pelvis with wide transverse diameter)
   Arrest of fetal descend at the pelvic inlet is common. This type of pelvis is seen in 5% of all women.

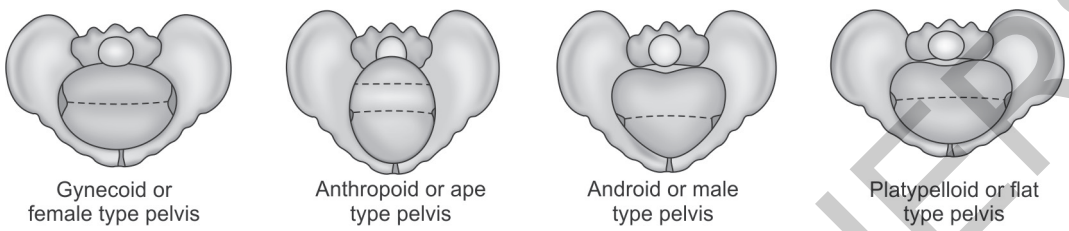

Figure 3: The four types of pelvis

Features of the Four Types of Pelvis

Plane of pelvis	Features	Gynecoid	Android	Anthropoid	Platypelloid
		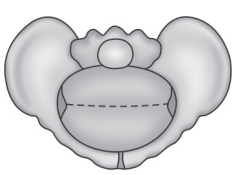	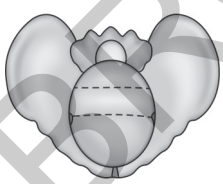	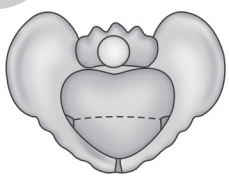	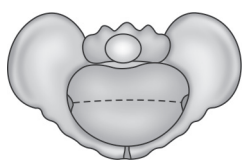
Brim	Forepelvis Brim	Wide Rounded	Narrow Heart-shaped	Narrow Oval anteroposteriorly	Wide Oval transversely (kidney-shaped)
Cavity	Side walls Sacrum	Straight Well-curved	Convergent Straight	Straight Deep concave	Divergent Flat
Outlet	Ischial spines Subpubic arch	Blunt Wide, 90 degrees	Prominent Narrow, <90 degrees	Blunt Wide >90 degrees	Blunt Wide >90 degrees
Bone structure		Medium	Heavy	Medium	Medium
Incidence		50%	20%	25%	5%

FETAL SKULL (REFER FIGURE 5)

The fetal skull is ovoid in shape. At term, it is larger in proportion to the other parts of the skeleton. The skull may be divided into three parts: vault, base and face.

1. The vault which contains the brain is composed of 5 bones: 2 frontal, 2 parietal and 1 occipital. These are united by membranes known as sutures and fontanelles. The sutures and fontanelles may be felt on vaginal examination during labor and indicate the position of the occiput and degree of flexion of the head.
2. The base of the skull is composed of 5 bones: 2 temporal, 1 ethmoid, 1 sphenoid and part of the occipital bone. These are firmly fused together. At the base of the skull is an opening known as *the foramen magnum*, through which passes the spinal cord.
3. The face is composed of 14 bones, all fused together.

JAYPEE BROTHERS

Sutures (Figure 4)

There are four sutures of obstetrical importance. They are composed of soft, fibrous tissue and allow mobility between the cranial bones. Sutures are very useful landmarks while making a vaginal examination.

1. *Sagittal suture:* Between two parietal bones
2. *Frontal suture:* Between two frontal bones
3. *Coronal suture:* Between the frontal bone on one side and the parietal bones on the other side.
4. *Lambdoidal suture:* Between the parietal and occipital bones.

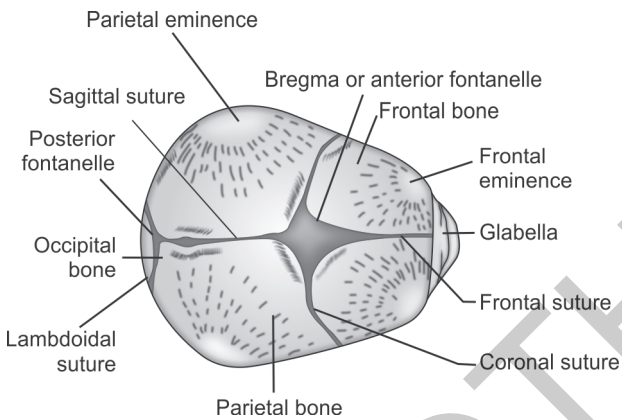

Figure 4: Fetal skull at term showing fontanelles and sutures

Fontanelles

Membranous spaces between the cranial bones of the fetus or newborn baby. There are six fontanelles on the skull, but only two are of obstetrical importance, the anterior and the posterior.

1. *Anterior fontanelle:* The largest fontanelle. It is the junction of the sagittal, frontal and coronal sutures. It is diamond shaped, 2.5 cm long and 1.5 cm wide. Pulsations of the cerebral vessels can be felt through it. The fontanelle closes by 18 months of age.
2. *Posterior fontanelle:* This is located where the sagittal suture meets the lambdoidal suture. It is triangle shaped and smaller than anterior fontanelle. This fontanelle can be recognized as the junction of three sutures in vaginal examination during labor. It closes by six weeks of age.

Regions of Fetal Skull (Figure 5)

1. *Vertex:* It is a quadrilateral area bounded by the anterior fontanelle and the coronal suture in front, the posterior fontanelle and the lambdoidal suture behind, and longitudinal lines through the parietal eminences laterally.
2. *Brow or sinciput:* It is the area bounded by the supraorbital ridges in front, the anterior fontanelle and the coronal sutures behind and longitudinal lines passing through the frontal eminences laterally.

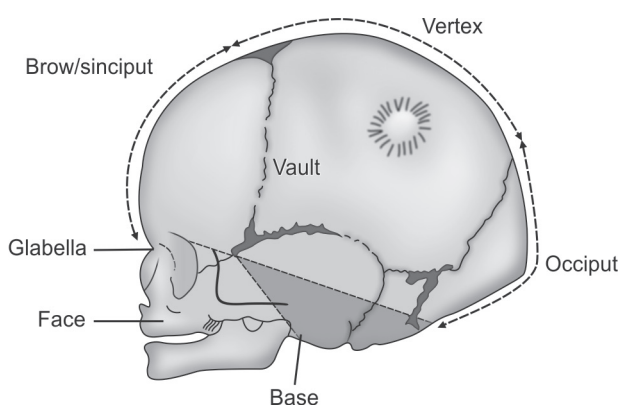

Figure 5: Regions of the fetal skull showing vault, face and base

JAYPEE BROTHERS

3. *Face:* It is the area bounded by the orbital ridges and the root of the nose to the junction of the chin and neck.
4. *Occiput:* This is the region that lies between the foramen magnum and the posterior fontanelle. The part below the occipital protuberance is known as the suboccipital region.

Diameters of the Fetal Skull (Figure 6)

The engaging diameter of the fetal skull depends on the degree of flexion present.

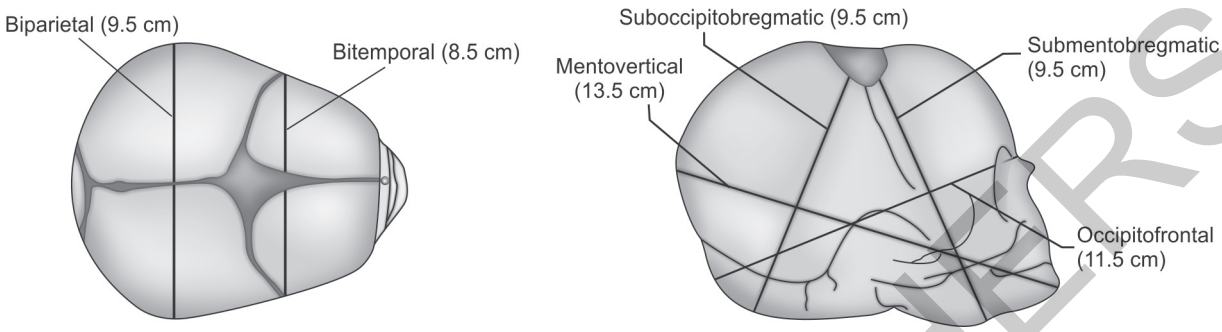

Figure 6: Diameters of the fetal skull

Diameters of the fetal skull

S. No.	Diameter	Measurement	Presentation
1.	Suboccipitobregmatic Measured from below the occipital protuberance to the center of the anterior fontanelle or bregma	9. 5 cm	Vertex well flexed
2.	Suboccipitofrontal Measured from below the suboccipital protuberance to the center of the frontal suture	10 cm	Vertex deflexed
3.	Occipitofrontal Measured from the occipital protuberance to the root of the nose (glabella)	11.5 cm	Vertex extremely deflexed in occipitoposterior position
4.	Submentobregmatic Measured from the point where the chin joins the neck to the center of the bregma	9.5 cm	Face completely extended
5.	Submentovertical Measured from the point where the chin joins the neck to the highest point on the vertex	11.5 cm	Face incompletely extended
6.	Mentovertical Measured from midpoint of the chin to the highest point on the vertex, slightly nearer to the posterior than to the anterior fontanelle	13.5 cm	Brow midway between flexion and extention
7.	Biparietal Transverse diameter, measured between the two parietal eminences	9.5 cm	
8.	Bitemporal Transverse diameter, measured between the furthest points of the coronal suture at the temples	8.2 cm	

Relationship of the Fetus to the Uterus and Pelvis

Relationship of the fetus to the uterus and pelvis are expressed using certain terms. These determine which part of the fetus enters the pelvic brim first and governs the mechanism of labor.

1. Lie—The lie of the fetus is the relationship between the long axis of the fetus to the long axis of the uterus. Lie may be longitudinal, transverse or oblique.
2. Attitude—Attitude is the relationship of the fetal head and limbs to its trunk and should be one of flexion. The fetus is curled up with chin on chest and arms and legs flexed, forming a compact mass. If the head is well flexed, the smallest diameters will be presenting.

JAYPEE BROTHERS

3. Presentation—Presentation refers to the part of the fetus that lies at the pelvic brim or in the lower pole of the uterus. Presentations can be *vertex, breech, shoulder, face* or *brow*. Vertex, face and brow are *cephalic* or *head presentations*.
   Breech is *podalic presentation* and depending on the degree of flexion, complete breech, footling, knee or extended breech may present.
   In transverse presentation, the fetus lies across the pelvis and there may be shoulder, arm or any part of the trunk presenting.
4. Denominator
   Denominator is the part of presentation that indicates or determines the position. Each presentation has different denominator and these are as follows:
   - In vertex presentation, the occiput is the denominator
   - In breech presentation, the sacrum is the denominator
   - In face presentation, the mentum is the denominator
   - In shoulder presentation, the acromion process is the denominator
   - In brow presentation, no denominator is used.
5. Position
   Position is the relationship between the denominator of the presentation and six areas of the pelvic brim:
   i. Right anterior ii. Left anterior
   iii. Right posterior iv. Left posterior
   v. Right lateral vi. Left lateral.
   In addition, when the denominator is found in the midline either anteriorly or posteriorly, it is described as direct anterior or direct posterior.

Engagement of the Fetal Head

Engagement of the fetal head is said to have occurred when the widest presenting transverse diameter has passed through the brim of the pelvis.

A head is not engaged when its greatest diameter is still above the plane of inlet. If freely movable, it is called a floating head. A head is said to be deeply engaged when the largest diameter has passed into the cavity. A head is at the outlet when the largest diameter is lying at the bony outlet and the perineum is beginning to bulge.

Presenting Part

The presenting part of the fetus is the part that lies over the cervical os during labor and on which the caput succedaneum forms and thus first to be felt per vagina during internal examination.

PREGNANCY

Pregnancy is the state of a female after conception and until the termination of gestation. Conception is the act of conceiving—the implantation of a blastocyst in the endometrium. The human conceptus from fertilization through eight weeks of pregnancy is termed as an *embryo*, from 9th week till delivery, it is called a *fetus*.

The duration of pregnancy is approximately 280 days or 40 weeks. Gestational age is expressed in completed weeks. Fertilization takes place at the time of ovulation, approximately 14 days after the first day of last menstrual period (in a 28 day cycle) and the period of gestation is thus 266 days or 38 weeks.

Gravidity is the total number of pregnancies regardless of their duration. *Parity* is the number of viable newborns live or dead that a woman has delivered regardless of the number of children involved. (e.g. the birth of twins or triplets increases the parity only by one).

Calculation of the Expected Date of Delivery (EDD) and Duration of Pregnancy

The expected date of delivery is calculated from the first day of the last menstrual period (LMP) by counting 9 calendar months and adding 7 days to it. The number of days counted from the first day of the last menstrual period to the date of examination will give the duration of pregnancy at that particular date.

JAYPEE BROTHERS

Estimation of Gestational Period from the Height of the Fundus of Uterus

The fundus assumes different heights in the abdomen at different periods of gestation **(Figure 7)**.

12	Level of the symphysis pubis
16	Half-way between symphysis pubis and umbilicus
20	1–2 fingerbreadths below the umbilicus
22–24	1–2 fingerbreadths above the umbilicus
28–30	1/3 of the way between umbilicus and xiphoid process. (3 fingerbreadths above the umbilicus)
32	2/3 of the way between umbilicus and xiphoid process. (3–4 fingerbreadths below the xiphoid process)
38	Level of the xiphoid process
40	2–3 fingerbreadths below the xiphoid process if lightening occurs.

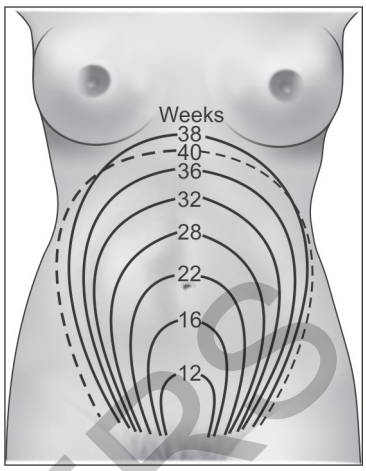

Figure 7: The level of fundus of uterus at different weeks

Diagnosis of Pregnancy

Pregnancy may be diagnosed by the woman herself even before she has missed a period because she feels different. Changes in breasts can occur as early as 5 to 6 weeks after conception. Several fast and easy pregnancy test kits are presently available in drug stores, which work by detecting the presence of human chorionic gonadotropin (hCG) in the woman's urine. Few drops of urine placed on a test strip will give the result in 1–2 minutes.

Diagnosis of pregnancy in the first trimester and early second trimester is based on a combination of presumptive and probable signs of pregnancy. Pregnancy is self-evident later in gestation when the positive signs are readily observed.

Presumptive Signs of Pregnancy

These are the maternal physiological changes which the woman experiences.

- Amenorrhea at 4th week (cessation of menstruation)
- Nausea and vomiting (morning sickness) from 4th to 14th week
- Tingling, tenseness and enlargement of breasts from 3rd to 4th week
- Frequency of micturition—6th to 12th weeks
- Fatigue
- Breast changes—Darkening of nipples, primary and secondary areolar changes and appearance of Montgomery's tubercles.
- Presence of colostrum in the nipples
- Excessive salivation
- Quickening—The first movement of fetus felt by the mother around 18th to 20th week
- Skin pigmentation and conditions such as chloasma, breast and abdominal striae, linea nigra and palmar erythema.

Probable Signs

Probable signs of pregnancy are maternal physiological changes other than presumptive signs which are detected upon examination and documented by the examiner.

- Enlargement of the uterus.
- Presence of human chorionic gonadotropin (hCG) in blood from 4th to 12th week and in urine from 6th to 12th week.
- Vaginal discharge—Copious non-irritating mucoid discharge which appears at 6th week.

JAYPEE BROTHERS

- Hegar's sign—Softening and compressibility of the isthmus from 6th to 10th week.
- Jacquemiers sign/Chadwick's sign—Violet-Blue discoloration of the vaginal membrane due to increased vascularity by about 8th week.
- Osiander's sign—Increased pulsation felt in the lateral fornices from 8th week onwards.
- Palmer's sign—Regular and rhythmic uterine contractions resembling systole and diastole of heart that can be elicited during bimanual examination as early as 8 weeks.
- Goodell's sign—Softening of the cervix from a nonpregnant state of firmness similar to the tip of a nose to the softness of lips of mouth in the pregnant state by sixth week
- Globular enlargement of uterus with a soft feel.
- Palpation of Braxton Hicks contractions.
- Ballottement of fetus from 16th to 28th week.

Positive Signs

Positive signs are those directly attributable to the fetus as detected and documented by the examiner.

- Visualization of fetus by ultrasound from 6th week onwards
- Visualization of fetal skeleton by 16th week
- Fetal heart sounds by ultrasound from 6th week onwards
- Palpable fetal movements from 22nd week onwards
- Visible fetal movements late in pregnancy
- Palpation of fetal parts from 24th week onwards.

Pregnancy Tests

1. **Immunologic test**
   This test is based on the production of chorionic gonadotropin (hCG) by the syncytiotrophoblastic cells during early pregnancy. hCG is secreted into the maternal bloodstream and then excreted in mother's urine.

   Specific antisera are mixed with urine from the woman suspected of being pregnant. If the urine contains hCG, it will neutralize the antibodies in the antiserum and inhibit agglutination indicating a positive pregnancy test.

   If the urine does not contain hCG, agglutination will occur—a negative pregnancy test.

   Pregnancy test kits for home use.

   Several self-use pregnancy test kits are now available. These FDA (Food and Drug Administration) approved products are easy to use (urine drops placed on test strip) and give quick results. The result seen on the test strip indicates if the test is positive or negative for pregnancy or needs to be repeated. Some of the pregnancy test strips presently available in drug stores are: *'i can*' one-step pregnancy test kit, '*First response*' pregnancy test kit, '*velocit eazy*' pregnancy detection kit and '*Pregakem*' pregnancy test kit.
2. **Radioimmunoassay test**
   Blood is tested to detect the hCG beta subunit. These are extremely sensitive tests, able to detect hCG at far lower levels than other tests. The test known as *beta pregnancy* can be used as early as one week after conception, if laboratory facilities are available.
3. **Biological tests of pregnancy**
   Biological tests were done in the past using mice and frogs. The tests included Aschheim Zondek test, Friedman test, Frank test and Hogben test.

ANTENATAL CARE

Antenatal care refers to the care given to an expectant mother from the time the conception is confirmed until the beginning of labor.

JAYPEE BROTHERS

Objectives

The objectives of prenatal care are to:

- Promote, protect and maintain the health of the mother during pregnancy.
- Detect high-risk pregnancies and give special attention
- Foresee complications and take preventive measures
- Remove anxiety and fear associated with pregnancy
- Reduce maternal and infant morbidity and mortality
- Teach the mother elements of nutrition, personal hygiene and newborn care.
- Sensitize the mother to the need of family planning

The importance of regular visits to the prenatal clinic must be emphasized to help the mother have an optimum outcome of pregnancy that is "healthy mother and healthy baby".

Frequency of Visits to the Antenatal Clinic

Ideally the mother should visit the antenatal clinic once a month during the first seven months (28 weeks) twice a month during the eight month (up to 32 weeks) and thereafter once a week if everything is normal.

Antenatal Examination

The first visit irrespective of when it occurs should include the client's health history, obstetric history, physical and pelvic examinations and laboratory examinations.

1. **Health history**
   - Personal history: Patient name, age, religion and occupation
     Spouse: Name, age, occupation, family income and address.
   - Medical history: Medical conditions that require special care
     - Urinary tract infection
     - Essential hypertension
     - Asthma, epilepsy
     - Diabetes
     - Cardiac condition.
   - Family history: History of conditions that are genetic in origin, familial or racial
     - Diabetes in first degree relative
     - Hypertension
     - Multiple pregnancies
     - Sickle cell anemia, thalassemia
     - Congenital anomalies.
   - Menstrual history
     - Age at menarche
     - Frequency, duration and amount of menstrual flow
     - Dysfunctional uterine bleeding.
2. **Obstetric history**
   - Prenatal health
   - Past pregnancy
     - Labor and delivery: Mode of delivery, duration of labor, postpartum hemorrhage (PPH)
     - Puerperium: Sepsis, mastitis, hypertension
     - Babies: Condition at birth, sex, weight
     - Lactation: Breastfeeding, any complication.
   - Present pregnancy
     - Duration of amenorrhea
     - Eating and sleeping habits

JAYPEE BROTHERS

- » Bowel and bladder pattern
- » Minor disorders.

3. Physical examination

A complete screening physical examination is done during the initial antepartal examination in order to ascertain if the woman has any medical disease or abnormalities.

The components of physical examination are:

- Physical measurements—temperature, pulse, respirations and blood pressure.
- General observations—appearance, emotional state, posture and apparent state of health
- Review of systems.

4. Assessments and laboratory tests

- Height and weight
- Urinalysis
- Blood tests—ABO blood group and Rh factor, hemoglobin and hematocrit, venereal disease research laboratory (VDRL), human immunodeficiency virus (HIV) and Rubella immune status.

5. Abdominal examination

An abdominal examination of the pregnant woman should be done in addition to the physical examination and assessment. The examination includes inspection, palpation and auscultation.

- Inspection is done to note
  - » Skin condition of abdomen
  - » Incisional scars
  - » Contour of abdomen which give clue to lie of the fetus presenting part and to determine if it is engaged or floating.
  - » Size of abdomen.
- Palpation is done using Leopold's maneuvers
  - » First maneuver (Fundal palpation) is performed to detect the height of fundus and presentation.
  - » Second maneuver (Lateral palpation) helps to identify the position, lie and variety.
  - » Third maneuver (Pawlick's grip/second pelvic grip) is done to identify the presenting part and to determine if it is engaged or floating.
  - » Fourth maneuver (Pelvic palpation/first pelvic grip) to determine the degree of flexion of the presenting part as well as the extent of its descend into the pelvic cavity.
- Auscultation—of fetal heart sounds helps in the diagnosis of a live fetus and its location of maximum intensity which provides information about the presentation.

6. Vaginal examination

Vaginal examination is performed in early pregnancy to detect the condition of vagina, presence of scars, prolapse of uterus or cervical fibroids. In late pregnancy, the examination is done to make pelvic assessment.

Ultrasonography

Ultrasonographic examination has almost replaced the radiological examination during pregnancy. This painless procedure is useful for detecting and confirming:

- The pregnancy
- Gestational age
- Abnormalities of pregnancy
- Fetal anomalies
- Fetal well-being.

Prenatal Education

Every mother needs advice regarding the importance of regular prenatal check-ups and measures to be taken to maintain or improve her health status during pregnancy in order to have a normal delivery and healthy baby.

JAYPEE BROTHERS

In order to remove the fear of unknown and to help them approach the event of childbirth without undue anxiety, 'child birth preparation' through explanation of physiological changes and methods of coping during labor and delivery and puerperium must be explained.

Rest and Sleep

Pregnant women may continue her usual activities throughout pregnancy.

Hard and strenuous activities should be avoided in the first trimester and last six weeks. The woman should have an average of 10 hours of sleep (8 hours at night and 2 hours at noon) especially in the last trimester.

In late pregnancy, lateral position in bed would be more comfortable.

Diet

The diet during pregnancy should be adequate to maintain maternal health, meet the needs of growing fetus and provide strength during labor. During pregnancy, the calorie requirement is increased by about 300. The diet should be light, nutritious, easily digestable and rich in protein, minerals and vitamins. In addition to the principal food, the mother needs additional quantity of milk, egg, green vegetables and fruits. 2400 calories is generally recommended.

Exercise

Day-to-day domestic and social activities to be continued during pregnancy. Brisk walk in the morning and evening and specific antenatal exercises to prepare the mother's body for labor and delivery are recommended.

Bathing and Clothing

Daily bath and wearing loose comfortable clothes are advised for the comfort of pregnant women. Wearing high heeled shoes should be avoided in late pregnancy when the center of balance alters.

Care of Breasts and Nipples

If the nipples are anatomically normal, nothing beyond ordinary cleaning is needed. If the nipples are flat or retracted, rolling of the nipples and drawing them out between thumb and forefinger, twice daily for 5 minutes must be explained. Drawing the nipples and rolling them between fingers is recommended after cleansing.

Dental Care

Tendency to dental caries is high in pregnancy and consulting a dentist and taking required treatment must be emphasized.

Alcohol and smoking—should be avoided in pregnancy since nicotine is harmful for the growing fetus and mother. Growth retardation and maldevelopment of fetus are the possible complications to be prevented.

Care of Bowels

Regulation of diet to include food containing roughage, fluids and vegetables as well as extra quantity of water are to be explained to mother.

Coitus—should be avoided in the first three months to prevent abortion and in the 3rd trimester to prevent premature labor and puerperal infection.

Travel—by vehicles having jerks are better avoided in first trimester and last six weeks. Rail journey is preferable to bus travel and travel by aircraft offers no risk.

Immunization—against tetanus is essential for mothers in developing countries to protect them as well as their neonates. Two doses of tetanus toxoid between 16 and 24 weeks are generally recommended.

JAYPEE BROTHERS

General Advice

The mother should be instructed to go to the hospital in the following circumstances:

- Active vaginal bleeding even if small amount
- Severe and continuous headache
- Swelling of face, fingers and toes
- Persistent vomiting
- Dimness or blurred vision
- Painful uterine contractions at interval of about 10 minutes or less for at least one hour
- Sudden gush of watery fluid per vagina
- Pain in abdomen
- Fever with chills.

MINOR DISORDERS OF PREGNANCY

At various times during the course of pregnancy, women will experience problems due to physiological changes occurring in their body.

- **Nausea and vomiting:** Nausea and vomiting upon getting up in the morning are experienced by some women, especially primigravidae in their first trimester. Advice to stay in bed longer, avoiding fatty foods and fluids in empty stomach are generally sufficient to relieve symptoms.
- **Backache:** A problem experienced in the last trimester by some women. Relaxation of pelvic joints, faulty posture, muscle spasm and urinary infection are some of the causes for backache.

  Advice regarding more rest in hard bed, massaging back muscles and wearing a well—fitting pelvic girdle belt while walking may be given.
- **Constipation:** This is a common problem in pregnancy due to the effect of progesterone on the gut and diminished physical activity.

  Regular bowel habits, taking fluids and including vegetables and fruits in diet are to be explained to mothers having problem of constipation.
- **Heartburn:** Restriction of greasy and spicy foods and avoiding fats often help to reduce the problem. Remaining upright for 1 to 2 hours after meals reduces the possibility acid reflux. Taking small, frequent meals to avoid overloading the stomach is helpful. Antacids if prescribed by the physician can be taken for relief of symptoms.
- **Leg cramps:** Leg cramps often occur due to deficiency of serum calcium and elevation of serum phosphorus. Instruct patient to elevate her legs periodically and avoid lying with toes pointed. Increasing milk intake, taking warm baths at bedtime and regular exercises prevent the occurrence of leg cramps.
- **Urinary frequency and dysuria:** Taking more fluids during day time, avoiding distension of bladder and early treatment for any urinary tract infection are the measures to help women with urinary problems in pregnancy.
- **Varicose veins:** Varicose veins in the legs, vulva or rectum appear in the later months of pregnancy. Elevation of legs while resting and elastic crepe bandage during movements can give symptomatic relief. For hemorrhoids, local application of hydrocortisone ointment and prescribed laxatives to keep the bowels soft are recommended.

LABOR

A process that involves a series of integrated uterine contractions that occur over time, and work to propel the products of conception (fetus, placenta and amniotic fluid) out of the uterus through the birth canal.

Normal Labor or Eutocia

Labor is normal when a fetus of 38 to 42 weeks presenting by the vertex, is delivered within 24 hours, spontaneously, uncomplicated and with minimal aid in case of both mother and baby.

JAYPEE BROTHERS

Causes of Onset of Labor

The precise mechanism of initiation of labor is still unclear. Some of the hypotheses are as listed below:

- Uterine distension. The stretching effect on the myometrium by the growing fetus and liquor amni.
- Pressure of the presenting part on the nerve endings in the cervix. Pressure stimulates a nerve plexus known as the cervical ganglion. Labor is more likely to start on time when the head is engaged.
- Over distension of uterus in case of multiple pregnancy and hydramnios, over distension tends to induce premature labor.
- Oxytocin stimulation theory—The uterus becomes increasingly sensitive to oxytocin as pregnancy progresses.
- Progesterone withdrawal theory—A decrease in progesterone production may stimulate prostaglandin synthesis and enhance the effect of estrogen which has a stimulating effect on uterine muscle.
- Estrogen stimulation theory—Estrogen stimulates irritability of uterine muscles and enhances uterine contractions.
- Fetal cortisol theory—Estrogen level increases due to the effects of fetal cortisol in late pregnancy.
- Prostaglandin stimulation theory—Initiation and maintenance of labor due to synthesis of prostaglandins in late pregnancy.

SIGNS OF LABOR

1. Prelabor or premonitory signs of labor may begin two to three weeks prior to the onset of true labor in primigravidae and a few days before in multiparae.
   - Lightening—In primigravidae, the presenting part sinks into the true pelvis due to active pulling up of the lower segment of the uterus around the presenting part. This minimizes the fundal height and hence relieves the pressure on diaphragm making breathing easier for the mother.
   - Frequency of micturition and constipation—The mother may experience urinary frequency and constipation due to pressure from the engaged presenting part.
   - Cervical changes—The cervix becomes ripe. A ripe cervix is soft, less than 1.3 cm in length, admits one finger and is dilatable.
   - Taking up of cervix—The cervix becomes shorter as it gets drawn up and merged into the lower uterine segment.
   - Appearance of false pains or spurious labor—False pains are erratic and irregular. The uterus contracts and relaxes and the discomfort remains stationary at the lower abdomen.
2. True labor

   The features of true labor pains are:
   - Painful, rhythmic uterine contractions with hardening of uterus
   - Progressive dilatation and effacement of cervix
   - Appearance of "show"—blood stained mucoid discharge
   - Formation of the bag of waters.

Features of True and False Labor Pains

True labor pains	False labor pains
• The pain arises in the back, radiates to the front of abdomen and thighs	• Pain occurs in the lower abdomen and groin only and remains stationary in the lower abdomen
• Intermittent in nature with increase in intensity, frequency and duration	• Pain is continuous without any rhythmicity
• Associated with hardening of uterus due to retraction of muscle fibers	• There is no hardening of uterus
• Expulsion of "Show" which is the mucus plug mixed with blood from the ruptured capillaries of the cervix	• No effect on dilatation of cervix and no "show"

Contd…

JAYPEE BROTHERS

Contd…

True labor pains	False labor pains
• Dilatation of internal os and taking up of cervix	• No dilatation and taking up of cervix
• Formation of "bag of waters" due to stretching of the lower uterine segment and detachment of membranes from the decidua	• No formation of bag of waters
• Pain increases after administration of an enema	• Pain diminishes after enema
• Pain occurs due to uterine contraction	• Pain occurs due to a loaded rectum

STAGES OF LABOR AND PHYSIOLOGICAL CHANGES DURING THE DIFFERENT STAGES

1. First Stage—Stage of Dilatation

First stage of labor begins with regular, rhythmic contractions and completes when the cervix is fully dilated. Average duration is 12 hours in primigravida and 8 hours in multigravida.

Physiological Changes

- Contraction and retraction of uterine muscle
- Formation of upper and lower segments
- Development of the retraction ring
- Polarity which is the neuromuscular harmony between the two poles or segments of uterus
- Dilatation and effacement of cervix
- Fetal axis pressure
- Formation of bag of water
- Rupture of membranes.

2. Second Stage—Stage of Expulsion

Second stage of labor begins with the complete dilatation of the cervix and ends with the expulsion of the fetus through the birth canal. Average duration is 1–1½ hours in primigravida and ½ hour in multigravida.

Physiological Changes

- Stronger, frequent contractions
- Voluntary contractions of the abdominal muscles–bearing down efforts
- Expulsive, downward force of uterine contractions
- Displacement of pelvic floor (soft tissue displacement)
- Expulsion of the fetus.

Mechanism of Normal Labor

Definition

The mechanisms of labor are the positional movements that the fetus undergoes to accommodate itself to the maternal pelvis as it negotiates the birth canal.

Positional movements

There are several basic movements which take place when the fetus is in a cephalic or vertex presentation.

- Engagement
- Descend throughout
- Flexion

JAYPEE BROTHERS

- Internal rotation of the head
- Crowning
- Birth of the head by extension
- Restitution
- Internal rotation of the shoulders
- External rotation of the head as the shoulders rotate internally
- Birth of the shoulders and body by lateral flexion.

Principles

The principles are common to all mechanisms.

- Descend occurs throughout
- The part that leads and first meets the resistance of the pelvic floor will rotate forwards until it comes under the symphysis pubis.
- The part that escapes under the symphysis pubis will pivot around the pubic bone.
- During the mechanism, the fetus turns slightly to take advantage of the widest available space in each plane of the pelvis, i.e. transverse at the brim and anteroposterior at the outlet.

Summary of mechanisms in left occipitoanterior position

- The lie is longitudinal
- The presentation is cephalic
- The position is left occipitoanterior
- The attitude is one of flexion
- The denominator is occiput
- The presenting part is the posterior part of the anterior parietal bone.

Positional movements

- Engagement takes place with sagittal suture of the fetal head in the right oblique diameter of the pelvic inlet and the biparietal diameter in the left oblique. The occiput points to the left iliopectineal eminence and sinciput to the right sacroiliac joint.
- Descend occurs throughout.
- Flexion substitutes the suboccipitobregmatic diameter for the suboccipito-frontal which entered the pelvic inlet.
- Internal rotation takes place as the occiput turns 1/8th of a circle (45 degrees) to the right and sagittal suture comes to the anteroposterior diameter of the pelvis (outlet).
- The occiput escapes under the symphysis pubis and crowning occurs when the head no longer recedes between contractions.
- The head is born by extension, pivoting on the suboccipital-region around the pubic arch.
- Restitution: The occiput turns 1/8th of a circle (45 degrees) to the left to undo the twist on the neck.
- Internal rotation of the shoulders.
  The anterior shoulder reaches the pelvic floor and rotates anteriorly to lie under the symphysis pubis. This movement can be seen as the head turns at the same time in external rotation.
- External rotation of the head.
  The head turns 1/8th of a circle (45 degrees) to the mother's left. The bisacromial diameter comes into the anteroposterior diameter of the maternal pelvis. This occurs in the same direction as restitution and at the same time as internal rotation of shoulders.
- The anterior shoulder escapes under the symphysis pubis and the body is born by lateral flexion.

3. Third Stage—Stage of Placental Delivery

Third stage of labor comprises the phase of placental separation, its descend to the lower segment and finally its expulsion with the membranes. The time begins upon completion of the birth of the baby and ends with the expulsion of placenta. Average duration of third stage is 30 minutes in both primigravidae and multipara.

JAYPEE BROTHERS

Physiological Changes

- Contraction and retraction of uterus
- Expulsion of placenta and membranes.

Signs of Placental Separation

- Sudden trickle or gush of blood
- Lengthening of the umbilical cord visible on the introitus
- Change in the shape of the uterus from discoid to globular
- Change in the position of the uterus as it rises in the abdomen.
  Method of separation of the placenta may be central (Schultz method) or marginal (Mathews Duncan method).

4. Fourth Stage

Fourth stage of labor begins with the birth of the placenta and ends one hour later. The first postpartal hour is a critical time of initial recovery from the stress of labor and delivery and requires close observation of the mother.

Physiological Changes

- Uterus becomes firm and retracted (hard to touch)
- When contracted, the entwining muscle fibers of the myometrium serve as ligatures to the open blood vessels at the placental site and bleeding is controlled naturally.
- Thrombi form in the distal blood vessels in the decidua do not get released into systemic circulation.

NURSING MANAGEMENT DURING LABOR AND DELIVERY

First Stage of Labor

- Admit the mother in labor room and complete the procedures such as changing to hospital gown, applying identification band, obtaining history and completing chart forms.
- Orient patient to labor and delivery rooms
- Explain admission protocol, labor process and management plans
- Carry out perineal shave and administer enema if not contraindicated
- Start an IV line if indicated and administer fluids
- Provide bodily care and attend to comfort needs.
- Monitor and evaluate maternal well-being, fetal well-being and progress of labor (vital signs of mother, fetal heart sounds, uterine contractions, cervical dilation and fetal descend).
- Encourage to use coping skills such as breathing, relaxation and positioning.
  - During latent phase (1–4 cm dilation): Review breathing technique she can use as labor progresses and encourage ambulation and comfortable position.
  - During active phase (4–8 cm dilation): Provide comfortable position, assist with breathing exercises, provide backup and sacral pressure and analgesia.
  - During transitional phase (8–10 cm dilation): Assist with deep breathing during contractions and shallow breathing and relaxation between contractions.
- Provide information about progress of labor, fetal well-being and how she is coping.

Second Stage of Labor

- Continue to monitor maternal well-being including vital signs, bladder care, hydration and analgesia
- Encourage maternal pushing efforts
- Evaluate perineal integrity and perform episiotomy if appropriate
- Deliver the baby and reassure mother about neonate's condition.

JAYPEE BROTHERS

Third Stage of Labor

- Encourage patient to maintain position to facilitate delivery of placenta
- Allow mother to hold and feed the baby if she desires
- Deliver placenta and membranes
- Monitor maternal vital signs, bleeding and consistency of uterus
- Administer oxytocin if required
- Examine placenta and membranes for completeness
- Perform episiotomy suturing if one was made.

Fourth Stage of Labor

- Provide clean gown, perineal pads and comfortable position
- Check vital signs regularly
- Palpate fundus of uterus for contractility
- Massage the fundus and express any clots present
- Inspect the perineum, bladder and change pads
- Offer food and fluids if not contraindicated.

ABNORMAL LABOR (DYSTOCIA)

Dystocia means abnormal or difficult labor or delivery.

Difficulty in labor and delivery may be due to:

- Fetal causes such as fault in
  - Attitude, e.g. deficient flexion
  - Position, e.g. posterior positions
  - Presentation, e.g. breech, shoulder
- Maternal causes such as
  - Fault in the force, e.g. abnormal uterine action
  - Fault in passage, e.g. Pelvic abnormalities
  - Poor maternal health, e.g. poor general condition.

MALPOSITIONS AND PRESENTATIONS

1. Occipitoposterior Position

An abnormal position of the vertex which gives rise to difficulty in delivery of the fetus with a normal gynecoid pelvis.

Causes

- Shape of the pelvic inlet. Android or anthropoid pelvis with wide posterior segment favors occipitoposterior position.
- Deflexion of the fetal head—Factors affecting flexion of the head are high pelvic inclination and attachment of placenta in the anterior wall of the uterus.
- Abnormal uterine contraction—This could be the cause or effect of deflexion.

Possible Difficulties in Occipitoposterior Position

- Difficulty in engagement of head
- Premature rupture of membranes
- Prolonged labor with increased risk of fetal asphyxia

JAYPEE BROTHERS

for detailed information on nursing books, visit our website www.ejaypee.com, for detailed information on nursing books, visit our website www.ejaypee

MIDWIFERY CASEBOOK
A Practical Record of Maternal and Newborn Nursing
for GNM Students

Salient Features

- A carefully planned and diligently arranged text for planning, providing and documenting nursing care to mothers and newborns
- Fulfills the INC syllabus requirements for GNM nursing course
- Includes brief notes on midwifery topics, nursing process and clinical nursing procedures for mothers and neonates
- Includes nursing care study formats for prenatal, intranatal and neonatal clients.

Scan for more nursing titles...

Printed in India

Available at all medical bookstores or buy online at www.ejaypee.com

JAYPEE BROTHERS
Medical Publishers (P) Ltd.
EMCA House, 23/23-B, Ansari Road,
Daryaganj, New Delhi - 110 002, INDIA
www.jaypeebrothers.com

Join us on facebook.com/JaypeeMedicalPublishers
Follow us on instagram.com/JaypeeMedicalPublishers

ISBN 978-93-6616-830-2