ebsite www.ejaypee.com, for detailed information on anatomy books, visit our website www.ejaypee.com, for detailed information on anatomy books, visit our website www.ejaypee.com,

3rd Edition

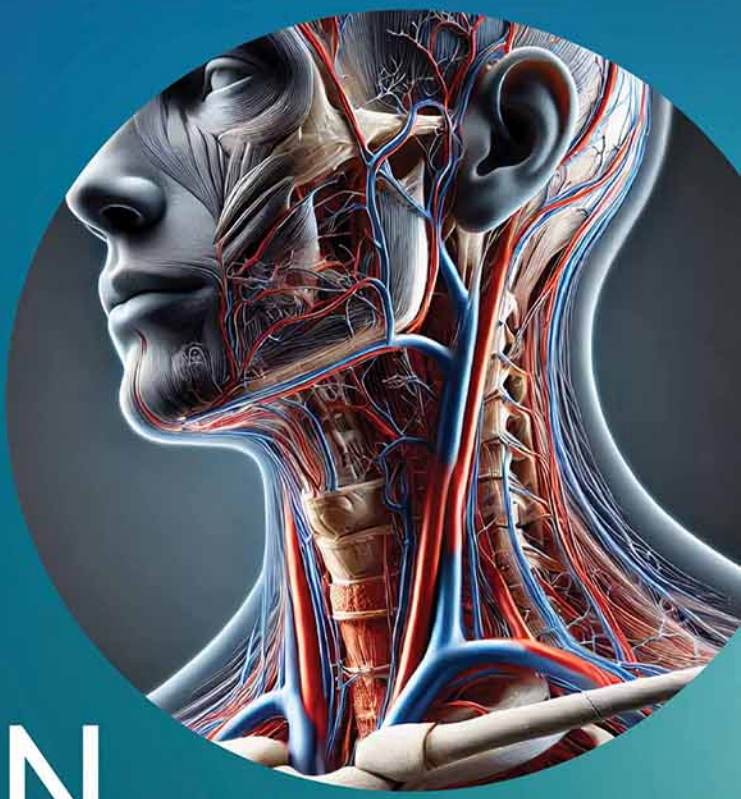

HUMAN ANATOMY

for Allied and Healthcare Sciences

Previously Known as Basics in Human Anatomy for BSc Paramedical Courses

Priya Ranganath
Leelavathy N

JAYPEE

Contents

1. Introduction 1

- Definition 1
- Terms of Position 2
- Terms of Movement 2
- Cell and its Organelles 3
- Applied Anatomy 7

2. Epithelial Tissue and Glands 8

- Epithelial Tissue 8
- Epithelial Glands 11
- Applied Anatomy 15

3. Connective Tissue and Skeletal System 17

- Connective Tissue 17
- Skeletal System 19
- Cartilage 19
- Bone 22
- Joints 40
- Applied Anatomy 48

4. Muscular System 52

- Skeletal Muscles 52
- Smooth Muscle 54
- Cardiac Muscle 56
- Applied Anatomy 73

5. Lymphatic System 75

- Lymphatics or Lymph Vessels 75
- Thoracic Duct 76
- Cisterna Chyli 76
- Lymphatic Organs 76
- Applied Anatomy 82

6. Cardiovascular System 83

- Mediastinum 83
- Pericardium 85
- Heart 85
- Arteries of the Body 93

- Veins of the Body 99
- Applied Anatomy 109

7. Respiratory System 113

- Nasal Cavity 113
- Paranasal Air Sinuses 115
- Larynx 116
- Trachea 117
- Lungs 118
- Bronchial Tree 121
- Diaphragm 123
- Applied Anatomy 124

8. Digestive System 126

- Peritoneum 126
- Mouth 127
- Salivary Glands 132
- Pharynx 134
- Esophagus 135
- Stomach 137
- Small Intestine 140
- Large Intestine 146
- Cecum 148
- Vermiform Appendix 149
- Rectum 152
- Anal Canal 152
- Accessory Digestive Organs 153
- Applied Anatomy 163

9. Urinary System 170

- Kidneys 170
- Ureters 175
- Urinary Bladder 176
- Urethra 180
- Applied Anatomy 182

10. Reproductive System 184

- Male Reproductive System 184
- Female Reproductive System 194
- Applied Anatomy 203

11. Endocrine System 206

- Pituitary Gland 206
- Thyroid Gland 209
- Parathyroid Gland 210

- Suprarenal Gland 212
- Applied Anatomy 215

12. Nervous System 217

- Neuron 218
- Neuroglia/Supporting Cells 220
- Meninges 220
- Spinal Cord 222
- Brainstem 226
- Ventricles 241
- Cerebrospinal Fluid 243
- Cranial Nerves 243
- Cranial Nerve Nuclei 248
- Autonomic Nervous System 251
- Peripheral Nervous System 252
- Applied Anatomy 261

13. Sensory Organs 266

- Skin 266
- Ear 270
- Eye 273
- Applied Anatomy 276

14. General Embryology 279

- Cell Division 279
- Spermatogenesis 282
- Oogenesis 283
- Fertilization 284

15. Nursing Care Related to Anatomy 288

- Connective Tissue, Skeletal and Muscular System 289
- Lymphatic System 290
- Cardiovascular System 291
- Respiratory System 291
- Digestive System 292
- Urinary System 293
- Reproductive System 293
- Endocrine System 294
- Nervous System 294
- Sensory Organs 295

16. The Crucial Role of Anatomy in Physiotherapy Education 297

Index 301

CHAPTER 10

Reproductive System

JAYPEE BROTHERS

LEARNING OBJECTIVES

The student should be able to:

- Parts of male reproductive system, details of testis, epididymis, vas deferens, prostate—gross and histology.
- Parts of female reproductive system, details of uterus, fallopian tubes, ovary—gross and histology.
- Mammary gland—gross.

MALE REPRODUCTIVE SYSTEM

- Male genital system is made up of testes, vas deferens, seminal vesicles and ejaculatory ducts.
- Accessory sex organs are prostate and bulbourethral glands.
- Male external genitalia are made up of scrotum and penis.

Testis

- Testes are a pair of ellipsoid bodies suspended by spermatic cord into the scrotum.
- Each testis lies obliquely such that the upper pole is tilted forwards and laterally.
- **Testis has two poles or ends:** Upper and lower, two borders: Anterior and posterior, two surfaces: Medial and lateral.
- Upper end of testis is covered by epididymis and is connected to it by ducts called efferent ductules. Lower end is related to tail of epididymis and connected to it by areolar tissue.
- Anterior border is smooth and convex. Posterior border is broad and flat and the spermatic cord is attached to its upper part.
- Medial surface is smooth and convex.
- Lateral surface is overlapped by epididymis and separated from it by a fold of processus vaginalis by a space called sinus of epididymis (this is useful for side determination).

Coverings of Testis

Testis is covered by three layers. From outside inwards, they are:

1. **Tunica vaginalis:** It has two layers, the outer **parietal** layer and the inner **visceral** layer. The visceral layer covers the testis and the epididymis except at the posterior border and is continuous with the parietal layer forming a closed sac. This sac is a site of collection of fluid; the condition is called **hydrocele**.

2. **Tunica albuginea:** It is a thick fibrous layer that covers the whole of the testis. It is thickened at the posterior border to form the mediastinum testis that sends septae inside the testis to divide it into lobules. About 200 to 300 lobules are present in each testis.
3. **Tunica vasculosa:** It is a vascular membrane that covers each lobule of the testis.

Macroscopic Structure of Testis (Fig. 10.1)

- Each lobule of the testis has one to three seminiferous tubules and some interstitial cells of Leydig.
- Total number of tubules in the testis is 400–600.
- Seminiferous tubules have a coiled part in the front and a straight part at the back.
- The straight parts join at the level of mediastinum testis to form a plexus of tubules called the rete testis.
- From the rete testis, efferent ductules arise and enter the head of the epididymis.
- Each seminiferous tubule has two kinds of cells, the spermatogenic cells (which produce sperms) and the Sertoli cells (supporting cells).
- Sertoli cells provide nutrition to the developing sperms and phagocytose the residual bodies.
- The **interstitial cells of Leydig** are situated outside the seminiferous tubules and secrete testosterone. This is the hormone responsible for maintenance of the sexual organs of a male.

Blood Supply

- Testicular artery which is a branch of abdominal aorta.
- A plexus of veins called the pampiniform plexus finally forms one vein which drains into the inferior vena cava on the right side and the renal vein on the left side.
- The plexus helps to absorb the heat produced by the testicular arteries and hence the temperature of the scrotum is less than the abdominal cavity which is necessary for production of sperms.

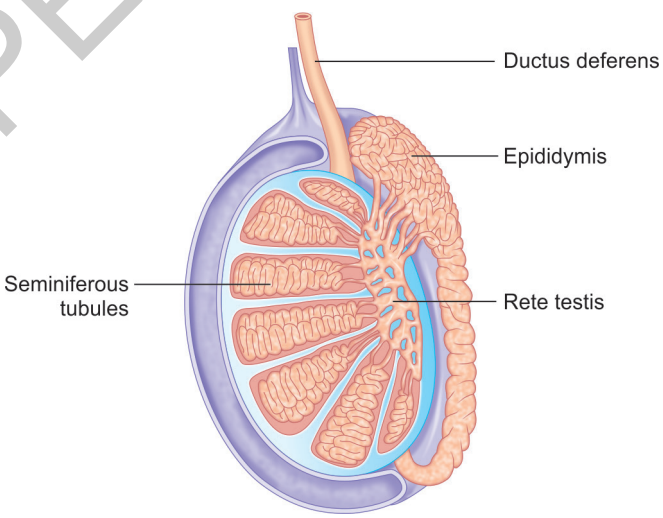

Fig. 10.1: Parts of testis.

JAYPEE BROTHERS

Lymphatic Drainage

Drains into the pre- and the para-aortic group of lymph nodes.

Nerve Supply

- Sympathetic nerves of the renal and aortic plexuses.
- The preganglionic fibers are derived from T10 and T11 segments of spinal cord.

Descent of Testis

- In fetal life, testis is formed at the level of the iliac fossa at the 4th month.
- It descends down slowly so that it reaches the deep inguinal ring at the 7th month, the inguinal canal in the 8th month and then in the scrotal sacs by the end of 9th month that is just before birth. This is called the descent of testis.

Microscopic Structure of Testis (Figs. 10.2A and B)

- The testis is made up of coiled tubes called the seminiferous tubules.
- These are separated from each other by connective tissue that has blood vessels and nerves.
- The wall of each tubule is made up of an outer layer of fibrous tissue that also contains muscle. The contraction of this layer helps in the propulsion of spermatozoa.
- Between the lumen of the tubule and the outer layer are rows of cells that are of various types. In these are the supporting cells called the Sertoli cells and the spermatozoa in various stages of development. Each sperm is formed by a process called spermatogenesis.
- The primordial cells are the spermatogonia. They lie in the most basal layer. The spermatogonia is divided by mitosis to form primary spermatocytes (2n). They are large cells with a prominent central oval nucleus. They form the second layer of cells. These undergo the first meiotic division to form secondary spermatocytes (n). They are smaller than the primary and form the third layer of cells. The secondary spermatocytes undergo the second meiotic division to form the spermatids (n). These are immature sperms, and they undergo a process called spermiogenesis to form sperms.
- Each sperm has a head, a body and a tail. The head lies embedded in the Sertoli cells such that the lumen of the seminiferous tubule shows tails of the sperms.

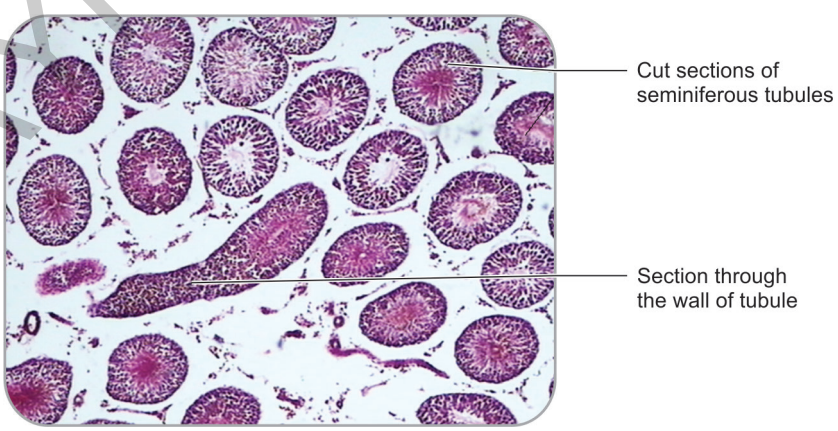

Fig. 10.2A: Photomicrograph of histology of testis.

JAYPEE BROTHERS

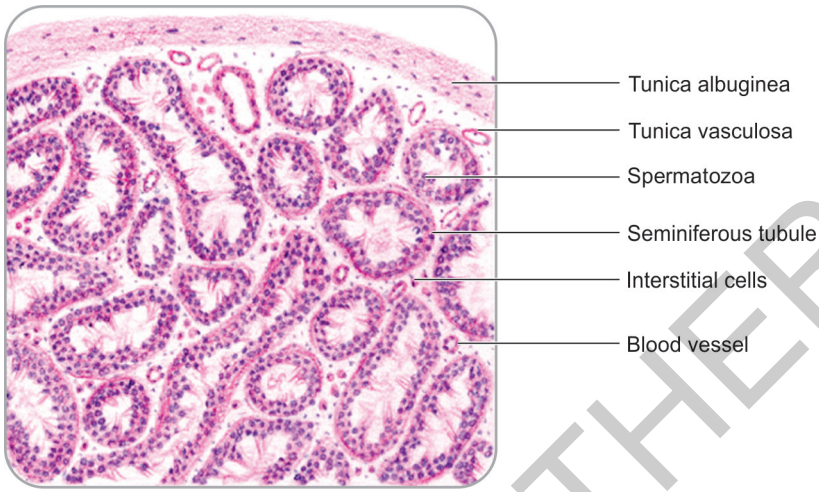

Fig. 10.2B: Diagrammatic representation of histology of testis.

- Sertoli cells are large cells with a basal nucleus. The spermatogonia in the various stages of development lie closely associated with the Sertoli cells in the layers one above the other. The mature sperms lie embedded in the Sertoli cell apex. Hence, the Sertoli cells support the sperms, provide nutrition to them and remove the waste products formed after spermatogenesis.
- Lying in between the seminiferous tubules in the connective tissue are cells that secrete testosterone. These are called interstitial cells of Leydig and are round cells with round nuclei.

Applied Anatomy

- **Hydrocele:** This is the collection of fluid in the sac formed by the visceral and parietal layers of the processus vaginalis.
- **Hernia:** Contents of the abdomen may descend into the testis if the processus vaginalis remains patent. This is called inguinal hernia.
- **Varicocele:** The pampiniform plexus of veins becomes dilated and enlarged to give rise to a condition called varicocele. It is more common on the left side as the left testicular vein is longer than the right, the left vein may be compressed by a loaded colon in iliac fossa and also because the left testicular vein enters the renal vein at a right angle.
- **Cryptorchidism:** This is a condition where the testis fails to descend and lies in the abdominal cavity only. These patients are sterile. An undescended testis is a frequent site of carcinoma.
- **Ectopic testis:** An ectopic testis is one that deviates from its normal path of descent so that it lies at an abnormal site.

Epididymis (Fig. 10.3)

- This is a comma shaped organ that lies along the lateral part of the posterior surface of the testis.
- It is made up of a head, a body and a tail. The head is connected to the testis by the efferent ductules. The tail continues as the ductus deferens.
- The epididymis transports sperms from the testis to the vas deferens.

JAYPEE BROTHERS

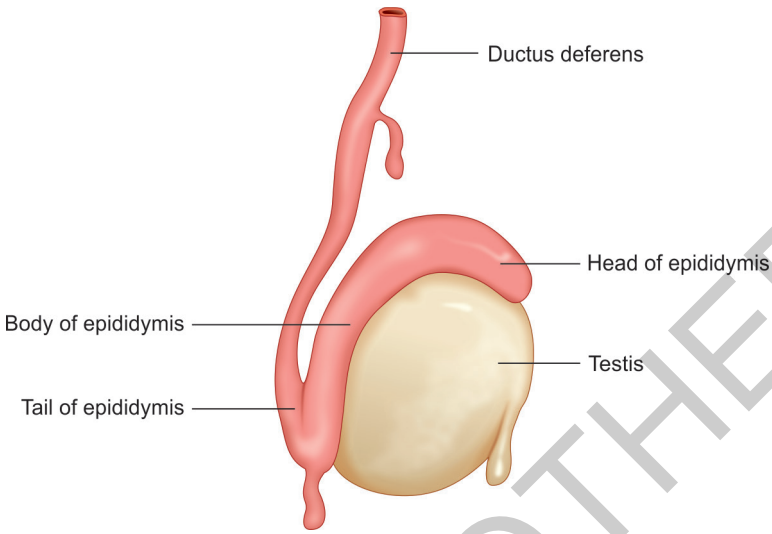

Fig. 10.3: Parts of epididymis.

JAYPEE BROTHERS

Microscopic Structure (Figs. 10.4A and B)

- The epididymis is made up of tubules separated by smooth muscle.
- The tubules are lined by columnar epithelium with stereocilia.

Vas Deferens

- The vas deferens or the ductus deferens is a thick cord-like tubular structure and is about 45 cm long.
- It starts from the tail of the epididymis and enters the spermatic cord.
- At the level of the deep inguinal ring, it becomes subperitoneal and then reaches the urinary bladder.
- At the base of prostate, it joins with duct of seminal vesicle to form ejaculatory duct.
- Bilateral ligation (tying) of the ductus deferens is done in vasectomy, a family planning procedure.

Histology

- The wall of the ductus deferens is made up of three layers.
- The innermost mucosa, thrown into folds, is lined by simple columnar epithelium.
- The middle layer is made up of smooth muscle arranged in three layers—inner longitudinal, middle circular and outer longitudinal.
- The outermost layer is connective tissue.

Seminal Vesicle

- They are a pair of pyramidal organs present between the base of the bladder and the ampulla of rectum.
- Secrete a viscid, yellowish white alkaline fluid that forms bulk of the semen.

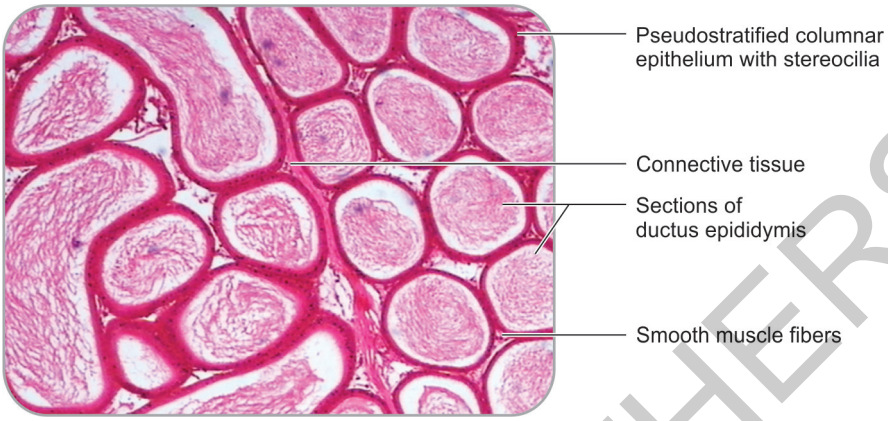

Fig.10.4A: Photomicrograph of histology of epididymis.

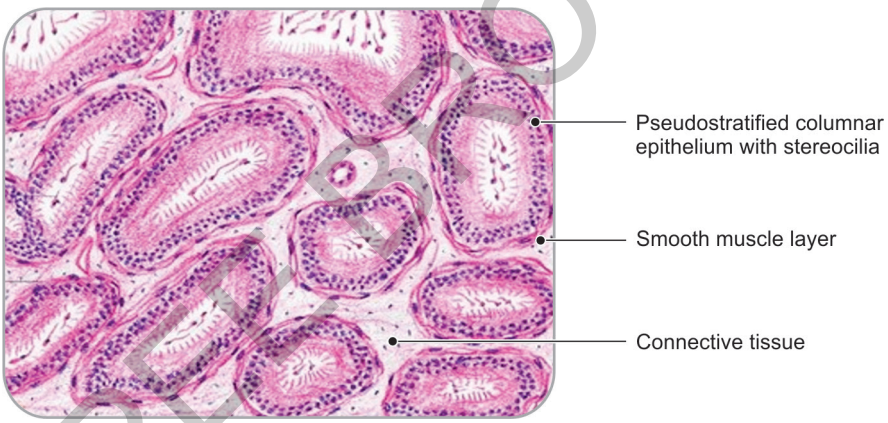

Fig. 10.4B: Diagrammatic representation of histology of epididymis.

Ejaculatory Ducts

- There are two ejaculatory ducts, each formed by the union of vas deferens and the duct of seminal vesicle.
- Each duct opens into the prostatic urethra at the colliculus seminalis on the sides of the prostatic utricle.
- They are responsible for the transport of sperms from the testis to the exterior.

Spermatic Cord

- The spermatic cord is a tubular sheath that contains the vas deferens and the vessels and nerves of the testis and epididymis.
- It is about 7.5 cm long and extends from the deep inguinal ring to the upper border of the testis.
- It suspends the testis in the scrotum.

JAYPEE BROTHERS

- **Contents of the cord are:**
  - Vas deferens
  - Pampiniform plexus of veins
  - *Arteries:* Testicular artery, artery to the vas and the cremasteric artery
  - Lymphatics of testis and epididymis.
  - *Nerves:* Genital branch of genitofemoral and nerve supply to testis
  - Loose connective tissue
  - Remains of the processus vaginalis.

Prostate Gland (Fig. 10.5)

- The prostate is an accessory gland of the males.
- It adds to the seminal fluid by secreting certain secretions.
- It is made up of glandular tissue embedded in a dense fibromuscular stroma. This makes the prostate firm in consistency.
- It lies in the lesser pelvis, below the neck of the urinary bladder behind the lower border of the pubic symphysis and in front of the ampulla of rectum.
- **It has the following parts:**
  - Apex that is directed downwards and rests on the urogenital diaphragm.
  - Base that is directed upwards and is continuous with the neck of the bladder.
  - Anterior surface.
  - Posterior surface.
  - Two inferolateral surfaces.

Lobes

- The prostate has five lobes—anterior, posterior, median (or medial) and right and left lateral lobes.
- The prostate is traversed by the urethra that passes at the junction of the anterior 1/3rd and posterior 2/3rd of the prostate. Hence, the two lateral lobes lie on either side of the urethra.

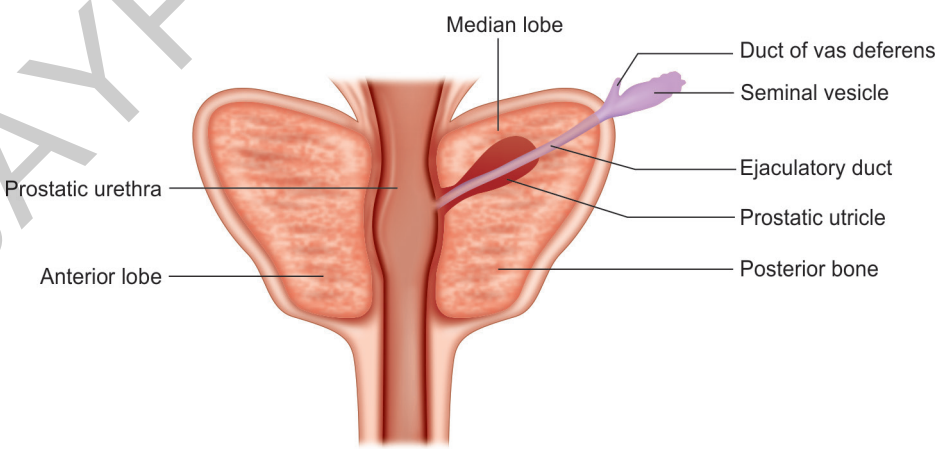

Fig. 10.5: Lobes of prostate gland.

JAYPEE BROTHERS

- The anterior lobes connect the lateral lobes in front of the urethra and the posterior lobes connect the lateral lobes behind the urethra.
- The median lobe lies just behind the upper part of urethra in front of the opening of the ejaculatory ducts in the urethra.

Capsules

- **True capsule:** It is formed by the condensation of the peripheral part of the gland. It contains no venous plexus.
- **False capsule:** It lies outside the true capsule and is derived from the pelvic fascia.
- The venous plexus that drains the prostate lies between the two capsules.

Structures within the Prostate

- Prostatic urethra that lies at the junction of anterior 1/3rd and posterior 2/3rd.
- The prostatic utricle is a blind sac that opens into the prostatic urethra.
- Opening of the two ejaculatory ducts on either side of the prostatic utricle.

Blood Supply

- Inferior vesical, middle rectal and the internal pudendal arteries.
- The veins form a rich plexus between the two capsules of the gland.
- It communicates with the vesical plexus and the vertebral venous plexus.

Lymphatic Drainage

Drain into the internal iliac and the sacral nodes.

Nerve Supply

- Inferior hypogastric plexus.
- It is supplied by both parasympathetic and sympathetic nerves derived from L3, L4, L5 and the upper sacral segments.

Age Changes in the Prostate

- At birth the prostate is small in size and made up of mainly stroma in which a small amount of duct system is present.
- At puberty, the gland greatly increases in size due to growth of glandular tissue. Hence, the amount of stromal connective tissue decreases.
- As the age advances, the size of the gland either increases or decreases and degenerate bodies called the amyloid bodies appear.

Microscopic Structure (Figs. 10.6A and B)

- The prostate is made up of 30–50 compound tubuloalveolar glands embedded in fibromuscular tissue and covered by a capsule.
- The capsule contains numerous veins and nerve fibers.
- Each gland is lined by columnar epithelium which is thrown into numerous folds in the lumen.

JAYPEE BROTHERS

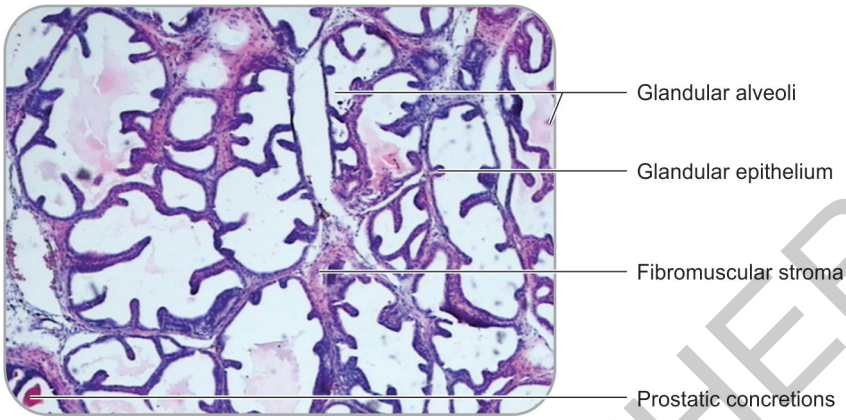

Fig. 10.6A: Photomicrograph of histology of prostate gland.

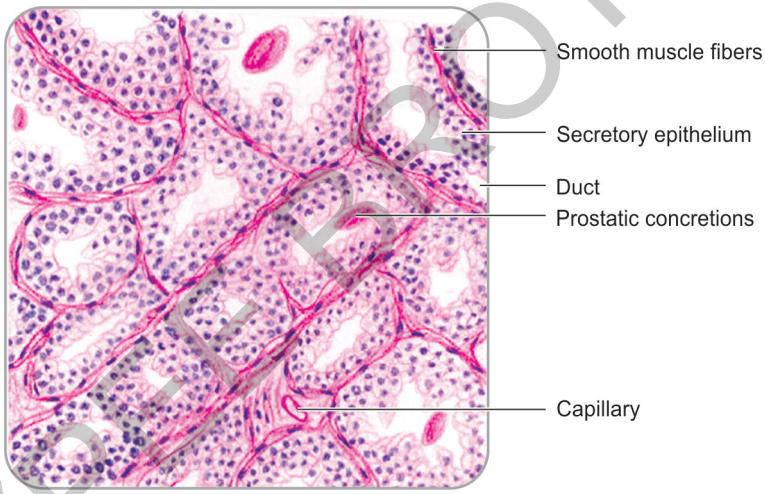

Fig. 10.6B: Diagrammatic representation of histology of prostate gland.

- Small rounded bodies are found in the lumen of each gland. They are called amyloid bodies and are found in a greater number in old age.
- The fibromuscular tissue is made up of collagen fibers and smooth muscle.
- Secretion of each gland goes to excretory ducts lined by double layered epithelium. The basal layer is cuboidal and the superficial layer is columnar. These ducts lie in the fibromuscular tissue.

Applied Anatomy

- **Senile enlargement of the prostate:** It is also called benign prostatic hyperplasia (BPH) which occurs due to enlargement of the median lobe of the prostate. Due to this the patient complains of increased frequency of urination and other urinary complaints due to distortion of the urethra.

JAYPEE BROTHERS

- Carcinoma of the prostate is more common in the posterior lobe. As the venous plexus of the prostate is connected to the vertebral venous plexus by valve less veins, carcinoma spreads to the vertebral bodies.
- Removal of an enlarged prostate is called prostatectomy. In these cases, the prostate is scooped out leaving the two capsules behind (due to the venous plexus present between the two capsules). This is called enucleation.

Scrotum

- Scrotum is a pouch that lies in the lower part of the anterior abdominal wall and contains the testis and the lower parts of the spermatic cords.
- It protects the testis from injury and maintains the temperature of the testis lower than the abdominal temperature, which is necessary for spermatogenesis.

Layers of the Scrotum

- Outermost skin.
- **Dartos muscle:** This is the modification of the superficial fascia.
- **External spermatic fascia:** It is derived from the aponeurosis of the external oblique muscle of the abdomen.
- **Cremasteric muscle and its fascia:** It is derived from the internal oblique muscle.
- **Internal spermatic fascia:** It is derived from the fascia transversalis.
- Parietal layer of the tunica vaginalis.

Cremasteric Reflex

- The genital branch of the genitofemoral nerve supplies both the cremasteric muscle and the medial side of the thigh.
- Due to this, stroking of the medial side of the thigh leads to contraction of the cremastetric muscle and elevation of the testis. This is called cremasteric reflex.

Penis

- The penis is the copulatory organ of the male. It is made up of a root and a body.
- The root is made of three parts; one crus on either side dorsally and a median bulb of the penis. Each crus is covered by the ischiocavernosus muscle and the bulb is covered by the bulbospongiosus muscle.
- When traced forwards in the body, the two crura form the corpora cavernosa of the penis and the bulb forms the corpus spongiosum.
- The corpora cavernosa is made up of cavernous spaces filled by blood during erection. The blood comes from the helicine arteries that are branches of the deep artery to the penis and the blood is drained into the deep dorsal vein of the penis. Hence, erection is a purely vascular phenomenon. The corpus spongiosum is traversed by the spongy urethra.
- The body of the penis shows an expanded portion at the end called the glans penis which is covered by a fold of skin called the prepuce. Circumcision is a surgery where the prepuce is removed.

Blood Supply

- Deep artery of penis, artery to bulb and the dorsal artery of the penis. These are the branches of the internal pudendal artery.

JAYPEE BROTHERS

- Superficial system of veins drain into great saphenous vein through superficial dorsal vein. The corpora are drained by the deep dorsal veins that drain into the prostatic venous plexus.

Lymphatic Drainage

Superficial and the deep groups of the inguinal lymph nodes.

Nerve Supply

- Somatic nerves that convey pain are derived from the pudendal nerves (dorsal nerve of penis).
- Parasympathetic nerves come from S2, S3 and S4 segments of the spinal cord. They are vasodilators.
- The sympathetic supply is from the L1 segment through the superior hypogastric plexus. These nerves are vasoconstrictor.

FEMALE REPRODUCTIVE SYSTEM

Female reproductive system is made up of a pair of ovaries, a pair of uterine tubes, uterus, vagina and external genitalia (labia majora, labia minora, clitoris and vestibule).

Ovaries

- The ovaries are female gonads situated in the ovarian fossa on the lateral pelvic wall.
- In young girls before the onset of ovulation the ovaries have a smooth surface and are pinkish in color. After the onset of puberty, the surface becomes uneven, and the color changes from pink to gray.
- The position of the ovary is variable. In a woman who has not borne any children, they are vertical in position such that they have an upper pole and a lower pole. In multipara, they become horizontal so that the upper pole faces laterally and the lower pole medially.

Parts of Ovary

- **Upper pole:** It is also called the tubal pole and is related to the uterine tube.
- **Lower pole:** It is also called the uterine pole and is related to the lateral angle of uterus by a ligament called the ligament of ovary.
- **Anterior (mesovarian) border:** It is straight and attached to the broad ligament by a fold of peritoneum called the mesovarium. It is also called the hilum of the ovary from where vessels enter the ovary.
- **Posterior (free) border:** It is convex and related to the ureter and uterine tube.
- **Lateral surface:** It is related to the ovarian fossa which is lined by the parietal peritoneum.
- **Medial surface:** It is covered by the uterine tube and separated from it by a bursa called the ovarian bursa.

Blood Supply

- Ovarian artery which is a branch of the abdominal aorta, uterine artery.
- The veins emerge at the hilus and form a pampiniform plexus of veins that drains into a single ovarian vein near the pelvic inlet. This drains into the inferior vena cava on the right side and the left renal vein on the left side.

Lymphatic Drainage

Drain into the lateral aortic and the preaortic group of lymph nodes.

JAYPEE BROTHERS

Nerve Supply

- The ovarian plexus has both sympathetic and parasympathetic nerves.
- The sympathetic nerves T10 and T11 are afferent for pain as well as vasomotor.
- Parasympathetic S2, 3, 4 are vasodilators.

Microscopic Structure (Figs.10.7A and B)

- The ovary is covered by cuboidal epithelium called germinal epithelium. This is modified mesothelium and does not form germ cells.
- The ovary is covered by a thick capsule below the cuboidal epithelium called **tunica** albuginea.
- Below this the substance of the ovary is divided into a cortex and a medulla. The cortex contains the developing follicles and the medulla has the blood vessels supplying the ovary.

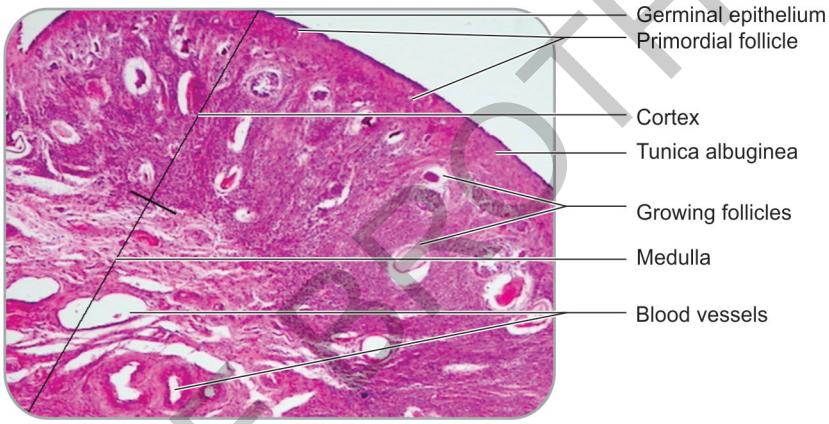

Fig. 10.7A: Photomicrograph of histology of ovary.

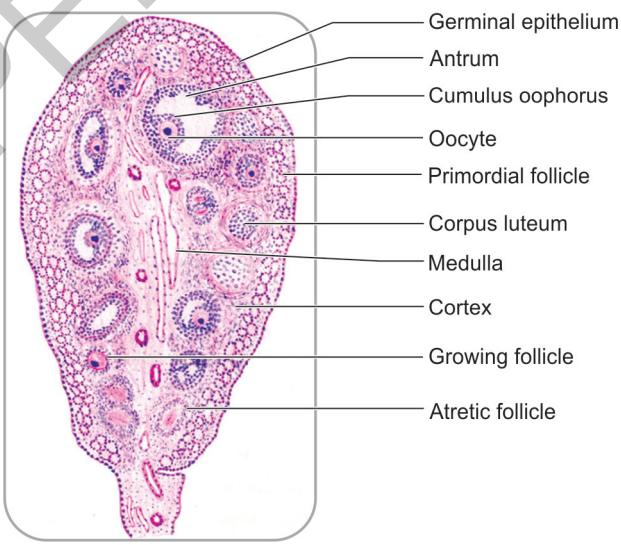

Fig. 10.7B: Diagrammatic representation of histology of ovary.

JAYPEE BROTHERS

The cortex has the following follicles:

- **Primordial follicles:** These are present just below the tunica albuginea and are the smallest in size and the largest in number. They consist of the ovum lined by a single layer of squamous epithelium.
- **Primary follicles:** The lining epithelium that surrounds the ovum changes from squamous to columnar.
- **Secondary follicles:** The stromal cells around the ovum now collect around the ovum to form layers of cells called follicular cells and now the ovum becomes a secondary follicle.
- **Graafian follicle:** Between the follicular cells that surround the ovum, a cavity appears in the cells that pushes the ovum to the periphery. This is called the antrum and is filled by fluid. The ovum now lies in a fluid filled cavity and it is most mature and ready for ovulation. This structure is called the Graafian follicle. The stromal cells surrounding the Graafian follicle differentiate into two layers, the theca interna just around the follicle that secretes estrogen and theca externa that is like a capsule surrounding the follicle.
- **Corpus luteum:** After ovulation (release of ovum into the peritoneal cavity), the follicular cells enlarge; accumulate a yellow pigment called lutein and start secreting progesterone.
- **Corpus albicans:** The corpus luteum after some time degenerates to leave fibrous scar tissue forming a structure called the corpus albicans.

Uterus (Fig. 10.8)

- It is the organ which protects and provides nutrition to a fertilized ovum, enabling it to become a fully formed fetus.
- It is piriform in shape. It is divided into upper expanded part called the body and a lower cylindrical part called the cervix.
- The junction of the two parts is constricted. The body forms the upper 2/3rd and the cervix forms the lower 1/3rd of the organ.

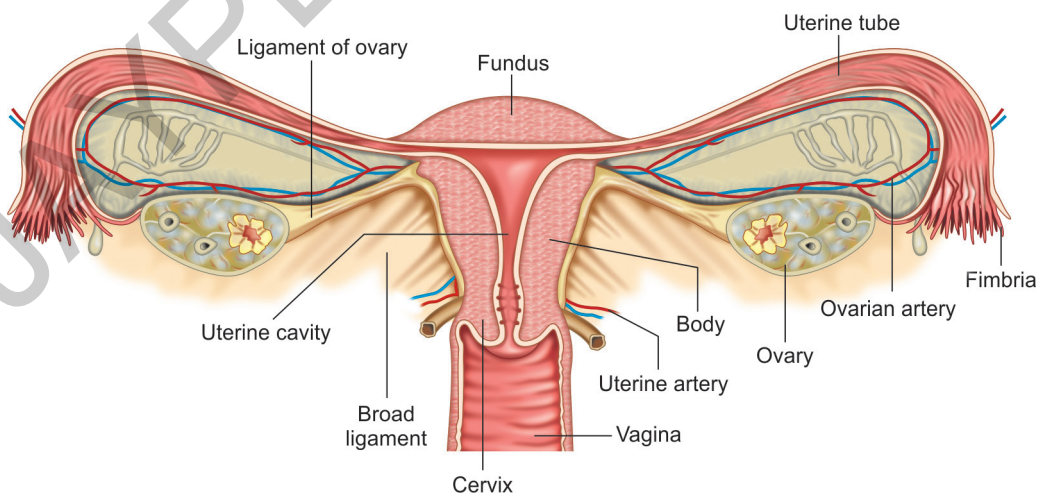

Fig. 10.8: Parts of female reproductive system.

JAYPEE BROTHERS

- Normally the long axis of uterus forms an angle of 90° with the vagina. This angle opens forwards and is called the angle of anteversion.
- The uterus is also slightly bended on itself at an angle of 120° called the angle of anteflexion.
- Superiorly, the uterus communicates on each side with the uterine tubes and inferiorly with the vagina.

Body of Uterus

The body has:

- A fundus which is the free upper end of the uterus. It is dome shaped and covered with peritoneum on all sides. Implantation takes place at the posterior wall of the fundus.
- The anterior surface is related to the urinary bladder and covered with peritoneum.
- The posterior surface is related to the coils of the small intestine and is also covered by peritoneum.
- There are two lateral borders which are related to a fold of peritoneum called the broad ligament. At the upper end is the attachment of the uterine tubes on either side.

Cervix of Uterus

- The cervix is cylindrical in shape and projects into the upper part of the vagina on its anterior wall. This divides the cervix into a supravaginal part and the vaginal part.
- The cavity of the cervix is called the cervical canal. It opens into the vagina at an opening called the external os. In a nulliparous woman, the os is small and circular but in a multiparous woman, it becomes oval.
- Similarly, the cavity of the body of the uterus communicates with the cervical canal at the internal os.

Ligaments of Uterus

Broad Ligament

- It is a large fold of peritoneum that lies on the lateral borders of the body of uterus.
- They attach the uterus to the lateral pelvic wall.
- Each broad ligament has two layers and covers the uterus like a sleeve.
- The superior border is free; the inferior and lateral borders are attached to the pelvic wall, the medial border is attached to the lateral border of uterus.
- Anterior surface and posterior surface become continuous at the superior border.
- **The broad ligament contains the following structures:**
  - Uterine tube
  - Round ligament of the uterus
  - Ligament of the ovary
  - Uterine vessels
  - Ovarian vessels
  - Nerve plexuses supplying the ovary, the uterus and the vagina.
  - Lymph nodes and lymph vessels
  - Dense connective tissue.

Round ligament of the uterus: It is a fibrous band that lies in the broad ligament below the attachment of the uterine tube. It passes through the deep inguinal ring, traverses the inguinal canal and ends in the labium majus. It keeps the fundus directed forwards and maintains the angle of anteversion.

JAYPEE BROTHERS

Transverse cervical ligaments: These are fan shaped condensations of the pelvic fascia on either side of the cervix. They connect the lateral wall of the cervix to the lateral pelvic wall and form a sling that supports the uterus.
Uterosacral ligaments: These are also condensations of the pelvic fascia that connect the cervix to the sacrum. They pull the cervix backwards. Thus, they balance the forward pull of round ligament.
Pubocervical ligaments: These are condensations of the pelvic fascia and connect the cervix to the posterior surface of pubis.

Blood Supply

Uterine artery and partly by the ovarian artery. The veins drain into the internal veins through the plexuses formed by uterine, ovarian and vaginal veins.

Lymphatic Drainage

The upper part of the uterus drains into the aortic group of lymph nodes. The rest of the uterus drains into the external iliac group of lymph nodes.

Nerve Supply

Uterus is supplied by the parasympathetic, S2,3,4 and sympathetic T12, L1 nerves.

Supports of Uterus (Fig. 10.9)

The uterus is a mobile organ that is prevented from sagging down by the following supports:

Primary Supports

Muscular

- **Pelvic diaphragm:** It is a muscular diaphragm that supports the pelvic organs and resists any increase in intra-abdominal pressure. Some of the fibers of the pubococcygeus part

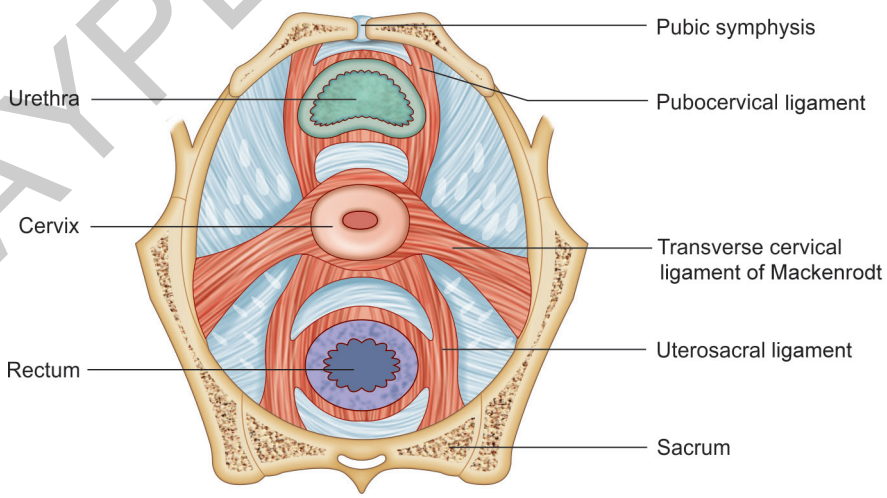

Fig. 10.9: Supports of uterus.

JAYPEE BROTHERS

of levator ani are inserted in the vagina and hence support the vagina and indirectly the uterus.

- **Perineal body:** It helps to support the pelvic diaphragm and hence indirectly supports the uterus.
- **Urogenital diaphragm:** A part of the diaphragm, i.e., the sphincter urethra muscle supports the vagina and hence supports the uterus.

Fibromuscular or mechanical

- **Uterine axis:** The anteverted position of the uterus prevents it from sagging down.
- **Pubocervical ligaments:** Support the cervix anteriorly.
- **Transverse cervical ligaments:** Support the cervix from the sides.
- **Uterosacral ligaments:** Support the cervix posteriorly.
- **Round ligament of uterus:** Keeps the uterus anteverted.

Secondary Supports

- Broad ligament
- **Uterovesical fold of peritoneum:** This fold lies between the uterus and the urinary bladder.
- **Rectovaginal fold of peritoneum:** This lies in between the rectum and the vagina. It is also called the pouch of Douglas.

Microscopic Structure (Figs. 10.10A and B)

The uterus is made up of three layers:

1. **Endometrium:** It is the innermost layer lined by simple columnar epithelium. The epithelium dips into the underlying connective tissue in the form of glands called the uterine glands. The endometrium is divided into an upper 2/3rd called the functional layer (it is shed off during menstruation) and the lower 1/3rd called the basal layer (it is retained during menstruation). The uterine glands become more coiled as the uterus reaches the secretory phase. The endometrium is richly supplied by blood vessels. They have thicker walls than elsewhere in the body and are called coiled arteries.
2. **Myometrium:** It is the middle layer. It is made up of smooth muscle bundles running in all directions and separated by connective tissue which has a rich supply of blood vessels.

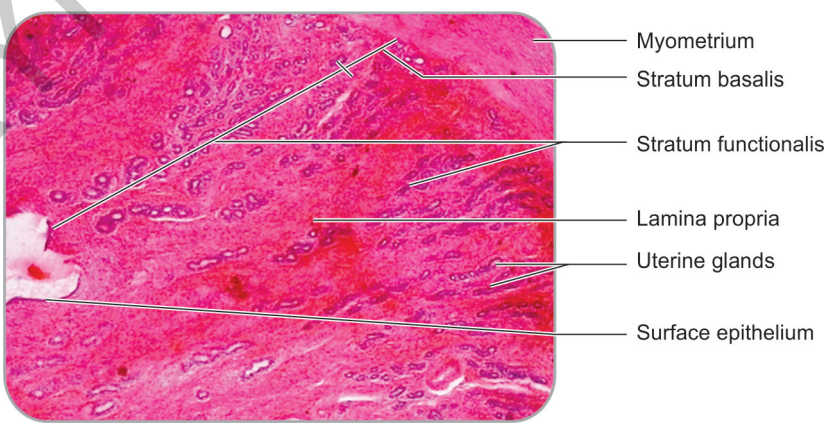

Fig. 10.10A: Photomicrograph of histology of uterus.

JAYPEE BROTHERS

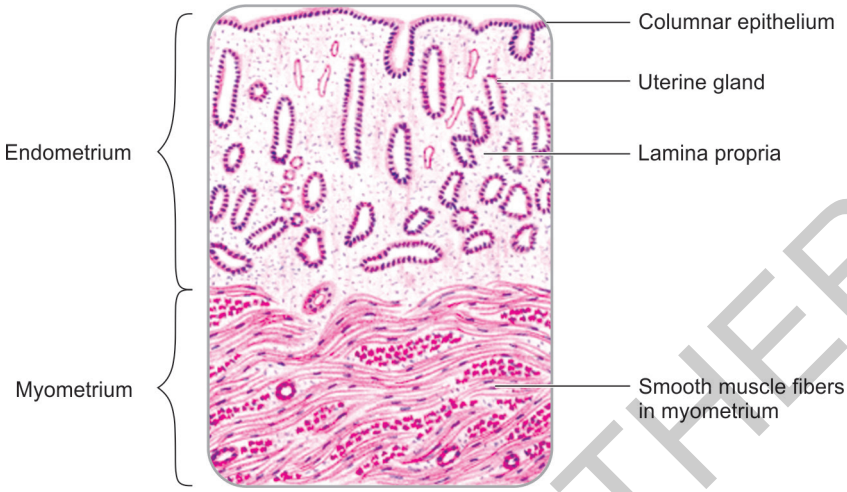

Fig. 10.10B: Diagrammatic representation of histology of uterus.

3. **Perimetrium:** It is the outermost layer of uterus made up of peritoneum and connective fibrous tissue.

Uterine Tubes/Fallopian Tubes

- These are ducts that convey ova from the ovary to the uterus.
- Spermatozoa introduced into the vagina travel through the uterus to the fallopian tubes. Fertilization normally takes place in the lateral part of the tube.

Parts of the Tube

- Each uterine tube is about 10 cm in length.
- The lateral end of the tube is shaped like a funnel and is called the infundibulum. It bears a number of finger-like processes called fimbria. One of them is the largest and is attached to the tubal pole of the ovary and is called the ovarian fimbria.
- At the lateral end, the uterine tube opens into the peritoneal cavity by its abdominal ostium.
- The part of the tube medial to the infundibulum is called the ampulla. It is thin walled and forms the lateral 2/3rd of the tube. Fertilization occurs here.
- The isthmus lies medial to the ampulla. It is thin, cord-like and forms the medial one third of the fallopian tube.
- The uterine part of the tube is 1 cm long and lies within the wall of the uterus. It opens in the uterine cavity by an ostium called the uterine ostium.

Blood Supply

The uterine artery supplies the medial two thirds, and the ovarian artery supplies the lateral one third of the fallopian tube. The veins run parallel with the arteries and drain into the pampiniform plexus of the ovary and into the uterine veins.

JAYPEE BROTHERS

Lymphatic Drainage

Most of the tube drains into the lateral aortic and the preaortic group of lymph nodes. The isthmus drains into the superficial inguinal group of lymph nodes.

Nerve Supply

The sympathetic nerves T10 to L2 are vasomotor and stimulate peristalsis. However, peristalsis is under mainly hormonal control. Parasympathetic S2, 3, 4 are vasodilator and inhibit peristalsis.

Microscopic Structure (Figs. 10.11A and B)

The fallopian tube has the following layers:

- **Epithelium:** It is lined by ciliated columnar epithelium thrown into many primary, secondary and tertiary folds.
- **Muscularis externa:** This is made up of smooth muscle arranged in two layers, inner circular and outer longitudinal.
- **Serosa:** Made up of fibrous tissue and mesothelium.

Vagina

- The vagina is a fibromuscular canal that is used for copulation.
- It extends from the vulva below to the uterus above and lies behind the bladder and urethra and in front of the rectum and anal canal.
- Its anterior and posterior walls are normally in contact except at its upper end where the cervix projects into the vagina. The cervix and the upper end of vagina are separated by a sulcus called fornix which is deep posteriorly.
- The fornix present on the posterior wall is related to the rectouterine pouch which is the most dependent part. The pus or blood tends to collect here. The fluid can be drained by inserting the needle into rectouterine pouch through the posterior fornix.

Mammary Gland

- Mammary gland is a modified sweat gland situated in the pectoral region.
- It is rudimentary in males. In females it starts enlarging at puberty.

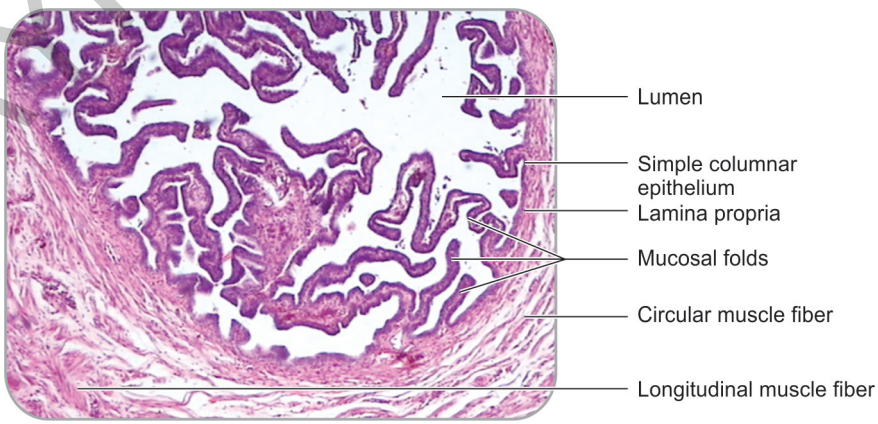

Fig. 10.11A: Photomicrograph of histology of uterine tube.

JAYPEE BROTHERS

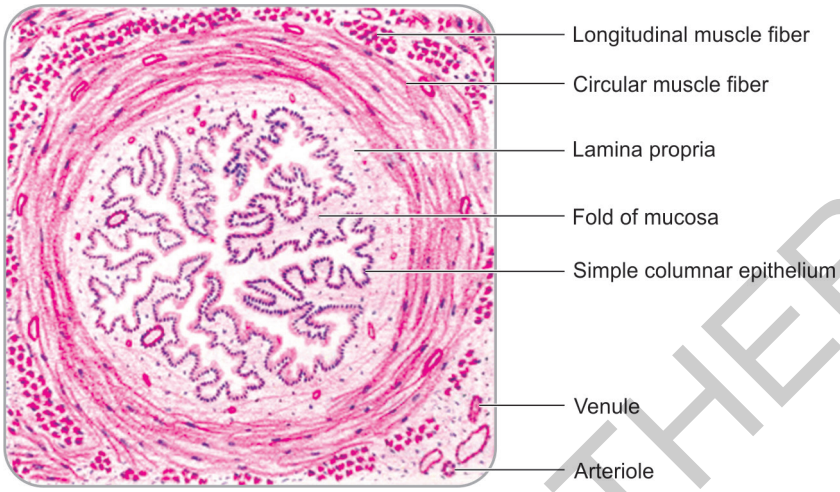

Fig. 10.11B: Diagrammatic representation of histology of uterine tube.

- It is conical in shape, extending from the lateral margin of the sternum to the midaxillary line transversely and from the 2nd to the 6th rib vertically.
- The gland rests on the pectoralis major which is covered by the pectoral fascia.

Structure

The gland is covered by the skin and shows a conical projection in the middle called the nipple. Surrounding the nipple is a circular area of skin called the areola which contains sebaceous glands.

Blood Supply

Lateral thoracic, internal thoracic and the 3rd, 4th and 5th intercostal arteries. The veins drain into the internal thoracic, axillary and intercostal veins.

Nerve Supply

Anterior and lateral cutaneous branches of the 3rd, 4th and 5th intercostal nerves.

Lymphatic Drainage

Lymphatics from the skin, except the nipple and areola, drain as follows:

- Lymphatics from outer upper and lower quadrants drain into anterior group of axillary lymph nodes and from there they reach the apical group of axillary lymph nodes. Some reach apical group of axillary lymph nodes directly and do not drain into anterior group.
- Lymphatics from upper medial quadrants drain into internal mammary group of lymph nodes of the same side. Some cross to the other side and drain into the internal mammary group of the opposite side.
- Lymphatics from lower medial quadrants drain into subperitoneal plexus of lymphatics. Lymphatics from parenchyma of the gland including nipple and areola drain into pectoral group of lymph nodes.

JAYPEE BROTHERS

Applied Anatomy

- Very common site for carcinoma. Removal of the gland is called mastectomy.
- Mastitis is inflammation of mammary gland.

Blood Supply

Vaginal branches of internal iliac and the uterine arteries. The veins drain into internal iliac veins.

Lymphatic Drainage

Upper 2/3rd: Internal and external iliac nodes; lower 1/3rd: Upper superficial inguinal nodes.

APPLIED ANATOMY

Male Reproductive System

Testes

- **Hydrocele:** Collection of fluid between visceral and parietal layer of processus vaginalis.
- **Hernia:** Abdominal contents may descend into testis if processus vaginalis is patent.
- **Varicocele:** Dilatation of pampiniform plexus.
- **Cryptorchidism:** Failure of descent of testes, lies in the abdominal cavity and is frequent site of carcinoma.
- **Ectopic testis:** Testis lies at an abnormal site deviating its normal path.

Prostate

- **Benign prostatic hyperplasia:** Enlargement of prostate.
- Carcinoma in prostate may spread to vertebral bodies due to the communication between prostatic venous plexus and vertebral venous plexus.
- **Prostatectomy:** Removal of prostate.

Female Reproductive System

Ovary

- **PCOD (polycystic ovarian disorder):** Obesity, irregular menstruation, acne, hirsutism.
- **Oophoritis:** Inflammation of ovary.
- **Krukenberg's syndrome (secondary ovarian cancer):** Cancer cells migrate from other tissues like breast.

Fallopian Tube

- **Tubectomy:** Fallopian tube cut between two ligated points.
- **Salpingitis:** Inflammation of the fallopian tube.
- Tubal implantation is the common type of ectopic pregnancy.

Uterus

- **Prolapse of uterus:** Uterus descends into vagina due to weakness of ligaments of uterus.
- **Myoma or fibroid:** Tumor in myometrium of uterus.
- **Hysterectomy:** Surgical removal of uterus.

JAYPEE BROTHERS

SUMMARY

Male Reproductive System

Testes

- **Parts:** Two poles (upper, lower), two borders (anterior, posterior), two surfaces (medial, lateral)
- **Epididymis:** Overlaps on lateral surface and connected to testis by efferent ductules
- **Coverings:** Tunica vaginalis, tunica albuginea, tunica vasculosa
- **Blood supply:** Arteries-testicular artery, veins-pampiniform plexus of veins → testicular vein
- **Nerve supply:** Sympathetic—renal and aortic plexus from T10 and T11 spinal segments.

Prostate

- Accessory gland, secretions add to seminal fluid
- **Components:** Glandular tissue, fibromuscular stroma
- **Parts:** Apex, base, surfaces (anterior, posterior, two inferolateral)
- **Lobes:** Anterior, posterior, median, right and left lateral
- **Coverings:** False capsule, true capsule and venous plexus between two
- **Structures within prostate:** Urethra, prostatic utricle, two ejaculatory ducts
- **Blood supply:** Arteries-inferior vesical, middle rectal, internal pudendal; veins-prostatic venous plexus
- **Nerve supply:** Sympathetic—L3, L4, L5 spinal segments; parasympathetic—upper sacral spinal segments.

Female Reproductive System

Ovaries

- **Situation:** Ovarian fossa on lateral pelvic wall.
- **Parts:** Two poles (upper and lower in nulliparous woman, lateral and medial in multiparous woman), two borders (anterior/mesovariam, posterior/free), two surfaces (lateral, medial).
- **Blood supply:** Arteries-ovarian artery, uterine artery; veins-ovarian vein.
- **Nerve supply:** Sympathetic—T10, T11 spinal segments; parasympathetic—S2, S3, S4 spinal segments.

Uterus

- Muscular organ which protects and nourishes the embryo.
- **Parts:** Fundus, body, cervix.
- **Anteversion:** Long axis of uterus forms an angle of 90° with long axis of vagina.
- **Anteflexion:** Long axis of body of uterus forms an angle of 120° with long axis of cervix.
- **Ligaments:** Broad ligament, round ligament of uterus, transverse cervical ligament, uterosacral ligament, pubocervical ligament.
- **Supports of uterus:** Primary supports-muscular (pelvic diaphragm, perineal body, urogenital diaphragm), fibromuscular/mechanical (uterine axis, pubocervical ligaments, transverse cervical ligaments, uterosacral ligaments, round ligament of uterus); secondary supports-broad ligament, uterovesical fold of peritoneum, rectovaginal fold of peritoneum.
- **Blood supply:** Arteries-uterine artery, ovarian artery; veins-uterine, ovarian, vaginal veins
- **Nerve supply:** Sympathetic—T12, L1 spinal segments; parasympathetic—S2, S3, S4 spinal segments

Uterine Tube

- **Pair of ducts:** Convey ova from the ovary to uterus.
- **Parts:** Fimbria, infundibulum, ampulla, isthmus, uterine part.
- **Blood supply:** Arteries-uterine artery, ovarian artery; veins-pampiniform plexus of ovary, uterine vein.
- **Nerve supply:** Sympathetic-T10 to L2 spinal segments; parasympathetic—S2, S3, S4 spinal segments.

JAYPEE BROTHERS

QUESTIONS

MALE REPRODUCTIVE SYSTEM

Long Essay

Name the parts of male genital system and describe the testis.

Short Essays

- Male urethra
- Testis—gross anatomy
- Testis—histology.

Short Answers

- Name the coverings of testis
- Components of male reproductive system
- Structure of testis
- Contents of spermatic cord
- Name accessory male reproductive organs
- Prostatic urethra
- Parts of epididymis and its lining epithelium
- Vasectomy
- Vas deferens—origin and termination
- Prostate—importance
- Prostate—histology.

FEMALE REPRODUCTIVE SYSTEM

Long Essays

- **Name the parts of female reproductive system. Describe the anatomy of uterus.**
- **Name the organs of female reproductive system. Describe the ovary.**

Short Essays

- **Microscopic structure of ovary**
- **Microscopic structure of uterus**
- **Microscopic structure of fallopian tube**
- **Graafian follicle**
- **Mammary glands**
- **Ligaments of uterus**
- **Fallopian tube**
- **Lymphatic drainage of breast.**

Short Answers

- **Name the parts of uterus giving function of each part.**
- **Name the parts of fallopian tubes and lining epithelium. Which is the widest part?**
- **Position of uterus in the body**
- **Where does fertilization occur?**

JAFFE BROTHERS

for detailed information on anatomy books, visit our website www.ejaypee.com, for detailed information on anatomy books, visit our website www.ejaypee.com, for detailed information on

HUMAN ANATOMY
for Allied and Healthcare Sciences

Salient Features

- The new edition of the book has been revised to provide a better understanding of the subject of anatomy to allied and healthcare courses.
- The diagrams are easier to learn and reproduce during examinations.
- A chapter for Physiotherapy students has been added to know why they need to study anatomy and in what context.
- Histology photomicrographs have been added to the chapters.
- This book hopes to make students better.

Priya Ranganath MBBS MS (Anatomy) is Professor and Head, Department of Anatomy, Bangalore Medical College and Research Institute, Bengaluru, Karnataka, India. She has completed her MBBS from Thanjavur Medical College, Thanjavur, and MS in Anatomy from MS Ramaiah Medical College, Bengaluru. She has numerous state, national, and international publications in areas such as gross anatomy, histology, anthropometric studies, genetics, dermatoglyphics, and medical education. In addition to her teaching responsibilities, she also handles administrative duties and oversees the genetic laboratory in the hospital. She is actively involved in exam duties as well.

Leelavathy N MSc (Anatomy) PhD has started her career in 1995 at St John's Medical College, Bengaluru, Karnataka, India. Presently, she is working as Professor in East Point College of Medical Sciences and Research Center, Bengaluru. Her fields of interest are anatomy, plastination, and genetics. She has received SS Misra Memorial Award for best unpublished work titled "Genetic Studies in Patients with Primary Amenorrhea" from NAMS. She has publications in state, national, and international peer-reviewed journals and co-authored books in histology and genetics.

Shelving Recommendation
ANATOMY

ISBN 978-93-6616-849-4

9 789366 168494

Buy from ejaypee

JAYPEE BROTHERS