s, visit our website www.jaypeebrothers.com, for detailed information on dental books, visit our website www.jaypeebrothers.com, for detailed information on dental books

Complimentary Online Student Resource MCQs Only with Genuine Book

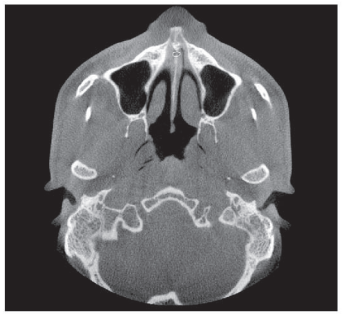



Essentials of Oral and Maxillofacial Radiology

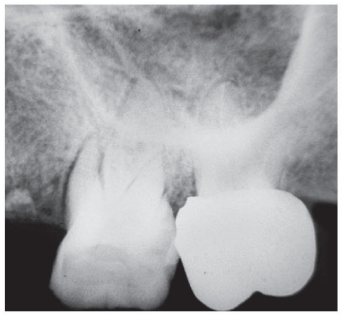
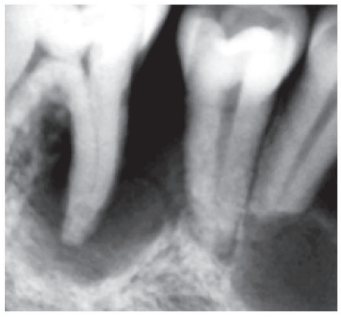
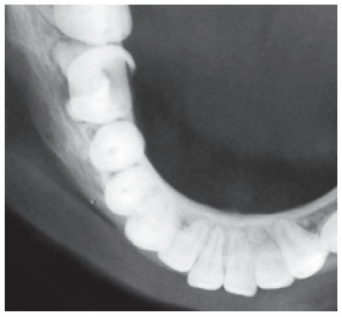


Freny R Karjodkar

3rd Edition

JAYPEE

Contents

Section 1: Introduction

1. History of Dental Radiography 3

Discovery of X-rays 3; X-ray Films 5; Growth of Dental Radiology 6; Maxillofacial Radiology: History and Current Status 8; Indian Scenario 8; Highlights in the History of Dental Radiology 8

Section 2: Physics of Ionizing Radiation

2. Radiation Physics 13

Basic Considerations 13; Electromagnetic Spectrum 14; Dental Applications of Lasers 17

3. Properties of X-rays 18

Definition 18; Physical Properties 18; Chemical Properties 22; Biological Properties 22; Physiochemical Properties 22; Properties of X-rays Which are Useful for Diagnostic Imaging 23; Uses of X-rays 23

4. Production of X-rays 24

Dental X-ray Machine 24; Production of Dental X-rays 30; Types of X-rays Produced 30; Quality Control 31

Section 3: Radiation and Health Physics

5. Radiation Biology 35

Radiation Effects 35; Somatic Deterministic Effect 35; Somatic Stochastic Effect 35; Genetic Stochastic Effect 35; Action Theory of Biological Tissues 35
Modifying Factors 38; Radiosensitivity 39; General Effects of Radiation 40; Radiotherapy 42; Radiobiology 45

6. Protection From Radiation 47

Radiation Protection 47; Protection in General 48; Means of Protection in the Working Areas 50; Sources of Radiation in A Dental Radiology Department 50; Quality Assurance 56; Continuing Education 58

Section 4: Imaging Principles

7. Ideal Radiographs 63

Visual Characteristics 63; Geometric Characteristics 67; Anatomical Accuracy 71; Radiographic Coverage 71; Peripheral Eggshell Effect 71

8. Radiographic Prescription 74

Guiding Principles for Radiographic Prescription 75; Informed Consent 75; Justification and Referral Criteria 76; Radiographic Examinations 81;

9. Faulty Radiographs 86

Projection Errors 86; Exposure and Processing Errors 93; Automatic Processing Errors 100; Miscellaneous Technique Errors 102

10. X-ray Films and Accessories 104

Composition of the X-ray Film 105; Intraoral Films 106; Film Holders 107; Extraoral Films 108; Grids 112; Filtration 114; Collimation 115; Film Illuminator 115

11. Processing **117**

Latent Image 117; Film Processing 118; Film Processing Solutions 119;
Point to Remember During Developing and Fixing Process 121; The Darkroom 121;
Different Methods of Processing 124; Management of Radiographic Wastes 131

Section 5: Imaging Techniques

12. Intraoral Radiographic Techniques **135**

Periapical Radiography 136; Paralleling Technique 137; Angle-Bisecting Technique 145;
Special Considerations 153; Extraoral Periapical Technique 154; Bitewing Radiography 156;
Occlusal Radiography (Sandwich Radiography) 158; Intraoral Localization Techniques 160

13. Extraoral Radiographs and Other Specialized Imaging Techniques **166**

Extraoral Radiographic Techniques Indications and Drawbacks 166;
Modified Method, Inclined Posteroanterior (Caldwell) Projection 168;
Posteroanterior Water's View 169; Posteroanterior Mandible 170;
Rotated Posteroanterior Mandible 170; Lateral Oblique 171;
Submentovertex (Base) Projection 174;
Jug Handle View (A Modification of the Submentovertex View) 174; Transcranial Projection 175;
Transpharyngeal Projection (Infracranial or Mcqueen Dell Technique) 175;
Transorbital Projection (Zimmer Projection) 177; Reverse Towne's Projection 178;
Lateral Cephalogram 178; True Lateral 179; Posteroanterior Cephalogram 180;
Posteroanterior Skull 181; Towne's Projection 181; Other Specialized Imaging Techniques 182

14. Panoramic Radiography **200**

Principle 201; Focal Trough or Image Layer 201; Rotation Center 201; Equipment 202;
Procedure 202; Common Errors 203; Clinical Indications 207; Interpreting the Panoramic Image 208;
Bony Landmarks of the Maxilla and Surrounding Structures 209;
Bony Landmarks of the Mandible and Surrounding Structures 210;
Airspace Images Seen on Panoramic Radiograph 212;
Soft Tissue Images Seen on Panoramic Radiograph 212;
Impacted Third Molars Classification on Radiograph Position and Panoramic Markers 212

15. Cone-Beam Computed Tomography **220**

Acquisition Configuration 221; Image Detection 225; Image Reconstruction 226;
Image Display 227; Advantages of Cone-beam Computed Tomography 231;
Limitations of Cone-beam Computed Tomography Imaging 235; Quality Assurance Program 238;
Clinical Applications of Cone-beam Computed Tomography 238;
Normal Landmarks as Seen on CBCT 246; Image-guided Surgery 253; Rapid Prototyping 253;
Orthodontic Planning 253; Maxillofacial Surgery Studies 254; Sleep Apnea Airway Imaging 255;
Temporomandibular Joint Studies 255; Implant Dentistry Software Applications 255;
Dental Pacs Cloud Based Image Management System 256

16. Digital Radiography **258**

Digital Imaging Fundamentals 258; Radiation Exposure 259; Equipment 259;
Digital Detector Characteristics 259; Digital Image Sensors Or Receptors 260; Image Output 264

Section 6: Radiographic Diagnosis of Pathology Affecting the Jaws

17. Normal Anatomy on Intraoral and Extraoral Radiographs and Basics in Interpreting Radiographs **269**

Radiopaque Structures 269; Radiolucent Structures 270; Anatomical Landmarks in Maxilla 272;
Anatomical Landmarks in Mandible 278; Basics in Interpreting Radiographs 284;
Systemic Sequence for Viewing a Dental Panoramic Radiograph 285

18. Dental Caries **294**

Radiographic Differential Diagnosis of Dental Caries 299;
Limitations of Radiographic Diagnosis of Caries 301

19. Periodontal Diseases **305**

Limitations of Radiographs 306; Radiographs for Detection of Periodontal Diseases 306;
Normal Anatomy 306; Classification of Inflammatory Periodontal Diseases 308;
Acute and Chronic Gingivitis 309; Periodontitis 309; Other Periodontal Pathologies 311;
Evaluation of Periodontal Therapy 313; Differential Diagnosis 313;
Effect of Systemic Diseases on Periodontal Disease 314

20. Dental Anomalies and Developmental Disturbances of the Jaws **316**

Developmental Anomalies of the Teeth 318; Acquired Anomalies of the Teeth 336;
Developmental Disturbances of the Jaws 343

21. Infections and Inflammatory Lesions and Systemic Diseases Affecting the Jaws **354**

Infections of Periapical Tissues 355; Acute Infections of Periapical Tissues 355;
Chronic Infections of Periapical Tissues 359; Osteomyelitis 364; Specific Chronic Infections of the Jaws 374;
Bisphosphonate-related Osteonecrosis of the Jaws 375; Pericoronal Infections 375;
Systemic Diseases Affecting the Jaws 376; Endocrinal Disorders 377;
Metabolic Bone Diseases Due to Nutritional Deficiency 387; Blood Disorders 394

22. Cysts of Jaws **400**

Classification of Cysts of the Oral Cavity 400; General Characteristics 400; General Symptoms 401;
General Radiographic Features 402; Odontogenic Developmental Cysts 403;
Odontogenic Inflammatory Cysts 415; Nonodontogenic Cysts 420;
Cysts of the Soft Tissues of the Face and Neck 425; Pseudo Bone Cysts 425

23. Benign Tumors of the Jaws **431**

Odontogenic Tumors 435

Classification of Benign Tumors of the Jaws 431; Odontogenic Epithelial Tumors 435;
Odontogenic Mesenchymal Tumors (Odontogenic Ectomesenchyme) 445;
Mixed Tumors of Odontogenic Epithelium and Odontogenic Ectomesenchyme 457

Nonodontogenic Tumors 464

Torus Palatinus (Palatine Torus) 464; Torus Mandibularis (Mandibular Torus) 465;
Exostosis (Hyperostosis) 465; Enostosis (Dense Bone Island, Periapical Idiopathic Osteosclerosis,
Bone Eburnation, Bone Whorl, Bone Scar, Focal Periapical Osteopetrosis) 466;
Desmoplastic Fibroma of the Bone (Aggressive Fibromatosis) 467;
Chondroma 468; Chondroblastoma (Codman's Tumor) 468; Osteoma 468;
Gardner's Syndrome (Familial Adenomatous Polyposis) 471; Osteoid Osteoma 471;
Osteoblastoma (Giant Osteoid Osteoma) 472; Osteochondroma 472; Hemangioma (Vascular Nevus) 473;
Arteriovenous Fistula (A-V Defect, A-V Shunt, A-V Aneurysm, A-V Malformation) 475;
Neurilemmoma (Schwannoma, Perineural Fibroblastoma, Neurinoma) 476;
Neuroma (Amputation Neuroma, Traumatic Neuroma) 477; Neurofibroma (Neurinoma) 477;
Neurofibromatosis (Von Recklinghausen's Disease) 478;
Melanotic Neuroectodermal Tumor of Infancy (Pigmented Ameloblastoma, Melano-Ameloblastoma,
Retinal Anlage Tumor, Melanotic Progonoma) 478; Giant Cell Tumor 479; Giant Cell Granuloma 479;
Peripheral Giant Cell Granuloma (Giant Cell Epulis, Osteoclastoma) 479;
Central Giant Cell Granuloma (Osteoclastoma, Myeloid Sarcoma, Chronic Hemorrhagic Osteomyelitis,
Giant Cell Reparative Granuloma, Giant Cell Tumor) 480; Reparative Giant Cell Granuloma 483;
Giant Cell Tumor of Hyperparathyroidism 484

24. Malignant Diseases of the Jaws **485**

Classification of Malignant Tumors of the Jaws 485; Malignant Ameloblastoma 487;
Squamous Cell Carcinoma 488; Clear Cell Odontogenic Tumor or Carcinoma 494;
Metastatic Carcinoma (Metastatic Tumor, Secondary Malignancies) 495; Malignant Melanoma 497;

Fibrosarcoma 497; Malignant Fibrous Histiocytoma (Malignant Fibroxanthoma) 498;
Chondrosarcoma (Chondrogenic Sarcoma) 499; Osteosarcoma (Osteogenic Sarcoma) 500;
Ewing's Sarcoma (Endothelial Myeloma, Round Cell Sarcoma) 504;
Neurofibrosarcoma (Malignant Schwannoma) 504; Malignant Lymphoma 505;
Diagnostic AIDS in Oral Cancer 511

25. Diseases of Bone Manifested in the Jaws **517**

Fibro-Osseous Diseases of the Jaws 517

Fibrous Dysplasia 517; Juvenile Ossifying Fibroma (Ossifying Fibroma, Aggressive Ossifying Fibroma,
Trabecular Demosteoblastoma, Cementifying Fibroma, Cemented Ossifying Fibroma) 528;
Cherubism (Familial Fibrous Dysplasia of the Jaws, Disseminated Juvenile Fibrous Dysplasia,
Familial Multilocular Cystic Disease of the Jaws, Hereditary Fibrous Dysplasia of the Jaws) 528;
Central Giant Cell Granuloma (Osteoclastoma, Myeloid Sarcoma, Chronic Hemorrhagic Osteomyelitis,
Giant Cell Reparative Granuloma, Giant Cell Tumor, Giant Cell Lesion) 530;
Paget's Disease (Osteitis Deformans) 531; Periapical Cemental Dysplasia
(Cementoma, Fibrocementoma, Sclerosing Cementum, Periapical Osteofibrosis,
Periapical Fibrosarcoma, Periapical Fibrous Dysplasia, Periapical Fibrosteoma) 534;
Florid Osseous Dysplasia (Gigantiform Cementoma, Florid Cemeto-Osseous Dysplasia,
Familial Multiple Cementomas, Chronic Sclerosing Osteomyelitis, Sclerosing Osteitis,
Multiple Enostosis, Sclerotic Cemental Masses) 534;
Ossifying Fibroma (Cemento-Ossifying Fibroma, Cementifying Fibroma) 534; Other Bone Lesions 534;
Osteoporosis 534; Infantile Cortical Hyperostosis (Caffey's Disease, Caffey-Silverman Syndrome) 536;
Osteopetrosis (Albers-Schönberg, Marble Bone Disease, Osteosclerosis Fragilis Generalisata) 537;
Osteogenesis Imperfecta (Brittle Bone, Lobstein Disease) 538; Leontiasis Ossea 538;
Progressive Systemic Sclerosis (Scleroderma) 539; Pierre Robin Syndrome (Robin Anomalad) 539;
Marfan's Syndrome (Marfan-Achard Syndrome, Arachnodactyly) 540; Down Syndrome 540;
Achondroplasia (Chondrodystrophia Fetalis) 540; Skeletal Fluorosis (Fluoride Toxicity) 541;
Generalized Cortical Hyperostosis (Van Buchem Disease) 541;
Massive Osteolysis (Vanishing Bone, Disappearing Bone, Phantom Bone, Progressive Osteolysis,
Gorham-Stout Syndrome, Idiopathic Osteolysis) 542

26. Temporomandibular Joint Disorders **543**

Normal Radiographic Appearance of the Temporomandibular Joint 547; Diagnostic Imaging 548;
Developmental Disorders of the Temporomandibular Joint 557; Remodeling and Arthritic Conditions 565;
Degenerative Joint Disease 565; Inflammatory Joint Disorders 568; Articular Loose Bodies 571;
Metabolic Disorders 572; Traumatic Disorder of the Temporomandibular Joint 573; Fracture 575;
Neoplastic Conditions 581; Neuropathic Disorders 584

27. Disorders of the Maxillary Sinus **589**

Functions 589; Anatomy of the Maxillary Sinus (Maxillary Antra or Antrum of Highmore) 589;
Intrinsic Diseases Involving the Maxillary Sinus 593; Inflammatory Disease 593; Cyst 598;
Calcifications 600; Benign Neoplasms 600; Malignant Neoplasms 601;
Extrinsic Diseases Involving the Maxillary Sinus 603; Benign Odontogenic Cysts and Tumors 603;
Other Diseases 606; Traumatic Injuries to Maxillary Sinuses 608

28. Soft Tissue Calcifications and Ossifications **613**

General Clinical Features 614; General Radiographic Features 614; Dystrophic Calcifications 614;
Idiopathic Calcification (or Calcinosis) 617; Metastatic Calcification 622;
Aberrant Calcifications in the Orofacial Region 625

29. Trauma to Teeth and Facial Structures **627**

Classification of Trauma to the Teeth and Facial Structures 627

Traumatic Injury to the Soft Tissue 627; Traumatic Injury to the Teeth 629;
Traumatic Injury to the Maxilla 637; Traumatic Injury to the Mandible 648;
Radiographic Differential Diagnosis of Fractures of Mandible 656;

30. Salivary Gland Disorders **660**

Parotid Gland 660; Submandibular Gland 661; Sublingual Gland 661;
Differential Diagnosis of Salivary Gland Enlargements 661;
Applied Diagnostic Imaging of the Salivary Glands 662; Salivary Gland Disorders 672

Section 7: Role of Maxillofacial Radiology in Specialized Dental Fields

31. Implant Radiology **689**

Preprosthetic Implant Imaging 689; Surgical and Interventional Implant Imaging 690;
Postprosthetic Implant Imaging 690; Imaging Modalities 691

32. Role of Dental Radiology in Forensic Odontology 716

Methods of Identification 717; Radiography of Postmortem Material 717;
Radiographic Views 719; Comparison Radiography 723

Case Reports *749*

Index *791*

13 CHAPTER

Extraoral Radiographs and Other Specialized Imaging Techniques

Science is the process that takes us from confusion to understanding...

—Brian Greene

Learning Objectives

- Extraoral Radiographic Techniques-Indications and Drawbacks
- Modified Method, Inclined Posteroanterior (Caldwell) Projection
- Posteroanterior Water's View
- Posteroanterior Mandible
- Rotated Posteroanterior Mandible
- Lateral Oblique
- Submentovertex (Base) Projection
- Jug Handle View (A Modification of the Submentovertex View)
- Transcranial Projection
- Transpharyngeal Projection (Infracranial or Mcqueen Dell Technique)
- Transorbital Projection (Zimmer Projection)
- Reverse Towne's Projection
- Lateral Cephalogram
- True Lateral
- Posteroanterior Cephalogram
- Posteroanterior Skull
- Towne's Projection
- Other Specialized Imaging Techniques

EXTRAORAL RADIOGRAPHIC TECHNIQUES INDICATIONS AND DRAWBACKS

These techniques imply that the film is placed outside the oral cavity, against the side of the face to be radiographed and the X-ray beam is directed towards it.

Indications

- When it is not possible to place the film intraorally as during trismus.
- To examine the extent of large lesions, especially when the area of pathology is greater than which can be covered by an intraoral periapical film.
- When jaws or other facial bones have to be examined for evidence of disease lesions and other pathological conditions.
- To evaluate skeletal growth and development.
- To evaluate the status of impacted teeth.
- To evaluate trauma.
- To evaluate temporomandibular joint area.

Drawbacks

- Magnification occurs due to the greater object to film distance used.
- Details are not well-defined due to the use of cassettes and intensifying screens. For optimum balance between loss of image detail and reduction of patient exposure medium or high speed screen film combinations should be used.
- Contrast is reduced as the secondary radiation produced by the soft tissues is more.
- An important aspect of the extraoral radiography techniques is the immobilization of the patient's head.

JAYPEE BROTHERS

This is achieved by the use of various devices like, compression bands, head clamps, craniostat.

Some Extraoral Landmarks used for Patient Positioning (Figs. 13.1A and B)

- The median plane of the head (midsagittal plane).
- The infraorbital line.
- The orbitomeatal line (canthomeatal line).
- The Frankfort horizontal line.

Important Parameters

- The film focus distance is of paramount importance. An increase in the focus film distance will improve the image sharpness, but adequate collimation must be used to prevent scattered radiation.
- Most of the techniques for skull radiography use a film focus distance of approximately 3′ (90 cm), in cephalometry a distance of 5–6′ (150–180 cm) is used.
- *The centering point*: The direction and angle of the central ray of the X-ray beam play an important and fundamental part in the clarity of the resultant shadow and the presence of distortion. The central beam should be so directed as to pass or project away from the dense structures which would overshadow the required details.

Required Equipment

- X-ray unit
  - Intraoral X-ray machine
  - Extraoral X-ray machine
  - Panoramic X-ray unit
  - Cephalometry X-ray unit
  - Cone-beam computed tomography unit.
- Films
  - Extraoral non-screen films
  - Extraoral screen films.
    - Sensitive to blue light
    - Sensitive to green light
  - Panoramic films.

Cephalometric and skull views require at least 20 × 25 cm (8 × 10 inch) image receptor whereas oblique lateral projections of the mandible can be obtained with 13 × 18 cm (5 × 7 inch) image receptor.

- Intensifying screens
  - Blue light
  - Green light
- Film cassettes [conventional/Imaging Plate (IP)]
- Grid.

Procedure

- Equipment preparation:
  - Load the extraoral cassette in the darkroom under safe-light conditions. Place one extraoral film between two intensifying screens and securely close the cassette.
  - For digital processing:
    - An IP cassette, make sure that the cassette has been read and cleared in the CR system.
    - For DR system the sensor has to be readied.
  - Set the exposure factors (kilo voltage, milliamperage, time) according to the manufacturer's recommendations.
  - Load the cassette into the cassette carrier.
  - Print in the date, patient's name, age, sex and the case number.

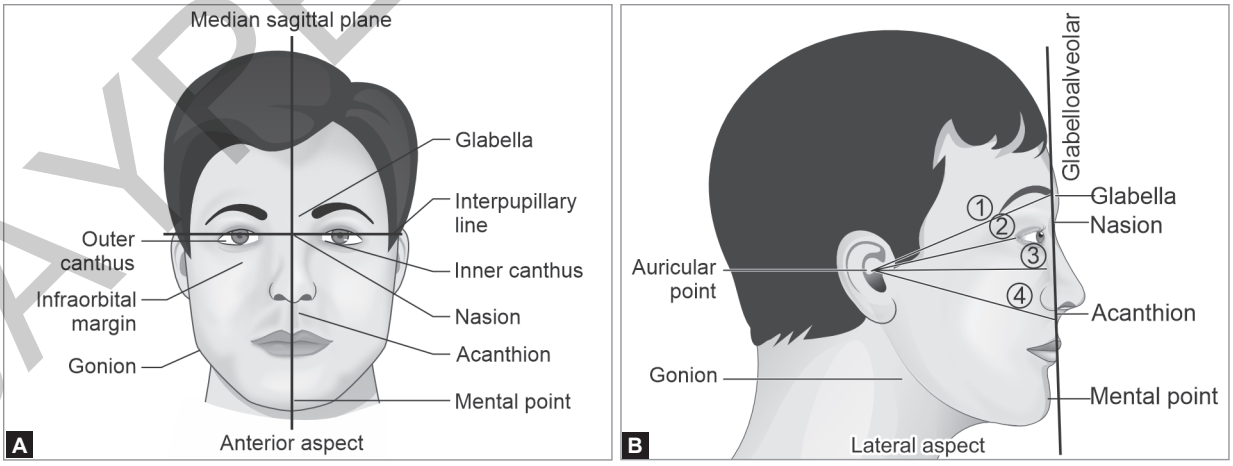

Figs. 13.1A and B: Diagram showing external guideline used for patient positioning: 1. Glabellomeatal line; 2. Orbitomeatal line; 3. Inframeatal line; 4. Acanthomeatal line.

JAYPEE BROTHERS

- Patient preparation:
  - Explain to the patient the radiographic procedure about to be performed.
  - Place a lead apron without a lead collar over the patient and secure it. A double sided apron is recommended. The apron must be placed low around the back of the neck so that it does not block the X-ray beam. A thyroid collar is not recommended for extraoral radiography because it blocks part of the beam and obscures important diagnostic information.
  - Remove all objects from the head and neck region that may interfere with film exposure. The patient must remove eyeglasses, earrings, necklaces, napkin chains, hearing aids, hairpins and complete or partial removable dentures or any other removable appliance in the oral cavity.

Most Commonly used views for Maxillofacial Imaging

- Radiography of paranasal sinuses:
  - Posteroanterior projection (also known as occipitofrontal projection of nasal sinuses). There are two methods for obtaining this projection:
    - Posterior-anterior (Granger projection).
    - Modified method, inclined posterior-anterior (Caldwell projection).
- Radiography of the maxillary sinuses:
  - Standard occipitomental projection (0° occipitomental projection)
  - Modified method (30° occipitomental projection)
  - Bregma-menton
  - PA Water's view
- Radiography of the mandible:
  - PA mandible
  - Rotated PA mandible
  - Lateral oblique:
    - Anterior body of mandible
    - Posterior body of mandible
    - Ramus of mandible
- Radiography of base of the skull:
  - Submentovertex projection
- Radiography of the zygomatic arches:
  - Jug handle view (a modification of submentovertex view)
- Radiography of the temporomandibular joint:
  - Transcranial projection
  - Transpharyngeal projection
  - Transorbital projection
  - Reverse Towne's projection
- Radiography of the skull
  - Lateral cephalogram
  - True lateral
  - PA cephalogram
  - PA skull
  - Towne's projection.

MODIFIED METHOD, INCLINED POSTEROANTERIOR (CALDWELL) PROJECTION (FIGS. 13.2A AND B)

Structures Shown

This angulation will cause the petrous ridges to be superimposed on the maxillary sinuses, thus allowing more accurate examination of the orbits and ethmoidal air cells.

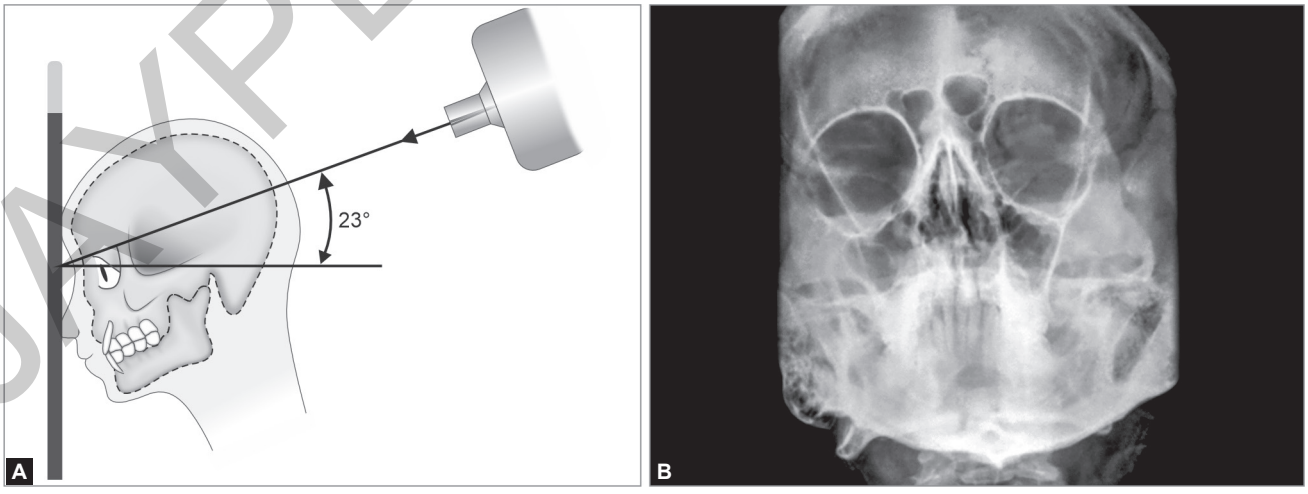

Figs. 13.2A and B: (A) Diagram of the positioning inclined posteroanterior (Caldwell) projection; (B) Caldwell projection.

JAYPEE BROTHERS

Film Placement

The cassette is placed perpendicular to the floor in a cassette holding device. The long axis of the cassette is positioned vertically.

Position of Patient

- The midsagittal plane is vertical and perpendicular to the cassette.
- Only the forehead and nose touch the cassette, so that the canthomeatal line is perpendicular to the cassette. On the resultant radiograph the superior border of the petrous ridge is projected in the lower-third of the orbit.

Central Ray

It is directed 23° to the canthomeatal line, entering the skull about 3 cm above the external occipital protuberance and exiting at the glabella.

Exposure Parameters

- Using extraoral machine
- kVp—70–80
- mA—60–50, seconds—1.6 (Bucky grid).

POSTEROANTERIOR WATER'S VIEW (FIGS. 13.3A AND B)

Structures Shown

- This projection is primarily used to demonstrate the maxillary sinus, frontal and ethmoidal sinuses.
- The sphenoidal sinuses can be seen if the patient is asked to open his mouth, whereby the sphenoidal sinuses are projected on the palate. The orbit, frontozygomatic suture, nasal cavity, coronoid process of the mandible and the zygomatic arch are also seen.

Film Placement

The cassette is placed perpendicular to the floor in a cassette-holding device. The long axis of the cassette is positioned vertically.

Position of Patient

- The midsagittal plane should be vertical and perpendicular to the plane of the film.
  - The patient's head is extended so that only the chin touches the cassette.
  - The cassette is centered round the acanthion (anterior nasal spine).
  - The canthomeatal line should be at 37° to the plane of the film and the line from the external auditory meatus to the mental protuberance should be perpendicular to the film.
  - In this position the aim is to extend the patient's head just enough so as to place the dense shadows of the petrosae immediately below the antral floors. When the head is extended too little, the petrosal shadows are projected onto the lower part of the antrum.
  - When the head is extended too much the antral shadows are foreshortened and results in failure to show the antral floor.
  - Water's (1915) specified that the tip of the nose should be 0.5–1.5 cm away from the cassette and Mahoney (1930)

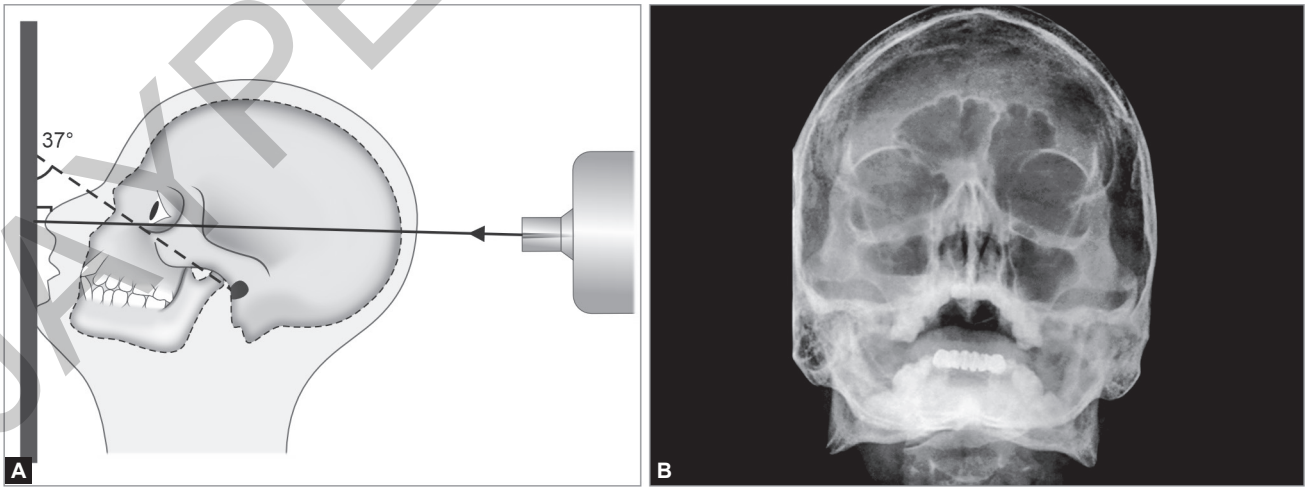

Figs. 13.3A and B: (A) Diagram for the positioning of posteroanterior Water's projection, the radiographic base line is at 37° to the film, and the X-ray is perpendicular to the film; (B) Posteroanterior Water's view.

JAYPEE BROTHERS

found that the petrosal shadows can be correctly placed by adjusting the orbitomeatal line at 37° to the horizontal.
- An easy visual method is that a line extending from the external auditory meatus to the mental protuberance of the chin should be perpendicular to the cassette.

Central Ray

Central ray is directed perpendicular and to the midpoint of the film. It enters from the vertex and exits from the acanthion.

Exposure Parameters

- Using extraoral machine
- kVp—70–80
- mA—60–50, seconds—1.6 (Bucky grid).

POSTEROANTERIOR MANDIBLE (FIGS. 13.4A AND B)

Structures Shown

- A posteroanterior (PA) projection of the mandibular body and the ramus. The symphysis region is not well seen because of the superimposition of the spine.
- It is used to study fractures of the posterior third of the body of the mandible, angles, rami and lower condylar necks, mediolateral expansion of the posterior third of the body or the rami in case of tumors or cystic lesions, maxillofacial deformities and mandibular hypoplasia or hyperplasia.

Film Placement

The cassette is placed perpendicular to the floor in a cassette holding device. The long axis of the cassette is positioned vertically.

Position of Patient

- The sagittal plane should be vertical and perpendicular to the film.
- The head is tipped downwards so that the forehead and nose touch the film. The radiographic base line is horizontal and perpendicular to the film.
- The film is adjusted so that the lips are centered to the film.

Central Ray

It is directed at right angles to the film through the midsagittal plane through the cervical spine, at the level of the angles of the mandible.

Exposure Parameters

- Using extraoral machine
- kVp—65–80
- mA—60–80, seconds—1.6 (Bucky grid).

ROTATED POSTEROANTERIOR MANDIBLE (FIGS. 13.5A AND B)

Structures Shown

This projection is used to show the tissues of one side of the face and used to investigate the parotid gland and the

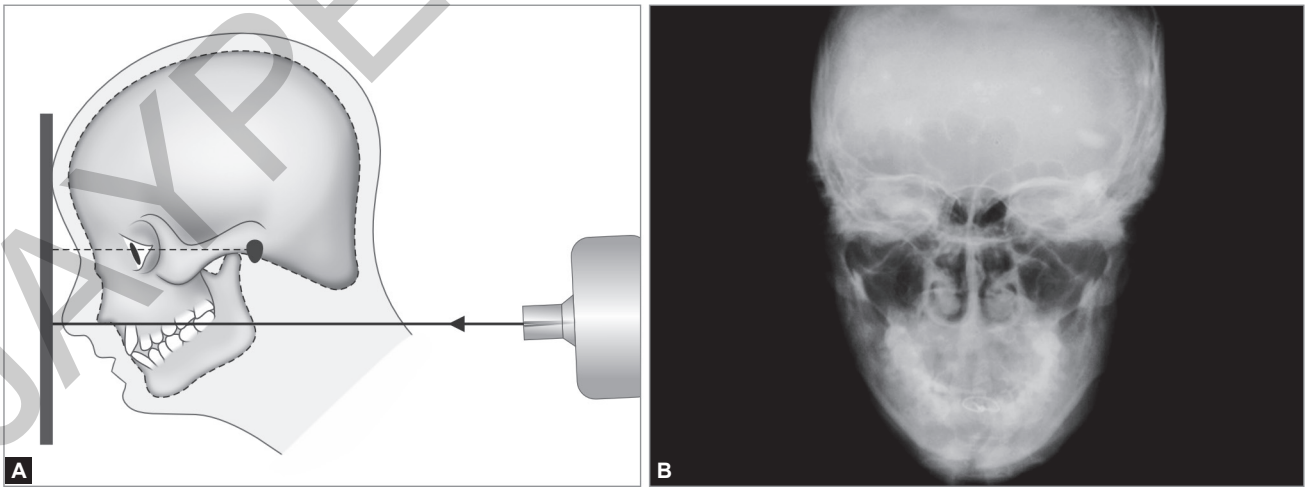

Figs. 13.4A and B: (A) Diagram for the positioning of posteroanterior mandible projection, the radiographic base line and the X-ray beam are perpendicular to the film; (B) Posteroanterior mandible view.

JAYPEE BROTHERS

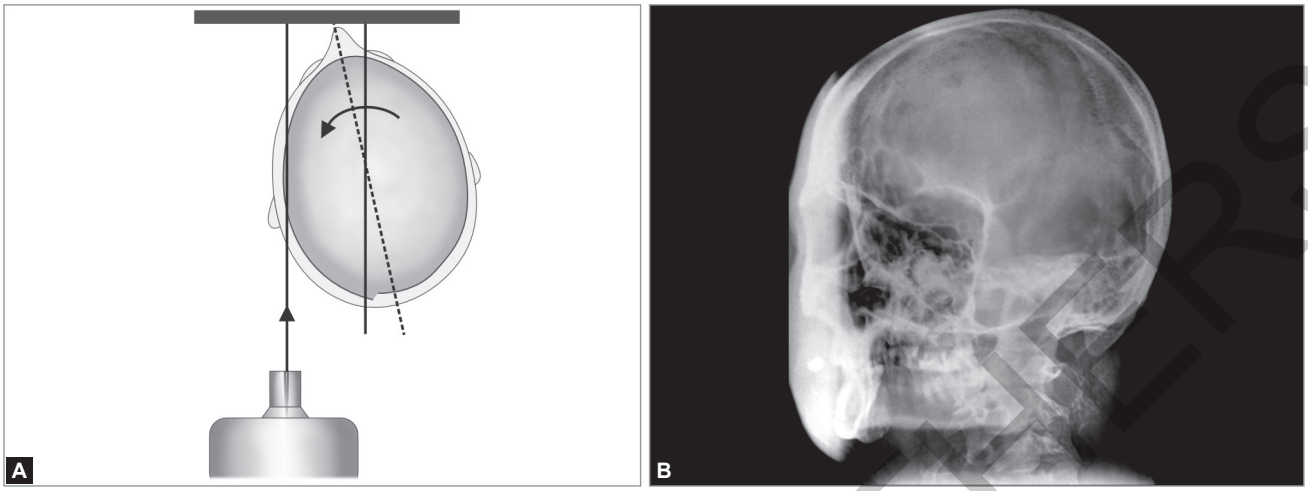

Figs. 13.5A and B: (A) Diagram for positioning rotated posteroanterior, from above, 10° rotation of the head to the side of interest and the X-ray beam aimed along the side of the face; (B) Rotated posteroanterior view showing parotid sialography, with the central ray passing through the glands.

ramus of the mandible. It is mainly used to demonstrate stones or calculi in the parotid, to note the mediolateral expansion of lesions in the ramus and submasseteric infections.

Film Placement

The cassette is placed perpendicular to the floor in a cassette holding device. The long axis of the cassette is positioned vertically.

Position of Patient

- The patient is positioned facing the film, with the occlusal plane horizontal and the tip of the nose touching the film.
- The head is rotated 10° to the side of interest. This rotates the bones of the back of the skull away from the side of the face under investigation.

Central Ray

It is directed at right angles to the film, aimed down the side of the face which is of interest.

Exposure Parameters

- Using extraoral machine
- kVp—65–80
- mA—60–80, seconds—1.6 (Bucky grid).

LATERAL OBLIQUE

Anterior Body of Mandible (Figs. 13.6A and B)

Structures Shown

Anterior body of the mandible, position of the teeth in the same area. Helps to evaluate impacted teeth, fractures and lesions located in the anterior portion of the mandible.

Film Placement

The cassette is placed flat against the patient's cheek and is centered over the body of the mandible, overlying the canine teeth. The patient must hold the cassette in position with the thumb placed under the edge of the cassette and the palm against the outer surface of the cassette.

Position of Patient

- The patient's head is so adjusted, that the ala tragus line is parallel to the floor.
- The mandible is protruded slightly to separate it from the vertebral column. The cassette is placed over the patient's cheek and centered over the area of interest. The inferior border of the cassette should be parallel to the lower border of the mandible and below it.
- The sagittal plane is tilted so that it is 5° to the vertical and rotated 30° from the true lateral position.
- For the bicuspid and incisor region, the patient's head should be turned slightly away from the tube so that the nose and chin approximate the cassette.

JAYPEE BROTHERS

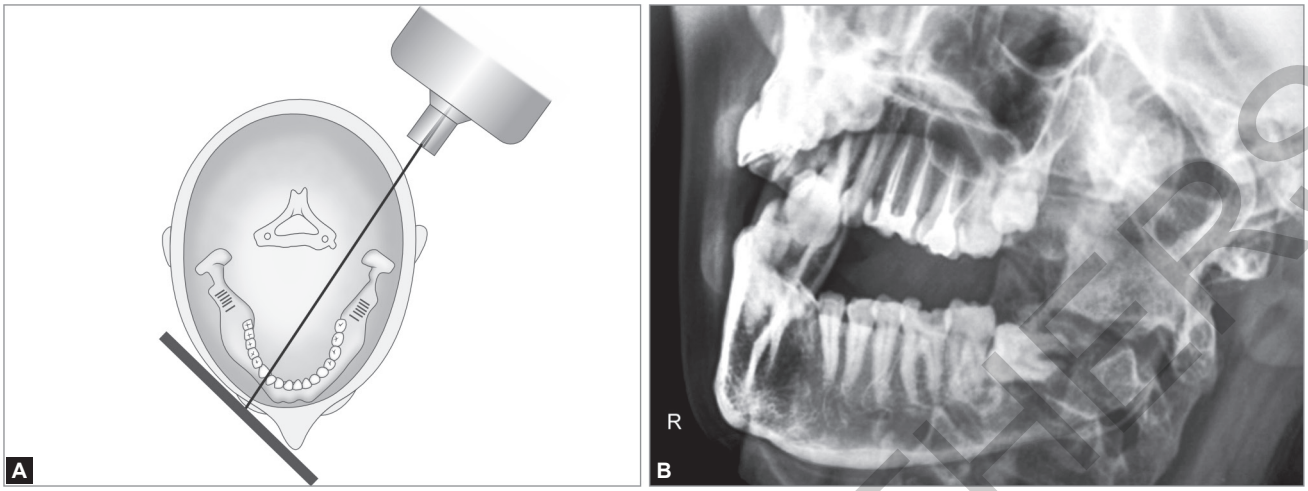

Figs. 13.6A and B: (A) Diagram for the positioning of lateral oblique projection for anterior body of the mandible, film is in contact with the cheek at the canine area, and the X-ray beam aims at the canine area, through the radiographic key hole; (B) Lateral oblique for the body of the anterior mandible.

Central Ray

It is directed from 2 cm below the angle of the mandible opposite to the side of interest. The beam is directed upward (–10° to –15°) and centered on the anterior body of the mandible. The beam must be directed perpendicular to the horizontal plane of the film.

Exposure Parameters

- Using intraoral X-ray machine
- kVp—65–70, mA—7–10, seconds—0.8
- Using extraoral X-ray machine
- kVp—40, mA—40, seconds—1.

Posterior Body of Mandible (Figs. 13.7A and B)

Structures Shown

Body of the mandible, position of the teeth in the same area, ramus of the mandible, angle of the mandible. Helps to evaluate impacted teeth, fractures and lesions located in the posterior border of the mandible.

Film Placement

The cassette is placed flat against the patient's cheek and is centered over the body of the mandible. The cassette also should be positioned parallel to the body of the mandible.

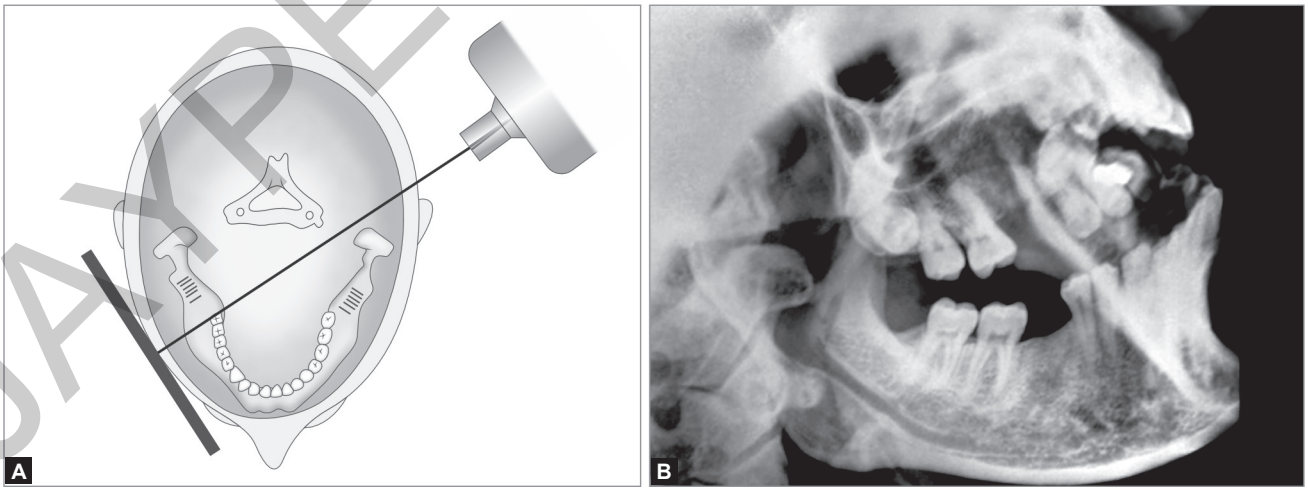

Figs. 13.7A and B: (A) Diagram for the positioning of lateral oblique projection for posterior body of the mandible, film is in contact with the cheek at the premolar area, and the X-ray beam aims at the premolar area, through the radiographic keyhole; (B) Lateral oblique projection of the body of the mandible.

JAYPEE BROTHERS

The patient must hold the cassette in position with the thumb placed under the edge of the cassette and the palm against the outer surface of the cassette.

Position of Patient

- The patient's head is so adjusted, that the ala tragus line is parallel to the floor.
- The mandible is protruded slightly to separate it from the vertebral column. The cassette is placed over the patient's cheek and centered over the area of interest.
- The inferior border of the cassette should be parallel to the lower border of the mandible and below it.
- The sagittal plane is tilted so that it is 5° to the vertical and the head is rotated 10°–15° from the true lateral position.

For the molar and ramus region, the head should not be turned away from the tube as this will place the ramus behind the vertebral column.

Central Ray

It is directed from 2 cm below the angle of the mandible opposite to the side of interest. The beam is directed upward (–10° to –15°) and centered on the body of the mandible. The beam must be directed perpendicular to the horizontal plane of the film.

Exposure Parameters

- Using intraoral X-ray machine
- kVp—65–70
- mA—7–10, seconds—0.8
- Using extraoral X-ray machine
- kVp—40
- mA—40, seconds—1.

Ramus of Mandible (Figs. 13.8A and B)

Structures Shown

The purpose of this view is to evaluate impacted third molars, large lesions, fractures that extend into the ramus of the mandible. This projection demonstrates a view of the ramus from the angle of the mandible to the condyles.

Film Placement

The cassette is placed flat against the patient's cheek and is centered over the ramus of the mandible. The cassette also should be positioned parallel to the ramus of the mandible. The patient must hold the cassette in position with the thumb placed under the edge of the cassette and the palm against the outer surface of the cassette.

Position of Patient

- The patient's head is so adjusted that the ala tragus line is parallel to the floor.
- The mandible is protruded slightly to separate it from the vertebral column. The cassette is placed over the patient's cheek and centered over the area of interest. The inferior border of the cassette should be parallel to the lower border of the mandible and below it.
- The sagittal plane is tilted so that it is 10° to the vertical and the head is rotated 5° from the true lateral position.

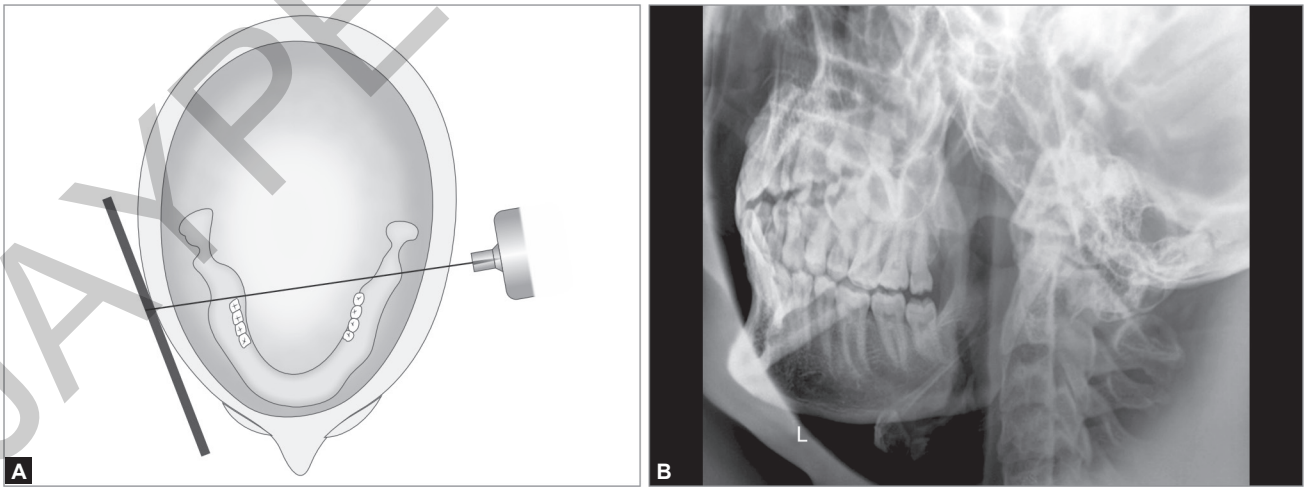

Figs. 13.8A and B: (A) Diagram for the positioning of lateral oblique projection for ramus of the mandible, film is in contact with the cheek at the ramus area, and the X- ray beam aims at the ramus area, from below the opposite angle of the mandible to a point distal to the third molar on the side of interest; (B) Lateral oblique projection of the mandibular ramus.

JAYPEE BROTHERS

Central Ray

It is directed from 2 cm below the angle of the mandible opposite to the side of interest, to a point posterior to the third molar region on the side opposite the cassette. The beam is directed upward (–10° to –15°) and centered on the ramus of the mandible. The beam must be directed perpendicular to the horizontal plane of the film.

Exposure Parameters

- Using intraoral X-ray machine
- kVp—65–70, mA—7–10, seconds—0.8
- Using extra oral X-ray machine
- kVp—40, mA—40, seconds—1.

SUBMENTOVERTEX (BASE) PROJECTION (FIGS. 13.9A AND B)

Structures Shown

- A full axial view of the base of the cranium showing a symmetrical projection of the petrosa, the mastoid process, foramen ovale, spinosum canals, carotid canals, sphenoidal sinuses, mandible, maxillary sinus, nasal septum, odontoid process of the atlas and the entire atlas, axial inclination of the mandibular condyles.
- Helps to study destructive or expansile lesions affecting the palate, pterygoid region or base of the skull, sphenoidal sinus.

Film Placement

The cassette is placed perpendicular to the floor in a cassette-holding device. The long axis of the cassette is placed vertically.

Position of Patient

- The head is centered on the cassette, with the patient's head and neck tipped back as far as possible, the vertex (top) of the skull touches the cassette.
- Both the midsagittal plane should be perpendicular to the plane of the film and the radiographic base line should be parallel to the film.

Central Ray

- It is directed perpendicular to the film and through the midsagittal plane, between the angles of the mandible, perpendicular to an imaginary line joining the mandibular 1st molars (approximately 1 inch from the chin).
- In order to view the petrous portion, the central ray is directed at right angles (or 5° to the horizontal) to the film midway between the external auditory meatus.

Exposure Parameters

kVp—50, mA—20–30, seconds—1.

JUG HANDLE VIEW (A MODIFICATION OF THE SUBMENTOVERTEX VIEW) (FIG. 13.10)

Structures Shown

A symmetrical axial view of the zygomatic arches.

Film Position

It is same as that in submentovertex.

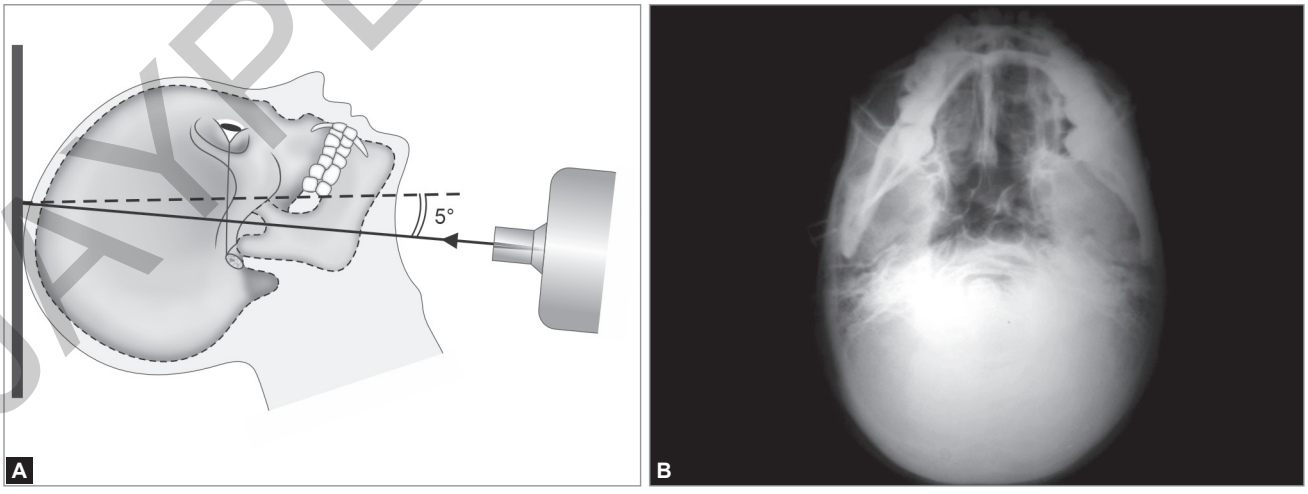

Figs. 13.9A and B: (A) Diagram for the positioning of submentovertex projection, the radiographic base line is parallel to the film, and the X-ray is perpendicular to the film; (B) Submentovertex view.

JAYPEE BROTHERS

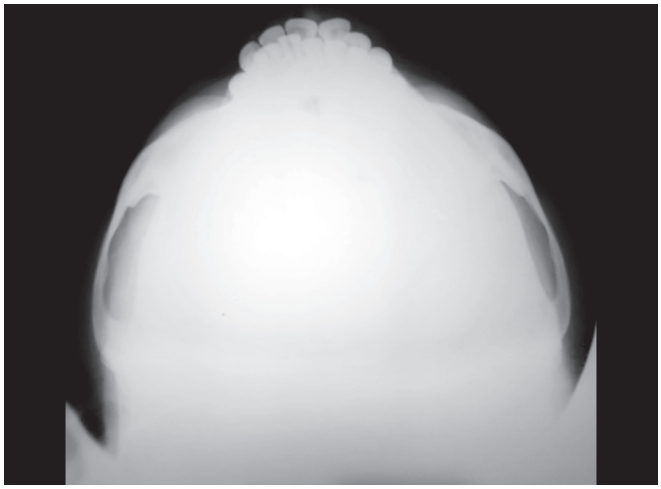

Fig. 13.10: Jug handle view.

Position of Patient

It is same as that in submentovertex.

Central Ray

The cone is brought as close as possible to the patient (which leads to magnification of the structures at the base of the skull).

Exposure Parameters

- kVp—less than 50, mA—20–30, seconds—0.4.
- The exposure time for the zygomatic arch is reduced to approximately one-third the normal exposure time for a submentovertex projection.

TRANSCRANIAL PROJECTION (FIGS. 13.11A TO D)

Structures Shown

This technique is most useful in detecting arthritic changes on the articular surface. It helps to evaluate the joint's bony relationship. Changes on the central and medial surfaces are not seen.

Film Position

The cassette is placed flat against the patient's ear and centered over the TM joint of interest, against the facial skin parallel to the sagittal plane.

Position of Patient

- The patient's head is adjusted so that the sagittal plane is vertical.
- The ala tragus line is parallel to the floor.
- This view is taken with the patient's mouth in three positions:
  1. Open mouth.
  2. Rest position.
  3. Closed mouth.

Central Ray

The point of entry is different according to the technique used:

- Postauricular or Lindblom technique:
  - Point of entry of the central ray is ½″ behind and 2″ above the auditory meatus.
  - According to Lindblom the central ray should be directed from posteriorly so that it passes along the long axis of the condyle (The medial pole of the condyle is more posterior to the lateral pole).
- Grewcock approach:
  - The central ray enters through a point 2″ above the external auditory meatus.
- Gill's approach:
  - The central ray enters through a point ½″ anterior and 2″ above the external auditory meatus.
  - In all the three techniques the central ray is directed caudally at an angle of +20° to +25°.
  - The point of exit is through the TM joint of interest.

Exposure Parameters

- Intraoral X-ray machine
- kVp—70, mA—07, seconds—1.5.

TRANSPHARYNGEAL PROJECTION (INFRACRANIAL OR McQUEEN DELL TECHNIQUE) (FIGS. 13.12A TO C)

Structures Shown

This view is a lateral projection showing medial surface of the condylar head and neck, usually taken in the mouth open position, so that the joint is projected into the shadow of air containing spaces of the nasopharynx, which helps to increase the contrast of the various parts of the joint.

Film Placement

The cassette is placed flat against the patient's ear and is centered to a point ½″ anterior to the external auditory meatus, over the TM joint of interest, against the facial skin parallel to the sagittal plane.

JAYPEE BROTHERS

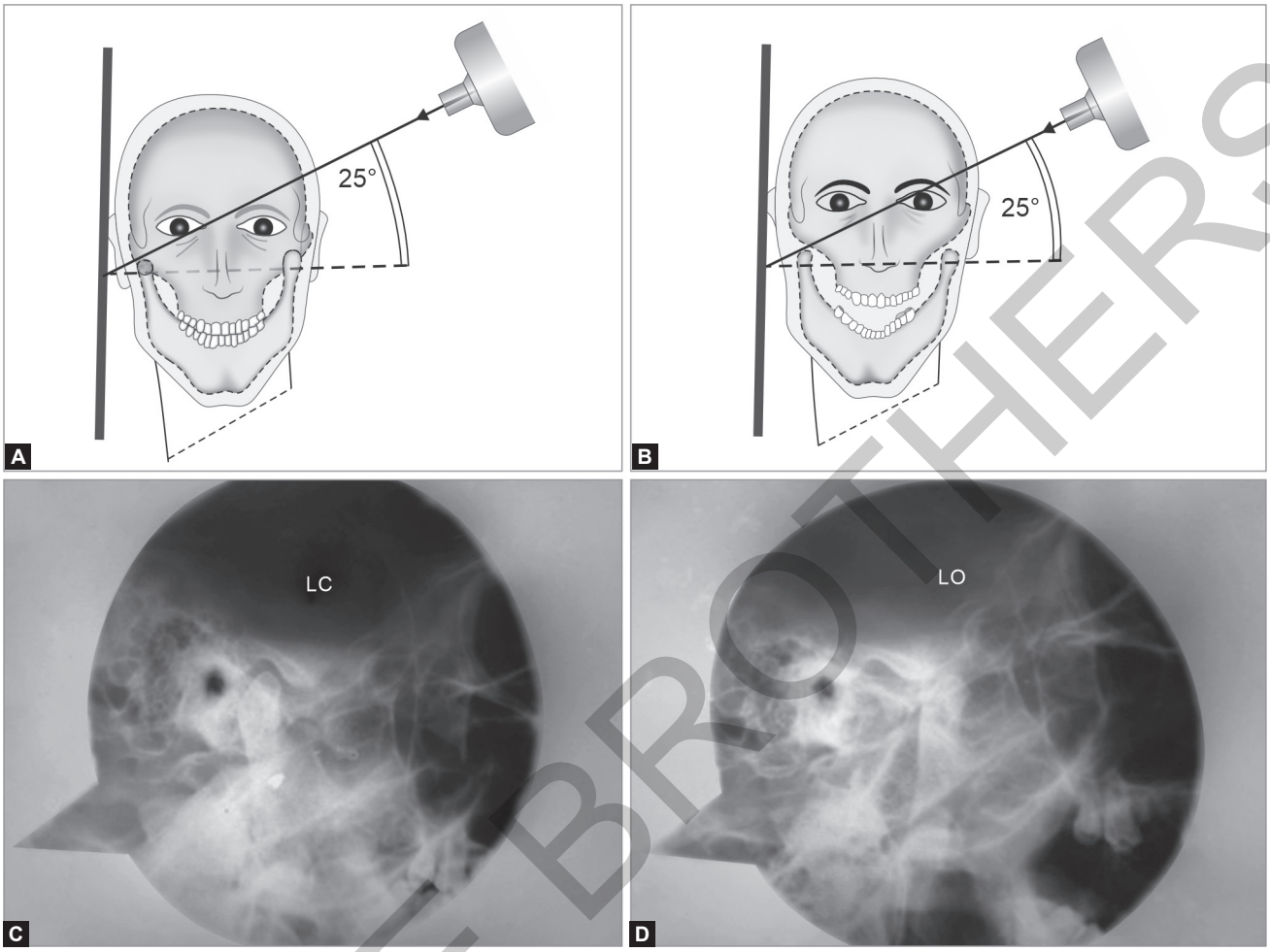

Figs. 13.11A to D: (A) Transcranial projection, the central ray is oriented at 25° positive angle from the opposite side and anteriorly 20°, centered over the TMJ of interest, mouth closed; (B) Transcranial projection, the central ray is oriented at 25° positive angle from the opposite side and anteriorly 20°, centered over the TMJ of interest, mouth open; (C) Transcranial view mouth closed position; (D) Transcranial view mouth open position.

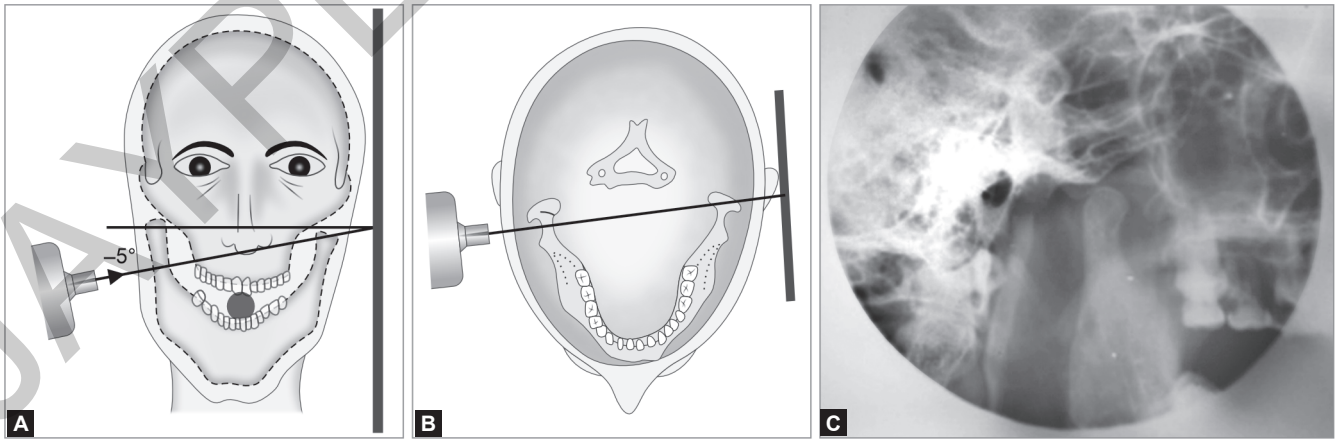

Figs. 13.12A to C: (A) Transpharyngeal projection. The central ray is oriented superiorly 5°–10° and posteriorly approximately 10°, centered over the TMJ of interest. The mandible is positioned at maximal opening; (B) Transpharyngeal projection, showing positioning from above, showing the X-ray beam aimed slightly posteriorly across the pharynx; (C) Transpharyngeal view.

JAYPEE BROTHERS

Position of Patient

- The patient is positioned so that the sagittal plane is vertical and parallel to the film, with the TM joint of interest adjacent to the film.
- The occlusal plane should be parallel to the transverse axis of the film so that the soft parts of the nasopharynx are in one line with the TM joint.
- The patient is instructed to slowly inhale through the nose during exposure, so as to ensure filling of the nasopharynx with air during the exposure.
- The patient should open his mouth so that the condyles move away from the base of the skull and the mandibular notch of the opposite side is enlarged.

Central Ray

- It is directed from the opposite side cranially, at an angle of –5° to –10° posteriorly.
- It is directed through the mandibular notch that is a window between the coronoid, condyle and the zygomatic arch, of the opposite side below the base of the skull to the TM joint of interest.

Exposure Parameters

- Using intraoral X-ray machine
- kVp—65–70, mA—7–10, seconds—0.8
- Using extraoral X-ray machine
- kVp—40, mA—40, seconds—1.

Parma Modification

The lead-lined open ended cone is removed and the tube head is brought close to the skin surface, producing magnification of the tube side structures and thereby reducing super imposition.

TRANSORBITAL PROJECTION (ZIMMER PROJECTION) (FIGS. 13.13A TO C)

This is the conventional frontal TM joint projection which is most successful in delineating the joint with minimal super impositions, leading to the production of a relatively true *enface* projection.

Structures Shown

The anterior view of the temporomandibular joint and medial displacement of fractured condyle and fracture of neck of condyle are clearly seen in this view.

Film Position

The film is positioned behind the patient's head at an angle of 45° to the sagittal plane.

Position of Patient

The patient is positioned so that the sagittal plane is vertical. The canthomeatal line should be 10° to the horizontal, with the head tipped downwards. The mouth should be wide open.

Central Ray

- The tube head is placed in front of the patient's face.
- The central ray is directed to the joint of interest, at an angle of +20°, to strike the cassette at right angles.

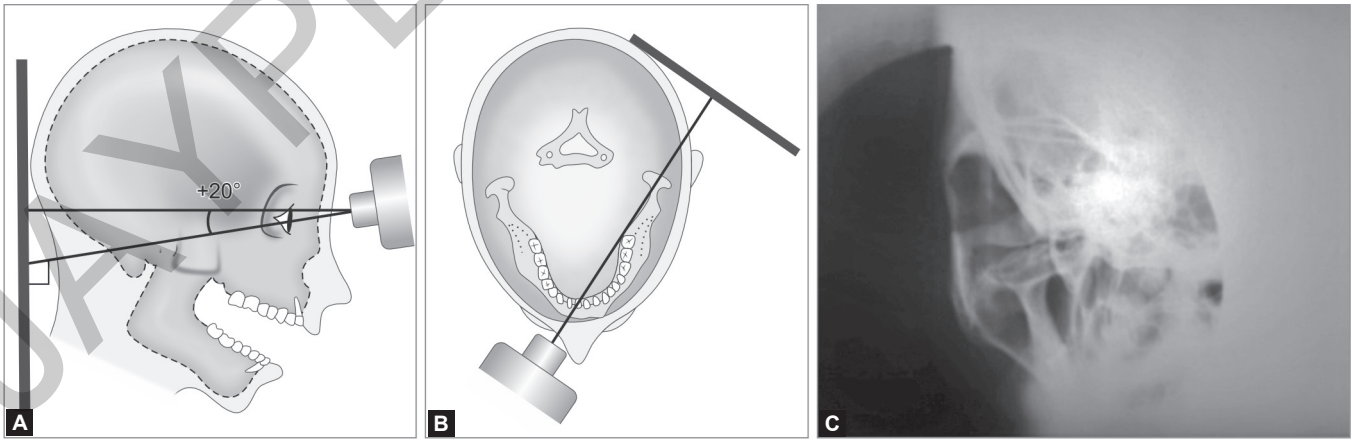

Figs. 13.13A to C: (A) Transorbital projection, the central ray is oriented downward approximately 20° and laterally approximately 30° through the contralateral orbit, centered over the TMJ of interest; (B) Transorbital projection, positioning from above, showing the cassette behind the condyle and X-ray beam aimed across the orbit; (C) Transorbital view.

JAYPEE BROTHERS

for detailed information on dental books, visit our website www.jaypeebrothers.com, for detailed information on dental books, visit our website www.jaypeebrothers.com, fo

Essentials of Oral and Maxillofacial Radiology

With over 800 high-quality radiographic images, the third edition of this book is highly informative and clinically relevant with the latest updates. It visually demonstrates the principles and applications of oral and maxillofacial radiographs, serving as a concise reference that comprehensively covers all aspects of diagnostic oral and maxillofacial radiology. It is an invaluable source of information for the undergraduate and postgraduate students, practicing clinicians, and radiographers in terms of:

- Providing a clear understanding of the essential physics of diagnostic radiology and its applications in modern dentistry.
- Detailing radiographic techniques and their indications and applications which are clearly summarized and well illustrated for easy understanding.
- Having a structured layout and descriptive text, complemented by illustrations, which effectively present normal radiographic anatomy with consequential pathological changes in disease as seen on the radiograph. Additionally, the inclusion of differential diagnoses makes this book an invaluable resource.
- Addition of a bonus final chapter which features case reports, allowing readers to consolidate their knowledge and apply the skills they have learned in a practical context.
- Additional new information on 4D imaging, along with the principles and applications of 3D printing in dentistry, has been included in this edition.

Overall, it is a well-structured and richly illustrated textbook which highlights key clinical and radiological features, ensuring a comprehensive and practical learning experience for the reader.

Freny R Karjodkar MDS (Oral Medicine and Radiology) has been an undergraduate, postgraduate, and PhD teacher in the subject for the last 40 years and is one of the senior-most oral and maxillofacial physicians in Maharashtra. Her greatest achievement is that she has gained vast clinical expertise by working and teaching in Nair Dental College & Hospital, which exposed her to a variety of clinical data of oral mucosal lesions, orofacial pain, temporomandibular disorders, etc. Her hands-on experience in diagnosing and applying different modalities of treatment for the oral maladies opened vistas of avenues for research. She has more than 250 publications in national and international journals, authored 3 books on maxillofacial radiology and a textbook on oral medicine, and contributed to various other dental textbooks. As HOD, she introduced various protocols for clinical and chairside diagnosis of potentially malignant lesions and oral cancer, treatment of soft-tissue lesions with lasers, treatment of TMD and orofacial pain with medication, TENS, and therapeutic ultrasound. She was instrumental in installing Kodak 90003D, the first 3D machine in a government institute, and was a Hon. Consultant Radiologist to assist set up of various CBCT centers in Mumbai. She is the first President for the Maharashtra Branch of Indian Academy of Oral Medicine and Radiology (2023–2025). Presently, she practices in her private clinic and is a visiting and online oral-medicine and radiology consultant.

Her motto is, "Don't just preach, reach out to teach and treat".

Printed in India

Available at all medical bookstores or buy online at www.ejaypee.com

JAYPEE BROTHERS
Medical Publishers (P) Ltd.
EMCA House, 23/23-B, Ansari Road,
Daryaganj, New Delhi - 110 002, INDIA
www.jaypeebrothers.com

Join us on facebook.com/JaypeeMedicalPublishers
Follow us on instagram.com/JaypeeMedicalPublishers

Shelving Recommendation
DENTISTRY

ISBN 978-93-6616-856-2
9 789366 168562