formation on medicine books, visit our website www.ejaypee.com, for detailed information on medicine books, visit our website www.ejaypee.com,

Mastering MRCP PACES

A Comprehensive Guide

PACES New Format 2023

Highlights

- Complete preparation for PACES
- New format for MRCP 2023
- Also beneficial for MD, FCPS and Diploma Examination
- Around 200 cases in role play format

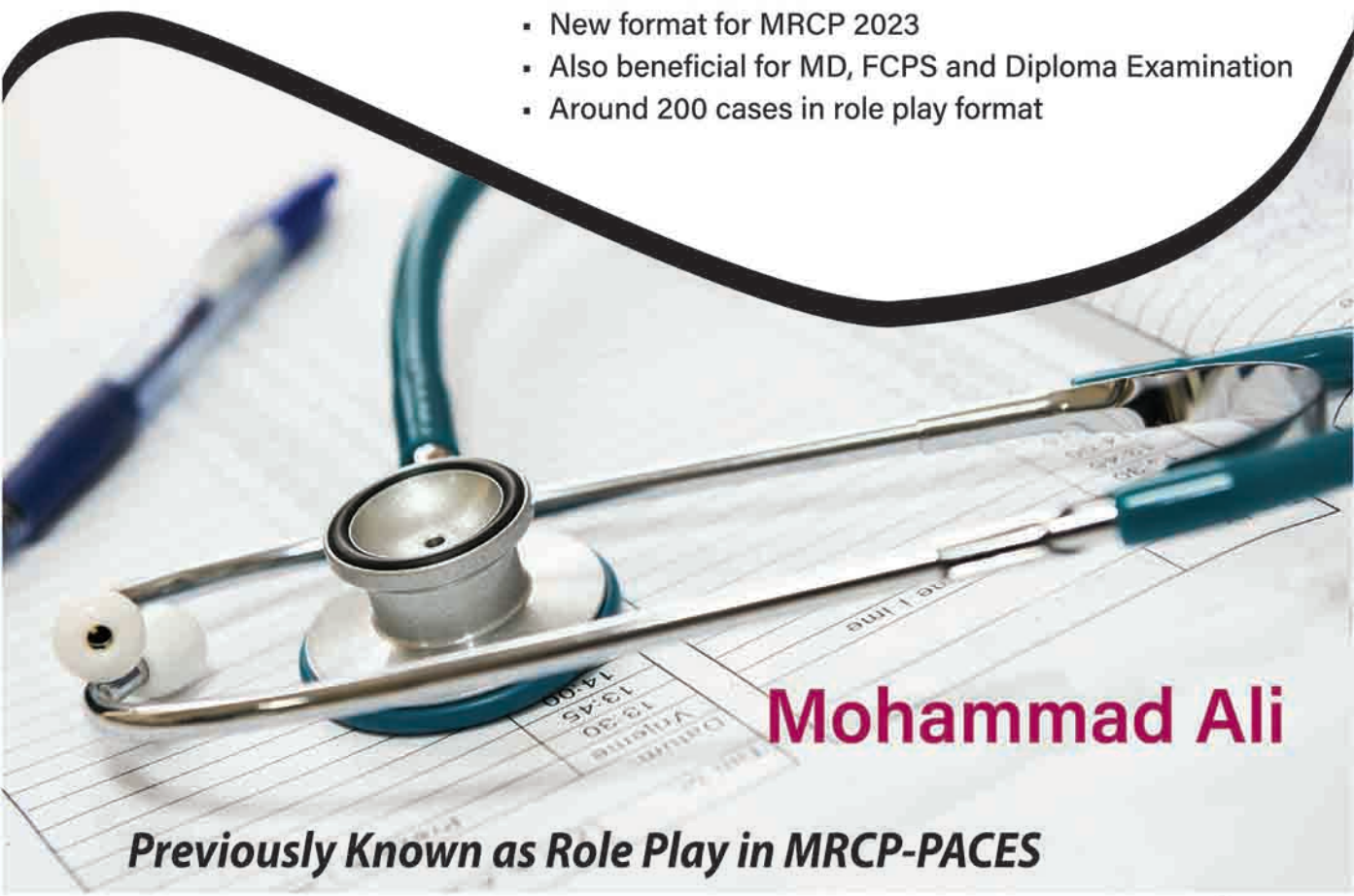

Mohammad Ali

Previously Known as Role Play in MRCP-PACES

Foreword
Quazi Deen Mohammad

2nd Edition

JAYPEE

Contents

Chapter 1 (Station-2 and 5): Clinical Consultation **1**

- ❑ Approach to a Scenario in Clinical Consultation Station (Station 2 and 5) *2*
- ❑ Spot Diagnosis *4*
- ❑ Hypothyroidism *32*
- ❑ Graves' Disease *38*
- ❑ Cushing Syndrome *43*
- ❑ Acromegaly *48*
- ❑ Addison's Disease *53*
- ❑ Diabetic Foot *58*
- ❑ Ankylosing Spondylitis *62*
- ❑ Back Pain *67*
- ❑ Systemic Lupus Erythematosus *71*
- ❑ Systemic Sclerosis *77*
- ❑ Rheumatoid Arthritis *82*
- ❑ Gout *89*
- ❑ Optic Atrophy *93*
- ❑ Diplopia *98*
- ❑ Retinitis Pigmentosa *103*
- ❑ Vitreous Hemorrhage *107*
- ❑ Pyoderma Gangrenosum *111*
- ❑ Psoriasis *115*
- ❑ Pleural Effusion *119*
- ❑ Chronic Obstructive Pulmonary Disease *124*
- ❑ Pulmonary Embolism *128*
- ❑ Atrial Fibrillation *133*
- ❑ Congestive Cardiac Failure *137*
- ❑ Lambert–Eaton Myasthenic Syndrome *142*
- ❑ Transient Ischemic Attack *147*
- ❑ Transient Ischemic Attack in Young Female *151*
- ❑ Marfan Syndrome *155*
- ❑ Osteogenesis Imperfecta *159*
- ❑ Post-transplant Lymphoproliferative Disorder *163*

- ❑ Sexually Transmitted Infection *168*
- ❑ Crohn's Disease *172*
- ❑ Bronchiectasis *177*
- ❑ Cerebral Artery Stroke *183*
- ❑ Reactive Arthritis *188*
- ❑ Celiac Disease/Thyrotoxicosis *193*
- ❑ Subacute Infective Endocarditis *198*

Chapter 2 (Station-3): Clinical Examination: Cardiovascular System 203

- ❑ Cardiovascular System Examination *204*
- ❑ Aortic Stenosis *208*
- ❑ Aortic Regurgitation *210*
- ❑ Mixed Aortic Valve Disease *212*
- ❑ Mitral Stenosis *214*
- ❑ Mitral Regurgitation *217*
- ❑ Mitral Valve Prolapse *220*
- ❑ Mixed Mitral Valve Disease *222*
- ❑ Pulmonary Stenosis *224*
- ❑ Prosthetic Aortic Valve *226*
- ❑ Prosthetic Mitral Valve *228*
- ❑ Atrial Septal Defect *230*
- ❑ Ventricular Septal Defect *232*
- ❑ Patent Ductus Arteriosus *234*
- ❑ Intracardiac Device *236*

Chapter 3 (Station-1): Clinical Examination: Respiratory System 239

- ❑ Respiratory System Examination *240*
- ❑ Interstitial Lung Disease *245*
- ❑ Rheumatoid Lung *247*
- ❑ Bronchiectasis *249*
- ❑ Cystic Fibrosis *252*
- ❑ Pneumonia *254*
- ❑ Chronic Obstructive Pulmonary Disease *256*
- ❑ Cor Pulmonale *259*
- ❑ Bronchial Asthma *261*
- ❑ Lung Cancer *263*
- ❑ Lobectomy *266*
- ❑ Pneumonectomy *268*
- ❑ Lung Transplant *270*

Chapter 4 (Station-4): Clinical Examination: Gastrointestinal System 273

- ❑ Gastrointestinal Tract Examination *274*
- ❑ Chronic Liver Disease *279*
- ❑ Cirrhosis with Portal Hypertension *283*
- ❑ Hepatomegaly with No Stigmata of Chronic Liver Disease *286*
- ❑ Hereditary Hemochromatosis *288*
- ❑ Primary Biliary Cholangitis/Cirrhosis *290*
- ❑ Ascites *293*
- ❑ Hepatosplenomegaly *296*
- ❑ Isolated Splenomegaly *298*
- ❑ Hemolytic Anemia (Hereditary Spherocytosis) *300*
- ❑ Autosomal Dominant Polycystic Kidney Disease *302*
- ❑ Renal Transplant *305*
- ❑ Liver Transplantation *308*
- ❑ Renal-pancreas Transplant *311*
- ❑ Chronic Pancreatitis *313*
- ❑ Crohn's Disease *315*
- ❑ Percutaneous Endoscopic Gastrostomy *317*

Chapter 5 (Station-3): Clinical Examination: Nervous System 319

- ❑ Examination of Upper Limb *320*
- ❑ Examination of Lower Limb *324*
- ❑ Examination of Cranial Nerves *327*
- ❑ Examination for Disequilibrium *332*
- ❑ Examination of Eye *334*
- ❑ Peripheral Neuropathy *338*
- ❑ Peripheral Neuropathy: Atypical Features *341*
- ❑ Chronic Inflammatory Demyelinating Polyneuropathy *343*
- ❑ Sensory Ataxia *345*
- ❑ Charcot–Marie–Tooth Disease *347*
- ❑ Claw Hand *349*
- ❑ Spastic Paraparesis *351*
- ❑ Cord Compression *353*
- ❑ Cervical Myelopathy *355*
- ❑ Stroke/Cerebrovascular Disease *357*
- ❑ Cerebellar Disorder (Upper Limb) *360*
- ❑ Cerebellar Ataxia *361*
- ❑ Multiple Sclerosis *363*
- ❑ Motor Neuron Disease (Kennedy's Disease) *365*

- ❑ Bulbar Palsy (Motor Neuron Disease) *367*
- ❑ Myotonic Dystrophy *369*
- ❑ Myasthenia Gravis (Ocular) *372*
- ❑ Parkinson's Disease *375*
- ❑ Tardive Dyskinesia *378*
- ❑ Involuntary Movement (Chorea) *379*

Chapter 6 (Station-1 and 4): Clinical Communication Skills and Ethics 381

- ❑ Communication and Ethics—Station Planning *382*
- ❑ Rheumatoid Arthritis *386*
- ❑ Lifestyle Modification of a Rheumatoid Arthritis Patient *390*
- ❑ Transient Ischemic Attack *394*
- ❑ Addison's Disease *397*
- ❑ Ulcerative Colitis with the Refusal to Admit Hospital *400*
- ❑ Celiac Disease *403*
- ❑ Patient with the First Fit *406*
- ❑ Emphysema with Smoking Cessation *409*
- ❑ Counseling of an Alcohol Drinker *413*
- ❑ Discussion on Breaking Bad News *417*
- ❑ Pancreatic Carcinoma *419*
- ❑ Multiple Sclerosis *422*
- ❑ Delayed Diagnosis of Cancer *426*
- ❑ Dementia *429*
- ❑ Renal Biopsy *432*
- ❑ Percutaneous Endoscopic Gastrostomy Tube Insertion *436*
- ❑ Intercostal Chest Drain *439*
- ❑ Hickman Line *442*
- ❑ Lumbar Puncture *444*
- ❑ Esophagogastroduodenoscopy Procedure *447*
- ❑ Offer a Blood Transfusion *450*
- ❑ Needle Stick Injury *452*
- ❑ Newly Diagnosed Human Immunodeficiency Virus *455*
- ❑ Hospital Superbug-1 *459*
- ❑ Hospital Superbug-2 *462*
- ❑ Genetic Counseling *465*
- ❑ Counseling for Anticoagulation *468*
- ❑ Patient with Poor Compliance *470*
- ❑ Nonorganic Disease *473*
- ❑ Medical Error-1 *476*
- ❑ Medical Error-2 *479*

- ❑ Medical Trial *481*
- ❑ Cancer Withhold *483*
- ❑ Live Organ Donation *486*
- ❑ Advance Care Decision *489*
- ❑ Decision about Do Not Resuscitate *493*
- ❑ End-of-Life Decision *496*
- ❑ Brainstem Death Testing *499*
- ❑ Brainstem Death and Organ Donation *502*
- ❑ Hospital Postmortem *505*
- ❑ Coroner's Postmortem *508*

Index **511**

CHAPTER 1
(Station-2 and 5)

Clinical Consultation

- Approach to a Scenario in Clinical Consultation Station (Station 2 and 5)
- Spot Diagnosis
- Hypothyroidism
- Graves' Disease
- Cushing Syndrome
- Acromegaly
- Addison's Disease
- Diabetic Foot
- Ankylosing Spondylitis
- Back Pain
- Systemic Lupus Erythematosus
- Systemic Sclerosis
- Rheumatoid Arthritis
- Gout
- Optic Atrophy
- Diplopia
- Retinitis Pigmentosa
- Vitreous Hemorrhage
- Pyoderma Gangrenosum
- Psoriasis
- Pleural Effusion
- Chronic Obstructive Pulmonary Disease
- Pulmonary Embolism
- Atrial Fibrillation
- Congestive Cardiac Failure
- Lambert–Eaton Myasthenic Syndrome
- Transient Ischemic Attack
- Transient Ischemic Attack in Young Female
- Marfan Syndrome
- Osteogenesis Imperfecta
- Post-transplant Lymphoproliferative Disorder
- Sexually Transmitted Infection
- Crohn's Disease
- Bronchiectasis
- Cerebral Artery Stroke
- Reactive Arthritis
- Celiac Disease/Thyrotoxicosis
- Subacute Infective Endocarditis

JAYPEE BROTHERS

Approach to a Scenario in Clinical Consultation Station (Station 2 and 5)

Two sorts of cases are typical during the Practical Assessment of Clinical Examination Skills (PACES) examination in clinical consultation stations:

1. The patient presenting with a common discrete medical presentation in the medical outpatient clinic, ward, or emergency department such as "the patient complains of sharp pain in the chest" and the patient with a spot diagnosis; most often with dermatological, rheumatological, endocrinological, or (probably less likely) ophthalmological diagnoses.
2. Candidates will be given written instructions for each of the stations, usually in the form of short notes or referral letters during 5 minutes interval before each station. The instructions to the candidate will give definite direction, and these must be followed; there is simply no time for going "off-track." Once you get this clinical scenario, start to think about your diagnosis and differential diagnoses and plan for taking focused history as well as focused examination.

Each station, as you know, will be 20 minutes which includes history taking, clinical examination, and explanation to the patient. Here, history taking is an essential component of their assessment and it is absolutely important that as a candidate you use the most scientific and modern way of collecting important information from the patient while keeping the patient the center of this exercise. So traditionally we have had things such as the presenting complaint followed by a history of present illness, followed by past medical history (PMH), followed by drug history, allergies, family history (FH), travel history, personal history, social history, and systems review while all of these are still very relevant and very important.

It is important to take history and do the examination in a patient-centered approach. We should consider the *Calgary Cambridge framework* during clinical consultation under five headlines that include:

1. *Initiating the session*: Introduce yourself to the patient; shake the hand; establish their identity by getting the name, date of birth, and address; take the patient's consent for speaking to them; then move on to establishing the agenda for the consultation and start with open questions. All of these can be considered under the headline initiating the session.
2. *Gathering the information:* Move from open questions to closed questions to analyze the presenting symptoms. At the same time an initial careful inspection for few seconds may provide essential clues, which may, e.g., guide further questioning and examination. Keeping a suspected diagnosis in your mind from the obvious clinical appearance as well as initial focused history, go for short-targeted history to establish your diagnosis, exclude the differential diagnosis, complications, causes, identify risk factors, and associated conditions. Then go for quick systemic review, PMH, FH, treatment, and social history according to your provisional and differentials. It is very important to *explore the patient's ideas, concerns, and expectations (ICE)*. To explore the patient's ideas, e.g., if the patient does come in with chest pain, what are their ideas about what could be causing this? And, what are their concerns? What are they worried about? The patient could be worried about this being a heart attack and then expectations, what are they expecting from your consultation? What would they like to be? In the end, maybe the patient would

JAYPEE BROTHERS

like to have been investigated and treated. So, this is under gathering information.

3. *Physical examination:* Take permission and do the focused examination based on the patient's history and spot diagnosis, e.g., if a patient complains of breathlessness, his focused systemic examination will be the respiratory and or cardiovascular system (CVS). Note the bedside clues and examine the patient in appropriate and professional manners to identify physical signs correctly. You can examine the patient after taking the complete history, or you can take history for the first few minutes, then start examination and continue taking the history at the same time.
4. *Explanation and planning:* You have gathered the information, explore the physical signs and address the patient's ICE, now move on to the explanation and planning. Here, you need to give the patient an explanation of what you have found from the history and examination, your idea about the patient's problem, your next plan, check the understanding, and acknowledge the patient's concerns. Since you are giving chunks of information to the patient, give a pause so that the patient can take it in and then check the patient's understanding—did you follow that? Did you follow what I have just said to you? Am I clear so far? Not only here, but you should also *take pauses throughout the station* to giving time to the patient to interrupt you so that patient can ask you things. All above, you should *avoid medical jargon, do not use complex medical terms* that the patient will not understand or will have difficulty understanding. If you use a complex medical term, please explain what does it means, e.g., in a patient with autoimmune disease, you should explain the autoimmune disease by saying "It is a disease due to disturbance in our defensive system which is supposed to attack bugs and germs. Sometimes, our immune system instead of attacking germs and bugs, go crazy for an unknown reason, and it starts attacking our own tissues."
5. *Closing the session:* Now move to close the interview, there are certain fundamental landmarks of this part of clinical consultation. At this point, you need to summarize what you have obtained from this conversation. Then again, ask if the patient has *any further concern or anything to mention* that you have not asked already. Then, negotiate a mutual plan of action and remember this, you are going to negotiate, this is not a one-way street, so the doctor is not to dictate their plan to the patient. So, suggest the patient about the investigation, treatment, admission, referral, or follow-up and ask is that okay with them or not? Moreover, finally, we can call it as a final safety net—*"Have I missed anything, or do you want to add anything more?"*

JAYPEE BROTHERS

Spot Diagnosis

Many of the patients seen in station 2 or 5 will have spot dermatological, rheumatological, endocrinological, or ophthalmological diagnosis.

Vitiligo (Fig. 1)

Well-demarcated depigmented macules and patches surrounded by normal skin with a hyperpigmented border without loss of sensation (which exclude differential diagnosis of leprosy).

Look for distributions such as the face, dorsal hands, axilla, nipple, umbilicus, sacrum, and anogenital region.

It may be associated with other autoimmune disorders, so ask about the suggestive history of other autoimmune disorders such as hypo or hyperthyroidism, pernicious anemia, Addison's disease, diabetes mellitus (DM), and alopecia areata.

Look for signs of associated autoimmune disorders including thyroidectomy scar, needle marks for DM, and evidence of peripheral neuropathy for pernicious anemia.

Alopecia Areata (Figs. 2A and B)

Loss of hair with no signs of scarring or inflammation with some small, tiny hairs at the periphery. It may be associated with nail pitting and other autoimmune disorders. So, proceed as a case of vitiligo described earlier. Usually, this is treated with topical steroids and minoxidil.



FIG. 1: Vitiligo.

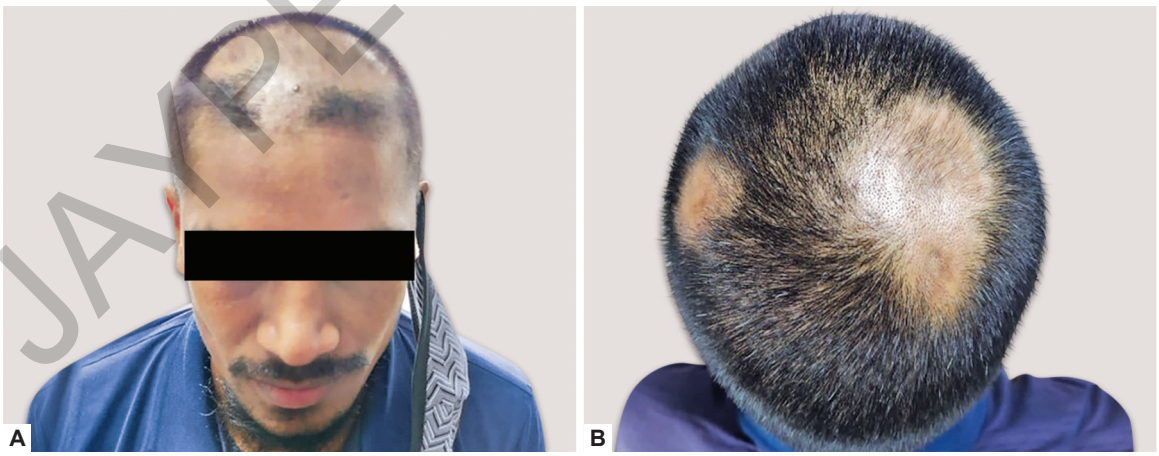

FIGS. 2A AND B: Alopecia areata.

JAYPEE BROTHERS

Lichen Planus (Fig. 3)

Itchy, flat-topped, pink, or purple papules in the arms, legs, or buccal mucosa with white Wickham striae on the surface. This may be associated with longitudinal nail ridge. Certain infections such as hepatitis C virus (HCV) infection and medications such as beta-blockers, thiazide diuretics, metformin, and antimalarials may trigger lichen planus.

It can affect different organs, so ask about:

- Change of voice or shortness of breath (? larynx)
- Difficulty or painful swallowing [? gastrointestinal tract (GIT)]
- Dysuria (? renal)
- Redness in the eye (? conjunctiva)

Diagnosis is confirmed by biopsy and usually treated with local steroid, but systemic steroid may be required in severe and widespread disease.

Necrobiosis Lipoidica (Fig. 4)

Sharply defined, a thin, shiny, and atrophic area with yellowish waxy center (feels like candle wax) with overlying dilated blood vessels (telangiectasia) in the skin.

It is a rare and chronic skin condition that may be associated with DM. So, ask about the suggestive history of DM and its complications; look for blood glucose monitoring (BM) testing pricks and insulin injections sites which indicate associated DM. Potent topical steroids/tacrolimus/intralesional steroids are the treatment of choice. However, oral steroid and/or cyclosporine may be required in a refractory case.



FIG. 3: Lichen planus.

Sturge–Weber Syndrome (Fig. 5)

Flat, pink, red, or purple-colored patch (port-wine stain) in one side of the face (caused by the concentration of dilated tiny blood vessels called capillaries-hemangioma).

Ask about fits or weakness (brain hemangioma) if present, then think it is a case of Sturge–Weber syndrome (caused by *GNAQ* gene mutation).

Then ask about pain in the eye or decrease vision (it can be associated with glaucoma).

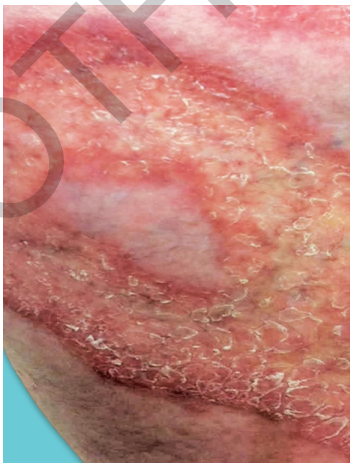

FIG. 4: Necrobiosis lipoidica.



FIG. 5: Sturge–Weber syndrome.

JAYPEE BROTHERS

Now examine the lower limbs neurologically for weakness and fundus for glaucoma or choroidal hemangioma.

It is congenital (presents from birth). Brain imaging [computed tomography (CT)/magnetic resonance imaging (MRI)] and a genetic test is the investigation of choice.

Neurofibromatosis Type-1 (Figs. 6A and B)

Multiple soft and firm, sessile, mobile nodules along the course of peripheral nerves (neurofibroma).

Now examine for:

- Light brown, evenly pigmented macules (Café-au-lait spots)
- Gold-tan to brown in color—dome-shaped gelatinous masses, developed on the surface of the iris [Lisch nodule characteristics of neurofibromatosis (NF)-1].
- Small circular spots on the axillary skin that are darker than the surrounding skin due to deposit of melanin (axillary freckling)
- Large nodules containing multiple neurofibromas "bag of worms" (plexiform neuroma)
- Any scar from previous surgery

Now ask about:

- Tinnitus, hearing loss, or balance problem (unilateral or bilateral acoustic neuroma for NF-2).
- Take suggestive histories and examine for cranial nerves (CNs) involvement
- Any weakness in the limbs for spinal involvement

It is an autosomal dominant inheritance (chromosome 17—NF-1, and chromosome 22—NF-2). Genetic screening and MRI are the investigations of choice. Surgical removal and antiepileptics are treatment options.

Hereditary Hemorrhagic Telangiectasia (Fig. 7)

Multiple telangiectasias (visible small linear red blood vessels) on the tongue, but look for distribution in the face, especially around the mouth, nail bed, and palate.

Now ask about:

- Do you bleed from any part of the body such as mouth or nose? Do you have any hematemesis or melena (recurrent bleeding)?
- Any shortness of breath, racing of the heart, or do you look pallor (? anemia)?
- Do you have any bleeding with your bowel motion [? bowel arteriovenous (AV)]?
- Do you have any blood with your waterworks [? kidney AV]?
- Do you have any weakness or clumsiness (? brain AV)?
- Do you have coughed up blood (? lung AV)?

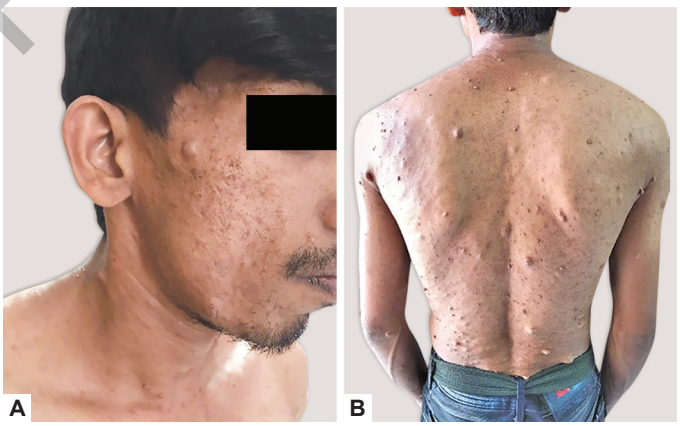

FIGS. 6A AND B: Neurofibromatosis type-1.

JAYPEE BROTHERS

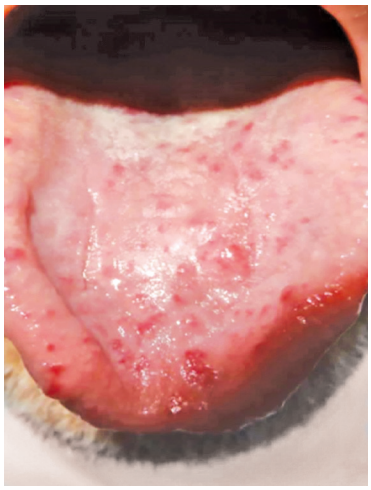

FIG. 7: Hereditary hemorrhagic telangiectasia.

- FH [autosomal dominant disorder; mutation in endoglin on chromosome 9 or *ACVRL1* gene on chromosome 12; characterized by epistaxis, cutaneous telangiectasia, and visceral arteriovenous malformations (AVMs)]

Examine the liver for enlargement and bruit (? AVM).

Neurological examination if weakness is present.

Examine the lung for pulmonary bruits, especially in the lower lobe (? pulmonary AVM)

Look for anemia and signs of iron deficiency anemia (IDA) (koilonychia) for evidence of chronic blood loss **(Fig. 8)**.

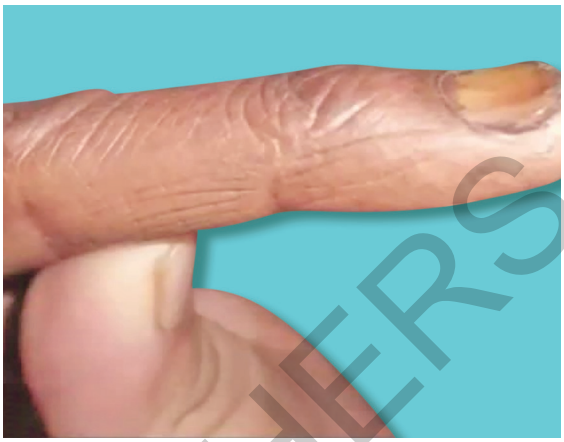

FIG. 8: Look for anemia and signs of iron deficiency anemia (koilonychia) for evidence of chronic blood loss.

Bullous Pemphigoid (Fig. 9)

Multiple bullae are arising from normal skin or red skin filled with clear or yellow or hemorrhagic fluid, which is large, tense, and involving inner thigh, upper arms, and trunk.

Ask about:

- Itching (it is intensely itchy lesion)
- Any weight loss, anorexia, nausea, vomiting, hematemesis, and lumps (underlying malignancy)
- Any joint pain and butterfly rash [underlying systemic lupus erythematosus (SLE)]

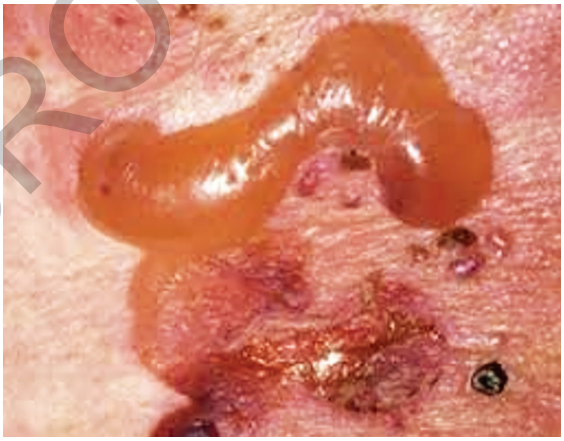

FIG. 9: Bullous pemphigoid.

- Any precipitating drug history [captopril, gliptins, antibiotics, nonsteroidal anti-inflammatory drugs (NSAIDs), and furosemide]
- Any history of radiation (precipitating events)

Now examine the lymph nodes and abdomen for underlying malignancy.

Diagnosis is confirmed by biopsy for histopathology and immunofluorescence shows deposition of immunoglobulin G (IgG) and C3 in dermoepidermal junction. Treatment includes steroid and azathioprine.

JAYPEE BROTHERS

Porphyria Cutanea Tarda (Fig. 10)

Multiple bullae (fluid-filled sacs), milia (small, dome-shaped white, or yellow bumps) and scarring over the sun-exposed area particularly on the dorsal hands, forearms, face, and ears.

Ask about predisposing factors such as alcohol intake, history of hepatitis or liver disease (hemochromatosis), or estrogen-containing drugs.

Ask about family history [commonly sporadic but sometimes Alzheimer's disease (AD)].

Diagnosis is confirmed by 24-hour urine for uroporphyrin; if it is confirmed, then consider hepatitis screen, iron, or ferritin level (to exclude hemochromatosis), and alpha-fetoprotein (to exclude hepatocellular carcinoma).

Treatment options include:

- Removal of offending agents
- Sun avoidance
- Phlebotomy
- Antimalarial (chloroquine)

Rheumatoid Hand and Foot (Figs. 11 and 12)

Picture illustrates Z deformity of the thumb and swan neck deformity of the other fingers and gross wasting of the small muscle of the hand.

Look for ulnar subluxation of the metacarpophalangeal (MCP) joints and ulna at the carpal joint, Boutonniere deformity, nail infarct, palmar erythema, carpal tunnel syndrome (CTS), and scars of previous surgery.

Look for rheumatoid nodule and disease activity (joint swelling and tenderness).

Assess the functional status of the joint and joint movement (active and passive).

Look for evidence of extra-articular manifestations—pulmonary [diffuse parenchymal lung disease (DPLD)], eye (uveitis and scleritis), and Felty's syndrome (anemia and splenomegaly).

Becker's Muscular Dystrophy (Figs. 13A and B)

Enlarged calves (pseudohypertrophy) and proximal muscle wasting.

Presented with proximal myopathy and waddling gait (walk on their toes or push their



FIG. 11: Rheumatoid hand.



FIG. 10: Porphyria cutanea tarda.



FIG. 12: Rheumatoid feet.

JAYPEE BROTHERS

abdomen forward when walking to maintain balance and compensate for lack of strength in the hip and legs).

Other signs particularly check for dilated cardiomyopathy can be the first sign of Becker's muscular dystrophy (BMD). On neurological examination—reduced muscle power with preserved reflex and sensation.

Becker muscular dystrophy is an X-linked recessive inherited disorder caused by mutations in the dystrophin gene. Slowly progressing muscle weakness of the legs and pelvis. Symptoms usually appear in teenage or early adult years.

Diagnosis based on history, examination, and investigations include elevated serum creatinine kinase, dystrophin gene deletion analysis, electromyography (EMG), and muscle biopsy with dystrophin antibody staining. Electrocardiogram (ECG) and echocardiography for cardiomyopathy.

There is no cure for BMD. Only treatment option is symptomatic care (steroid and/or gene therapy) under multidisciplinary team (MDT).

Dermatomyositis (Figs. 14A and B)

Purple or red colored erythematous rash around eyes (heliotrope rash), over the knuckles (Gottron's papule).

Look for rash in other parts of the body around the neck (shawl rash), chest, and back—above the breast (V-sign).



FIGS. 13A AND B: Becker's muscular dystrophy.



FIGS. 14A AND B: Dermatomyositis.

JAYPEE BROTHERS

Ask about:

- Weakness in climbing stairs and combing hair (? proximal myopathy)
- Shortness of breath and cough (? lung fibrosis)
- Painful hand joints and butterfly rash with photosensitivity [? mixed connective tissue disease (MCTD)].
- Fever, weight loss, anorexia, difficulty in swallowing, hematemesis (? underlying malignancy).

Examine for proximal myopathy, chest for signs of DPLD, or any evidence of malignancy (lymph node, abdomen).

Investigations include a blood test [creatine phosphokinase (CPK), anti-Jo antibody, complete blood count (CBC), C-reactive protein (CRP)], EMG, and screening for malignancy depending on the symptoms (CT, endoscopy, or colonoscopy).

Amiodarone Facies (Fig. 15)

Deep and bluish gray discoloration around malar area, nose, and cheeks.

Ask about drug history (? amiodarone) and the reason for taking the drug.

Look for signs and symptoms of amiodarone toxicity:

- Pulmonary fibrosis
- Thyrotoxicosis/Hypothyroidism
- Liver impairment

Pretibial Myxedema (Fig. 16)

Waxy discolored induration of the skin-given the characteristic appearance of peau d'orange on the anterior aspect of the lower leg spreading to the dorsum of the foot (pretibial myxedema) **(Fig. 16)**. Now look for the *myxedematous face* **(Figs. 17A and B)** (expressionless face with apathetic look, periorbital swelling, puffiness of the face with baggy eyelids, loss of outer one-third of the eyebrows, and xanthelasma).

Or, *thyrotoxic face* **(Fig. 18)** (patient appears anxious, restless, and fidgety with unilateral or bilateral proptosis).

Now examine for thyroid status and thyroid gland.

Mitral Facies (Fig. 19)

Malar flush—rosy, flushed cheeks, and dilated capillaries. The rash correlates with the severity of mitral stenosis due to reduced cardiac output.

- Look for signs of mitral stenosis, evidence of pulmonary hypertension (PHTN) or right ventricular hypertrophy, heart failure, and infective endocarditis.
- Listen for a hoarse voice (left vocal cord paralysis secondary to left atrial enlargement in mitral stenosis).
- Ask about rheumatic heart disease.

Exclude SLE; facial telangiectasia occurs in outdoor workers.



FIG. 15: Amiodarone facies.



FIG. 16: Pretibial myxedema.

JAYPEE BROTHERS



FIGS. 17A AND B: Myxedematous face.

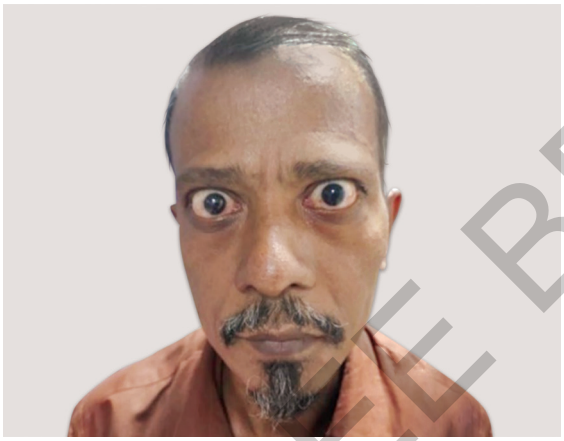

FIG. 18: Thyrotoxic face.



FIG. 19: Mitral facies.

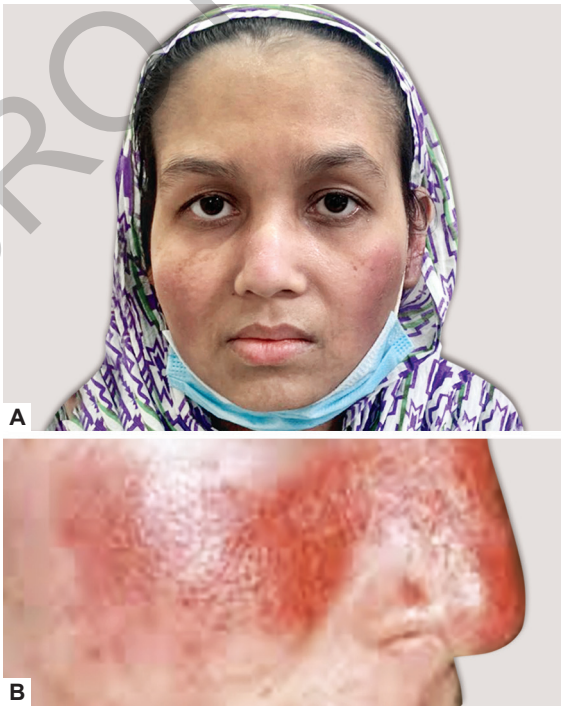

FIGS. 20A AND B: Photosensitive rash.

Photosensitive Rash (Figs. 20A and B)

Rash over both cheeks and bridge of the nose with sparing of the nasolabial fold—butterfly rash of SLE.

JAYPEE BROTHERS

Differential diagnosis: MCTD, dermatomyositis, leprosy, erysipelas, post kala-azar dermal leishmaniasis (PKDL), and rosacea.

Look for other signs: Discoid rash (typically sun-exposed area), oral ulcer, periungual erythema, nail fold telangiectasia, livedo reticularis, alopecia, hyperpigmentation, purpura, and urticaria.

Ask about drug history (procainamide, isoniazid, and hydralazine—drug-induced SLE), and thrombosis [antiphospholipid antibody (APLA) syndrome].

Sarcoidosis (Figs. 21A to D)

Dusky blue or purple plaque on the nose (lupus pernio).

Look for other sites of involvement (ears, cheeks, lips, and forehead).

Differential diagnosis: Rhinophyma (rosacea), SLE, and leprosy.

Look for other signs:

- Erythematous tender bumps on the lower leg—erythema nodosum.
- Multiple dusky purple plaque-like lesions in the skin of the different parts—skin sarcoid.

Ask for systemic symptoms:

- Cough, shortness of breath, and chest pain (? pulmonary)
- Red and watery eye (? uveitis)
- Headache, confusion, and malaise [? central nervous system (CNS)]
- Joint pain and or swelling (? arthritis)
- Loin pain or hematuria (? nephrocalcinosis)

Examine the heart, lung, eye, liver, lymph nodes, and CNS according to the symptoms.



FIGS. 21A TO D: Sarcoidosis.

JAYPEE BROTHERS

for detailed information on medicine books, visit our website www.ejaypee.com, for detailed information on medicine books, visit our website www.

Mastering MRCP PACES

A Comprehensive Guide

Salient Features

- This book is a complete package for clinical knowledge that starts from attending to the patient until goodbye.
- Around 200 cases are organized in a role-play format to give an exact idea of managing a patient practically.
- A helping handbook for postgraduate exams particularly MRCP, MD, FCPS and other allied.
- The format lends itself to individual study and group role play, which will stimulate dialogue around the theme introduced.

Mohammad Ali FCPS MCPS D-Card is a Clinical Professor and Head, Department of Medicine at Dhaka Central International Medical College and Hospital, Dhaka, Bangladesh. He serves as an examiner of the MBBS and BDS examination and regularly participates in various cardiac and medicine-oriented seminars and workshops at home and abroad. Apart from that his 20 publications have been printed in home and international journals. His key goal is to develop an advanced multidisciplinary treatment approach to standard care in patient management. His strong communication and interpersonal skills together with his background as an internist have established him as a renowned medicine, heart, and diabetes specialist in Bangladesh.

Dr Mohammad Ali was born in the district of Naogaon, Bangladesh in 1979. He passed his SSC and HSC successfully from Rajshahi Cadet College. He achieved his MBBS degree from Dhaka Medical College in the year 2003, later he trained himself at Dhaka Medical College, National Heart Foundation Hospital, and Bangabandhu Sheikh Mujib Medical University (BSMMU) at various times.

He earned his D-Card degree from BSMMU in his first appearance in the year of 2010. Later he successfully gained an MCPS degree in medicine and an FCPS degree from the Bangladesh College of Physicians and Surgeons (BCPS) in his first appearance during the period of 2012 and 2014 respectively.

In 2013, he achieved a CCD degree in diabetes from BIRDEM hospital and turned himself into a gold medalist from the institute for his outstanding performance. He got a membership from the American College of Physicians in 2016 and a membership from the European Society of Cardiology in 2018.

He joined as an Assistant Professor of the Medicine Department at East West Medical College and Hospital, Bangladesh in 2013 and later he served as an Associate Professor here.

Printed in India

Available at all medical bookstores or buy online at www.ejaypee.com

JAYPEE BROTHERS
Medical Publishers (P) Ltd.
EMCA House, 23/23-B, Ansari Road, Daryaganj, New Delhi - 110 002, INDIA
www.jaypeebrothers.com

Join us on facebook.com/JaypeeMedicalPublishers
Follow us on instagram.com/JaypeeMedicalPublishers

Shelving Recommendation
MEDICINE

ISBN 978-93-6616-861-6