hopedics books, visit our website www.ejaypee.com,for detailed information on orthopedics books, visit our website www.ejaypee.com, for detailed information on orthopedics books

4

Master Series Monographs

Tibial Condyle Fractures

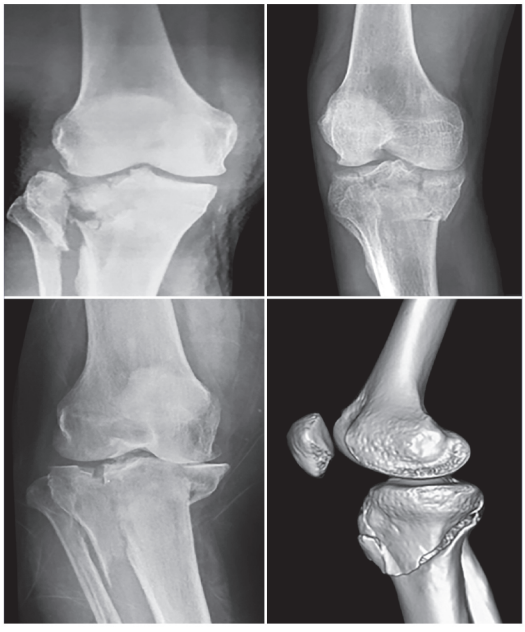

Editor-in-Chief
Gautam Zaveri

Section Editors
Sangeet Gawhale
Vivek Shetty

JAYPEE

Contents

Note from the Editor-in-Chief xi

Note from the Section Editors xiii

Contributors xv

1. **Clinical and Surgical Anatomy of the Proximal Tibia** 1
   Siddharth Shah, Sachin Yashwant Kale

2. **Classification of Tibial Condyle Fractures** 11
   Harshad Argekar

3. **Lateral Condyle Fractures** 23
   Kashyap Ardeshana

4. **Medial Condyle Fractures** 47
   Sangeet Gawhale, Kushal Gohil

5. **Bicondylar Fractures** 61
   Vivek Shetty, Shaswat Mishra

6. **Tibial Condylar Fractures with Associated Ligament/Meniscal Injuries** 75
   Swapnil Kothadia, Gautam Zaveri

7. **Malunited Tibial Condyle Fractures** 95
   Mangal Parihar, Girish K Nathani, Amit Kumar Yadav

8. **Fracture Related Infections of the Proximal Tibia** 111
   Vikas M Agashe, Gautam Zaveri

9. **Tibial Plateau Fractures: Case Series** 123
   Jignesh Pandya, Pranav D Shah

   Case 1: Comminuted Medial Condyle Fracture with Anterior Cruciate Ligament and Posterior Cruciate Ligament Involvement *123*

   Case 2: Comminuted Lateral Condyle Fracture with Split Depression and Column Involvement *128*

   Case 3: Bicondylar Tibial Plateau Fracture with Medial Condyle Displacement and Anterior Cruciate Ligament Avulsion *134*

Case 4: Posterior Bicondylar Tibia Fracture with Posteromedial and Posterolateral Condyle Involvement *139*

Case 5: Isolated Posterolateral Condyle Fracture with Articular Depression *143*

Case 6: Hyperextension Bicondylar Tibial Plateau Fracture with Varus Deformity *149*

Case 7: Posterior Bicondylar Tibial Plateau Fracture with Anterior Cruciate Ligament Avulsion and Coronal Plane Medial Condyle Fracture *154*

Case 8: Zero-column Fractures of the Lateral Tibial Condyle *158*

Index **171**

5 Bicondylar Fractures

Vivek Shetty, Shaswat Mishra

Introduction

Bicondylar fractures (Schatzker V and VI) account for 18–39% of all tibial plateau fractures. These are complex injuries that involve both the medial and lateral articular surfaces leading to articular fragment displacement and metaphyseo-diaphyseal disruption. They result from moderate to high energy trauma and are often accompanied by significant soft tissue injury, compartment syndrome, ligament disruptions and meniscal tears.[1-3]

Surgical treatment of bicondylar fractures is associated with a high complication rate (28–39%). Complications include infections, progression of arthritis, nonunions, and failed fixation requiring additional surgery.[3,4] Bicondylar fractures have historically had poorer outcomes, highlighting the need for improved analysis, characterization, and treatment strategies.[5-7] This chapter aims to give the readers a framework on systematic management of bicondylar tibial plateau fractures.

Evaluation

History

Bicondylar tibial fractures typically result from high energy trauma such as car accidents, motorcycle collisions, pedestrian-vehicular accidents and falls from height. The mode of injury should be documented as it can give the treating team clues as to the energy involved and possible associated injuries. Effort should be made to elicit the mechanism of injury, i.e., varus or valgus force, flexion/extension, and internal/external rotation which would help in better understanding of fracture morphology and in drawing up a fixation plan.[4]

Physical Examination

Basic principles of physical examination should be followed when assessing a patient who has a bicondylar tibial plateau fracture. Limb alignment, open wounds, and soft-tissue status should be assessed and documented. Open injuries are common (8–43%).[1] Detailed descriptions and photographs are recommended to help plan the operative approach and to aid in tracking of soft-tissue status.[1,8] Neurovascular findings including foot and ankle motor function, sensation and pulses should be documented and re-examined serially.

Apart from open fractures, compartment syndrome and vascular deficit are two major dreaded complications of bicondylar fractures. They require emergency intervention and hence should not be missed. Compartment syndrome occurs in 11–27% of bicondylar tibial plateau fractures. It is frequently missed, with potentially disastrous consequences.[9,6] The most commonly affected compartment in the leg is the anterolateral compartment, followed by the lateral compartment. A high index of suspicion should be maintained for compartment syndrome, with clinical examination still being the gold standard for diagnosis in the awake and reliable patient. Close monitoring is crucial in the first 24–48 hours, especially in patients who are unconscious or unreliable. Measuring compartment pressure may help diagnose compartment syndrome but always

JAYPEE BROTHERS

needs validation with clinical examination to establish diagnosis.[10] Clinical manifestations of compartment syndrome in the leg include severe pain disproportionate to the injury, swelling, and tightness in the affected compartment, along with paresthesia and muscle weakness. On examination, there is often visible swelling, tenderness, and in severe cases, visible muscle bulging, pallor (pale skin), and absent pulses. Leg pain typically worsens with passive stretching of the affected muscles. Collectively, the features of compartment syndrome can be summarized as pain, pallor, paresthesia, pulselessness, and paralysis.

Imaging

Plain radiographs and CT scans help in diagnosis and characterization of the osseous injury. **(Fig 1)** the most common injury pattern is the extension valgus force resulting in a lateral condyle split/split depression fracture (33%). The other common injury patterns include flexion-varus (19%) and extension-varus (17%). A study of fracture geometry gives a clue to the mechanism of injury, and can guide fracture reduction and fixation strategies.

MRI scans may be additionally necessary to study soft tissue injury, ligament and meniscal disruption, and cartilage damage.

Management

Bicondylar tibial plateau fractures are complex injuries that require individualized treatment considerations. Factors such as bone quality, fracture pattern, patient age, soft-tissue injuries, and host factors, can impact treatment outcomes. Poor outcomes are associated with advanced age (≥ 50 years), open fractures, compartment syndrome, and smoking.[2,12,13] A tailored treatment plan is essential to address the unique challenges of these fractures. This

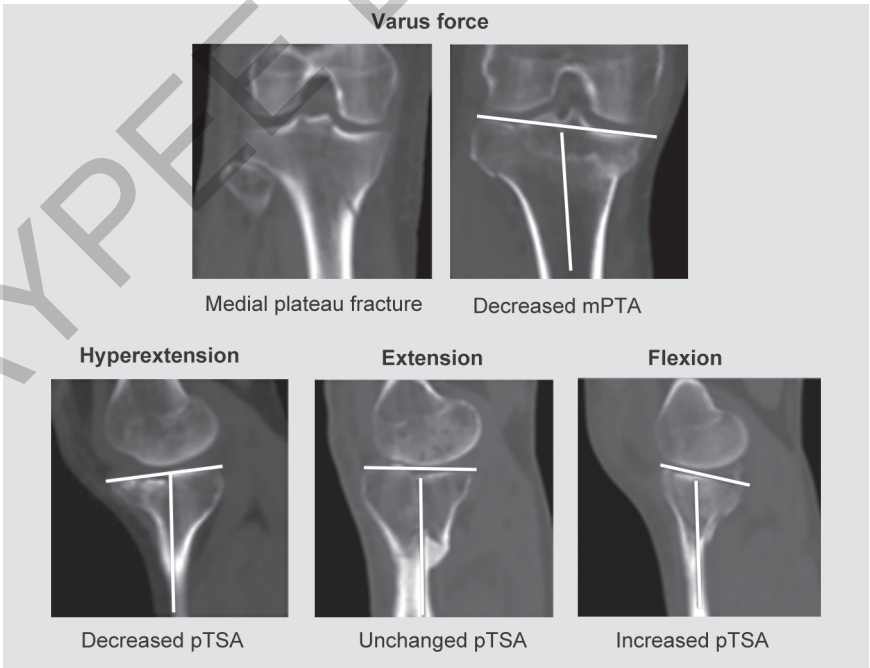

Fig 1: *Continued*

JAYPEE BROTHERS

Continued

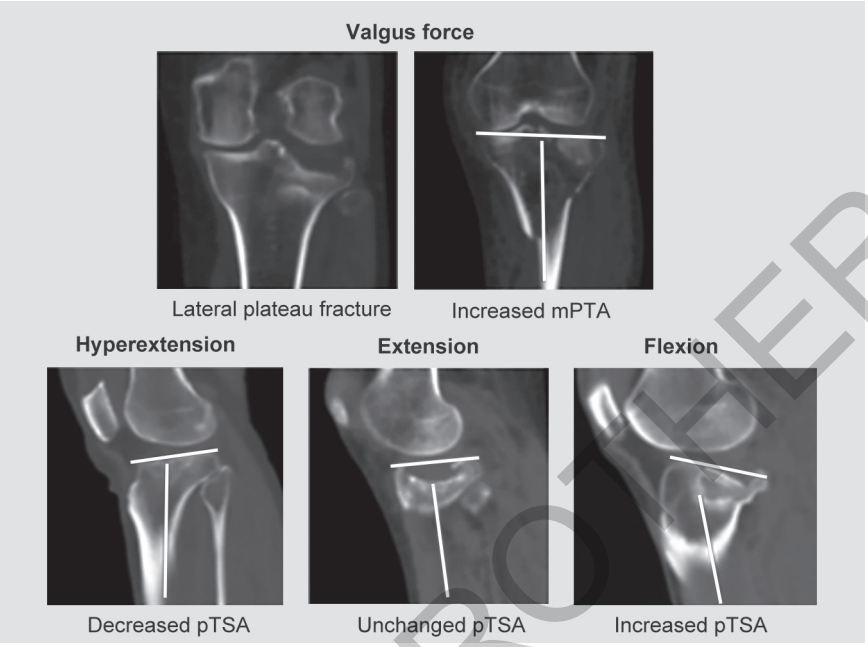

Fig 1: Tibial plateau fracture injury mechanism in 2-dimensional computed tomography (CT) images.
(mPTA: medial proximal tibial angle; pTSA: posterior tibial slope angle)

JAYPEE BROTHERS

section aims at giving a systematic approach to deal with these fractures in a structured manner, with representative cases.

Conservative Management

Nonoperative treatment for bicondylar tibial plateau fractures is limited to undisplaced fractures or medically unfit patients. These are treated with immobilization in a long knee brace followed by mobilization in hinged knee brace. Weight bearing is dictated by signs of fracture healing X-rays and the patient profile. The main complications are malunion and joint stiffness.

Indications for Surgery

- Intraarticular incongruity
- Angular deformity in the sagittal or coronal plane > 5° resulting in instability
- Open fractures
- Neurovascular compromise or compartment syndrome

Timing and Staging of Surgery

Clinical and neurovascular status of the limb dictates timing of surgery and the decision of single versus staged surgery. Compartment syndrome and neurovascular deficit constitute an absolute emergency, mandating mandating exploration/stabilization at the earliest. Bicondylar fractures accompanied by severe soft tissue injury (tense skin/blebs), open injuries, and compartment syndrome require initial stabilization with external fixators. External fixation allows provisional reduction of the fracture, maintains fracture alignment, and leg length, provides excellent pain control, helps in reduction of soft tissue swelling, and monitoring for compartment syndrome. Additionally, it allows access for assessment

and management of soft tissue injuries. Usually, a unilateral fixator is applied with 2–3 anteroposterior pins in the femur and in the tibia, avoiding the zone of soft tissue, and bony injury. For more unstable injuries, an additional plane of fixation should be used. CT scans are performed only after application of external fixator so as to obtain clearer images with minimum overlapping shadows. Definitive fixation is performed after adequate soft tissue healing.

For milder soft tissue injuries, the knee is elevated, immobilized, cold compresses applied, and appropriate anti-inflammatory/antiproteolytic agents administered to reduce knee swelling and prevent/heal skin blebs before undertaking surgical stabilization. This process may take 3–10 days.

Surgical Planning and Execution

Surgery aims to restore articular congruity and align the articular metaphyseal block with the diaphysis. The articular block is first anatomically reduced and rigidly stabilized followed by indirect reduction and stabilization of the articular block with the diaphysis, ensuring satisfactory alignment, length, and rotation. Buttressing remains the mainstay of treatment of proximal tibial bicondylar fractures. However, with the advent of CT and better understanding of fractures mechanics, the need to buttress each fractured column individually has become apparent.

The patient position, surgical approach, order of fixation of the columns, and implants needed for the fixation are all dictated by the fracture morphology. Robust fixation is needed to prevent subsidence of the articular fragment and allow early knee mobilization. Most of these fractures require dual fixation via single or dual approaches. Positioning of the patient and the operation theater (OT) setup is planned accordingly. Here, we take a case-based discussion approach to understand some of the more frequently encountered fracture patterns.

Valgus-flexion Injury

- *Fracture pattern:* Flexion-posteromedial fragment, with valgus-anterolateral depression.
- *Surgical plan and approach*:
  - *Floppy lateral position:* Inverted L incision/posteromedial approach—buttress plate.
  - *Lateral/supine position:* Anterolateral approach—depression elevated-plate with raft screws.

Case Example

A 40-year-old male suffered a road traffic accident (RTA) and presented with these X-rays **(Figs 2A and B)**. CT scans showed a large posterior-medial fragment with a posteromedial column breach along with an anterolateral fragment, suggesting a valgus-flexion mechanism of injury **(Figs 2C to E)**.

The operative plan was to buttress the two fragments individually using two separate approaches. While choosing between the two columns, the simpler fracture pattern should be addressed first. We recommend buttressing the medial flexion component first, as there is usually less comminution medially and hence it is easier to reconstruct. Once done, it gives a sense of the native joint line in both planes, providing a guide for elevation of the lateral plateau depression. Radiographs of the contralateral knee also aid in knowing the native patient anatomy.

Initially, with the patient in a semiprone position, using a reverse L-shaped incision and a posteromedial approach, the posteromedial fragment was exposed. The large and noncomminuted posteromedial fragment was gently reduced using a small bone spike.[14,15] A precontoured locked buttress plate was then applied on the posterior surface with the screw immediately distal to the fracture being inserted first. The antiglide effect thus generated, pushes the posteromedial fragment proximally, and anterolaterally reducing

JAYPEE BROTHERS

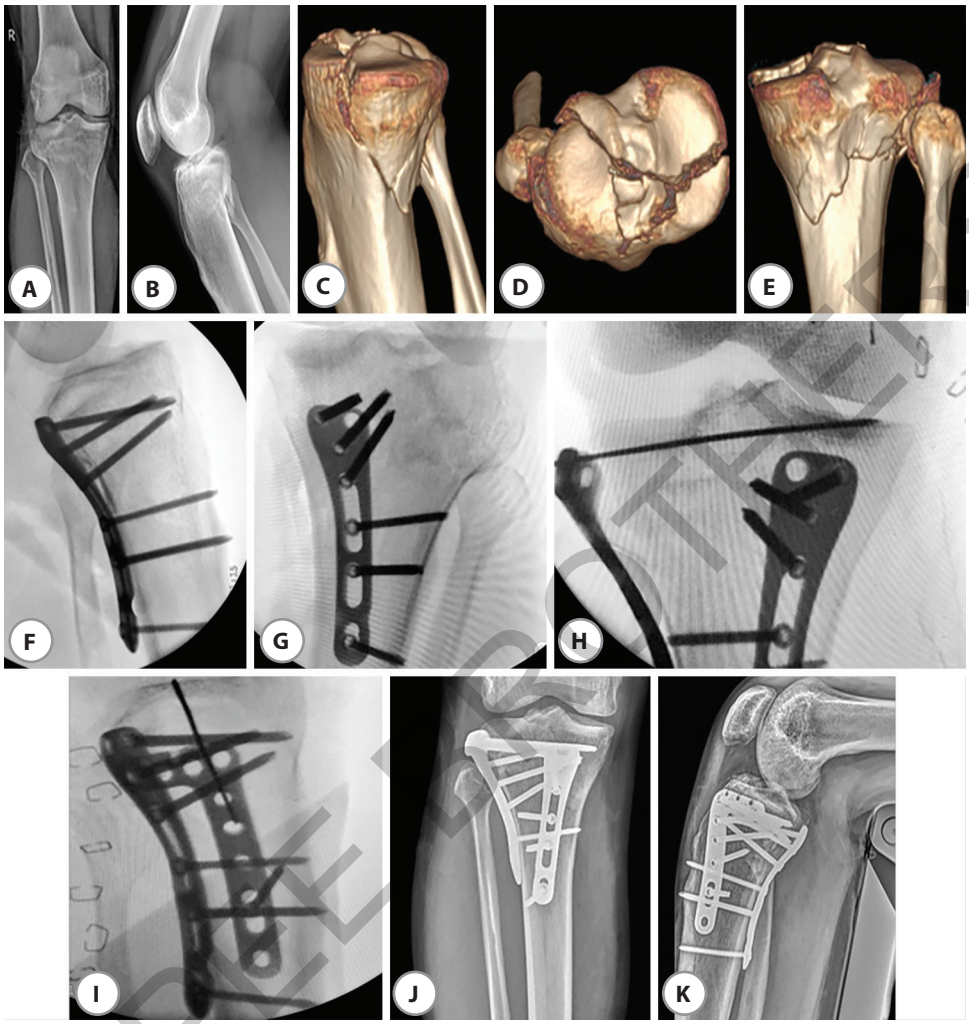

Figs 2A to K: A 40-year-old male was involved in a road traffic accident (RTA). (A and B) Plain X-rays and (C to E) CT scan show a valgus-flexion injury with a posteromedial shear fracture along with an anterolateral plateau depression. (F to I) Intraoperative C-arm images showing the initial posteromedial buttress plating followed by anterolateral plating after elevating the anterolateral fragment. (J and K) Postoperative radiographs showing excellent reconstruction of both columns.

the fracture.[16] Additional screws were inserted through the plate proximal and distal to the first screw. Generally, two screws on either side of the fracture with sufficient working length are adequate **(Figs 2F and G)**. Fracture reduction should be palpated. Unless there is significant posteromedial comminution, an arthrotomy to check joint reduction is unnecessary.

Next, with the patient in lateral position, an anterolateral approach was taken. Care should be taken to provide a skin bridge of minimum 7–8 cm between the two incisions. The depressed

JAYPEE BROTHERS

lateral plateau was then elevated to the level of the articular surface. Since there was no intraarticular comminution in this case, reduction was confirmed using fluoroscopy only. However, if need be, intraarticular congruity should be checked under direct vision by reflecting the lateral meniscus off the condyle, which can then be sutured back in place through the holes in the plate. The elevated lateral plateau was held temporarily with K-wires, which were then replaced with multiple subchondral screws passed through a lateral buttress plate, to support the elevated fragments giving a "raft" effect **(Figs 2H and I)**.[17]

Bicondylar fractures often have metaphyseal bone voids after elevation of the depressed articular fragments, due to compressed subchondral cancellous bone. These voids can be filled with autograft, allograft, or bone substitutes like calcium hydroxyapatite.[18]

Postoperative radiographs **(Figs 2J and K)** showed a stable fixation allowing immediate postoperative knee range of motion (ROM) exercises. Generally, we recommend using a hinged knee brace along with nil weight-bearing or toe touch for the first 8 weeks. Full weight-bearing is only commenced after fracture healing.

Varus-flexion Injury

- *Fracture pattern:* Flexion—posteromedial + posterolateral fragment, Varus—posteromedial fragment + anterolateral depression of medial tibial plateau.
- *Surgical plan and approach*:
  - *Floppy lateral position:* Inverted L incision—posteromedial + posterolateral buttress plate
  - *Anterolateral joint depression:* Plate with raft screws ± bone graft.

Case Example

A 53-year-old gentleman who sustained a fall from height presented with these X-rays **(Figs 3A and B)**. CT evaluation showed a medial fragment in varus and posterolateral fragments in flexion, with significant comminution of the posterior articular surface **(Figs 3C to E)**. Additionally, a major anterolateral fragment was seen, with metaphyseal-diaphyseal discontinuity. The fracture pattern indicated a varus-flexion mechanism of injury. X-rays with prominent medial fragment displacement and angulation, such as these, should raise suspicion of vascular deficit, which was ruled out in this case.

The plan was to buttress posterolateral and posteromedial fragments with two separate plates and then addressing the anterolateral fragment with plate and raft screws.

With the patient in a semiprone position, an inverted L incision **(Fig 3F)** was taken, with a long vertical limb to allow retraction of the gastrocnemius for adequate visualization. The posteromedial fragment was buttressed with a long plate which was used to address the metaphyseal-diaphyseal discontinuity as well **(Fig 3G)**. Then a small T plate was used to buttress the posterolateral comminution, placing the plate in an oblique fashion to avoid damage to the traversing vessels distally **(Figs 3H and I)**. The anterolateral column was then addressed with a separate approach and buttressed with a long anterolateral plate and raft screws **(Fig 3J)**. A submeniscal arthrotomy was used to visualize the joint and ensure proper articular congruity. Finally, the meniscus was sutured to the holes on the anterolateral plate. Patient had excellent radiological and clinical outcomes at the end of 1 year follow-up **(Figs 3K to N)**.

JAYPEE BROTHERS

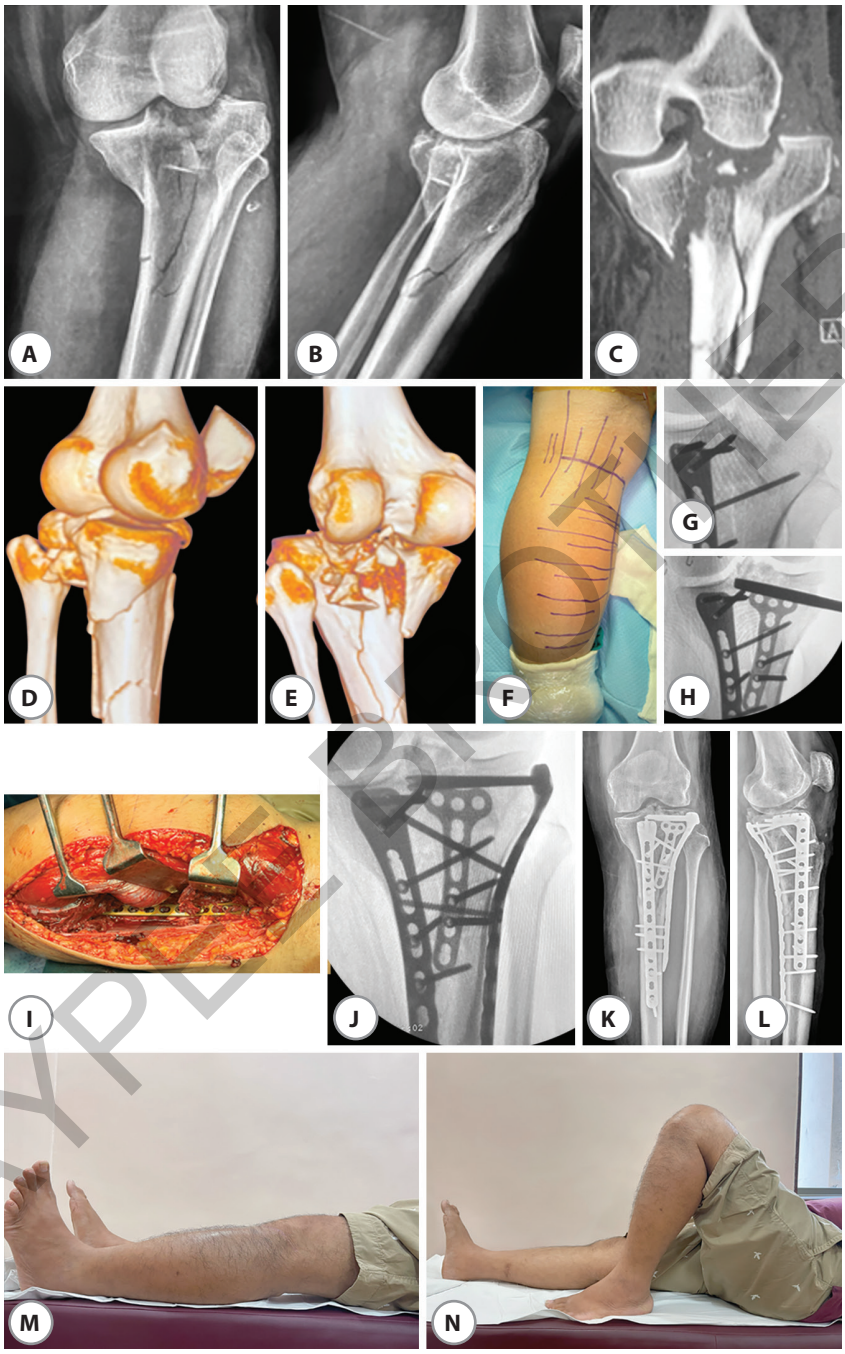

Figs 3A to N: A 53-year-old male fell from height. (A and B) Plain X-rays and (C to E) CT scans show a varus-flexion injury with posteromedial, posterolateral, and anterolateral fractures with metaphyseal-diaphyseal discontinuity. (F) Intraoperative photograph showing a posterolateral inverted L shaped incision with the patient in semiprone position. (G to I) Intraoperative images showing placement of the posteromedial and posterolateral buttress plates. (J) Intraoperative fluoroscopy image after placing the anterolateral plate and raft screws. (K and L) Postoperative radiographs showing elevation of the anterolateral fragment, excellent restoration of alignment with stable fixation. (M and N) Clinical pictures at 1 year follow-up showing painless knee range of motion from 0 to 110°.

JAYPEE BROTHERS

Compartment Syndrome

- *Fracture pattern:*
  - Medial condyle fracture + lateral joint depression
  - Compartment syndrome
- *Surgical plan and approach*:
  - Fasciotomy + knee-spanning external fixator
  - CT scan
  - Wait for wrinkles to appear
  - *Anterolateral approach:* Elevate joint line—lateral plate + raft screws
  - *Medial approach:* Plate for medial condyle fracture.

Case Example

A 35-year-old male presented 5 days postinjury (RTA) from a peripheral center with blebs on the affected leg **(Fig 4A)**, with features suggestive of compartment syndrome. He was taken up on the same day for compartment decompression **(Fig 4B)**, and external fixator **(Figs 4C and D)**.

Subsequent CT evaluation showed medial column discontinuity with a big medial fragment and anterolateral column fracture with comminution **(Figs 4E and F)**. After the blebs settled and wrinkles appeared, patient was taken up for fixator removal and definitive fixation. In supine position, the medial fragment was addressed with a posteromedial buttress plate using a posteromedial approach. The anterolateral column

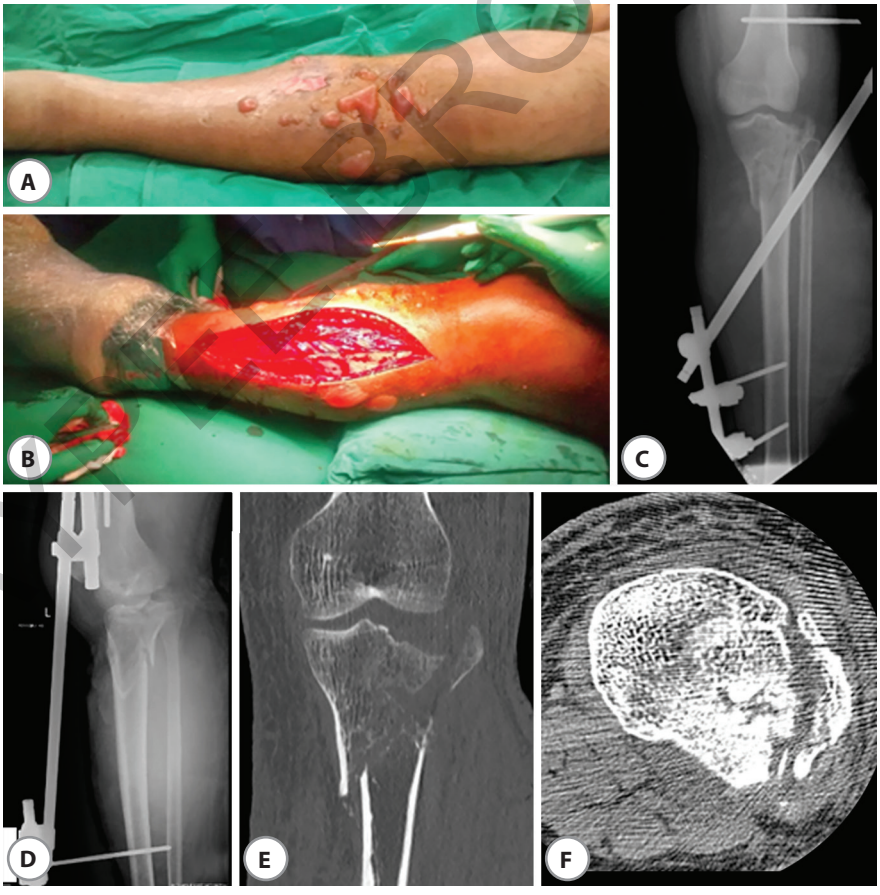

Figs 4A to J: *Continued*

JAYPEE BROTHERS

Continued

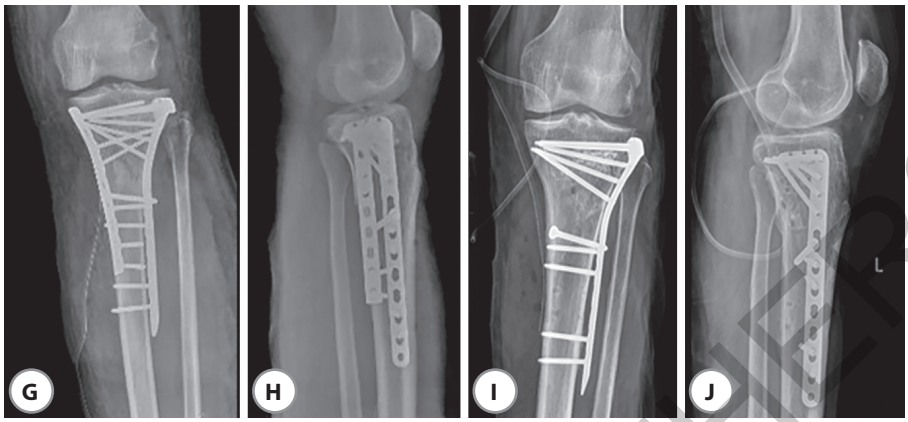

Figs 4A to J: A 35-year-old male presented 5 days postinjury [road traffic accident (RTA)] from a peripheral center with (A) Blebs on the affected leg and features suggestive of compartment syndrome. (B) He was taken up for surgery the same day for compartment decompression and knee-spanning external fixator. (C to F) Plain X-rays and Ct scans done after external fixation showed a medial condyle fracture with an anterolateral fracture. (G and H) Postoperative X-rays following posteromedial and anterolateral stabilization. (I and J) X-rays at 1 year follow-up.

comminution was fixed with a raft plate **(Figs 4G and H)**. The compartment decompression wound was covered with split thickness skin graft.

Fracture united as expected in 6 months. Two years later the medial plate had to be removed owing to deep infection. Further follow-up was uneventful **(Figs 4I and J)**.

Four-column Injury with Valgus-flexion Pattern

- *Fracture pattern:* Posteromedial + posterolateral + anterolateral + anteromedial fragments (all four columns).
- *Surgical plan and approach*:
  - *Floppy lateral position:* Inverted L incision—posteromedial + posterolateral + anteromedial plates (all three plates in one approach).
  - *Supine/lateral position*: Separate anterolateral incision—raft screws through plate.

Case Example

A 48-year-old male was involved in a motorcycle accident. He presented with a comminuted proximal tibia fracture **(Figs 5A and B)**. CT scan showed a flexion-valgus injury involving all four columns **(Figs 5C to E)**. With the patient in prone position, a reverse L incision was taken posteromedially **(Fig 5F)**. Both the posteromedial and posterolateral fragments were anatomically reduced and buttressed using separate plates **(Figs 5G and H)**. Short screws were inserted in the proximal fragment so as to subsequently accommodate the medial and anterolateral plate raft screws. The distal end radius plate used for buttressing the posterolateral fragment is placed in an oblique manner so as to avoid injury to the vascular bundle at the back **(Figs 5I to K)**. After putting a medial buttress plate and closing the reverse L incision, an anterolateral approach **(Fig 5L)** was taken with patient in lateral position to address the anterolateral column **(Figs 5M and N)**.

JAYPEE BROTHERS

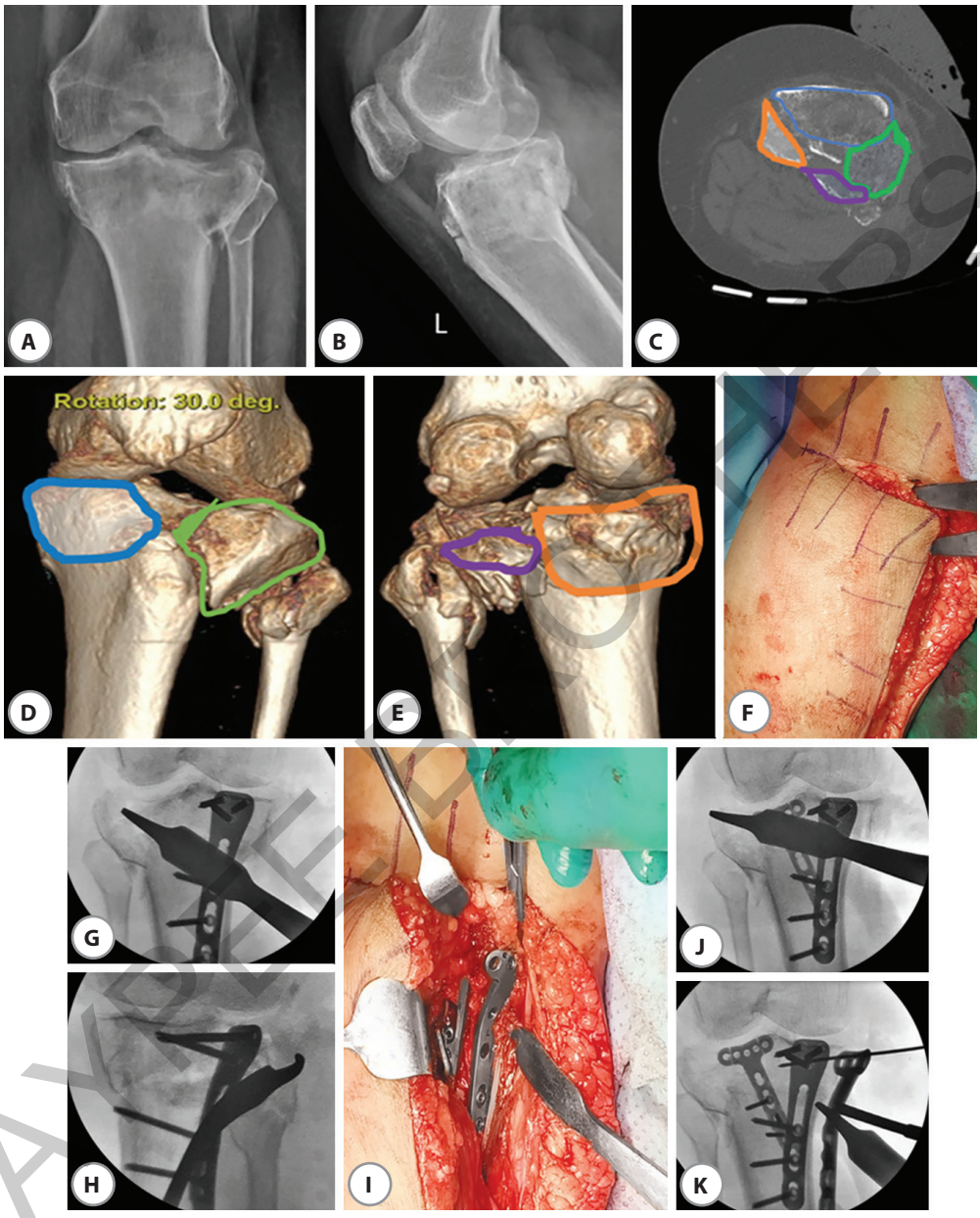

Figs 5A to N: *Continued*

JAYPEE BROTHERS

Continued

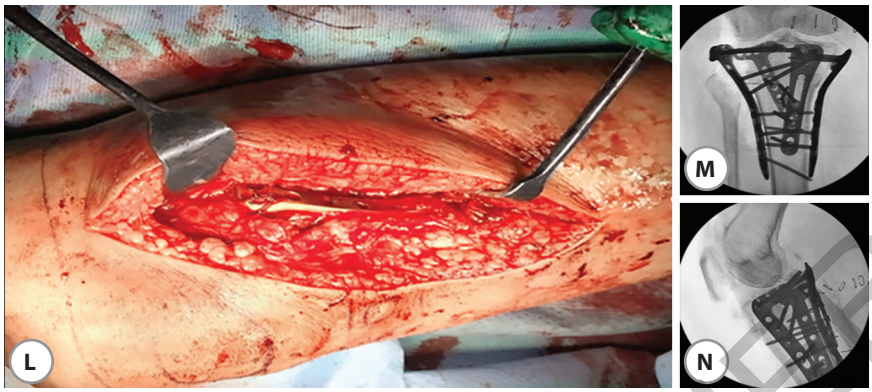

Figs 5A to N: A 48-year-old male was involved in a motorcycle accident. (A and B) Plain X-rays and (C to E) CT scans reveal a four-column proximal tibia fracture. (F) A posteromedial inverted L shaped incision was taken. (G to K) Posteromedial, posterolateral and medial buttress plates were then applied. (L) A separate anterolateral incision was then taken and the anterolateral fragment was buttressed. (M and N) Fluoroscopic images at the end revealing excellent reduction and robust fixation of the proximal tibia.

Role of Ring Fixators

Although, the use of ring fixators in the management for tibial plateau fractures is only occasional, it is a valuable tool in patients with complex, shattered proximal tibial fractures, and in patients with severe soft tissue injuries. Baloch et al, reported outcomes in 72 patients with Schatzker types III–VI injuries who were primarily managed with Ilizarov ring fixation.[19] All patients were started with knee mobilization and full weight-bearing on the first postoperative day. All fractures healed with 67 patients attaining a knee range > 100°. The average time to union and removal of external fixation is around 15 weeks.[20] The advantages of ring fixators include minimum additional soft tissue trauma, excellent stability, ability to adjust alignment postoperatively if necessary, and ability to bear weight immediately after the procedure.[19-23] An additional advantage is the low rate of infection compared to other external or internal fixation techniques.[22,23]

Conclusion

Bicondylar tibial plateau fractures are complex injuries that require nuanced diagnosis and treatment. When evaluating these fractures, it is essential to consider associated injuries in multi-traumatized patients and the high rates of soft tissue injuries, open fractures, and compartment syndrome. Plain radiographs and CT scans with 3D reconstruction are the gold standard for preoperative planning, while MRI has a limited role. We recommend using the column classification based on CT scans for their practicality and understanding of fracture morphology, which aids in operative planning. Given the heterogeneity of these injuries, the optimal timing of definitive operative treatment varies and should be considered on a case-by-case basis. Staging definitive treatment with a temporary external fixator or staged plating and delayed definitive fixation may allow for soft tissue recovery.

Buttressing remains the mainstay of addressing these fractures. Individually addressing each fractured column with column-specific plates while achieving articular congruity and metaphyseal-diaphyseal continuity should dictate patient positioning, approach, and order of fixation. Often, a dual approach is required, and more than two plates may be needed to achieve desired fixation, which should not be compromised. We encourage early postoperative ROM to avoid joint stiffness. Weight-bearing should be determined based on fracture consolidation on serial follow-up X-rays and cannot be generalized for all patients. **Flowchart 1** offers an algorithm for fixation strategies for different fracture patterns in bicondylar proximal tibial fractures.

JAYPEE BROTHERS

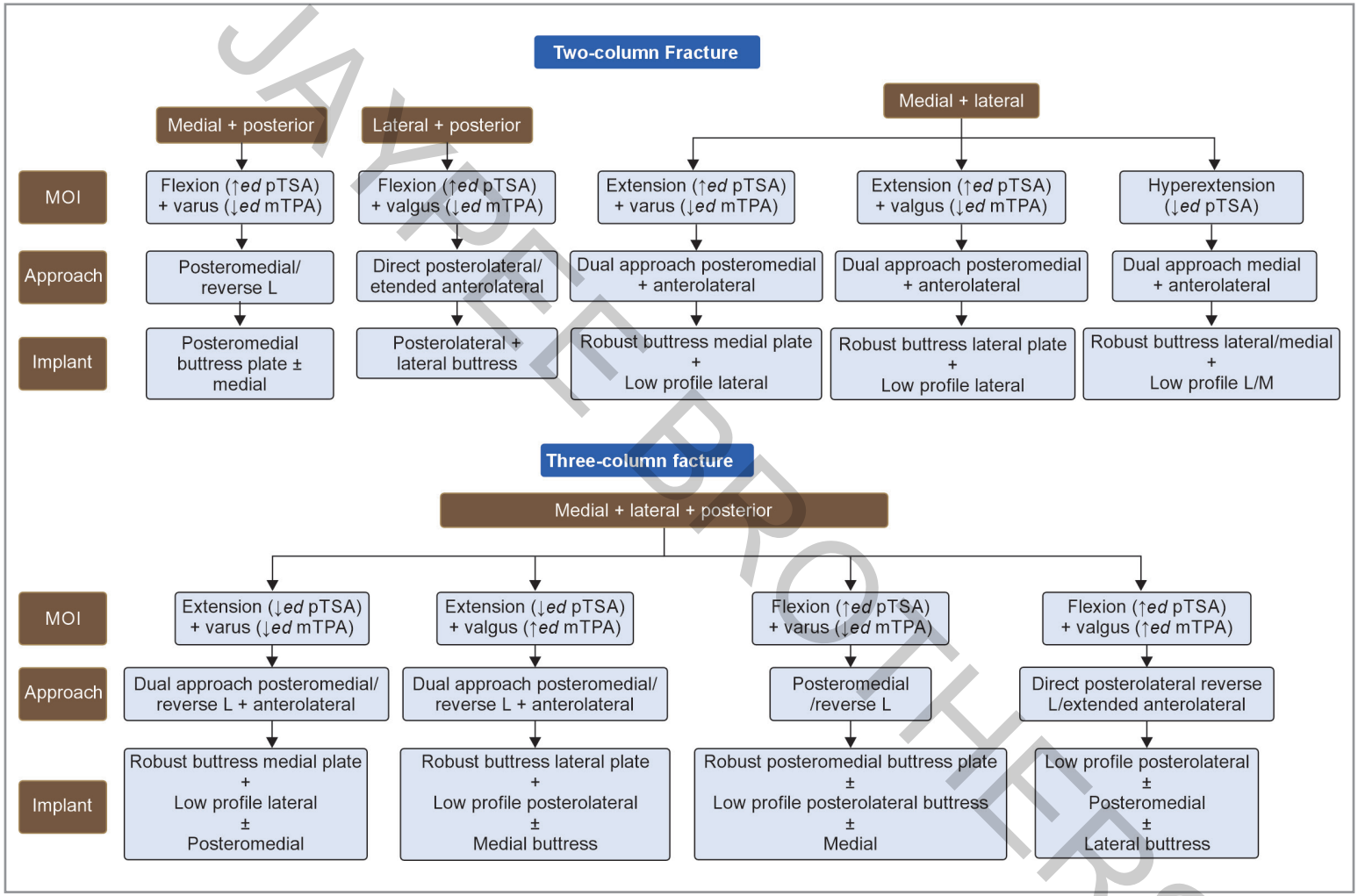

Flowchart 1: Summarizing the fixation strategy for two- and three-column fractures of the proximal tibia.

(MOI: mechanism of injury; mPTA: medial proximal tibial angle; pTSA: posterior tibial slope angle)

JAYPEE BROTHERS

KEY POINTS

- Bicondylar tibial plateau fractures are a result of high velocity injuries and are usually accompanied by extensive soft tissue injuries, compartment syndrome, and even neurovascular injuries.
- Schatzker types V and VI fractures are also commonly associated with meniscal and ligament injuries.
- Closed fractures with tense skin can be elevated and immobilized until skin turgor returns, before planning definitive treatment.
- Open fractures, closed fractures with severe soft tissue injury, or compartment syndrome are best treated with an external fixator in an emergency. Definitive internal fixation is done after adequate soft tissue healing.
- Goal of surgery is to restore articular congruity, restore alignment, and provide stable fixation that will allow early postoperative knee mobilization.
- Understanding the fracture pattern on CT scans is crucial for planning surgical approach and sequence of fixation.
- Adequate exposure of the injured column, reduction of fractured fragments, and buttressing each column are important for stability.
- Ilizarov ring fixator, though not commonly used, is a useful tool when dealing with Schatzker V and VI injuries with severe soft tissue trauma.
- Surgical site infections are a frequent complication.

JAYPEE BROTHERS

References

1. Albuquerque RP, Hara R, Prado J, Schiavo L, Giordano V, do Amaral NP. Epidemiological study on tibial plateau fractures at a level I trauma center. Acta Ortop Bras. 2013;21(2):109-15.
2. Morris BJ, Unger RZ, Archer KR, Mathis SL, Perdue AM, Obremskey WT. Risk factors of infection after ORIF of bicondylar tibial plateau fractures. J Orthop Trauma. 2013;27(9):e196-200.
3. Stannard JP, Lopez R, Volgas D. Soft tissue injury of the knee after tibial plateau fractures. J Knee Surg. 2010;23(4):187-92.
4. Ruffolo MR, Gettys FK, Montijo HE, Seymour RB, Karunakar MA. Complications of high-energy bicondylar tibial plateau fractures treated with dual plating through 2 incisions. J Orthop Trauma. 2015;29(2):85-90.
5. Molenaars RJ, Mellema JJ, Doornberg JN, Kloen P. Tibial plateau fracture characteristics: computed tomography mapping of lateral, medial, and bicondylar fractures. J Bone Joint Surg Am. 2015;97(18):1512-20.
6. Ziran BH, Becher SJ. Radiographic predictors of compartment syndrome in tibial plateau fractures. J Orthop Trauma. 2013;27(11):612-5.
7. Jansen H, Frey SP, Doht S, Fehske K, Meffert RH. Medium-term results after complex intra-articular fractures of the tibial plateau. J Orthop Sci. 2013;18(4):569-77.
8. Gardner MJ, Yacoubian S, Geller D, Suk M, Mintz D, Potter H, et al. The incidence of soft tissue injury in operative tibial plateau fractures: A magnetic resonance imaging analysis of 103 patients. J Orthop Trauma. 2005;19(2):79-84.
9. Stark E, Stucken C, Trainer G, Tornetta P 3rd. Compartment syndrome in Schatzker type VI plateau fractures and medial condylar fracture dislocations treated with temporary external fixation. J Orthop Trauma. 2009;23(7):502-6.
10. Elliott KG, Johnstone AJ. Diagnosing acute compartment syndrome. J Bone Joint Surg Br. 2003;85(5):625-32.
11. Xie X, Zhan Y, Wang Y, Lucas JF, Zhang Y, Luo C. Comparative analysis of mechanism-associated 3-dimensional tibial plateau fracture patterns. J Bone Joint Surg Br. 2020;102(5):410-8.
12. Ali AM, Burton M, Hashmi M, Saleh M. Treatment of displaced bicondylar tibial plateau fractures (OTA-41C2&3) in patients older than 60 years of age. J Orthop Trauma. 2003;17(5):346-52.

13. Schwartsman R, Brinker MR, Beaver R, Cox DD. Patient self-assessment of tibial plateau fractures in 40 older adults. Am J Orthop. 1998;27(7):512-9.
14. He X, Ye P, Hu Y, Huang L, Zhang F, Liu G, et al. A posterior inverted L-shaped approach for the treatment of posterior bicondylar tibial plateau fractures. Arch Orthop Trauma Surg. 2013;133(1): 23-8.
15. Galla M, Lobenhoffer P. Der direkte dorsale zugangsweg zur versorgung posteromedialer luxationsfrakturen des tibiakopfes. Unfallchirurg. 2003;106(3):241-7.
16. Weil YA, Gardner MJ, Boraiah S, Helfet DL, Lorich DG. Posteromedial supine approachfor reduction and fixation of medial and bicondylar tibial plateau fractures. J Orthop Trauma. 2008;22(5):357-62.
17. Kumar G, Peterson N, Narayan B. Bicondylar tibial fractures: Internal or external fixation? Indian J Orthop. 2011;45(2):116-24.
18. Russell TA, Leighton RK; Alpha-BSM Tibial Plateau Fracture Study Group. Comparison of autogenous bone graft and endothermic calcium phosphate cement for defect augmentation in tibial plateau fractures. A multicenter, prospective, randomized study. J Bone Joint Surg Am. 2008;90(10):2057-61.
19. Baloch SR, Rafi MS, Junaid J, Shah M, Siddiq F, Ata-Ur-Rahman S, et al. Ilizarov fixation method of tibia plateau fractures: A prospective observational study. Cureus. 2020;12(10):e11277.
20. Ghimire A, Devkota P, Bhandari KK, Kharel Y, Pradhan S. Ilizarov ring external fixation for complex tibial plateau fractures. Rev Bras Orthop. 2022;57(4):667-74.
21. Watson JT, Coufal C. Treatment of complex lateral plateau fractures using Ilizarov techniques. Clin Orthop Relat Res. 1998;353:97-106.
22. Catagni M, Ottaviani G, Maggioni M. Treatment strategies for complex fractures of the tibial plateau with external circular fixation and limited internal fixation. J Trauma. 2007;63(5):1043-53.
23. Parameswaran AD, Roberts CS, Seligson D, Voor M. Pin tract infection with contemporary external fixation: how much of a problem? J Orthop Trauma. 2003;17(7):503-7.

JAYPEE BROTHERS

for detailed information on orthopedics books, visit our website www.ejaypee.com, for detailed information on orthopedics books, visit our website www.ejaypee.com,for detailed info

Master Series Monographs

Tibial Condyle Fractures

BOS Worldwide

Building bridges—Sharing knowledge, experience, and expertise…

The BOS Masterseries Monographs are a series of books commissioned by the Bombay Orthopaedic Society with the goal of providing updated information, decision-making algorithms, and surgical techniques on selected orthopedic conditions. Reputed orthopedicians from Mumbai, around India, and internationally renowned experts have shared their knowledge, experience, and expertise in the field through this series.

"Tibial Condyle" Fractures will be immensely beneficial to practicing orthopedic surgeons and trainees alike. The tome will also be useful to allied specialists in physiotherapy.

Key Features

- The monograph aims to serve as a single source for updated information on the management of tibial condyle fractures.
- The decision-making and surgical technique of management of various morphological injury patterns is discussed at length.
- The management of complications such as malunion and surgical site infections is outlined using case examples.
- A case series is provided to highlight the appropriate treatment option for specific clinical and radiological presentations.

Gautam Zaveri is President of the Bombay Orthopaedic Society and the Bombay Spine Society. He is the Director of Spine Surgery at the Jaslok Hospital and Research Centre, Mumbai, Maharashtra, India. He is also the Editor-in-Chief of the ASSI Monograph Series, a series of books on various spinal disorders.



Sangeet Gawhale is Professor and Unit Head at the Grant Medical College and JJ Group of Hospitals, Mumbai, Maharashtra, India. He is a Consultant Orthopedic Surgeon at the Saifee, Jaslok, and Bhatia Hospitals, Mumbai. He is a well-known traumatologist who has served as faculty on national and international trauma courses.



Vivek Shetty is a Consultant Orthopedic Surgeon at the PD Hinduja Hospital, Mahim and Khar, Mumbai, Maharashtra, India. He has been a Faculty and Chairperson of AO Trauma courses for many years.



Buy from ejaypee

JAYPEE BROTHERS

Shelving Recommendation
ORTHOPEDICS

ISBN 978-93-6616-903-3