ebsite www.jaypeebrothers.com, for detailed information on radiology books, visit our website www.jaypeebrothers.com

2nd Edition

Clinico Radiological Series

IMAGING OF INTERSTITIAL LUNG DISEASES

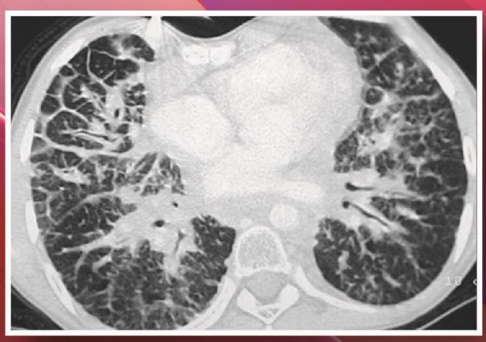

Editors
Ashu Seith Bhalla
Manisha Jana

Co-Editors
Surabhi Vyas
Priyanka Naranje

Clinical Content Editors
Anant Mohan • Vijay Hadda

JAYPEE

Contents

SECTION 1: GENERAL

1. Classification and Approach to Interstitial Lung Disease **3**
Priyanka Naranje, Manisha Jana, Anya Arora

• Classification *3* • Relevant Anatomy *4* • Approach *5*

2. Imaging Modalities for the Evaluation of Interstitial Lung Disease **16**
Kondaveeti Nikhileswar, Devasenathipathy Kansdasamy, Vimal Raj

• Chest Radiographs *16* • Computed Tomography *17*
• Magnetic Resonance Imaging *25* • Ultrasonography *26*
• Artificial Intelligence in Interstitial Lung Disease *27*

3. Interstitial Lung Diseases: Pathologic Diagnosis **30**
Deepali Jain, Shraddhanjali Satapathy

• Staining and Evaluation of Sections *30* • Histopathologic Patterns on Surgical Lung Biopsy *31* • Pathology Report Content *37* • Transbronchial Lung Biopsy *37*
• Bronchoalveolar Lavage *37* • Newer Advances *40*

4. Interstitial Lung Diseases: Clinical Evaluation **41**
Vijay Hadda, Muniza Bai

• Classification *41* • Clinical Features *41* • Laboratory Testing *46* • Role of Bronchoscopy *49* • Lung Biopsy *50*

SECTION 2: IDIOPATHIC INTERSTITIAL PNEUMONIAS

5. Idiopathic Interstitial Pneumonias: Clinical Diagnosis and Management **55**
Karan Madan, Sahajal Dhooria

• Specific Idiopathic Interstitial Pneumonia Entities *56*

6. Imaging in Idiopathic Interstitial Pneumonias **62**
Aparna Irodi, Ankur Goyal

• Classification *62* • Chronic Fibrosing Idiopathic Interstitial Pneumonia *64* • Smoking-related Idiopathic Interstitial Pneumonias *67* • Acute/Subacute Idiopathic Interstitial Pneumonias *72* • Rare Idiopathic Interstitial Pneumonias *73*
• Unclassifiable Idiopathic Interstitial Pneumonias *76*

7. Imaging Approach to Fibrosing ILD and Idiopathic Pulmonary Fibrosis **78**
Stuti Chandola, Ashu Seith Bhalla

• Part I: Fibrosing Interstitial Lung Diseases and Progressive Pulmonary Fibrosis *78* • Part II: Imaging in Idiopathic Pulmonary Fibrosis *83*

8. Interstitial Lung Abnormalities **97**
Stuti Chandola, Mandeep Garg

• Clinical Risk Factors *97* • Imaging Features *98* • Categories of Interstitial Lung Abnormality *101* • Histology *102* • Differentiation from Interstitial Lung Diseases *102* • Clinical Outcomes and Prognosis *103* • Association with Lung Cancer *103* • Evaluation and Monitoring *103* • Quantification Using Automated Analysis *104*

SECTION 3: CONNECTIVE TISSUE DISEASES/IMMUNE MEDIATED DISORDERS

9. Connective Tissue Diseases-related Interstitial Lung Disease: Clinical Diagnosis and Management **109**
Ghan Shyam Pangtey, Uma Kumar, Sujata E Mathews

• Systemic Sclerosis *110* • Mixed Connective Tissue Disease *113* • Rheumatoid Arthritis *114* • Antirheumatic Drug-induced Interstitial Lung Disease *116* • Inflammatory Myopathies Associated Interstitial Lung Disease *117* • Systemic Lupus Erythematosus *121* • Sjögren's Syndrome *121* • Approach to Connective Tissue Disease/ Systemic Autoimmune Rheumatic Disease Interstitial Lung Disease *122*

10. Connective Tissue Diseases-related Interstitial Lung Disease: Imaging Part 1 **124**
Damini S, Surabhi Vyas

• Imaging Patterns in Connective Tissue Disease-associated Interstitial Lung Disease *125* • Prognostication with Imaging Features *128* • Complications *130* • Systemic Sclerosis *132* • Rheumatoid Arthritis *135*

11. Connective Tissue Diseases-related Interstitial Lung Disease: Imaging Part 2 **140**
Surabhi Vyas, Damini S

• Idiopathic Inflammatory Myopathies *140* • Systemic Lupus Erythematosus *144* • Mixed Connective Tissue Disease *149* • Sjögren's Syndrome *151* • Interstitial Pneumonia with Autoimmune Features *152*

12. Vasculitis Related Interstitial Lung Disease: Clinical Diagnosis and Management **156**
Piyush Jain, Ghan Shyam Pangtey

• Diffuse Alveolar Hemorrhage *157* • Antineutrophil Cytoplasmic Antibody-associated Vasculitis *159*
• Granulomatosis with Polyangiitis *161*
• Eosinophilic Granulomatosis with Polyangiitis *162*
• Microscopic Polyangiitis *163* • Anti-glomerular Basement Membrane Disease/Goodpasture's Syndrome *164*
• Behçet's Disease *165*

13. Vasculitis Related Interstitial Lung Disease: Imaging **167**
Soham Banerjee, Ashu Seith Bhalla

• Terminology *167* • Classification *167* • Patterns of Thoracic Involvement *167* • Diffuse Alveolar Hemorrhage *172*
• Small Vessel Vasculitis *172* • Variable Vessel Vasculitis *178*
• Other Vasculitides with Thoracic Involvement *181*
• Pulmonary Renal Syndrome *182*

14. Sarcoidosis **184**
Ravinder Kaur, Priyanka Naranje

• Clinical Features *184* • Investigations *185*
• Imaging Classification/Staging System *185* • *Imaging* Features *185* • Lymph Nodal Involvement *186*
• Lung Parenchymal Involvement *187* • Airway Involvement *192* • Pleural Involvement *194*
• Typical and Atypical Radiological Features *195*
• Activity Assessment *196* • Common Differential Diagnosis *196*

SECTION 4: EXPOSURE RELATED DIFFUSE LUNG DISEASES

15. Exposure Related ILD: Clinical Diagnosis and Management **203**
Anant Mohan, Tejas M Suri

• Clinical Presentation *204* • History *204* • Physical Examination *205* • Laboratory Investigations *205*
• Specific Entities *206* • Hypersensitivity Pneumonitis/ Extrinsic Allergic Alveolitis *207*

16. Inorganic Dust Exposure Related Lung Disease: Imaging **210**
Aachi Kaushik Chary, Ashu Seith Bhalla, Manisha Jana

• Terminology *210* • Classification *210* • Imaging Modalities *211* • Specific Entities *214* • Silicosis *215*
• Coal Worker's Pneumoconiosis *219* • Asbestos-related Lung and Pleural Disease *222* • Talcosis *225* • Chronic Beryllium Disease *226* • Giant Cell Pneumonia Associated with Hard Metal Inhalation *227* • Siderosis *228*

• Other Inorganic Dust Exposure-related Diffuse Lung Disease *228*

17. Organic Dust Exposure Related Lung Disease: Imaging **231**
Ashu Seith Bhalla, Manisha Jana

• Classification *231* • Organic Dust Exposure *232* • Organic Dust Toxic Syndrome *232* • Biomass Fuel Exposure *232* • Noxious Fume Exposure *235* • Burns-related Lung Injury *235* • Lung Diseases in Military Personnel *236* • Chemical Pneumonitis *237* • Less Common Entities *239*

18. Hypersensitivity Pneumonitis **242**
Tany Chandra, Ashu Seith Bhalla

• Pathophysiology *243* • Specific Entities *243* • Classification *244* • Histopathological Classification and Criteria *244* • Role of Bronchoalveolar Lavage *245* • Imaging Technique *245* • Terminology *245* • Imaging Criteria *248* • Diagnosis *252* • Differential Diagnosis *252* • Clinical Course of Disease and Management *253*

SECTION 5: CYSTIC LUNG DISEASES

19. COPD and Bronchial Asthma: Clinical Aspects **259**
Saurabh Mittal, Randeep Guleria

• Chronic Obstructive Pulmonary Disease *259* • Bronchial Asthma *263*

20. Imaging in Chronic Obstructive Pulmonary Disease **266**
Chandrashekhara SH, Ashu Seith Bhalla, Mukesh K Yadav

• Basic Concepts *266* • Imaging Modalities *268* • Patterns on Computed Tomography *269* • Follow-up/ Complications *277* • Comorbidities *277* • Asthma *279*

21. Cystic Lung Disease **282**
Manisha Jana, Ashu Seith Bhalla

• Etiology of Cystic Lung Diseases *282* • Approach to Cystic Lung Disease on Imaging *282* • Lymphangioleiomyomatosis *283* • Pulmonary Langerhans Cell Histiocytosis *288* • Birt–Hogg–Dubé Syndrome *291* • Lymphoid Interstitial Pneumonia *291* • Uncommon Causes *292* • Combination of Patterns *295* • Further Evaluation *295*

SECTION 6: PEDIATRIC DIFFUSE LUNG DISEASES

22. Pediatric Diffuse Lung Diseases: Clinical Diagnosis and Management **299**
Rakesh Lodha, Sushil K Kabra

• Classification and Causes *299* • Pathophysiology *300* • Clinical Presentation *300* • Diagnosis *301* • Management *302* • Prognosis *303*

23. Imaging in Pediatric ILD: Disorders Common in Infancy **305**
Deeksha Bhalla, Manisha Jana

• Classification *306* • Diffuse Developmental Disorders *306* • Alveolar Growth Abnormalities *307* • Surfactant Dysfunction Disorders *309* • Specific Conditions of Unknown or Poorly Understood Etiology *312*

24. Imaging in Pediatric ILD: Disorders Not Specific to Infancy **317**
Deeksha Bhalla, Manisha Jana

• Disorders of Normal Host *317* • Disorders Related to Systemic Disease Processes *322* • Disorders of Immunocompromised Host *330* • Disorders Masquerading as Interstitial Lung Disease *330* • Miscellaneous Disorders *333* • Unclassified Disorders *336*

SECTION 7: ACUTE DIFFUSE LUNG DISEASES

25. Acute Interstitial Lung Diseases: Clinical and Management Issues **341**
Pawan Tiwari, GC Khilnani

• Terminology *341* • Evaluation *341* • Physical Examination *342* • Ancillary Investigations *343* • Radiology *344* • Monitoring Oxygenation *344* • Management *344* • Specific Entities *345*

26. Imaging in Acute Diffuse Lung Diseases **353**
Ashu Seith Bhalla, Manisha Jana

• Causes *353* • Imaging Modalities *354* • Pulmonary Edema *354* • Acute Lung Injury *358* • Diffuse Alveolar Damage/Acute Respiratory Distress Syndrome *359* • Acute Interstitial Pneumonia *366* • Diffuse Alveolar Hemorrhage *367* • Acute Exacerbation of Interstitial Lung Diseases *368* • Other Idiopathic Interstitial Pneumonias *369* • Acute Eosinophilic Pneumonia *370* • Infections *371* • Aspiration Syndromes *371* • Fat Embolism Syndrome *371* • Drug-induced Acute Lung Injury *372* • Malignancy *372*

SECTION 8: MISCELLANEOUS

27. Eosinophilic Lung Diseases **377**
Ashu Seith Bhalla, Manisha Jana

• Diagnostic Criteria *377* • Classification *377*
• Idiopathic Acute Eosinophilic Pneumonia *377*
• Chronic Eosinophilic Pneumonia *379* • Helminthic Infections *380* • Nonhelminthic Infections *384*
• Hypereosinophilic Syndromes *384* • Eosinophilic Granulomatosis with Polyangiitis *385* • Allergic Bronchopulmonary Aspergillosis *385* • Eosinophilic Bronchitis *385* • Drugs/Toxins-induced *385*
• Other Interstitial Lung Diseases *386* • Neoplasms *386*
• Differential Diagnosis *387*

28. Small Airway Disease **389**
Aishwarya Manoharan, Priyanka Naranje

• Terminology *389* • Evaluation of Small Airway Disease *390*
• Imaging Modalities *390* • Imaging Findings *390*
• Classification *391*

29. Drug Induced ILD **399**
Lokesh Sharma, Ashu Seith Bhalla

• Terminology *399* • Grades of Medication-induced Pulmonary Injury *400* • Imaging Patterns *400*
• Medication Classes Associated with MIPI *401*
• Clinical Scenario-based/Referring Clinic-based Approach *405* • Specific Clinical Entities/Syndromes *411*
• Toxins and Medication-induced Pulmonary Injury *412*
• EVALI (E-cigarette or Vaping Product Use-associated Lung Injury) *413*

30. Interstitial Lung Disease in Oncology **416**
Divij Agarwal, Krithika Rangarajan, Mukesh K Yadav

• Malignancies with Interstitial Lung Disease-like Appearance *416* • Treatment-related Complications *423* • Posthematopoietic Stem Cell Transplant Complications *427*

31. Diffuse Lung Disease in Immunocompromised Host **432**
Manisha Jana, Ashu Seith Bhalla

• Diffuse Lung Disease in Primary Immune Deficiency Disorders *433* • Diffuse Lung Diseases in Human Immunodeficiency Virus-related Acquired Immunodeficiency Syndrome *434* • Lung Transplant-related Disorders *437*

• Other Solid Organ Transplant Related Disorders *440*
• Pattern-wise Types of Pulmonary Infections and their Noninfectious Mimics in Solid Organ Transplant *443*

32. Imaging in Uncommon ILDs **445**
Smita Manchanda, Priyanka Naranje

• Pulmonary Amyloidosis *445* • Mediastinal Amyloidosis *448* • Pulmonary Alveolar Proteinosis *448* • Lipoid Pneumonia *449* • Interstitial Lung Disease Associated with Inflammatory Bowel Disease *450* • Pulmonary Veno-occlusive Disease and Pulmonary Capillary Hemangiomatosis *451* • Immunoglobulin G4-related Lung Disease *453* • Vanishing Lung Syndrome *454*

SECTION 9: APPROACH TO DIAGNOSIS AND ILLUSTRATIVE CASES

33. Approach to Diagnosis: Distribution of Disease **459**
Priyanka Naranje, Manisha Jana

• Basic Approach *459* • Axial/Central Lung versus Peripheral Lung *461* • Upper Lung versus Middle versus Lower Lung *465* • Anterior Lung versus Posterior Lung *469* • Asymmetric versus Symmetric *470*

34. Approach to Diagnosis: Ground-glass Opacity **474**
Krishna Kumar RG, Smita Manchanda

• Terminology *474* • Approach to Differential Diagnosis *474* • Crazy Paving Pattern *482* • Mosaic Attenuation *483*

35. Approach to Diagnosis: Linear Opacities **486**
Smita Manchanda, Surabhi Vyas

• Terminology *486* • Approach Based on Patterns *488* • Approach Based on Distribution *496*

36. Approach to Diagnosis: Nodular Pattern **498**
Krishna Kumar RG, Smita Manchanda

• Approach to Nodular Pattern *498* • Centrilobular Nodules *501* • Perilymphatic Nodules *507* • Random Nodules *508*

37. Illustrative Cases and Reporting Format **515**
Surabhi Vyas, Stanzin Spalkit

• Case 1 *516* • Case 2 *518* • Case 3 *520* • Case 4 *522* • Case 5 *524* • Case 6 *526*

Index **529**

17 Organic Dust Exposure Related Lung Disease: Imaging

Ashu Seith Bhalla, Manisha Jana

- Classification
- Organic dust exposure
- Organic dust toxic syndrome
- Biomass fuel exposure
  - Anthracofibrosis
- Noxious fume exposure
- Burns-related lung injury
  - Acute phase
  - Subacute phase
  - Delayed phase
- Lung diseases in military personnel
- Chemical pneumonitis
  - Hydrocarbon pneumonitis
- Less common entities

INTRODUCTION

- Organic dust and chemical antigens are responsible for a wide variety of occupational lung diseases.
- Organic dust exposure can also occur in nonoccupational settings.

CLASSIFICATION

The mechanism of injury may be direct or immune-mediated **(Flowchart 1)**. The more common specific entities are discussed below.[1,2] The immunologically mediated entities include hypersensitivity pneumonitis and occupational asthma. This has been covered in Chapter 18.

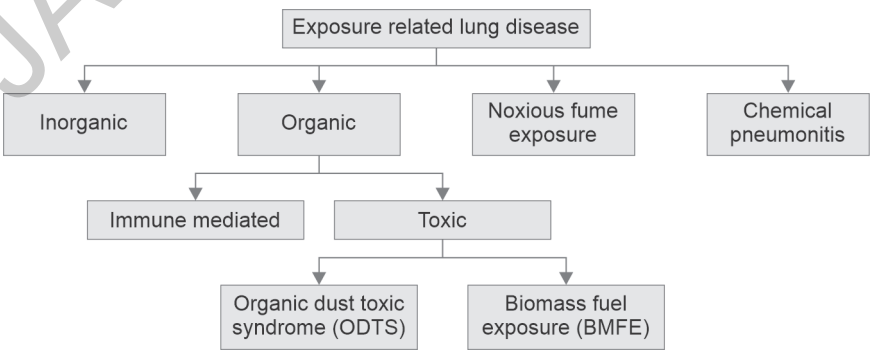

FLOWCHART 1: Classification of exposure-related lung disease.

JAYPEE BROTHERS

ORGANIC DUST EXPOSURE

- Organic dust exposure (ODE) is primarily reported in agricultural workers. Less frequently, it has also been described in other settings such as poultry, manual scavengers, carpenters, and packaging industry.
- Organic dust exposure per se in a chronic setting typically results in small airway disease/bronchiolitis.
- On computed tomography (CT), this is seen as multiple centrilobular nodules with or without peribronchial thickening and dilation.
- However, there are other mechanisms of lung injury in ODE, primarily hypersensitivity pneumonitis, which, for instance, is the main mechanism implicated in Farmer's lung. Occupational asthma is also a consequence. Microorganisms, e.g., *Aspergillus*, also predisposes to infection.

ORGANIC DUST TOXIC SYNDROME

- Endotoxins from microorganisms in bioaerosols (bacteria and actinomyces) can result in acute presentation with acute/chronic injury to the lungs/airways.
- Organic dust toxic syndrome (ODTS) results when the exposure occurs in large concentrations.
- Clinical symptoms are flu-like symptoms including fever, chest tightness, nasal and eye congestion, and cough.
- Onset may be within 24 hours or even up to a week after exposure.
- There is limited literature on imaging findings. However, as reported in byssinosis, ground-glass opacities (GGOs) and ill-defined centrilobular nodules are the main findings.
- Basal predominance may be seen.
- Organic dust toxic syndrome, however, is seldom associated with hypoxemia or respiratory compromise, unlike acute presentation of hypersensitivity pneumonitis.

BIOMASS FUEL EXPOSURE

- Biomass fuel exposure (BMFE), although reducing, is still a concern in developing countries. It is estimated that up to half of the world's population still uses biomass as a source of energy for cooking or heating.
- Biomass fuel is made of various combinations of wood, dung cakes, straw, shrubs, kerosene, and coal. On burning, biomass emits toxic fumes, which are composed of carbon monoxide, small solid particles, hydrocarbons, and formaldehyde.
- These fumes are especially harmful when burnt in small, confined spaces.
- There are several names given to these disorders depending on the type of exposure, for example, hut lung and Gujjar lung.
- Chronic exposure to these fuels can lead to a variety of respiratory illnesses.

JAYPEE BROTHERS

- These include respiratory infections, chronic obstructive pulmonary disease, asthma, anthracosis, and lung carcinoma.

Imaging features **(Figs. 1 and 2)** change depending on the predominant pattern of involvement and include hyperinflation, mosaic attenuation, GGO, bronchial wall thickening and cuffing, and centrilobular nodules (changes of SAD).

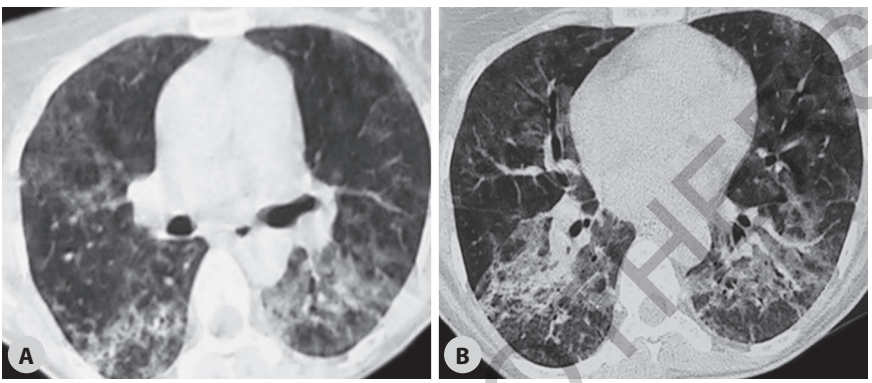

FIGS. 1A AND B: ***Biomass fuel exposure*** (acute exposure to chullah smoke). CT images reveal GGO with subtle interlobular septal thickening.

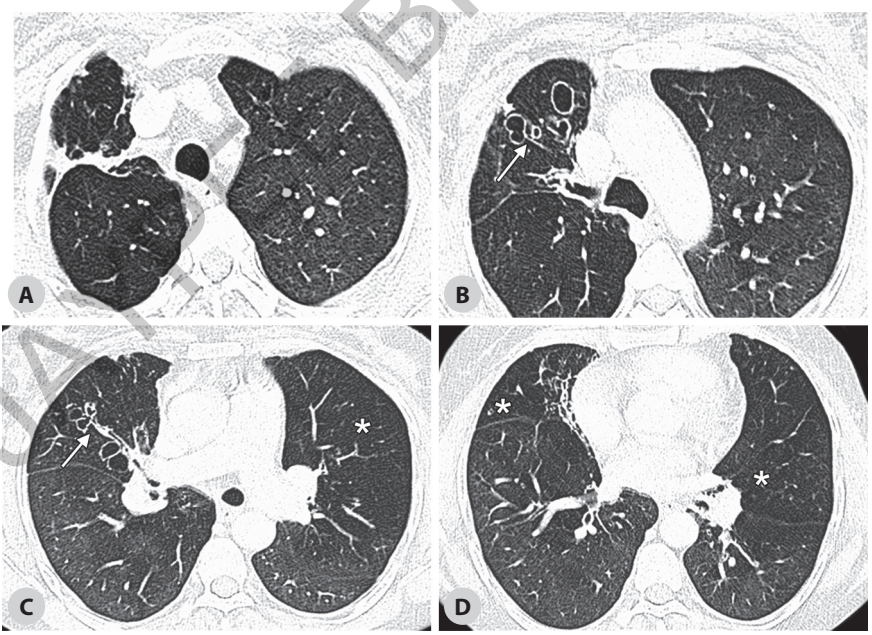

FIGS. 2A TO D: ***Chronic biomass fuel exposure*****.** CT images reveal upper lobe fibrosis, traction bronchiectasis (arrows), and lower lobe compensatory emphysematous changes (asterisks).

JAYPEE BROTHERS

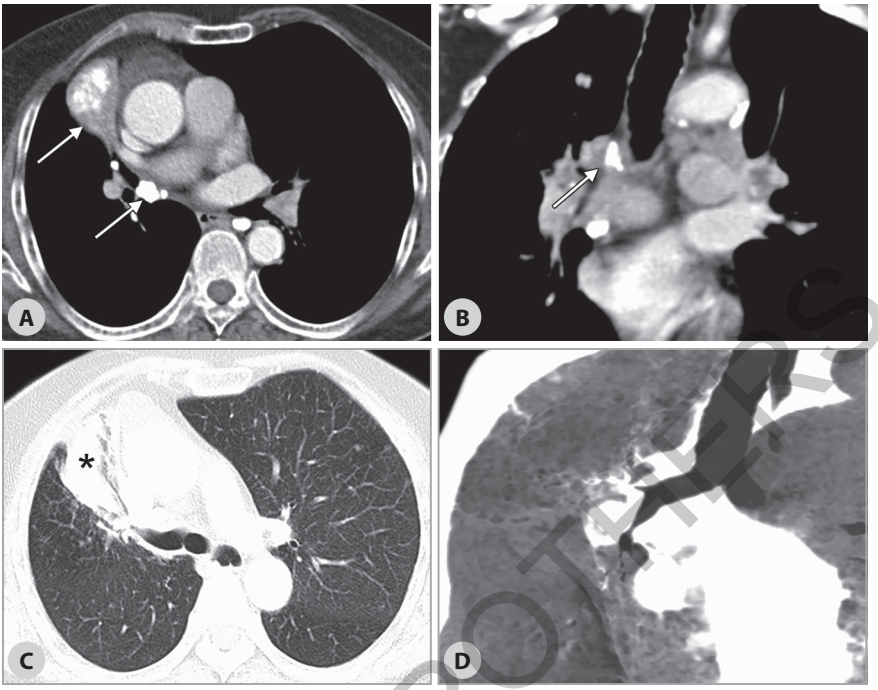

FIGS. 3A TO D: ***Bronchial anthracofibrosis.*** (A and B) Calcified mediastinal nodes and a pulmonary mass with calcification (arrows in A and B). (C and D) Right middle lobe bronchial narrowing and RML collapse (asterisk).

Anthracofibrosis

- Bronchial anthracofibrosis is a recently recognized entity, over the last decade or so. Anthracosis refers to black pigment deposition seen in the bronchial mucosa on bronchoscopy. It results from the deposition of carbon, silica, or other air pollutants. When resulting in fibrosis (bronchial stenosis), it is referred to as anthracofibrosis.[3]
- The term is used when there is no occupational exposure to silica/coal. It has been reported in middle-aged/elderly adults, especially females. This gender predilection is because of its association with biomass fuel exposure.
- It is often associated with active tuberculosis (TB)/sequelae of TB. CT findings are predominantly of bronchial stenosis, peribronchial thickening, and calcified nodes. However, lung changes are also reported in this condition. Pulmonary changes include atelectasis/collapse (most commonly right middle lobe), conglomerate masses as in progressive massive fibrosis (PMF), and also multiple nodules **(Figs. 3A to D)**.
- Differentials include silicosis, TB, and carcinoma lung. The nodes of anthracosis may show uptake on 18FDG PET CT further confusing the diagnosis. There is, however, no occupational exposure to coal/silica.

JAYPEE BROTHERS

NOXIOUS FUME EXPOSURE

- Noxious fume exposure can result in acute direct lung injury as well as chronic lung parenchymal changes.
- Various gases such as nitric oxide, sulfur dioxide, ammonia, and chlorine have been implicated. Acute exposure can cause increased capillary permeability edema, whereas chronic exposure leads to obliterative bronchiolitis.
- Two examples include burns-related lung injury and lung diseases in military personnel.

BURNS-RELATED LUNG INJURY

- Burns-related injury can be broadly divided into the following three major pathologies:
  i. Heat-related upper airway damage
  ii. Chemical damage to lower airways
  iii. Systemic toxicity due to carbon monoxide or cyanide exposure
- The factors determining burns-related injury include the physical properties of the toxin, duration of exposure, temperature of the smoke, and host factors.
- Heat injury typically affects the upper airway by direct exposure to heated air, and reflex closure of the glottis protects the lower airway. Excessive swelling of the tongue, epiglottis, and aryepiglottic folds can happen within a few hours, resulting in obstruction.
- Chemical injury to the lower airways takes place due to the toxins contained in the smoke. The nature of the toxin depends on the material burnt. Sulfur dioxide is produced when plastic or rubber is burnt, cyanide is released from laminated furniture, and aldehydes are released from cotton/wool combustion. Nitrogen dioxide, ammonia, and chlorine are other components in the smoke that can cause direct chemical injury to the airways. Due to the low heat capacity of air and the efficient bronchial circulation regulating the temperature of the airway gases, most gases are at body temperature when they pass through the glottis.
- Pulmonary parenchymal changes are toxin-mediated and occur hours after the injury. The major derangements that follow inhalation injury include edema, lowered pulmonary compliance following extravascular lung water and pulmonary lymph, and sudden inactivation of the surfactant. Pulmonary edema and ARDS may result.

Acute Phase

- This manifests within 24 hours. The changes are mainly due to direct inhalational damage to the lungs and mucosal edema to the upper airways.
- *Imaging*: Bronchial edema and subglottic edema are early imaging findings. Subglottic edema may also indicate damage to the lung parenchyma. It may also make endotracheal intubation difficult. Therefore, the

JAYPEE BROTHERS

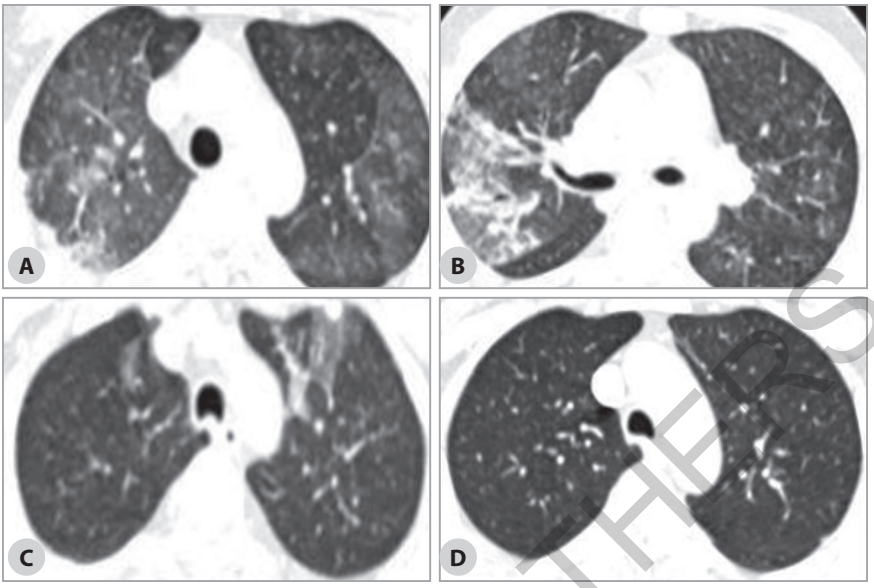

FIGS. 4A TO D: *Burns-related lung injury*. (A and B) Acute phase (48 hours). Bilateral diffuse GGO and ill-defined centrilobular nodules and RUL consolidation. (C) Partial resolution after 7 days. (D) Complete resolution after 10 days.

initial chest radiograph is an important predictor of significant smoke inhalation injuries enabling selection of patients likely to need ventilatory support **(Figs. 4A to D)**.

Subacute Phase

- The lung abnormalities that manifest between 2 and 5 days after thermal injury include pulmonary edema, atelectasis, pulmonary microembolism, and ARDS.
- *Imaging*: Variable pattern may range from normal to an almost airless appearance of the lungs. The latter is a manifestation of secondary changes such as edema, hemorrhage, or atelectasis.

Delayed Phase

The changes evident after the fifth day include pulmonary thromboembolism, pneumonia, or ARDS.

LUNG DISEASES IN MILITARY PERSONNEL

Noxious gas and fume-related lung and airway injury have been observed in military service members, owing to exposure to sulfur gas and other noxious fumes. The CT changes consist of centrilobular nodules in acute phase, and mosaic attenuation/air trapping in chronic phases because of obliterative bronchiolitis.

JAYPEE BROTHERS

CHEMICAL PNEUMONITIS

- Chemical pneumonitis, that is, acute lung injury resulting due to direct injury by inhaled agents can be a consequence of inhalation or aspiration of gastric contents. The latter scenario is much more frequent.
- Similarly, in ingested poisons, aspirated contents, such as organophosphates or corrosives, can vary, with aspiration occurring either due to altered mental status or during gastric lavage. A complete discussion of poisons and aspiration syndrome is beyond the scope of this chapter.
- Acute exposure to inhalable noxious chemical substances may be organic or inorganic. Organic contents include organophosphates, polymer fumes, paraquat, polyvinyl chloride, and smoke. Inorganic fumes include ammonia, hydrogen sulfide, sulfur dioxide, and nitrogen oxide.
- Computed tomography in acute phase shows centrilobular nodules and GGOs. Pneumonitis can occur when exposed to high doses **(Figs. 5A and B)**.
- Bronchiolitis obliterans like picture may develop weeks to months following acute exposure. CT in chronic phase can show air trapping/mosaic perfusion and bronchiolectasis.

Hydrocarbon Pneumonitis

- Chemical pneumonitis secondary to hydrocarbon ingestion/inhalation is mostly accidental. For *lipoid pneumonia*, *see* Chapter 32.
- The specific toxicity of a hydrocarbon exposure is determined by the route, type of chemical compound, and amount of exposure. Although hydrocarbons are toxic to essentially all body systems, the most important toxicities occur in the lungs, brain, and heart.
- Pulmonary aspiration and chemical pneumonitis are major features of hydrocarbon ingestion. The resultant pathology is severe necrotizing pneumonia. Other findings include direct destruction of the airway epithelium, alveolar septae, and pulmonary capillaries, as well as solubilization of the lipid surfactant layer.

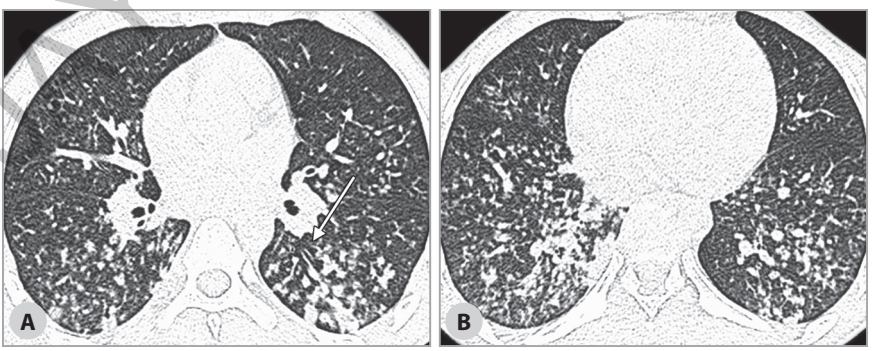

FIGS. 5A AND B: Chemical pneumonitis in mosquito repellent "All out" poisoning and aspiration. Centrilobular nodules in both lungs, confluent at places, and peribronchial thickening (long arrow).

JAYPEE BROTHERS

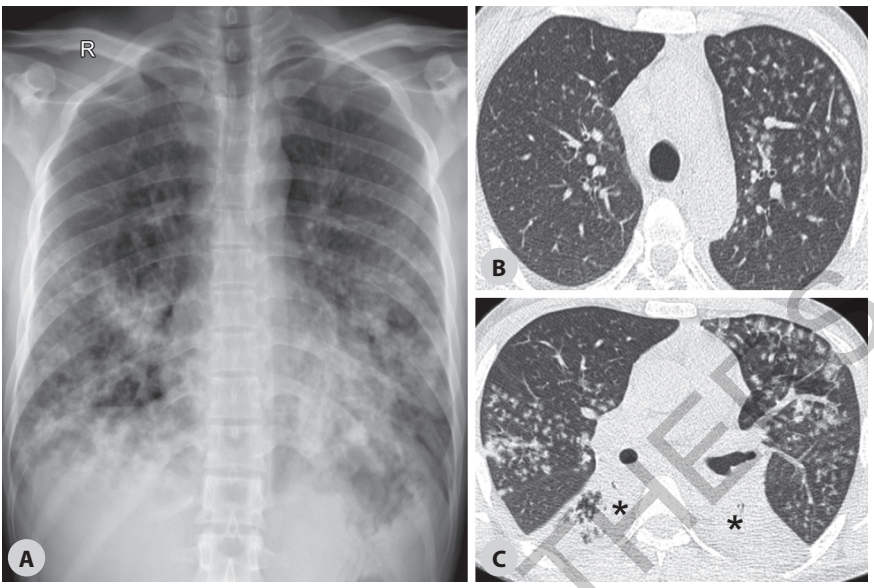

FIGS. 6A TO C: ***Hydrocarbon pneumonitis*** in a 30/M with history of diesel siphoning. (A) CXR showing dependent patchy consolidation in both lower lobes. (B and C) Bilateral lower lobe collapse (asterisks), and extensive centrilobular nodules in both upper lobes.

- Kerosene, gasoline, mineral spirits, mineral seal oil, turpentine, and other petroleum distillates are examples of low viscous and low surface tension hydrocarbons, with high volatility. They have high potential to cause aspiration pneumonitis but rarely cause systemic symptoms except in the setting of massive ingestion.
- Aromatic hydrocarbons (e.g., benzene and toluene), halogenated hydrocarbons (e.g., trichloroethylene), and pine oil primarily produce toxicity through systemic absorption via the gastrointestinal tract or the lungs. Inhalation of high concentrations of highly volatile hydrocarbons, particularly halogenated hydrocarbons, can cause lung irritation with pulmonary edema.
- In patients who ultimately manifest pulmonary aspiration after hydrocarbon ingestion, the radiographic findings of hydrocarbon aspiration are evident in most individuals within 6 hours of exposure. Radiographic abnormalities typically peak by 48 hours after aspiration.
- Initial radiographic findings of pulmonary aspiration/chemical pneumonitis consist of multiple, small, patchy densities with ill-defined margins. The lesions become larger and coalesce as the injury progresses **(Figs. 6A to C)**.
- In some cases, the radiographic findings may be minimal at a few hours and then rapidly progress to extensive infiltrates. Emphysema or pneumothorax may also develop. The resolution of radiographic changes is gradual and lags behind clinical improvement.

JAYPEE BROTHERS

- Pneumatoceles may develop within 1–2 weeks after aspiration despite clinical improvement.
- Hydrocarbon pneumonitis can be diagnosed by the presence of lipid-laden macrophages in bronchoalveolar lavage (BAL) fluid on the basis of a history of hydrocarbon aspiration.

LESS COMMON ENTITIES

Less frequently encountered entities are enumerated in **Table 1**.

TABLE 1: Organic dust exposures and their clinicoradiopathologic features.

Disease	*Occupation/agent*	*Clinicoradiopathologic findings*
Byssinosis/brown lung disease/ Monday fever **(Figs. 7A and B)**	• Cotton dust, especially in a closed environment. Effect direct/due to gram-negative bacteria • Raw cotton, flax, and hemp	• Direct irritant • Symptoms most marked on the first day of the work week • Imaging not well described • Ill-defined nodules
Flavor worker's lung	2–3 butanedione, a diacetyl used in the flavoring of microwave popcorn	• *Pathology*: Constrictive bronchiolitis • *Imaging findings—chest radiograph*: Normal/hyperinflated lung fields • *HRCT*: Air trapping/mosaic attenuation bronchial wall thickening, bronchiectasis (volume loss of upper lobes, subpleural nodules)
Indium	Television manufacturing used in the coatings	• Pulmonary alveolar proteinosis type picture crazy paving pattern • *Less common*: Nodules (centrilobular nodules or perilymphatic) subpleural emphysematous blebs
Farmer's lung **(Figs. 8 and 9)**	Agricultural products (e.g., hay dust, mold spores, thermophilic actinomycetes, and aspergillus)	• Hypersensitivity pneumonitis (type III pattern) • *Imaging*: Similar to HP
Flock worker's lung	Ultra-fine nylon fiber used in fabrics	• Lymphoid hyperplasia, lymphocytic follicular bronchiolitis, and peribronchiolitis • Micronodules, patchy GGO, and consolidation
Ardystil syndrome	Aerosolized Acramin FWN used in textile printing	Organizing pneumonia pattern (peripheral patchy bronchocentric consolidations)

(GGO: ground-glass opacity; HRCT: high-resolution computed tomography)

JAYPEE BROTHERS

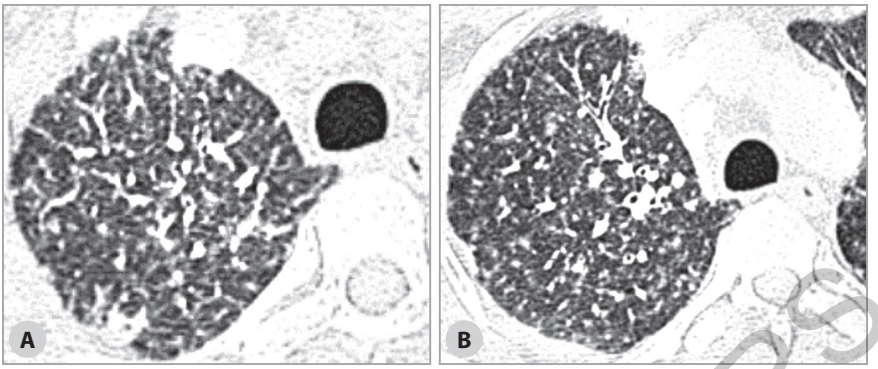

FIGS. 7A AND B: *Byssinosis*. Diffuse centrilobular nodules scattered over both lungs. Interspersed septal thickening at the apices.

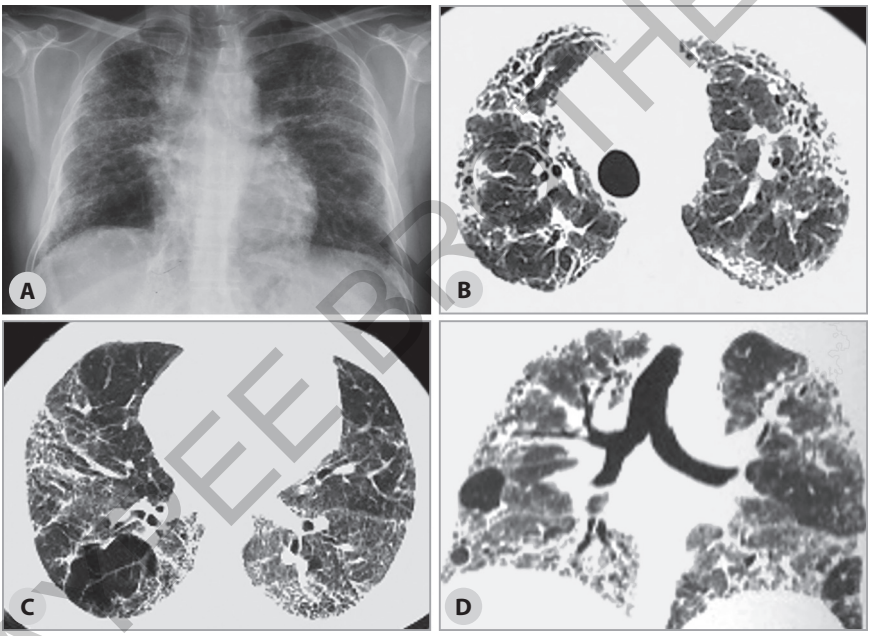

FIGS. 8A TO D: *Farmer's lung*. (A) Reticular shadows in peripheral subpleural distribution, hyperinflation. (B to D) Interlobular septal thickening, fibrosis, traction bronchiectasis, and honeycombing in bilateral peripheral subpleural distribution, mosaic attenuation.

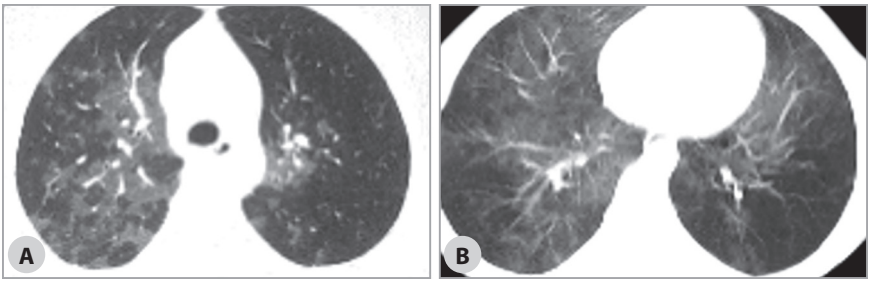

FIGS. 9A AND B: *Farmer's lung*. CT reveals bilateral central perihilar ground glass opacities.

JAYPEE BROTHERS

REFERENCES

1. Cox CW, Rose CS, Lynch DA. State of the art: imaging of occupational lung disease. Radiology. 2014;270:681-96.
2. Satija B, Kumar S, Ojha UC, Gothi D. Spectrum of high-resolution computed tomography imaging in occupational lung disease. Indian J Radiol Imaging. 2013;23(4): 287-96.
3. Gupta A, Shah A. Bronchial anthracofibrosis: an emerging pulmonary disease due to biomass fuel exposure. Int J Tuberc Lung Dis. 2011;15(5):602-1.

JAYPEE BROTHERS

for detailed information on radiology books, visit our website www.jaypeebrothers.com, for detailed information on radiolo

Clinico Radiological Series

IMAGING OF INTERSTITIAL LUNG DISEASES

Salient Features

- Focuses on core imaging and management issues in interstitial lung diseases
- Provides a comprehensive visual representation of diffuse lung diseases including but not limited to interstitial lung diseases
- Presents complex topics in a simple and lucid manner
- Extensive coverage of newer classification and terminology
- Shows unique arrangement of sections having a combined clinical and radiological perspective of the disease
- Includes high quality images and illustrations with detailed description of the disease entities
- Acts as a ready-reckoner guide to the radiologists in practice on how to reach a differential diagnosis
- Consists of comprehensive algorithmic decision trees for the key radiological abnormality, to guide you to reach a particular diagnosis
- Attempts to provide tables of close radiological differentials
- Aims to become a 'vade mecum' for all the radiologists and physicians involved in this field.

Ashu Seith Bhalla MD FICR MAMS is a Professor of Radiodiagnosis and Interventional Radiology at All India Institute of Medical Sciences (AIIMS), New Delhi, India. She is a reputed radiologist with special interest in Thoracic, and Head & Neck Radiology with over 20 years experience in the field. She has over 300 publications, has authored numerous chapters in books and is on the editorial boards of several journals. She has a passion for teaching and is extensively involved in teaching programs all over the country.

Manisha Jana MD DNB FRCR is a Professor of Radiodiagnosis and Interventional Radiology at All India Institute of Medical Sciences (AIIMS), New Delhi, India. She has special interest in Pediatric and General Radiology and nurtures a love for teaching. She has published over 200 articles in reputed journals, written many book chapters, and is actively involved in teaching and research activities in the institute.

Printed in India

Available at all medical bookstores or buy online at www.ejaypee.com

JAYPEE BROTHERS
Medical Publishers (P) Ltd.
EMCA House, 23/23-B, Ansari Road,
Daryaganj, New Delhi - 110 002, INDIA
www.jaypeebrothers.com

Join us on facebook.com/JaypeeMedicalPublishers
Follow us on instagram.com/JaypeeMedicalPublishers

Shelving Recommendation
RADIOLOGY

ISBN 978-93-6616-954-5