ur website www.ejaypee.com, for detailed information on anatomy books, visit our website www.ejaypee.com, for detailed information on anatomy books, visit our website www.ejaypee.com



Dr. Wise
Innovative & Genius
AI Chatbot
access code inside



12th Edition

Singh's Textbook of
CLINICAL NEUROANATOMY

A Clinically Integrated Approach with *Case Scenarios & Clinical Applications*

As per the Revised Competency-based Medical Education Curriculum (NMC)

Revised & Edited by **Kanchan Kapoor**



Genuine?
Scratch, Scan
& Validate

diginerve®
A Jaypee Initiative
• Video Lectures • Dr. Wise AI Chatbot
• Question Bank • Notes
Download App

JAYPEE

Contents

1. Development of Nervous System 1

- Neurulation *1*
- Neural Crest *2*
- Development of Brain *3*
- Flexures of Brain *3*
- Development of the Ventricular System *4*
- Development of Circumventricular Organs *4*
- Neural Tube Defects *11*

2. Introduction to Nervous System 17

- Divisions of the Nervous System *17*
- Tissues Constituting the Nervous System *18*
- Structure of a Typical Neuron *18*
- Neuroglia *22*

3. Peripheral Nervous System 26

- Peripheral Nervous System *26*
- Classification of Peripheral Nerve Fibers *28*
- Myelin Sheath and Process of Myelination *28*
- Typical Spinal Nerve *29*
- Synapse *31*
- Neurotransmitters *32*
- Innervation of Skeletal Muscle *33*
- Loss of Innervation to a Skeletal Muscle *34*
- Receptors *35*
- Segmental Innervation *35*
- Ganglia *38*

4. Autonomic Nervous System 42

- Efferent Autonomic Pathway *43*
- Sympathetic Nervous System *44*
- Autonomic Plexuses *45*
- Parasympathetic Nervous System *46*
- Neurotransmitters of Autonomic Neurons *48*
- Afferents Accompanying Autonomic Pathways *49*
- Autonomic Nerve Supply of Some Important Organs *51*

5. Central Nervous System: General Considerations 62

- Parts of the Brain *62*
- Organization of Gray Matter *64*
- Base of the Brain *65*
- Meninges of the CNS *65*

6. Spinal Cord 69

- Extent and Dimensions of the Cord *69*
- Enlargements of the Cord *70*
- Age-Wise Changes in the Cord *70*

- Functions of Spinal Cord *70*
- Spinal Meninges *71*
- External Features of the Spinal Cord *72*
- Spinal Segments *72*
- Internal Features of Spinal Cord *74*
- Variation in the Internal Structure of Spinal Cord at Different Levels *74*
- Microscopic Structure of Spinal Cord *76*
- Neurons in the Gray Matter *76*
- Nuclei in Gray Matter *77*
- White Matter *78*
- Tracts in the Spinal Cord *78*
- Ascending Tracts *78*
- Descending Tracts *85*
- Somatotopic Lamination *88*
- Intersegmental Tract or Propriospinal Tract *88*
- Spinal Reflexes *88*
- Blood Supply of Spinal Cord *91*
- Lesions of Spinal Cord *93*

7. Medulla Oblongata 99

- External Features *99*
- Internal Features of Medulla *101*
- Transverse Section through Medulla Oblongata at the Level of Pyramidal Decussation (the Great Motor Decussation) *101*
- Section through Medulla Oblongata at the Level of Sensory Decussation (Lemniscal Decussation) *102*
- Section through Medulla Oblongata at the Level of Olive (Open Level) *103*
- Cranial Nerve Nuclei in Medulla Oblongata with their Functional Groups *106*
- Blood Supply of Medulla Oblongata *107*

8. Pons 112

- External Features of Pons *112*
- Internal Features of Pons *113*
- Transverse Section through the Lower Part of Pons (at the Level of Facial Colliculi) *115*
- Section through the Upper Part of Pons (at the Level of Trigeminal Nerve) *116*
- Cranial Nerve Nuclei in Pons *116*
- Blood Supply of Pons *119*

9. Midbrain 123

- External Features of Midbrain *123*
- Internal Features of Midbrain *124*
- Section through Midbrain at the Level of Inferior Colliculi *125*
- Section through Midbrain at the Level of Superior Colliculi *127*
- White Matter *128*
- Cranial Nerve Nuclei *128*
- Blood Supply of Midbrain *129*

10. Cerebellum 133

- External Features *133*
- Subdivisions of Cerebellum *136*
- Internal Structure of Cerebellum *137*

- Gray Matter *137*
- Deep Cerebellar Nuclei *139*
- White Matter of Cerebellum *140*
- Connections of Cerebellum *142*
- Cerebellar Peduncles *142*
- Connections between Cerebellum and Spinal Cord *145*
- Connections between Cerebellum and Cerebral Cortex *145*
- Functions of Cerebellum *146*
- Cerebellum and Learning *147*
- Arterial Supply of Cerebellum *147*
- Cerebellum: The Rule of Three *147*

11. Diencephalon **152**
- Thalamus *152*
- Metathalamus *161*
- Hypothalamus *163*
- Epithalamus *168*
- Subthalamus (Ventral Thalamus) *169*
- Arterial Supply of Diencephalon *170*

12. Cerebral Hemispheres **175**
- External Features of Cerebral Hemispheres *176*
- Superolateral Surface of Cerebral Hemisphere *178*
- Medial Surface of Cerebral Hemisphere *181*
- Inferior Surface of Cerebral Hemisphere *181*
- Functional Areas of Cerebral Cortex *181*
- Structure of Cerebral Cortex *187*
- Neurons in Cerebral Cortex *187*
- Laminae of Cerebral Cortex *188*
- Variations in Cortical Structure *189*
- Types of Cerebral Cortex *189*
- Arterial Supply of the Cerebral Cortex *189*
- Lateralization of Cerebral Hemispheres *190*

13. White Matter of Cerebral Hemispheres **196**
- Association Fibers *197*
- Commissural Fibers *198*
- Corpus Callosum *198*
- Projection Fibers *200*
- Internal Capsule *201*
- Ascending Fibers (Corticopetal Fibers) *203*
- Descending Fibers (Corticofugal Fibers) *204*
- Arterial Supply of Internal Capsule *204*

14. Basal Nuclei (Basal Ganglia) **209**
- Caudate Nucleus *211*
- Lentiform Nucleus *211*
- Connections of Corpus Striatum *212*
- Subthalamic Region *214*
- Functions of Basal Nuclei *214*
- Blood Supply of Basal Nuclei *215*

15. Limbic System and Reticular Formation **219**
- Components of the Limbic System *220*
- Olfactory Pathways *220*
- Amygdaloid Nuclear Complex *220*
- Septal Region *222*
- Hippocampal Formation *223*
- Fiber Bundles of Limbic Region *226*
- Reticular Formation of the Brainstem *226*
- Functional Divisions of Reticular System *229*
- Functions of the Reticular Formation *230*

16. Ventricles of the Brain **233**
- Lateral Ventricles *233*
- Third Ventricle *237*
- Fourth Ventricle *238*

17. Blood Supply of Central Nervous System **245**
- Blood Supply of Brain *247*
- Circle of Willis (Circulus Arteriosus) *249*
- Venous Drainage of Brain *253*
- Blood-Brain Barrier *256*

18. Meninges and Cerebrospinal Fluid **260**
- Meninges of the Central Nervous System *260*
- Cerebrospinal Fluid *267*
- Blood-Cerebrospinal Fluid Barrier *268*

19. Functional Components of Cranial Nerves **273**
- Developmental Aspects *274*
- Organization of Functional Components of Cranial Nerve *275*
- Nuclei Connected to more than One Nerve *288*

20. Pathways of Special Senses **294**
- Olfactory Pathway *294*
- Olfactory Epithelium *295*
- Visual Pathway *297*
- The Retina *297*
- Auditory Pathway *303*
- Gustatory Pathway *307*

21. Neuroimaging Techniques **312**
- Principles of Neuroimaging Techniques *312*
- Anatomical Route Used for Carotid Angiogram and Vertebral Angiogram *312*

Glossary 317

Eponyms 323

Index 327

19

CHAPTER

Functional Components of Cranial Nerves

JAYPEE BROTHERS

Specific Learning Objectives

At the end of learning, the student shall be able to:

- Describe the location of nuclei and functional components of all cranial nerves.

Scan me for Chapter's NMC Competencies or, for detailed competencies, please refer Prelims page xxix

INTRODUCTION

The term "functional component" refers to define the nature of neurons/nerve fibers in a nerve in the following aspects:

- Whether the sensation is from the effector organ to the central nervous system or from the central nervous system to the target organ **(afferent or efferent)**?
- Whether the sensation is from viscera or from body wall **(visceral or somatic)?**
- Whether the sensation is from structure derived from pharyngeal arches or not **(special or general)**?
- Whether the sensation is received from special senses, i.e., vision and auditory **special sensory afferent (SSA)**?

Keeping in view the distinction between afferent and efferent, on one hand, and somatic and visceral, on the other, the peripheral nerves can be divided into four broad categories:

1. Somatic efferent
2. Visceral efferent
3. Somatic afferent
4. Visceral afferent

With the exception of somatic efferent fibers, each of the categories named above is subdivided into a general and a special group. We thus have a total of seven functional components as follows:

1. **Somatic efferent (or somatomotor fibers):** Fibers supply striated muscle of the limbs and body wall. They also supply the extrinsic muscles of the eyeballs and the muscles of the tongue.
2. **General visceral efferent** (also called **visceromotor fibers**) supply smooth muscle and glands. The nerves to glands are called secretomotor nerves.
3. **Special visceral efferent** fibers supply striated muscles developing in branchial (pharyngeal) arch mesoderm. They are frequently called branchial **efferent or branchiomotor fibers**. The muscles supplied include those of mastication and of the face, the pharynx, and the larynx.
4. **General somatic afferent** fibers are those that carry:
   - Sensation of touch, pain, and temperature from the skin (exteroceptive impulses).
   - Proprioceptive impulses arising from muscles, joints, and tendons conveying information regarding movement and position of joints.
5. **Special somatic afferent** fibers carry impulses of:
   - Vision
   - Hearing
   - Equilibrium
6. **General visceral afferent fibers** (also called visceral sensory fibers) carry sensations, e.g., pain from viscera (visceroceptive sensations).
7. **Special visceral afferent** fibers carry the sensation of taste.

Key Point

A typical spinal nerve contains fibers of the four general categories. The special categories are present in cranial nerves only.

DEVELOPMENTAL ASPECTS

In the embryo, the nuclei related to the various components are arranged in vertical rows (or columns) in a definite sequence in the gray matter related to the floor of the fourth ventricle **(Figure 19.1)**. The sequence is easily remembered, if the following facts are kept in mind:

- Each half of the floor of the ventricle is divided into a medial part and a lateral part by the **sulcus limitans**. **Efferent nuclei** lie in the medial part (called the **basal lamina**) and **afferent nuclei** in the lateral part (called the **alar lamina**) **(Table 19.1)**.
- In each part (medial or lateral), **visceral nuclei** lie nearer the sulcus limitans than **somatic nuclei**.

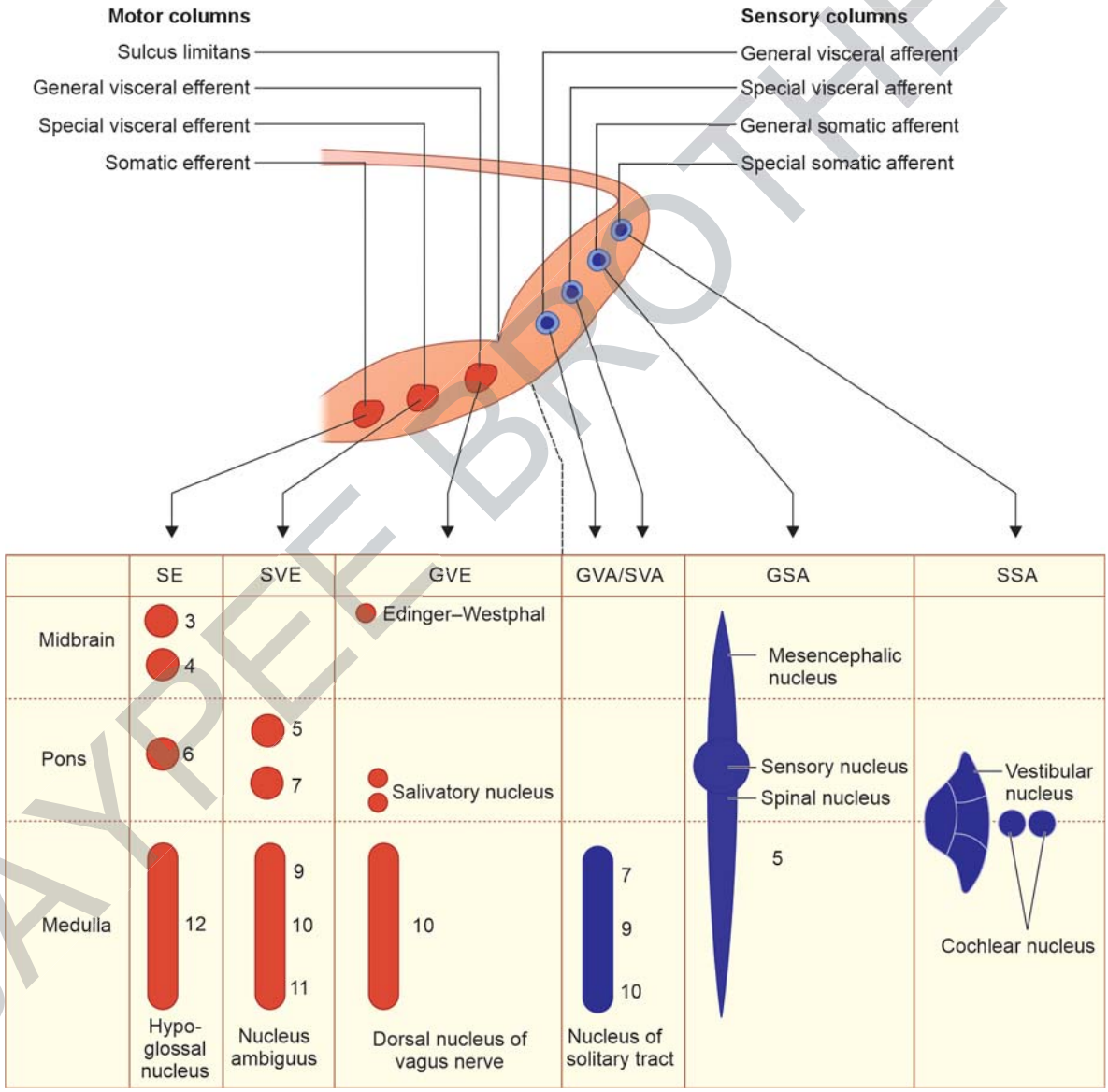

Figure 19.1: Functional classification of cranial nerve nuclei. The upper figure shows the arrangement of nuclear columns in the brainstem of the embryo. The lower figure shows the nuclei derived from each column. Numbers indicate the cranial nerves connected to the nuclei.

(GSA: general somatic afferent; GVA: general visceral afferent; GVE: general visceral efferent; SE: somatic efferent; SSA: special somatic afferent; SVA: special visceral afferent; SVE: special visceral efferent)

JAYPEE BROTHERS

Table 19.1: Functional columns and their distribution.

Basal lamina (efferent columns)		*Alar lamina (afferent columns)*	
Somatic efferent (SE)	Muscles of somatic origin: • Extraocular • Tongue (except palatoglossus)	General visceral afferent (GVA)	General sensation from viscera
Special visceral efferent (SVE)	Skeletal muscles originating from pharyngeal arches: Muscles of mastication, face, larynx, and pharynx	Special visceral afferent (SVA)	Special sensation from viscera (smell, taste)
General visceral efferent (GVE)	Peripheral parasympathetic: Smooth and cardiac muscles glands	General somatic afferent (GSA)	General sensations from body wall: Touch, pain, temperature, pressure, proprioception
		Special somatic afferent (SSA)	From special senses: Visual, auditory, and equilibrium

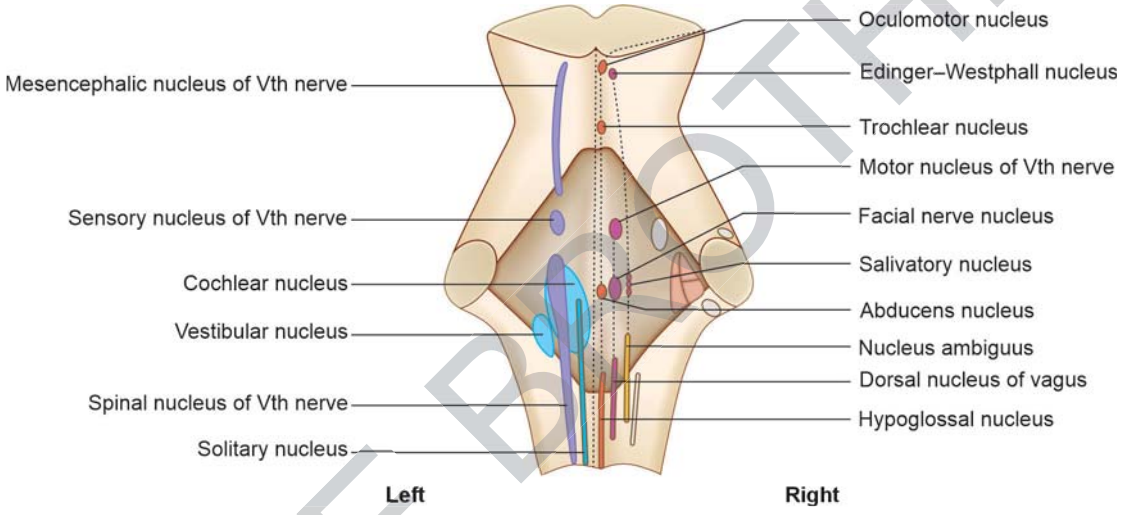

Figure 19.2: Cranial nerve nuclei on the dorsal aspect of the brainstem. Motor nuclei are shown on the right side and sensory nuclei are shown on the left side.

- Within each category (e.g., visceral efferents and somatic afferents), the **general nucleus** lies nearer the sulcus limitans than the **special nucleus**.
- Thus, in proceeding laterally from the midline, the sequence of nuclear columns is as follows:
  - Somatic efferent: This column is **not subdivided** into general and special parts
  - Special visceral (or branchial) efferent
  - General visceral efferent
  - General visceral afferent
  - Special visceral afferent
  - General somatic afferent
  - Special somatic afferent

Key Point

Each functional component has its own nuclei of origin (in the case of efferent fibers) or termination (in the case of afferent fibers).

The positions of the nuclei as seen in transverse sections of the brainstem are shown in **Figures 19.2 and 19.3A to F**.

ORGANIZATION OF FUNCTIONAL COMPONENTS OF CRANIAL NERVE

The functional components of cranial nerve nuclei are shown in **Table 19.2**. It should be noted that some of these **nuclei contribute fibers for more than one nerve**. Similarly, some of the cranial nerves consist of fibers arising from **more than one nucleus**.

The olfactory and the optic nerves are not true nerves. These are extensions of telencephalon and diencephalon, respectively. They carry the cavity of the brain (which secondarily gets obliterated) and the meninges with them.

I. Olfactory Nerve

This is the nerve of smell. As the olfactory mucosa is derived from ectoderm (of the nasal placodes), this nerve

JAYPEE BROTHERS

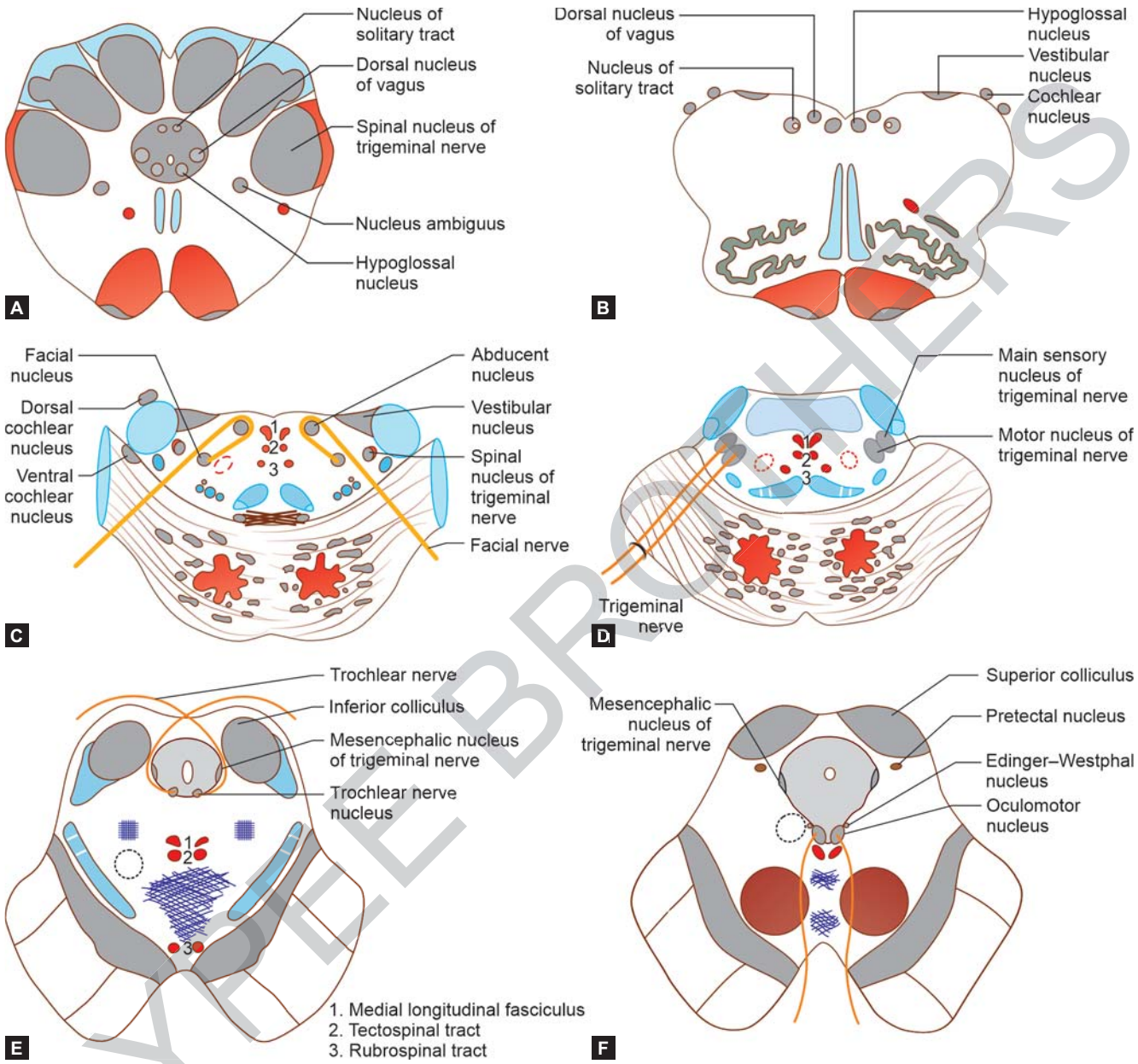

Figures 19.3A to F: Location of cranial nerve nuclei as seen in transverse sections at various levels of the brainstem. A and B: Medulla oblongata: lower and upper levels; C and D: Pons—lower and upper levels; E and F: Midbrain—lower and upper levels respectively.

JAYPEE BROTHERS

is classified, developmentally, as **special somatic afferent** (along with vision and hearing). However, in view of the close relationship between the sensations of smell and taste, this nerve is functionally classified as **special visceral afferent**.

Peripheral Distribution

- Enters the skull via the foramina of the cribriform plate of the ethmoid bone.
- Projects directly to the telencephalon.
- Synapses with mitral and tufted cells found in the olfactory bulb, an outgrowth of the telencephalon.
- The only cranial nerve that projects directly to the forebrain.

Lesions

- Results in anosmia, loss of olfactory sensation (e.g., ethmoid bone fracture).
- The olfactory epithelium is capable of regeneration after injury.

Table 19.2: The functional nuclear columns and cranial nerve nuclei.

Location	Motor (efferent)			Sensory (afferent)		
	SE	SVE	GVE	GVA/SVA	GSA	SSA
Midbrain	• Oculomotor (III) • Trochlear (IV)		Edinger–Westphal nucleus (III)		Mesencephalic nucleus of trigeminal nerve (V)	
Pons	Abducent (VI)	• Motor nucleus of trigeminal nerve (V) • Facial (VII)	Salivatory nuclei (VII, IX)		Sensory nucleus of trigeminal nerve (V)	Vestibulocochlear nuclei (VIII)
Medulla	Hypoglossal nucleus (XII)	Nucleus ambiguus (IX, X, Cr XI)	Dorsal nucleus of vagus (X)	Nucleus of the solitary tract (VII, IX, X)	Nucleus of the spinal tract of the trigeminal nerve (V)	Vestibulocochlear nuclei (VIII)
Spinal cord		Spinal accessory (Sp XI)				

(Cr: cranial; GSA: general somatic afferent; GVA: general visceral afferent; GVE: general visceral efferent; SE: somatic efferent; SSA: special somatic afferent; SVA: special visceral afferent; SVE: special visceral efferent; Sp: spinal)

- Loss of olfaction can occur as a result of some viral infections such as seen recently in COVID-19 cases.

II. Optic Nerve

This is the nerve of vision. Its fibers are **special somatic afferent**. From the point of view of its structure and development, this nerve is to be regarded as a tract of the brain rather than as a peripheral nerve.

Peripheral Distribution

- Enters the skull via the optic canal of the sphenoid bone.
- Continue via the optic chiasma and optic tracts to the lateral geniculate body, a thalamic relay nucleus that projects to the visual cortex (area 17) of the occipital lobe.
- **Not a true peripheral nerve** but a tract of the diencephalon.
- Contain fibers from the nasal retina that decussate in the optic chiasma.
- Contain fibers from the temporal retina that continue ipsilaterally through the optic chiasma.
- Invested by the dura and pia-arachnoid membranes and lies within the subarachnoid space.

Lesions

Papilledema in case of increased intracranial pressure. If transected, will result in **ipsilateral blindness and loss of direct pupillary light reflex**.

III. Oculomotor Nerve

- **Somatic efferent** fibers arise in the **oculomotor nucleus**, at the level of superior colliculus of the midbrain, and **supply all extrinsic muscles of the eyeball** except the lateral rectus and the superior oblique.
- **General visceral efferent** fibers (preganglionic) arise in the **Edinger–Westphal nucleus** and relay in the **ciliary ganglion**. Postganglionic fibers arising in this ganglion supply the sphincter pupillae and the ciliaris muscle via **short ciliary nerves**.

The general visceral efferent component of the oculomotor nerve is involved in accommodation of lens (for the near-vision) and **constriction of pupil**. The accommodation of lens is due to contraction of ciliary muscles and the constriction of pupils is due to contraction of the sphincter pupillae muscle of iris **(Figures 19.4A and B)**.

Peripheral Distribution

- Fibers of the oculomotor nerve after originating from their nuclei emerge on the surface of the brain stem in the inter-peduncular fossa.
- The nerve passes through the lateral wall of the cavernous sinus and enters the orbit through the tendinous ring.
- The nerve divides into superior and inferior division which supply the superior rectus, levator palpebrae superioris, inferior rectus, inferior oblique and medial rectus.
- Its inferior division gives the parasympathetic root to the ciliary ganglion. Post ganglionic fibers from the ciliary ganglion course through the short ciliary nerves to reach the constrictor pupillae and ciliary muscle.

Lesion

Peripheral lesion of the nerve is characterized by the divergent squint, diplopia on convergence, ptosis,

JAYPEE BROTHERS

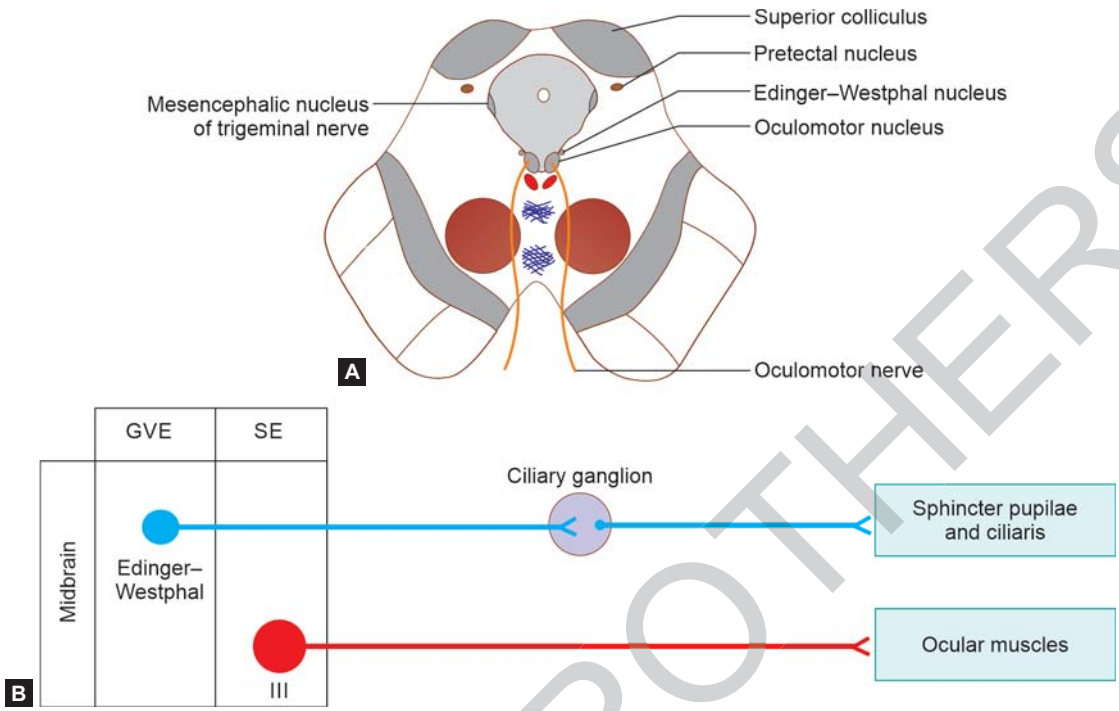

Figures 19.4A and B: Oculomotor nerve nucleus. (A) Functional components of the oculomotor nerve; (B) Oculomotor nerve nuclei. (GVE: general visceral efferent; SE: somatic efferent)

dilation of the pupil, loss of the light and accommodation reflexes.

IV. Trochlear Nerve

This nerve is made up of **somatic efferent** fibers arising in the **trochlear nucleus** from the midbrain at the level of inferior colliculus and supplies the superior oblique muscle of the eyeball **(Figure 19.5)**.

Peripheral Distribution

- The nerve courses dorsally around the periaqueductal gray matter from its nucleus and decussates with the opposite nerve before emerging on the dorsal surface of the midbrain.
- The nerve then courses around the crus cerebri to reach the ventral surface of the brain stem.
- It then reaches the orbit by passing through the lateral wall of the cavernous sinus and through the outer part of superior orbital fissure to supply the superior oblique muscle.

Lesion

Results in the slight convergent squint and diplopia on looking down.

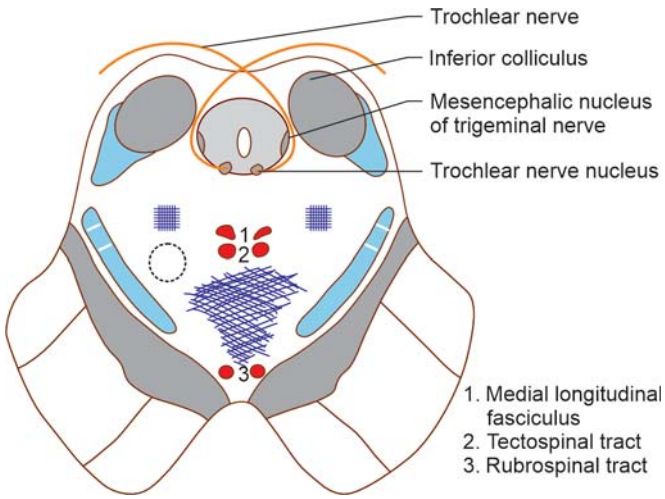

Figure 19.5: Trochlear nerve nuclei.

V. Trigeminal Nerve

This nerve contains the following components **(Figures 19.6A and B)**:

- **Special visceral efferent** fibers arise from the **motor nucleus** of the nerve located at the level of upper pons and supply the muscles of mastication.

JAYPEE BROTHERS

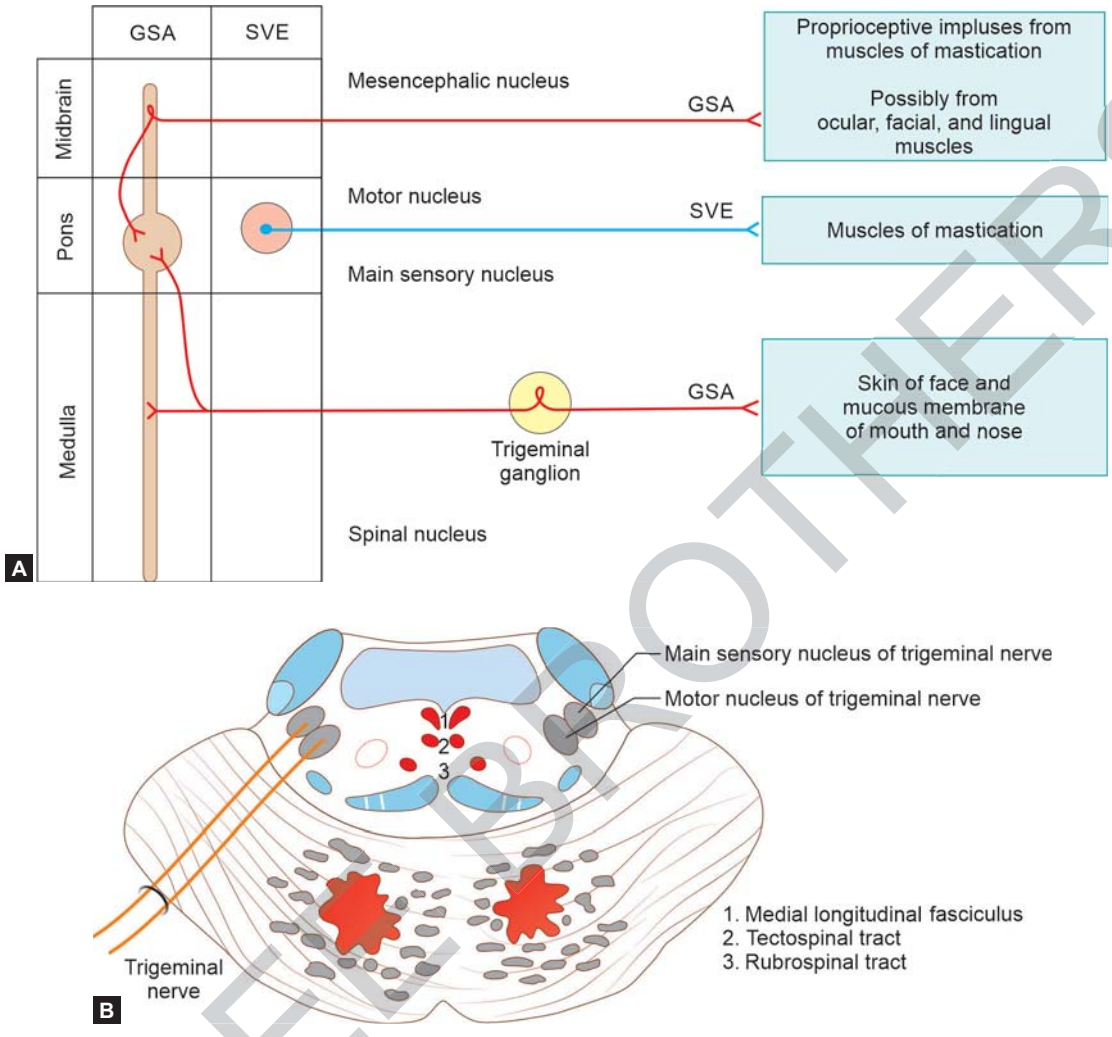

Figures 19.6A and B: (A) Functional components of the trigeminal nerve; (B) Trigeminal nerve nuclei. (GSA: general somatic afferent; SVE: special visceral efferent)

- **General somatic afferent** fibers of the nerve are peripheral processes of bipolar neurons in the trigeminal ganglion. They carry exteroceptive sensations from the skin of the face and the mucous membrane of the mouth and nose.

  The central processes of the neurons in the ganglion constitute the sensory root of the nerve. They terminate in the **main sensory nucleus** in the upper pons and **in the spinal nucleus of the nerve** extending up to the spinal cord.
- Another group of general somatic afferent neurons carry proprioceptive impulses from the muscles of mastication (and possibly from ocular, facial, and lingual muscles). These fibers are believed to be peripheral processes of first order neurons located in the **mesencephalic nucleus** of this nerve located in the midbrain. The central processes of this nucleus terminate in the main sensory nucleus.

Peripheral Distribution

- **Motor root** after emerging from the pons enters into the trigeminal cave where it lies under the trigeminal (semilunar) ganglion and joins the mandibular division for innervation of various muscles derived from the first pharyngeal arch.
- **Sensory root:** Consists of central process of the cells located in the trigeminal ganglion. The peripheral processes of these cells constitute the three divisions

JAYPEE BROTHERS

of the trigeminal nerve (ophthalmic, maxillary and mandibular nerves).

- The sensory root enters the pons at the junction of the middle cerebellar peduncle and the basilar part.
- There is spatial arrangement of fibers in the sensory root so that the ophthalmic division fibers are dorsal, mandibular fibers are ventral and maxillary in between.
- The fibers carrying proprioceptive and discriminative touch impulses from the three divisions end in the superior sensory nucleus.
- Those carrying light touch on entering the pons divide into two branches; one of which ends in the superior nucleus and other descends downwards as spinal tract to terminate in the nucleus of spinal tract of the trigeminal nerve.
- Fibers carrying pain and temperature however descend inferiorly in the spinal tract without division to terminate in the caudal part of the spinal tract nucleus.
- The superior sensory nucleus is responsible for discriminative proprioceptive impulses and shares the sensation of light touch with the spinal tract nucleus. The caudal part of the spinal tract nucleus receives mainly thermal and painful stimuli.

Lesions

Lesions involving the trigeminal nerve are characterized by the:

- Loss of sensation over the area of distribution of the nerve.
- Paralysis of the masticatory muscles on the side of lesion.
- Deviation of the jaw towards the affected side.
- Loss of reflexes (corneal reflex, jaw jerk).
- Impairment of hearing due to paralysis of tensor tympani.

VI. Abducent (Abducens) Nerve

This nerve consists of **somatic efferent** fibers that arise from the **abducent nucleus** in lower pons and supply the lateral rectus muscle of the eyeball **(Figure 19.7)**.

Peripheral Distribution

- The fibers of the abducent nerve pass in a ventral direction from the nucleus to emerge from the brain stem in the groove between the pons and the pyramid of medulla oblongata.
- It pierces the dura mater in the posterior cranial fossa and comes to lie lateral to the internal carotid artery in the cavernous sinus.

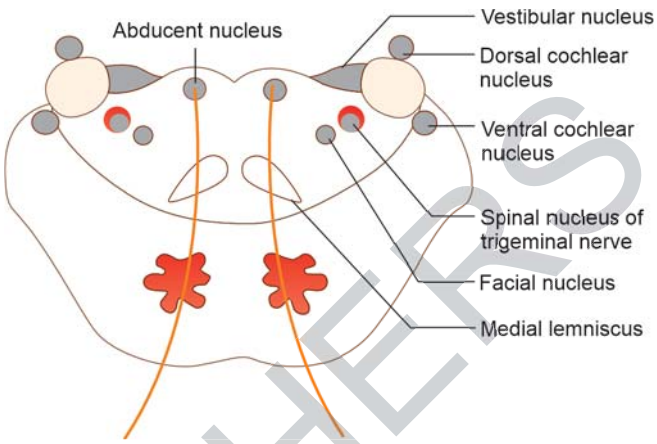

Figure 19.7: Abducent nerve nuclei.

- It enters the orbit through the annular tendinous ring bridging the superior orbital fissure and supplies the lateral rectus muscle of the eye ball from its ocular surface.

Lesions

Peripheral lesion of the nerve after it emerges from the brain results in: Paralysis of the lateral rectus muscle producing medial squint (strabismus) on the side of the lesion.

VII. Facial Nerve

The components of this nerve are as follows **(Figures 19.8A and B)**:

- **Special visceral efferent** fibers begin from the **motor nucleus** at the level of lower pons and supply the muscles of facial expression.
- **General visceral efferent** fibers (preganglionic) arise in the **superior salivatory nucleus**. They relay in the submandibular ganglion from which postganglionic fibers arise to supply the submandibular and sublingual salivary glands.

  The facial nerve also carries general visceral efferent fibers for the lacrimal gland. The preganglionic neurons concerned are said to be located in the **lacrimatory nucleus** which is a part of the superior salivatory nucleus. Their axons terminate in the pterygopalatine ganglion, from which postganglionic fibers arise to supply the gland.
- **Special visceral afferent** fibers are peripheral processes of cells in the geniculate ganglion of the nerve. They supply taste buds in the anterior two-thirds of the tongue (and some in the soft palate). The central processes of the ganglion cells carry these sensations to the upper part of the **nucleus of the solitary tract**.

JAYPEE BROTHERS

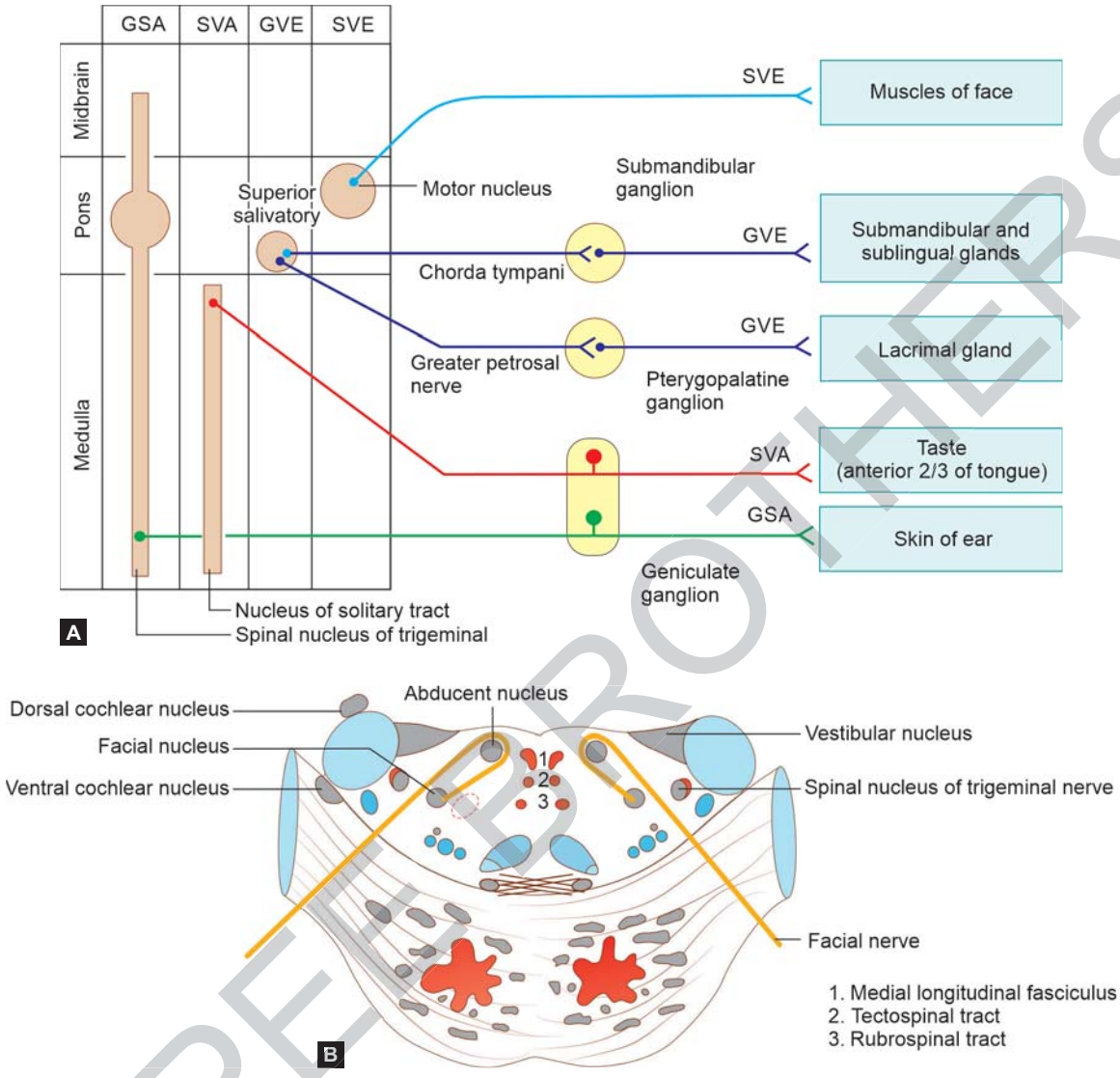

Figures 19.8A and B: (A) Functional components of the facial nerve; (B) Facial nerve: Location of nucleus and course of facial nerve fibers at their origin.

(GSA: general somatic afferent; GVE: general visceral efferent; SVA: special visceral afferent; SVE: special visceral efferent)

MAYPEE BROTHERS

Clinical Anatomy

Paralysis of facial nerve

Paralysis of the facial nerve is fairly common. It can occur due to injury or disease of the facial nucleus (nuclear paralysis) or of the nerve anywhere along its course **(infranuclear paralysis)**. Both are together called lower motor neuron (LMN) type of paralysis. In the most common type of infranuclear paralysis called **Bell's palsy**, the nerve is affected near the stylomastoid foramen. Facial muscles can also be paralyzed by interruption of corticonuclear fibers running from the motor cortex to the facial nucleus: This is referred to as **supranuclear** paralysis (upper motor neuron type of paralysis) **(Table 19.3 and Figures 19.9A and B)**.

The effects of paralysis are due to the failure of the muscles concerned to perform their normal actions. Some effects are as follows:

- The normal face is more or less symmetrical. When the facial nerve is paralyzed on one side, the most noticeable feature is the loss of symmetry.
- Normal furrows on the forehead are lost because of paralysis of the frontal belly of occipitofrontalis.
- The palpebral fissure is wider on the paralyzed side because of paralysis of the orbicularis oculi. The corneal and conjunctival reflexes are lost for the same reason.

The neural pathway for corneal/conjunctival reflex: Touch of cornea (nasociliary nerve)/conjunctiva (ophthalmic/maxillary) → trigeminal ganglion → main sensory nucleus of trigeminal in pons → motor nucleus of facial → facial nerve → orbicularis oculi

- There is marked asymmetry of the mouth because of paralysis of the orbicularis oris and of muscles inserted into the angle of the mouth. This is most obvious when a smile is attempted. When the patient attempts to smile, the angle of the mouth **deviates to the normal side**.
- During mastication, food tends to accumulate between the cheek and the teeth (this is normally prevented by the buccinator).

Table 19.3: Differences between supranuclear lesion and infranuclear lesion of facial nerve.

Supranuclear lesion of facial nerve	*Infranuclear lesion of facial nerve*
Lesion is usually in internal capsule	Lesion is usually at stylomastoid foramen
Accompanied by hemiplegia, on the same side as facial paralysis	Hemiplegia, seen only in nuclear paralysis in lower pons, will be contralateral
Movements of the lower part of the face affected because the upper part of the face is under bilateral cortical control	Movements of the entire half of face affected
Voluntary movements are affected, emotional expressions appear to be normal since different pathways are involved	Both voluntary and emotional movements are affected since it is the final common pathway

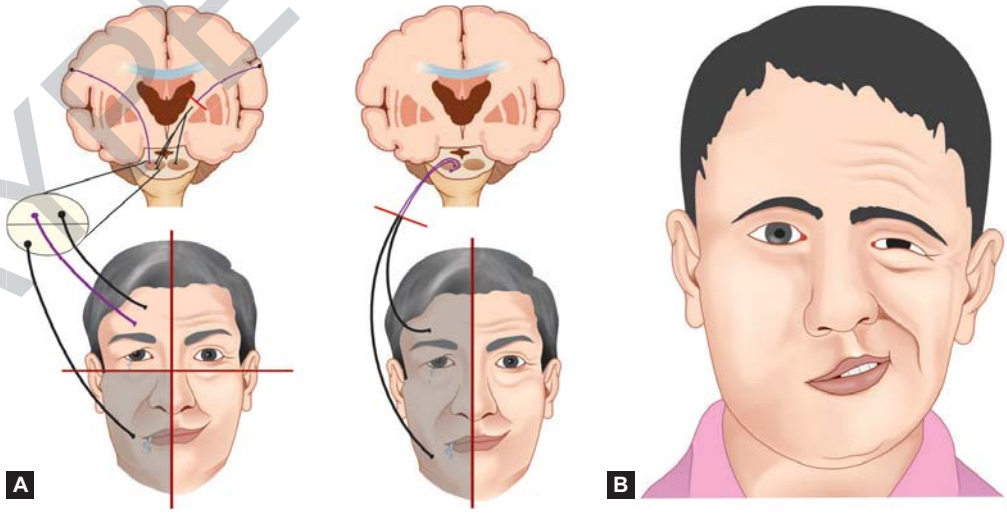

Figures 19.9A and B: (A) Effects of upper motor neuron and lower motor neuron lesions of the facial nerve; (B) Infranuclear paralysis of the facial nerve on the right side.

JAYPEE BROTHERS

- **General somatic afferent** fibers are also peripheral processes of some cells of the geniculate ganglion. They innervate a part of the skin of the external ear. The central processes of these cells end in the **spinal nucleus of the trigeminal nerve**.

Peripheral Distribution

- The motor fibers originate from the motor nucleus and pass dorsomedially to loop over the abducent nerve nucleus forming the internal genu and producing a swelling termed facial colliculus in the floor of the fourth ventricle.
- Fibers then pass ventrolaterally between its own motor nucleus and spinal tract nucleus to emerge on the surface between the pons and medulla oblongata on the lateral side.
- The sensory fibers originate from the cell bodies situated in the geniculate ganglion.
- The central processes of these cells form the **nervus intermedius** which accompanies the motor root and terminate in the nucleus of the tractus solitarius and the nucleus of spinal tract of trigeminal nerve.
- The secretomotor fibers also follow the nervus intermedius. Both the nervus intermedius and the motor root of the facial nerve enter the internal auditory meatus and join together at the geniculate ganglion located in the medial wall of the middle ear.
- The nerve then makes a bend inferiorly termed the external genu and emerges out through the stylomastoid foramen.
- The preganglionic parasympathetic fibers to submandibular and sphenopalatine (pterygopalatine) ganglia are given through chorda tympani and greater petrosal nerves respectively. Postganglionic fibers from these ganglia go to lacrimal, nasal and palatine (sphenopalatine ganglion) glands and submandibular and sublingual glands (submandibular ganglion).
- The taste fibers from the anterior two thirds of the tongue and palate travel through the chorda tympani and greater petrosal nerve to reach the cell bodies in the geniculate ganglion.

VIII. Vestibulocochlear Nerve

Both the cochlear and vestibular divisions of this nerve are made up of **special somatic afferent** fibers. The fibers of the cochlear nerve are central processes of bipolar cells in the spiral ganglion. The peripheral processes of these neurons supply the organ of Corti. The fibers of the vestibular nerve are central processes of bipolar neurons in the vestibular ganglion. The peripheral processes of these neurons innervate the semicircular ducts, the utricle, and the saccule of the internal ear.

Vestibular Nuclei

The vestibular nuclei lie in the gray matter underlying the lateral part of the floor of the fourth ventricle **(Figure 19.10)**. They lie partly in the medulla and partly in the pons. Four distinct nuclei are recognized. These are medial, lateral, inferior, and superior. The lateral nucleus is also called **Deiters' nucleus**.

Connections of vestibular nuclei

The vestibular nuclei receive the following afferents **(Figure 19.11)**:

- Central processes of bipolar neurons of the vestibular ganglion. These fibers constitute the vestibular part of the vestibulocochlear nerve and are necessary for maintenance of equilibrium.

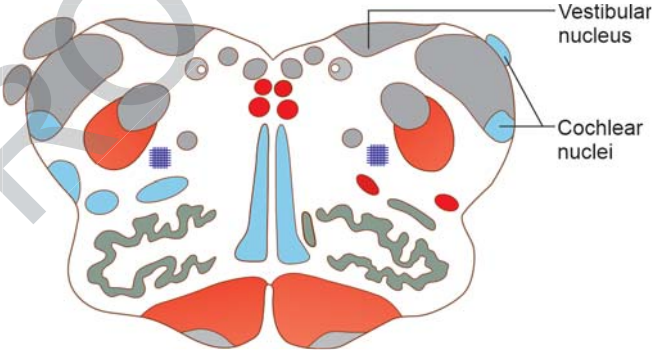

Figure 19.10: Vestibulocochlear nerve nuclei.

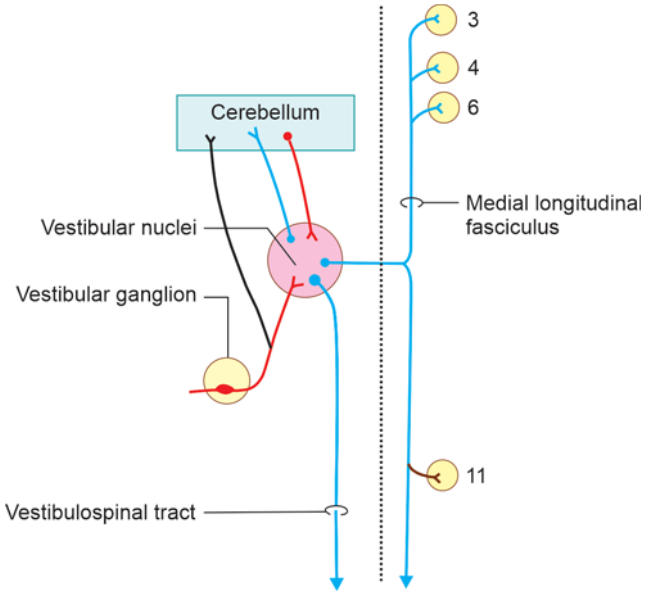

Figure 19.11: Connections of the vestibular nuclei.

JAYPEE BROTHERS

- The vestibular nuclei also receive fibers from some parts of the cerebellum.

The efferents from the vestibular nuclei are as follows:

- Vestibulocerebellar fibers pass through the inferior cerebellar peduncle.
- Fibers arising in the vestibular nuclei establish connections with cranial nerve nuclei responsible for movements of the eyes (third, fourth, and sixth) and of the neck (eleventh). These fibers form the **medial longitudinal fasciculus (or bundle)**.
- Fibers from the lateral vestibular nucleus descend to the spinal cord as the vestibulospinal tract.
- Some fibers from the vestibular nuclei enter the lateral lemniscus.
- Some vestibular impulses reach the thalamus (ventroposterior nucleus) and are relayed to the cerebral cortex.

Lesion

Lesion of the vestibular nerve is associated with vertigo, nystagmus, nausea, vomiting and low blood pressure.

IX. Glossopharyngeal Nerve

The components of this nerve are as follows:

- **Special visceral efferent** fibers arise in the **nucleus ambiguus** and supply the stylopharyngeus muscle.
- **General visceral efferent** fibers (preganglionic) begin from the **inferior salivatory nucleus** and travel to the otic ganglion. Postganglionic fibers arising in the ganglion supply the parotid gland.
- **General visceral afferent** fibers are peripheral processes of neurons in the inferior ganglion of the nerve. They carry general sensations (touch, pain, and temperature) from the pharynx and the posterior part of the tongue to the ganglion. They also carry inputs from the carotid sinus and carotid body. Central processes of the neurons carry these sensations to the **nucleus of the solitary tract**. Some fibers from the carotid sinus and body reach the paramedian reticular formation of the medulla.
- **Special visceral afferent** fibers are also peripheral processes of neurons in the inferior ganglion. They carry sensations of taste from the posterior one-third of the tongue to the ganglion. The central processes carry these sensations to the **nucleus of the solitary tract (Figure 19.12)**.

The important reflexes mediated by glossopharyngeal nerve are shown in **Table 19.4**.

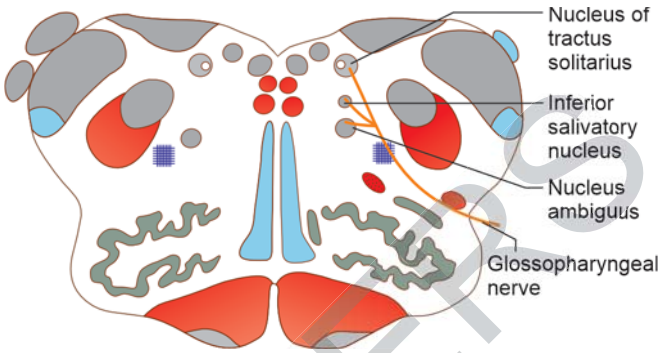

Figure 19.12: Glossopharyngeal nerve nuclei.

Table 19.4: Important reflexes mediated by glossopharyngeal nerve.

Reflex	*Afferent limb*	*Efferent limb*
Gag reflex	Glossopharyngeal nerve	Vagus nerve
Carotid sinus reflex	Glossopharyngeal nerve	Vagus nerve

Peripheral Distribution

- The roots of the nerve emerge from the medulla between the olive and inferior cerebellar peduncle.
- It leaves the cavity through the jugular foramen.
- It has two ganglia outside the cranial cavity. The superior ganglion contains cell bodies of general and special visceral afferent neurons.
- The nerve is distributed to the pharynx, posterior one third of the tongue, carotid body, parotid gland and the stylopharyngeus muscle through its various branches.

Lesions

The lesion of the nerve results in:

- Loss of taste in the posterior one third of the tongue
- Loss of gag reflex
- Loss of general sensation in the pharynx accompanied by slight dysphagia, deviation of the uvula to the normal side
- In some cases tachycardia probably due to disturbance of carotid sinus reflex.

X. Vagus Nerve and Cranial Part of Accessory Nerve

The components of this nerve are as follows **(Figures 19.13A and B)**:

- **Special visceral efferent** fibers are processes of neurons in the **nucleus ambiguus** in the medulla and supply the muscles of the pharynx and larynx.
- **General visceral efferent** fibers arise in the **dorsal (motor) nucleus of the vagus**. These are preganglionic

JAYPEE BROTHERS

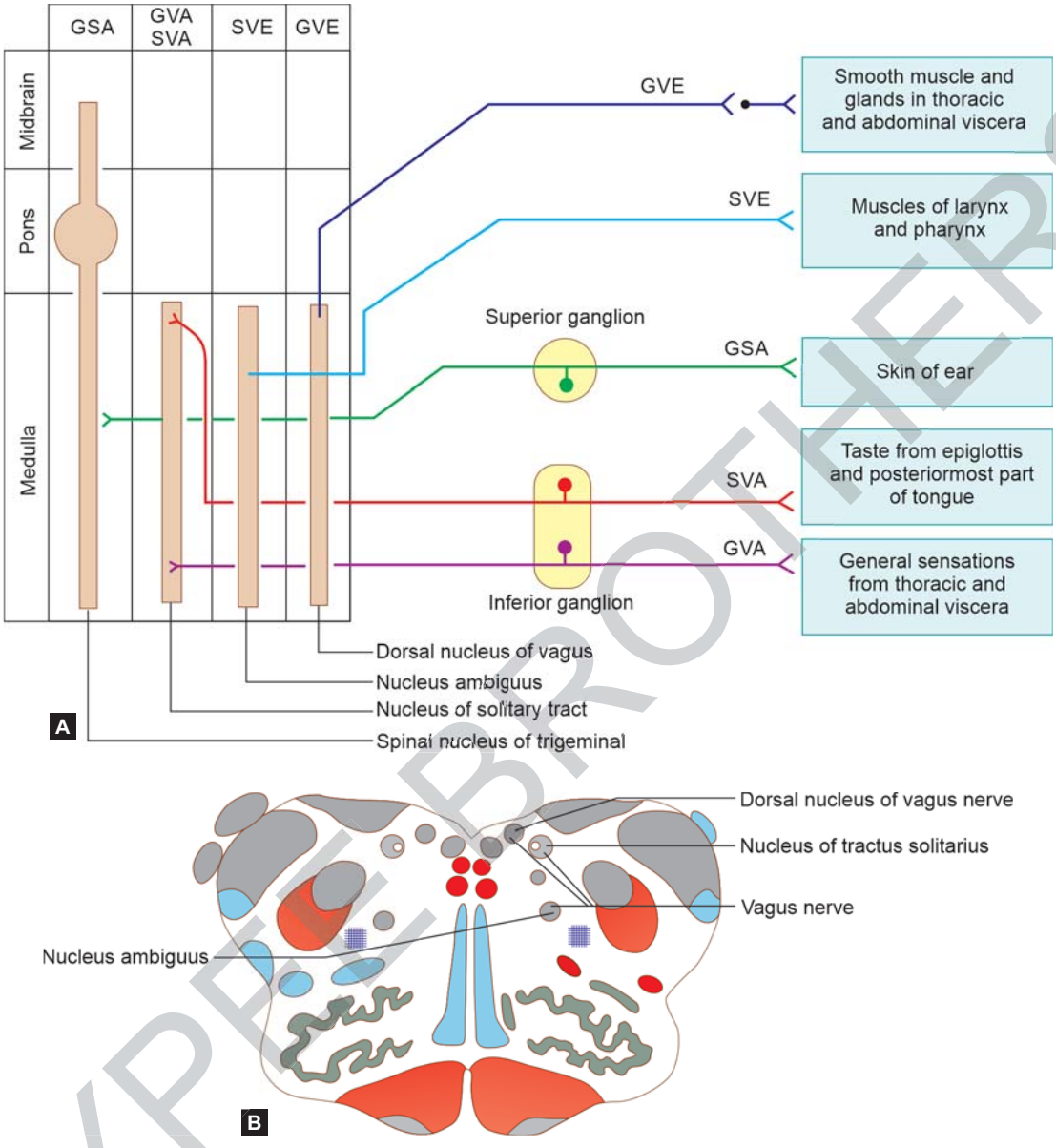

Figures 19.13A and B: (A) Functional components of the vagus nerve; (B) Vagus nerve nuclei.

(GSA: general somatic afferent; GVA: general visceral afferent; GVE: general visceral efferent; SVA: special visceral afferent; SVE: special visceral efferent)

parasympathetic fibers. They are distributed to thoracic and abdominal viscera. The postganglionic neurons concerned are situated in ganglia close to or within the walls of the viscera supplied.

- **General visceral afferent** fibers are peripheral processes of neurons located in the inferior ganglion of the nerve. They bring sensations from the pharynx, larynx, trachea, esophagus, and abdominal and thoracic viscera. These are conveyed by central processes of the ganglion cells to the **nucleus of the solitary tract**. According to some authorities, some of these fibers terminate in the dorsal nucleus of the vagus.
- **Special visceral afferent** fibers are also peripheral processes of neurons in the inferior ganglion. They carry sensations of taste from the posterior most part of the tongue and the epiglottis. The central processes of the neurons concerned terminate in the upper part of the **nucleus of the solitary tract**.

JAYPEE BROTHERS

- **General somatic afferent** fibers are peripheral processes of neurons in the superior ganglion and are distributed to the skin of the external ear. The central processes of the ganglion cells terminate in relation to the **spinal nucleus of the trigeminal nerve**.

Peripheral Distribution

- The vagus nerve emerges from the medulla between the olive and the inferior cerebellar peduncle.
- It leaves the cranial cavity through the jugular foramen where it is joined by the cranial part of accessory nerve.
- Outside the cranium it has two ganglia. The superior ganglion has cell bodies for general somatic afferent fibers from the external ear.
- The inferior ganglion contains cell bodies for general and special visceral afferent fibers from the thoracoabdominal viscera and area near the root of the tongue and epiglottis.
- The nerve is distributed through its various branches to the epiglottis, ear, larynx, pharynx, and thoracoabdominal viscera.

XI. Spinal Accessory Nerve

This nerve consists of **special visceral efferent** fibers which arise from the **lateral part of the anterior gray column of the upper five cervical segments** of the spinal cord, to supply the trapezius and sternocleidomastoid muscles.

Peripheral Distribution

- The rootlets of the cranial root emerge from the medulla between the olive and tuberculum cinereum and is joined by the spinal root which enters the cranial cavity through the foramen magnum.
- The nerve leaves the cranial cavity through the jugular foramen where the cranial part separates to join the vagus nerve and the spinal part passes out as the accessory nerve.
- The cranial part is distributed through the pharyngeal and recurrent laryngeal branches of vagus nerve to the musculature of soft palate (except tensor palati) and larynx.
- The spinal part passes deep to the carotid sheath to supply the sternocleidomastoid and the trapezius muscles.

Lesion

The lesion involving the spinal part of the nerve results in the paralysis of the sternocleidomastoid and trapezius muscles on the affected side producing the following features:

- No effect, weakness when turning. The head way from the paralyzed side against resistance.
- Moderate sagging of the shoulder.
- Inability to shrug the shoulder against resistance.

Clinical Anatomy

Effect of unilateral supranuclear lesion of nucleus ambiguus

Damage to supranuclear supply to the nucleus ambiguus may cause temporary interference with phonation and swallowing.

XII. Hypoglossal Nerve

This nerve is made up of the **somatic efferent** fibers which are processes of neurons in the **hypoglossal nucleus** in the medulla. They supply the muscles of the tongue (except palatoglossus) **(Figure 19.14)**.

The general somatic afferent fibers carrying proprioceptive impulses from muscles of the eyeball, face, and tongue are carried by communicating fibers of the trigeminal nerve (ophthalmic nerve from eyeball, cutaneous branches of ophthalmic, maxillary and mandibular nerves from facial muscles, and lingual branch of mandibular nerve from tongue).

Peripheral Distribution

It leaves the cranial cavity through the hypoglossal canal and is joined by a branch from the first cervical nerve in the neck. It reaches the tongue by passing between the mylohyoid and hyoglossus muscle.

A summary of cranial nerve nuclei with their functional components are given in **Table 19.5**.

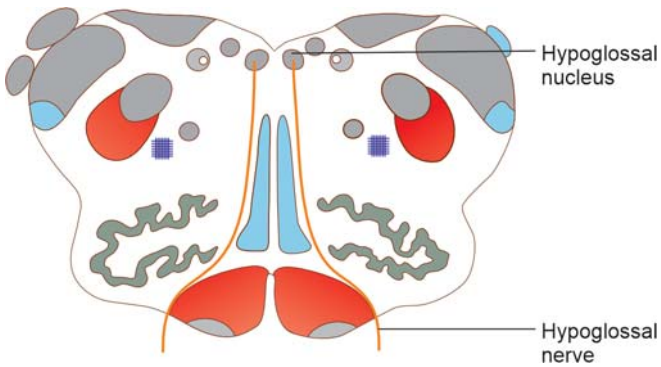

Figures 19.14: Hypoglossal nerve nuclei.

JAYPEE BROTHERS

Clinical Anatomy

Effect of unilateral supranuclear lesions of hypoglossal nerve

Hypoglossal nerve contains somatic efferent neurons supplying extrinsic and intrinsic muscles of the tongue. The nucleus is involved in hemiplegic stroke. As the supranuclear supply of hypoglossal nucleus is mainly crossed, therefore the tongue when protruded deviates to the paralyzed side because of the stronger pull of the healthy genioglossus. This together with comparable deficiency in the corticonuclear supply to the facial nerve which supplies lips accounts for the dysarthria (slurred speech) which persists after a hemiplegic stroke.

Effects of bilateral supranuclear lesions of X and XII

The supranuclear supply to hypoglossal nucleus and nucleus ambiguus is compromised bilaterally in thrombotic episodes in the brainstem in patients suffering from arteriosclerosis of the vertebrobasilar arterial system. There is a tightened (spastic) oral and pharyngeal musculature with consequent difficulty with speech articulation, chewing, and swallowing. In such cases, gait is slow and shuffling because of involvement of descending corticonuclear fibers to the spinal cord.

Table 19.5: Summary of cranial nerve nuclei with their functional components.

Cranial nerve	*Somatic efferent*	*Special visceral efferent*	*General visceral efferent*	*General visceral afferent*	*Special visceral afferent*	*General somatic afferent*	*Special somatic afferent*
Olfactory					Olfactory epithelium*		Olfactory epithelium*
Optic							Bipolar cells of retina
Oculomotor	Oculomotor		Edinger–Westphal				
Trochlear	Trochlear						
Trigeminal		Motor				Mesencephalic, main sensory and spinal	
Abducent	Abducent						
Facial		Motor	Superior salivatory		Tractus solitarius	Spinal nucleus of trigeminal	
Vestibulocochlear							Vestibular and cochlear
Glossopharyngeal		Ambiguus	Inferior salivatory	Tractus solitarius	Tractus solitarius	Spinal nucleus of trigeminal	
Vago-accessory		Ambiguus	Dorsal vagal	Tractus solitarius	Tractus solitarius	Spinal nucleus of trigeminal	
Spinal accessory		Accessory					
Hypoglossal	Hypoglossal						

* Olfactory mucosa develops from nasal placode (ectodermal in origin); hence, it is considered as somatic, developmentally. However, due to the close relationship between the sensations of smell and taste, this nerve is functionally classified as visceral.

JAYPEE BROTHERS

NUCLEI CONNECTED TO MORE THAN ONE NERVE

Some nuclei having a specific functional component may convey/receive fibers from more than one cranial nerve. These are as follows:

- Spinal nucleus of trigeminal nerve
- Nucleus ambiguus
- Nucleus tractus solitarius
- Superior and inferior salivatory nuclei

Spinal Nucleus of Trigeminal Nerve

The spinal nucleus of trigeminal nerve extends from the lower part of pons to the third cervical segment of the spinal cord. That is why, it is called spinal nucleus. It belongs to the **general somatic afferent (GSA)** functional group. It receives pain and thermal sensations from these nerves:

- **Trigeminal nerve (CN V):** All the three branches of trigeminal nerve convey fibers to this nucleus from their areas of distribution. Fibers are represented topographically. The mandibular nerve fibers terminate in the uppermost part, the maxillary fibers in the mid-region, and the ophthalmic fibers in the lowermost part.
- **Facial nerve (CN VII):** Fibers from a part of the skin of the external ear are conveyed to the spinal nucleus of the trigeminal nerve.
- **Glossopharyngeal (CN IX):** The central process of tympanic branch of glossopharyngeal nerve synapses in spinal nucleus of the trigeminal nerve.
- **Vagus nerve (CN X):** Fibers from the rest of the skin of external ear are conveyed to the spinal nucleus.

The second set of neurons arises from the spinal nucleus, crosses to the opposite side in the upper part of brainstem, and forms **trigeminal lemniscus** which terminate in the ventral posteromedial (**VPM**) nucleus of thalamus.

Nucleus Ambiguus

The nucleus ambiguus represents **special visceral efferent (SVE)** column. It is located in the open part of medulla, ventrolateral to the dorsal nucleus of vagus nerve. It supplies efferent fibers to the muscles derived by pharyngeal arches (i.e., branchiomotor). The nucleus is connected to:

- **Glossopharyngeal nerve (CN IX):** To supply the stylopharyngeus muscle, derived from third pharyngeal arch.
- **Vagus nerve (CN X):** To supply palatal, laryngeal and pharyngeal muscles derived from 4th and 6th pharyngeal arches. They also supply the striated muscles of the upper one-third part of esophagus.
- **Cranial accessory (CN XI):** It is connected to lower most part of nucleus ambiguus. Fibers of this nerve join the vagus nerve to form the pharyngeal plexus to supply palatal, laryngeal and pharyngeal muscles derived from 4th and 6th pharyngeal arches.

Nucleus of Solitary Tract (Also Known as Tractus Solitarius)

The solitary nucleus is a long, vertical nucleus located in the upper open part of medulla oblongata, dorsolateral to dorsal nucleus of the vagus nerve. It represents **special visceral afferent (SVA)** functional column and receives taste fibers from:

- **Facial nerve:** Taste sensations from anterior 2/3 of tongue, conveyed via lingual nerve to the chorda tympanic branch of facial nerve.
- **Glossopharyngeal nerve:** Taste sensations from posterior 1/3 of tongue and from circumvallate papillae of the tongue terminate in nucleus tractus solitarius.
- **Vagus nerve:** Taste sensations from the posterior most part of tongue and epiglottis relay to nucleus tractus solitarius.

Efferent fibers from the solitary nucleus cross to the opposite side and form the **solitariothalamic** tract which terminates onto the **ventral posteromedial** nucleus of the thalamus. From the thalamus, fibers pass to the postcentral gyrus (sensory area) of cerebral cortex **(Flowchart 19.1)**.

Flowchart 19.1: Tracing the functional column of "Taste" (SVA).

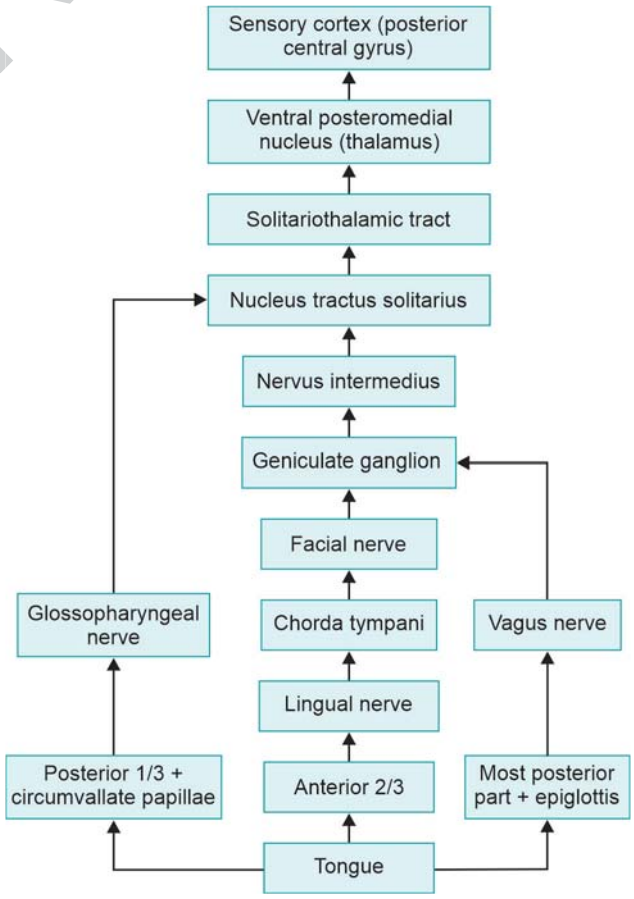

JAYPEE BROTHERS

Superior and Inferior Salivatory Nuclei

These nuclei carry **general visceral efferent (GVE)** functional component. They belong to the reticular formation of pons and medulla. These nuclei contribute preganglionic parasympathetic fibers to:

- **Facial nerve (CN VII):** To supply the submandibular and sublingual glands.
- **Glossopharyngeal nerve (CN IX):** To supply the parotid gland.

A brief outline of origin, course, and distribution of cranial nerves is given in **Table 19.6**. The students are advised to refer to the gross anatomy textbooks for more details.

Table 19.6: Origin, course, and distribution of cranial nerves.

Cranial nerve (Nature)	*Origin*	*Course*	*Distribution (Innervation)*
Olfactory (I) (special sensory)	Olfactory receptor cells of nasal cavity	• Pass through cribriform plate of ethmoid bone • Synapse in olfactory bulb • Olfactory tract terminates in primary olfactory cortex	Olfactory epithelium
Optic (II) (special sensory)	Retina of eye	Exit through optic canal to form **optic chiasma** at the base of brain	Retina of eye
Oculomotor (III) (motor)	Midbrain	• Enters orbit through superior orbital fissure • Divides into superior and inferior divisions to supply muscles of eyeball and ciliary ganglion	Inferior, medial, superior rectus, inferior oblique and levator palpebrae muscles; intrinsic eye muscles
Trochlear (IV)	Midbrain	Enters orbit through superior orbital fissure	Superior oblique muscle of eyeball
Trigeminal (V)	Pons	Forms the trigeminal ganglion, from where the three divisions emerge	Areas associated with the jaws
Ophthalmic (sensory)		Enters orbit through superior orbital fissure	Orbital structures, nasal cavity, skin of forehead, upper eyelid, eyebrows, nose (part)
Maxillary (sensory)		Pass to face through foramen rotundum; enters orbit via inferior orbital canal and then exits through infraorbital foramen on to upper part of face	Lower eyelid, upper lip, gums and teeth; cheeks, nose (part), palate, and pharynx (part)
Mandibular (mixed)		Pass to infratemporal fossa through foramen ovale and divides into anterior and posterior divisions	***Sensory*** to lower gums, teeth, lips; palate (part) and tongue (part) ***Motor*** to muscles of mastication
Abducens (VI) (motor)	At the junction of pons and medulla oblongata	Courses through as content of cavernous sinus and then enters orbit through superior orbital fissure	Lateral rectus muscle of eyeball
Facial (VII) (mixed)	At the junction of pons and medulla oblongata (at cerebellopontine angle)	Enters middle ear cavity via internal acoustic meatus; emerge through stylomastoid foramen to course on the lateral side of face; terminates by dividing into five branches within parotid gland	***Sensory*** to taste receptors on anterior 2/3 of tongue (via chorda tympani branch) ***Motor*** to muscles of facial expression, lacrimal gland, submandibular gland, sublingual salivary glands and glands of soft palate and nasal cavity

Contd...

JAYPEE BROTHERS

Contd...

Cranial nerve (Nature)	*Origin*	*Course*	*Distribution (Innervation)*
Vestibulocochlear (acoustic) (VIII) (special sensory)	At the junction of pons and medulla oblongata (at cerebellopontine angle)	Enters middle ear cavity via internal acoustic meatus; divides into cochlear and vestibular divisions	• Cochlea (receptors for hearing) • Vestibule (semicircular canals, utricle, and saccule of internal ear) (receptors for motion and balance)
Glossopharyngeal (IX) (mixed)	Medulla oblongata	Exit from skull through jugular foramen; descends in neck to pass between constrictors of pharynx	***Sensory*** from posterior 1/3 of tongue; pharynx and palate (part) palatine tonsil; receptors for blood pressure, heart rate, O_2, and CO_2 concentrations ***Motor*** to pharyngeal muscle (stylopharyngeus) and parotid gland
Vagus (X) (mixed)	Medulla oblongata	Exit from skull through jugular foramen; lie in the neck as a content of carotid sheath; joins cranial accessory nerve to form the pharyngeal plexus; descends downward into thoracic cavity and contributes in cardiac, pulmonary, and esophageal plexuses; passes to abdominal cavity through diaphragm and contributes in plexuses around abdominal organs	***Sensory*** from pharynx, pinna and external auditory canal, diaphragm, visceral organs in thoracic and abdominal and pelvic cavities ***Motor*** to palatal, laryngeal, and pharyngeal muscles, and to visceral organs in thoracic and abdominopelvic cavities
Accessory (XI) (motor)	Medulla oblongata	Formed by cranial and spinal roots; cranial root joins vagus nerve to form pharyngeal plexus; spinal root descends into neck to supply the neck muscles	• Skeletal muscles of palate, pharynx, and larynx (with vagus nerve) • Sternocleidomastoid and trapezius muscles
Hypoglossal (XII) (motor)	Medulla oblongata	Exits skull via hypoglossal canal; descends in neck along with 9, 10, 11 cranial nerves and pass medially to the tongue muscles	Both intrinsic and extrinsic muscles of tongue except palatoglossus

JAYPEE BROTHERS

One-line Definitions

- **Functional component:** Described in nerves to define their nature with respect to afferent/efferent; special/general and visceral/somatic sensations.
- **Edinger-Westphal nucleus:** General visceral efferent fibers of oculomotor nerve arise from this nucleus and relay in ciliary ganglion.
- **Nucleus of solitary tract:** Special visceral afferent fibers carrying the taste sensations from 7th, 9th and 10th nerves.
- **Nucleus ambiguus:** Special visceral efferent fibers to supply the muscles of 3th, 4th and 6th pharyngeal arches via 9th, 10th and 11th cranial nerves.
- **Gag reflex:** Involuntary reflex upon stimulation of oropharynx; mediated by glossopharyngeal nerve.
- **Salivatory nuclei:** Carry general visceral efferent fibers to supply secretomotor fibers to parotid, submandibular and sublingual glands via 9th and 7th cranial nerves respectively.

Summary

- The functional components are defined to represent the destination, source, and development of the peripheral nerve fibers.
- Depending upon the destination, the nerve fibers can be afferent/efferent; depending upon the source, it can be somatic/visceral and depending upon the development, it can be general/special.
- During the development, sulcus limitans divides the lateral wall of neural tube into basal lamina, which is medial and efferent, and alar lamina, which is lateral and afferent.
- According to these, the functional components can be divided into seven groups from medial to lateral: SE, SVE, GVE, GVA, SVA, GSA, and SSA.
- The olfactory nerve (CNI) carries special somatic afferent (SSA) from nasal cavity to olfactory cortex while optic nerve (CN II) is regarded as an extension of prosencephalon. It also carries special somatic afferent (SSA) fibers.
- The oculomotor (CN III), trochlear (CN IV), and abducent nerves (CN VI) nerves are somatic efferent (SE) fibers supplying to muscles of eyeball.
- The trigeminal nerve (CN V) contains SVE and GSA components. The nerve supplies muscles of mastication and carry exteroceptive sensations from the skin of the face and the mucous membrane of the mouth and nose.
- The facial nerve (CN VII) contains SVE, SVA, GVE, and GSA components. The nerve supplies motor/secretomotor fibers to facial muscles, submandibular, sublingual, and lacrimal glands. Also, it conveys the taste sensations from the anterior 2/3 of tongue and cutaneous supply from a part of external ear.
- The vestibulocochlear (CN VIII) nerve is made up of SSA fibers, which convey the auditory and vestibular impulses from the ear to higher centers.
- The components of glossopharyngeal (CN IX) nerve are SVE, GVE, GVA, and SVA. It conveys motor/secretomotor fibers to stylopharyngeus and parotid gland. It also conveys taste sensations from the posterior 1/3 part of tongue and general sensations from pharynx to higher centers.
- The vagus nerve (CN X) contains SVE fibers for muscles of pharynx and larynx; GVE fibers for thoracic and abdominal viscera; GVA fibers from cervical, thoracic, and abdominal organs; and SVA fibers for taste sensations from the posteriormost part of the tongue and epiglottis and GSA fibers from the skin of external ear.
- The mixed nerves with more than one functional component are connected to all those nuclei which contain the same functional neurons, e.g., 5th, 7th, 9th, and 10th cranial nerves.
- Similarly, a few nuclei having a specific functional component may convey/receive fibers from more than one cranial nerve, e.g., ambiguus, tractus solitarius, and spinal nucleus of 5th nerve.

Clinical Cases

19.1. Patient number 1 had paralysis of the muscles of the lower and upper half of the right face. There were no other symptoms. Patient number 2 had similar complaints, but in addition, he had hyperacusis, tinnitus, and vertigo.

A. Specify the type of facial paralysis in these two persons.

B. Localize the site of lesion in them.

19.2. A 30-year-old woman had to undergo extraction of impacted third molar tooth. Injury to lingual nerve happened during tooth extraction after which she did not feel any sensation over the tongue and also complained the loss of taste sensation.

A. Explain the anatomical basis of loss of taste sensation.

19.3. A 50-year-old man complained of severe pain in the ear and throat, symptoms were loss of gag reflex, loss of sensations in tonsillar region and dysphagia. Any action involving swallowing, chewing, coughing, etc., triggered the pain.

A. Which cranial nerve's lesion produces these neurologic deficits?

JAYPEE BROTHERS

Answer: Clinical Cases

19.1. A. Lower motor neuron type of lesion in both the persons

B. Site of lesion in patient number 1—right stylomastoid foramen

Site of lesion in patient number 2—right cerebellopontine angle

19.2. A. Lingual nerve contains the fibers of chorda tympani which carries the taste sensations. Therefore, damage to lingual nerve will also lead to loss of taste sensation along with loss of general sensation.

19.3. A. **Glossopharyngeal neuralgia** has all the above-mentioned symptoms. It may also include loss of taste sensation from posterior third of the tongue and radiating pain up to ear. The cause of lesion can be fracture of the skull base, thrombosis of sigmoid sinus, tumors or aneurysms of the posterior cranial fossa.



Multiple Choice Questions

1. **Which of the following nuclei belongs to the general visceral efferent column?**
   A. Motor nucleus of facial
   B. Motor nucleus of trigeminal
   C. Dorsal nucleus of vagus
   D. Nucleus ambiguus

2. **The mesencephalic nucleus of the trigeminal nerve receives:**
   A. Pain sensations from the scalp
   B. Proprioceptive impulses from the muscles of mastication
   C. Sensations from the cornea
   D. Tactile impulses from the face

3. **The nerves belonging to the somatic efferent column supply the muscles developed from:**
   A. Somites
   B. Intermediate mesoderm
   C. Pharyngeal arches
   D. Somatopleuric mesoderm

4. **Which of the following nerves belongs to the special visceral efferent column?**
   A. Oculomotor
   B. Trochlear
   C. Abducent
   D. Facial

5. **Which of the following functional components is represented by the accessory nerve?**
   A. Somatic efferent
   B. Special visceral efferent
   C. General visceral efferent
   D. General somatic afferent

6. **The functional component of the taste sensations carried by the glossopharyngeal nerve is:**
   A. General somatic afferent
   B. Special somatic afferent
   C. General visceral efferent
   D. Special visceral afferent

7. **The nucleus ambiguus is associated with which of the following cranial nerves?**
   A. Facial
   B. Glossopharyngeal
   C. Spinal accessory
   D. Hypoglossal

8. **The nucleus that carries the parasympathetic fibers of the facial nerve begins from:**
   A. Motor nucleus of facial nerve
   B. Inferior salivatory nucleus
   C. Nucleus of tractus solitarius
   D. Superior salivatory nucleus

9. **Which nerve is often damaged during transtentorial herniation:**
   A. Abducent
   B. Oculomotor
   C. Trigeminal
   D. Trochlear

10. **Which of the following nerves are damaged if the muscles attached to the styloid process are paralyzed?**
    A. V, IX and X
    B. VII, IX and X
    C. VII, IX and XII
    D. VII, X and XII

JAYPEE BROTHERS

11. To which of the following nerves, does trauma to the foramen rotundum cause damage?
A. Mandibular
B. Maxillary
C. Ophthalmic
D. Trochlear

12. In a patient, if light is shone into the left eye, it elicits a direct pupillary reflex but no consensual reflex. Which of the following nerves has lesions?
A. Right oculomotor nerve
B. Left oculomotor nerve
C. Right optic nerve
D. Left optic nerve

13. Which cranial nerve's damage result in anosmia?
A. I B. II
C. III D. IV

14. A 40-year-old woman arrives at the casualty with vertical diplopia that worsens when walking downstairs or reading. Imaging reveals a small lesion located on the dorsal aspect of the brainstem. Which cranial nerve is most likely involved?
A. Trochlear nerve B. Trigeminal nerve
C. Abducent nerve D. Oculomotor nerve

15. A patient with known trigeminal neuralgia experiences a sudden flare-up of facial pain. The sensory afferent fibers responsible for pain and temperature are relayed up to which of the following segments?
A. Upper end of the medulla
B. Lower end of the medulla
C. Second cervical spinal segment
D. Fifth cervical spinal segment

Answer Key

1. C	2. B	3. A	4. D	5. B
6. D	7. B	8. D	9. B	10. C
11. B	12. A	13. A	14. A	15. C

Short Note

1. Describe the classification of functional components of cranial nerves.

Long Questions

1. Describe the functional components and nuclei associated with facial nerve in a well labeled diagram or flowchart.
2. Describe the functional components and nuclei associated with trigeminal nerve in a well labeled diagram or flowchart.
3. Describe the functional components and nuclei associated with glossopharyngeal nerve in a well labeled diagram or flowchart.
4. Describe the functional components and nuclei associated with vagus nerve in a well labeled diagram or flowchart.
5. Describe the cranial nerve nuclei which are connected to more than one nerve according to their functional component.

JAYPEE BROTHERS

for detailed information on anatomy books, visit our website www.ejaypee.com, for detailed information on anatomy books, visit our website www.ejaypee.com, for detailed information on anat

Singh's Textbook of CLINICAL NEUROANATOMY

Key Features

- The present edition of *Singh's Textbook of Clinical Neuroanatomy* (12th edition) has been thoroughly revised for a better understanding and concept making.
- The NMC competencies have been covered in each chapter and can be accessed by the user, through the given QR Code by scanning.
- The text has been updated and more flowcharts and figures have been added.
- The clinical-based problems along with their answers and also clinically based MCQs have been added adequately.
- The book has an increased number of clinical anatomy and key points boxes.
- At the end of each chapter, a new feature, i.e., one-line definition, has been added to memorize the more important facts.

Kanchan Kapoor PhD MNAMS is Professor, Department of Anatomy, Government Medical College and Hospital, Chandigarh, India. She has a teaching experience of 30 years in the field of anatomy. She is an active researcher and has published several papers in international and national journals and also authored chapters in books. She has also presented her research work at international, national, and regional conferences. She is a member of the American Association of Clinical Anatomists and a lifetime member of the Anatomical Society of India, Indian Society for Atherosclerotic Research, Association of Basic Medical Scientists, and North Chapter of the Anatomical Society. She has authored three textbooks on Anatomy for nursing and paramedical courses. Her main areas of interest include congenital birth defects, neuroanatomy, and medical education.

Shelving Recommendation
ANATOMY

ISBN 978-93-6616-969-9
9 789366 169699

Buy from ejaypee

JAYPEE BROTHERS