docrinology books, visit our website www.ejaypee.com, for detailed information on endocrinology books, visit our website www.ejaypee.com, for detailed information on endocrinology books,

RSSDI Atlas of Dermatological Conditions in Diabetes

Editor-in-Chief
NK Singh

Assistant Editors
Akashkumar N Singh
Anuradha Kapoor
Amit Kumar

Associate Editors
Vijay Vishwanathan
Anuj Maheshwari
Sanjay Agarwal

JAYPEE

Contents

SECTION 1: Introduction and Overview

CHAPTER 1: Epidemiology of Diabetes and Its Cutaneous Manifestations 3
Amit Kumar, Arti Muley

CHAPTER 2: Normal Skin and Pathogenesis of Skin Changes in Diabetes 5
Amit Kumar, Arti Muley

CHAPTER 3: Common Skin Conditions in Diabetes and their Distribution 11
Arti Muley, Akashkumar N Singh

SECTION 2: Dermatologic Conditions Directly Attributed to Diabetes

CHAPTER 4: Diabetic Dermopathy (Shin Spots) in a Type 2 Diabetic Male 19
Suhas Gopal Erande

CHAPTER 5: Necrobiosis Lipoidica Based on a Skin Biopsy 24
Namrata C Manjunath, Chinmayee Anand N, Niraj, Deepak Das

CHAPTER 6: Bullous Diabeticorum 28
Firdous Shaikh, Avina Jain, Abhinav Jain, Armaan Mishra

CHAPTER 7: Bullous Pemphigoid in a Diabetic Male 31
Nipul Vara, Vishwa Marvania, Preya Parag Rana

CHAPTER 8: Yellow Palms in Diabetes Mellitus: A Case of Carotenoderma 34
Arijit Singha, Pradip Mukhopadhyay, Sujoy Ghosh

CHAPTER 9: Carotenemia in a Patient with Type 2 Diabetes Mellitus 36
NK Singh, Akashkumar N Singh, Anuradha Kapoor

CHAPTER 10: Diabetic Rubeosis Faciei with Palmar Erythema 38
Ashma Surani, Bela J Shah

CHAPTER 11: Finger Pebbles (Huntley's Papules) in a Diabetic Male 40
Suhas Gopal Erande

CHAPTER 12: Perforating Dermatosis **42**

Nipul Vara, Vishwa Marvania, Preya Parag Rana, Suhas Gopal Erande, Prabhat Kumar Agrawal, Sandipta Kumar Panda, Gaurav Gupta, Anil Patki, Ashma Surani, Firdous Shaikh, Avina Jain

Part A: Perforating Folliculitis in Uncontrolled Diabetes 42

Part B: Acquired Perforating Dermatosis in a Diabetic Female with Chronic Renal Failure 44

Part C: Kyrle's Disease in a Patient of Diabetes Mellitus and Chronic Kidney Disease on Hemodialysis 46

Part D: Acquired Perforating Dermatosis (Reactive Perforating Collagenosis Variant) in Diabetes 48

Part E: Reactive Perforating Collagenosis in a Type 2 Diabetic Female 50

Part F: Pruritic Perforating Dermatosis Associated with Type 2 Diabetes Mellitus 52

SECTION 3: Skin Conditions Associated with or Exacerbated by Diabetes

CHAPTER 13: Psoriasis in a Diabetic Patient **57**

Nipul Vara, Vishwa Marvania

CHAPTER 14: Acanthosis Nigricans and Acrochordons (Skin Tags) in Diabetes **59**

Suhas Gopal Erande, Anil Patki, Bharat Bhushan Kukreja, Ruchi Shah, Yogesh Marfatia

CHAPTER 15: Lichen Planus in a Diabetic Male with Hypothyroidism **68**

Nipul Vara, Vishwa Marvania

CHAPTER 16: Xerosis and Pruritus in Diabetes (Dry Skin and Generalized Itch) **70**

J Thadeus

CHAPTER 17: Subacute Eczema with Id Eruption in Metabolic Syndrome and Type 2 Diabetes **73**

Rutul Gokalani, Viral Thakkar

SECTION 4: Cutaneous Infections in Diabetes

CHAPTER 18: Fungal Infections **79**

Arti Muley, Akashkumar N Singh, Yashika Doshi, Bela J Shah, Ashma Surani, Nipul Vara, Dhaivat Joshi, Armaan Mishra, Firdous Shaikh, Avina Jain

Part A: Dermatophyte Infection in Diabetes (Tinea and Onychomycosis) 79

Part B: Candidiasis and Other Yeast Infections in Diabetes 86

CHAPTER 19: Bacterial Skin Infections in Diabetes **95**

Nipul Vara, Vishwa Marvania, Preya Parag Rana, Hiral Shah, J Thadeus, Aarathy Kannan, Akashkumar N Singh, Ankur Kothari, Suhas Gopal Erande, Anil Patki, Ruchi Shah, Yogesh Marfatia

Part A: Acute Paronychia in a Diabetic Male 95

Part B: Erythrasma in a Diabetic Patient 96

Part C: Furunculosis in Diabetic Patients 99

Part D: Fournier's Gangrene in an Undiagnosed Diabetic Male 103

Part E: Carbuncle in a Diabetic Female 105

Part F: Cutaneous Nontuberculous Mycobacterium Infections in Diabetes 106

Part G: Necrotizing Skin and Soft Tissue Infections in Uncontrolled Diabetes 108

CHAPTER 20: Viral Skin Infections in Diabetes: Hemorrhagic Herpes Zoster (Multidermatomal) in an Uncontrolled Diabetic Patient **111**

Bela J Shah

SECTION 5: Rare Dermatological Manifestations of Diabetes (Musculoskeletal and Connective Tissue Manifestations in Diabetes)

CHAPTER 21: Diabetic Cheiroarthropathy (Diabetic Hand Syndrome/Stiff Skin Syndrome) in Long-standing Diabetes **115**

Suhas Gopal Erande, Anil Patki

CHAPTER 22: Scleredema Diabeticorum (Diabetic Scleroderma) **118**

Suhas Gopal Erande

CHAPTER 23: Granuloma Annulare in Diabetes **121**

Firdous Shaikh, Avina Jain, Bela J Shah, Akashkumar N Singh, Anuradha Kapoor, Ruchi Shah, Yogesh Marfatia

CHAPTER 24: Eruptive Xanthomas in Uncontrolled Diabetes Mellitus **129**

NK Singh, Akashkumar N Singh, Anuradha Kapoor

CHAPTER 25: Abdominal Pseudohernia due to Diabetic Truncal Neuropathy **132**

Santosh B

CHAPTER 26: Porphyria Cutanea Tarda in Patients with Type 2 Diabetes Mellitus **134**

Suhas Gopal Erande, Anil Patki

SECTION 6: Psychosocial and Cosmetic Skin Conditions in Diabetes

CHAPTER 27: Vitiligo in Diabetes (Autoimmune Pigmentary Changes) **139**

Nipul Vara, Vishwa Marvania

CHAPTER 28: Hidradenitis Suppurativa in Diabetes **141**

Bharat Bhushan Kukreja

CHAPTER 29: Alopecia in Diabetes Mellitus (Hair Loss Associations) **144**

Nipul Vara, Vishwa Marvania

CHAPTER 30: Postinflammatory Hyperpigmentation in Diabetes: Truncal Distribution **147**

Suhas Gopal Erande, Anil Patki

SECTION 7: Dermatology of Diabetic Foot

CHAPTER 31: Nonhealing Foot Ulcer in Diabetes Mellitus 153
Nipul Vara, Vishwa Marvania

CHAPTER 32: Nonhealing Trophic Ulcer in a Diabetic Male 156
Bela J Shah

CHAPTER 33: Difficult-to-Treat Diabetic Foot Ulcer Complicated by Osteomyelitis 159
Amalkumar Bhattacharya, Pradnya Gatkal, Dipali Rahirkar, Arjun Khadse, Chaitanya Bhandekar

CHAPTER 34: Maggot Infestation in a Diabetic Foot Ulcer: Clinical Case and Review 162
Bharat Bhushan Kukreja

CHAPTER 35: Diabetic Toe Gangrene (Dry Gangrene) in Uncontrolled Diabetes 166
Suhas Gopal Erande, Anil Patki

CHAPTER 36: Diabetic Foot Gangrene with Heel Ulceration and Digital Necrosis 169
Suhas Gopal Erande, Anil Patki

CHAPTER 37: Extensive Dry Gangrene of the Foot in a Diabetic Smoker 172
Nipul Vara

SECTION 8: Diagnostic and Special Considerations in Diabetic Dermatology

CHAPTER 38: Insulin Injection Site Reactions 177
Arti Muley, Akashkumar N Singh, Sona Mitra, Sudhir Kumar, Gururaj B Sattur, Suhas Gopal Erande, Anil Patki,NK Singh, Leena Singh

Part A: Lipohypertrophy and Lipoatrophy 177

Part B: Allergic Contact Dermatitis from Insulin Pump Adhesive 182

Part C: Postinflammatory Hyperpigmentation Following Insulin Injections 184

CHAPTER 39: Cutaneous Adverse Effects of Diabetes Therapies 187
Yashika Doshi, Bela J Shah, Twinkle C Rangnani, Tithi Shah

Part A: Gliptin-Induced Bullous Pemphigoid 187

Part B: Vildagliptin-Induced Bullous Pemphigoid—Blisters Unveiled 189

Index ***193***

SECTION 2

Dermatologic Conditions Directly Attributed to Diabetes

JAYPEE BROTHERS

Section Outline

Chapter 4: Diabetic Dermopathy (Shin Spots) in a Type 2 Diabetic Male
Suhas Gopal Erande

Chapter 5: Necrobiosis Lipoidica Based on a Skin Biopsy
Namrata C Manjunath, Chinmayee Anand N, Niraj, Deepak Das

Chapter 6: Bullous Diabeticorum
Firdous Shaikh, Avina Jain, Abhinav Jain, Armaan Mishra

Chapter 7: Bullous Pemphigoid in a Diabetic Male
Nipul Vara, Vishwa Marvania, Preya Parag Rana

Chapter 8: Yellow Palms in Diabetes Mellitus: A Case of Carotenoderma
Arijit Singha, Pradip Mukhopadhyay, Sujoy Ghosh

Chapter 9: Carotenemia in a Patient with Type 2 Diabetes Mellitus
NK Singh, Akashkumar N Singh, Anuradha Kapoor

Chapter 10: Diabetic Rubeosis Faciei with Palmar Erythema
Ashma Surani, Bela J Shah

Chapter 11: Finger Pebbles (Huntley's Papules) in a Diabetic Male
Suhas Gopal Erande

Chapter 12: Perforating Dermatosis
Nipul Vara, Vishwa Marvania, Preya Parag Rana, Suhas Gopal Erande, Prabhat Kumar Agrawal, Sandipta Kumar Panda, Gaurav Gupta, Anil Patki, Ashma Surani, Firdous Shaikh, Avina Jain

JAYPEE BROTHERS

CHAPTER

4

Diabetic Dermopathy (Shin Spots) in a Type 2 Diabetic Male

Suhas Gopal Erande

JAYPEE BROTHERS

Case 1

PRESENTATION

A 64-year-old male with a 15-year history of type 2 diabetes mellitus presented with complaints of gradually developing dark patches over the front of both lower legs. The lesions had appeared slowly over the past 6 months. The patient reported no pain, itching, trauma, or history of prior ulceration at the sites.

EXAMINATION

On physical examination, multiple well-demarcated, round-to-oval, brownish macules and papules were observed over the anterior aspects of both shins **(Fig. 1)**. The lesions measured between 0.3 and 1.5 cm in diameter and showed central atrophy with peripheral hyperpigmentation. The skin over the lesions appeared thin and mildly scaly. There were no signs of ulceration, active inflammation, or secondary infection.

INVESTIGATIONS

- *Neuropathy foot screening:* Revealed altered capillary morphology with mild tortuosity and capillary dropout.
- *Glycemic profile:* Glycated hemoglobin (HbA1c) was found to be 8.1%, indicating poor glycemic control.
- *Ophthalmic evaluation:* Showed early signs of background diabetic retinopathy without macular involvement.
- *Renal parameters:* Urine albumin-to-creatinine ratio (UACR) indicated early microalbuminuria.

Diagnosis

- Diabetic dermopathy (also known as "diabetic shin spots")
- The diagnosis of diabetic dermopathy, also known as "shin spots", was confirmed based on the above clinical findings. It represents a common cutaneous manifestation of long-standing diabetes mellitus and may serve as a cutaneous marker of underlying microvascular complications, analogous to the involvement seen in diabetic retinopathy and nephropathy.[1,2]

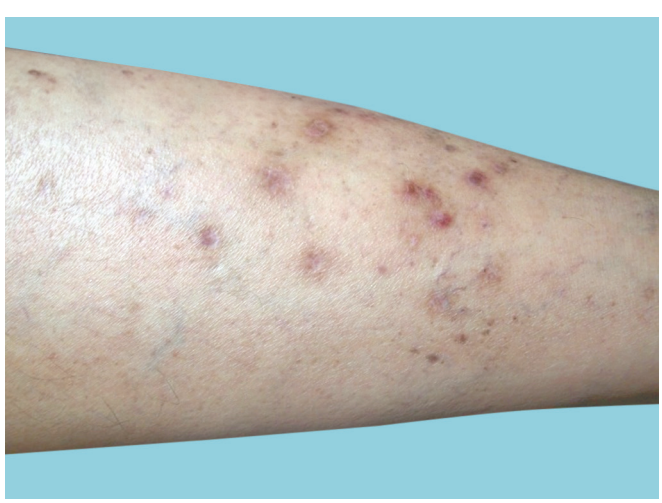

FIG. 1: Dark brown macules and patches over the anterior lower legs in a male patient with type 2 diabetes mellitus.

Differential Diagnoses

- *Stasis dermatitis*: It presents with hyperpigmentation, erythema, and scaling near the ankles, often accompanied by edema.[3]
- *Postinflammatory hyperpigmentation:* It occurs following a history of trauma or preceding inflammation.[3]
- *Lichen planus:* It is characterized by violaceous, flat-topped papules that may be pruritic.[4]
- *Purpura annularis telangiectodes:* It show petechial patches often associated with vasculitis.[5]
- *Necrobiosis lipoidica:* Necrobiosis lipoidica features sharply demarcated plaques with central atrophy and a yellowish hue.[5]

Pathophysiology

- Believed to result from *diabetic microangiopathy*, leading to poor blood flow and subsequent *dermal ischemia.*[2,6]
- Often follows *minor trauma* due to increased skin fragility in diabetes
- Histopathologically, it shows *mild lymphocytic perivascular infiltrate,* hemosiderin deposition, and dermal atrophy.[2]

Management

Dermatology Management

- *No specific treatment* needed in most cases[1,7]
- Application of *emollients* to maintain hydration and barrier function[7]
- Avoidance of trauma to lower legs[2]
- Rarely, cosmetic camouflage for extensive pigmentation[2]

Diabetology/Physician Management

- *Optimize glycemic control* to prevent progression of microvascular complications.[1,8]
- Evaluate for associated *retinopathy, nephropathy, and neuropathy.*[1]
- Educate the patient that lesions are *harmless* and do not require aggressive treatment.[7]
- Encourage foot and leg care to *prevent trauma and secondary infections.*[7]

Prognosis

- Lesions are benign and *do not ulcerate or progress* to malignancy.[2,6]
- Typically *resolve over months to years* but may leave residual pigmentation.[2]
- New lesions may appear even after glycemic control.[8]

Clinical Pearls

- Seen in *up to 55% of diabetics*, more common in older men.[1,5]
- Often the *earliest cutaneous* sign of diabetes[1]
- Should prompt a search for *other microvascular complications* (e.g., fundus examination and urine microalbumin).[1,3]
- Painless and often symmetrical over bony prominences (tibial region)[2]
- Also called "*shin spots*" in layman's terminology.[2]

REFERENCES

1. Duff M, Demidova O, Blackburn S, Shubrook J. Cutaneous manifestations of diabetes mellitus. Clin Diabetes. 2008;26(1):27-32.
2. Saxena Pal R, Wal P, Pal Y, Wal A. Recent insights on diabetic dermopathy. Open Dermatol J. 2019;13:8-12.
3. Roslind S, Muhammed K, Kumar KGS. Cutaneous manifestations in patients with type 2 diabetes mellitus and normal controls. J Sci Soc Ther Dermatol. 2020;7(2):95-101.
4. Huntley AC. Cutaneous manifestations of diabetes mellitus. Diabetes Care. 1980;3(1):75-88.
5. Romano G, Moretti G, Di Benedetto A, Giofrè C, Di Cesare E, Russo G, et al. Skin lesions in diabetes mellitus: prevalence and clinical correlations. Diabetes Res Clin Pract. 1998;39(2):101-6.
6. Brzezinski P, Chiriac AE, Pinteala T, Foia L, Chiriac A. Diabetic dermopathy ("shin spots") and diabetic bullae ("bullosis diabeticorum"): two associated cutaneous markers in diabetes mellitus. Clujul Med. 2011;84(1):129-32.
7. Apollo Hospitals. (2025). Diabetic Dermopathy—Causes, Symptoms, Diagnosis, and Treatment. 2025. [online] Available from https://www.apollohospitals.com/diseases-and-conditions/diabetic-dermopathy [Last accessed Aug., 2025].
8. Karra MC, Maheswari PM, Atluri SC, Samanthula H. Dermatological manifestations in diabetes mellitus and its relation with HbA1c levels – An observational study. IP Indian J Clin Exp Dermatol. 2024;10(4):393-7.

JAYPEE BROTHERS

Case 2

PRESENTATION

A 48-year-old male presents with a 1-year history of multiple, asymptomatic, and brownish spots on both shins. The lesions have progressively darkened over time and have not been associated with trauma, scratching, or infection. The patient has a long-standing medical background of poorly controlled type 2 diabetes mellitus (12 years, HbA1c 9.6%), hypertension, and dyslipidemia. Compliance with antidiabetic medications (metformin and glimepiride) has been irregular.

EXAMINATION

- On examination, multiple well-demarcated, round-to-oval brown macules and papules with central atrophy and peripheral hyperpigmentation are observed, distributed bilaterally over the anterior tibiae **(Fig. 2)**.
- The lesions are nonscaly, nontender, and not ulcerated, with no surrounding edema or signs of active inflammation.
- Peripheral pulses are intact, and sensory examination is normal.



FIG. 2: Multiple well-demarcated, round-to-oval brown macules and papules with central atrophy and peripheral hyperpigmentation distributed bilaterally over the anterior tibiae.

INVESTIGATIONS

To confirm the clinical suspicion and assess the associated systemic status, the following investigations were performed:

- *Glycemic status*:
  - *Glycated hemoglobin (HbA1c):* 9.6% (Reference range: <6.5%)—Suggestive of long-standing and poorly controlled diabetes mellitus
  - *Fasting plasma glucose (FPG):* 165 mg/dL (Reference range: 70–99 mg/dL)—Elevated fasting glucose
  - *Postprandial plasma glucose (PPG):* 250 mg/dL (Reference range: <140 mg/dL)—Elevated postprandial glucose.
- *Lipid profile*:
  - *Low-density lipoprotein (LDL):* 134 mg/dL (Reference range: <100 mg/dL)—Elevated
  - *Triglycerides:* 180 mg/dL (Reference range: <150 mg/dL)—Elevated
- *Urine microalbumin*: 46 mg/g (Reference range: <30 mg/g)—Suggestive of early nephropathy
- *Monofilament test*: Normal—No clinical evidence of neuropathy.
- *Additional dermatological assessment*:
  - *Dermoscopy:* Shows central atrophy with a pigment network, perilesional hyperpigmentation, and sparse perifollicular pigmentation.
  - *Histopathology (if performed):* Epidermal atrophy, increased dermal collagenization, mild perivascular lymphocytic infiltrate, and dermal hemosiderin deposition (no evidence of vasculitis).

PATHOPHYSIOLOGY

In diabetic dermopathy, chronic hyperglycemia leads to microangiopathy and subsequent changes within the skin:

- Capillary basement membrane thickening and endothelial dysfunction
- Reduced perfusion and tissue hypoxia in the lower extremities
- Extravasation of red blood cells with deposition of hemosiderin within the dermis
- Impaired wound healing and vulnerability to minor, unnoticed trauma in the shin area, promoting persistence and recurrence of lesions[1,2]

JAYPEE BROTHERS

DIAGNOSIS

Diabetic Dermopathy (Shin Spots)

A clinical diagnosis based on the characteristic morphology and distribution of the lesions over the shins in a patient with long-standing and poorly controlled diabetes mellitus.[3,4]

Systemic Correlation

- Diabetic dermopathy is seen in approximately 30–60% of patients with longstanding type 2 diabetes mellitus.[10,11]
- It is strongly associated with other microvascular complications of diabetes, including:
  - Retinopathy
  - Nephropathy
  - *Peripheral neuropathy* (often present subclinically despite absence of overt clinical signs)
- The presence of these lesions is closely linked to the duration and severity of hyperglycemia.[1,4]

DIFFERENTIAL DIAGNOSIS

- *Necrobiosis lipoidica:* Yellow, waxy plaques with telangiectasia and central atrophy, typically located on the shins and associated with long-standing diabetes.
- *Pigmented purpuric dermatoses:* Characterized by petechiae and "cayenne-pepper" spots, often pruritic and presenting on the lower legs.
- *Stasis dermatitis:* Usually unilateral with associated edema, lipodermatosclerosis, and hyperpigmentation due to chronic venous insufficiency.
- *Lichen planus:* Presents as pruritic, violaceous, polygonal lesions with a characteristic flat-topped surface and Wickham striae.
- *Postinflammatory hyperpigmentation:* Develops following eczema, trauma, or other inflammatory skin conditions, presenting as dark patches in the affected area.

MANAGEMENT

Dermatologist Management

- No specific therapy required for most cases.
- Reassure patient about the benign and selflimiting nature of the condition.
- *Supportive skin care*:
  - Use moisturizers or emollients to reduce dryness.
  - Apply broadspectrum sunscreen to prevent pigment intensification.
- *Cosmetic options (if desired)*:
  - Topical retinoids (e.g., tretinoin 0.025%)
  - Azelaic acid (15–20%) or Kojic acid for lightening hyperpigmentation[5,6]

Diabetologist/Physician Management

- Optimize glycemic control with intensification of therapy (oral agents or insulin as required).
- *Address associated comorbidities*: Hypertension and dyslipidemia.
- *Screen for microvascular complications*:
  - Fundoscopy for diabetic retinopathy
  - Urine albumin assessment for nephropathy
  - Foot examination for early neuropathy
- *Provide patient education on foot care*:
  - Gentle cleaning and inspection of skin
  - Avoid trauma or friction in affected areas

PROGNOSIS

- Benign and nonprogressive
- Individual lesions may *persist for years* or gradually fade.
- New lesions can develop with ongoing poor glycemic control.
- May act as a *cutaneous biomarker* for systemic microvascular complications.[1,3]

Clinical Pearls

- The most common dermatologic sign of diabetes mellitus.[1]
- Frequently overlooked but may correlate with silent retinopathy or nephropathy.[3]
- No biopsy required in classical presentations.[1,3]
- The presence of bilateral, atrophic brown macules over the shins in a diabetic patient should be considered "diabetic dermopathy" until proven otherwise.[1,3]
- The progression and activity of these lesions often mirror the patient's glycemic control.[1]

JAYPEE BROTHERS

REFERENCES

1. Nigam PK, Saxena AK. Diabetic dermopathy: A cutaneous marker of microangiopathy in diabetes mellitus. Indian J Dermatol. 2019;64(5):379-84.
2. Sanad EM, ElFangary MM, Sorour NE, ElNemisy NM. Skin manifestations in Egyptian diabetic patients: a case-series study. Egypt J Dermatol Venerol. 2013;33(2):56-62.
3. Dinneen SF, Bruckner A, Kirby B, Rogers S, McCulloch DK. Diabetic dermopathy: A marker for microangiopathy. Clin Endocrinol. 1995;43(5):593-8.
4. Singh R, Akhtar N, Chauhan A, Singh A. Histopathological and clinical correlation of diabetic dermopathy. J Clin Diagn Res. 2015;9(6):WC01-WC03.
5. Kumar S, Dogra D, Gupta S. Dermoscopic features of diabetic dermopathy. Clin Dermatol Rev. 2021;5(1):21-4.
6. DiNardo JC. Skin manifestations of diabetes. Clin Dermatol. 2023;41(2):212-9.

JAYPEE BROTHERS

for detailed information on endocrinology books, visit our website www.ejaypee.com, for detailed information on endocrinology books, visit our website www.ejaypee.com, for detailed informa

RSSDI Atlas of Dermatological Conditions in Diabetes

Salient Features

- The "RSSDI Atlas of Dermatological Conditions in Diabetes" provides a concise and clinically relevant overview of the wide range of skin changes associated with diabetes.
- It highlights how early cutaneous signs can serve as valuable indicators of underlying metabolic dysfunction.
- The atlas simplifies complex pathophysiology and connects it with real-world clinical presentations.
- Rich in visuals and practical guidance, it empowers clinicians to recognize, diagnose, and manage diabetic dermatoses more effectively.
- This book is an essential tool for diabetologists, dermatologists, general physicians, and postgraduate trainees involved in diabetes care.

Editor-in-Chief

NK Singh
MD FICP FACP FRSSDI
Director
Department of Diabetology
Diabetes and Heart Research Centre, Dhanbad, Jharkhand, India
VICE President (Elect) 2026–2029, RSSDI
Founder CME INDIA

Assistant Editors

Akashkumar N Singh
MD(Medicine) MSc(Diabetes) FRCP(Edinburgh & Glasgow) FACP FICP FRSSDI Fellow Diabetes India FIACM FISH FISC FCCDSI
Director
Department of Internal Medicine & Diabetes
Manjalpur Hospital Private Limited
Vadodara, Gujarat, India

Anuradha Kapoor
MD PG diploma in Clinical Endocrinology and Diabetes Fellow ICCMD(CCDSI)
Preventive Diabetologist
Department of Diabetology
Lifeline Medicare Hospital
Mumbai, Maharashtra, India

Amit Kumar
MD(Derm & STD)
Dermatologist
Department of Dermatology
CosmoDerma
Ranchi, Jharkhand, India

Associate Editors

Vijay Vishwanathan
MD DNB FICP FRCP(Glasgow)
Honorary President, D-Foot International
President, RSSDI
Head and Chief Diabetologist
Prof M Viswanathan Diabetes Research Centre,
Chennai, Tamil Nadu, India

Anuj Maheshwari
MD FACP FACE FRSSDI FRCP(London & Edinburgh)
Diabetologist & Metabolic Physician
President Elect, RSSDI
Professor in Medicine
Hind Institute of Medical Sciences
Lucknow, Uttar Pradesh, India

Sanjay Agarwal
MD FRSSDI FACE(USA)
Secretary General, RSSDI
Director, Aegle Clinic – Diabetes Care Head,
Department of Medicine and Diabetes
Senior Consultant in Diabetes and Endocrine Medicine
Jehangir Hospital, Pune, Maharashtra, India

Shelving Recommendation
ENDOCRINOLOGY

ISBN 978-93-7202-069-4

9 789372 020694

Buy from ejaypee

JAYPEE BROTHERS