iled information on dermatology books, visit our website www.ejaypee.com, for detailed information on dermatology books, visit our website www.ejaypee.com,

DYP Dermatopathology Handbook

Punch to Proof



Editors
Sharmila Patil
Fiza Choudhary
Kritika Singh Yadav

Foreword
Rajiv Rao

JAYPEE

Contents

Clinical Presentation & Histopathological Findings on Dermatologic Conditions

Case 1: Acne Fulminans 2

Case 2: Acne Keloidalis Nuchae 4

Case 3: Acute Generalized Exanthematous Pustulosis 6

Case 4: Angiokeratoma 8

Case 5: Annular Elastolytic Giant Cell Granuloma 10

Case 6: Basal Cell Carcinoma 12

Case 7: Borderline Lepromatous Leprosy 14

Case 8: Borderline Tuberculoid Leprosy 16

Case 9: Bowen's Disease 18

Case 10: Bullous Pemphigoid 20

Case 11: Confluent and Reticulated Papillomatosis 22

Case 12: Cutaneous Histoplasmosis 24

Case 13: Dermatitis Herpetiformis 26

Case 14: Dermatophytosis (Tinea) 28

Case 15: Dyschromatosis Universalis Hereditaria 30

Case 16: Erythema Elevatum Diutinum 32

Case 17: Erythema Induratum 34

Case 18: Genital Wart 36

Case 19: Glomangioma 38

Case 20: Hailey–Hailey Disease 40

Case 21: Henoch–Schönlein Purpura 42

Case 22: Histoid Leprosy 44

Case 23: Intradermal Nevus 46

Case 24: Keratoacanthoma **48**
Case 25: Lamellar Ichthyosis **50**
Case 26: Lentigens **52**
Case 27: Leukoplakia **54**
Case 28: Lichen Planopilaris **56**
Case 29: Lichen Planus **58**
Case 30: Lichen Sclerosus et Atrophicus **60**
Case 31: Lichen Scrofulosorum **62**
Case 32: Lichenoid Pseudovesicular Eruption of the Nose **64**
Case 33: Linear and Whorled Hypermelanosis **66**
Case 34: Lobular Capillary Hemangioma **68**
Case 35: Molluscum Contagiosum **70**
Case 36: Morphea **72**
Case 37: Papulonecrotic Tuberculid **74**
Case 38: Parapsoriasis **76**
Case 39: Pemphigus Foliaceous **78**
Case 40: Pemphigus Vulgaris **80**
Case 41: Pityriasis Amiantacea **82**
Case 42: Pityriasis Rosea **84**
Case 43: Polymorphous Light Eruption **86**
Case 44: Prurigo Nodularis **88**
Case 45: Psoriasis **90**
Case 46: Pseudopelade of Brocq **92**
Case 47: Seborrheic Keratoses **94**
Case 48: Stasis Dermatitis **96**
Case 49: Steatocystoma Multiplex **98**
Case 50: Trichilemmal Cyst (Pilar Cyst) **100**
Case 51: Tuberculosis Verrucosa Cutis **102**
Bibliography **105**
Index ***107***

Case 1

Case History: A 19-year-old male, a known case of acne vulgaris comes with complains of pustular and nodular lesions over the face, back, chest and neck with aggrevation of lesion since 3 months.

CLINICAL IMAGE



On Examination: Multiple well-defined erythematous nodules and cyst present over face with few pustules seen along with it.

Clinical Differential Diagnosis: Acne Conglobata/Acne Fulminans

Clinical Differential Diagnosis	Key Clinical Features
Acne conglobata	Severe form of nodulocystic acne without systemic manifestations, chronic course, lacks ulceration and necrosis.
Acne fulminans	The most severe form of acne with nodular and suppurative lesions, rapidly painful oozing plaques, haemorrhagic crusts and granulation tissue, leading to severe scarring.
Folliculitis	Superficial pustules, not deep abscesses.

JAYPEE BROTHERS

HISTOPATHOLOGY

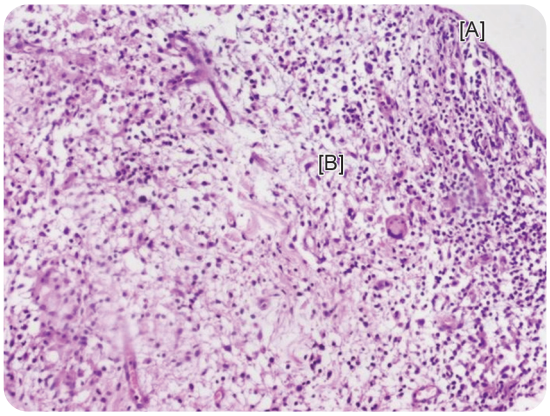

FIG. 1: Epidermis: Ulcerated with necrosis [A]. Dermis: Mixed inflammation comprising of neutrophils, lymphocytes, plasma cells, few giant cells consistent with dermal abscess. No adnexal structures seen [B].

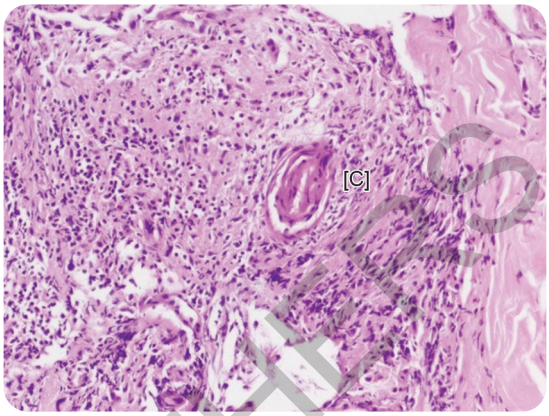

FIG. 2: Few hyalinized blood vessels also seen [C].

Histopathological D/D: Hidradenitis suppurativa.

Diagnosis: Acne Fulminans

- Acne fulminans is characterized by a sudden, aggressive eruption of ulcerative and inflammatory nodules associated with systemic symptoms.
- More common in young men.
- Types: Acne fulminans – classic, acne fulminans without systemic symptoms, isotretinoin induced acne fulminans, acne fulminans sine acne.
- Associated with osteolytic bone changes and erythema nodosum.
- Hallmark feature of acne fulminans is its potential to be precipitated or exacerbated by oral isotretinoin.

JAYPEE BROTHERS

Case 2

Case History: A 28-year-old man complains of recurrent painful, pus-filled lesions gradually increasing in size and number over the occiput since 2 years which healed with scarring.

CLINICAL IMAGE



On Examination: Multiple well-defined skin-colored to erythematous plaques seen over the nape of the neck.

Clinical Differential Diagnosis: Acne Keloidalis Nuchae

Clinical Differential Diagnosis	Key Clinical Features
Acne keloidalis nuchae	Firm hypertrophic papules and plaques resembling keloid or scar with rubbery feel and follicular pustules present at nape of the neck with loss of hair.
Chronic folliculitis	Erythema, inflammation around the affected follicles healing with scarring.

JAYPEE BROTHERS

HISTOPATHOLOGY

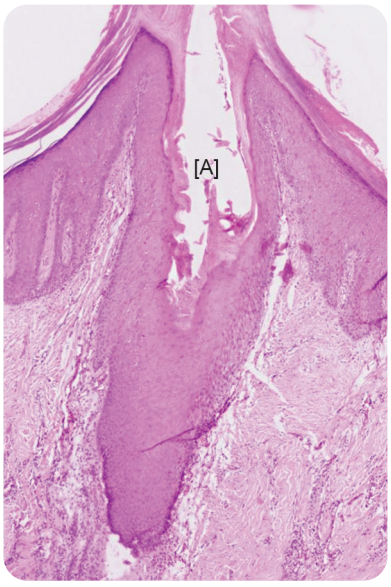

FIG. 1: Skin biopsy shows single hair follicle with follicular plugging [A].

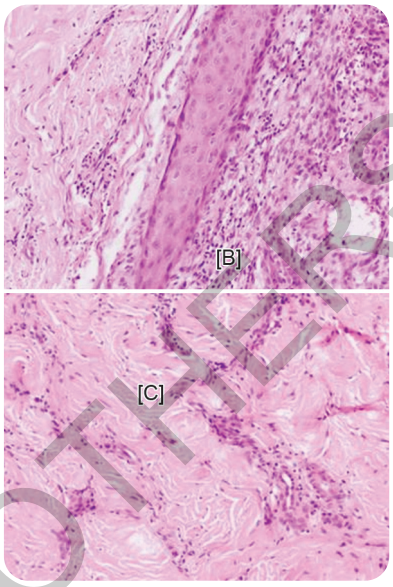

FIG. 2: Perifollicular inflammation [B] and surrounding dermal fibrosclerosis [C].

Diagnosis: Acne Keloidalis Nuchae

- Early lesions on microscopy show granulomatous folliculitis—rupture of hair follicle and giant cell reaction around naked hair shafts.
- The name is a misnomer as it is neither related to acne nor keloid formation.
- Predisposed individuals include people with dark, thick, curly hair, people wearing collared shirts leading to constant irritation.
- Can be associated with pseudofolliculitis barbae and seborrheic dermatitis.

JAYPEE BROTHERS

Case 3

Case History: A 4-year-old male child presented with fluid filled lesions over the face and flexural areas since 2 days. History of capsule amoxiclav taken for fever prior to the onset of lesions.

CLINICAL IMAGE



On Examination: Multiple well-defined pustules and erythematous papules and vesicles seen over head, nape of the neck and trunk.

Clinical Differential Diagnosis: Acute Generalized Exanthematous Pustulosis (AGEP)

Clinical Differential Diagnosis	Key Clinical Features
Pityriasis lichenoides et varioliformis acuta (PLEVA)	Papulonecrotic lesions, crusting, varioliform scars, usually idiopathic or post-infectious.
Varicella zoster (Chickenpox)	Vesicular rash in crops, starts on trunk and spreads, with multinucleated giant cells on tzanck smear.
Hand foot mouth disease (HFMD)	Vesicles and ulcers on hands, feet, and mouth, caused by enteroviruses.

JAYPEE BROTHERS

HISTOPATHOLOGY

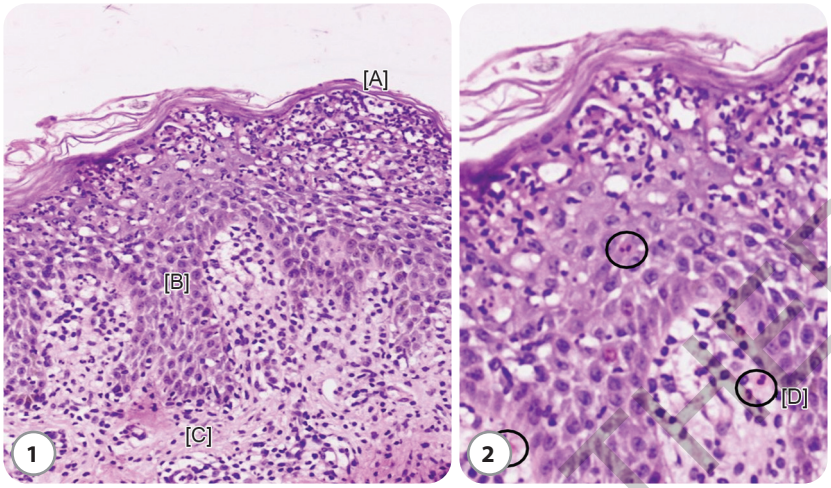

FIGS. 1 AND 2: Epidermis shows subcorneal pustule formation [A]; Neutrophilic infiltrate within epidermis and spongiosis. [B]; Mild papillary dermal edema along with peri-vascular mixed inflammatory cell infiltrate [C] comprising occasional eosinophils [D].

Histopathological D/D: Pustular psoriasis (shows acanthosis and no dermal eosinophils).

Diagnosis: Acute Generalized Exanthematous Pustulosis

- It is a rare severe drug-induced pustular lesion triggered by beta-lactam antibiotics, calcium channel blockers, NSAID's.
- Keratinocyte necrosis may be seen focally in the pustules, mimicking pustular psoriasis.
- Can uncommonly evolve into generalized exfoliative dermatitis if prolonged.
- IL-36 pathway has been implicated in familial/refractory cases.

JAYPEE BROTHERS

Case 4

Case History: A 15-year-old boy came with complaints of lesions over right leg and buttock since birth, patient tried multiple treatments.

CLINICAL IMAGE

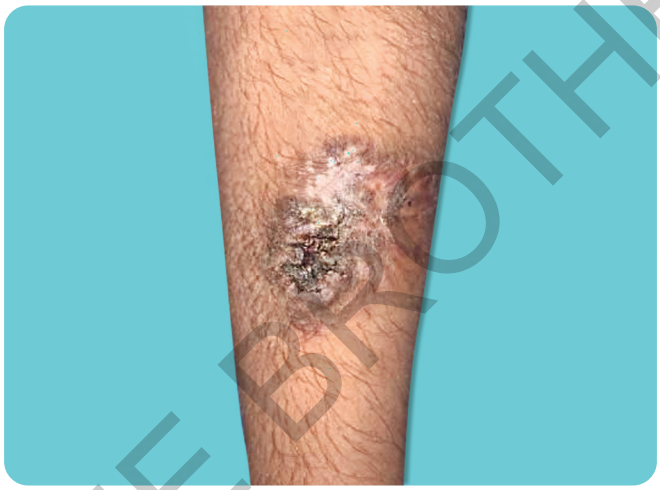

On Examination: Single well-defined hyperpigmented plaque seen over the right leg.

Clinical Differential Diagnosis: Angiokeratoma Circumscriptum Nevi Form

Clinical Differential Diagnosis	Key Clinical Features
Angiokeratoma	Angiokeratomas are firm, dark red to black, non-blanchable papules with a warty surface that may bleed on trauma.
Verrucous hemangioma	Hyperkeratotic vascular lesion involving both superficial and deep dermis, often extending into subcutaneous tissue.
Melanocytic nevus (epidermal nevus)	Pigmented or skin-colored plaques, often linear, without vascular proliferation.
Verruca vulgaris	Hyperkeratotic papules with papillomatosis, caused by HPV, with viral cytopathic effects.

JAYPEE BROTHERS

HISTOPATHOLOGY

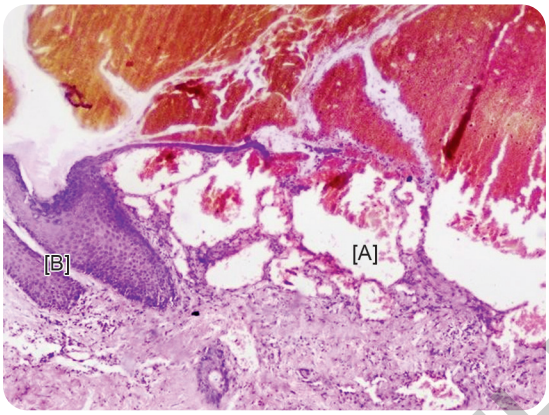

FIG. 1: Ectasia of papillary dermal vessels lined by bland endothelial cells [A]; Reactive epidermal hyperplasia wrapping around the dilated cavernous channels [B].

Histopathological D/D: Hemangioma (extends to deep dermis and subcutaneous tissue, no acanthosis)

Diagnosis: Angiokeratoma

- Rare "zosteriform" or linear patterns along Blaschko's lines have been reported.
- Vessels may be dilated in the papillary dermis but can also extend focally into reticular dermis.
- Some show superficial thrombosis, leading to pain or ulceration.

JAYPEE BROTHERS

for detailed information on dermatology books, visit our website www.ejaypee.com, for detailed information on dermatology books, visit our website www.ejaypee

DYP Dermatopathology Handbook
Punch to Proof

Dermatopathology is central to dermatology, translating clinical findings into definitive diagnoses. Yet for many postgraduates, it feels overwhelming and fragmented across large texts. This book bridges that gap by presenting dermatopathology in a clear, structured, and clinically relevant format.

Built around real cases, it guides readers from history and examination to differential diagnosis, histopathology, and final interpretation, with key teaching points in each case. Emphasizing clinicopathological correlation, it highlights how microscopic patterns and cellular details shape accurate diagnosis.

Designed for postgraduate students and practicing dermatologists alike, the book offers concise, image-based learning that is practical for exams, revision, and everyday clinical practice—strengthening confidence at the microscope and beyond.



Sharmila Patil MD DDVL FAIMER PGDHHM is Professor and Head of Dermatology at Dr DY Patil Medical College, Hospital and Research Centre, Navi Mumbai, Maharashtra, India. A Former Honorary Secretary General of IADVL Maharashtra and FAIMER Fellow, she has received multiple Best Teacher Awards at state and national levels, including the prestigious Teacher of Teachers Award. With over 100 publications and 4 edited books to her credit, Dr Patil is widely recognized for her academic contributions and commitment to mentoring future dermatologists.



Fiza Choudhary MBBS MD(Dermatology) is Assistant Professor in the Department of Dermatology at Dr DY Patil Medical College, Hospital and Research Centre, Navi Mumbai, Maharashtra, India. She has extensive experience in managing outpatient and inpatient dermatological cases, with expertise in dermatologic surgery, vitiligo surgery, and laser dermatology. She has published several articles, particularly on hyperpigmentary disorders, and focuses on advancing evidence-based dermatology.



Kritika Singh Yadav MD DNB DipRCPath(Histopathology) is Associate Professor of Pathology at Dr DY Patil Medical College, Hospital and Research Centre, Navi Mumbai, Maharashtra, India. She completed her MD in Pathology from Seth GS Medical College and KEM Hospital, Mumbai. She has international research experience at the Cancer Science Institute, National University of Singapore, and has authored several peer-reviewed publications. Her academic interests include dermatopathology, and she is an Associate Member of the Asian Society of Dermatopathology.

Shelving Recommendation
DERMATOLOGY

ISBN 978-93-7202-166-0

Buy from ejaypee

JAYPEE BROTHERS