aypee.com, for detailed information on dermatology books, visit our website www.ejaypee.com, for detailed information on dermatology books,

Atlas and Synopsis of Contact and Occupational Dermatology



Sanjay Ghosh

Foreword
Magnus Bruze

3rd Edition

JAYPEE

CONTENTS

Chapter 1 Classification of Contact Dermatitis 1

Chapter 2 Irritant Contact Dermatitis 4

Chapter 3 Allergic Contact Dermatitis 8

Allergic Contact Dermatitis Syndrome 11

Airborne Contact Dermatitis 23

Chapter 4 Investigations of Allergic Contact Dermatitis 29

Patch Test 29

Patch Test: Other Forms 39

Chapter 5 Regional Contact Dermatitis 40

Regional Assessment: Importance 40

Hand Dermatitis 44

Chapter 6 Non-eczematous Contact Dermatitis 52

Lichenoid Contact Dermatitis or Lichen Planus-like CD 52

Oral Lichenoid Contact Dermatitis 56

Pigmented Contact Dermatitis 57

Bullous Contact Dermatitis 61

Purpuric Contact Dermatitis 62

Erythema Multiforme-like Contact Dermatitis 63

Contact Urticaria 65

Chapter 7 Contact Dermatitis from Topical Medicaments 67

Chapter 8 Contact Dermatitis from Footwear 70

Chapter 9 Contact Dermatitis from Cosmetics 76

Chapter 10 Contact Dermatitis from Ornaments 80

Chapter 11 Contact Dermatitis from Daily-usage Objects 83

Chapter 12 Occupational Contact Dermatitis 86

Chapter 13 Chemical Leukoderma 90

Chapter 14 Photocontact Dermatitis 98

Photopatch Test 102

Chapter 15 Contact Dermatitis: Differential Diagnosis 104

Atopic Dermatitis 104
Seborrheic Dermatitis 105
Psoriasis 106
Tinea Infection 107
Polymorphous Light Eruption 109

Chapter 16 Complications of Contact Dermatitis 110

Chapter 17 Management of Contact Dermatitis 112

Management: Occupational Dermatitis 119
Management: Photocontact Dermatitis 119
Management: Chemical Leukoderma 119

Bibliography 121

Index 123

CHAPTER 15

Contact Dermatitis: Differential Diagnosis

Contact dermatitis may simulate many dermatoses very closely. Detailed history, clinical findings, certain pathological tests and patch test can differentiate between these diseases.

Contact Dermatitis: Differential Diagnosis

- Atopic dermatitis
- Seborrheic dermatitis
- Psoriasis
- Tinea infection
- Polymorphous light eruption (PLE)

ATOPIC DERMATITIS

SALIENT FEATURES

- Usually onset at childhood
- Family history of atopy (allergic rhinitis, bronchial asthma, allergic conjunctivitis)
- Personal history of atopy
- High IgE level (usually)
- Infants: Extensor aspect of the limbs affected
- Older children/adults: flexural aspect more affected
- Fulfil major and minor criteria of atopic dermatitis.

Atopic Dermatitis (AD) and Systemic Reaction of Contact Dermatitis (SRCD)

	AD	SRCD
Onset	Childhood	Adulthood
Family history	Usually +ve	–ve
IgE	Usually high	Normal
Patch test to offending allergens	–ve	+ve



FIGURE 1

Atopic dermatitis of an adult involving flexors of the limbs.

JAYPEE BROTHERS

SEBORRHEIC DERMATITIS

SALIENT FEATURES

- Greasy scales or erythematous scaly dermatitis on scalp, face (eyebrows, beard area, nasolabial furrows), front and back of chest, axillae, groin and flexors
- First 6 to 9 months of age and then after puberty age group
- Occasionally familial.

Seborrheic Dermatitis and Airborne Contact Dermatitis: Comparison

	Seborrheic Dermatitis	Airborne Contact Dermatitis
Age	Infancy, puberty, adult	Not in infancy
History	No h/o aeroallergens	H/o aeroallergens
Patch test	–ve	+ve



FIGURES 2A AND B

Seborrheic dermatitis of a patient involving face and axillae.

JAYPEE BROTHERS

PSORIASIS

SALIENT FEATURES

- Silver dry scales on scalp, extensor aspect of limbs, palmoplantar area or lower back
- Well-defined border
- Guttate psoriasis are dewdrop like generalized eruption with minimal scales
- Auspitz sign +ve
- Nail pitting and other nail changes
- Occasionally arthropathy
- Patch test negative.



FIGURE 3

Guttate psoriasis in a man.



FIGURE 4

Psoriasis involving fingers and extensor aspect of knee.

JAYPEE BROTHERS

TINEA INFECTION

SALIENT FEATURES

- Inflammatory active border and central clearing
- Characteristic nail changes occasionally
- Usually unilateral
- Skin scraping or nail clipping shows positive fungal smear (by KOH)
- Patch test negative.



FIGURE 5

Tinea corporis of abdomen with active border.



FIGURES 6A AND B

Tinea pedis and tinea manuum with onychomycosis of same person showing active border.

JAYPEE BROTHERS

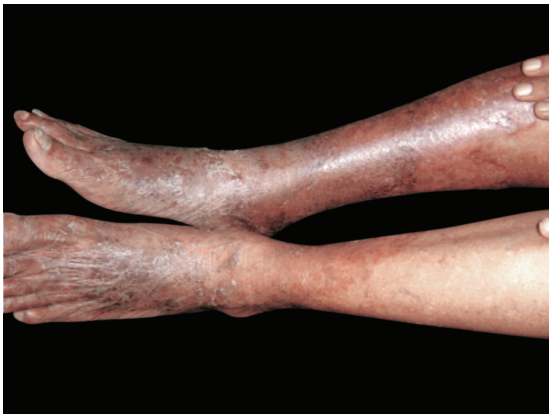

FIGURE 7

Tinea of feet with active border.



FIGURE 8

Tinea of hands with active border involving one hand mostly interdigital areas.



FIGURE 9

Tinea on dorsum of feet showing active border and central clearing.

JAYPEE BROTHERS

POLYMORPHOUS LIGHT ERUPTION

SALIENT FEATURES

- Eczematous eruption on exposed skin, i.e. dorsum of hand and feet, forehead, V-area of neck
- No history of contact with photoallergens
- Photopatch test negative.



FIGURE 10

Polymorphous light eruption on dorsum of hands, photopatch test being negative.

JAYPEE BROTHERS

for detailed information on dermatology books, visit our website www.ejaypee.com, for detailed information on dermatology books, visit our web

Atlas and Synopsis of
Contact and Occupational Dermatology

Key Features

- The new edition provides updated knowledge of the subject in a concise and comprehensive manner.
- The manuscript has been updated as per the current understanding in the field.
- In this edition, special focus has been put upon the chapters of systemic contact dermatitis, airborne contact dermatitis, and noneczematous contact dermatitis with their recent updates.
- Special emphasis has been laid on allergic contact dermatitis and dermatitis due to contact with topical medicaments, cosmetics, ornaments, footwear, and other daily usage objects.
- A chapter is especially dedicated to chemical leukoderma as the subject has seen a lot of advances in recent years.
- This edition includes chapters on detailed discussion of differential diagnoses, investigations, and management of contact dermatitis.
- Each chapter includes key points highlighting the clinical experience of the authors.
- The book is a treasure trove of knowledge not only to the dermatologists, but also to the practicing physicians and postgraduate students.

Sanjay Ghosh MD(Dermatology and Venerology) (Kolkata) is a Professor, Department of Dermatology, Santiniketan Medical College, Bolpur, West Bengal, India. He is former Professor and Head, Department of Dermatology and Venereology at MGM Medical College and LSK Hospital, Kishanganj, Bihar, India, and former Medical Director (Honorary), Institute of Allergic and Immunologic Skin Diseases (IAISD), Kolkata, West Bengal. He was former Vice-President of Contact and Occupational Dermatoses Forum of India (CODFI); Ex-Coordinator, Psoriasis SIG Group, IADVL; and Ex-Member, IADVL SIG Urticaria Group. He was the former Editor of Indian Journal of Dermatology. He has been a past reviewer of British Journal of Dermatology, Clinical and Experimental Dermatology, Indian Journal of Dermatology, and Indian Journal of Dermatology, Venereology, and Leprology. He is the author of Atlas and Synopsis of Contact and Occupational Dermatology, Manual of Rational Skin Therapy and Dermatological Drugs, 201 Skin Diseases, and Urticaria and Angioedema Management. He has also contributed to all the past editions of IADVL Textbook of Dermatology. He is the Editor of Recent Advances in Dermatology I, II, and III and CODFI Newsletter. He was awarded with Ambady Oration 2014 DERMACON ICD, Delhi; RK Panja Memorial Oration CUTICON 2013; AK Jha Oration CUTICON Bihar 2018; NRS 150 Foundation Day Oration 2022; Life Time Achievement Award: AAD India Conclave 2024; IADVL Best Teacher Award 2025; and Dr AK Bajaj Memorial Oration at APEOD and CODFICON 2025. He has been practicing in his field for more than 37 years.

Shelving Recommendation
DERMATOLOGY

ISBN 978-93-7202-272-8

9 789372 022728

Buy from ejaypee

JAYPEE BROTHERS