ejaypee.com, or detailed information on ophthalmology books, visit our website www.ejaypee.com, or detailed information on ophthalmology books, visit our website www.ejaypee.com

CLINICAL OPHTHALMOLOGY

(Medical and Surgical Care)

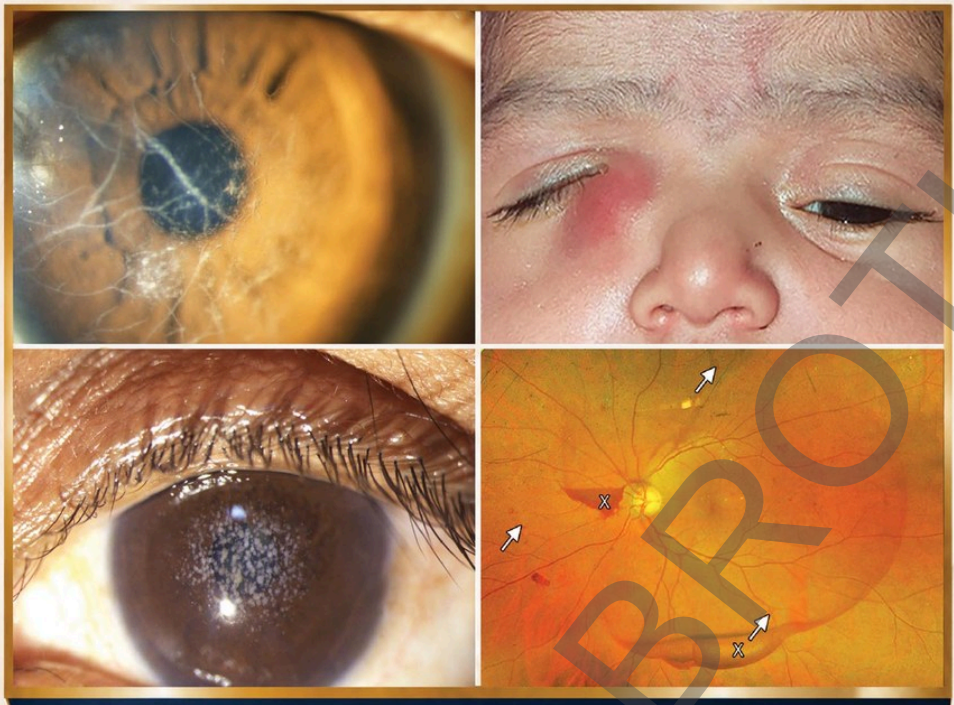

Volume 1

MEDICAL

Editor **Prafulla Kumar Maharana**

Co-Editors
Pranita Sahay • Gunjan Saluja
Devesh Kumawat • Namrata Sharma

JAYPEE

website www.ejaypee.com, or detailed information on ophthalmology book

AL
OLOGY
cal Care)

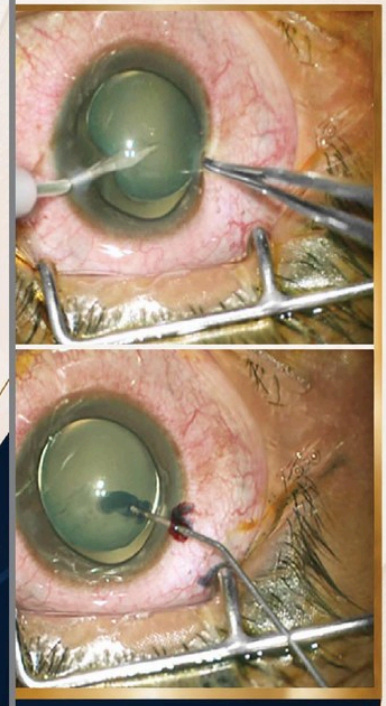

Volume 2

SURGICAL WITH VIDEOS

Editor **Prafulla Kumar Maharana**

Co-Editors
Aafreen Bari • Anu Malik
Namrata Sharma

JAYPEE

JAYPEE BROTHERS

Contents

Volume 1

MEDICAL

SECTION 1 ORBIT

Section Editor: Sanjana Molugu

1.1. Eyelids 1

1.1.1 **Eyelid Anatomy 1**
Oshin Bansal, Jyoti Batra

1.1.2 **Eyelid Embryology and Congenital Anomalies of Eyelid 9**
Oshin Bansal, Anirudh Vaishnav, Jyoti Batra

1.1.3 **Blepharitis 14**
Oshin Bansal, Jyoti Batra

1.1.4 **Blepharoptosis 18**
Kavya Madhuri Bejjanki

1.1.5 **Eyelid Reconstruction 36**
Kavya Madhuri Bejjanki, Anasua Ganguly Kapoor

1.1.6 **Tumors of the Eyelids 44**
Vijitha S Vempuluru, Anasua Ganguly Kapoor

1.1.7 **Management of Eyelid Tumors 51**
Vijitha S Vempuluru, Anasua Ganguly Kapoor

1.1.8 **Eyelid Retraction 54**
Akruti Desai, Roshmi Gupta

1.1.9 **Eyelid Malpositions: Entropion and Ectropion 60**
Akruti Desai, Suryasnata Rath

1.2. Lacrimal Drainage System 71

1.2.1 **Anatomy of the Lacrimal Drainage System 71**
Ayushi Agarwal, Prerna Sinha, Nandini Bothra

1.2.2 **Congenital Lacrimal Disorders 73**
Ayushi Agarwal, Nandini Bothra

1.2.3 **Acquired Lacrimal Disorders 79**
Ayushi Agarwal, Priyanka Walvekar, Nandini Bothra

1.2.4 **Evaluation of Epiphora 86**
Nandini Bothra, Ayushi Agarwal

JAYPEE BROTHERS

1.2.5 Dacryocystorhinostomy 91
Ayushi Agarwal, Nandini Bothra

1.2.6 Dacryocystectomy 98
Ayushi Agarwal, Nandini Bothra

1.3. Orbit 100

1.3.1 Orbital Anatomy 100
Akruti Desai, Anasua Ganguly Kapoor

1.3.2 Orbital Inflammatory Diseases 109
Sumer Doctor, Vidhi Anklesaria, Tarjani Vivek Dave

1.3.3 Orbital Infections 121
Ashi Morawala

1.3.4 Congenital Lesions of Orbit 131
Vijitha S Vempuluru, Anasua Ganguly Kapoor

1.3.5 Orbital Cysts and Tumors 136
Vijitha S Vempuluru, Keerthana Kasi, Anasua Ganguly Kapoor

1.3.6 Anophthalmic Socket 152
Sumer Doctor, Vidhi Anklesaria, Tarjani Vivek Dave

1.3.7 Thyroid Eye Disease 165
Varshitha Hemanth Vasanthapuram

1.3.8 Orbitotomy 179
Vijitha S Vempuluru, Anasua Ganguly Kapoor

1.3.9 Techniques of Evisceration and Enucleation 182
Tarjani Vivek Dave

1.4. Tumors 188

1.4.1 Ocular Surface Tumors 188
Sanjana Molugu, Anasua Ganguly Kapoor

1.4.2 Intraocular Tumors 203
Vijitha S Vempuluru, Anasua Ganguly Kapoor

SECTION 2 CONJUNCTIVA

Section Editor: Aafreen Bari

2.1. Anatomy of Conjunctiva 211
Siddhartha Rao BS, Keerthana Kasi, Aafreen Bari

2.2. Bacterial Conjunctivitis 217
Chandradevi Shanmugam, Shivayan Srivastava, Aafreen Bari

2.3. Viral Conjunctivitis 223
Ananya Parampalli Ravindra, Aafreen Bari

2.4. Allergic Conjunctivitis 230
Aafreen Bari, Hemant Jhajharia, Prafulla Kumar Maharana

2.5. Trachoma 238
Aafreen Bari, Siddhartha Rao BS, Aniket Ramteke

JAYPEE BROTHERS

2.6. Conjunctivitis in Blistering Mucocutaneous Conditions 244
Jyothi Balakrishnan, Aafreen Bari

2.7. Miscellaneous Disorders of Conjunctiva 250
Aafreen Bari, Siddhartha Rao BS

2.8. Conjunctival Degenerations 252
Vishal Kumar, Naintara Chouhan, Aafreen Bari

2.9. Subconjunctival Hemorrhage 258
Avneet Kaur, Subikshaa S, Aafreen Bari

SECTION 3 DRY EYE DISEASE

Section Editor: Priyadarshini K

3.1. Tear Film and Lacrimal Function Unit 261
Chandradevi Shanmugam, Priyadarshini K

3.2. Dry Eye Disease 266
Chandradevi Shanmugam, Priyadarshini K, Pranita Sahay

3.3. Dry Eye Disease: Investigations 271
Priyadarshini K, Chandradevi Shanmugam

3.4. Specific Types of Dry Eye Disease 275
Priyadarshini K, Tanya Verma, Chandradevi Shanmugam

3.5. Dry Eye Disease: Management 287
Priyadarshini K, Chandradevi Shanmugam

SECTION 4 CORNEA

Section Editor: Sohini Mandal

4.1. Anatomy 292
Mitali V Mangoli

4.2. Corneal Transparency 298
Sonali Sahoo

4.3. Corneal Edema 300
Nisha Rani

4.4. Congenital Anomalies of Cornea and Globe 306
Sikha Misra

4.5. Corneal Degenerations 317
Pranita Sahay, Tapashree Ghosh, Naintara Chouhan, Prafulla Kumar Maharana

SECTION 5 KERATITIS

Section Editor: Pranita Sahay

5.1. Introduction to Infective Keratitis 335
Pranita Sahay, Kanchita Pandey, Niranjana J, Mittali Khurana

JAYPEE BROTHERS

5.2. **Investigations in Keratitis** 347
Parul Jain, Chitra Ogia, Poornima Sen, Prarthana Gour

5.3. **Bacterial Keratitis** 356
Arpita Khasnavis, Aditya HR, Rashmi Deshmukh

5.4. **Fungal Keratitis** 369
Pranita Sahay, Vaishali Tomar, Aarushi Saini, Niranjana J

5.5. **Herpes Simplex Keratitis** 380
Anitha Venugopal, Pranita Sahay

5.6. **Herpes Zoster Ophthalmicus** 395
Rakhi Kusumesh, Nilesh Mohan

5.7. **Interstitial Keratitis** 404
Gayathri Karunanithi, Shikha Jain

5.8. **Protozoan Keratitis** 411
Anita Raghavan, Ram Rammohan

5.9. **Pythium Keratitis** 421
Bharat Gurnani, Kirandeep Kaur

5.10. **Bacterial Hypersensitivity-mediated Keratitis** 427
Sohini Mandal

5.11. **Contact Lens-associated Keratitis** 434
Kalathil Reshmi Shaji, Anubha Rathi

5.12. **Postsurgery Infective Keratitis** 440
Aastha Singh, Ramneek Kaur Mahal, Naintara Chouhan, Pranita Sahay

5.13. **Peripheral Ulcerative Keratitis** 451
Pranita Sahay, Disha Goyal, Prafulla Kumar Maharana

5.14. **Exposure Keratopathy** 466
Ritika Mukhija, Vipul Singh

5.15. **Microsporidial Keratitis** 471
Pranita Sahay, Akansha Tailor, Prafulla Kumar Maharana

SECTION 6 CORNEAL ECTASIA AND DYSTROPHY

*Section Editor: **Manasi Tripathi***

6.1. **Keratoconus** 474
Prafulla Kumar Maharana, Manasi Tripathi, Siddhartha Rao BS, Ipsita Barman, Priyadarshana Bardoloi

6.2. **Other Cornea Ectasia** 486
Siddhartha Rao BS, Manasi Tripathi, Keerthana Kasi

6.3. **Corneal Dystrophy** 496
Akshaya Balaji, Manasi Tripathi, Tapashree Ghosh, Prafulla Kumar Maharana

6.4. **Metabolic Keratopathy** 525
Vandita Agarwal, Manasi Tripathi, Abhishek Kumar, Pranita Sahay

JAYPEE BROTHERS

SECTION 7 STRABISMUS AND NEURO-OPHTHALMOLOGY

Section Editor: Gunjan Saluja

7.1. Strabismus 535

7.1.1 Anatomy and Physiology of Extraocular Muscles 535
Mary Stephen, Karthikeyan Mahalingam, Gunjan Saluja

7.1.2 Clinical Evaluation of Strabismus: A Practical Approach 543
(Lt Col) Deepesh Unni, (Brig) Sanjay K Mishra, Abhilash Unnikrishnan, Sandeep Shankar, K Shyamsundar, Alok Sati, Bhupesh Bhatkoti, Sankalp Seth, Pradeep Kumar

7.1.3 Amblyopia 563
Nilutparna Deori, Rutusha Dodwad, Nikita Sah

7.1.4 Vergence Abnormalities 569
Kirandeep Kaur, Bharat Gurnani

7.1.5 Esotropia 576
Kirandeep Kaur, Bharat Gurnani

7.1.6 Exotropia 585
Abhipsa Sharma

7.1.7 Alphabet Pattern Strabismus 593
Divya Choudhary, Shailja Tibrewal

7.1.8 Paralytic Strabismus 603
Anita Ganger, Nikita Dash, Shashi Nath Jha

7.1.9 Congenital Cranial Dysinnervation Disorders 611
Mayank Jain

7.1.10 Monocular Elevation Deficiency 618
Jenil Nilesh Sheth

7.1.11 Brown Syndrome 623
Shweta Chaurasia

7.1.12 Botulinum Toxin Chemodenervation 631
Sandra Ganesh

7.2. Neuro-ophthalmology 637

7.2.1 Neuroimaging 637
Madhurima A Nayak

7.2.2 Pupil 645
Soveeta Rath, Rolli Khurana, Abhijay Luthra

7.2.3 Optic Neuritis 655
Abhipsa Sharma, Gunjan Saluja

7.2.4 Disc Edema 661
Anita Ganger, Suvir Dev, SN Jha

7.2.5 Optic Chiasma 672
Niranjana Balasubramaniam

7.2.6 Retrochiasmal Pathways 677
Gunjan Saluja

JAYPEE BROTHERS

7.2.7 **Supranuclear Disorders of Ocular Motility** 679
Suman Meena

7.2.8 **Cavernous Sinus Thrombosis and Orbital Apex Syndrome** 686
Gunjan Saluja

7.2.9 **Ocular Myopathies** 688
Gunjan Saluja

7.2.10 **Nystagmus** 693
Asha Samdani

7.2.11 **Neuralgia and Facial Spasms** 702
Mayur R Moreker, Tejas Patil, Zahra Parekh, Varsha Patil, Sunila Jaggi

7.2.12 **Migraine** 705
Mayank Jain

7.2.13 **Neuro-ophthalmology of Space Flight** 710
Akshaya Balaji, Karthikeyan Mahalingam

SECTION 8 LENS

Section Editor: Anu Malik

8.1. **Embryology and Anatomy of Lens** 713
Ravindra Kumar Chowdhury, Sarita Behera, Sharmistha Behera

8.2. **Physiology of Lens** 722
Sharmistha Behera, Devi Aiswarya Das, Rangumudri Sai Sunanda

8.3. **Pathological Changes in Age-related Crystalline Lens** 726
Rubie Malhotra

8.4. **Nutritional and Environmental Influences on Risk of Cataract** 732
Rituparna Sahoo, Sharmistha Behera, Ravindra Kumar Chowdhury

8.5. **Abnormalities of Lens** 737
Nayana Potdar, Salma Tabani, Himanshu Khandelwal

8.6. **Pediatric Cataract** 755
Ranjan Kumar Behera, Parul Chawla Gupta, Jaspreet Sukhija, Shweta Chaurasia

8.7. **Senile Cataract** 769
Pragati Garg, Aparajita Shukla

8.8. **Metabolic Cataract** 784
Pratyusha Ganne

8.9. **After Cataract** 786
Rubie Malhotra

8.10. **Clinical Evaluation of Cataract** 791
Pushpa Kumari, Sharmistha Behera, Rangumudri Sai Sunanda

8.11. **Management of Cataract** 798
Anu Malik, Himanshu Khandelwal

8.12. **Aphakia** 812
Sharmistha Behera, Rangumudri Sai Sunanda, Devi Aiswarya Das

JAYPEE BROTHERS

8.13. Intraocular Lenses 815
Devi Aiswarya Das, Sharmistha Behera

8.14. Ectopia Lentis 824
Nilima Khochikar, Deepti Kulkarni, Ameya Kulkarni, Anu Malik

SECTION 9 GLAUCOMA

Section Editor: Talvir Sidhu

9.1. Anatomy of Optic Nerve Head 828
Talvir Sidhu

9.2. Anatomy of Angle 832
Talvir Sidhu

9.3. Aqueous Humor Dynamics and Intraocular Pressure 837
Talvir Sidhu

9.4. Overview and Investigations in Glaucoma 843
Talvir Sidhu

9.5. Primary Open-angle Glaucoma 871
Talvir Sidhu

9.6. Normal Tension Glaucoma 883
Talvir Sidhu

9.7. Glaucoma Suspects-ocular Hypertension and Primary Open-angle Glaucoma Suspects 887
Talvir Sidhu

9.8. Primary Angle Closure Disease 891
Talvir Sidhu

9.9. Secondary Glaucoma 902
Talvir Sidhu

9.10. Pseudoexfoliation 903
Talvir Sidhu, Chavi Harkawat

9.11. Pigment Dispersion Syndrome and Pigmentary Glaucoma 906
Talvir Sidhu, Tanuj Dada

9.12. Neovascular Glaucoma 911
Talvir Sidhu

9.13. Uveitic Glaucoma and Uveitis-induced Ocular Hypertension 916
Talvir Sidhu

9.14. Steroid-induced Ocular Hypertension and Glaucoma 919
Talvir Sidhu, Chavi Harkawat, Mohit Goyal

9.15. Traumatic Glaucoma 923
Talvir Sidhu, Tanuj Dada

9.16. Lens-induced Glaucoma 932
Talvir Sidhu

JAYPEE BROTHERS

9.17. Iridocorneal Endothelial Syndrome 937
Talvir Sidhu, Tanuj Dada

9.18. Other Secondary Glaucomas 941
Talvir Sidhu

9.19. Juvenile Open-angle Glaucoma 943
Talvir Sidhu

9.20. Childhood Glaucoma 947
Talvir Sidhu

9.21. Primary Congenital Glaucoma (Isolated Trabeculodysgenesis) 948
Talvir Sidhu

9.22. Glaucoma in Phakomatoses 959
Talvir Sidhu, Tanuj Dada

9.23. Medical Management of Glaucoma 962
Talvir Sidhu

9.24. Lasers in the Management of Glaucoma-Peripheral Iridotomy, Selective Laser Trabeculoplasty, Cyclodestructive 976
Talvir Sidhu

9.25. Trabeculectomy and its Complications 988
Talvir Sidhu, Tanuj Dada

9.26. Nonpenetrating Glaucoma Surgery: Goniotomy and Trabeculotomy 1009
Ankush Mahajan

9.27. Minimally Invasive Glaucoma Surgery 1015
Ankush Mahajan

9.28. Glaucoma Drainage Devices 1025
Tirupati Nath, Ankur Sinha, Talvir Sidhu

SECTION 10 RETINA AND UVEA

Section Editor: Devesh Kumawat

10.1. Disorders of Vitreous Humor 1035
Amber Bhayana, Sriram Simakurthy, Devesh Kumawat

10.2. Retinal Detachment 1057
Athul S Puthalath, Siddhartha Rao BS, Devesh Kumawat

10.3. Retinal Vascular Disorders in Adults 1087
Ramanuj Samanta, Gitanjli Sood, Siddhartha Rao BS, Devesh Kumawat

10.4. Pediatric Retinal Vascular Disorders 1131
Devesh Kumawat, Rahul Bhatia

10.5. Acquired Macular Disorders 1146
Devesh Kumawat, Baiju Virani, Siddhartha Rao BS

JAYPEE BROTHERS

10.6. Fundus Dystrophies and Vitreoretinopathies 1207
Sikshya Moharana, Ridham Nanda, Poornachandra B, Srikanta Kumar Padhy

10.7. Uveitis 1232
Mousumi Banerjee, Shreya Nayak, Saumya Kumar, Debarun Sharma, Deeksha Rani, Anita Kumari, Megha Gupta, Devesh Kumawat

SECTION 11 REFRACTIVE SURGERY

Section Editor: Pranita Sahay

11.1. Refractive Surgery 1332
Pranita Sahay, Disha Goyal, Piyush Kumar, Luci Kaweri

SECTION 12 OCULAR TRAUMA

Section Editor: Ritu Nagpal

12.1. Mechanical Ocular Trauma 1360
Prafulla Kumar Maharana, Subikshaa S, Ritu Nagpal

12.2. Thermochemical Injuries of the Eye 1377
Prafulla Kumar Maharana, Anirudh Vaishnav, Burra Shivani Srivastava, Pranita Sahay

SECTION 13 SCLERA

Section Editor: Pranita Sahay

13.1. Episcleritis and Scleritis 1390
Niranjana J, Abhishek Kumar, Hardik Gupta, Pranita Sahay

SECTION 14 MISCELLANEOUS

Section Editor: Ritu Nagpal

14.1. Systemic Diseases and the Eye 1403
Ritu Nagpal, Devesh Kumawat, Prafulla Kumar Maharana

14.2. Genetics in Ophthalmology 1424
Shailja Tibrewal, Ria Sachdeva, Abha Gaur, Meenakshi Lallar

14.3. Artificial Intelligence in Ophthalmology 1444
Prafulla Kumar Maharana, Pranita Sahay, Ritu Nagpal

14.4. Limbal Stem Cell Deficiency 1448
Ritu Nagpal, Prafulla Kumar Maharana, Subikshaa S

JAYPEE BROTHERS

Volume 2
SURGICAL

SECTION 1 ORBIT

1.1. Ptosis 1455
Aafreen Bari, Kalaimani Senguttuvan

1.2. Entropion Surgeries 1463
Sravani Yarrarapu, Archana Singh, Livia Khan, Sahil Agrawal, Neelam Pushker

1.3. Ectropion Surgeries 1472
Sravani Yarrarapu, Archana Singh, Livia Khan, Sahil Agrawal, Neelam Pushker

1.4. Eyelid Reconstruction 1479
Livia Khan, Antriksh Wahi, Sravani Yarrarapu, Sahil Agrawal, Neelam Pushker

1.5. Chalazion 1485
Shreyosi Bala, Aafreen Bari

1.6. Evisceration 1488
Aafreen Bari, Kalaimani Senguttuvan

1.7. Enucleation 1491
Aafreen Bari, Deepsekhar Das

1.8. Orbitotomy 1494
Gaurav N Patil, Pritesh Shetty

SECTION 2 CONJUNCTIVA

2.1. Pterygium 1500
Inderjeet Kaur, Aafreen Bari

SECTION 3 CORNEA

3.1. Therapeutic Penetrating Keratoplasty 1506
Ananya Parampalli Ravindra, Aafreen Bari

3.2. Optical Penetrating Keratoplasty 1510
Ananya Parampalli Ravindra, Anirudh Vaishnav

3.3. Descemet's Stripping Automated Endothelial Keratoplasty 1514
Aafreen Bari, Ramneek Kaur Mahal, Tanya Verma

3.4. Descemet's Membrane Endothelial Keratoplasty 1519
Aafreen Bari, Subikshaa S, Prafulla Kumar Maharana

3.5. Superficial Anterior Lamellar Keratoplasty 1524
Inderjeet Kaur, Aafreen Bari, Anu Malik

JAYPEE BROTHERS

3.6. Anterior Lamellar Therapeutic Keratoplasty 1527
Aafreen Bari

3.7. Deep Anterior Lamellar Keratoplasty 1530
Aafreen Bari, Priyadarshana Bardoloi, Prafulla Kumar Maharana

SECTION 4 STRABISMUS AND NEURO-OPHTHALMOLOGY

4.1. Muscle Resection and Tenoplication of Rectus for Correction of Strabismus 1535
Akanksha Mulay

4.2. Muscle Recession Surgery for Correction of Strabismus 1538
Akanksha Mulay

4.3. Chemodenervation in Strabismus 1541
Hage Angku

4.4. Optic Nerve Sheath Fenestration 1543
Anant Shelke

SECTION 5 LENS

5.1. Phacoemulsification 1545
Aafreen Bari, Alok Singh, Pranita Sahay

5.2. Small Incision Cataract Surgery 1548
Zakir Hussain, Aafreen Bari, Anu Malik

5.3. Lens Aspiration 1552
Aafreen Bari, Tapashree Ghosh, Prafulla Kumar Maharana

5.4. Secondary Intraocular Lens Implantation 1556
Aafreen Bari, Naintara Chouhan, Prafulla Kumar Maharana

SECTION 6 GLAUCOMA

6.1. Trabeculectomy 1560
Anuja Patil

6.2. Goniotomy 1564
Anuja Patil

6.3. Glaucoma Drainage Device Surgery 1566
Adwitiya Biswas

6.4. Minimally Invasive Glaucoma Surgery 1569
Adwitiya Biswas

6.5. Nonpenetrating Glaucoma Surgeries and Cycloablative Procedures 1572
Adwitiya Biswas, Aafreen Bari

JAYPEE BROTHERS

SECTION 7 RETINA AND UVEA

7.1. Scleral Buckling 1576
Siddhartha Rao BS, Devesh Kumawat

7.2. Pneumatic Retinopexy 1580
Baiju Virani, Devesh Kumawat

7.3. Vitreoretinal Surgery 1584
Siddhartha Rao BS, Devesh Kumawat

SECTION 8 REFRACTIVE SURGERY

8.1. Photorefractive Keratectomy 1589
Vaibhav Namdev, Himanshu Khandelwal, Pranita Sahay

8.2. Laser-assisted in situ Keratomileusis 1591
Vaibhav Namdev, Tapashree Ghosh, Anu Malik

8.3. Small Incision Lenticule Extraction 1593
Vaibhav Namdev, Pranita Sahay

8.4. Phakic Intraocular Lens 1595
Vaibhav Namdev, Anirudh Vaishnav, Prafulla Kumar Maharana

Index 1597

JAYPEE BROTHERS

SECTION 13

Sclera

Section Editor: *Pranita Sahay*

13.1 EPISCLERITIS AND SCLERITIS

Niranjana J, Abhishek Kumar, Hardik Gupta, Pranita Sahay

RELEVANT ANATOMY

The sclera is a tough, fibrous, and opaque outer coat of the eye that provides structural integrity and serves as the site of attachment for extraocular muscles. The sclera develops from the mesenchyme surrounding the optic cup, predominantly derived from neural crest cells. It makes up about 85% of the eyeballs outer surface and offers protection to the inner structures of the eye. Sclera is divided into two subparts—(1) *scleral stroma* that forms the bulk of the sclera and (2) *lamina fusca*, which is the innermost brownish layer. It contains pigment cells and lies close to the suprachoroidal space.

The sclera is composed mainly of type I collagen arranged irregularly, which accounts for the opacity of sclera unlike the transparent cornea where collagen is regularly arranged. It also contains elastin fibrils embedded in a proteoglycan-rich matrix, with a sparse population of fibroblasts and melanocytes.[1,2]

Its opacity is due to the irregular arrangement and variable diameter of collagen fibrils. The episclera is a thin vascular layer of loose connective tissue that lies superficial to the sclera and deep to the Tenon's capsule and conjunctiva. It carries the deep episcleral vascular plexus, which plays a central role in the pathogenesis of both episcleritis and scleritis **(Fig. 1)**.[3]

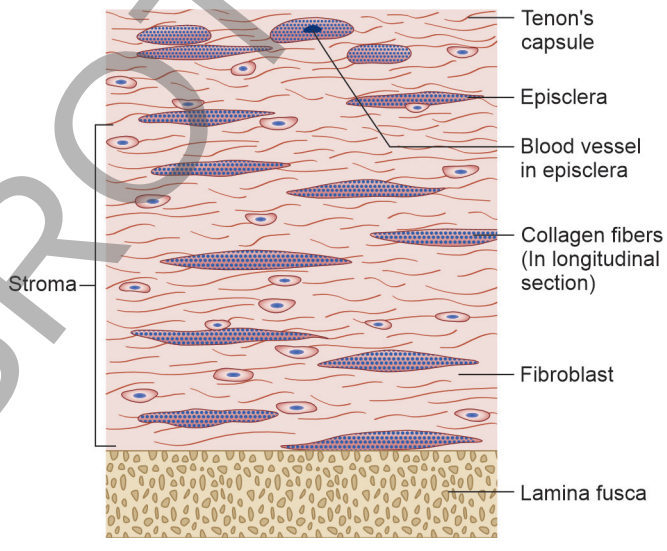

Fig. 1: Anatomy of the episclera and sclera.

EPISCLERITIS

Episcleritis is a benign, self-limiting inflammatory condition limited to the episcleral tissue. It is characterized by sectoral or diffuse hyperemia of the episcleral vessels, typically without pain or visual loss. it can be classified as:

- Simple episcleritis **(Fig. 2)**
- Nodular episcleritis

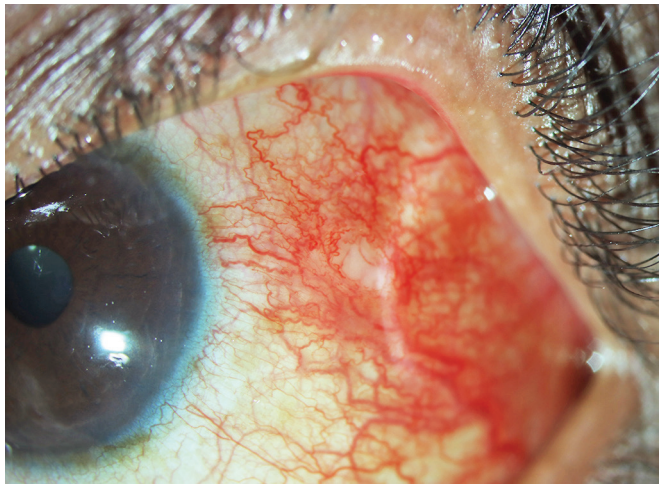

Fig. 2: Episcleritis.

JAYPEE BROTHERS

Etiopathogenesis

The precise etiopathogenesis of episcleritis remains incompletely understood. Most cases are idiopathic, arising from nonspecific inflammation of the episcleral vascular plexus. A type III hypersensitivity reaction (immune complex deposition) has been postulated in some cases.[4]

Approximately 30–36% of cases are associated with a systemic disease, including:

- Rheumatoid arthritis (most common systemic association)
- Inflammatory bowel disease (IBD) (Crohn's disease and ulcerative colitis)
- Seronegative spondyloarthropathies (ankylosing spondylitis and reactive arthritis)
- Gout and hyperuricemia
- Rosacea
- Herpes zoster ophthalmicus
- Atopy

Clinical Features

Patients of episcleritis present with the following:

Symptoms:

- Pain—mild or absent
- Redness is seen which disappears or reduces with instillation of 2.5% phenylephrine.
- Episcleritis does not cause vision disturbances.

Signs:

- Sectoral or diffuse hyperemia of the superficial episcleral vascular plexus **(Figs. 3A and B)**.
- Vessels are radially arranged and move with conjunctival displacement; blanch readily with topical 2.5% phenylephrine.[4]
- Chemosis may be present in severe cases.
- Sectoral episcleritis (most common) versus nodular episcleritis (raised, tender, and movable episcleral nodule)
- Absence of deep scleral injection or scleral edema

Investigations

Episcleritis is a clinical diagnosis. However in case of nonresponding or recurrent episcleritis a detailed investigations is required to rule out associated connective tissue disorders similar to a case of scleritis.

Management

The majority of episcleritis episodes are self-limiting with spontaneous resolution in 1–4 weeks. Such patients are treated with lubricants only. If the episcleritis is recurrent or associated with systemic connective tissue diseases like rheumatoid arthritis, a short course of topical steroid is useful:

- *Topical lubricants/artificial tears:* For symptomatic relief of irritation
- *Topical corticosteroids:* Mild topical corticosteroids such as fluorometholone 0.1% or loteprednol etabonate 0.5% are used four times a day for 1–2 weeks then tapered down. In case of no response. prednisolone acetate 1% can be used.
- *Topical nonsteroidal anti-inflammatory drugs (NSAIDs):* Ketorolac 0.5% or diclofenac 0.1% four

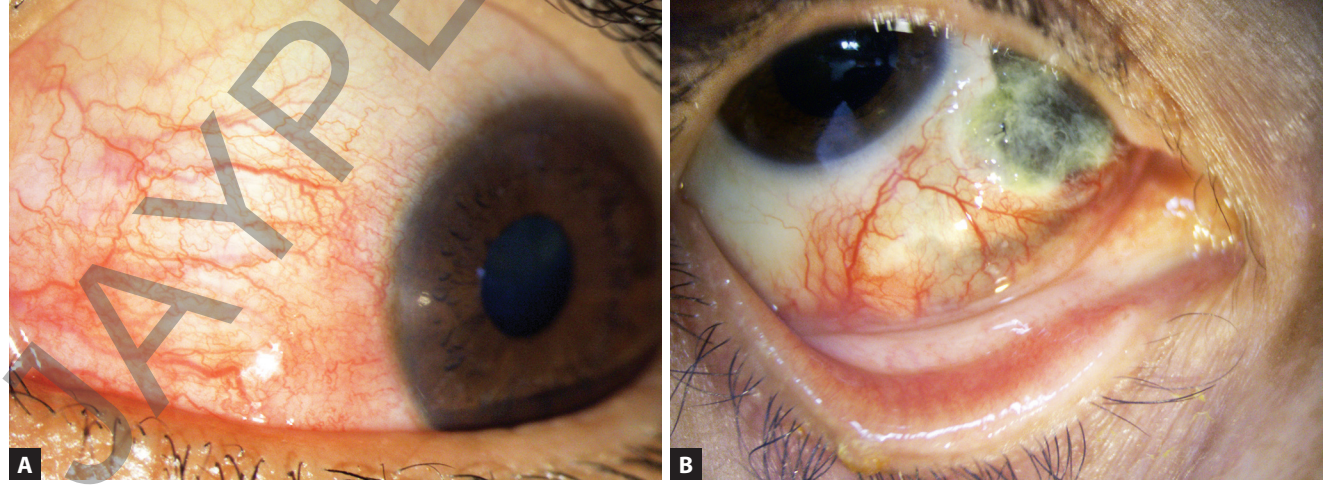

Figs. 3A and B: (A) Diffuse episcleritis; (B) Scleritis.

JAYPEE BROTHERS

times daily for mild-moderate symptoms. NSAIDs are rarely used in episcleritis.
- *Systemic NSAIDs:* Ibuprofen 400 mg three times daily is used in case of failure of topical steroids and if there is persistent pain.
- Treatment of underlying systemic disease reduces recurrence frequency.

SCLERITIS

Scleritis can be simply defined as inflammation of the sclera. It is usually painful, chronic, often vision threatening and can be associated with infectious as well as noninfectious causes. It is characterized by inflammation of the episcleral and scleral tissue with injection in both superficial and deep episcleral vessels. Scleritis is frequently associated with systemic autoimmune or infectious diseases and may lead to permanent structural damage if inadequately treated.[5] It has been classified by Watson and Hayreh et al. as following **(Table 1)**:

- *Anterior scleritis:*
  - Diffuse scleritis
  - Nodular scleritis
  - *Necrotizing scleritis:*
    - With inflammation
    - Without inflammation (scleromalacia perforans)
- Posterior scleritis

Etiopathogenesis

Scleritis involves a granulomatous or nongranulomatous inflammation primarily affecting the scleral stroma. The underlying mechanism usually involves an immune-mediated vasculitis of the deep episcleral and scleral vessels, with activation of complement pathways and T cell-mediated cytotoxicity. This may lead to obliterative endarteritis, scleral necrosis, and in severe cases, globe perforation.[6,7]

Approximately 50% of scleritis cases are associated with a systemic disease (the anatomical structure of sclera resembles the components of joints), and scleritis may

TABLE 1: Classification of scleral inflammation.

Anatomic classification (by Watson and Hayreh)	Episcleritis	Nodular
		Diffuse
	Anterior scleritis	Diffuse
		Nodular
		Necrotizing: • With inflammation • Without inflammation (scleromalacia perforans)
	Posterior	
Etiological classification	Infective	• Bacterial— *Mycobacterium tuberculosis*, *Mycobacterium leprae, Treponema pallidum*, *Staphylococcus aureus*, and others. • Viral—herpes simplex and varicella zoster, Ebstein–Barr virus, and coxsackie B5 • Fungal—*Aspergillus* • *Acanthamoeba* • Parasitic—*Toxoplasma*
	Autoimmune	• Rheumatoid arthritis • Wegener's granulomatosis • Relapsing polychondritis • Systemic lupus erythematosus • Polyarteritis nodosa • Inflammatory bowel disease • Gout
	Surgically-induced necrotizing scleritis (SINS)	Postsurgery for pterygium, cataract, glaucoma, vitreoretina, and others
	Others	Post-trauma, drug induced, congenital erythropoietic porphyria, and GVHD after BMT

(BMT: bone marrow transplant; GVHD: graft-versus-host disease)

JAYPEE BROTHERS

TABLE 2: Diseases associated with episcleritis and scleritis.

Noninfectious	• Connective tissue diseases and other inflammatory conditions • Rheumatoid arthritis • Systemic lupus erythematosus • Ankylosing spondylitis • Reactive arthritis • Psoriatic arthritis • Arthritis and inflammatory bowel disease • Relapsing polychondritis
Vasculitic diseases	• Polyarteritis nodosa • Allergic granulomatous angiitis (Churg–Strauss syndrome) • Granulomatosis with polyangiitis (Wegener) • Behçet's disease • Giant-cell arteritis • Cogan's syndrome • Vasculitic diseases associated with connective tissue diseases and other inflammatory conditions
Miscellaneous	• Atopy • Rosacea • Gout • Foreign body granuloma • Chemical injury
Infectious	• Bacterial • Fungal • Viral • Parasitical

be the presenting manifestation of an occult systemic vasculitis or granulomatous disease. Rheumatoid arthritis is the most common association in the West, while tuberculosis (TB) is a major etiology in endemic regions such as India **(Table 2)**.[8,9]

Clinical Features

It is most common seen in the fourth to sixth decades of life. Recurrences and remissions are common in scleritis. Unilateral or bilateral involvement simultaneous or at various times can be seen.

Patients of scleritis present with the following symptoms:

- *Pain:* Scleritis pain is typically severe, boring/gnawing, radiates to the periorbital region, scalp, jaw, or ear, is worse at night, awakens the patient from sleep, and is exacerbated by ocular movement. It is only temporarily relieved by analgesics.
- *Redness:* It may be localized or diffuse. A blue-violet hue of deep vessels may be seen in scleritis. No blanching with 2.5% topical phenylephrine instillation (unlike episcleritis).
- *Visual disturbance:* It may occur due to blurring, tearing, etc. (complications of anterior scleritis can cause keratitis, uveitis, elevated IOP, etc.). Involvement of extraocular muscles may cause diplopia. Corneal astigmatism due to scleral thinning can cause a decrease in visual acuity. Episcleritis does not cause vision disturbances.
- *Photophobia and lacrimation:* More common in scleritis

Past History

History of previous ocular surgery [pterygium excision—surgically-induced necrotizing scleritis (SINS)], trauma, etc., predisposes to scleritis. TB exposure or treatment history and Bacillus Calmette-Guérin (BCG) vaccination is relevant for scleritis patient as TB is an important cause for scleritis in Southeast Asia.

Systemic History

- *Diagnosed autoimmune disease:* Rheumatoid arthritis, systemic lupus erythematosus (SLE), granulomatosis with polyangiitis (GPA), IBD, and ankylosing spondylitis
- TB exposure or treatment history; BCG vaccination
- Sexually transmitted infections (syphilis—syphilitic scleritis)
- Gout, rosacea, atopy, and herpes zoster
- *Systemic symptoms:* Fever, weight loss, joint pain, oral ulcers, skin rash, and hematuria (vasculitis screening)

Drug History

Bisphosphonates (pamidronate-induced scleritis), topical mitomycin C, and beta-blockers.

Travel History

Infectious causes in endemic regions.

Signs

- *Periocular signs:*
  - Periorbital edema and proptosis (posterior scleritis)
  - Skin changes in herpes zoster (vesicles) and rosacea
  - *Palpation of globe:* Tenderness (a cardinal sign of scleritis and absent in episcleritis)

JAYPEE BROTHERS

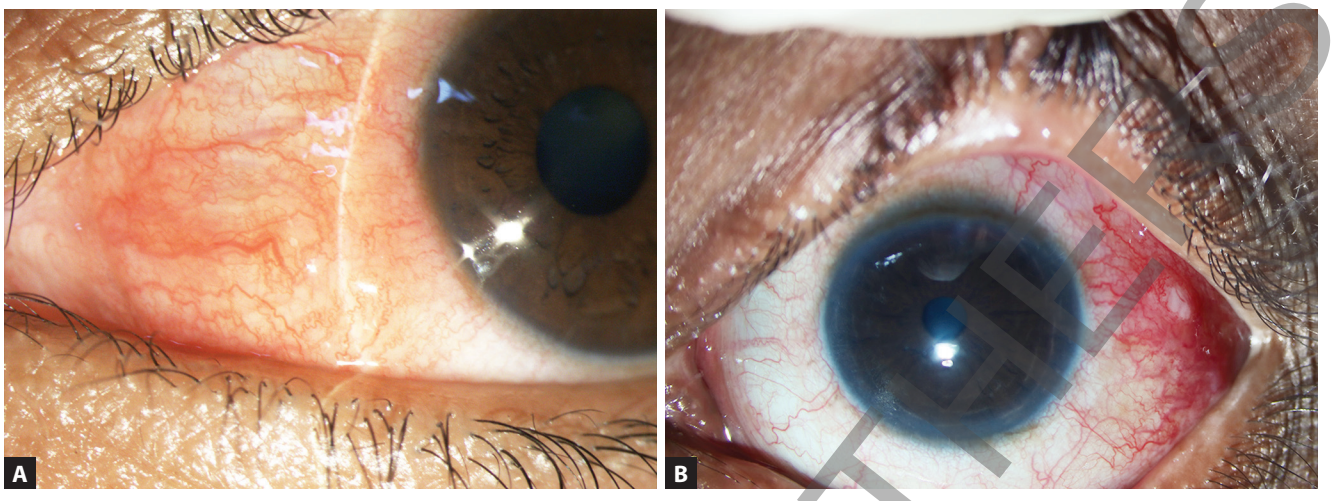

Figs. 4A and B: (A) Diffuse episcleritis with slit-beam image showing engorgement of superficial episcleral vessels; (B) Nodular episcleritis.

- Lymphadenopathy of preauricular, submandibular and cervical lymph nodes.

- *Ocular signs:*
  - Deep violet-red hue (due to deep episcleral and superficial scleral vessel engorgement) **(Figs. 4A and B)**
  - Vessels do not blanch with topical phenylephrine 2.5% (unlike episcleritis).
  - Vessels do not move with conjunctival displacement.[4]
  - Scleral edema—focal or diffuse
  - Reduced visual acuity due to complications, e.g., uveitis, glaucoma, exudative retinal detachment, and macular edema
  - Nodular scleritis—scleral nodule, which is firm, tender, immobile, and associated with focal congestion **(Fig. 5)**
  - *Necrotizing scleritis:* Avascular scleral zone (white necrotic area), thinning, and uveal show (dark area indicating choroidal visibility through thinned sclera) **(Fig. 6)**
  - *Scleromalacia perforans:* Asymptomatic yellowish-white necrotic plaques; absent episcleral vascularity; parchment-thin avascular sclera; and choroidal pigment visible **(Fig. 7)**
  - *Cornea:* Peripheral ulcerative keratitis (PUK), sclerosing keratitis, interstitial keratitis, and limbal guttering may be seen **(Fig. 8)**.
  - *Anterior chamber:* Cells and flare (scleritis-associated uveitis) may be seen, although rare.
  - *IOP:* Elevated in trabeculitis or raised episcleral venous pressure, or steroid-induced—rare

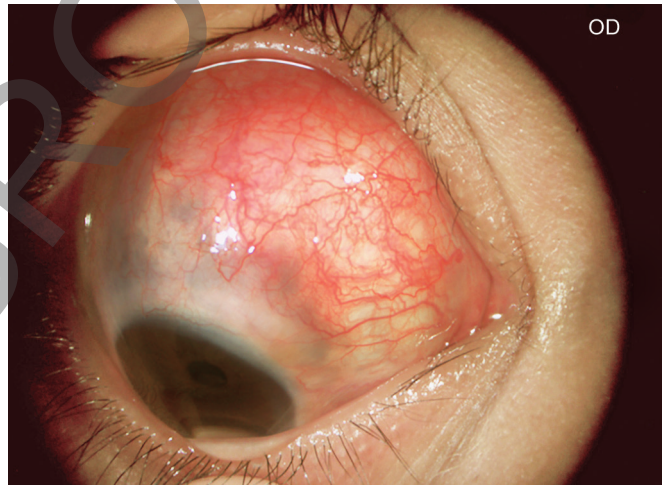

Fig. 5: Diffuse anterior scleritis—slit-lamp photograph showing diffuse deep episcleral and scleral congestion with violaceous discoloration.

  - *Fundus changes are classically seen in cases of posterior scleritis:*
    - Serous (exudative) retinal detachment
    - Choroidal detachment or effusion
    - Choroidal folds (Paton's lines)
    - Disc edema/papilledema
    - Cotton-wool spots and retinal hemorrhages
    - Macular edema
    - Shallow anterior chamber and secondary angle-closure glaucoma (from choroidal effusion)
  - Proptosis, restricted ocular motility, and pain on movement (may mimic orbital inflammatory syndrome)

JAYPEE BROTHERS

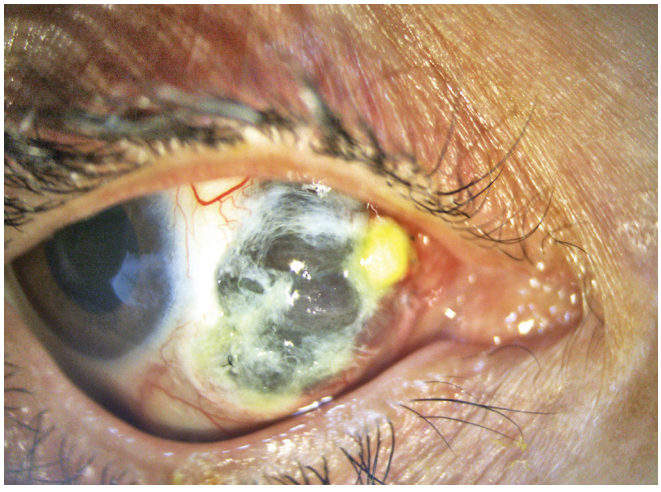

Fig. 6: Necrotizing anterior scleritis with inflammation—clinical photograph demonstrating intense scleral inflammation with areas of avascular white sclera, necrosis, and surrounding congestion.

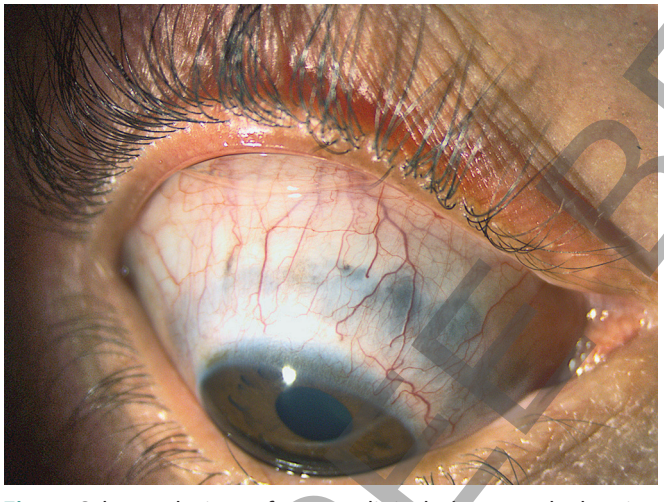

Fig. 7: Scleromalacia perforans—clinical photograph showing painless, progressive scleral thinning with exposure of underlying uveal tissue and minimal active inflammation.

Grading of Scleritis

McCluskey and Wakefield proposed a scoring system for the extent and severity of the disease. Another grading system was given by Sen et al. **(Table 3)**.[10]

Differential Diagnoses

- *Conjunctivitis:* Superficial congestion of conjunctival tissue, no pain **(Table 4)**
- *Episcleritis:* Minimal pain, blanching of the episcleral vessels with phenylephrine 2.5% drops

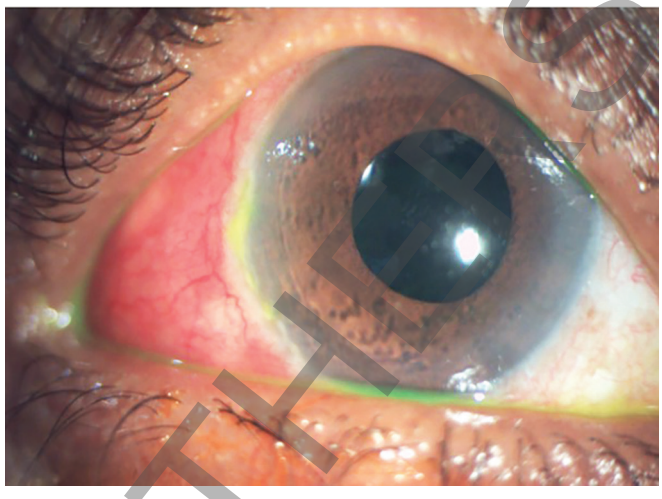

Fig. 8: Scleritis with peripheral ulcerative keratitis.

TABLE 3: Grading of scleritis by Sen et al.

Grade	*Grading description*
0	No scleral inflammation with complete blanching of vessels
0.5	Trace inflammation with minimally dilated deep episcleral vessels
1	Mild scleral inflammation with diffuse mild dilatation of deep episcleral vessels
2	Moderate scleral inflammation with tortuous and engorged deep episcleral vessels
3	Severe scleral inflammation with diffuse significant redness of sclera and obscuration of deep episcleral vessels with edema and erythema
4	Necrotizing scleritis with or without uveal show

- *Orbital cellulitis/orbital inflammatory syndrome:* Proptosis, pain on movement; CT/MRI distinguishes two entities.
- *Anterior uveitis:* Circumciliary congestion, keratic precipitates, and cells/flare in anterior chamber can coexist with scleritis, pain is usually minimal.

Investigations

Scleritis should undergo a thorough ocular and systemic examination with serological investigation to rule out the presence of any systemic disease. Many a time scleral inflammation can be the initial manifestation of these systemic diseases and many of them can be life threatening, the systemic evaluation in such patients can be rewarding.

JAYPEE BROTHERS

TABLE 4: Distinguishing episcleritis, scleritis, and conjunctivitis.

	Episcleritis	*Scleritis*	*Conjunctivitis*
Pain	Mild/absent	Severe, boring, and nocturnal	Minimal/absent
Tenderness to palpation	Absent/minimal	Present (hallmark)	Absent
Discharge	Absent	Absent	Present (watery/mucopurulent)
Visual involvement	Absent	May be present	Usually absent
Vessel hue	Bright red	Deep violet-red	Bright red
Vessel movement with conjunctival shift	Move with conjunctiva	Do not move	Move with conjunctiva
Blanch with 2.5% phenylephrine	Yes	No	Yes
Scleral edema/nodule	Absent	Present	Absent
Photophobia	Mild/absent	May be present	Mild
Systemic association	~30–36%	~50%	Uncommon (viral URI)
Visual prognosis	Excellent	May be poor (necrotizing)	Excellent

(URI: upper respiratory infection)

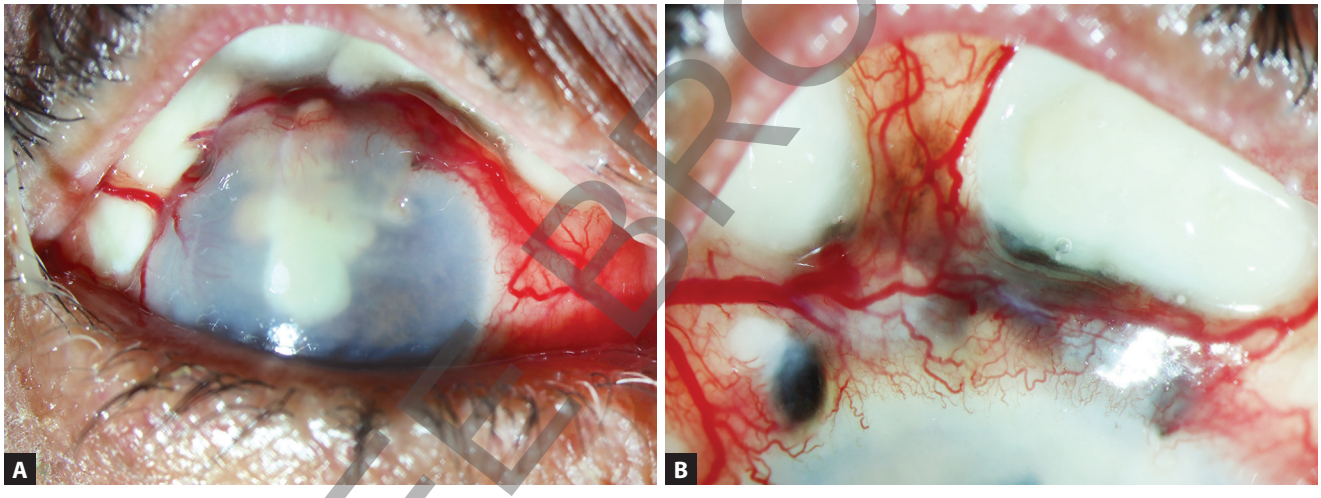

Figs. 9A and B: (A) Infectious scleritis with keratitis; (B) Magnified view of the same case showing scleral melt with infiltrate.

Ocular Investigations

- *B-scan ultrasonography (essential for posterior scleritis):*[11]
  - Scleral and choroidal thickening (>2 mm thickening of posterior coats)
  - Fluid in Tenon's space (T-sign)—pathognomonic of posterior scleritis
  - Scleral nodule
  - Optic disc swelling and distended optic nerve sheath
  - Retinal detachment
- *Optical coherence tomography (OCT):* Scleral thickening, choroidal folds, subretinal fluid, and disc edema
- *Anterior segment OCT (AS-OCT):* Quantify scleral thinning in necrotizing scleritis
- *Fundus fluorescein angiography (FFA):* Disc leakage, choroidal vascular anomalies in posterior scleritis
- *Indocyanine green (ICG) angiography:* Choroidal inflammation and perfusion abnormalities
- *MRI/CT orbit:* Scleral thickening and orbital extension; differentiate from orbital inflammatory disease
- *Scleral biopsy:* Considered in atypical or refractory cases, or when infectious scleritis is strongly suspected and culture is needed **(Figs. 9A and B)**.

Systemic Investigations

Systemic evaluation is important in patients with scleritis because a significant proportion of cases are associated with underlying autoimmune, infectious, or systemic

JAYPEE BROTHERS

inflammatory diseases. Investigations should be guided by clinical history, laterality, severity, recurrence, type of scleritis, and associated systemic symptoms. A complete systemic workup is especially indicated in recurrent, bilateral, necrotizing, posterior, severe, or treatment-resistant scleritis.[12,13]

Basic Baseline Investigations

All patients with clinically significant scleritis may be evaluated with basic inflammatory and hematological tests. These include:

- Complete blood count
- Erythrocyte sedimentation rate (ESR)
- C-reactive protein (CRP)
- Renal function tests
- Liver function tests (LFTs)
- *Urine routine/microscopy:* Urine examination is particularly useful to look for hematuria or proteinuria, which may suggest systemic vasculitis such as GPA.

Autoimmune and rheumatological workup:

- Antinuclear antibodies (ANA)
- Since rheumatoid arthritis is one of the most common systemic associations of scleritis, rheumatoid factor, and anticyclic citrullinated peptide (CCP) antibody should be considered.
- For SLE and other connective tissue diseases, ANA, antidouble-stranded DNA (dsDNA), extractable nuclear antigen (ENA) profile, and complement levels may be requested depending on clinical suspicion.
- For suspected systemic vasculitis, especially in necrotizing scleritis, posterior scleritis, or scleritis associated with systemic symptoms, antineutrophil cytoplasmic antibody (ANCA) testing is important. Both cytoplasmic ANCA(c-ANCA)/proteinase-3 (PR3)-ANCA and perinuclear ANCA (p-ANCA)/myeloperoxidase (MPO)-ANCA may be performed to evaluate for GPA and related vasculitic disorders **(Fig. 10)**.

Infective Workup

Infective causes should be excluded, particularly before starting systemic corticosteroids or immunosuppressive therapy in suspected cases **(Table 5)**. Tests may include:

- *Syphilis:* Venereal Disease Research Laboratory/rapid plasma reagin (VDRL/RPR) and treponema pallidum hemagglutination assay/fluorescent treponemal antibody absorption (TPHA/FTA-ABS)

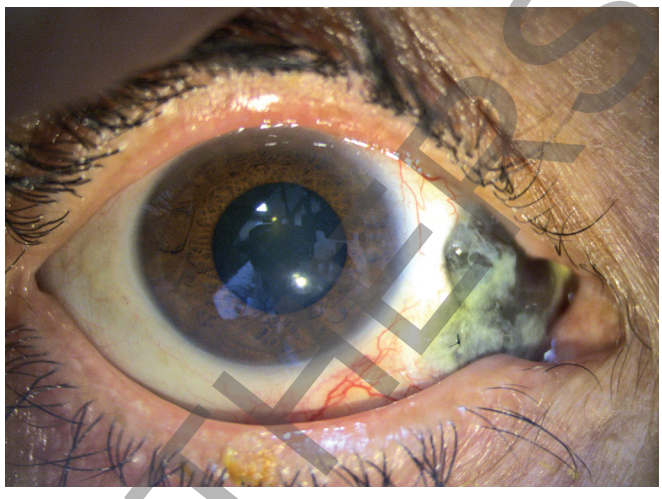

Fig. 10: Surgically-induced necrotizing scleritis—clinical photograph showing scleral necrosis at or adjacent to a previous surgical site postsquint surgery.

TABLE 5: Treatment of infectious scleritis by etiology.

Pathogen	*Treatment*
Herpes simplex virus (HSV)	Oral acyclovir 400 mg 5 ×/day (or valacyclovir 500 mg TDS) ± systemic corticosteroids after initiating antiviral cover
Herpes zoster virus (HZV)	Oral valacyclovir 1 g TDS or acyclovir 800 mg 5×/day for 7–10 days ± systemic steroids
Mycobacterium tuberculosis	*Antitubercular therapy (ATT)*: Isoniazid + rifampicin + pyrazinamide + ethambutol for 2 months, then isoniazid + rifampicin for 4 months ± topical steroids after ATT initiation
Syphilis (*T. pallidum*)	IV benzylpenicillin 3–4 MU 4-hourly for 10–14 days OR IV ceftriaxone 2 g/day for 14 days (penicillin allergy)
Bacterial (nonsyphilitic)	Fortified antibiotics (topical and/or systemic) based on culture sensitivity; surgical debridement in refractory cases
Fungal	Systemic antifungals (voriconazole and amphotericin B) based on species
SINS	Remove offending agent (e.g., residual beta-radiation effects); systemic NSAIDs or steroids; anti-infectives if superinfection

(NSAIDs: nonsteroidal anti-inflammatory drugs; SINS: surgically-induced necrotizing scleritis)

- *TB:* Mantoux test or interferon-gamma release assay (IGRA) for TB, and chest X-ray or high-resolution computed tomography (HRCT) chest
- In selected cases, screening for human immunodeficiency virus (HIV), hepatitis B, and hepatitis C is

JAYPEE BROTHERS

useful, especially when systemic immunosuppression is planned. If there is suspicion of infective scleritis following surgery, trauma, or adjacent keratitis, microbiological evaluation should be performed.

- *Scleral biopsy:* In suspected cases of infective cause, de-roofing followed by debridement can be done using a 15 number blade. The content is sent for microbiology smear and culture.

Investigations for Specific Systemic Associations

- *Rheumatoid arthritis:* Rheumatoid factor, anti-CCP antibody, ESR, and CRP
- *GPA/vasculitis:* ANCA, urine routine, renal function tests, and chest imaging
- *SLE:* ANA, anti-dsDNA, complement levels, and urine examination
- *TB:* Mantoux test, IGRA, and chest X-ray/HRCT chest
- *Syphilis:* VDRL/RPR with confirmatory TPHA/FTA-ABS
- *Sarcoidosis:* Serum angiotensin-converting enzyme (ACE), serum calcium, and chest X-ray/HRCT chest
- *Gout:* Serum uric acid
- *IBD:* Gastroenterology evaluation, stool tests, and colonoscopy if clinically indicated
- *Seronegative spondyloarthropathy:* HLA-B27 may be considered in appropriate clinical settings.
- *Imaging and specialist evaluation:* Chest imaging is useful when TB, sarcoidosis, or systemic vasculitis is suspected. Additional imaging such as CT chest, CT paranasal sinuses, or joint imaging may be requested based on systemic symptoms. Collaboration with a rheumatologist, physician, infectious disease specialist, or gastroenterologist is often required for diagnosis and long-term systemic management.

Management

The primary aim of the treatment of scleral inflammation is to control the inflammatory process to relieve the symptoms and thereby reduce the damage to the eye. Good visual outcome is noted if adequate treatment is initiated shortly after its onset. The main modality of treatment is medical although some conditions may require surgical treatment also (**Flowchart 1** showing management algorithm for scleritis).

Medical Management of Scleritis: The Mainstay of Treatment

- *Systemic NSAIDs:* Systemic NSAID therapy cyclo-oxygenase (COX) inhibitor is almost invariably effective. There are various agents that are used given in **Table 6** along with dose. Although indomethacin sustained release 75 mg BD is considered as first choice if available. However long-term NSAIDs should be avoided in the view of systemic side effects
- *Corticosteroids:*
  - Topical steroids are given as adjuvant to the oral NSAID. The agent widely used is prednisolone acetate 1%, etc.
  - Oral corticosteroids are indicated in cases which are nonresponsive to first line of therapy or with posterior or necrotizing disease. The starting dose is 1 mg/kg/day the weekly reduction by 10 mg/week and once 40 mg/day is reached the further reduction to maintenance dose of 5 mg/day is dependent in clinical response.
  - Intravenous (IV) corticosteroids are for cases where aggressive management of the scleral inflammation is required such as threatened scleral or corneal perforation in necrotizing scleritis. Pulse therapy of IV methylprednisolone is given 500 mg–1 g for 3 days. It is followed by high dose of oral steroid or immunosuppressive agents.
  - As corticosteroids can have serious side effects on long-term use so steroid treatment should be initiated and maintained after systemic workup special caution must be taken in diabetics and hypertensive cases.
  - The role of periocular steroids is still controversial in scleritis and not widely used.
- *Immunomodulatory therapy (IMT):* It is indicated when scleritis is refractory to steroids, steroid-sparing is required, necrotizing or posterior scleritis is present, or there is associated sight-threatening autoimmune disease.[14] Various immunosuppressants have been tried for treatment of scleritis and these include antimetabolites (methotrexate, azathioprine, and mycophenolate mofetil), alkylating agents (chlorambucil and cyclophosphamide), and T-cell inhibitors (cyclosporine and tacrolimus). The most commonly and widely used is methotrexate with or without a short course of oral steroid in tapering dosage. Dosage of methotrexate is 0.1–0.5 mg/kg/week; low-dose therapy is started at a dose of 7.5 mg/week and it can be increased up to 25 mg/week. It is given orally once a week along with folic acid analogue. As it causes hepatotoxicity and bone marrow suppression, complete blood count (CBC) and LFT monitoring

JAYPEE BROTHERS

Flowchart 1: Treatment algorithm for scleritis.

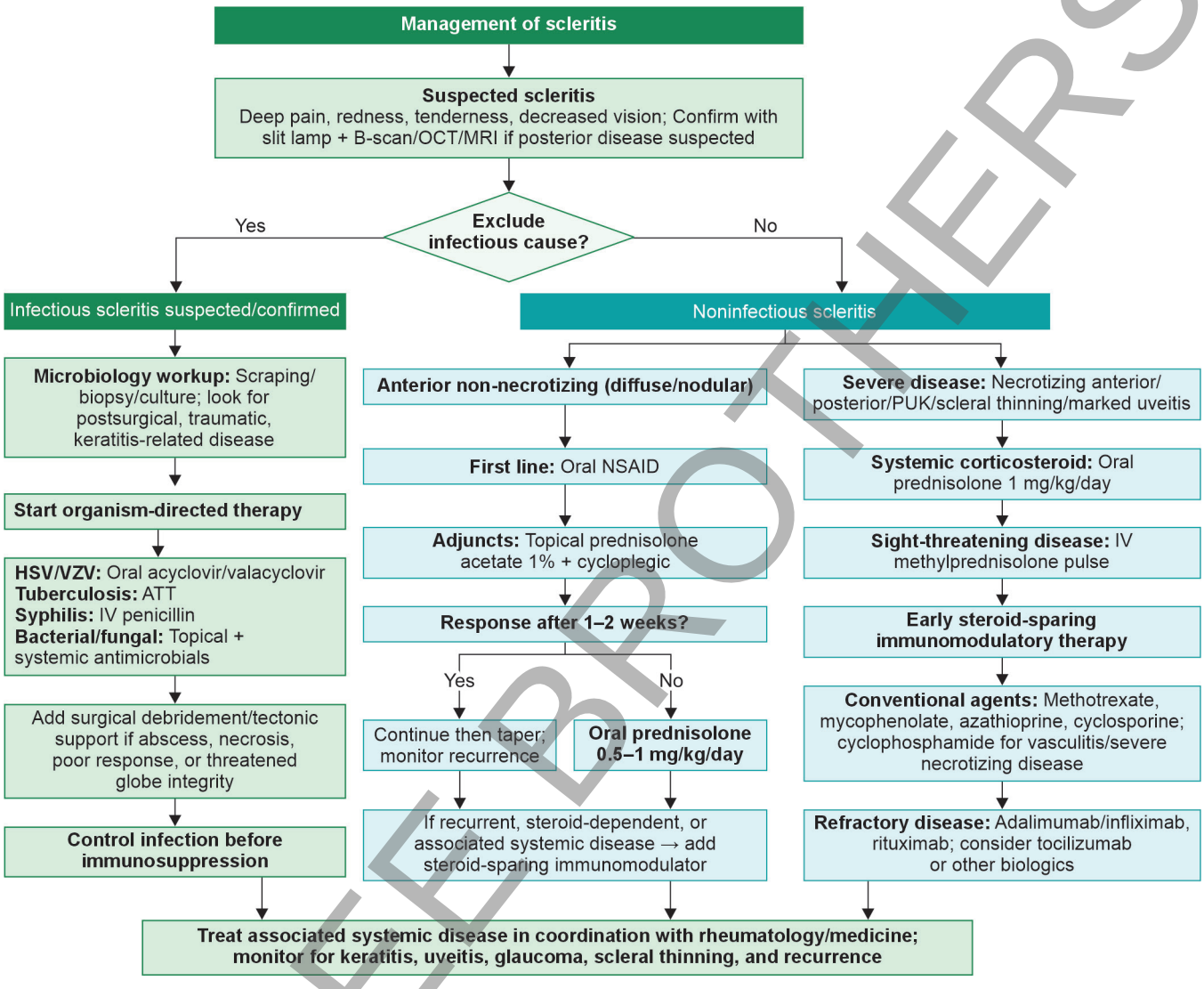

(ATT: antitubercular therapy; HSV: herpes simplex virus; IV: intravenous; MRI: magnetic resonance imaging; NSAID: nonsteroidal anti-inflammatory drug; PUK: peripheral ulcerative keratitis; OCT: optical coherence tomography; VZV: varicella zoster virus)

are essential. Azathioprine and cyclophosphamides are next-line drugs.

- *Antimetabolites:* Methotrexate (7.5–25 mg/week), mycophenolate mofetil (1–3 g/day), and azathioprine (1–3 mg/kg/day)
- *Alkylating agents:* Cyclophosphamide (pulse IV or oral), especially for GPA-associated necrotizing scleritis
- *T-cell inhibitors:* Cyclosporine (2.5–5 mg/kg/day) and tacrolimus
- *Biologic response modifiers:*
  - *Antitumor necrosis factor-alpha (TNF-α) agents:* Infliximab (5 mg/kg IV at 0, 2, 6 weeks then 8-weekly), Adalimumab (40 mg SC fortnightly)—for refractory RA-associated or IBD-associated scleritis
  - *Anti-CD20: Rituximab* (375 mg/m^2 weekly × four doses or 1 g IV × two doses)—particularly for GPA-associated necrotizing scleritis and scleromalacia perforans[15]
- *Tocilizumab (anti-IL-6):* Emerging evidence in refractory cases.

JAYPEE BROTHERS

TABLE 6: Drugs used in management of scleritis.

Drug	*Common indication in scleritis*	*Usual dose*	*Important adverse effects*
Oral NSAIDs	First-line for mild to moderate anterior non-necrotizing scleritis	*Indomethacin:* 25–50 mg 2–3 times/day *Ibuprofen:* 400–800 mg 3–4 times/day *Naproxen:* 250–500 mg twice/day	Gastritis, peptic ulcer, GI bleed, renal dysfunction, fluid retention, hypertension, bronchospasm in aspirin-sensitive asthma
Topical corticosteroid	Adjunct to oral NSAID in anterior scleritis; more useful when associated episcleritis/anterior chamber reaction is present	Prednisolone acetate 1% 4–6 times/day, then taper according to response	Raised IOP, steroid-induced glaucoma, cataract, delayed epithelial healing, secondary infection
Oral corticosteroid	NSAID nonresponsive disease; posterior scleritis, necrotizing scleritis, severe anterior scleritis, systemic autoimmune association	Prednisolone 1 mg/kg/day initially. Taper by about 10 mg/week until 40 mg/day; thereafter taper more slowly according to clinical response to a maintenance dose, often around 5–10 mg/day if required	Hyperglycemia, hypertension, gastritis, weight gain, mood changes, osteoporosis, Cushingoid features, cataract, glaucoma, infection reactivation including TB
IV corticosteroid pulse	Sight-threatening inflammation; severe necrotizing scleritis, threatened scleral/corneal perforation, severe posterior scleritis	IV methylprednisolone 500 mg–1 g/day for 3 days, followed by high-dose oral steroid and/or immunosuppressive therapy	Hyperglycemia, hypertension, fluid retention, electrolyte disturbance, arrhythmia, mood/psychotic symptoms, infection risk. Requires systemic monitoring
Methotrexate	Most commonly used steroid-sparing IMT; recurrent, steroid-dependent or autoimmune-associated scleritis	7.5–25 mg once weekly or 0.1–0.5 mg/kg/week. Give with folic acid supplementation	Hepatotoxicity, bone marrow suppression, oral ulcers, nausea, pneumonitis, teratogenicity. Monitor CBC, LFT, renal function. Avoid in pregnancy, significant liver disease and heavy alcohol use
Mycophenolate mofetil	Steroid-sparing agent; useful when methotrexate is not tolerated or inadequate	1–3 g/day orally, commonly 1 g twice daily	GI upset, leukopenia, infection risk, teratogenicity. Monitor CBC and LFT. Avoid in pregnancy
Azathioprine	Alternative antimetabolite; systemic autoimmune-associated scleritis	1–3 mg/kg/day orally	Bone marrow suppression, hepatotoxicity, pancreatitis, GI intolerance, infection risk. Monitor CBC and LFT. TPMT/NUDT15 testing may be considered before use where available
Cyclosporine	T-cell inhibitor; selected steroid-sparing use, especially ocular inflammatory disease without severe systemic vasculitis	2.5–5 mg/kg/day orally in divided doses	Nephrotoxicity, hypertension, tremor, gingival hyperplasia, hypertrichosis, infection risk. Monitor BP, serum creatinine, renal function and drug interactions
Tacrolimus	Alternative T-cell inhibitor in refractory ocular inflammation	Dose individualized; commonly oral low-dose regimens under specialist supervision	Nephrotoxicity, neurotoxicity, hypertension, hyperglycemia, infection risk. Monitor renal function, BP, blood sugar and drug levels when indicated
Cyclophosphamide	Severe necrotizing scleritis, systemic vasculitis, especially GPA-associated necrotizing scleritis	Oral 1–2 mg/kg/day or IV pulse therapy as per rheumatology protocol	Bone marrow suppression, hemorrhagic cystitis, infertility, malignancy risk, opportunistic infections, nausea, alopecia. Monitor CBC, urine routine, renal function

Contd…

JAYPEE BROTHERS

or detailed information on ophthalmology books, visit our website www.ejaypee.com, or detailed information on ophthalmology books, visit our website www.ejaypee.com, or detailed inform

Clinical Ophthalmology
(Medical and Surgical Care)

Clinical Ophthalmology (Medical and Surgical Care) Volume 2 is dedicated to ophthalmic surgery and has been designed around the surgical knowledge and skills that every postgraduate student of ophthalmology is expected to acquire during training. Rather than being an exhaustive surgical encyclopedia, this volume focuses on the commonly performed and essential ophthalmic procedures that a postgraduate student must know and understand. Each surgical procedure is presented in a systematic, step-by-step format, beginning with the relevant principles, indications, surgical preparation and progressing through the key operative steps, important precautions, and practical considerations. The surgical descriptions are complemented by illustrative photographs, diagrams, and sequential images, allowing readers to visualize each stage of the procedure and better understand the operative technique. Recognizing that surgery is best understood visually, the book goes beyond conventional text-based learning. Selected chapters are supplemented with surgical videos that can be accessed through QR code links provided at the end of the chapter. This integration of text, images, and videos enables students to read the surgical steps, visualize the technique, and subsequently reinforce their understanding by watching the procedure being performed.

The volume has been developed primarily for postgraduate students and residents in ophthalmology, with particular emphasis on examination preparation, surgical discussions, wet-lab learning, and supervised operative training. Fellows and practicing ophthalmologists may also find it useful as a concise reference for reviewing established surgical techniques. Through its combination of stepwise surgical descriptions, operative images, illustrations, and QR code-linked videos, Volume 2 aims to make ophthalmic surgery easier to understand, remember, and translate into clinical practice, providing a practical companion throughout postgraduate surgical training.



Prafulla Kumar Maharana
MD
Additional Professor
Dr Rajendra Prasad Centre
for Ophthalmic Sciences
All India Institute of Medical Sciences
New Delhi, India



Aafreen Bari
MD
Assistant Professor
Dr Rajendra Prasad Centre
for Ophthalmic Sciences
All India Institute of Medical Sciences
New Delhi, India



Anu Malik
MS
Assistant Professor
Dr Rajendra Prasad Centre
for Ophthalmic Sciences
All India Institute of Medical Sciences
New Delhi, India



Namrata Sharma
MD
Professor
Dr Rajendra Prasad Centre
for Ophthalmic Sciences
All India Institute of Medical Sciences
New Delhi, India

Have a doubt or need clarification?
Students are welcome to connect with us at clinicalophthalmology123@gmail.com

JAYPEE BROTHERS

Shelving Recommendation
OPHTHALMOLOGY

ISBN 978-93-7202-273-5

Buy from ejaypee

JAYPEE BROTHERS