te www.ejaypee.com, for detailed information on radiology books, visit our website www.ejaypee.com, for detailed information on radiology books, visit our website www.ejaypee.com

AIIMS-MAMC-PGI IMAGING SERIES

DIAGNOSTIC RADIOLOGY
Paediatric Imaging

Editors
Raju Sharma
Gaurav Shanker Pradhan
Paramjeet Singh

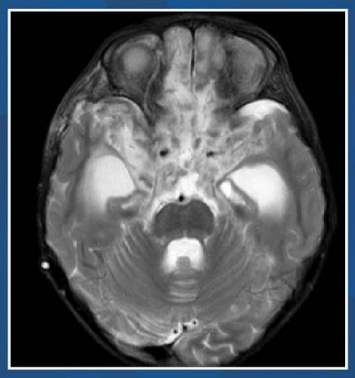
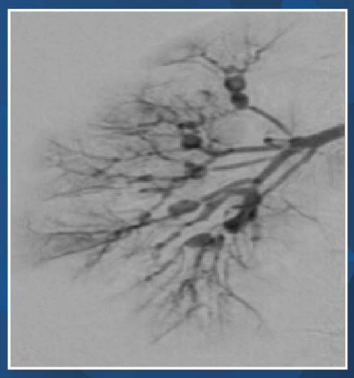

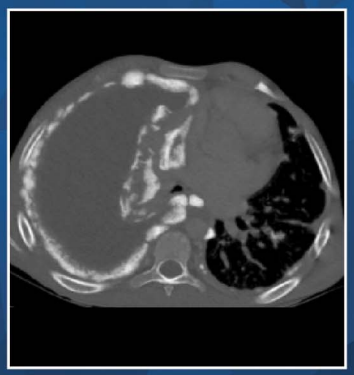

5th Edition

Associate Editors
Manisha Jana
Devasenathipathy Kandasamy
Rashmi Dixit
Anjali Prakash
Akshay Kumar Saxena
Kushaljit Singh Sodhi

JAYPEE

Contents

SECTION 1: GENERAL

1. **Technical Considerations in Pediatric Imaging** 3
   Surabhi Vyas, Ashu Seith Bhalla, Stanzin Spalkit

2. **Recent Advances in Pediatric Radiology Including Radiomics** 20
   Kushaljit Singh Sodhi, Anmol Bhatia, Amit Gupta, Akshay Kumar Saxena

3. **Genetics: What a Pediatric Radiologist Needs to Know?** 40
   Devasenathipathy Kandasamy, Atin Kumar, Manisha Jana

4. **Vascular Interventions in Children** 45
   Rajendra Kumar Behera, Devasenathipathy Kandasamy, Priyanka Naranje, Shivanand Gamanagatti

5. **Nonvascular Interventions in Children** 53
   Priyanka Naranje, Devasenathipathy Kandasamy, Shivanand Gamanagatti

6. **Imaging of Pediatric Trauma** 63
   Shivanand Gamanagatti, Atin Kumar, Amarinder Singh Malhi

SECTION 2: CHEST

7. **Neonatal Respiratory Distress** 89
   Kushaljit Singh Sodhi, Anmol Bhatia, Mansi Verma, Akshay Kumar Saxena

8. **Childhood Pulmonary Infections** 102
   Jyoti Kumar, Anjali Prakash, Alpana Manchanda

9. **Imaging of Pediatric Chest Masses** 130
   Devasenathipathy Kandasamy, Smita Manchanda, Sanchita Gupta

10. **Pediatric Airway** 149
    Ashu Seith Bhalla, Surabhi Vyas, Priyanka Naranje

11. **Pediatric Interstitial Lung Diseases** 176
    Priyanka Naranje, Ashu Seith Bhalla, Manisha Jana

SECTION 3: GASTROINTESTINAL AND BILIARY TRACT, LIVER AND PANCREAS

12. Developmental Anomalies of Gastrointestinal Tract 195
Alpana Manchanda, Jyoti Kumar, Swati Gupta

13. Imaging of Anorectal Anomalies 233
Manisha Jana, Devasenathipathy Kandasamy

14. Gastrointestinal Masses in Children 252
Devasenathipathy Kandasamy, Raju Sharma, Manisha Jana

15. Inflammatory and Infective Conditions of Gastrointestinal Tract in Children 271
Devasenathipathy Kandasamy, Ankur Goyal

16. Hepatic and Pancreatic Masses in Children 285
Akshay Kumar Saxena, Anmol Bhatia, Shubham Saini, Kushaljit Singh Sodhi

17. Imaging and Interventions in Pediatric Budd–Chiari Syndrome 308
Kumble S Madhusudhan, Sanjay Sharma

18. Childhood Biliopathies 332
Rashmi Dixit, Sapna Singh, Gaurav Shanker Pradhan, Swati Gupta

SECTION 4: GENITOURINARY

19. Congenital Anomalies of the Urinary Tract 363
Sanchita Gupta, Chandan Jyoti Das, Smriti Hari

20. Urinary Tract Infections (Including Vesicoureteral Reflux and Neurogenic Bladder) 385
Anmol Bhatia, Kushaljit Singh Sodhi, Mansi Verma, Akshay Kumar Saxena

21. Renal and Retroperitoneal Masses 396
Anjali Prakash, Satyam, Alpana Manchanda, Radhika Batra

22. Evaluation of Female Pelvis and Testicular Abnormalities 439
Anmol Bhatia, Kushaljit Singh Sodhi, Abhinandan Kumar, Akshay Kumar Saxena

23. Imaging of Disorders of Sex Differentiation 462
Manisha Jana, Sanjay Sharma, Amarinder Singh Malhi

SECTION 5: MUSCULOSKELETAL

24. Skeletal Dysplasias 481
Gaurav Shanker Pradhan, Radhika Batra, Sapna Singh

25. Short Stature and Skeletal Maturity Assessment 512
Manisha Jana, Priyanka Naranje

26. Spinal Dysraphism **526**
Ankur Goyal, Raju Sharma, Devasenathipathy Kandasamy

27. Imaging of Pediatric Joint Pathology **547**
Swati Gupta, Anjali Prakash, Gaurav Shanker Pradhan

28. Benign Bone and Soft-tissue Tumors and Conditions **582**
Mahesh Prakash, Kushaljit Singh Sodhi, Anindita Sinha, Raghuraman Soundararajan

29. Pediatric Malignant Bone and Soft-tissue Tumors **599**
Ankur Goyal, Manisha Jana, Stanzin Spalkit

SECTION 6: CENTRAL NERVOUS SYSTEM

30. Congenital Brain Anomalies **627**
Sameer Vyas, Vikas Bhatia, Ajay Kumar

31. Hypoxic-ischemic Encephalopathy **651**
Atin Kumar, Manisha Jana, Devasenathipathy Kandasamy

32. Craniospinal Sonography **664**
Radhika Batra, Rashmi Dixit, Satyam

33. Infectious and Inflammatory Diseases of the Brain **700**
Chirag Kamal Ahuja, Anuj Prabhakar, Paramjeet Singh

34. Pediatric Brain Tumors **735**
Shailesh B Gaikwad, Savyasachi Jain

35. Imaging of Pediatric Infratentorial Tumors **766**
Ajay Garg, Leve Joseph

36. Metabolic Disorders of the Brain **789**
Sapna Singh, Jyoti Kumar, Rashmi Dixit

37. Pediatric Neck Lesions **845**
Smita Manchanda, Ashu Seith Bhalla

Index **867**

10 Pediatric Airway

JAYPEE BROTHERS

INTRODUCTION

Diseases affecting the airway, extrinsic or intrinsic, are frequent in children compared to adults. Also, these are more often symptomatic as children have smaller airways that are more prone to collapse. Hence, even mild edema can result in symptoms. Clinically, the presentation of these disorders may be acute or chronic. In their acute form, the airway disorders can be life-threatening. "Always look at the airway" is a lesson that must be emphasized in pediatric radiology.[1-4]

The airway is referred to as the *upper airway* (above the thoracic inlet) or *lower airway* being below it. While the predominant presentation of upper airway obstruction is inspiratory stridor, that of lower airway obstruction is expiratory wheeze.[2,3] Other clinical presentations include feeding difficulty, respiratory distress, tachypnea, nasal flaring, chest wall retractions, hemoptysis, fever, failure to thrive, and even no symptoms.[2] Diseases affecting the pediatric airway are broadly classified in **Table 1**.

Table 1: Diseases affecting the pediatric airway.

Upper airway obstruction	***Lower airway obstruction***
Acute: • Croup • Epiglottitis • Retropharyngeal cellulitis and abscess • Exudative tracheitis • Foreign body	*Central airway*: • *Extrinsic causes:* ○ *Congenital:* – Vascular compression, vascular malformations – Bronchopulmonary foregut malformations—bronchogenic cyst – Thoracic deformity
Chronic: • Space-occupying lesions: ○ Adenoidal enlargement ○ Enlarged pharyngeal tonsils ○ Juvenile nasopharyngeal angiofibroma • *Fixed airway narrowing:* ○ Stenosis/stricture • *Congenital:* ○ Micrognathia ○ Macroglossia ○ Laryngomalacia ○ Laryngeal cysts	○ *Inflammatory:* – Lymph nodes – Mediastinal abscess/cellulitis ○ *Masses:* – Hemangioma – Lymphoma – Germ cell tumor • *Intrinsic causes:* ○ *Wall abnormalities:* – Congenital: ♦ Tracheobronchomalacia ♦ Tracheal stenosis ♦ Bronchopulmonary foregut malformations ♦ Bronchial atresia ♦ Tracheoesophageal fistula ♦ Tracheobronchial branching anomalies – *Inflammatory:* ♦ Exudative tracheitis ♦ Tuberculosis ♦ Fibrotic stricture ♦ Postintubation stricture – *Intraluminal:* ♦ Foreign body ♦ *Masses*: Hemangioma, carcinoid *Peripheral airway*: • Asthma • Bronchiectasis • Bronchiolitis/small airway disease

IMAGING MODALITIES

The goals of imaging are to delineate:

- Location of the abnormality
- Whether the involvement is diffuse or focal
- Whether the involvement is extrinsic or intrinsic. If the lesion is an intrinsic process, it is mural or intraluminal and is the obstruction fixed or dynamic.[2]

Challenges of Imaging

- The radiographic evaluation of airways in infants and young children is challenging due to inability to obtain motionless end-inspiratory and end-expiratory images.
- The resultant artifacts are especially noticeable in high-resolution computed tomography (HRCT) images.
- Also, the caliber of airways of young children is small and difficult to detail in infants and small children.

Plain Radiographs

Plain radiographs are the primary and often only imaging modality used in evaluation of children with airway obstruction. The evaluation should include frontal and lateral high kV radiographs of the upper airways [also referred to as soft-tissue neck (STN)] and frontal and lateral views of the chest. When an endobronchial foreign body (FB) is suspected, decubitus chest views have been reported to be useful. Expiratory radiographs aid in demonstrating air trapping. However, in times of multidetector computed tomography (MDCT), these are seldom used and have been replaced by CT.

Fluoroscopy

Fluoroscopy of the airway demonstrates dynamic airway collapse during expiration in children with tracheobronchomalacia.[2] Decubitus fluoroscopy may be performed in cases of suspected FB in infants and young children, lying on the affected side, demonstrating the relative immobility of lung on respiration. With advances in MDCT, fluoroscopy is seldom employed.

Barium Swallow

A barium swallow may be useful for demonstrating gastroesophageal reflux in patients with chronic aspiration simulating asthma. This study is also helpful for establishing the diagnosis of vascular rings and slings, although cross-sectional imaging is eventually required for better anatomic delineation.

Ultrasonography

Ultrasound is a potentially useful point of care technique in evaluation of upper airway abnormalities such as laryngomalacia, laryngeal cyst, subglottic hemangioma, vocal cord palsy, and lymphatic malformations. The unossified cartilage of pediatric airway provides acoustic window for ultrasound evaluation. However, limited depth penetration for posteriorly located lesions, reverberation artifacts complicate the imaging.[5]

Computed Tomography

Relative to MRI, CT has the advantage of rapid scan times enabling performance of the examination without sedation; it has the disadvantage of radiation exposure and need for using contrast. *Dynamic CT* can be obtained as a paired inspiratory-expiratory scan in older cooperative children.

In uncooperative children, cine-CT can be used. *Cine-CT* involves rapid acquisition of images of the airway throughout the respiratory cycle during free breathing. Once the site of suspected airway stenosis or malacia is localized, CT images are rapidly and sequentially acquired at the same axial level. Cine-CT technique can provide multiple images of the airway during inspiration and expiration, even in tachypneic patients.

Multiplanar and three-dimensional (3D) volume-rendered image reconstructions including virtual bronchoscopy further enhance the accuracy of MDCT in delineating the level of narrowing, degree of obstruction, segment length, and distal airway.[5]

Techniques of Dynamic Airway Image[6-9]

- *Paired inspiratory-expiratory*: Older, cooperative child, and larger field of view (FOV) are possible.
- *Ultra-high pitch CT*: Pitch >3, available on Siemens health scanner dual-source CT (DSCT scanners), e.g., Somatom Definition Flash or Somatom Force (limitation—craniocaudal coverage 4–6 cm only achievable depending on width of the detector and hence not useful in older children).
- Dynamic helical scanning, e.g., adaptive four-dimensional (4D) spiral, Siemens Healthineers—wide area detector.

Magnetic Resonance Imaging

Magnetic resonance imaging (MRI) can demonstrate abnormal airway motion in addition to anatomic causes of obstruction. The protocol includes axial and sagittal T1-weighted (T1W) as well as short tau inversion recovery (STIR) images.

Dynamic (cine) MRI studies can be used to evaluate airway motion in real time. Sagittal midline MR cine (fast gradient echo imaging) is performed. Axial MR cine images are obtained craniocaudally at the level of mid-tongue in those with obstructive sleep apnea.[10] The use of cine MRI during coughing for evaluation of tracheal

JAYPEE BROTHERS

collapsibility in patients with suspected tracheomalacia has been described.[11,12]

Ultrashort echo time MRI (UTE-MRI) has been reported to be useful in assessing the tracheal dynamics in neonates without the need for sedation or any increased risk.[13]

UPPER AIRWAY OBSTRUCTION

Plain radiographs STN [anteroposterior (AP)/lateral] are frequently employed in upper airway obstruction. It is, hence, essential to be familiar with the normal anatomy.

Normal Anatomy (Figs. 1A to C)

Epiglottis

The normal epiglottis has very thin borders. Epiglottis may appear artifactually thickened if imaged obliquely—this is due to both the left and right sides being imaged next to each other. This is referred to as the "omega" appearance.[1,2]

Aryepiglottic Folds

Aryepiglottic folds are mucosal folds which extend from the epiglottis superiorly to the arytenoid cartilages, posteroinferiorly. On a lateral radiograph, these appear thin and convex inferiorly.

Subglottic Trachea

On frontal views, subglottic trachea appears rounded with lateral convexities or "shoulders". On the lateral view, it should not be narrower than the airway above or below it.

Retropharyngeal Soft Tissues

Normally, the soft tissues between the posterior aspect of the aerated pharynx and anterior aspect of the vertebral column should not be more than the anteroposterior diameter of the vertebral bodies. However, "pseudothickening" of the retropharyngeal soft tissues may be seen if the radiographs are obtained in a flexed position of the neck, especially in infants with short necks. The radiographs should, hence, be performed with adequate neck extension. The thickness of soft tissues is measured transversely somewhere between the level of adenoids superiorly to base of epiglottis inferiorly, below which these are normally thicker due to the presence of esophagus.

Tonsils/Adenoids

At <6 months of age, the adenoids are rarely visible on radiography. There is rapid proliferation during infancy with peak size reaching between 2 and 10 years. A size up to 12 mm is considered normal. Subsequently, during the second decade, there is reduction in size.

Acute Obstruction

The most common causes of acute upper airway obstruction are inflammatory, followed by FB. Ingestion of corrosive/caustic substances is another cause.

Croup (Acute Laryngotracheobronchitis)

Croup is a benign, self-limiting acute inflammatory condition of the upper airways. It results from viral infection and is the most common cause of upper airway obstruction in young children and infants (6 months to 3 years of age). Affected children present with "croupy" (barky) cough and inspiratory stridor.

The purpose of obtaining radiographs in a suspected case of croup is to exclude secondary causes such as FB. It, however, has characteristic findings—on frontal radiographs, there is loss of the normal shoulders (lateral convexities) of the subglottic trachea due to subglottic

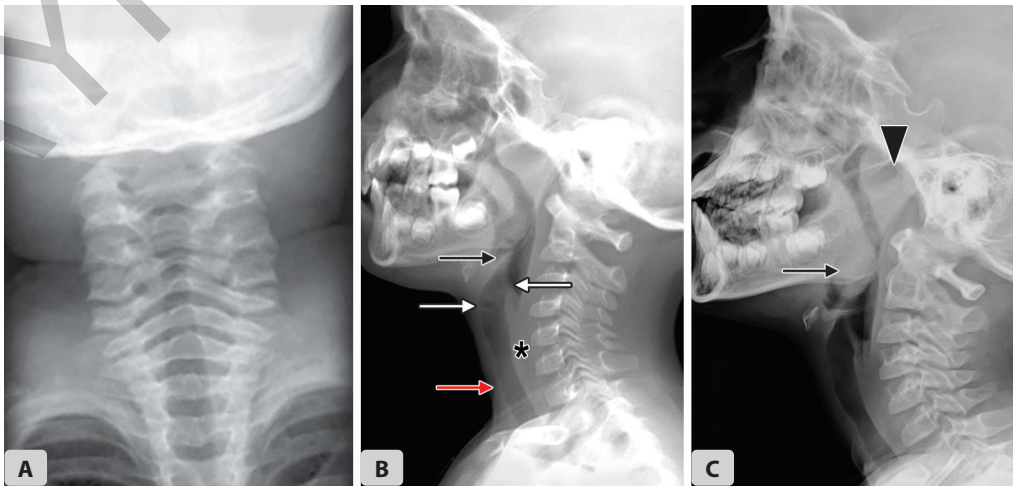

FIGS. 1A TO C: Normal frontal (A) and lateral (B) radiographs neck of a 5-year-old child. Epiglottis (black arrow); glottis (white arrow); aryepiglottic folds (small white arrow); subglottic trachea (red arrow); retropharyngeal soft tissues (asterisk). (C) Lateral radiograph of 9 years old boy showing enlarged tonsils (arrow) and adenoids (arrowhead).

JAYPEE BROTHERS

edema. The subglottic trachea becomes elongated, extending below the level of the pyriform sinuses. The appearance is referred to as a "church steeple" or "inverted V" appearance. Lateral radiographs may reveal similar narrowing of the subglottic trachea with loss of its wall definition.

Epiglottitis

Unlike croup, epiglottitis is a life-threatening condition requiring emergency intubation. The most common organism responsible is *Haemophilus influenzae*. Affected children present with abrupt onset of fever, dysphagia, stridor, and worsening of respiratory distress in recumbent position. The classic mean age of presentation is 3–5 years (older than croup). Now with availability of vaccination, the incidence of this entity has significantly declined and patients may present at a later age (13–14 years).

Diagnosis is made on basis of presentation and physical examination. If not, a single lateral radiograph of neck may be obtained. This reveals markedly thickened epiglottis ("thumb" appearance). The pathological thickening of epiglottis can be differentiated from "omega" appearance, due to associated thickening of aryepiglottic folds in the former. The thickened aryepiglottic folds appear convex superiorly.

Retropharyngeal Cellulitis and Abscess

Retropharyngeal space inflammation is usually of pyogenic origin, following upper respiratory tract infection. Patients present with fever, dysphagia, a stiff neck, and occasional stridor. It is most common between 6 and 12 months of age.

Lateral radiographs reveal thickening of the retropharyngeal soft tissues. On radiographs, the only conclusive finding differentiating cellulitis from abscess is the presence of gas within the latter. Contrast-enhanced CT scans can aid in the distinction of cellulitis from a drainable fluid collection. An abscess appears as a well-defined, low-attenuation area with an enhancing rim **(Figs. 2A and B)**.

Exudative Tracheitis

Exudative tracheitis is also referred to as membranous laryngotracheobronchitis or membranous croup. It is a purulent infection of the trachea characterized by formation of exudative plaques along the tracheal walls. Patients are older than croup, typically 6–10 years of age and are also more ill. The causative organism may be *Staphylococcus aureus* or the infections may be multimicrobial.

The characteristic finding on radiographs is a linear soft tissue-filling defect (membrane) seen within the airway. A plaque-like irregularity of the tracheal wall is also suggestive. Other findings include narrowing of subglottic trachea (symmetric or asymmetric) with loss of its wall definition. The older age of the patient (>3 years) aids in distinction from croup.

Foreign Body

Post-aspiration, most foreign bodies (FB) lodge in the lower airway. FB in the larynx or trachea are much less common and the patients present with sudden onset stridor and respiratory distress. FB, if lodged in the esophagus, may also present with respiratory symptoms. Radiographs reveal either a radiopaque FB or soft-tissue density within the airway or loss of definition of the airway wall **(Figs. 3A to C)**.

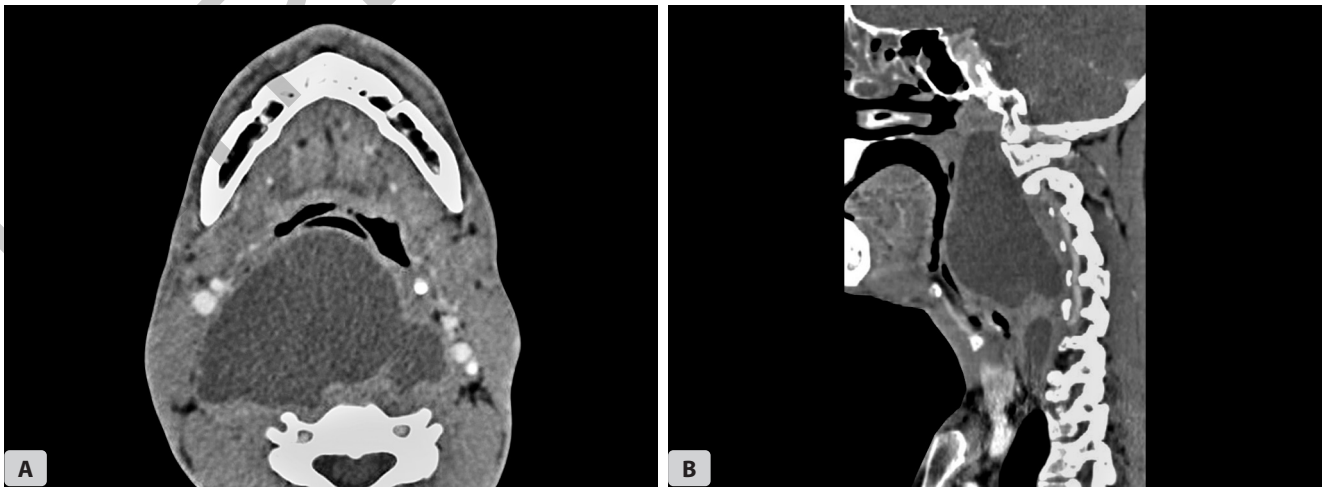

FIGS. 2A AND B: Retropharyngeal abscess: Contrast-enhanced CT neck in a patient with low-grade fever, respiratory distress, and dysphagia shows a large peripherally enhancing, prevertebral abscess compressing airway.

JAYPEE BROTHERS

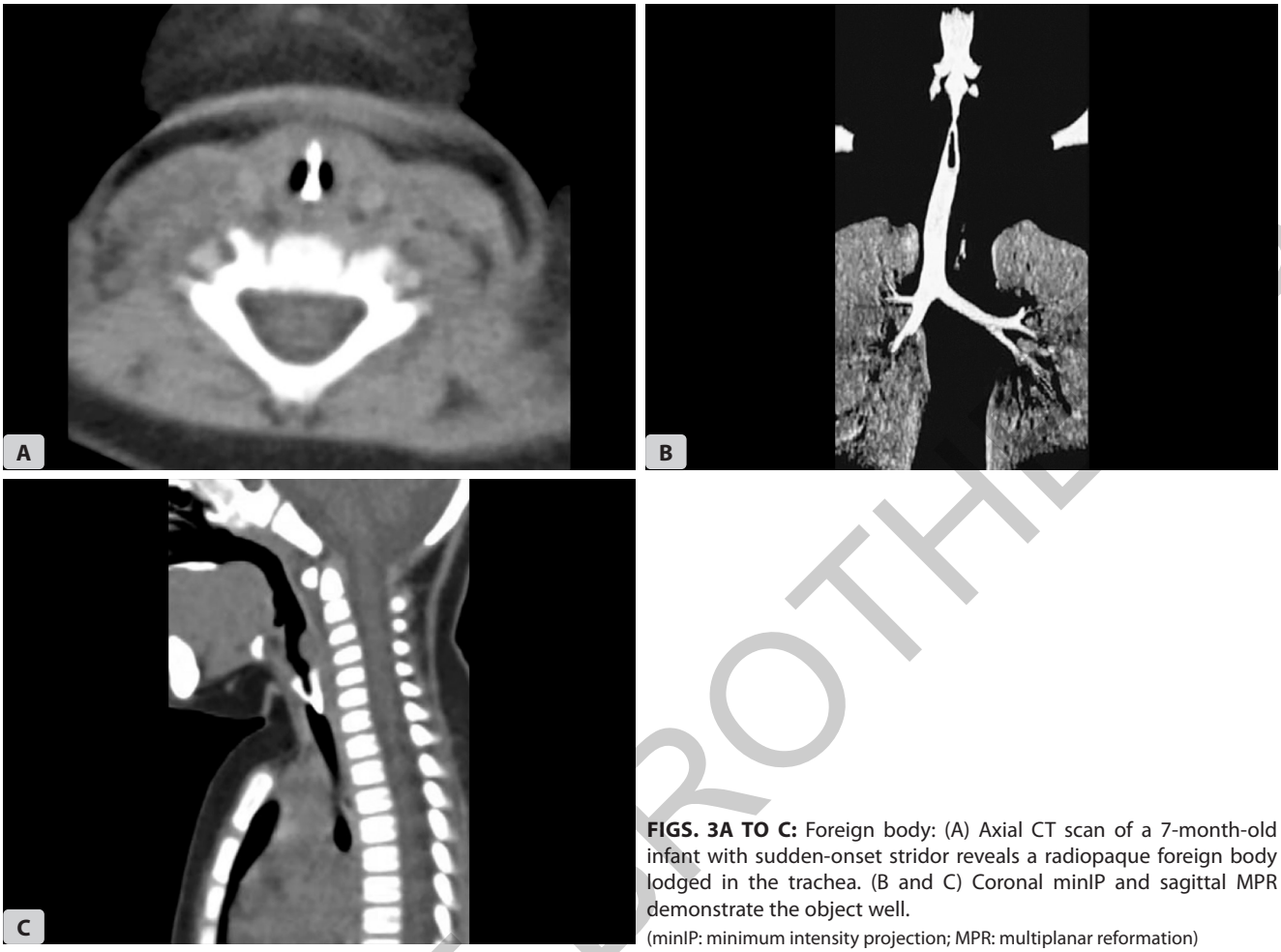

FIGS. 3A TO C: Foreign body: (A) Axial CT scan of a 7-month-old infant with sudden-onset stridor reveals a radiopaque foreign body lodged in the trachea. (B and C) Coronal minIP and sagittal MPR demonstrate the object well.
(minIP: minimum intensity projection; MPR: multiplanar reformation)

Chronic Obstruction

The clinical presentation in children with chronic upper airway obstruction differs from that of acute obstruction. While these children may present with stridor, symptoms of sleep apnea or snoring are more common.

Obstructive Sleep Apnea

Sleep apnea may be seen in 1–6% of children.[1,14] The various causes include any space-occupying lesion or fixed narrowing, which may be congenital, inflammatory, or neoplastic in etiology.

At various levels, the causes are:

- *Nasal cavity/nasopharynx*: Adenoidal enlargement, choanal atresia, and juvenile angiofibroma.
- *Oropharynx*: Micrognathia or retrognathia with posterior displacement of tongue **(Fig. 4)**, macroglossia, and glossoptosis.
- *Hypopharynx*: Hypopharyngeal collapse.
- *Larynx*: Laryngomalacia, congenital cysts.

Large hemangiomas/vascular malformations can cause airway obstruction at any level.



FIG. 4: Micrognathia with posterior displacement of tongue. Still image from cine magnetic resonance imaging (MRI) shows the retrognathia (arrowhead) and displaced tongue narrowing the oropharyngeal airway (black arrow).

Magnetic resonance imaging is useful in evaluation of patients with obstructive sleep apnea (OSA). Indications for dynamic MR sleep imaging include persistence

JAYPEE BROTHERS

of OSA despite tonsillectomy and adenoidectomy, OSA with predisposition to obstruction at multiple sites (craniofacial anomalies, Down syndrome), and evaluation of OSA before any complex airway surgery and obesity.

Enlarged Tonsils/Adenoids

The most common cause of chronic upper airway obstruction is enlargement of adenoids and palatine tonsils. Enlargement of lingual tonsils results in OSA only uncommonly. On a lateral radiograph, enlarged adenoids appear as convex soft-tissue mass (>2 cm) in the posterior nasopharynx narrowing or obliterating the nasopharyngeal air lucency. CT also demonstrates tonsillar adenoidal enlargements as well **(Figs. 5A to C)**. Enlarged palatine tonsils appear as soft-tissue mass projecting on the posterior aspect of soft palate.[1]

On T2-weighted (T2W) and STIR images, adenoids and tonsils appear hyperintense.

Glossoptosis

Glossoptosis means abnormal posterior motion of the tongue during sleep and is associated with underlying hypotonia, macroglossia, or micrognathia. Macroglossia and micrognathia may be diagnosed on lateral radiograph. However, glossoptosis can be demonstrated on dynamic sleep fluoroscopy or cine MRI.

Hypopharyngeal Collapse

Congenital hypopharyngeal collapse refers to cylindrical collapse of the hypopharynx, with its anterior, posterior, and lateral walls all moving centrally. It is associated with disorders of decreased muscular tone. This can be diagnosed on cine fluoroscopy or MRI.

Osseous Causes

Children with mandibular hypoplasia (micrognathia) or retrognathia have OSA consequent to posterior tongue.

Subglottic Obstruction

Subglottis is a common site of obstruction in children.

Subglottic Stenosis

Short segment subglottic stenosis is often congenital in origin **(Figs. 6A and B)**.

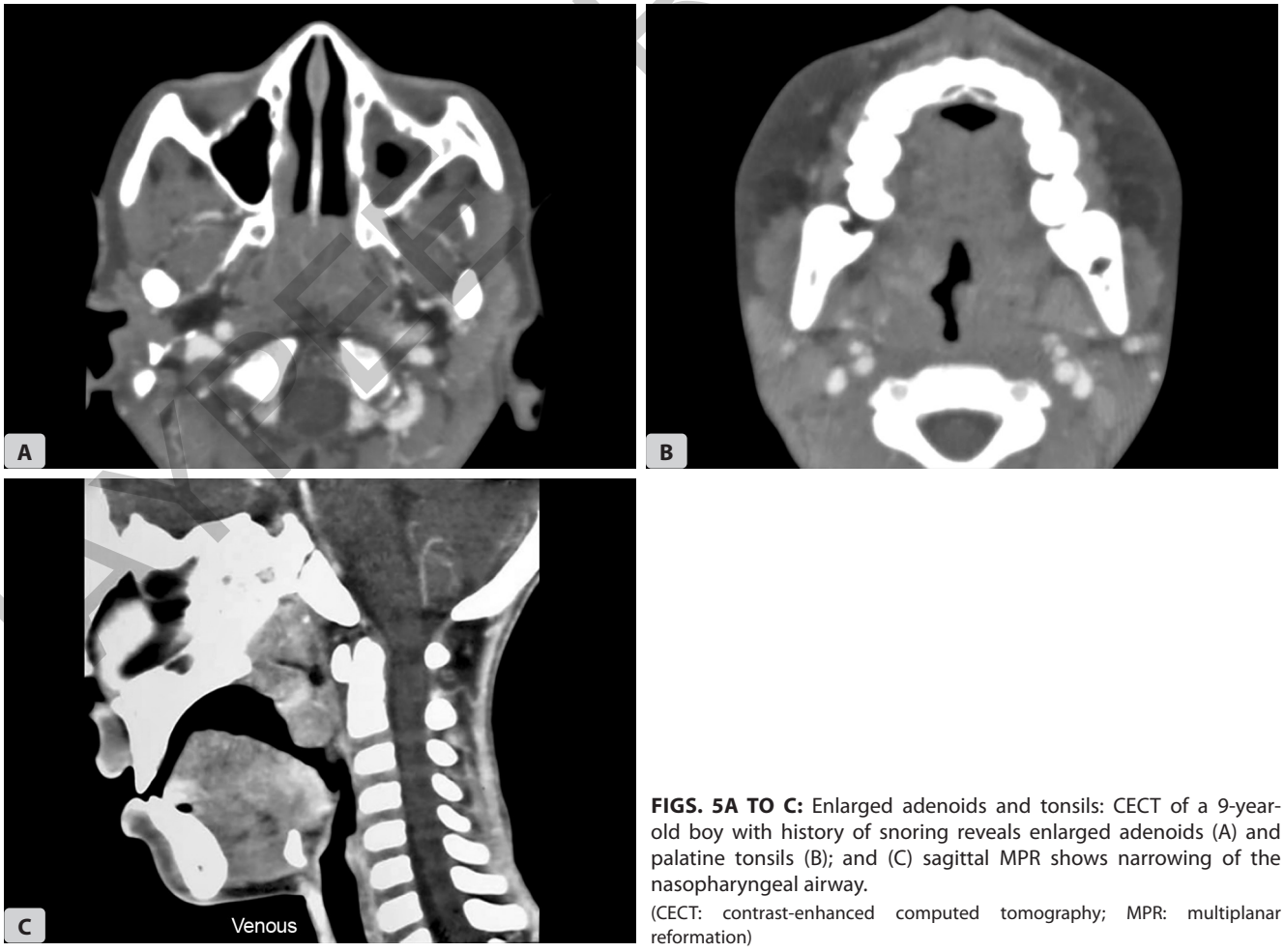

FIGS. 5A TO C: Enlarged adenoids and tonsils: CECT of a 9-year-old boy with history of snoring reveals enlarged adenoids (A) and palatine tonsils (B); and (C) sagittal MPR shows narrowing of the nasopharyngeal airway.

(CECT: contrast-enhanced computed tomography; MPR: multiplanar reformation)

JAYPEE BROTHERS

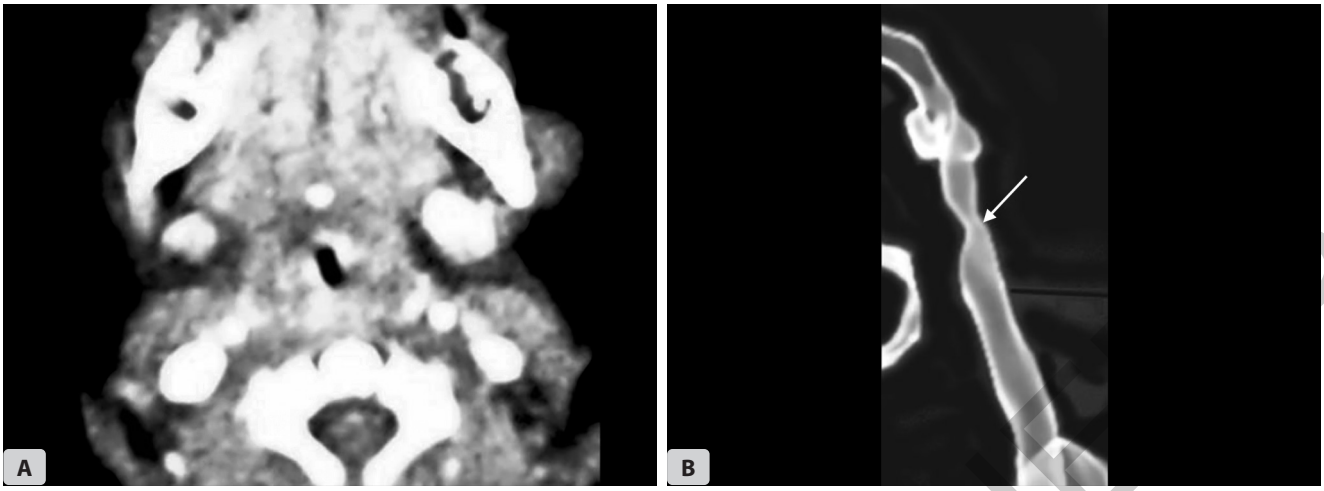

FIGS. 6A AND B: Subglottic stenosis: CECT of a newborn with stridor. Axial (A) and sagittal VRT (B) images show a short segment, smooth subglottic stenosis (arrow).
(CECT: contrast-enhanced computed tomography; VRT: volume rendering technique)



FIGS. 7A TO C: Postintubation stenosis: A short segment, smooth stenosis is seen in upper trachea on sagittal MPR (A), coronal minIP (B), and VB (C) CT images of a child with history of prolonged intubation.
(minIP: minimum intensity projection; MPR: multiplanar reformation)

Postintubation Stenosis

Prolonged intubation can lead to either tracheomalacia or airway stenosis, particularly with oversized endotracheal tubes or balloon cuffs. Airway stenosis consequent to prolonged intubation usually occurs at the level of cricoid cartilage, which is the narrowest part of the upper airway **(Figs. 7A to C)**.[15]

Subglottic Hemangioma

Hemangiomas located in the soft tissues of the neck may extend into the subglottic airway. Large hemangiomas or vascular malformations can cause obstruction at any level **(Figs. 8 and 9)**. These present in infancy, often at <6 months of age and may be associated with hemangiomas of the face or trunk.

Plain radiographs reveal asymmetric subglottic narrowing with associated soft tissue. Ultrasonography (USG) of upper airway region is useful in identifying the lesion and assessment on color Doppler provides diagnostic information **(Fig. 8C)**. On cross-sectional imaging, the lesions show intense contrast enhancement which may be nodular. These lesions are unilateral or bilateral, but often asymmetric and occasionally circumferential. On T2W images, as elsewhere, hemangiomas appear hyperintense. Although a benign lesion with a natural history of proliferation and involution, complications of bleeding and airway obstruction can be life-threatening. Spontaneous regression is typical. Endoscopy confirms the diagnosis. When the presentation demands active management, as in patients with symptomatic airway compromise, treatment options include systemic or intralesional corticosteroids, laser ablation, interferon therapy, or surgical excision.[16]

JAYPEE BROTHERS

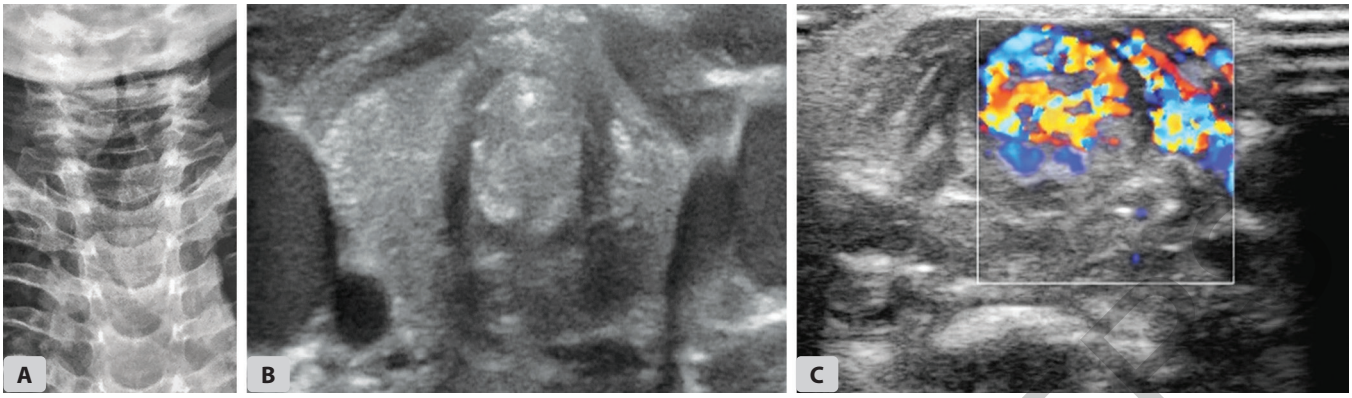

FIGS. 8A TO C: Subglottic hemangioma: (A) Frontal radiograph shows narrowing in the subglottic region. (B and C) Ultrasonography (USG) of upper airway shows echogenic mass in subglottic region showing intense vascularity on color Doppler.

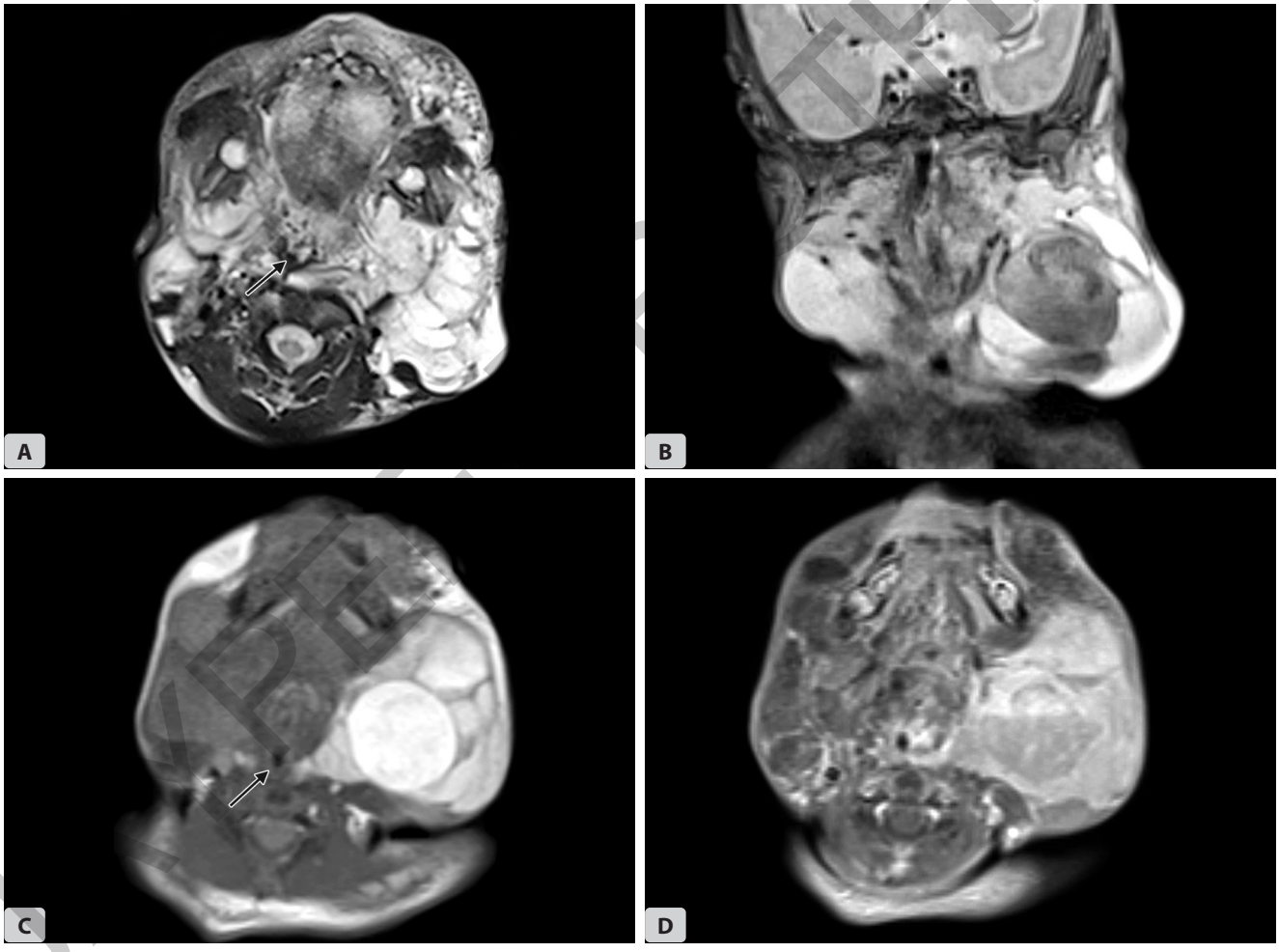

FIGS. 9A TO D: Venolymphatic malformation with airway compression: (A and B) T2WI showing hyperintense multicystic mass in left parotid and submandibular regions extending in parapharyngeal space causing airway narrowing (black arrow). (C) T1WI shows hyperintense contents within (suggestive of hemorrhage) (black arrow). (D) Fluid levels are also noted within the lesion.

(T1WI: T1-weighted image; T2WI: T2-weighted image)

LOWER AIRWAY OBSTRUCTION

Central Airways

The central causes of airway obstruction may be extrinsic or intrinsic (involving either the wall or lumen).

Investigations include frontal and lateral radiographs of the airway and chest. The neck radiographs help to exclude upper airway obstruction. Chest radiographs should be evaluated for tracheal caliber, cardiac size, position of the aortic arch, mediastinal widening, asymmetric lung aeration, lung collapse or consolidation, and radiopaque FB. The length of tracheal narrowing and involvement of anterior/posterior walls should be noted. If the radiographs are suggestive of an intrinsic cause of obstruction, then one can proceed with fiberoptic bronchoscopy. If the suspected cause is extrinsic, then further cross-sectional imaging is indicated.

The choice between CT and MRI is not clearly defined. While MRI has the advantage of being radiation free and not dependent on intravenous contrast, its main drawback is the long scanning times. The need for sedation, especially in a child with airway compromise often negates the advantages of MRI, making CT the preferred modality. Both modalities offer good contrast between the central airway and surrounding structures, while the lungs are better visualized on CT.

Extrinsic Causes

Any mass lesion of the mediastinum such as nodes and cysts includes the nonvascular causes of airway compression. Chest wall deformities may similarly result in airway compromise.

The classical vascular causes include double aortic arch, anomalous left pulmonary artery (pulmonary sling), and innominate artery compression syndrome. However, several other vascular causes such as dilatation of pulmonary artery, enlargement of ascending aorta, midline descending aorta, and right arch with aberrant left subclavian artery can also result in airway compression. A vascular ring encircling the airway occurs as a result of the failure of primitive vascular structures to fuse and regress normally during the development of the aortic arch, pulmonary arteries, and/or ductus arteriosus. Patients with vascular rings may have wheezing, stridor, feeding difficulties, choking episodes, or even aspiration pneumonia, depending on the degree of tracheal and esophageal narrowing. Plain radiographs and barium swallow cannot reliably distinguish among the types of vascular ring. Cross-sectional imaging, either with CT or MR, is helpful in delineating the anatomy and aiding in presurgical planning and postsurgical assessment.[17]

Vascular Causes

Vascular Rings (Tables 2 and 3)

Double aortic arch: It is a congenital arch anomaly and is the most common vascular ring to cause airway compression. It is usually an isolated anomaly. Both right and left arches are seen to arise from the ascending aorta and join to form the descending aorta. Right arch is commonly larger and posterosuperior.

The two arches surround and compress the trachea anteriorly and esophagus posteriorly **(Figs. 10A and B)**. The level of compression is mid to lower thirds of intrathoracic trachea **(Table 2)**.[18] On radiography, lateral tracheal indentations are seen. On cross-sectional imaging, it is important to determine the dominant arch (side), as the surgical approach differs accordingly **(Figs. 10A and B)**.

Right arch with aberrant left subclavian artery: This is an arch anomaly wherein the aortic arch is located to the right of trachea. The left subclavian artery (LSA) originates from the proximal descending aorta and courses to the left behind the esophagus. In 60% cases, there is dilatation of origin of the LSA (aortic diverticulum of Kommerell).[19] It is commonly an asymptomatic finding with only 5% patients having symptoms. However, this anomaly may be associated with a constricting left ligamentum arteriosum, forming a vascular ring and causing airway compression. If the ligamentum arteriosum connects to LSA, it forms a loose vascular ring, while if it extends to the aortic diverticulum of Kommerell, a tight vascular ring is formed.

On frontal radiograph, there is aortic arch indentation on the right wall of the trachea with tracheal deviation to the left **(Figs. 11A to C)**. Right-sided descending aorta

Table 2: Vascular rings.

Aortic abnormalities	*Incidence*	*Embryology*	*Associations*	*Age of presentation/symptoms*
Double aortic arch	Most common	Persistent bilateral fourth branchial arches	Mostly isolated	• Symptomatic • Infancy
Right aortic arch with aberrant left subclavian artery (SCA)	Second most common	Interrupted hypothetical left arch [between left common carotid artery (CCA) and left SCA]	Mostly isolated	• Often asymptomatic • "Loose ring" between left SCA and persistent left ligamentous arteriosum
Left aortic arch with aberrant right SCA	–	–	–	Ring formed between right SCA and intact right ligamentum arteriosum

JAYPEE BROTHERS

Table 3: Imaging features of vascular rings.

Aortic abnormalities	*CXR*	*Barium swallow*	*CTA/MRA*
Double aortic arch	• Right-sided/bilateral aortic knuckles • Trachea midline (abnormal) • Narrowing—supracarinal • Lateral—anterior bowing, narrowing • Air trapping—infrequent	• Right/bilateral indentations on esophagus • Lateral view posterior indentation • Level aortic arch	• Right arch dominant—classical variant (majority 70%) • Higher, larger • Left—smaller/atretic band may cause traction on left SCA • Important to identify dominant arch • Nondominant side operated • Aortic diverticulum (in case of atretic segment) • Square (trapezoid) symmetric appearance of major arch branches • "Four artery sign" • Lower trachea/carina narrowing
Right aortic arch with aberrant left subclavian artery (SCA)	• Right-sided aortic knuckle • Lateral—rounded mass like opacity retrotracheal, just above arch of aorta (space is called Raider triangle)	• Right lateral and posterior indentation • Oblique angled to left shoulder • Normal left aortic arch indentation absent	• Right-sided aortic arch • Four brachiocephalic branch vessels (instead of three) • Lateral SCA last branch • Aortic diverticulum at origin, retroesophageal • Airway narrowing—variable, lower trachea • Ligamentum arteriosum is not directly visualized

(CTA: computed tomography angiography; CXR: chest X-ray; MRA: magnetic resonance angiography)

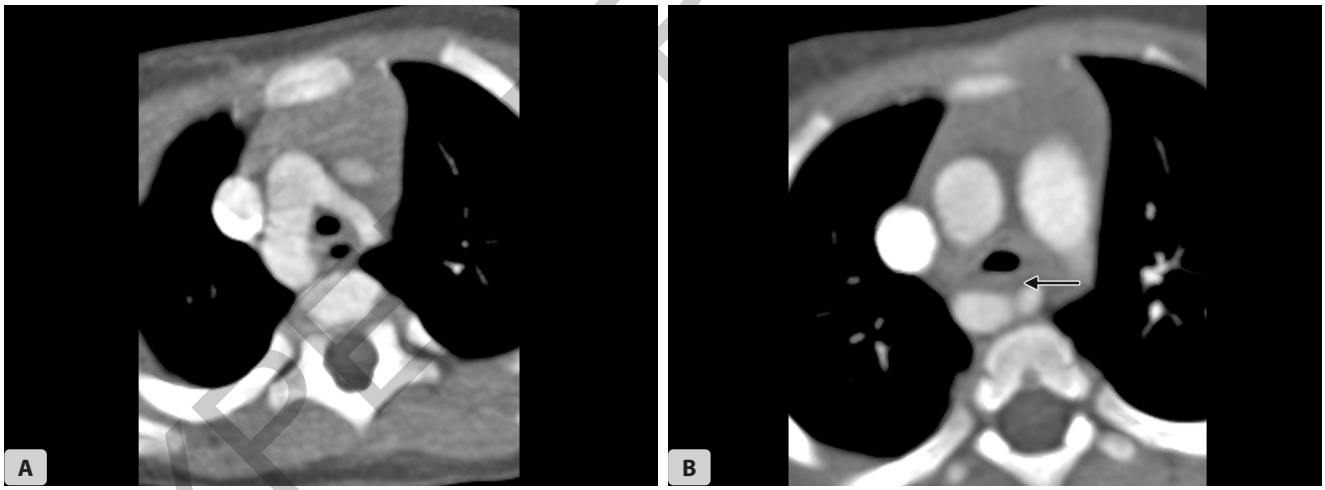

FIGS. 10A AND B: Double aortic arch: (A and B) Axial computed tomography angiography (CTA) images show right-sided dominant arch with mild extrinsic anterior compression on lower trachea and posterior compression on esophagus (black arrow).

may also be seen. Lateral view reveals indentation on the posterior aspect of trachea. On barium swallow, frontal views show a filling defect coursing from right inferior to left superior. On lateral view, there is posterior esophageal indentation. Cross-sectional imaging is indicated when there is clinical or radiographic evidence of airway compression.

There are several other aortic arch anomalies which can result in airway compression; these are uncommon. Some of these are associated with cervical position of aortic arch. Computed tomography angiography (CTA)/magnetic resonance angiography (MRA) can demonstrate the location of the arch, its major branches, and associated airway narrowing. A patent ductus arteriosus (PDA) is also well-delineated. Ligamentum arteriosum is not directly seen on CTA/MRA; although some indirect signs can point to its presence, i.e., presence of aortic diverticulum, tracheal narrowing/distortion. Also, these are mostly opposite to aortic arch side. It is to be noted that incidence of aortic arch anomalies may be different from associated airway narrowing, as not all anomalies will result in airway compression. Also, congenital heart diseases should be looked for even in nongated CTA/MRA and reported as far as possible.

JAYPEE BROTHERS

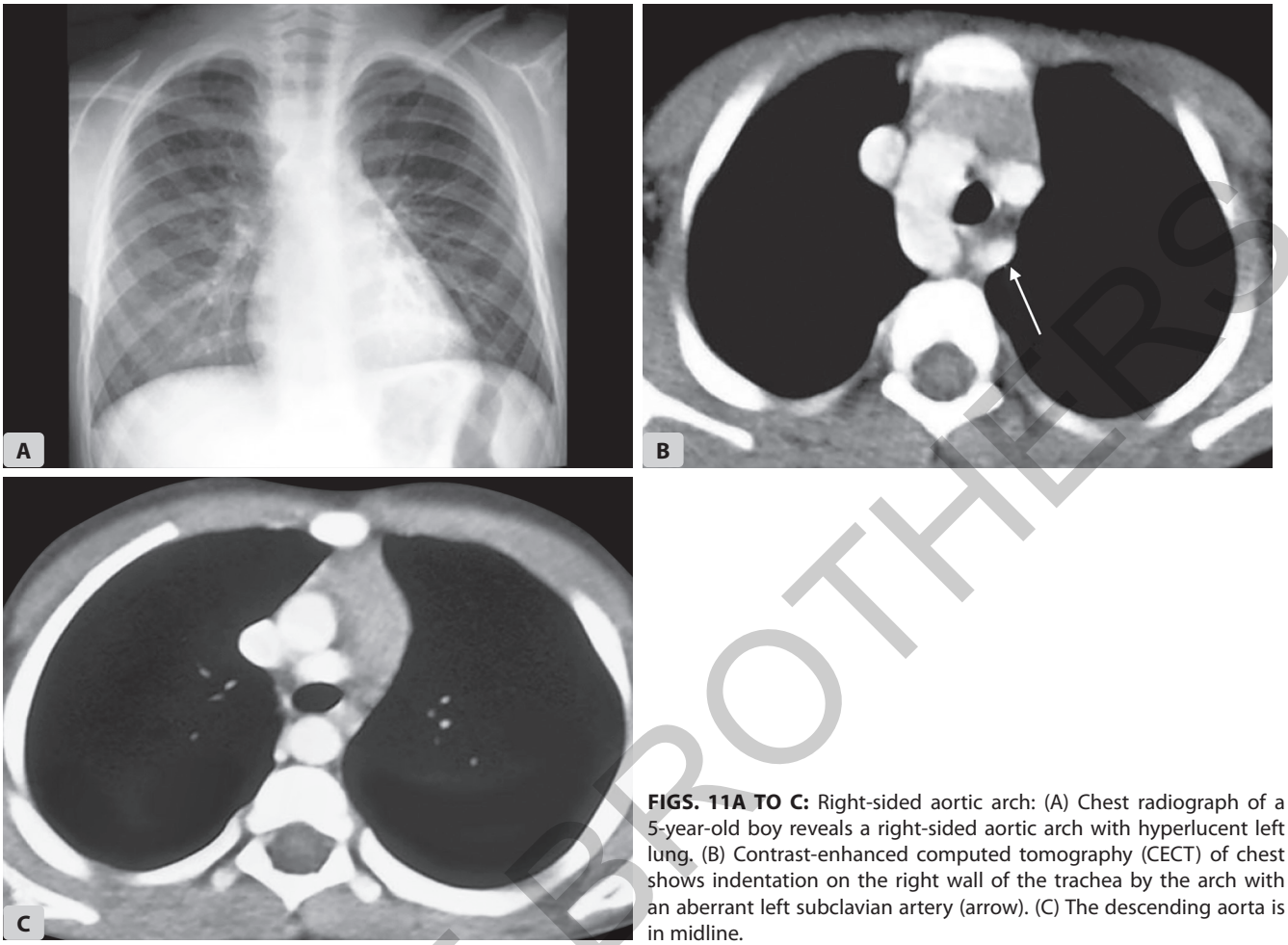

FIGS. 11A TO C: Right-sided aortic arch: (A) Chest radiograph of a 5-year-old boy reveals a right-sided aortic arch with hyperlucent left lung. (B) Contrast-enhanced computed tomography (CECT) of chest shows indentation on the right wall of the trachea by the arch with an aberrant left subclavian artery (arrow). (C) The descending aorta is in midline.

Midline descending aorta: In this anomaly, the descending aorta is positioned immediately anterior to the vertebral body, instead of the normal left paravertebral location. It may be an isolated lesion or be associated with hypoplastic right lung and hence mediastinal shift or aortic arch anomalies. Malposition may result in airway compression due to crowding of structures. Radiographs are often normal and cross-sectional imaging reveals the diagnosis.

Pulmonary Sling

It refers to a pulmonary artery anomaly wherein the left pulmonary artery arises from the proximal right pulmonary artery, forming a "sling" around the trachea. It subsequently passes between the trachea and esophagus as it courses toward the left lung **(Fig. 12A)**.[20]

It may be associated with congenital heart disease and complete tracheal rings, worsening the airway compromise **(Figs. 12A and B)**. Frontal radiograph reveals asymmetric lung inflation. On lateral radiograph, there is posterior compression of the trachea with anterior esophageal impression. It is the only vascular ring to course between the trachea and esophagus, to be associated with asymmetric lung inflation and also the only one to cause anterior indentation on the esophagus.

Types of pulmonary slings: There are two types on basis of associated airway anomalies **(Flowchart 1)**.[18]

Innominate artery compression syndrome: Innominate artery (brachiocephalic) crosses the trachea anteriorly, just below the thoracic inlet. In infants, it arises more to the left than adults.[21]

In addition, the presence of a large thymus in the mediastinum and lack of rigidity of infantile trachea result in tracheal compression. The range of symptoms varies from none to stridor and dyspnea resulting from severe compression. Most children outgrow the disease, and surgery is reserved only for those with severe compression. Lateral radiographs reveal focal anterior indentation of the trachea. CT and MRI detail the severity of the compression and exclude other causes **(Fig. 13)**.

Vascular Malformations

Vascular malformations may be venous, lymphatic, or mixed venolymphatic. Although these lesions are usually soft and compressible, giant malformations of the neck and/or chest can compress airway.

Bronchopulmonary foregut malformations: Bronchogenic cysts are among most common cystic lesions in the

JAYPEE BROTHERS

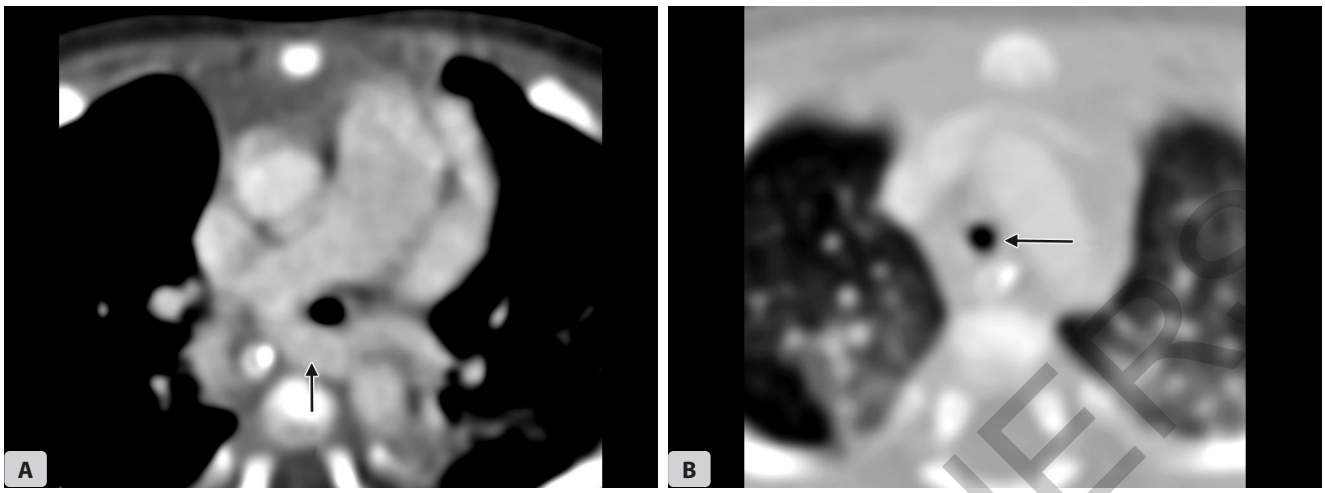

FIGS. 12A AND B: Pulmonary sling type II: (A) Axial contrast-enhanced computed tomography (CECT) image showing the left pulmonary artery (black arrow) coursing posterior to lower trachea. (B) Associated complete cartilage ring giving a rounded appearance to trachea (black arrow).

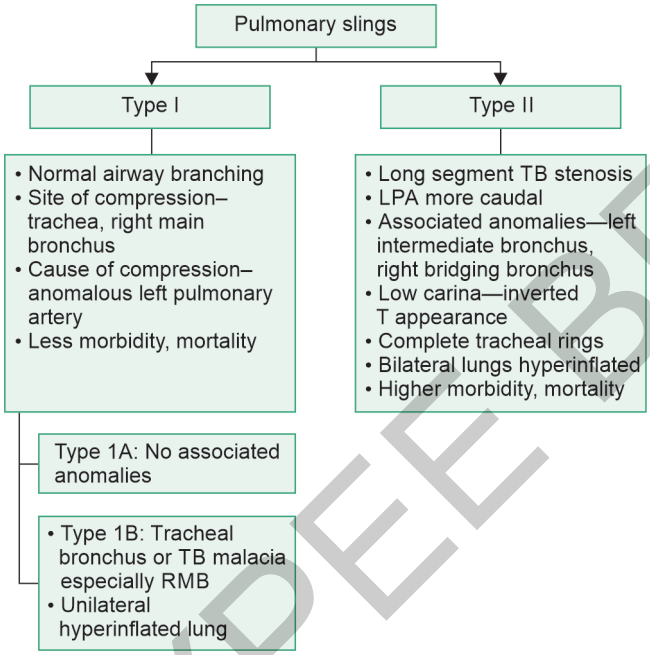

FLOWCHART 1: Types of pulmonary slings.
(LPA: left pulmonary artery; RMB: right main bronchus; TB: tuberculosis)

pediatric chest. The most common location is around the carina.

Hence, when large, these result in compression of the proximal bronchi **(Figs. 14A to C)**. They can occur anywhere along the respiratory tract. The dilated proximal esophageal pouch in patients of esophageal atresia can also exert a mass effect on the adjoining airway **(Fig. 15)**.

Inflammatory causes: Deep neck space infections, when they spread into the mediastinum, can compress the airway **(Figs. 16A to C)**. Large paravertebral abscesses, even tubercular, may result in significant airway compression. Mediastinal lymphadenopathy, tubercular, or fungal infections can also narrow the airway by mass effect **(Figs. 17A to D)**.

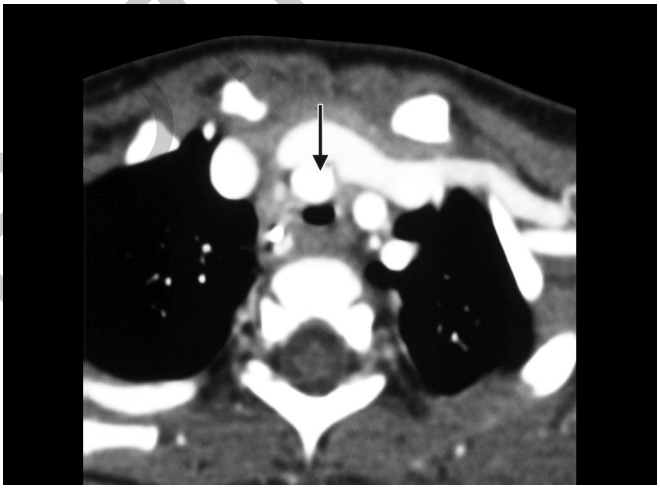

FIG. 13: Innominate artery compression syndrome: Computed tomography angiography (CTA) axial image shows the right brachiocephalic artery compressing the anterior tracheal wall (black arrow).

Masses: Lymphoma is the most common childhood neoplasm to cause symptomatic airway compromise in children. Other neoplasms that tend to narrow the airway by extrinsic mass effect include infantile hemangiomas, germ cell tumors, rhabdomyosarcomas, and neurogenic tumors **(Figs. 18A and B)**.

Intrinsic Causes

Intrinsic causes include those involving the wall, which may be dynamic (tracheomalacia) or fixed (stenosis) and intraluminal lesions.

Wall Abnormalities

Tracheomalacia: It refers to abnormal softening of the trachea due to abnormality of the cartilaginous rings. This results in intermittent (expiratory) collapse of the trachea. The narrowing of the tracheal lumen is most marked during forced expiration, coughing, or the Valsalva

JAYPEE BROTHERS

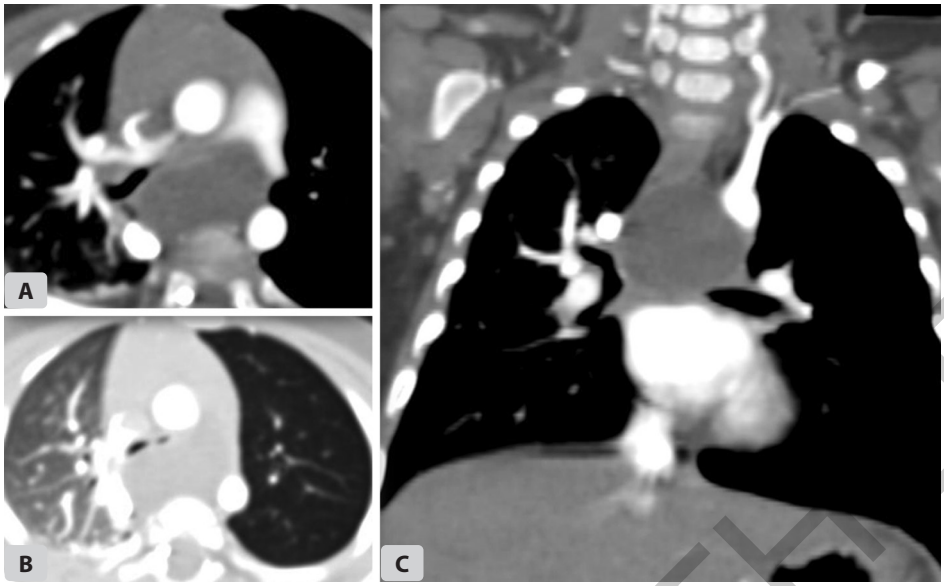

FIGS. 14A TO C: Bronchogenic cyst: Subcarinal cystic lesion causing severe compression of left main bronchus with resultant hyperinflation and lucency of left lung.

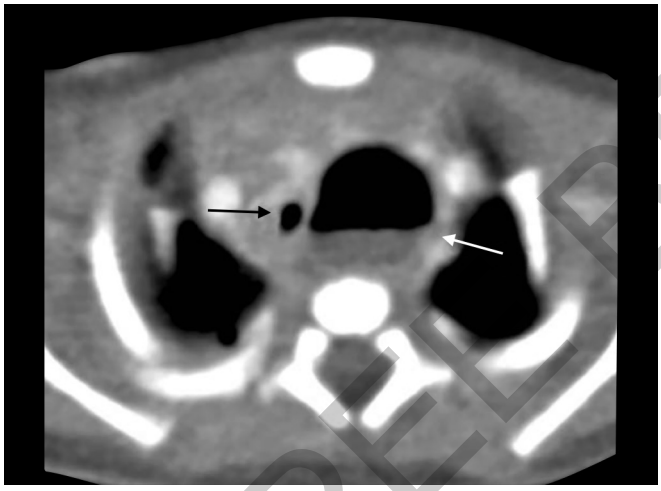

FIG. 15: Esophageal atresia: Contrast-enhanced computed tomography (CECT) of a neonate with esophageal atresia, performed to evaluate respiratory distress shows the dilated proximal esophageal pouch (white arrow) causing significant compression of the trachea (black arrow).

maneuver. It may be primary or secondary to compression by masses or vascular structures. Similar condition may involve the proximal bronchi. It may be congenital associated with syndromes such as cystic fibrosis or even result from chronic inflammation, chronic extrinsic compression, or prior intubation.[22] The characteristic clinical presentation is of an expiratory wheeze. Various causes of tracheomalacia are shown in **Table 4**.

The diagnosis cannot be made on the basis of a single radiograph. Fluoroscopy and typically fiberoptic bronchoscopy can demonstrate the characteristic dynamic collapse of the trachea. Airway fluoroscopy done in a lateral projection is the traditional radiographic method of diagnosing tracheomalacia. However, bronchomalacia is difficult to diagnose on fluoroscopy and dynamic/multiphasic CT/MRI are preferred methods for this entity. On a single-phase inspiratory CT, the diagnosis is difficult, although the trachea may demonstrate an abnormal shape being flattened slightly posteriorly in the membranous part **(Figs. 19A to D)**. The diagnostic criteria on imaging are >50% reduction in tracheal/bronchial caliber on expiratory scans. Paired inspiratory-expiratory CT/cine CT is more sensitive to demonstrate the expiratory collapse and requires the measurement of the area of trachea in both the phases.[23]

Stenosis: Fixed tracheal stenosis may be congenital or acquired. Congenital tracheal stenosis results from absence of the membranous portion of the trachea resulting in complete or near complete cartilaginous tracheal rings. The various patterns of tracheal stenosis include generalized stenosis, carrot- or funnel-shaped segmental stenosis, and focal stenosis. Focal stenosis usually involves the lower trachea. A tight focal stenosis causes more severe symptoms than a long, mild stenosis. It may be associated with congenital heart disease, pulmonary sling, tracheoesophageal fistula (TEF), or skeletal abnormalities. On axial imaging, trachea appears as a round or complete circle (O-shaped). Other findings include circumferential narrowing of the entire length of the trachea and fusion of the cartilaginous tracheal rings posteriorly.[24]

Congenital tracheal web is a rare entity. The web is usually not associated with deformity of the tracheal cartilage or the tracheal wall. CT reveals a web-like structure traversing and narrowing the tracheal lumen,[25] which is well-demonstrated on coronal reformatted images and virtual bronchoscopy.

JAYPEE BROTHERS

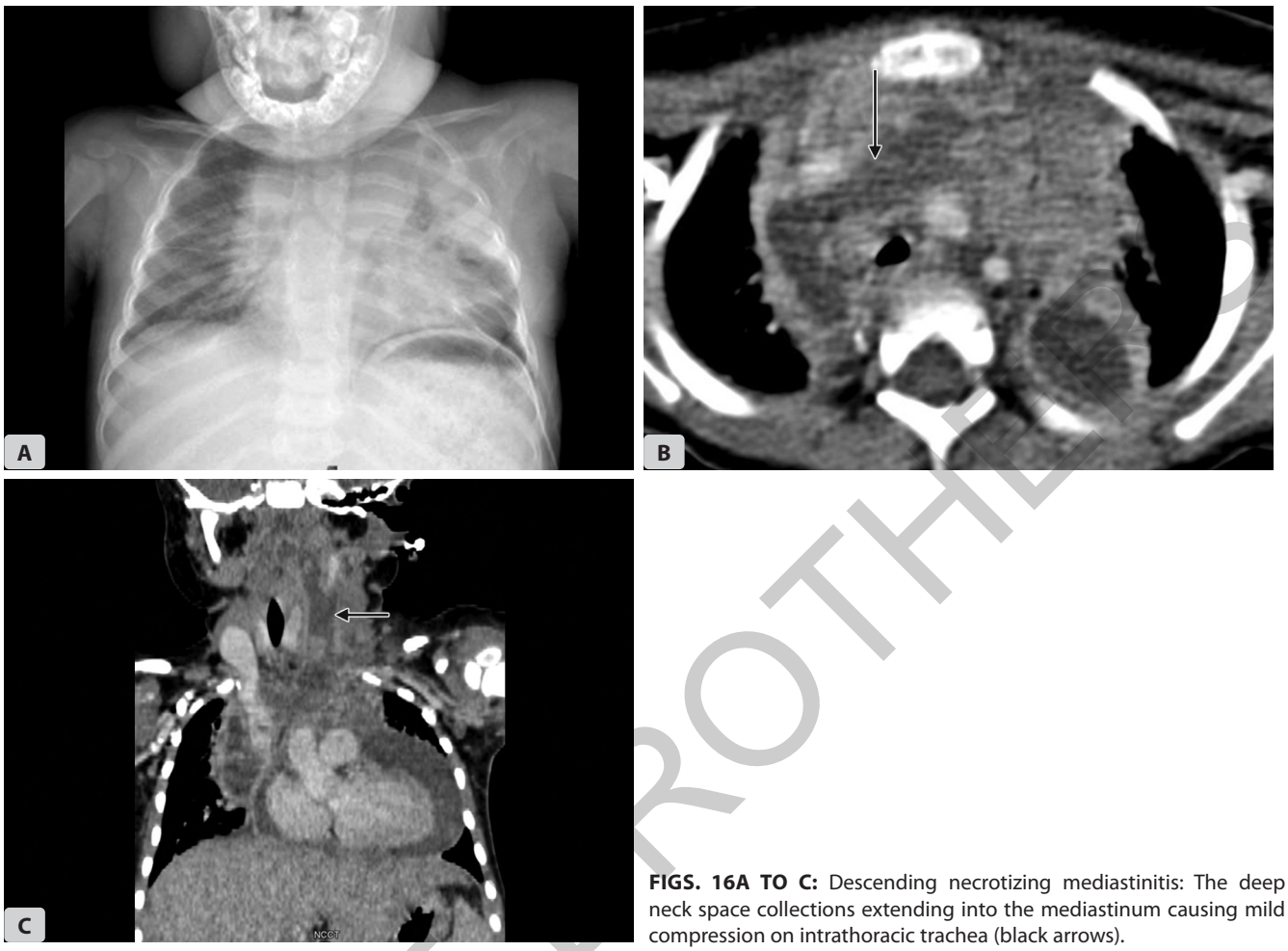

FIGS. 16A TO C: Descending necrotizing mediastinitis: The deep neck space collections extending into the mediastinum causing mild compression on intrathoracic trachea (black arrows).

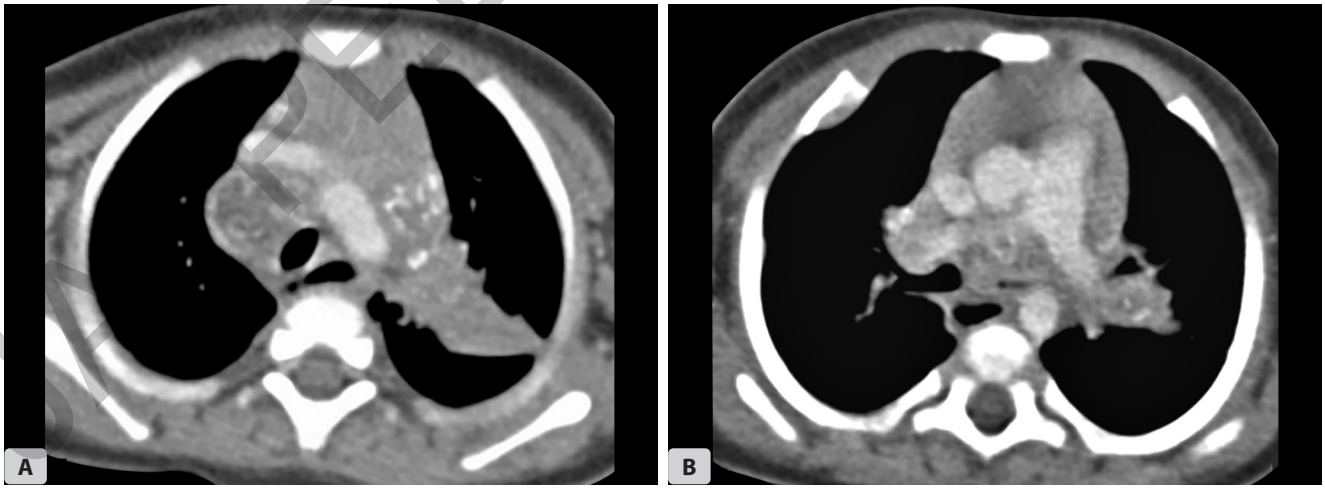

FIGS. 17A TO D: *Continued*

NOT FOR BROTHERS

Continued

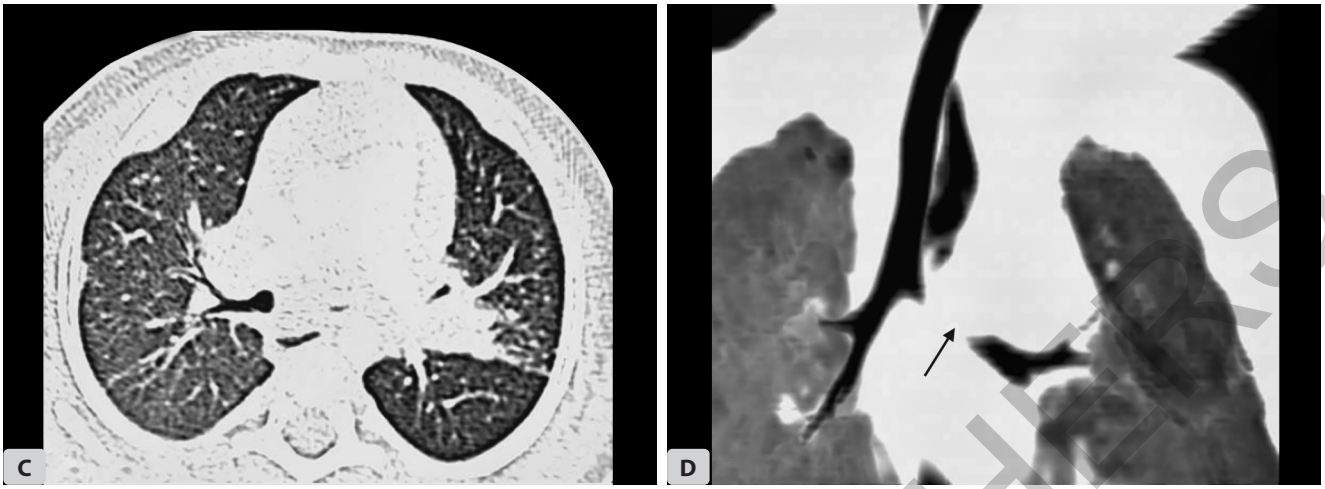

FIGS. 17A TO D: Tubercular lymphadenopathy: (A) CECT of a 6-year-old boy reveals conglomerate, necrotic, and calcific mediastinal lymphadenopathy with left upper lobe consolidation; (B to D) A more caudal section of mediastinal window and lung window and minIP show narrowing of the left main (arrow) and upper lobe bronchi.

(CECT: contrast-enhanced computed tomography; minIP: minimum intensity projection)

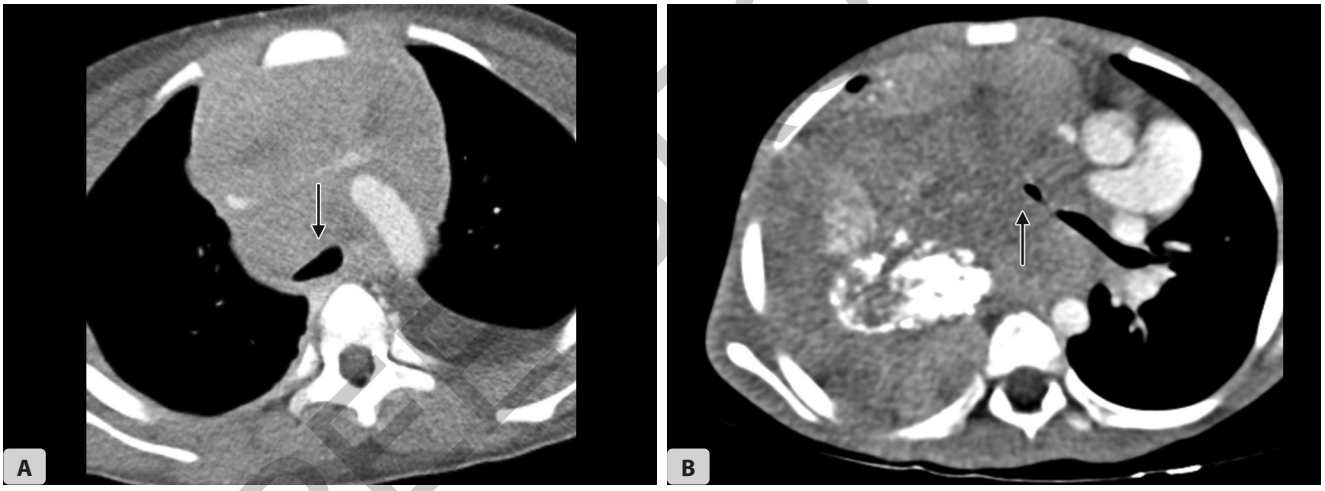

FIGS. 18A AND B: Masses causing airway compromise: (A) Lymphoma: Anterior and middle mediastinal mass causing tracheal compression (black arrow). (B) Thoracic neuroblastoma: Contrast-enhanced computed tomography (CECT) showing a large posterior mediastinal mass lesion with calcifications causing displacement and compression of the major bronchi, especially the right main bronchus (black arrow).

Table 4: Etiologies of tracheomalacia.

Congenital	***Acquired***
• Defective cartilage maturation • Most common central airway anomaly	• Degeneration of cartilage • Intubation • Infection • Trauma

Bronchopulmonary foregut malformations: Bronchopulmonary foregut malformations include a wide spectrum of disorders such as—tracheal agenesis, tracheal stenosis, tracheal fistula, branching anomalies, bronchial stenosis, or lung agenesis and hypoplasia as well as bronchogenic cysts are also included in this group. These anomalies may present with respiratory distress in the newborn, recurrent pulmonary infections, or mass lesions later in life. This chapter deals with anomalies affecting the major bronchi.

Bronchial atresia and sequestration: Bronchial atresia most often involves the left upper lobe. On CT, a mucocele is identified as a hypo- or fluid-attenuating branching structure distal to the atretic bronchus near the hilum. The pulmonary parenchyma distal to the atretic segment is often lucent and demonstrates air trapping. The affected region may even be outlined by pseudo-fissures.

Bronchial atresia may be isolated or associated with a retained systemic vascular connection when it is referred to as intralobar sequestration. The imaging appearance

JAYPEE BROTHERS

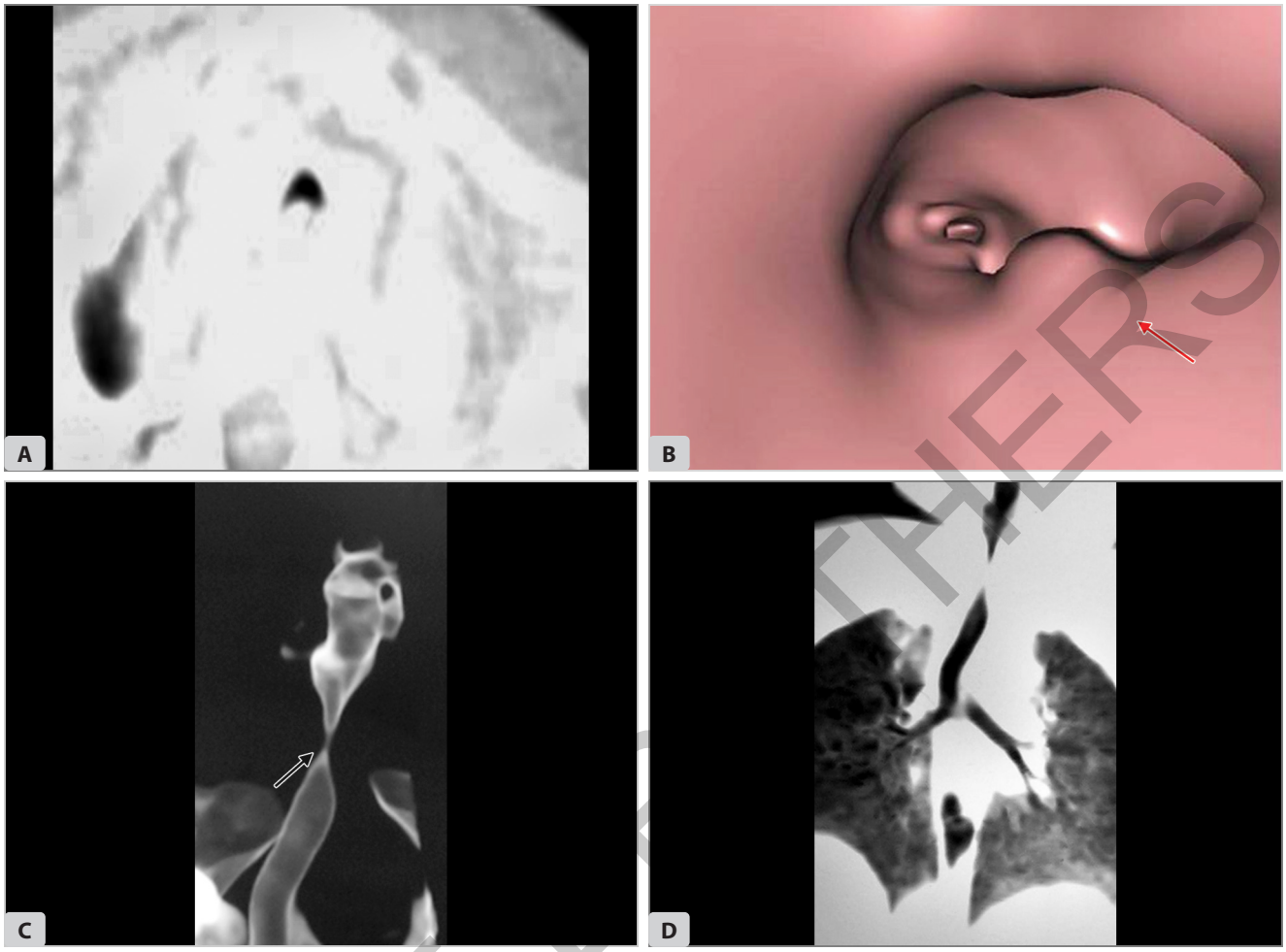

FIGS. 19A TO D: Tracheomalacia: Axial CT (A) and virtual bronchoscopy image (B) of a neonate with stridor showing slight posterior bowing of the trachea. minIP (C) and VRT images (D) show narrowing of subglottic trachea. On bronchoscopy, this narrowing was found to be dynamic.
(minIP: minimum intensity projection; VRT: volume rendering technique)

JAYPEE BROTHERS

is virtually identical to that of isolated bronchial atresia, except that the atretic bronchus is ectopically located at the margin of the lung. Rarely, such ectopic bronchi may not be atretic but have a connection with the gastrointestinal tract, usually the esophagus. Such cases are usually accompanied by bronchiectasis and accumulated secretions from impaired clearance of lung parenchyma. It is hence important to look for airway abnormalities, pulmonary parenchymal abnormalities, retained systemic vascular connections, anomalous pulmonary venous drainage, and airway communication with the gastrointestinal tract in patients with suspected bronchopulmonary foregut malformations.[26,27]

Tracheoesophageal fistula: Esophageal atresia with or without TEF is believed to result from a faulty separation of the embryonic trachea and esophageal remnants. The most common type of these is proximal esophageal atresia with distal TEF (up to 80–90%). H-shaped TEFs with no atresia constitute up to 5–8%. Typical clinical presentation includes failure to pass a feeding tube in a newborn with a history of polyhydramnios at prenatal ultrasound, excessive secretions from the mouth, and respiratory distress. Chest radiograph demonstrates the feeding tube catheter ending/coiling in the proximal thoracic esophagus. The presence of air in the distal gastrointestinal tract confirms the presence of a distal TEF. In such patients, it is important to observe the airway as there is frequently associated tracheomalacia.[18] Also, a dilated proximal esophageal pouch can result in airway compression. Patients with H-type fistula may present with recurrent aspiration or small airway disease (SAD). While contrast esophagogram is the investigation of choice, CT scan may demonstrate the fistula **(Figs. 20A and B)**.

Tracheobronchial branching anomalies: It may be seen as an isolated finding or accompanying heterotaxy syndromes, pulmonary sling, and conditions associated with pulmonary underdevelopment (agenesis, aplasia, or hypoplasia). The most common among these is the tracheal bronchus or "pig bronchus" **(Figs. 21A and B)**. A tracheal bronchus arises from the trachea or mainstem bronchus and aerates either the entire upper lobe or a segment.[28] An accessory cardiac bronchus or tracheal

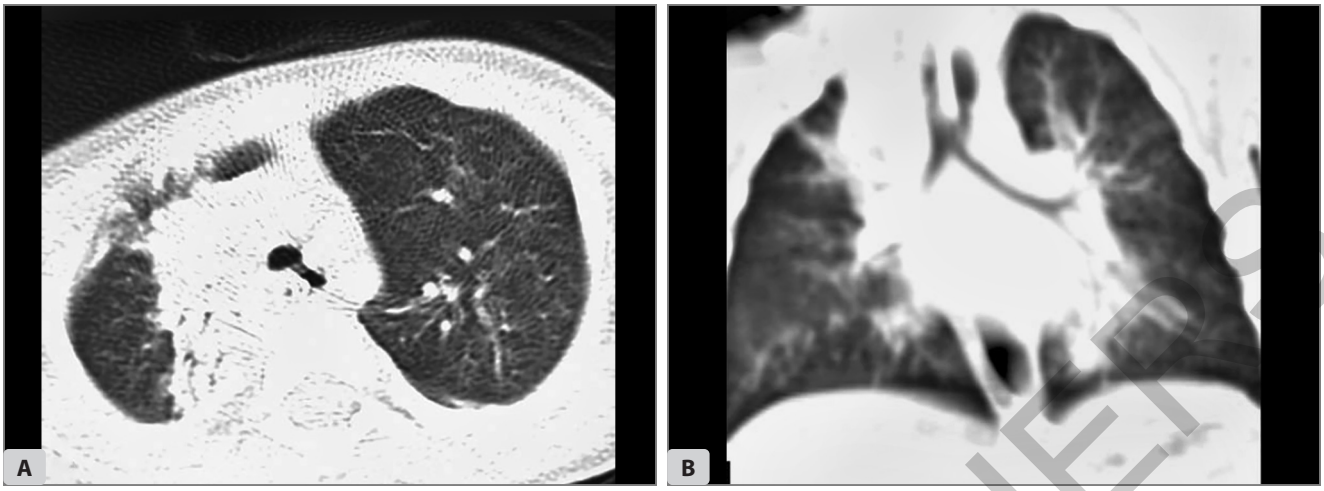

FIGS. 20A AND B: Tracheoesophageal fistula (TEF): (A) Axial CT of an infant reveals a communication between the trachea and esophagus with right upper lobe consolidation. (B) Coronal multiplanar reformation (MPR) also demonstrates the fistula.

diverticulum is also relatively common anomalies. An accessory cardiac bronchus arises from the medial wall of the right mainstem bronchus or bronchus intermedius, grows toward the pericardium terminating as a blind-ending stump or branching further **(Figs. 21C and D)**. Tracheal diverticula are seen arising with an arrow stalk from the right posterolateral wall of the trachea near the thoracic inlet.[4] Other abnormal branching patterns include tracheal trifurcation, bilateral right-sided isomerism, or bilateral left-sided isomerism. A detailed classification of tracheobronchial branching anomalies has been given in "Imaging of the tracheobronchial tree" in AIIMS-MAMC-PGI Imaging Course Series, Diagnostic Radiology-Chest and Cardiovascular Imaging, 5th edition. Lobe-based tracheobronchial classification is shown in **Table 5**.[29]

Metabolic conditions: Hunter syndrome (a mucopolysaccharidosis) may cause the deposition of mucopolysaccharides in the walls of the major airways that result in progressive airway narrowing due to wall thickening and anteroposterior collapse.[30]

Acquired: Acquired tracheal or bronchial strictures usually result from chronic inflammation, often tubercular **(Figs. 22A to E)**. Another cause of acquired airway strictures is post-traumatic sequelae.

Intraluminal Causes

The FB is the most common cause of bronchial obstruction. Soft-tissue masses of the trachea and bronchi are rare.

Foreign body: FB aspiration is most often seen in infants and toddlers (8 months to 3 years). The bronchi are the most common site of lodgment (76%) while laryngeal (6%) or tracheal (4%) lodgment is far less common. Right bronchus is more common (58%) than the left (42%).[31] The clinical presentation may be acute while more often the symptoms remain indolent. The symptoms and signs can mimic asthma, upper respiratory infection, or pneumonia. The history of aspiration is often not elicited. FB may lead to partial ("ball-valve" effect) or complete obstruction, resulting in hyperinflation or collapse, respectively. Chest radiograph findings include asymmetric lung aeration, lung consolidation or atelectasis, and even pneumothorax or pneumomediastinum **(Figs. 23A and B)**. Metallic FBs can be identified on plain radiographs **(Fig. 23A and Flowchart 2)**. However, commonly aspirated airway FBs are food products, particularly nuts and seeds, which are not radiopaque enough to be identified at conventional radiography **(Figs. 24A to D)**. These organic materials can swell following absorption of water and then rapidly change a partial airway obstruction to a complete obstruction.

Inspiratory radiographs alone may be normal in up to a third of patients (14–35%) with FBs. The lung volume of the affected lung/segment may be normal, increased, or decreased. Majority (up to 97%) of the FBs are nonradiopaque. The characteristic radiographic finding is that the lung volume remains static with no change in different phases of respiration. This can be demonstrated by obtaining paired inspiratory-expiratory radiographs in cooperative children. In infants and uncooperative children, bilateral decubitus radiographs of the chest or fluoroscopy can demonstrate the same finding. The differential diagnosis of an asymmetric, lucent lung includes Swyer–James syndrome and pulmonary hypoplasia. However, air trapping may be seen in partial obstruction.

Computed tomography is not routinely advocated in evaluation of a bronchial FB. It may, however, be performed as workup for nonresolving pneumonia or collapse or even stridor **(Figs. 24A to D)**.[32] CT is also a good option when the clinical setting does not strongly warrant bronchoscopy or if bronchoscopy is not readily available. On CT, FBs are well-demonstrated as filling defects in the bronchus, besides detailing the changes in the distal lung. It can identify both opaque and nonopaque FBs. Kosucu

JAYPEE BROTHERS

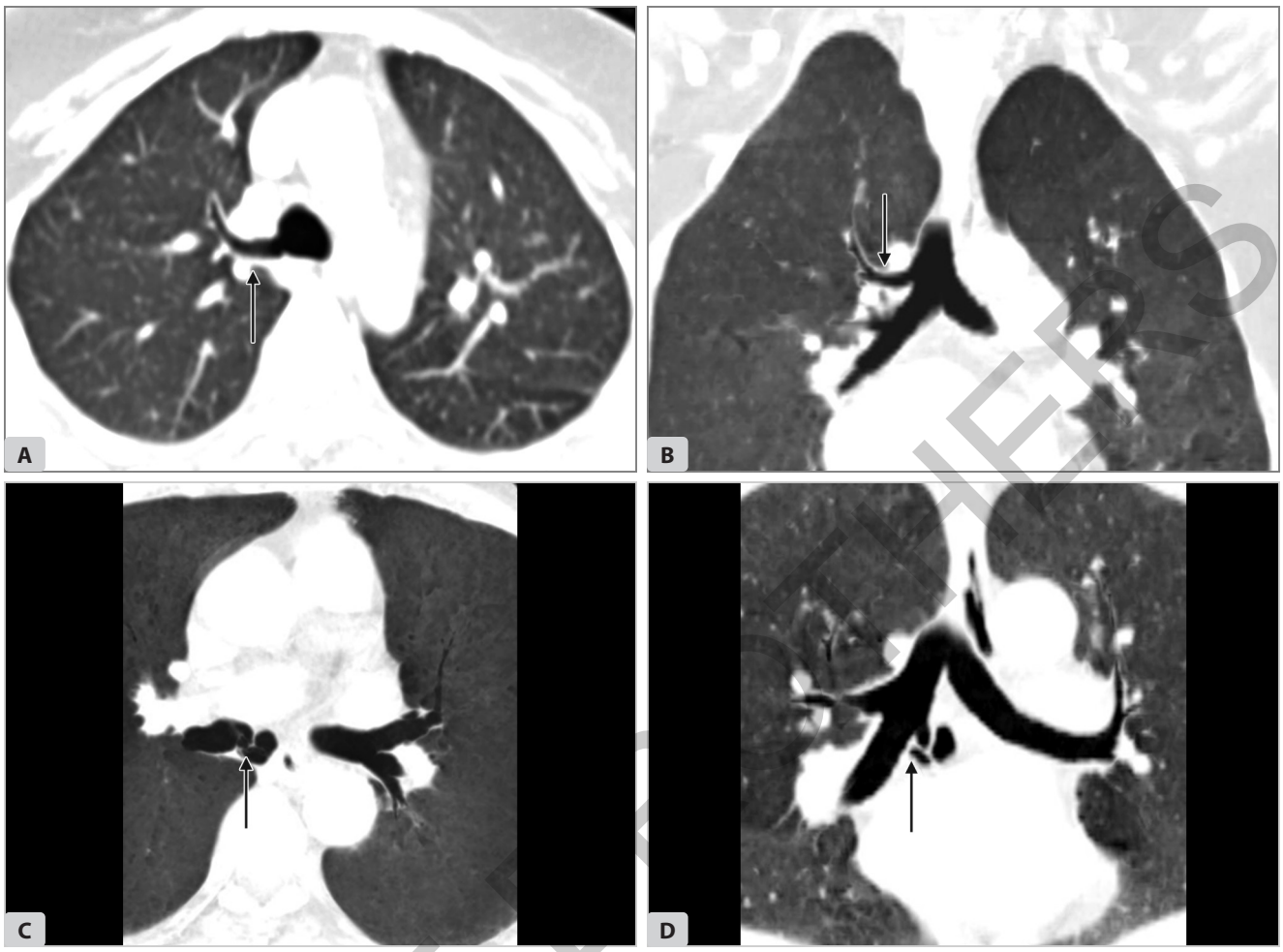

FIGS. 21A TO D: Tracheal bronchus: Axial lung window (A) and coronal minimum intensity projection (minIP) (B) reveal an accessory bronchus arising from the trachea and aerating the posterior segment of right upper lobe (black arrows). (C and D) Cardiac bronchus: Accessory bronchus arising from the medial wall of the right mainstem bronchus, grows toward the pericardium terminating as a blind-ending stump (black arrows).

Table 5: Lobe-based classification of tracheobronchial anomalies.

Categories of tracheo-bronchial anomaly	***Entities***
Bronchial situs anomalies/anomalies of entire lung	• Right isomerism • Left isomerism • Situs inversus
Upper lobe	• Tracheal bronchus • Right preeparterial bronchus • Right posteparterial bronchus • Left eparterial bronchus • Left prehyparterial bronchus
Middle lobe	Gross upward displacement of middle lobe bronchus
Lower lobes	Suprasuperior bronchus
Others	• Accessory cardiac bronchus • Types 1 and 2 bridging bronchus

et al. reported a 100% sensitivity and specificity of CT in the evaluation of endobronchial FBs.[33] Applegate et al. while evaluating low-dose helical CT found a sensitivity of 83% and specificity of 89% for visualizing plastic pieces in the airway. Peanuts, however, were not well-visualized in the same study.[34] Indirect findings of FB in TB tree are described in **Table 6**. Even esophageal FBs can present acutely with symptoms related to airway compression or with complications consequent to perforation and neck and/or mediastinal infection **(Flowchart 3)**.

Mucous plugs: Mucous plugs are another cause of intraluminal airway obstruction and result from inspissation of bronchial secretion. Compared to adults, these are infrequent in children but can be encountered in those with impaired cough reflex, cystic fibrosis, primary ciliary dyskinesia, or asthma. The most common site of impaction is the major bronchi and an acute presentation is more common than chronic one. On imaging, mucous

JAYPEE BROTHERS

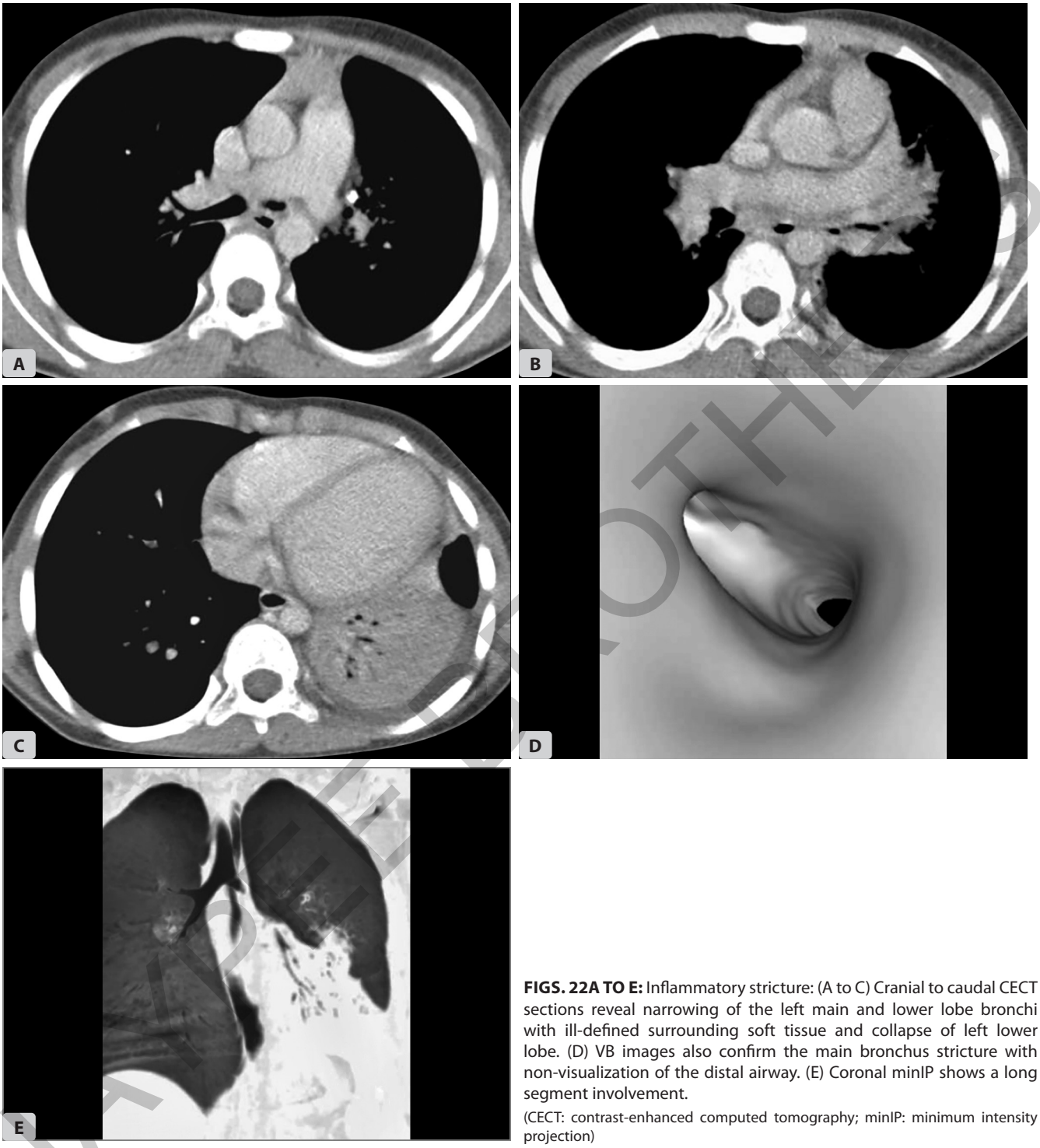

FIGS. 22A TO E: Inflammatory stricture: (A to C) Cranial to caudal CECT sections reveal narrowing of the left main and lower lobe bronchi with ill-defined surrounding soft tissue and collapse of left lower lobe. (D) VB images also confirm the main bronchus stricture with non-visualization of the distal airway. (E) Coronal minIP shows a long segment involvement.

(CECT: contrast-enhanced computed tomography; minIP: minimum intensity projection)

plugs appear very similar to an organic FB, i.e., both have low attenuation and may display trapped air foci or a strand-like linear pattern. The secondary causes of obstruction are also seen; however, atelectasis and postobstructive pneumonia are far more common with mucous plugs; unlike air trapping is more frequent in FB.[35]

Tuberculosis: Occasionally, enlarged lymph nodes erode into the bronchus and result in endobronchial fibrosis or luminal occlusion. Intraluminal granulomas may occur in the trachea or bronchi. Airway involvement in tuberculosis may be seen in up to 30% of cases.[36,37]

Tumors: Tracheal soft-tissue masses include tracheal papilloma while bronchial masses may be carcinoid tumors. Carcinoid tumor is the most common among these. Rare lesions include adenoid cystic carcinoma, mucoepidermoid carcinoma, inflammatory

JAYPEE BROTHERS

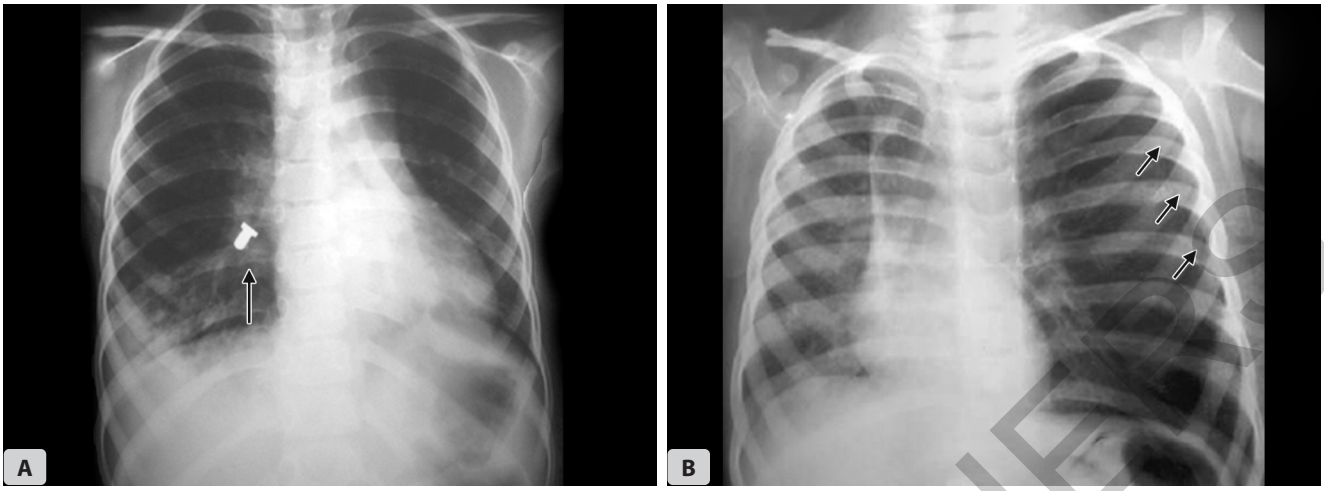

FIGS. 23A AND B: Foreign body: (A) Chest radiograph demonstrates a radiopaque foreign body in the right lower lobe bronchus with consolidation in the distal lung (black arrow); and (B) Chest radiograph of a 2-year-old boy with history of foreign body aspiration and sudden-onset respiratory distress reveals a hyperinflated left lung with spontaneous pneumothorax (short black arrows) and extensive subcutaneous emphysema.

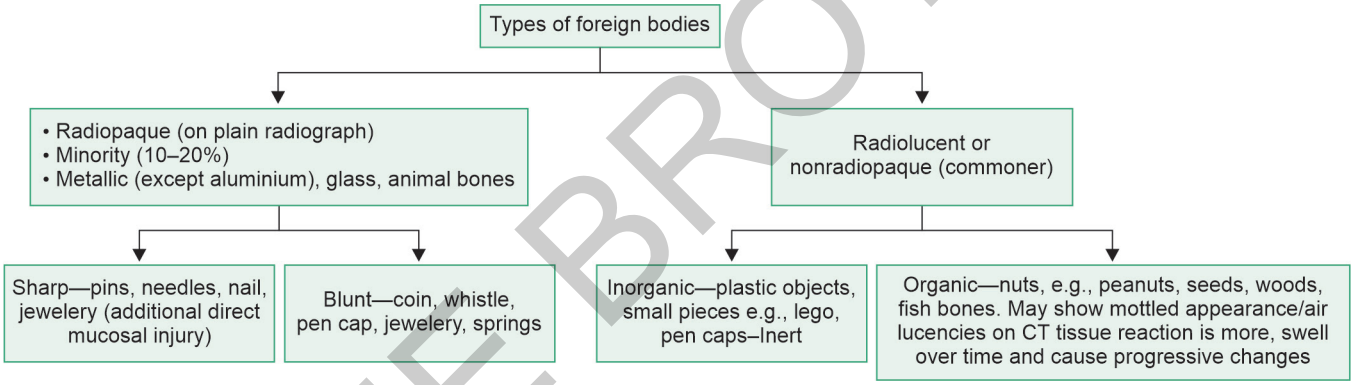

FLOWCHART 2: Types of foreign body (FB).



FIGS. 24A TO D: *Continued*

HYPEE BROTHERS

Continued

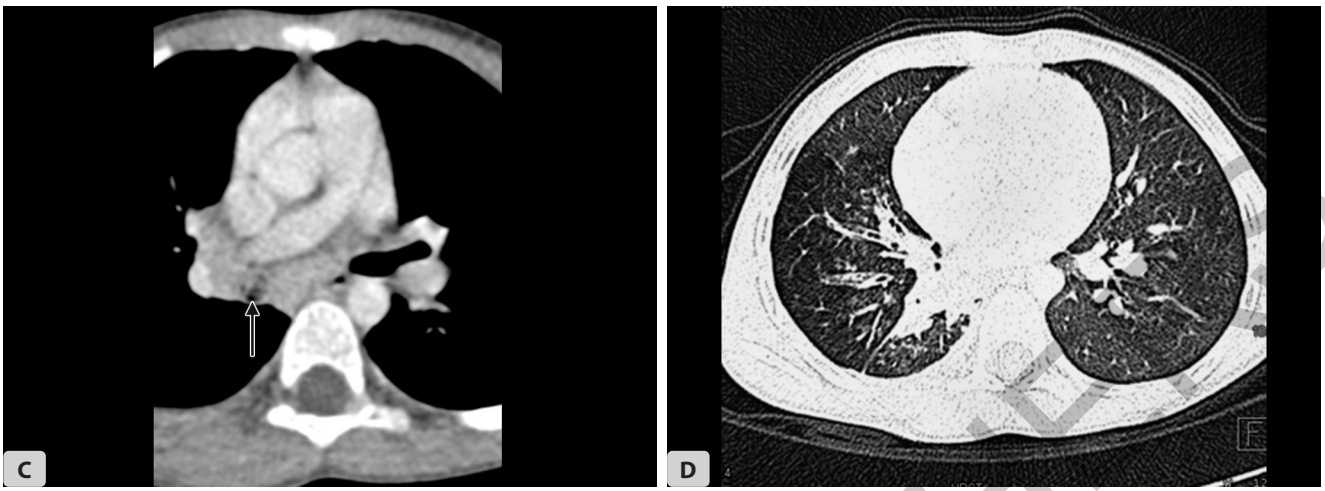

FIGS. 24A TO D: Foreign body: (A) Chest radiograph of a 6-year-old boy with history of recurrent high-grade fever reveals right paracardiac opacities with tram-track lesions. (B to D) CT scan reveals abrupt cutoff of the right bronchus intermedius with intraluminal contents (arrow) and distal bronchiectasis. A peanut was removed on bronchoscopy.

Table 6: Indirect findings of foreign body (FB) in tracheobronchial tree.

Complications	***Imaging findings***
• Hyperinflation/air trapping (due to ball-valve mechanism of obstruction) • Most common	• Seen in both acute/chronic FB aspiration • Unilateral/segmental/bilateral (in tracheal FB) • Involved lung increased in volume • Fixity of volume on dynamic or multiphasic imaging (fluoroscopy, inspiratory-expiratory, or decubitus imaging) • Limited diaphragmatic excursion • Hyperlucent lung (due to air and resultant oligemia) • Mediastinal shift ±
• Atelectasis • Postobstructive pneumonia • Seen in about one-fourth of cases	• More frequent in chronic or delayed presentation • Increase lung density with volume loss • Air bronchogram may be present in early cases or partial obstruction • "Shifting atelectasis" if FB migrates
Combination of hyperinflation and atelectasis in same hemithorax	• As lung adjacent to atelectasis will hyperinflate • Nonspecific, seen in any airway obstruction
Bronchiectasis	In delayed/chronic presentation
Air leaks: • Pneumothorax • Pneumomediastinum • Subcutaneous emphysema • Epidural emphysema (pneumorrhachis)—very rare	• Rare • Due to rupture of alveoli as intrathoracic pressure increases • Even more rarely due to direct perforation of TB tree (sharp objects)

myofibroblastic tumor, juvenile xanthogranuloma, and metastasis.[37-40] Carcinoid tumors comprise about 80% of endobronchial neoplasms in children and adolescents. These present in children or young adults and may be associated with neuroendocrine secretion. Most carcinoid tumors occur in the mainstem or lobar bronchi and patients present with dyspnea, wheezing, cough, or hemoptysis. CT reveals typically intensely enhancing, ovoid lesions with a long axis parallel to the bronchovascular bundle. These lesions may have intraluminal, mural, and extrabronchial components. Associated collapse, consolidation, or air trapping is often seen **(Figs. 25A to C)**. They are relatively slow-growing masses and complete surgical resection offers the best chance of cure.

Plastic bronchitis: It is a rare disorder characterized by formation of branching endobronchial casts that obstruct

JAYPEE BROTHERS

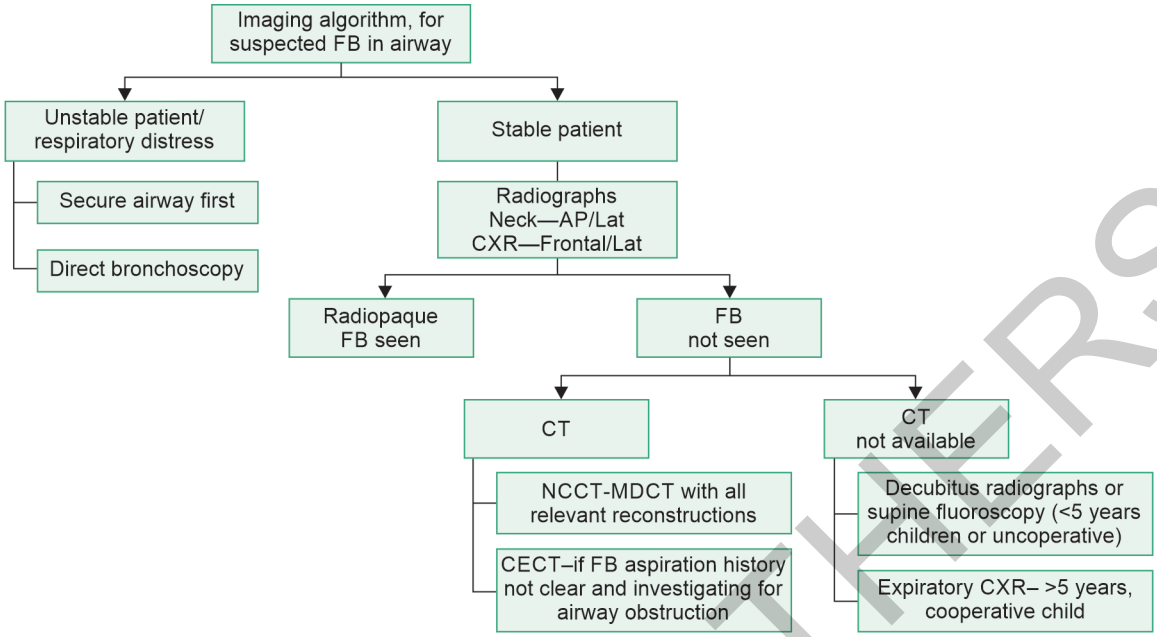

FLOWCHART 3: Imaging algorithm for suspected foreign body (FB) in airway.

(AP: anteroposterior; CECT: contrast-enhanced computed tomography; CXR: chest X-ray; MDCT: multidetector computed tomography; NCCT: non-contrast-enhanced computed tomography)

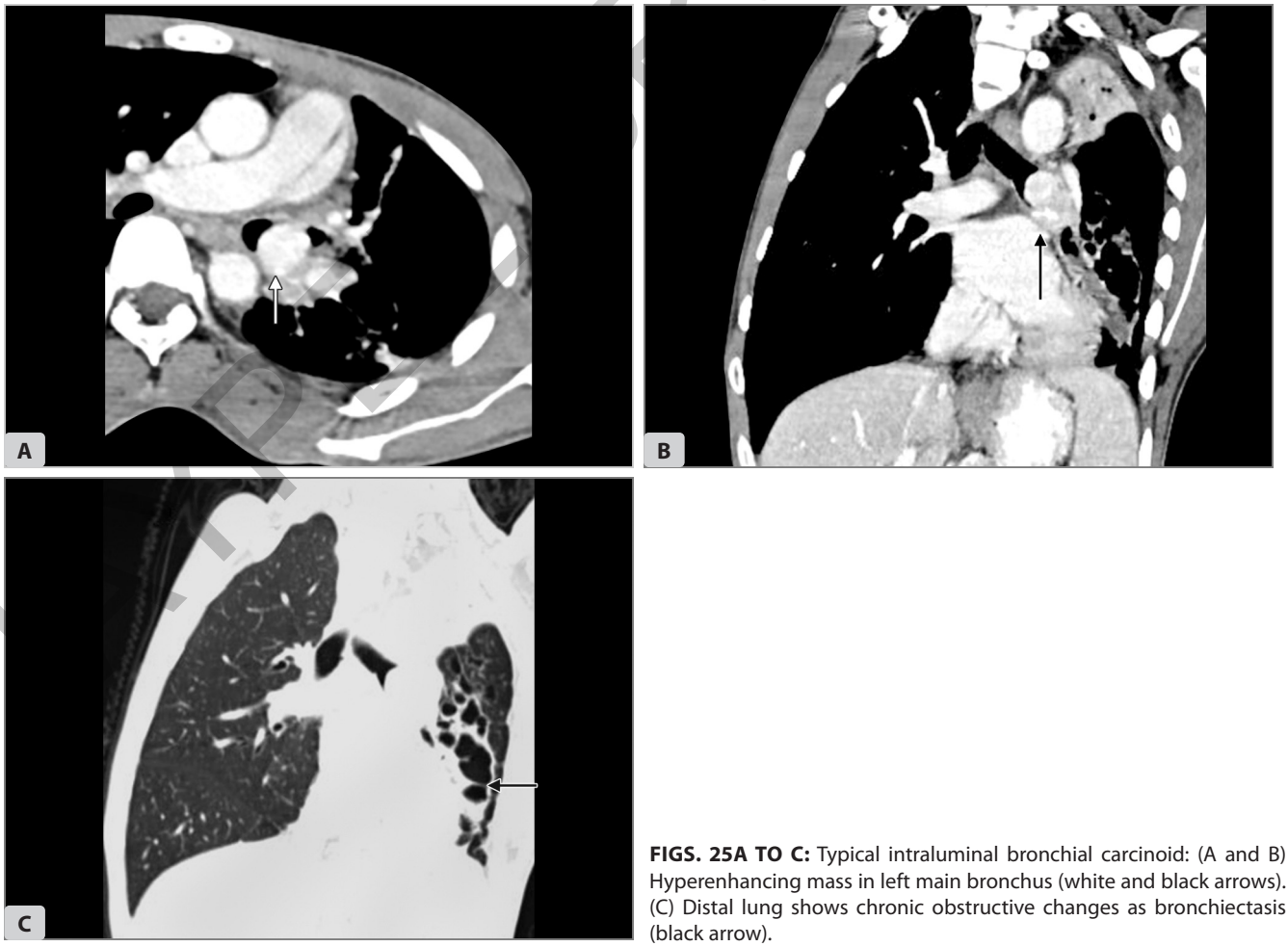

FIGS. 25A TO C: Typical intraluminal bronchial carcinoid: (A and B) Hyperenhancing mass in left main bronchus (white and black arrows). (C) Distal lung shows chronic obstructive changes as bronchiectasis (black arrow).

JAYPEE BROTHERS

or detailed information on radiology books, visit our website www.ejaypee.com, for detailed information on radiology books, visit our website www.ejaypee.com, for detailed informatio

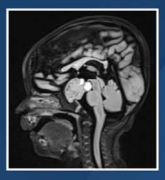

AIIMS-MAMC-PGI IMAGING SERIES

DIAGNOSTIC RADIOLOGY

Paediatric Imaging

This fifth edition of "Paediatric Imaging" marks a significant milestone in a journey that began in 1996. Born from a unique, collaborative venture among three of India's premier institutions—AIIMS (New Delhi), MAMC (New Delhi), and PGIMER (Chandigarh)—this series was established with a single vision to standardize and elevate radiology teaching nationwide. Having successfully navigated four complete series covering various organ systems, we are proud to introduce the fourth course of our fifth series.

The hallmark of these highly popular courses has always been the accompanying textbook, recognized for providing state-of-the-art knowledge in the field. However, the rapid pace of technological innovation—moving from structural observation to molecular, data-driven insights—has necessitated this reorganized volume. This edition transcends simple morphology to embrace the future of the subspecialty, incorporating precision diagnostics and the genetic signatures of paediatric oncology. There is a renewed focus on the biological differences of the child, emphasizing radiation sensitivity and the ALARA principle. Artificial Intelligence has been highlighted as an integral tool for day-to-day practice for dose reduction, triage, and quantitative imaging.

Designed as an essential bridge between the imager and the clinician, this book is a reference for Residents, practicing Radiologists, Paediatricians, and Paediatric Surgeons alike. Whether used as a foundational guide for postgraduates or a definitive manual for seasoned practitioners, this text will ensure that the latest guidelines and protocols are always at your fingertips.



Raju Sharma
AIIMS, New Delhi



Gaurav Shanker Pradhan
MAMC, New Delhi



Paramjeet Singh
PGI, Chandigarh

Buy from ejaypee

JAYPEE BROTHERS

Shelving Recommendation
RADIOLOGY

ISBN 978-93-7202-315-2

9 789372 023152